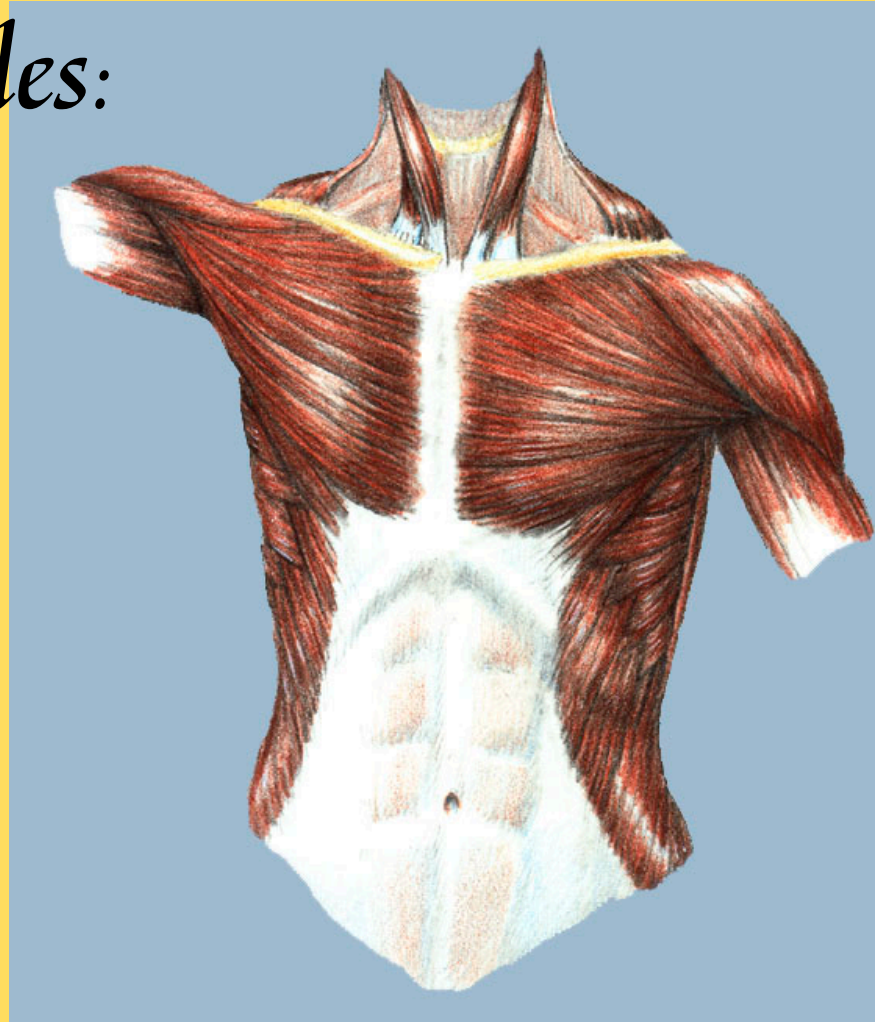




# *Bones and Muscles: An Illustrated Anatomy*

Written and Illustrated by  
Virginia Cantarella



## *Table of Contents*

Acknowledgements	3
Introduction	4
List of Illustrations	5
List of Terms	10
Head and Neck	11
Shoulder	46
Arm and Hand	56
Back and Thorax	97
Abdomen and Pelvis	121
Leg and Foot	142

Copyright © 1999 Virginia Cantarella  
Published by Wolf Fly Press, South Westerlo, New York

All rights reserved. No part of this book may be reproduced, transmitted or stored in a retrieval system without the prior written consent of the publisher.

For information on ordering this book contact the publisher at:  
Wolf Fly Press  
P.O. Box 719  
Greenville, New York 12083  
ginger@capital.net

Written and illustrated by Virginia Cantarella  
Design by Virginia Cantarella, Publisher  
Edited by Marilyn Hagberg  
PDF production by Subtext Communications

## *Acknowledgements*

There are many people to whom I feel deep gratitude for helping me realize this book. First is Barbara Hollis, who asked me to help her learn the muscles and their origins and insertions as she was studying to become a massage therapist. I did drawings for her. While doing them, it occurred to me that one could make an illustrated book from which others might be able to learn. I am deeply grateful to Marilyn Hagberg, fellow artist and journalist, who spent months editing the text. Erica Manfred suggested to me that I self-publish this work as an ebook and introduced me to the people who could help me learn how to do it. I am most grateful to Dr. Greg La Trenta who went over all the artwork checking it for accuracy. Thanks to Laurie Burke, who, by email and telephone guided me in the making of this book. Thanks to our children who have helped, guided and encouraged me. Finally, there is my husband, Herman Shonbrun, who encouraged me all the way and put up with my long hours at the computer.

## *Bones and Muscles: An Illustrated Anatomy*

*Bones and Muscles: An Illustrated Anatomy* is designed for professionals who work with the body—for physical therapists and massage therapists, as well as for students, professors of anatomy, and physicians. People who are interested in aerobics, dance, or sports and are interested in their musculature will find this book informative. Additionally, artists interested in drawing the figure would benefit from studying it.

Going from the top to the bottom—from head to toe—I shall illustrate all of our bones and voluntary muscles. For each part of the body I illustrate the bones involved, and with drawings and text show how and where the muscles attach to them.

In making my drawings I have referred to *Gray's Anatomy*, long considered the definitive anatomy book, Frank Netter's *Atlas of Human Anatomy*, *Grant's Atlas of Anatomy*, Carmine D. Clemente's *Anatomy—A Regional Atlas of the Human Body*,

and R.M. H. McMinn and R. T. Hutching's *Color Atlas of Human Anatomy* and finally Werner Spalteholz's *Hand Atlas of Human Anatomy*. I have also worked from my own drawings done from dissections. I have done the skeleton drawings from my own skulls, backbone and pelvis, other bones loaned by friends, and from whole skeletons owned by acquaintances.

## *List of Illustrations*

1	The skull from a 3/4 frontal view	p.12		15	The digastric muscle	p.30
2	The skull seen from the side	p.14		16	The styloid muscle	p.31
3	The frontalis and the occipital muscles	p.15		17	The mylohyoid muscle	p.32
4	The corrugator supercilii and the procerus muscles	p.17		18	The goniohyoid muscle	p.33
5	The palpebral levator superioris muscle	p.18		19	The thyrohyoid muscle The sternothyroid muscle	p.34
6	The orbicularis oculi muscle	p.19		20	The sternohyoid and omohyoid muscle	p.35
7	The auricularis muscles	p.20		21	The bones of the neck, interior-frontal view	p.36
8	The nasalis muscle The depressor septi muscle	p.21		22	The skull, neck and upper back, posterior view	p.37
9	The orbicularis oris muscle The buccinator muscle The levator anguli oris muscle	p.22		23	The sternocleidomastoid muscle	p.38
10	The zygomaticus major muscle The zygomaticus minor muscle The levator labii superioris muscle The levator anguli oris muscle The levator labii superioris alaeque nasi muscle The depressor anguli oris muscle The deppressor labii inferioris muscle The mentalis muscle The risorious muscle	p.24		24	The rectus capitis lateralis muscles The rectus capitis anterior muscles	p.39
11	The temporalis muscle	p.26		25	The rectus capitis posterior minor muscle The rectus capitis posterior major muscle The obliquus capitis superior muscle The obliquus capitis inferior muscle	p.40
12	The masseter muscle	p.27		26	The scalenus muscles	p.42
13	The pterygoid muscles	p.28		27	The longus colli muscle The longus capitis muscle	p.43
14	The bones of the neck	p.29		28	The platysma muscle	p.45
				29	The bones of the shoulder, anterior view	p.47
				30	The bones of the shoulder posterior view	p.48

31	The levator scapulae The rhomboideus major muscle	p.49	47	The flexor pollicis longus muscle	p.69
32	The teres minor muscle The teres major muscle	p.51	48	The flexor digitorum profundus muscle	p.71
33	The supraspinatus muscle The infraspinatus muscle	p.52	49	The flexor digitorum superficialis muscle	p.72
34	The subscapularis muscle	p.53	50	The flexor carpi ulnaris muscle, anterior and posterior views	p.73
35	The deltoid muscle	p.54	51	The palmaris longus muscle	p.74
36	The trapezius muscle	p.55	52	The flexor carpi radialis muscle	p.75
37	The bones of the right arm and hand with shoulder and two ribs, anterior view; The same bones without the ribs, posterior view	p.57	53	The abductor pollicis longus muscle	p.76
38	The humerus, the clavicle, the rib cage the sternum, and the scapula: anterior view	p.58	54	The extensor pollicis brevis muscle	p.77
39	The pectoralis major muscle	p.60	55	The extensor pollicis longus muscle	p.78
40	The latissimus dorsi muscle	p.61	56	The extensor indicis muscle	p.79
41	The coracobrachialis muscle The brachialis muscle	p.62	57	The brachioradialis muscle	p.80
42	The biceps brachii muscle	p.63	58	The extensor carpi radialis longus muscle	p.81
43	The triceps brachii muscle	p.64	59	The extensor carpi ulnaris muscle The extensor carpi radialis brevis muscle	p.82
44	The elbow and forearm from the palmer view The elbow and forearm from the dorsal view	p.65	60	The extensor digitorum muscle The extensor digiti minimi muscle	p.83
45	The pronator teres muscle The pronator quadratus muscle The supinator muscle	p.66	61	The bones of the right hand and wrist, palmar view	p.85
46	Anconeus muscle	p.68	62	The bones of the hand, dorsal view	p.86
			63	The dorsal interossei muscles	p.87
			64	The interossei palmares muscles	p.88
			65	The lumbricales muscles of the hand	p.89
			66	The opponens digiti minimi muscle	p.90

67	The flexor digiti minimi brevis muscle	p.91	84	The ribcage and the spinal column, showing the sixth cervical vertebra, the twelve thoracic vertebrae, and the first lumbar vertebrae, posterior view	p.112
68	The abductor digiti minimi muscle	p.92	85	The rib cage or thorax with the twelve thoracic vertebrae, left lateral view	p.113
69	The adductor pollicis muscle	p.93	86	The transverse thoracic muscle	p.114
70	The opponens pollicis muscle The palmaris brevis muscle	p.94	87	The intercostales interni muscles	p.115
71	The flexor pollicis brevis muscle	p.95	88	The intercostales externi muscles	p.116
72	The abductor pollicis brevis muscle	p.96	89	The serratus anterior muscle	p.117
73	The bones of the back	p.97	90	The serratus posterior muscles, superior and inferior	p.118
74	Three views of the tenth and eleventh thoracic vertebrae	p.99	91	The levatores costorum muscles	p.119
75	The splenius capitis muscle The splenius cervicis muscle	p.101	92	The pectoralis minor muscle The subclavius muscle	p.120
76	The transversospinales muscles The rotatores brevis and the rotatores longus muscles The intertransversarii muscles The interspinales muscles	p. 102	93	The torso from a three quarter front view; the ribcage with the sternum, scapula and humerus; the spinal column with the sacrum, showing how it articulates with the pelvis; the top of the femur, showing how it articulates with the pelvis	p.122
77	The multifidus muscle	p. 104	94	The torso seen from the side	p.123
78	The semispinales muscles	p. 105	95	The rectus abdominis muscle	p.124
79	The spinales muscles	p. 106	96	The transversus abdominis muscle	p.126
80	The longissimus dorsi muscle	p.107	97	The obliquus internus abdominis muscle	p.127
81	The iliocostalis muscle	p.109	98	The obliquus externus abdominis muscle	p.128
82	The thorax or rib cage	p.110	99	The quadratus lumborum muscle	p.129
83	The sternum, the costal cartilages and part of ten ribs, ventral view	p.111			



100	The pelvis, anterior view	p.131	115	The gracilis muscle	p.148
101	The right innominate bone, lateral view The right innominate bone, medial view	p.132	116	The vastus intermedius The vastus lateralis The vastus medialis muscles	p.149
102	The pelvis, posterior inferior view, showing the head of the femur in the acetabum; The pelvis, anterior inferior view, showing the top portion of the femur with its head in the acetabulum	p.133	117	The rectus femoris muscle	p.151
103	The psoas major muscle The psoas minor muscle The iliacus muscle	p.134	118	The sartorius muscle	p.152
104	The obturator externus muscle	p.136	119	The tensor fasciae latae muscle	p.153
105	The obturator internus muscle The gemellus muscle, superior and inferior The quadratus femoris muscle The piriformis muscle	p.137	120	The biceps femoris muscle	p.154
106	The gluteus minimus muscle	p.139	121	The semitendinosus muscle	p.155
107	The gluteus medius muscle	p.140	122	The semimembranosus muscle	p.156
108	The gluteus maximus muscle	p.141	123	The bones of the lower leg, anterior and posterior views	p.158
109	The bones of the right leg and pelvis, anterior and posterior views	p.142	124	The popliteus muscle	p.160
110	The bones of the right thigh, anterior and posterior views	p.143	125	The plantaris muscle	p.161
111	The adductor magnus and adductor minimus muscle	p.144	126	The extensor digitorum longus muscle The fibula tertius muscle	p.163
112	The adductor brevis muscle	p.145	127	The flexor hallucis longus muscle	p.165
113	The adductor longus muscle	p.146	128	The tibialis anteriore muscle	p.166
114	The pectineus muscle	p.147	129	The peroneus (fibula) brevis muscle The peroneus (fibula) longus muscle	p.167
			130	The tibialis posteriore muscle	p.169
			131	The flexor hallucis longus muscle	p.170
			132	The flexor digitorum longus muscle	p.171

133	The medial and lateral aspect of the foot showing the tendinous extensions of all the flexor and extensor muscles on the lower leg which control the movement of the foot and ankle and the retinaculae which keep them in place	p.172
134	The soleus muscle	p.173
135	The gastrocnemius muscle	p.174
136	The bones of the foot, dorsal view	p.176
137	The bones of the foot, plantar view	p.177
138	The bones of the foot, medial view The bones of the foot lateral view	p.178
139	The dorsal interossei muscles	p.179
140	The extensor digitorum brevis muscle	p.180
141	The plantar interossei muscles	p.181
142	The flexor hallucis brevis muscle The flexor digiti minimi brevis muscle	p.182
143	The adductor hallucis muscle	p.183
144	The lumbricales muscles The quadratus plantae muscle	p.185
145	The abductor hallucis muscle The abductor digiti minimi muscle	p.187
146	The flexor digitorum brevis muscle	p.188

## *List of Terms*

### **TERMS DESCRIBING POSITIONS**

Superior: above

Inferior: below

Lateral: to the outside

Medial: toward the middle

Anterior: in front

Posterior: in back

Nasal: toward the nose

Ventral: on the side of the stomach

Dorsal: on the side of the back

Caudal: at or near the tail, or where the tail would be

Superficial: outermost layer

### **TERMS DESCRIBING MOVEMENT**

Abduction: a moving away from the body or the median axis

Adduction: a moving toward the body or the median axis

Extension: the straightening of a limb or body part

Flexion: the bending of a limb or body part

Rotation: the turning of a limb or body part

### **TERMS DESCRIBING MUSCLES**

Belly: the body of the muscle, the fattest part

Heads: Some muscles arise as two or more bodies and merge into one tendon. The bodies are called heads.

### **TERMS DESCRIBING BONES**

Foramen: a small opening or hole

Fossa: a cavity

Process: a projection or outgrowth from a larger structure

Tubercle, tuberosity: a rough rounded prominence or

Elevation: (not as big as a process)

# *Head and Neck*

## **HEAD**

There are some features unique to the skull. The individual bones do not always dictate the larger shapes of the skull. A suture, or meeting of two different bones, is found in the middle of a larger form. You can see this meeting particularly in the zygomatic arch as well as in the ocular orbit.

The frontal bone, the ethmoid and the maxilla have within them empty spaces called sinuses. The ethmoid bone, if cut in half, looks like a cluster of bubbles, and the walls of the sinuses are almost as thin as the wall of a bubble and are very fragile. If the skull were solid bone it would be so heavy you wouldn't be able to hold your head up. By having empty spaces within the bones and therefore making them lighter, the sinuses are nature's way of solving that problem. They can present other problems, however, for they are lined with mucous membranes that can become infected and get clogged up. Each sinus has a small opening into the nasal cavity which allows drainage.

## Head and Neck Illustration I

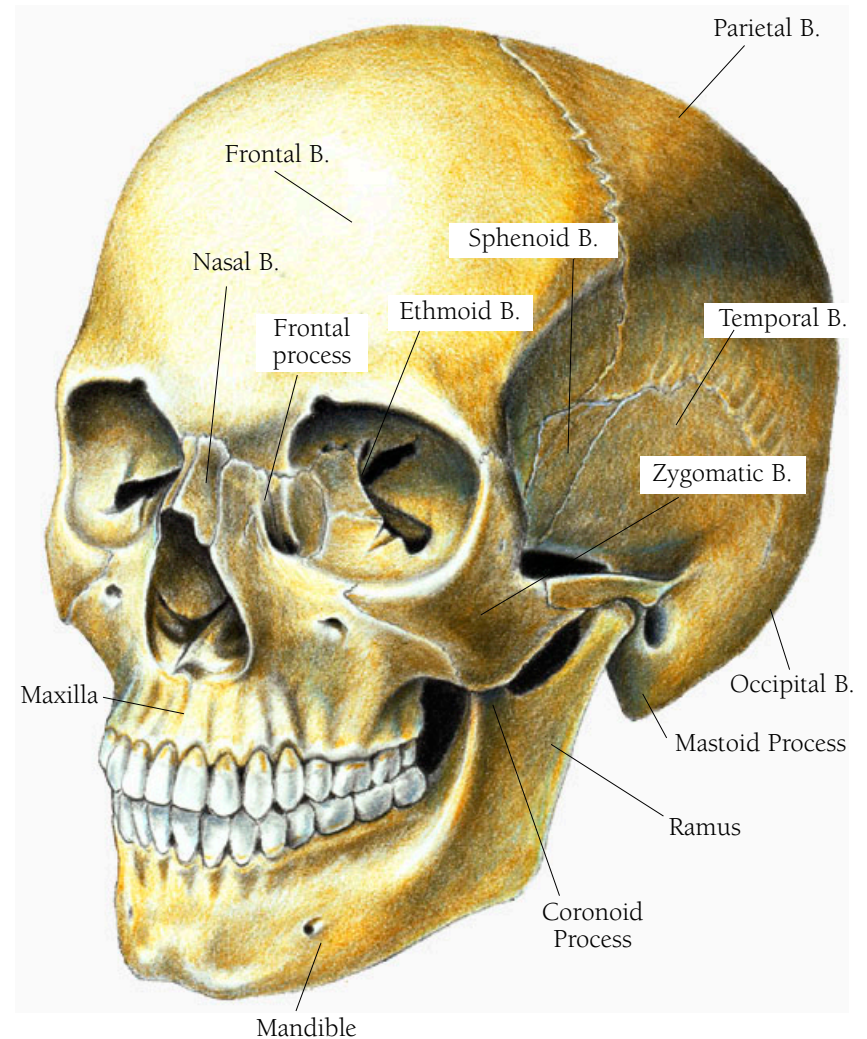
### THE SKULL FROM A $\frac{3}{4}$ FRONTAL VIEW

The skull is made up of 19 bones, 12 of which are pairs. You can see most of these bones in the illustration. Where the bones join is called a suture. Little fingers of bone interdigitate with adjoining little fingers to make the joining solid. The bones shown are: the frontal bone, the nasal bones, the lacrimal bones, the ethmoid bones, the sphenoid bones, the zygomatic bones, the maxilla, the mandible, the parietal bones, the temporal bones, the occipital bone, the palatine bones (not seen, since they are inside the orbit of the eye), and the vomer (not seen, since it is inside the nasal cavity).

There are two bones that you cannot see in the illustration, the palatine and the vomer. The palatine bones are paired and are buried deep in the skull behind the nose. They make up the rear part of the palate, part of the base of the nasal cavity, and a small part of the floor of the orbit. The vomer is a thin bone which forms part of the nasal septum separating the two sides of the nasal cavity.

• • •

Lacrimal, meaning tear producing, is from the Latin *lachrymal*, meaning a small vase, of the kind found in ancient Roman sepulchers that was used for collecting tears shed in



THE SKULL

mourning. (The lacrimal bone forms half of the receptacle, which holds the lacrimal sac, a structure that receives the tears and directs them into the nasal cavity. That explains why we blow our noses in cold weather, or when we cry, we are blowing out the tears that have drained into the cavity. The other half of the receptacle for the lacrimal sac is made from the frontal process of the maxilla.) Ethmoid, so-named because it is full of holes, is from the Greek *ethmo* and *oiedes*, meaning “formed like a strainer.” Sphenoid is from the Greek *spheno* and *eidōs* together meaning wedge-shaped. Zygomatic or zygoma comes from the Greek *zygon*, which means yoke, the kind used to harness oxen. *Maxilla* is from the Latin *mala* meaning jaw, particularly the upper jaw. Mandible derives from the Latin *mandibula*, which stems from *mandare* meaning to chew and pertains particularly to the lower jaw, which has most of the chewing motion. Parietal is from the Latin *paries*, *parietes*, meaning “walls of a hollow cavity.” Temporal indicates the temple, from the Latin *tempora*, meaning “temple, the right place, the fatal spot..” (As well as indicating a place on the skull where death can easily be afflicted, this word conveys a sense of reverence for life.) Occipital is from the Latin *occiput*, meaning “the back of the head.” Palatine is from the Latin *palatum*, meaning the hard palate and is the base for the words palatable and palliative. *Vomer* is the Latin word for plowshare.

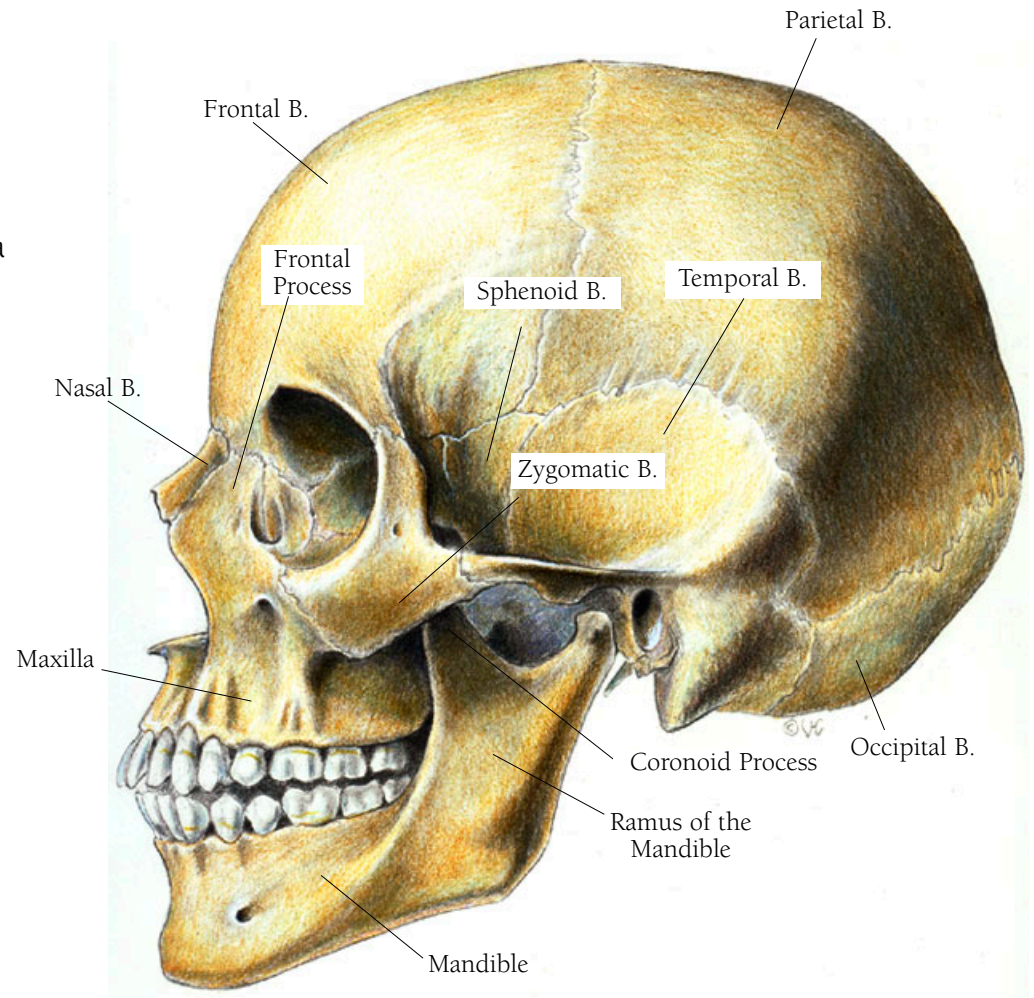
## Head and Neck Illustration 2

### THE SKULL SEEN FROM THE SIDE

Here you can clearly see the temporal region and the ramus of the mandible. The frontal process of the maxilla should not be confused with the frontal bone. A process, which is a projection from a larger structure, is less important than a ramus.

• • •

*Ramus* comes from the Latin word for branch.



THE SKULL

## Head and Neck Illustration 3

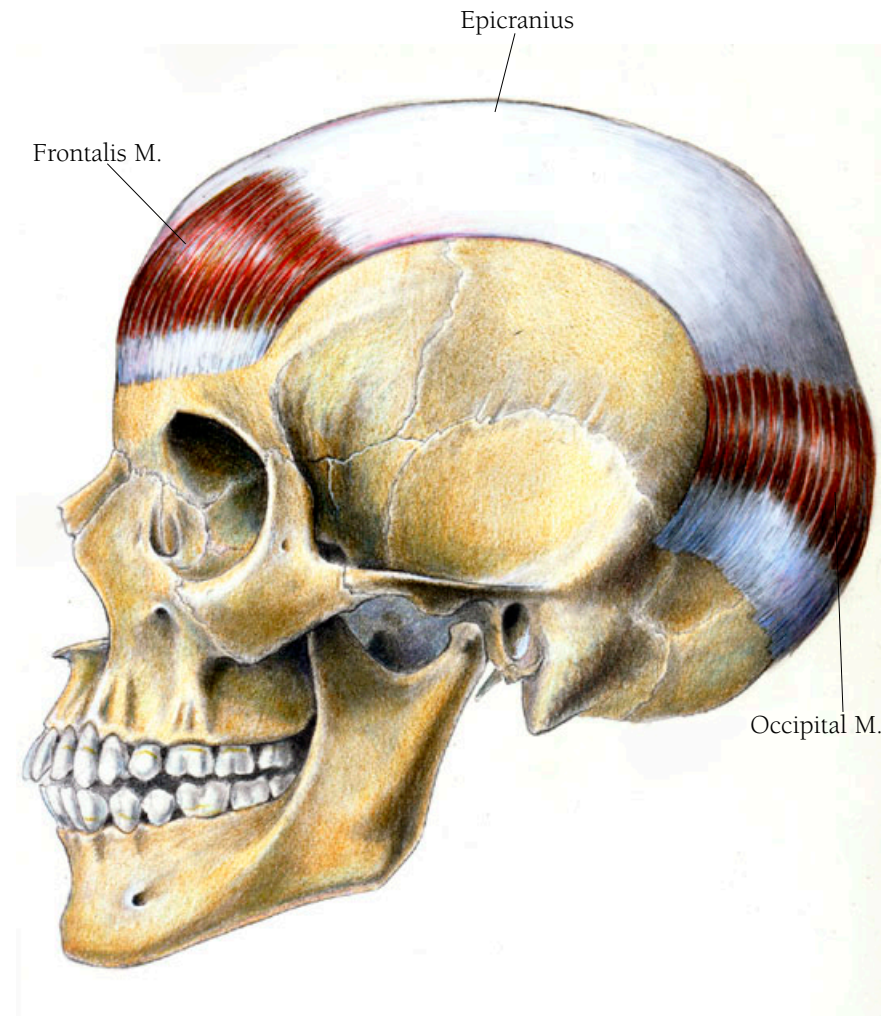
### THE FRONTALIS AND THE OCCIPITAL MUSCLES

Both part of the epicranium, these muscles create expressions of surprise and fright by tightening the entire scalp. The epicranium is a broad sheet of muscle and aponeurotic tissue covering the top, the front, and the back of the head.

Aponeurotic tissue, or an aponeurosis, is a broad, glistening white tendinous tissue. On the head it is known as the galea aponeurotica. In front (anteriorly) it becomes the frontalis muscle. The frontalis muscle arises out of muscles that are over the bridge of the nose—the procerus, the corrugator supercilii muscles, and the orbicularis oculi muscle—and inserts into the posterior edge of the galea aponeurotica. The galea aponeurotica travels over the top of the skull. The occipitalis muscle arises along the superior nuchal line at the base of the occipital bone of the skull and courses upward to insert into the posterior edge of the galea.

• • •

Occipitalis comes from two Latin words: *ob*, meaning over or against, and *caput*, meaning head. Galea derives from the Latin word for helmet. Aponeurosis is from the Greek *apo-*, meaning from and *neuro*, meaning nerve.



THE EPICRANIUM



In their anatomy studies both the Greeks and Romans confused nerve tissue with tendons and ligaments, which looked similar, all three being white and glistening. It took until later centuries for the function of the nerves to be understood.

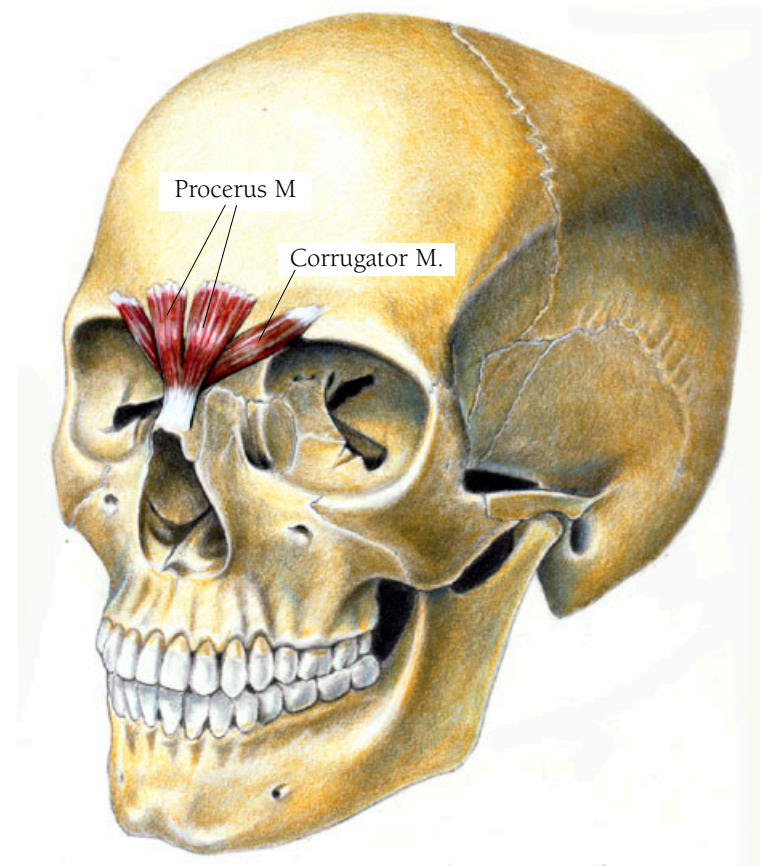
## Head and Neck Illustration 4

### THE CORRUGATOR SUPERCILII AND THE PROCERUS MUSCLES

These are the frowning muscles. Both have fibers that originate with the frontalis muscle and insert just above the root of the nose.

• • •

Corrugator comes from the Latin meaning to wrinkle. *Supercilii* is from the Latin, meaning hairs above the eyelashes or the eyebrows. *Super-* or *supra-* are frequently used prefixes meaning above something. *Cilia* in Latin refers to the lashes of the lid. *Procerus* is Greek, meaning “before the horn.”



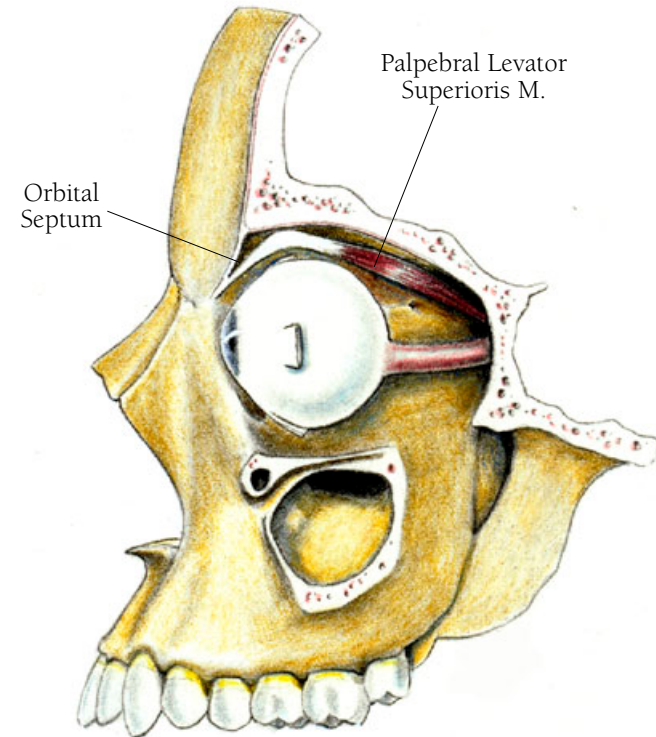
## Head and Neck Illustration 5

### THE PALPEBRAL LEVATOR SUPERIORIS MUSCLE

This muscle lifts the upper lid in the second part of the blinking action and maintains the correct level of the upper lid when the eye is open. The levator, as this muscle is commonly called, arises from the small wing of the sphenoid bone, at the apex of its orbit. It then courses forward, broadening out over the eye and its muscles. At this point the muscle fibers become an aponeurosis which bends over the front of the eye as it blends with the orbital septum. It ends as many tiny fiber-like attachments to the inner surface of the skin of the lids forming the lid crease. The septum separates the contents of the orbit from the exterior lid structures and helps to hold the contents of the orbit in place. The levator passes through the barrier created by the septum without compromising its function.

• • •

*Septum* is Latin for hedge, barrier, or fence. *Palpebral levator superioris* in Latin means “upper eyelid lifter.”



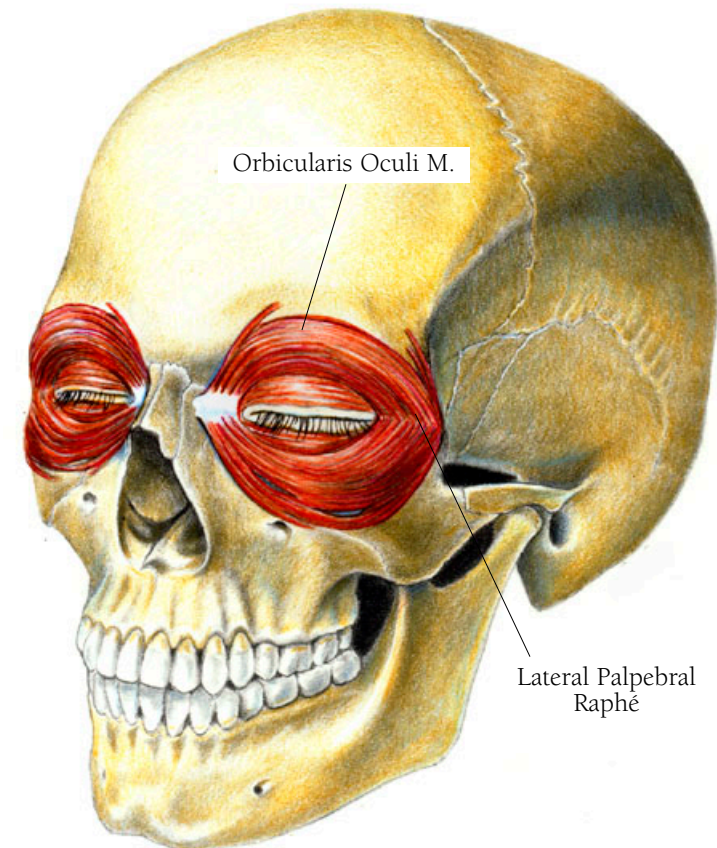
## Head and Neck Illustration 6

### THE ORBICULARIS OCULI MUSCLE

This muscle, which closes the lids when blinking and allows you to squint or wink your eye, is one of two muscles that affect the functions of the lids. (The palpebral levator superioris opens the lids. See p.18.) Fibers of the orbicularis lie right over the entrance to the lacrimal sac, and when the eye blinks they aid in pressing the tears down into the lacrimal sac. The muscle has fibers that form two semicircles, one above and one below the eye. These fibers arise on the nasal part of the frontal bone, on the frontal process of the maxilla in front of the lacrimal groove, and on the borders of the medial canthal tendon. They insert at the outer edge of the eye into the lateral palpebral raphé. A raphé is an interdigitation of fibers, in this case the fibers that come from beneath and above the eye.

• • •

*Orbicularis* is Latin for disk.



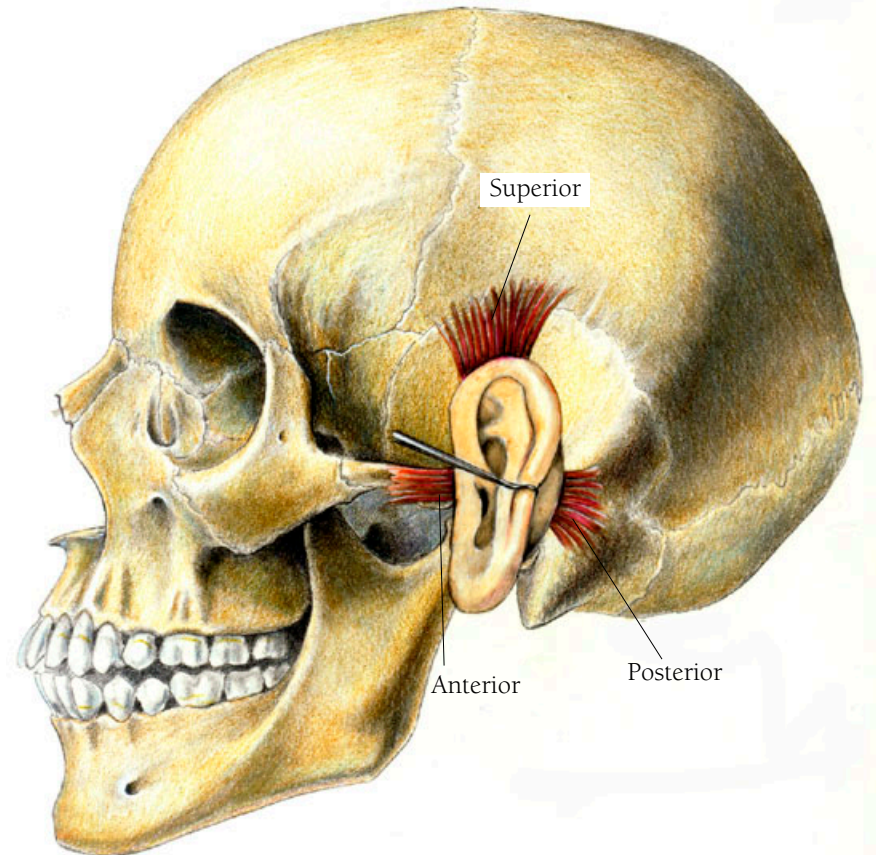
## Head and Neck Illustration 7

### THE AURICULARIS MUSCLES

Most people cannot use these muscles, but if they can, they are able to wiggle their ears—good for amusing young children. There are three of them: anterior, superior, and posterior. The anterior muscle is in front, the superior muscle above and the posterior muscle behind the ear. These are very superficial muscles whose attachments are not to bone but to underlying fascia.

• • •

*Auricula* is Latin for ear.



AURICULARIS MUSCLES

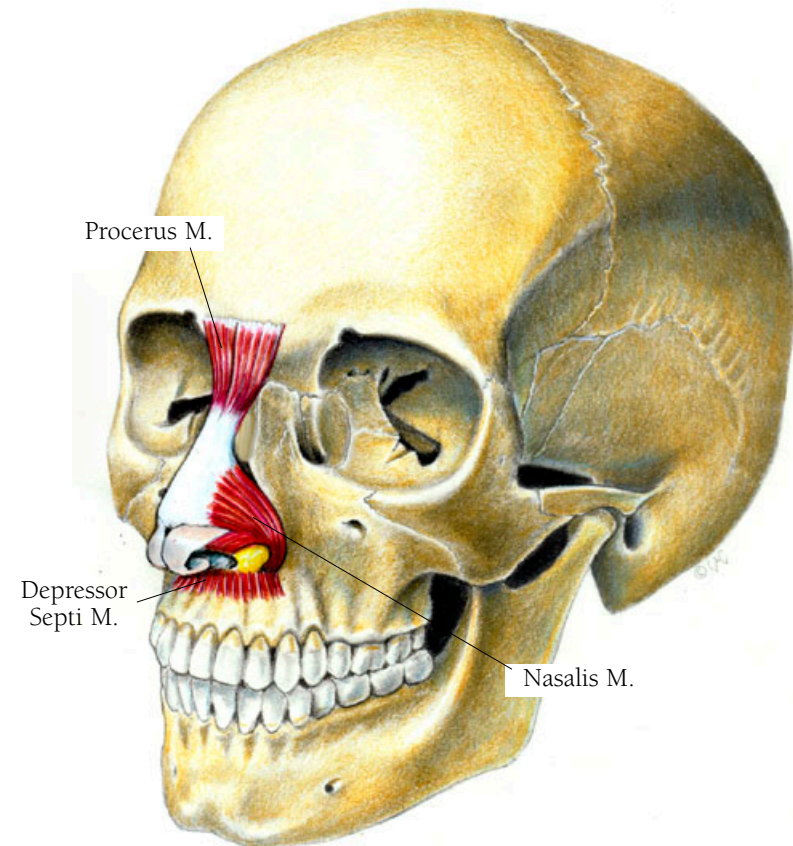
## Head and Neck Illustration 8

### THE NASALIS MUSCLE

The nasalis muscle allows you to flare your nostrils. One part arises from the tendinous end of the procerus muscle at the bridge of the nose, on each side of the nose, and the other part goes from the tip and over the outside of the nostrils.

### THE DEPRESSOR SEPTI MUSCLE

The depressor septi muscle draws the nose downward. It arises from the maxilla, just under the nose, and inserts into the septum of the nose.



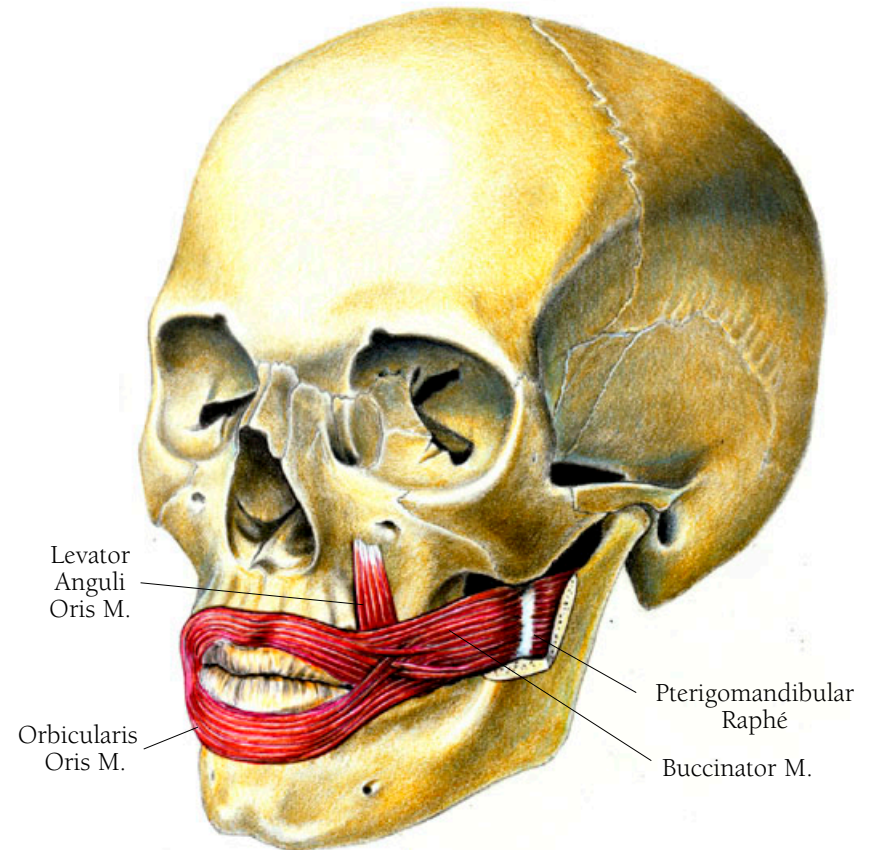
## Head and Neck Illustration 9

### THE ORBICULARIS ORIS MUSCLE

This muscle is used when you to close your mouth and to pout. It has some similarities with the orbicularis oculi muscle, discussed above, in that its fibers encircle the mouth just as the fibers of the oculi muscle encircle the eye, and both are sphincter muscles. However, the oris is more complicated because it is comprised of fibers that feed into it from radiating muscles. Most of these fibers go around the mouth, but unlike the fibers of the oculi muscle, they are in four sections with some of the fibers attaching to the underside of the skin. One section joins in the middle of the upper lip forming a little “gutter” under the nose. Another is in the middle of the lower lip without a gutter. The two others are at the corners of the mouth. The orbicularis arises from several places: from the maxilla, the mandible, the lips, and the buccinator muscle.

• • •

*Maxilla* is the diminutive of the Latin *mala*, meaning upper-jawbone.



## THE BUCCINATOR MUSCLE

The buccinator is the muscle of the cheek which aids in chewing by holding the cheek close to the teeth. It is also the muscle used for horn blowing. It arises from the outer surfaces of the maxilla, the mandible, and the superior constrictor pharyngis muscle, and is joined to that muscle by the pterygomandibular raphé. It inserts into the orbicularis oris and the modiolus, beneath the risorius muscle.

• • •

Buccinator is from the Latin *buccinare* meaning “to blow a trumpet”. Buccinator is pronounced “booksinator,” the oo’s as in goose. Raphé is from the Greek *rhaphe*, meaning seam or suture, suture referring to a joining.

## THE LEVATOR ANGULI ORIS MUSCLE

This muscle contributes to the naso-labial fold in the cheek. It lifts the upper lip exposing the teeth when smiling. It originates on the maxilla just below the infraorbital foramen and inserts into the modiolus.



## Head and Neck Illustration 10

### THE ZYGOMATICUS MAJOR MUSCLE

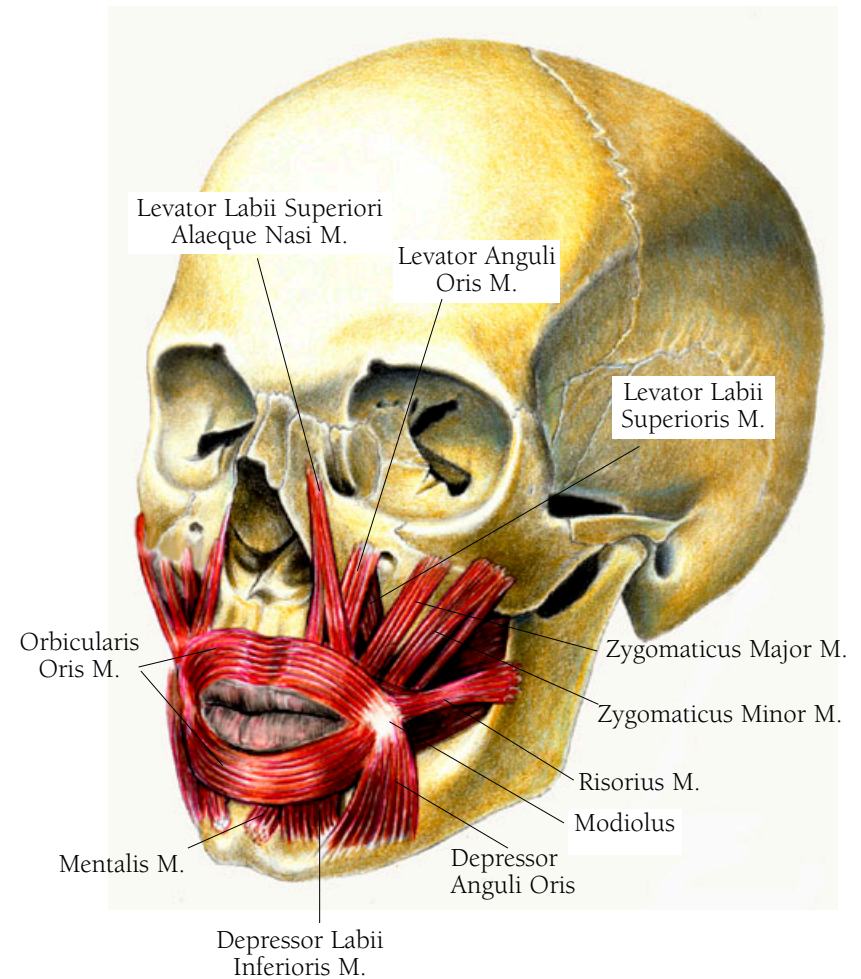
The zygomaticus major muscle assists the risorius muscle in laughing and smiling by lifting the corners of the mouth. It inserts into the orbicularis at the modiolus and arises on the zygomatic bone. The modiolus is a tendinous tissue found at the corners of the mouth to which many of the muscles of expression attach.

### THE ZYGOMATICUS MINOR MUSCLE

The zygomaticus minor muscle is also a lip lifter and aids in smiling. It inserts on the orbicularis oris just next to and above the zygomaticus major and arises from the malar surface of the zygomatic bone just nasal to the place where the zygomaticus major muscle arises.

### THE LEVATOR LABII SUPERIORIS MUSCLE

The levator labii superioris muscle lies nasal to the zygomaticus minor muscle. It is the upper lip lifter, as its name implies. It inserts on the orbicularis, between the levator anguli oris and the levator labii superioris alaeque nase.



MUSCLES OF EXPRESSION

### THE LEVATOR ANGULI ORIS MUSCLE

This muscle is already shown in the previous illustration. The name of the levator anguli oris muscle tells what it does. It translates from the Latin as “lifter of mouth at corners.” It is not parallel with the above three muscles but instead it inserts at the modiolus, as do the zygomaticus major and the risorius. It lies beneath them, coursing under the levator labii superioris, then arising just outside of and beneath the orbital rim.

### THE LEVATOR LABII SUPERIORIS ALAEQUE NASI MUSCLE

The levator labii superioris alaeque nasi muscle is the most nasal of the levator labii muscles and is the one which allows you to sneer.

• • •

In Latin it means “upper-lips lifter next to noses.”

### THE DEPRESSOR ANGULI ORIS MUSCLE

The depressor anguli oris muscle of the lower lip aids in drawing the lower lip downward. It inserts at the modiolus, mingling its fibers with the risorius and the orbicularis oris, and arises out of the fibers of the platysma muscle. (The platysma is a broad thin sheath of muscle which connects with the lower jaw muscles and covers the neck and clavicle.)

### THE DEPRESSOR LABII INFERIORIS MUSCLE

The depressor labii inferioris muscle is the main depressor or drawing down muscle of the lower lip. It lies next to the depressor anguli oris muscle, going toward the center, or medially. This muscle inserts on the orbicularis oris and rises from the mental region of the lower mandible.

• • •

The term mental comes from the Latin word for the chin and translates literally as “depressor of the lower lips.”

### THE MENTALIS MUSCLE

The mentalis muscle allows you to dimple your chin when this muscle is contracted because it pulls on the skin. It is included with this group because in some people, but not all, fibers of this muscle arise from and mingle with the orbicularis oris. Note that this is an origin, not an insertion. The insertion is into the skin near the point of the chin.

### THE RISORIOUS MUSCLE

The risorius muscle is the “laughing muscle,” the one used when you laugh or smile. It inserts into the underside of the skin over the modiolus, with some fibers inserting into the orbicularis oris in the area of the modiolus. It arises in the fascia of the cheek.

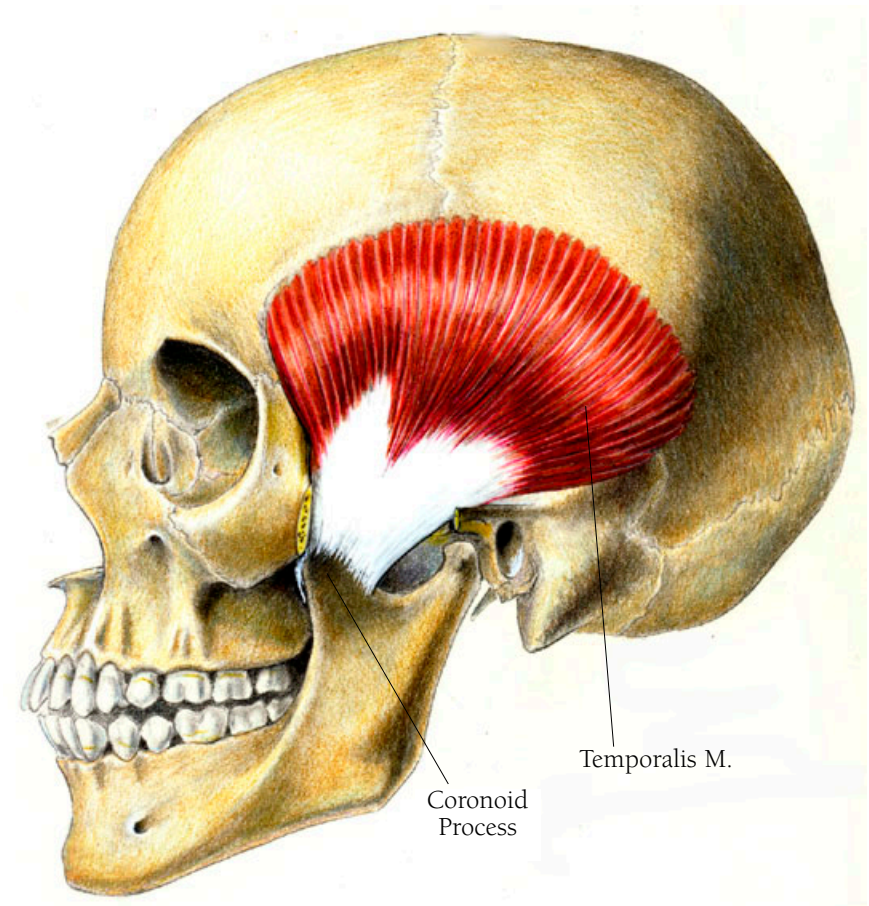
## Head and Neck Illustration II

### THE TEMPORALIS MUSCLE

The temporalis muscle helps to close the mouth, in grinding the teeth and to move the mouth from side to side when chewing. This muscle arises along the entire rim of the temporal fossa of the skull. The fibers of the muscle cover the temporal region and converge into a tendon which inserts on the coronoid process of the mandible.

• • •

Coronoid is from the Greek *korone* which means “like the beak of a crow.”



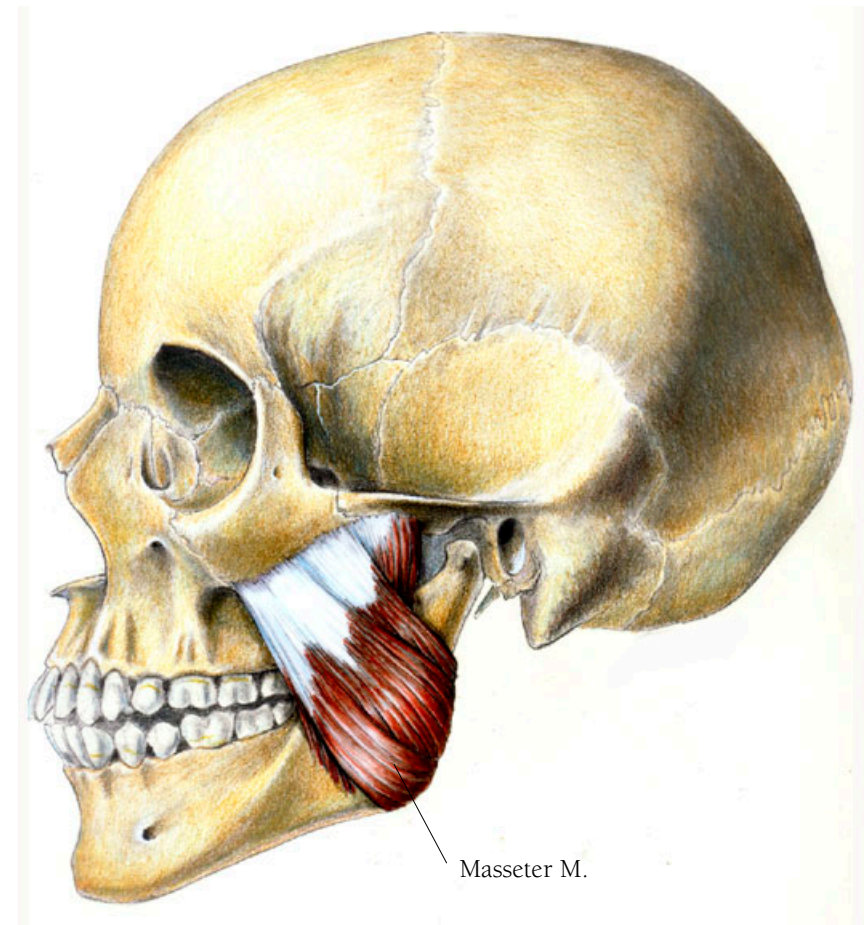
## Head and Neck Illustration 12

### THE MASSETER MUSCLE

The jaw's masseter muscle is one of the strongest muscles in the body. It is a very thick muscle, noticeable when someone clenches his teeth. It is the primary chewing muscle for closing the jaws. Its outer portion originates along the zygomatic arch and inserts on the surface of the ramus of the mandible. Its inner portion also originates from the zygomatic arch but further to the rear, posteriorly, and it inserts on the upper surface of the ramus of the mandible.

• • •

The name of this muscle comes from the Latin and Greek *maseter*, meaning chewer.



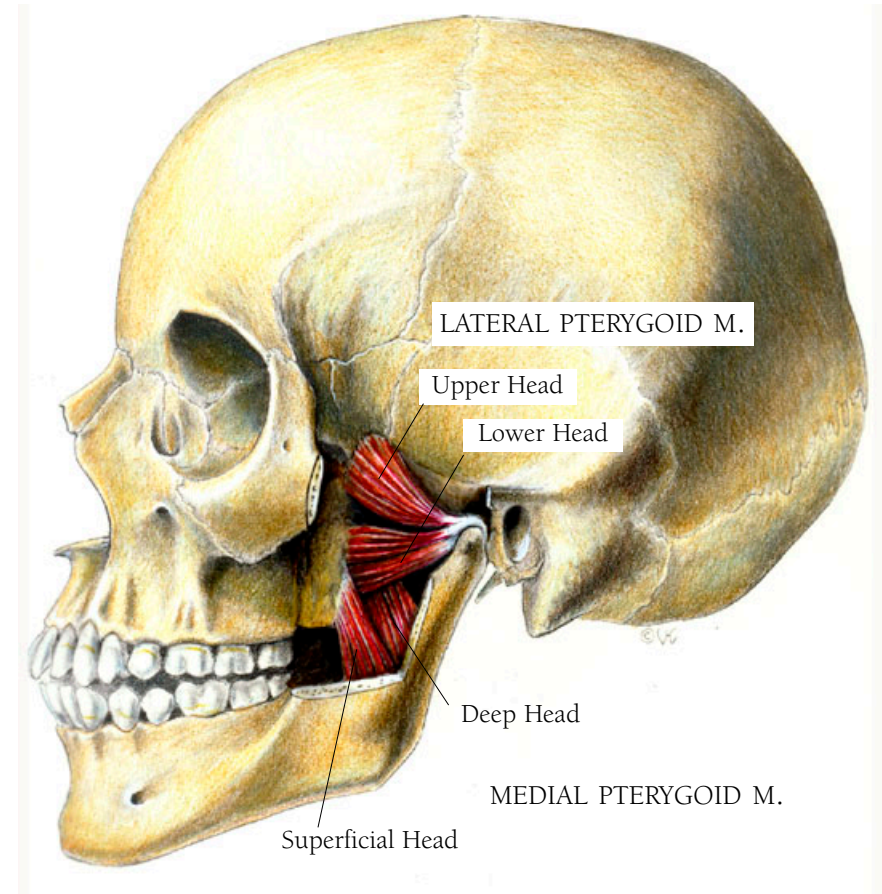
## Head and Neck Illustration I3

### THE PTERYGOID MUSCLES

The pterygoid muscles, which are found on the inside of the ramus of the mandible, work together with the masseter muscle in chewing. My illustration cuts away part of the ramus so that the muscles can be seen. There are two of them, the lateral pterygoid muscle and the medial pterygoid muscle. The lateral muscle assists in opening the mouth, and they both assist in jaw rotation and side-to-side movement as well as in the projection of the lower jaw. Each of these muscles has two heads. The lateral pterygoid muscle is the more superior, or higher of the two muscles. The upper head of the lateral pterygoid muscle arises from the lateral plate of the ethmoid bone, the lower from the pterygoid plate. Both parts join to insert onto the articular capsule which covers the condyle of the mandible's ramus. The superficial head of the medial muscle, the one closest to the surface, arises from the pterygoid plate, and the deep head arises from the palatine bone. Both heads join in a broad insertion on the inner, inferior, surface of the mandible's ramus.

• • •

Pterygoid is from the Greek word for wing-like. It refers to the pterygoid plate, a part of the sphenoid bone of the skull.



## Head and Neck Illustration 14

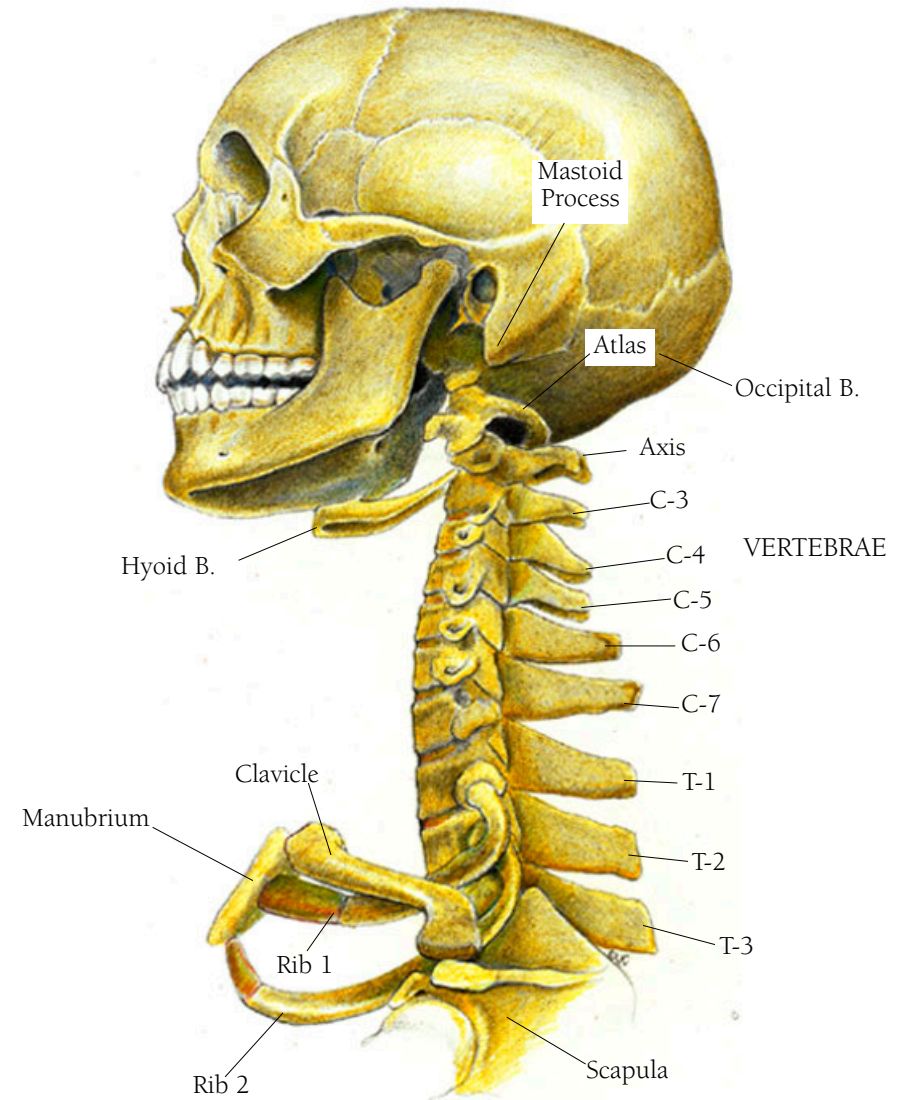
### THE BONES OF THE NECK

In this illustration you should note the first seven vertebrae, called the cervical vertebrae; three thoracic vertebrae; part of the shoulder girdle, made up of the scapula (partly seen), the clavicle and head of the humerus; the first two ribs; the clavicle, which goes from the spine of the scapula to the top of the sternum, the part called the manubrium; the hyoid bone; and a side view of the skull showing the occipital bone and the mastoid process.

The hyoid bone is situated at the angle of the throat where the chin meets the neck just above the thyroid cartilage—the Adam's Apple. It is the one bone in the body that is not articulated with another bone, rather it is held in place by the suprahyoid and infrahyoid muscles—those involved with swallowing.

• • •

*Hyoid* means shaped like the Greek letter upsilon: *u*. *Oid* at the end of a word means like, as in resemble.



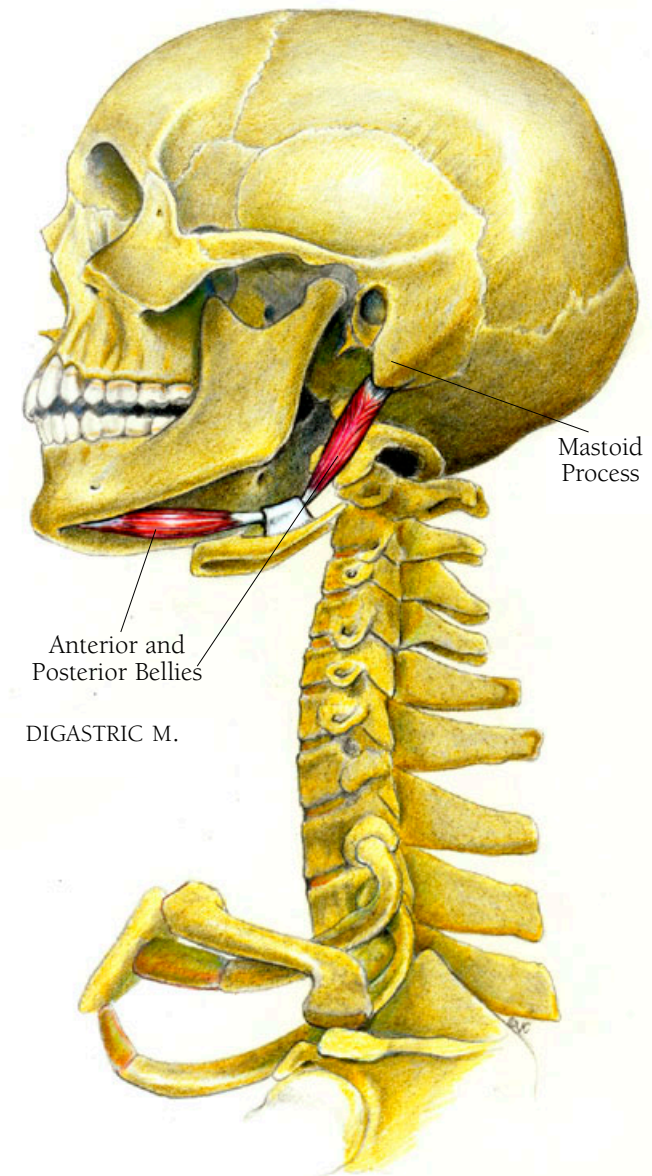
## Head and Neck Illustration 15

### THE DIGASTRIC MUSCLE

The digastric muscle becomes tendinous in the middle so that it can go through a fibrous ring which is attached to the hyoid bone. It arises in the rear of the mastoid process, a bony process just below and behind the ear, slopes down and forward through its ring on the hyoid bone and then swings forward to insert on the inside of the chin on the mandible.

• • •

The name digastric derives from the Greek *di*, meaning two and *gastēr*, meaning bellies.



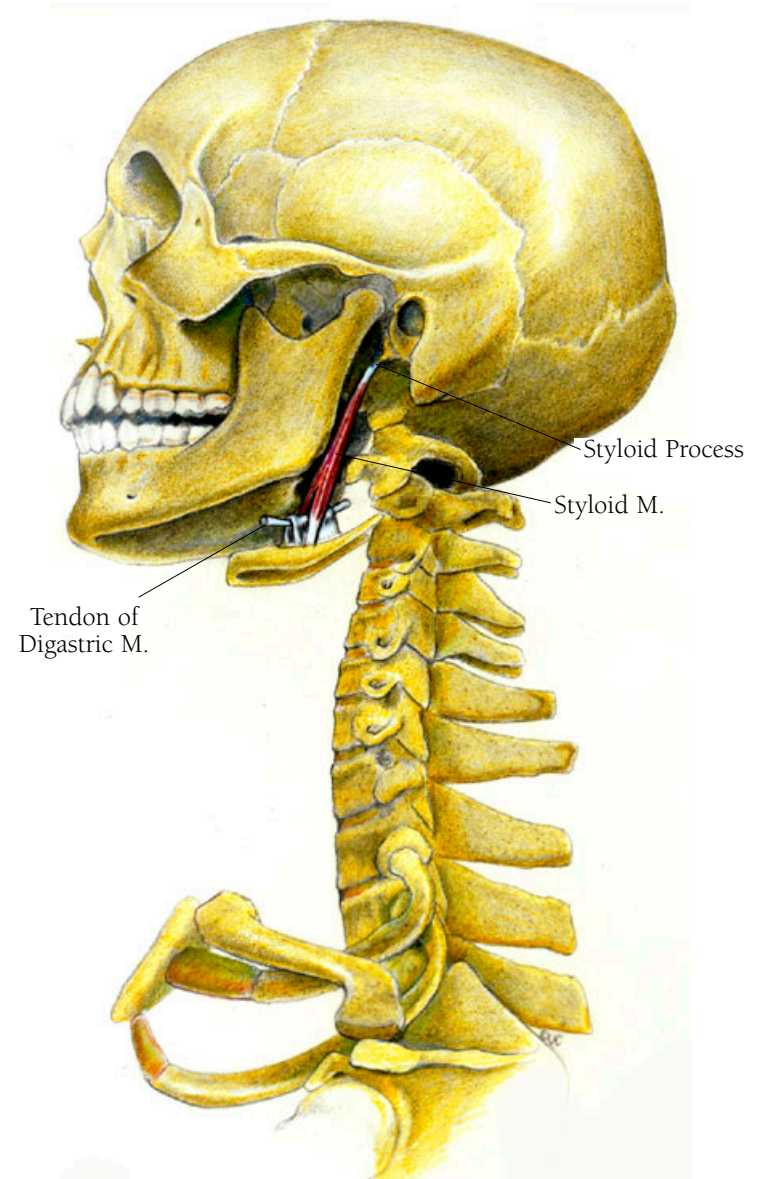
## Head and Neck Illustration 16

### THE STYLOID MUSCLE

The styloid muscle is a slender muscle which arises from the styloid process of the temporal bone and passes straight down to insert on the body of the hyoid bone. If you look at the drawing of the skull's side view, you can see the styloid process as a little finger of bone just below where the ear would be.

• • •

Styloid derives from the Latin word for pointed and refers to the shape of the bone.





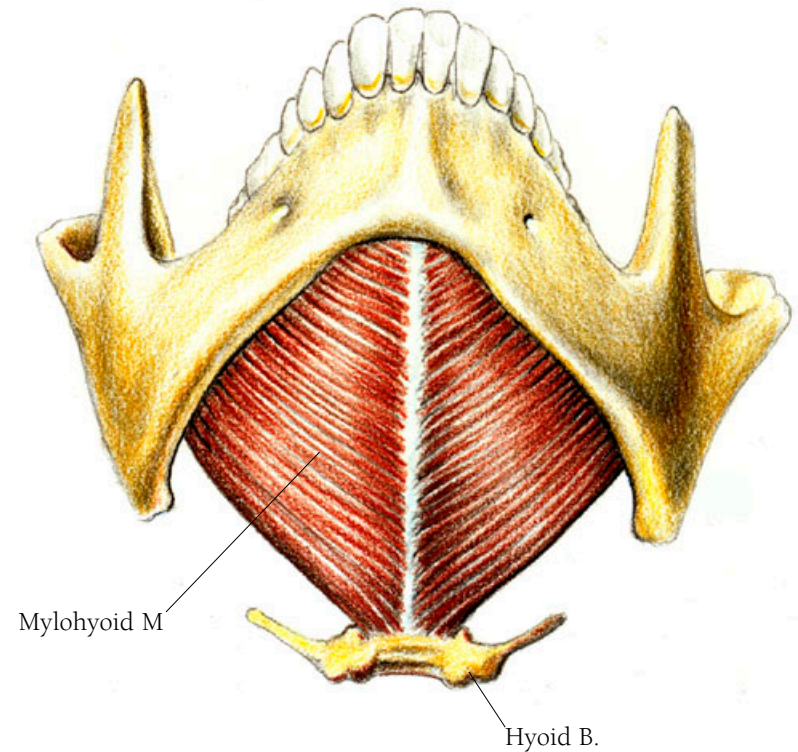
## Head and Neck Illustration 17

### THE MYLOHYOID MUSCLE

The mylohyoid muscle lies beneath the anterior belly of the digastric muscle and the stylohyoid muscle discussed above and forms the whole floor of the mouth. It arises near the molars of the lower jaw and attaches all the way around the inner rim of the mandible. Its fibers converge downward to insert on the body of the hyoid bone.

• • •

*Mylo* is the Greek word for mill, a place where grinding is done and hence relates to the molars.



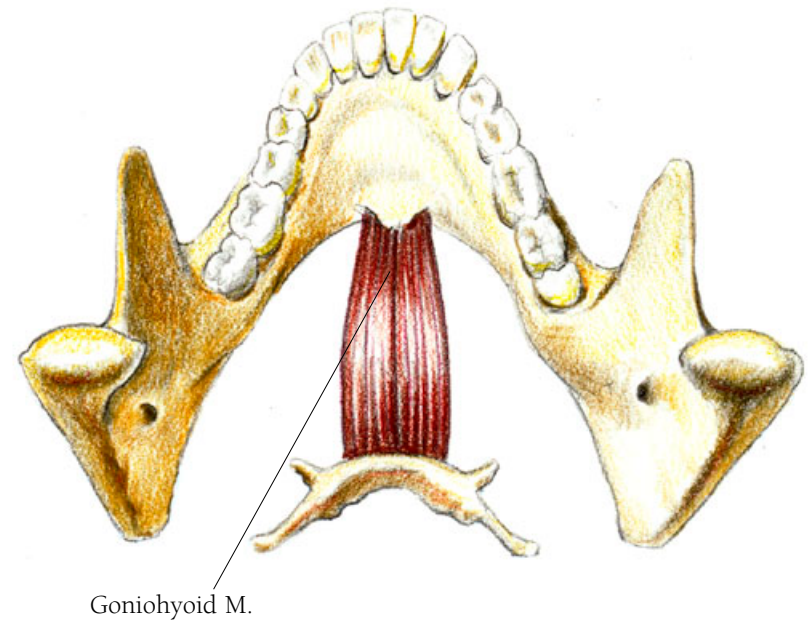
## Head and Neck Illustration 18

### THE GONIOHYOID MUSCLE

The gonioid muscle, which lies beneath the mylohyoid muscle, arises from behind the point of the chin and inserts on the body of the hyoid bone.

• • •

*Gonio* is the Greek word for angle, and refers here to the angle of the lower jaw.



## Head and Neck Illustration 19

The following muscles work to lower the hyoid bone when swallowing, except for the sternothyroid muscle, which moves the thyroid cartilage backward when swallowing. The thyroid cartilage is known as the Adam's Apple. The infrahyoid muscles are those below the hyoid bone.

### THE THYROHYOID MUSCLE

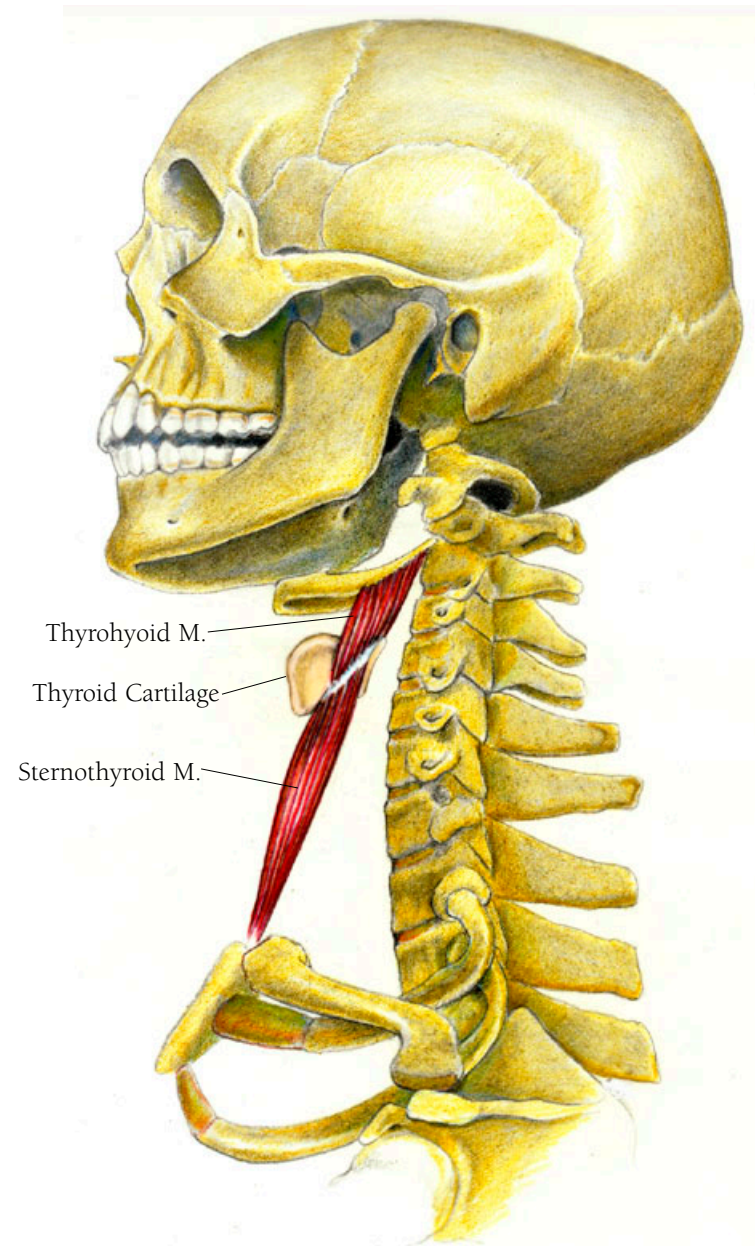
The thyrohyoid muscle arises from the thyroid cartilage and inserts on the hyoid bone.

### THE STERNOTHYROID MUSCLE

The sternothyroid muscle arises from the back upper surface of the sternum and inserts on the upper rim of the thyroid cartilage.

• • •

Thyroid is from the Greek *thyreos* and *eides* meaning shield shaped.



## Head and Neck Illustration 20

### THE STERNOHYOID MUSCLE

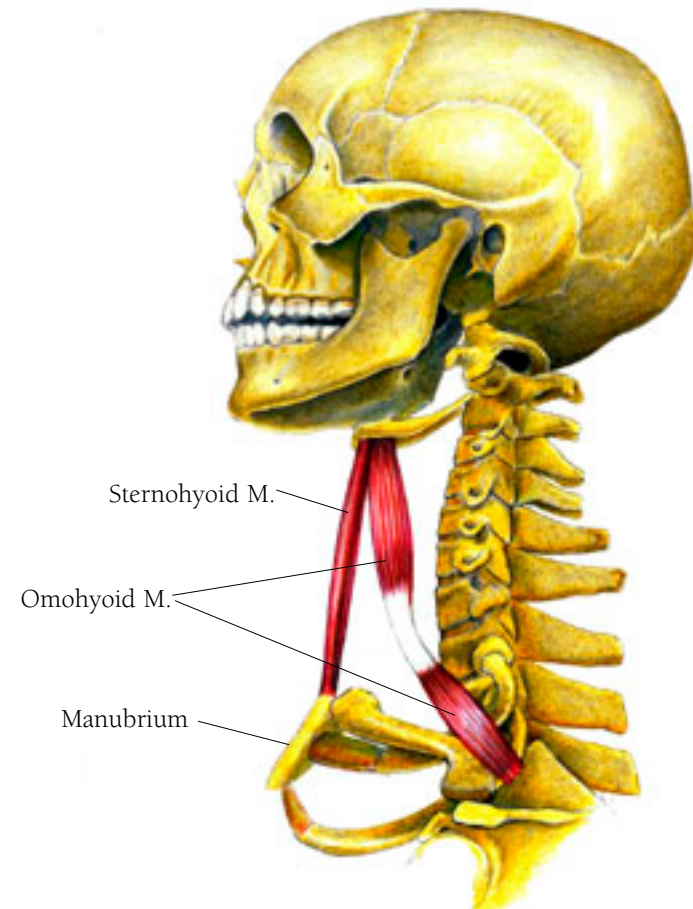
The sternohyoid muscle arises from the tip end of the sternum called the manubrium, and inserts on the hyoid bone.

### THE OMOHYOID MUSCLE

The omohyoid muscle has two bellies connected by a tendon, the front portion lying just next to the sternohyoid muscle. It arises from the upper border of the scapula, passes through a tendinous loop attached to the clavicle, and then continues upward to insert on the hyoid bone.

• • •

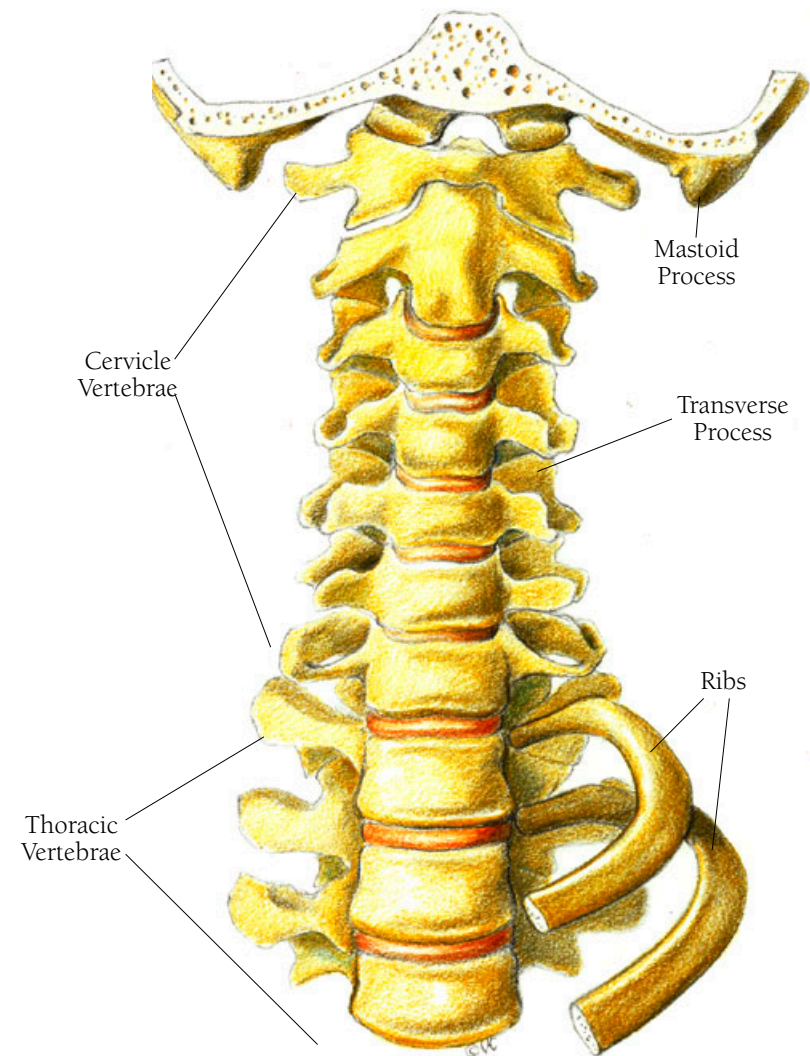
*Omo* is Greek for shoulder.



## Head and Neck Illustration 2I

### THE BONES OF THE NECK: INTERIOR-ANTERIOR VIEW

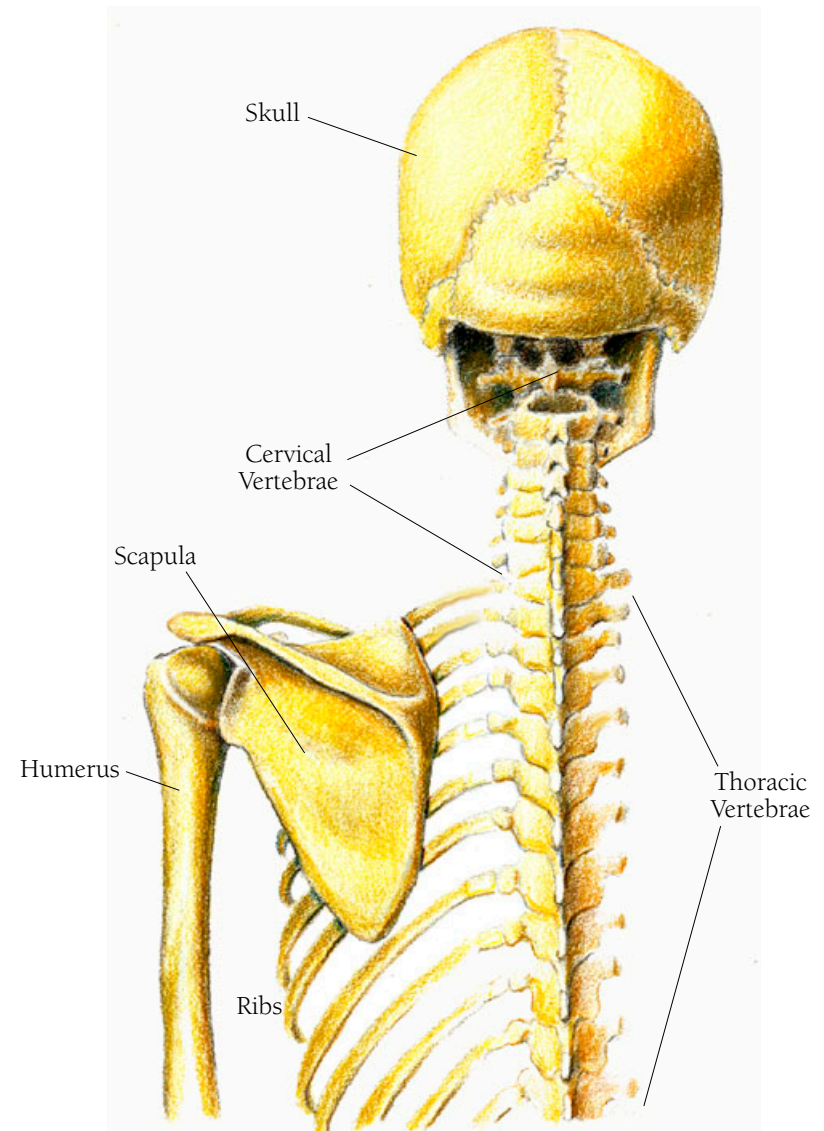
Here you see the seven cervical vertebrae along with the next three thoracic vertebrae, a section of the skull showing the mastoid process, and two ribs, all seen from the ventral (front) view. The transverse processes of the vertebrae can be clearly seen.



## Head and Neck Illustration 22

### THE SKULL, NECK, AND UPPER BACK: POSTERIOR VIEW

In this illustration you see the skull, seven cervical vertebrae, and eleven of the twelve thoracic vertebrae with ribs attached, from the back or posterior view. The scapula, a bit of the clavicle, and the top of the humerus can also be seen.



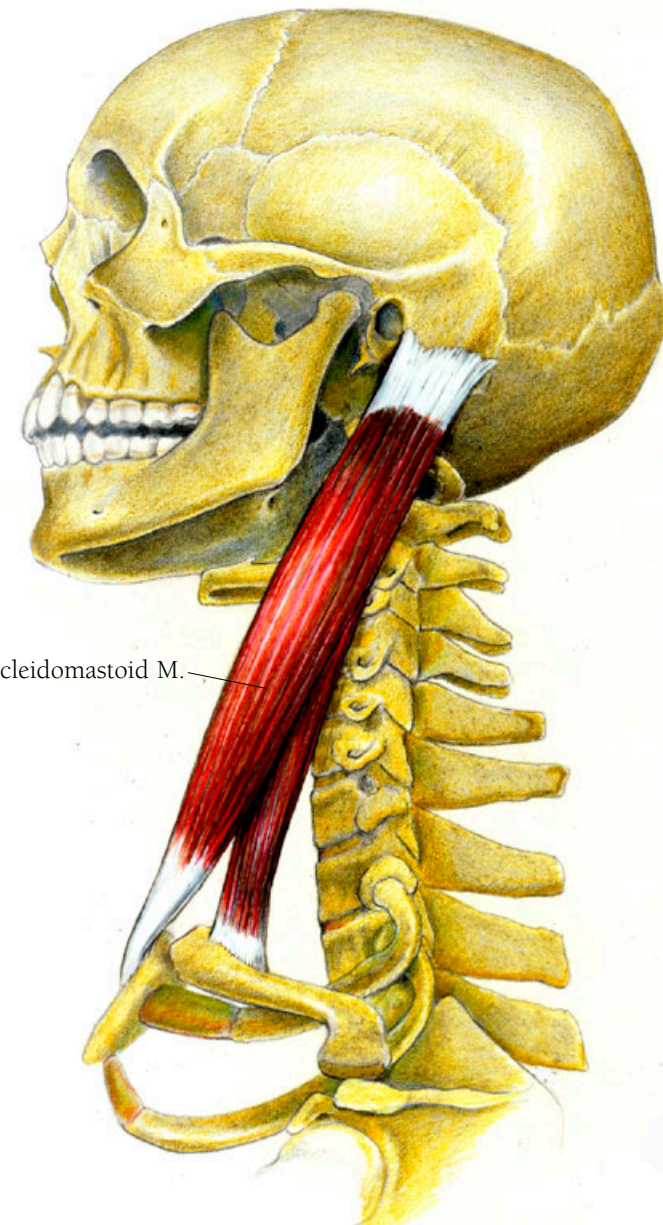
## Head and Neck Illustration 23

### THE STERNOCLEIDOMASTOID MUSCLE

The sternocleidomastoid muscle aids in rotating the head and neck and in lowering the chin to each side. It also assists breathing by lifting the sternum when you inhale. It arises in two places—on the top of the manubrium of the sternum and on the clavicle. It joins together about one third of the way up its diagonally upward course to its point of insertion on the mastoid process.

• • •

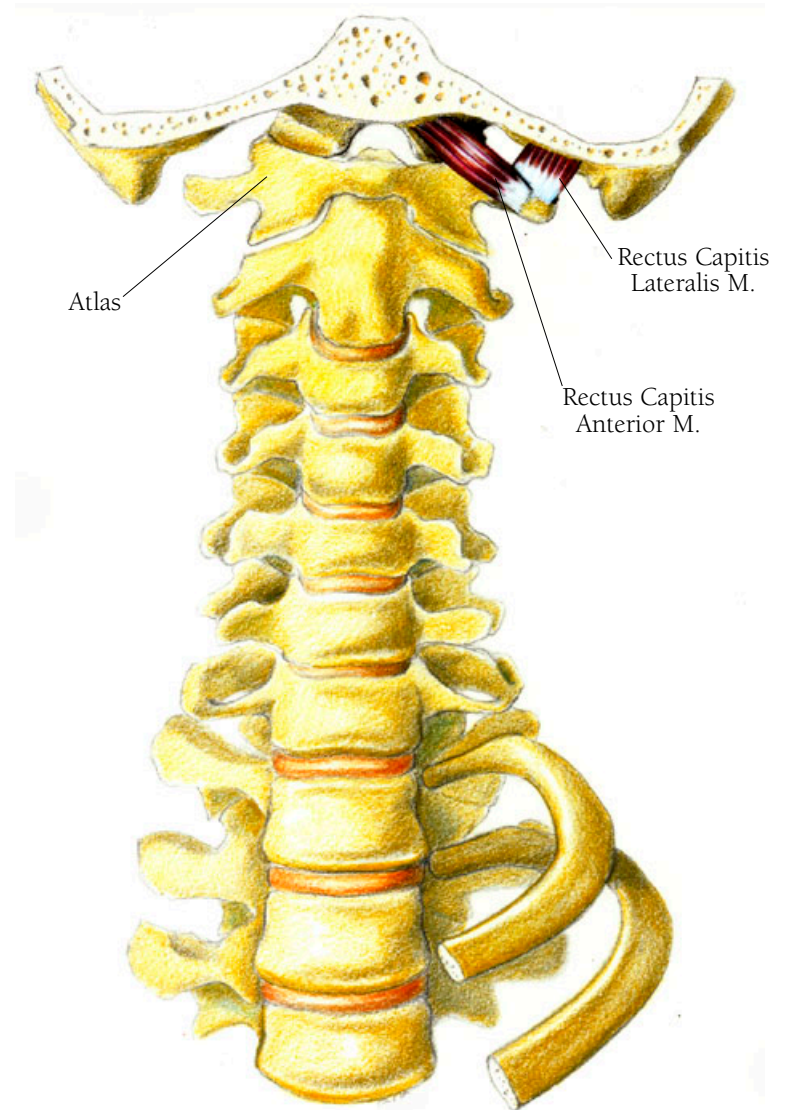
Sterno is from the Latin *sternum*, meaning breastbone; cleido is from the Greek “pertaining to the clavicle,” and mastoid comes from the Greek word *mastos*, meaning nipple or breast-like.



## Head and Neck Illustration 24

### THE RECTUS CAPITIS LATERALIS AND THE RECTUS CAPITIS ANTERIOR MUSCLES

Here you see two small muscles which form the deepest layer of the neck muscles: the rectus capitis lateralis muscle, and the rectus capitis anterior muscle. The former, a small, flat, squarish muscle, moves the head from side to side. It arises from the upper surface of the transverse process of the atlas (the first cervical vertebra) and inserts on the occipital bone of the skull. The latter muscle allows the head to bend forward. It arises from the transverse process and the adjacent body of the atlas and inserts just in front of the magnum foramen of the skull, the opening through which the spinal column passes to join the brain stem.





## Head and Neck Illustration 25

### THE RECTUS CAPITIS POSTERIOR MINOR MUSCLE

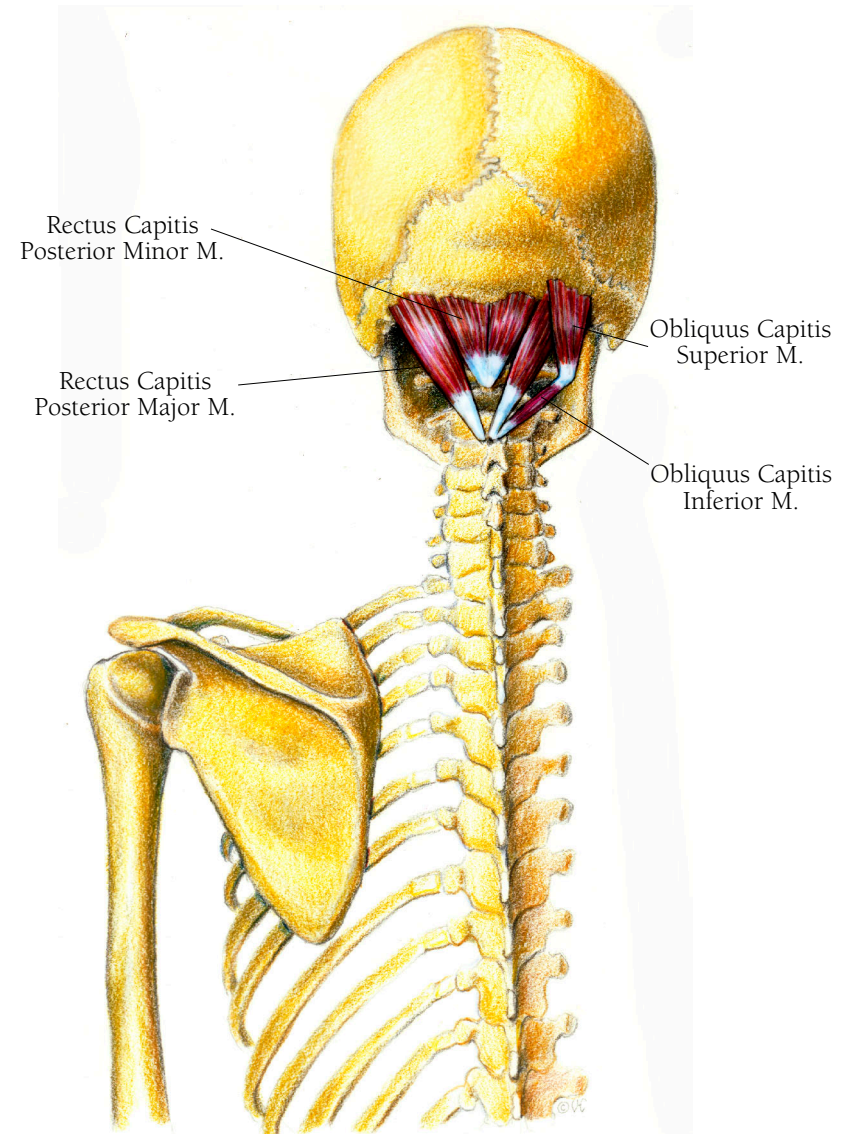
The rectus capitis posterior minor muscle is a head extender: It helps lift the head up. It arises from the tubercle of the posterior arch of the atlas in the form of a narrow tendon from which the muscles rises to insert on the inferior nuchal line of the occipital bone of the skull.

### THE RECTUS CAPITIS POSTERIOR MAJOR MUSCLE

The rectus capitis posterior major muscle is another head extender and also assists in turning the head to the side. It arises from the spinous process of the axis and courses upward to insert on the inferior nuchal line just next to the rectus capitis posterior minor muscle.

### THE OBLIQUUS CAPITIS SUPERIOR MUSCLE

The obliquus capitis superior muscle assists in holding the head erect as well as helping to bend it to the side. It arises from the transverse process of the atlas and inserts onto the occipital bone just over the rectus capitis posterior major muscle along the inferior nuchal line.



## THE OBLIQUUS CAPITIS INFERIOR MUSCLE

The obliquus capitis inferior muscle helps to turn the head to the side by rotating the axis, the second cervical vertebra. It arises from the spinous process of the axis and rises obliquely to insert on the transverse process of the atlas in the same area where the superior muscle arises.

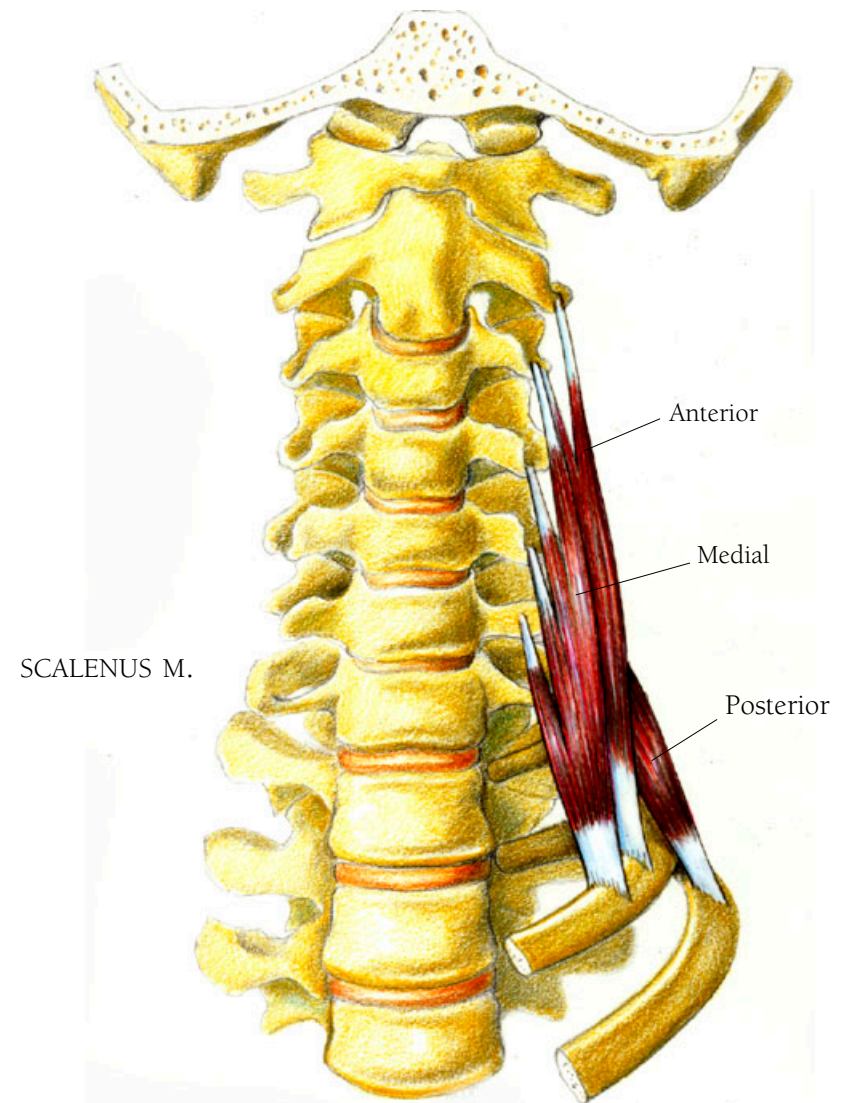
## Head and Neck Illustration 26

### THE SCALENUS MUSCLE

The scalenus muscle helps lift the ribcage, assisting in breathing. It also assists in some rotation of the neck and flexion of the upper spinal column. This muscle, too, is in three parts. The posterior part arises on the transverse processes of the top two or three cervical vertebrae and courses downward to insert on the top middle edge of the second rib. The medial part, the largest of the three sections, arises on the transverse processes of all the cervical vertebrae except the atlas and descends to attach on the top surface of the first rib. The anterior part arises from the transverse processes of the third through sixth cervical vertebrae and inserts on the top of the first rib, just in front of the medial portion's insertion. Whereas the longus colli and the longus capitis muscles course upward, the scalenus muscle courses downward. Muscles always shorten in the direction of their origin.

• • •

*Scalenus* is a Latin word derived from the Greek *skalenos* meaning odd or uneven. In geometry the word refers to a triangle with unequal sides.



## Head and Neck Illustration 27

### THE LONGUS COLLI MUSCLES

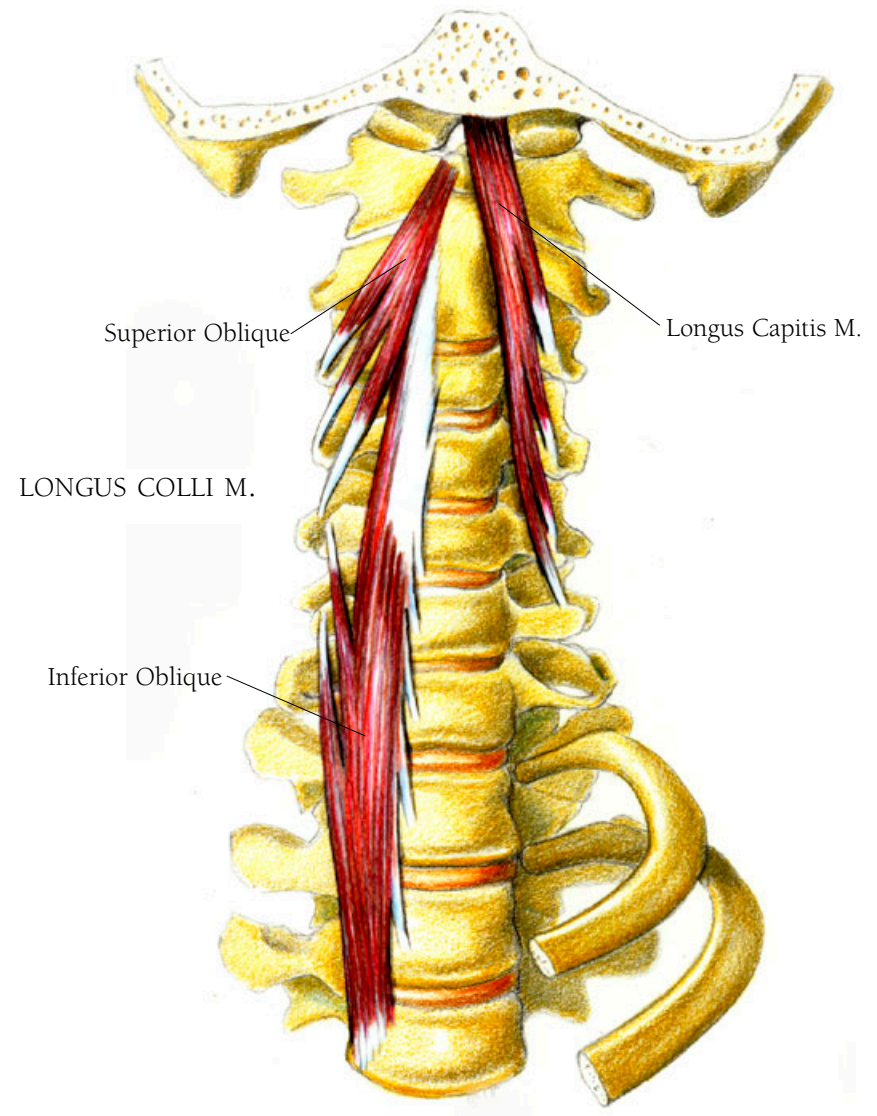
In the next layer of neck muscles, going inward, are the longus colli muscles, which help the neck to bend and rotate. It is in three parts: upper (superior) and lower oblique muscle and, joining these, a vertical muscle. The superior oblique portion arises from the transverse process of the third, fourth, and fifth cervical vertebrae and rises obliquely inward to insert on the inner central portion of the atlas, called the anterior arch. The lower oblique arises from the bodies of the first two or three thoracic vertebrae and inserts on the bodies of the top three cervical vertebrae. The vertical part arises from the bodies of the first three thoracic vertebrae and inserts on the bodies of the top three cervical vertebrae.

• • •

*Collum* is Latin for neck and the source of the word collar.

### THE LONGUS CAPITIS MUSCLE

Overlying the longus colli muscle is the longus capitis muscle, which flexes the head. It arises from tendons



attached to the transverse processes of the third through sixth cervical vertebrae and courses upward to insert on the middle portion of the occipital bone, the basilar portion (the base), just in front of the insertion of the rectus capitis anterior muscle.

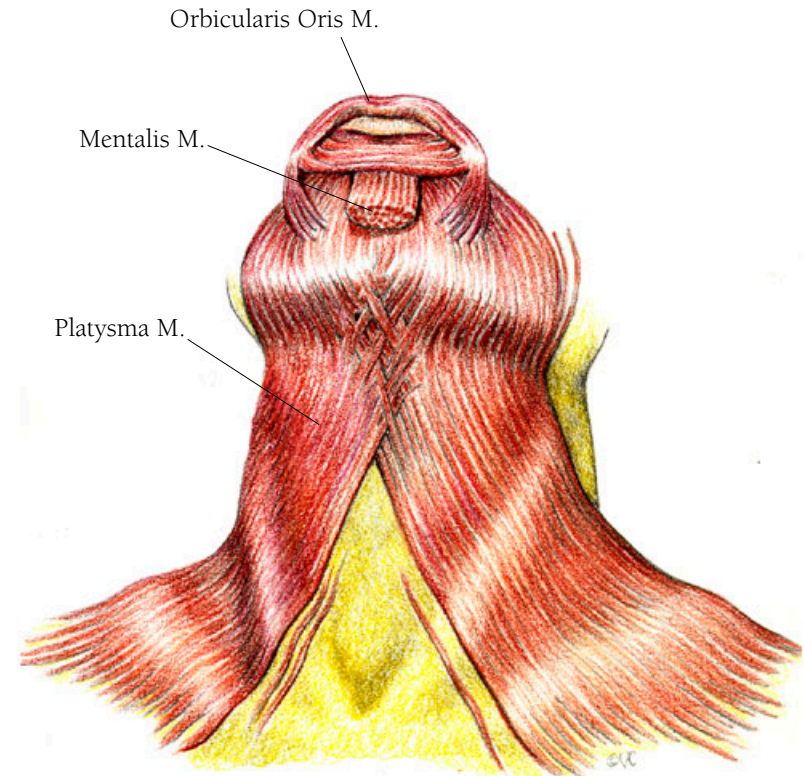
## Head and Neck Illustration 28

### THE PLATYSMA MUSCLE

When your collar is too tight it is the constriction of the platysma muscle that helps loosen it. Otherwise this muscle doesn't have much function. Laxness of this muscle is often a major factor in causing the sag under the chin in older people (this is not just aging skin, or from accumulating fat). This muscle forms the outermost layer of the neck muscles. The muscle fibers arise from the fascia at the top part of the torso covering the pectoral muscles and the deltoids and course over the clavicle and up each side of the neck. They meet with intertwining fibers just under the chin and then continue, passing over the edge of the mandible, to join the fibers of the lower facial muscles. It is a broad, thin muscle.

• • •

*Platy* in Greek means flat or plate like.



## *The Shoulder*

The shoulder is the most complicated joint in the body. The humerus, the upper arm bone, has a round head that fits into a socket called the glenoid cavity of the scapula, which lies on the rear of the ribcage. You see the clavicle in the front. The medial end of the clavicle attaches to the manubrium, the top section of the sternum. The scapula, the clavicle, and the manubrium together form what is called the shoulder girdle. Numerous muscles pass above, around, through and beside these bones. (If you look at the movement of the shoulder area from a broader view, you would have to involve muscles that cover the chest and back as well. I shall discuss the pectoralis and latissimus dorsi muscles, which fan out over the chest and lower back, in the section on the arm, since they directly affect arm movement). When you look at the deltoid muscle and the pectoral muscles, which lie right next to each other, it's hard to see where one ends and the other begins. Similarly with the actions of these two muscles, it is hard to tell when one takes over from the other, when one stops and the other starts.

The muscles of the shoulder girdle are involved with the movement of the scapula. The muscles of the shoulder joint

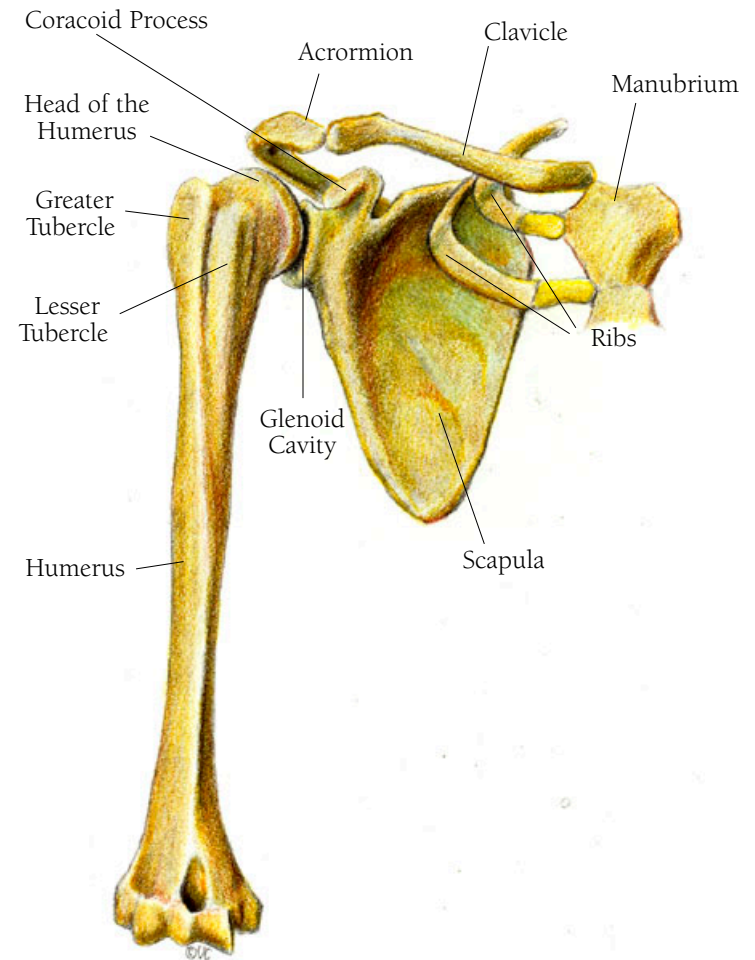
are involved with the movement of the arm, specifically the humerus, which articulates with the glenoid cavity of the scapula.

The rotator cuff muscles maintain the position of the head of the humerus in the glenoid cavity (shoulder joint) even as the upper arm is moving. They are: the subscapularis, the supraspinatus, the infraspinatus, and the teres minor muscles.

## Shoulder Illustration 29

### THE BONES OF THE SHOULDER: ANTERIOR VIEW

Here you can see the clavicle, the humerus and the scapula, as well as the manubrium and two ribs. The features you should note on the scapula are the coracoid process, the acromion and the glenoid cavity. The head of the humerus fits into the glenoid cavity. Behind the head are the greater and lesser tubercles.



ANTERIOR VIEW



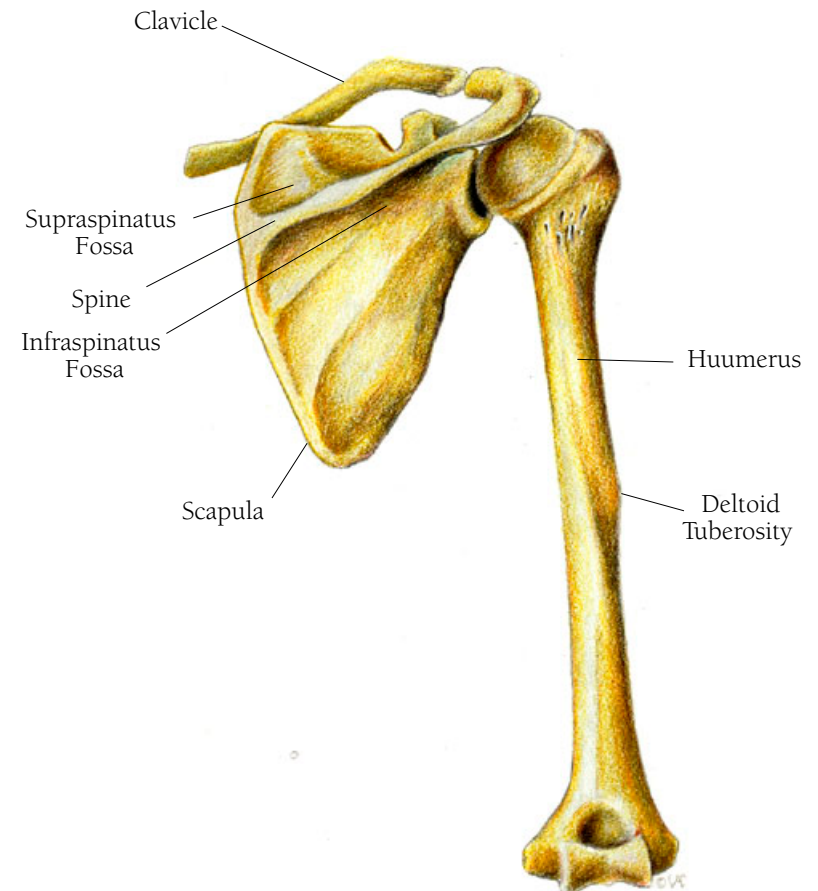
## Shoulder Illustration 30

### THE BONES OF THE SHOULDER: POSTERIOR VIEW

You can see the three bones that make up the shoulder girdle—the scapula, the humerus and the clavicle. The feature to be noted on the scapula is the spine with the supraspinatus fossa above the spine and the infraspinatus fossa below it. On the humerus, note the deltoid tuberosity.

• • •

*Scapula* in Latin means the shoulder blade. *Humerus* is Latin for the shoulder or the upper part of the arm. *Clavicle* comes from the Latin *clavcula* meaning a key or lock.



POSTERIOR VIEW

## Shoulder Illustration 3I

### THE LEVATOR SCAPULAE

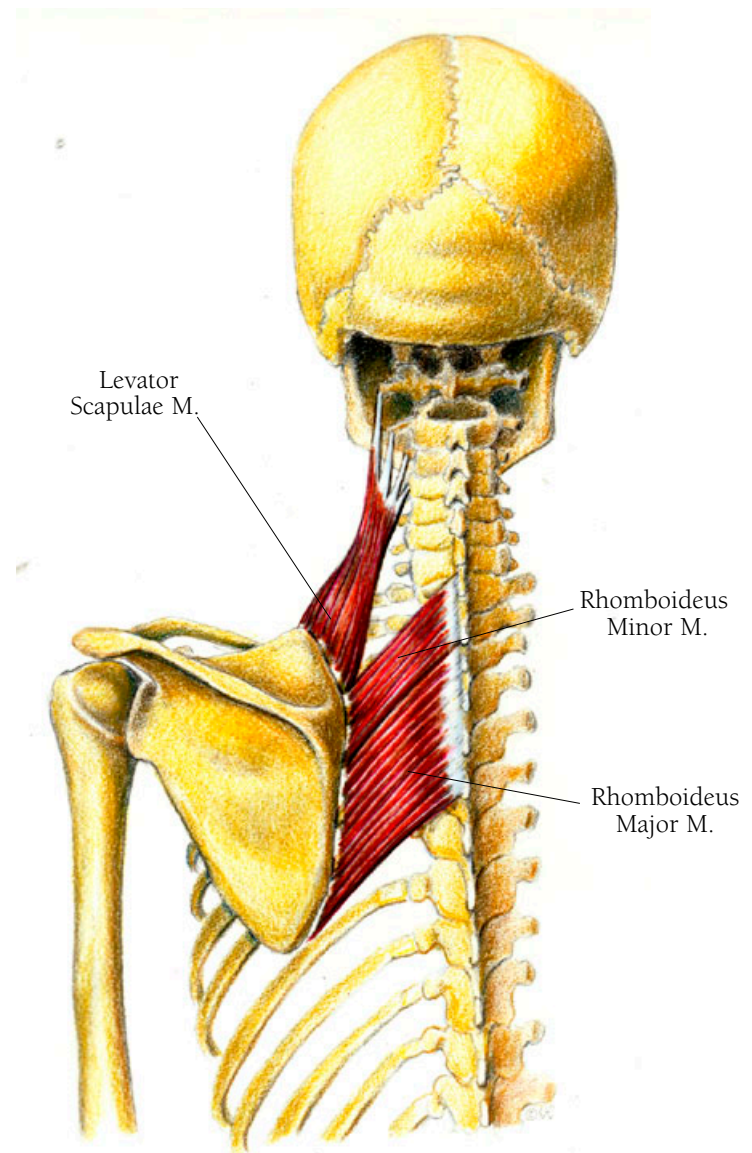
Its name in Latin describes what it does: it is “a lifter of scapulas.” It also assists in bending the neck. It arises as small tendons from the transverse processes of the atlas and axis as well as from the next two vertebrae. It inserts on the top part of the medial border of the scapula.

### THE RHOMBOIDEUS MAJOR MUSCLE

This muscle is located just below the levator scapulae and the rhomboideus minor muscle. Along with the levator scapulae, it assists in moving the scapula inward or medially, toward the spine, and upward. In the process it assists in moving the arm inward, called adduction. It arises from the spinous processes of the second through the fifth vertebrae—and inserts on the medial border (the one closest to the spine), of the scapula all the way to its tip.

### THE RHOMBOIDEUS MINOR MUSCLE

This muscle lies just above the rhomboideus major muscle. Working with the levator scapulae and the rhomboideus



major muscle, its actions contribute to the actions of the two muscles described above. It arises from the spinous processes of the lowest cervical and the uppermost thoracic vertebrae. It inserts at the base of the spine of the scapula on its medial border, just above the rhomboideus major muscle.

• • •

The Latin *rhomboides* and the Greek *rhomboides* mean a parallelogram, a four sided figure with parallel sides but different adjacent angles.

## Shoulder Illustration 32

### THE TERES MINOR MUSCLE

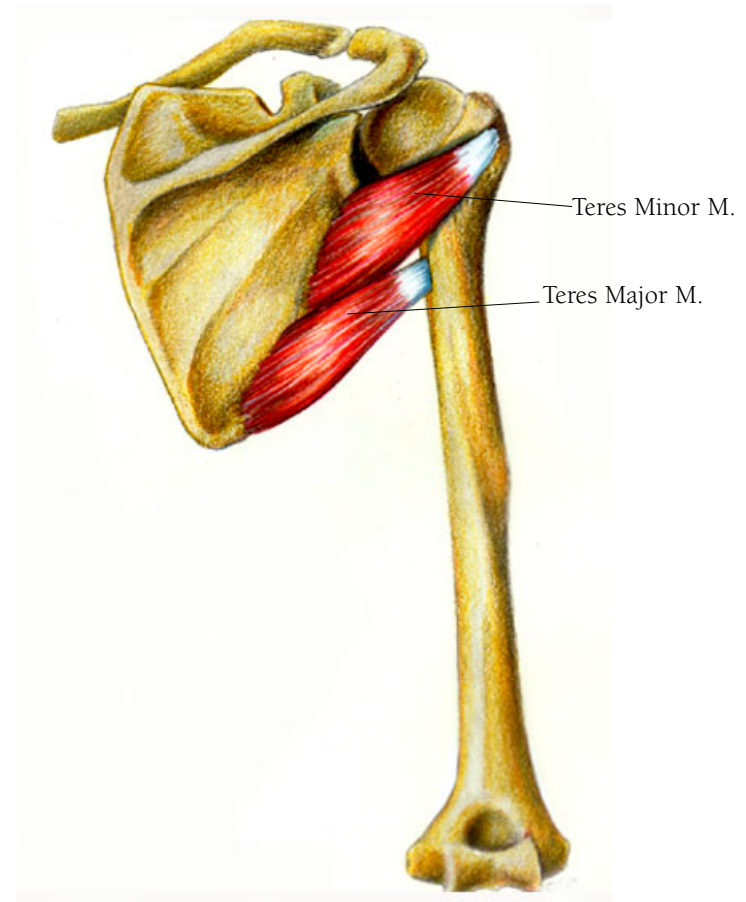
Along with the teres major muscle this muscle assists in drawing the arm backward—medial rotation—as well as in swinging the arm. One of the rotator cuff muscles, it arises on the surface of the scapula somewhat below the spine and under the infraspinatus muscle, courses out over the border of the scapula below the infraspinatus and inserts as a tendon right next to the infraspinatus tendon's insertion on the greater tubercle of the humerus.

### THE TERES MAJOR MUSCLE

This round, smooth muscle, which assists in socket stabilization as well as medial rotation, arises from the bottom of the scapula, courses over the arising fibers of the lower teres minor muscle to insert on the upper shaft of the humerus, just a little below the insertion of the teres minor.

• • •

*Teres* in Latin means round.



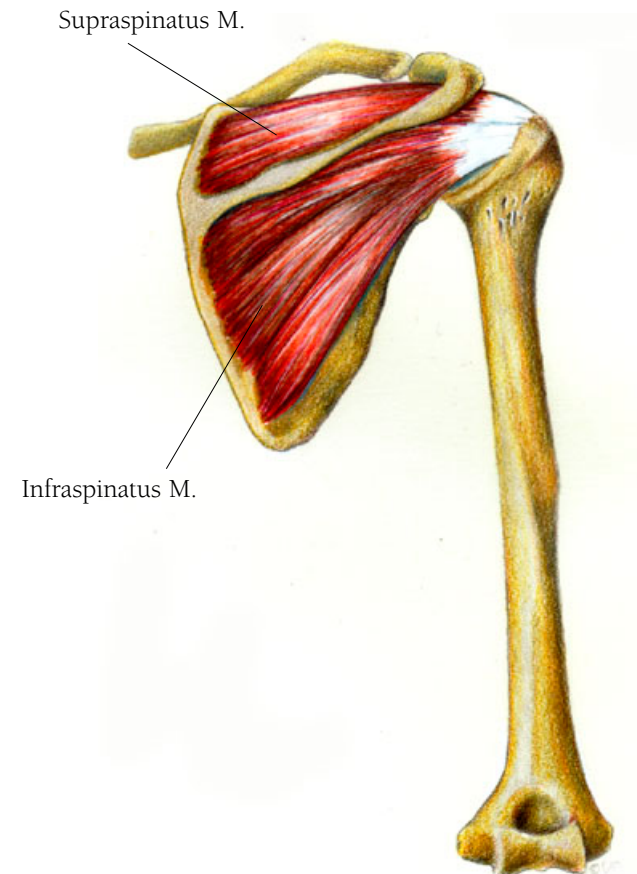
## Shoulder Illustration 33

### THE SUPRASPINATUS MUSCLE

The supraspinatus muscle assists in lifting the arm outward—abduction. Another of the rotator cuff muscles it arises from the top of the scapula, the area above the spine. Its fibers merge into a tendon that crosses the joint to insert on the greater tubercle of the humerus. This tubercle is just behind the head of the humerus.

### THE INFRASPINATUS MUSCLE

The infraspinatus muscle along with the supraspinatus muscle assists in rotating the arm backward. Another of the rotator cuff muscles, it arises just under the spine of the scapula, passes over the outside edge of the scapula, and inserts on the greater tubercle right next to, and almost fusing with, the supraspinatus muscle.



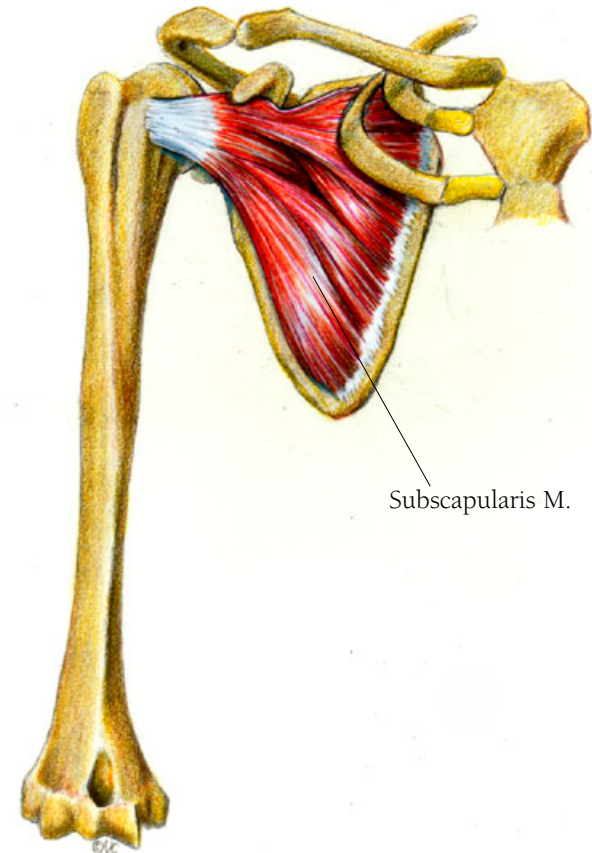
## Shoulder Illustration 34

### THE SUBSCAPULARIS MUSCLE

This muscle assists in rotating the arm inward and pulling it toward the body—adduction. It is one of the four muscles whose tendinous endings encircle the end of the humerus head to protect the joint, making up part of the rotator cuff. It arises from a major portion of the undersurface of the scapula and inserts on the lesser tubercle of the humerus. The tubercle is found at the top of the humerus just behind the head of the humerus.

• • •

*Subscapularis* in Latin means “under the scapula.”



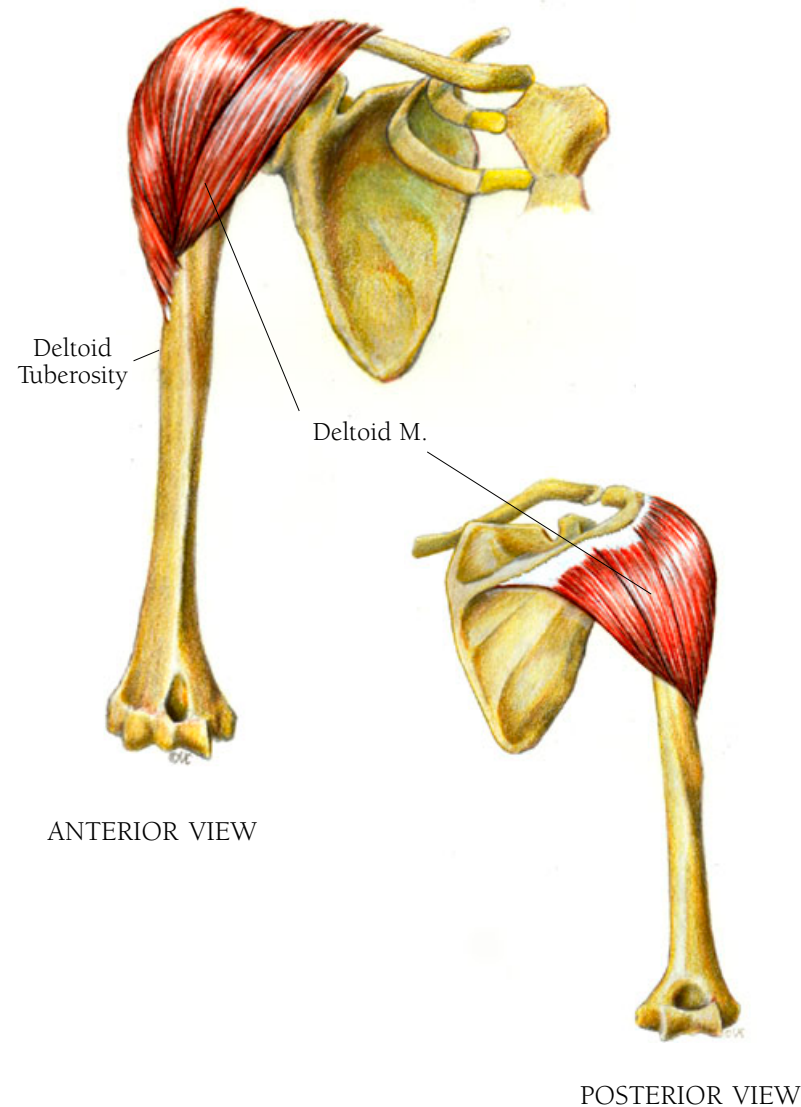
## Shoulder Illustration 35

### THE DELTOID MUSCLE

This thick muscle covers the shoulder protecting the joint. If someone punches you in the shoulder, it helps absorb the blow keeping that inner joint from being damaged. It assists in many movements of the arm, moving it forward, backward, and outward—abduction. It arises from two bones and three places: from the lateral third of the clavicle, from the acromion, and from the spine of the scapula. The fibers cover the shoulder joint to merge as a small tendon which inserts onto the deltoid tuberosity, a small projection on the lateral aspect of the shaft of the humerus, about midway down.

• • •

*Delta* is a Greek letter that corresponds to our D but is shaped like a triangle  $\Delta$ .



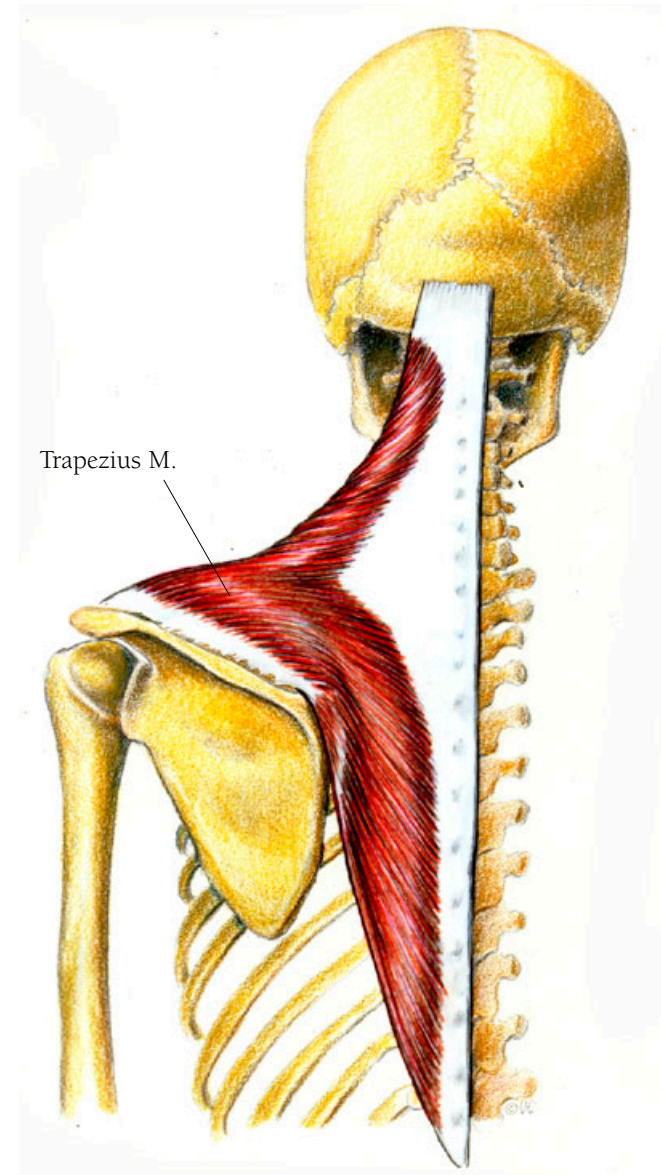
## Shoulder Illustration 36

### THE TRAPEZIUS MUSCLE

This large, flat muscle, which looks like a pointed cape over the top half of the back, assists in moving the head backward. It helps in rotating the scapula as well as in drawing it toward the spine. The lower part of the muscle assists in drawing the scapula downward and in drawing the arm inward. It arises from the back of the skull along a part of the superior nuchal line on the occipital bone, from the spinous process of the 7th cervical vertebra, and from the spinous processes of all the thoracic vertebrae. It drapes over the shoulder to insert on the clavicle and along the superior border of the spine of the scapula.

• • •

Trapezius comes from the Greek *trapezion* meaning “four legged bench” and has come to mean a figure with four unequal sides. You will encounter the origin of this word again in the bones of the wrist.





## *Arm and Hand*

### **THE UPPER ARM**

For the most part, the muscles of the upper arm cause the whole arm to move, those of the mid arm allow the lower arm to rotate, and those of the lower arm move the hand and fingers. Working together with the muscles of the upper arm are the muscles that spread across the chest and lower back.

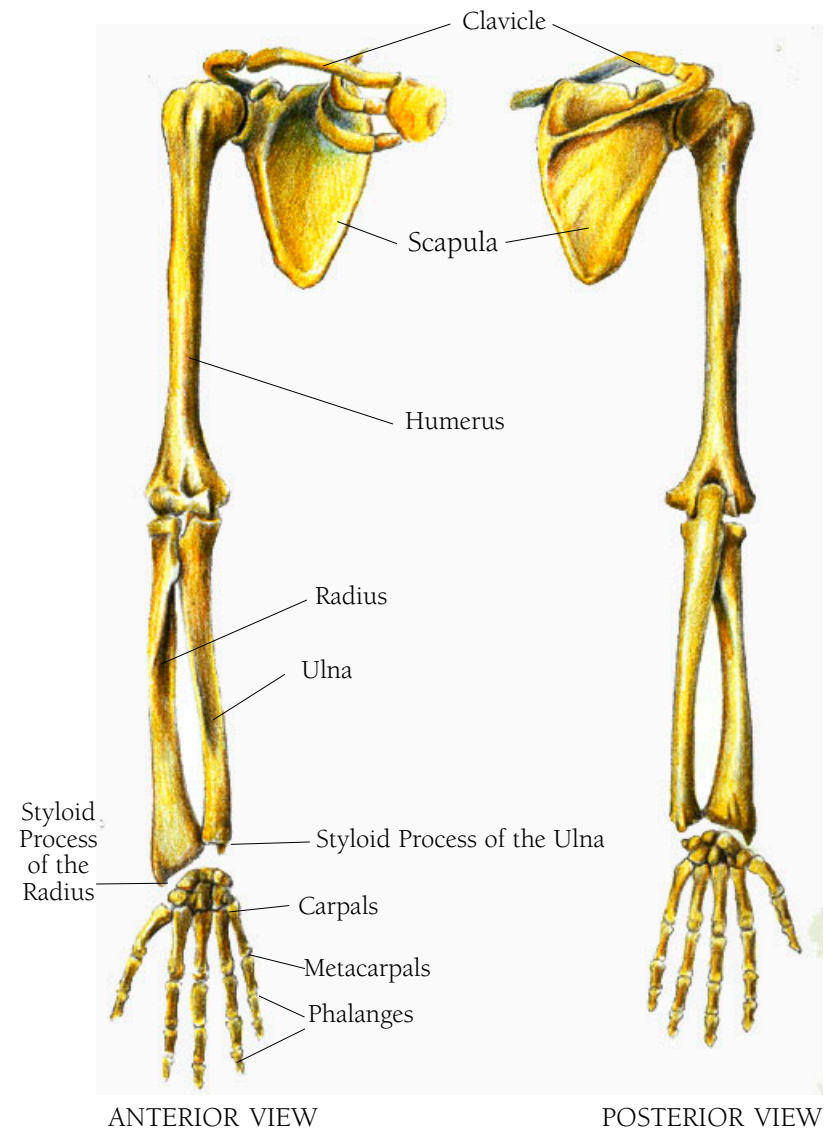
## *Arm and Hand Illustration 37*

THE BONES OF THE RIGHT ARM AND HAND WITH SHOULDER AND TWO RIBS: ANTERIOR VIEW; THE SAME BONES WITHOUT THE RIBS: POSTERIOR VIEW

You can see the clavicle, the scapula, the humerus, which makes up the whole shoulder joint, the radius, and the ulna, and the elbow that is the joint between the radius and the ulna and the humerus. Below them are the carpal bones, which form the wrist; the metacarpal bones, which form the body of the hand; and the phalanges, which are the fingers. There are many parallels between the arm /hand and the leg/foot. The differences are of interest also. At the knee, the leg can bend in only one direction. The lower leg is always in line with the upper leg. This is not so with the arm. Not only can the arm bend like the leg; the lower arm can also turn back and forth (supination and pronation), with the ulna staying in place and the radius pivoting around.

• • •

*Ulna* is Latin for forearm and *radius* is the Latin for rod or spoke.

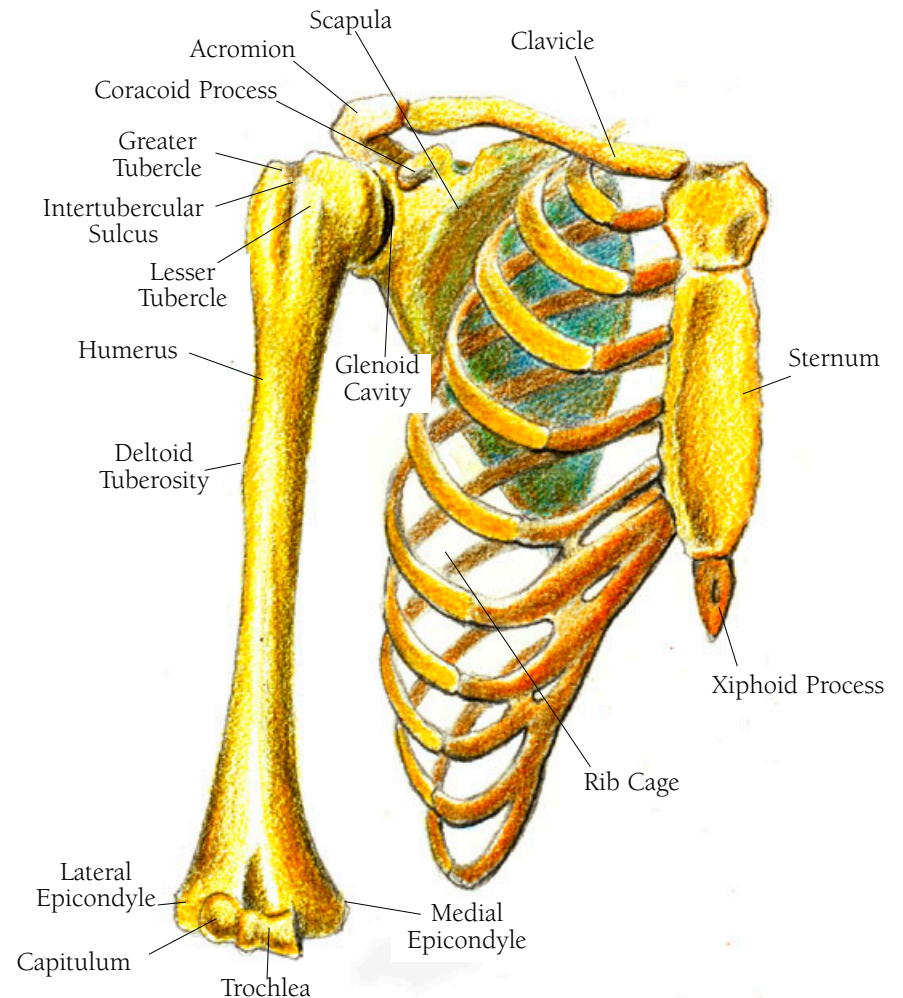


## *Arm and Hand Illustration 38*

### THE HUMERUS, THE CLAVICLE, THE RIB CAGE, THE STERNUM, AND THE SCAPULA: ANTERIOR VIEW

There are some features to be noted when looking at the humerus. At the top you see a rounded portion which fits into the socket called the glenoid cavity of the scapula. There is a small neck and then two protrusions divided by an indentation. The two protrusions are the greater tubercle on the lateral side and the lesser tubercle on the medial side, with each sitting on either side of the intertubercular sulcus. In the middle of the lateral side of the shaft is a slight protrusion called the deltoid tuberosity. As the shaft reaches the bottom it broadens to form the medial condyle on the inside with the medial epicondyle beyond it, and the lateral condyle with its lateral epicondyle beyond it on the outside. The hinge of the elbow, which allows the arm to bend, is made up of the trochlea and the capitulum. Note the xiphoid process at the bottom of the sternum.

A condyle is a rounded end of a bone that fits into a concavity in the adjoining bone so that a joint is formed and the bone can rotate within that joint.



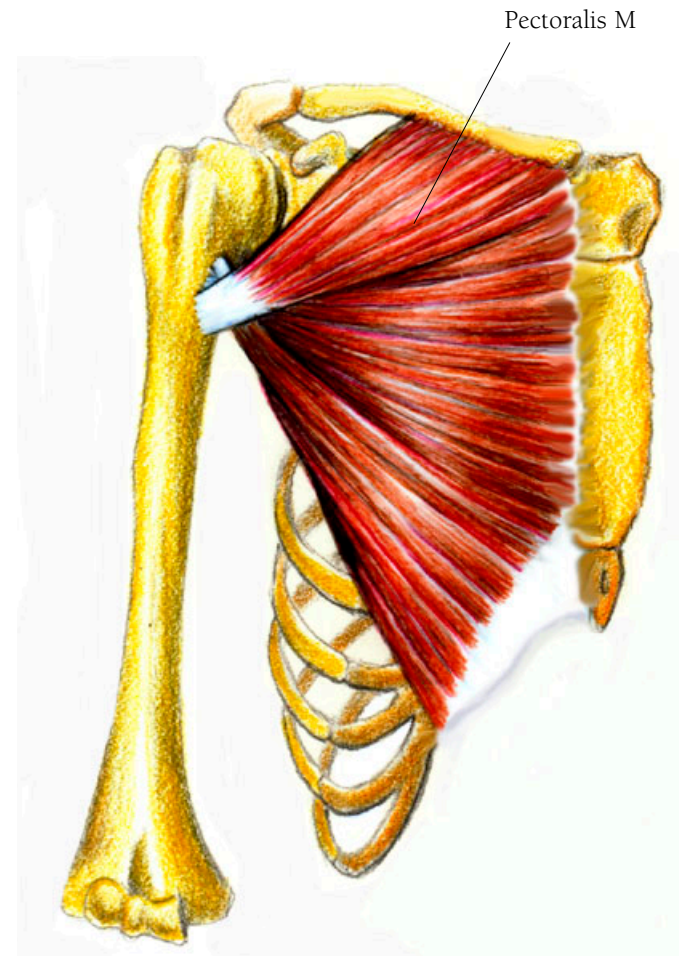
• • •

Condyle comes from the Greek *kondylos* and Latin *condylus* meaning knuckle or joint. The *epi* in epicondyle is from the Greek *epi-* a prefix meaning above or beside. *Trochlea* is from the Greek *trochilia* meaning a pulley. Capitulum is from the Latin *caput* meaning head. *Xiphoid* is from the Greek word *Xiphoeides* meaning sword shaped.

## *Arm and Hand Illustration 39*

### THE PECTORALIS MAJOR MUSCLE

This big muscle spreads across the chest area and moves the arm, by rolling the arm inward, or by moving it toward the body if held out. It arises along the middle half of the clavicle, the sternum, and the cartilage of the upper six or seven ribs. It then converges into tendinous endings which are in three parts and insert on the bicipital groove of the humerus; the lower portion attaches above, the middle portion attaches in the middle, and the upper portion attaches below. That middle portion lies beneath the other two portions, with the upper one on top.



## Arm and Hand Illustration 40

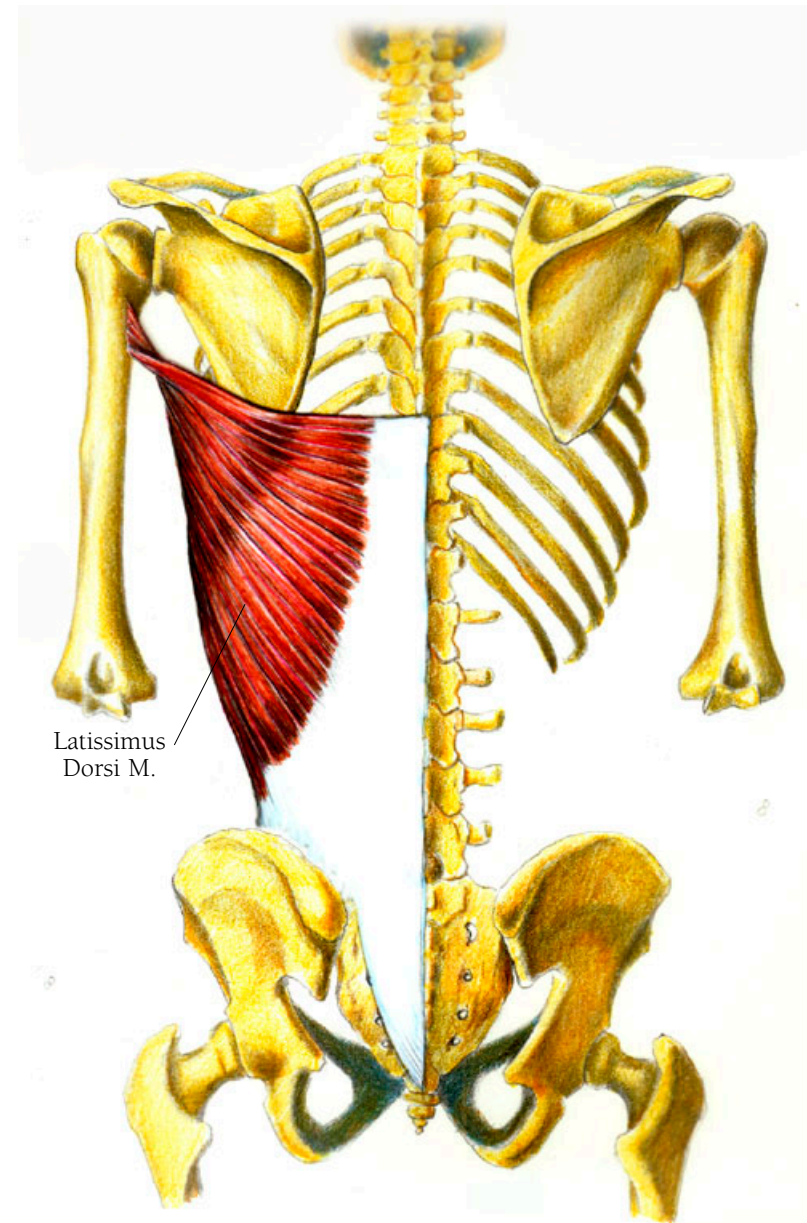
### THE LATISSIMUS DORSI MUSCLE

This muscle has a wide range of actions. It assists in arm rotation and it pulls the arm backward and inward from an outward position. It also pulls the body up in climbing. It plays a part in breathing as well, it aids in that last puff of expiration just when you think you've finished breathing out. It is also active when playing a wind instrument.

Starting wide and ending up by converging to a point it arises from a sheet of fascia known as an aponeurosis. You saw a tiny aponeurosis in the eye lid. This one is a broad sheet that arises along the vertebral column, from the spinous processes of the lower six thoracic vertebrae and from all of the lumbar vertebrae. It passes over the top of the iliac crest of the pelvis, or hip bone, and from there it passes over the tip of the scapula where fibers arise to join the main body of the muscle. All parts of this broad muscle converges to a small tendon that inserts on the humerus, its place of attachment being called the intertubercular groove. The tendon blends with the insertion fibers of the teres major just above it.

• • •

When translated from the Latin *latissimus dorsi* means “the widest back muscle.”



## *Arm and Hand Illustration 4I*

### THE CORACOBRACHIALIS MUSCLE

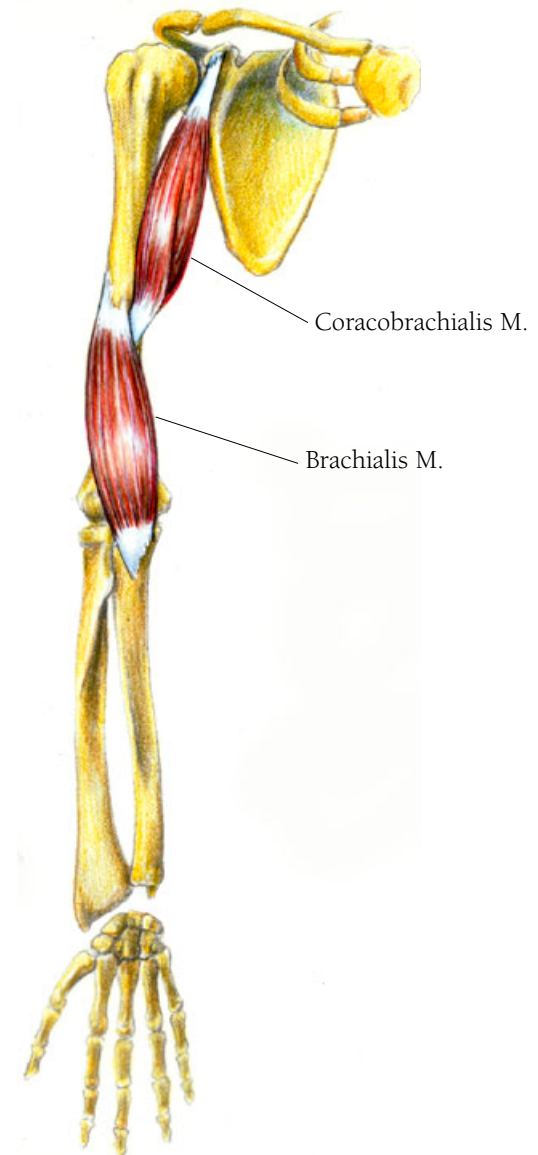
This muscle assists in bringing the arm forward and inward—called adduction. It arises from the coracoid process of the scapula (the supraglenoid tubercle is at the base of this process) and inserts on the shaft of the humerus along the inner border.

• • •

Coraco is a medical or anatomical term meaning “connection with or relation to” and brachialis is from Latin *brachium* meaning the arm from shoulder to elbow.

### THE BRACHIALIS MUSCLE

The brachialis muscle lifts the forearm when you bend the elbow. It arises on the humerus just beneath the insertion of the deltoid muscle, and other fibers of this muscle arise along the bone from just above the elbow joint. It inserts as a thick tendon on the top of the ulna.



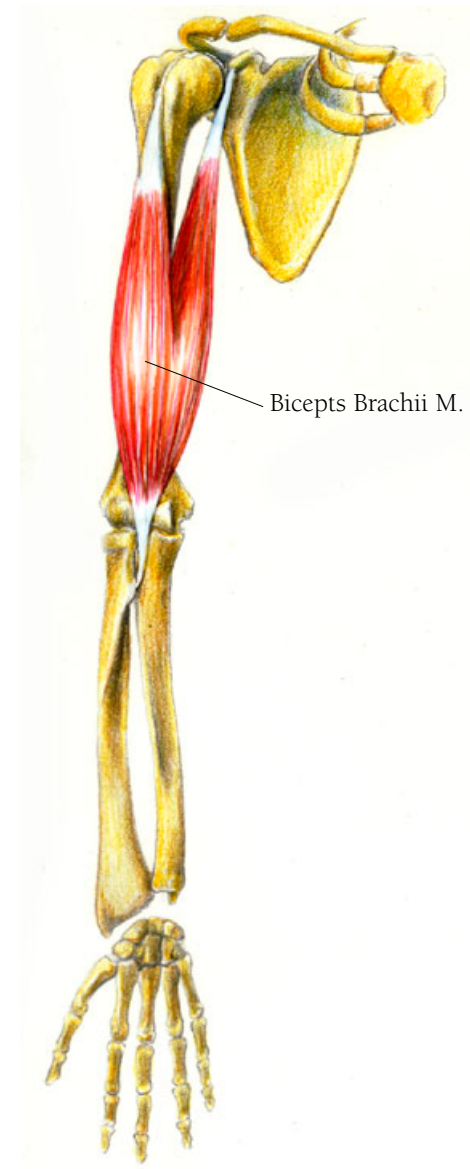
## Arm and Hand Illustration 42

### THE BICEPS BRACHII MUSCLE

The biceps brachii muscle, familiarly known as the biceps, moves the arm forward and assists in turning the hand outward, a movement called supination. The biceps is a long muscle extending the length of the humerus. It arises in two places. It arises in two places; medially, the short head arises from the coracoid process of the scapula and laterally, the long head arises as a slender tendon from the supraglenoid tubercle inside the capsule of the shoulder joint. The tendon passes over the head of the humerus into a groove called the intertubercular sulcus. At this point the muscle has two bellies which fuse and then form a single tendon at the bottom. The tendon inserts on the tuberosity of the radius.

• • •

Biceps derives from the Latin *bi* and *caput*, meaning two heads.





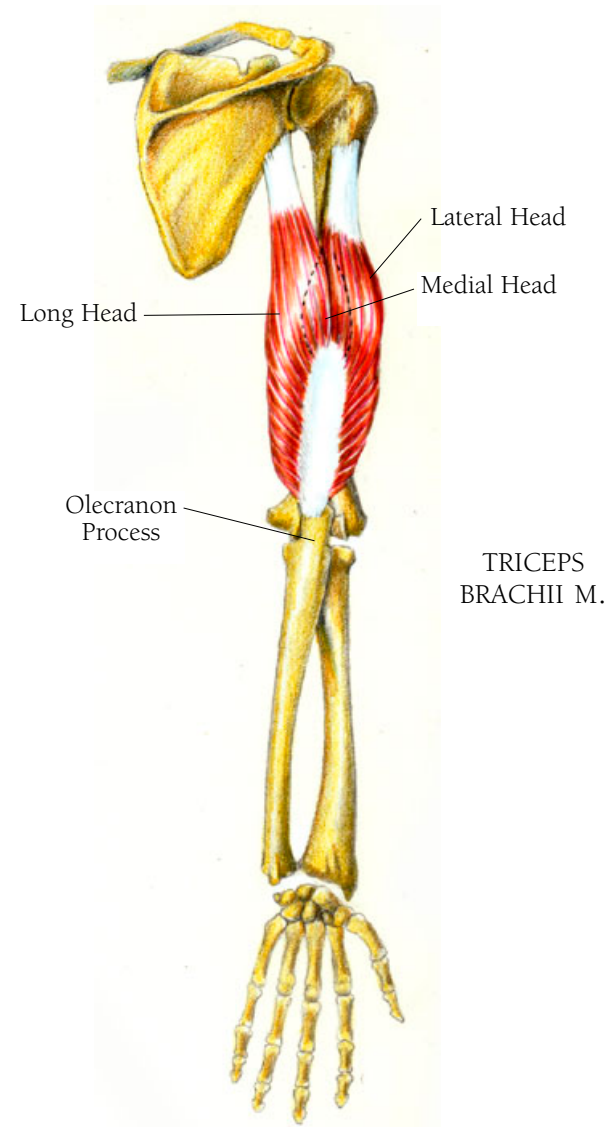
## *Arm and Hand Illustration 43*

### THE TRICEPS BRACHII MUSCLE

The triceps brachii muscle extends the forearm, straightens it out from a bent position and assists in pulling the entire arm inward (adduction). It has three heads called long, lateral, and medial. The long head arises from the infraglenoid tuberosity, a slight projection just below the glenoid cavity. The lateral head arises on the upper rear surface of the humerus. The medial head is covered by the bellies of the other two but arises on the rear shaft of the humerus about where the two outer bellies merge. The fibers of this muscle insert into a large tendon which inserts on the olecranon process (at the top rear of the ulna).

• • •

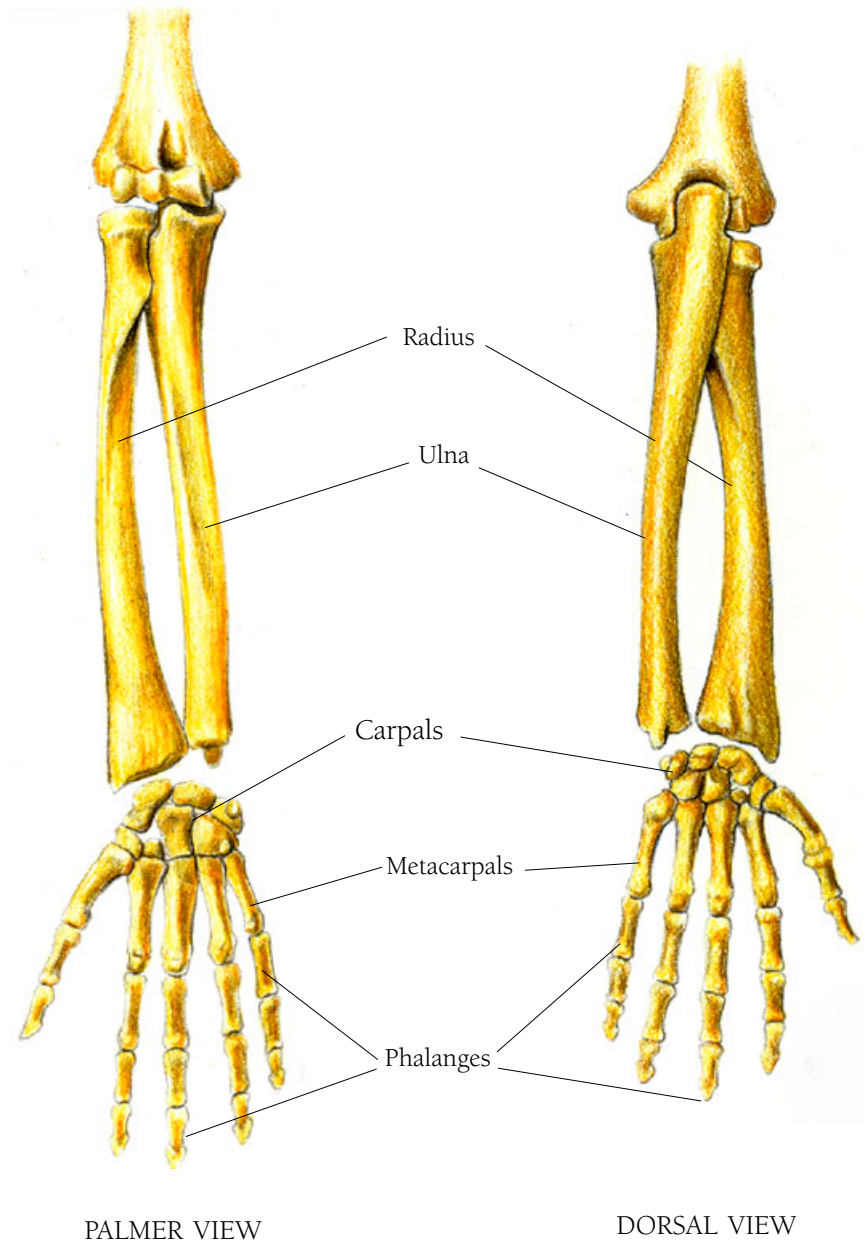
*Olecranon* is from the Greek for “head of the ulna.”



## *Arms and Hand Illustration 44*

### ELBOW AND FOREARM: PALMER AND DORSAL VIEWS

You can see the radius and the ulna of the lower arm, and the carpals, metacarpals, and phalanges of the wrist and hand.



PALMER VIEW

DORSAL VIEW

## Arm and Hand Illustration 45

### THE PRONATOR TERES MUSCLE

The pronator quadratus muscle lies right next to the bones, but the pronator teres muscle is in the superficial layer of muscles.

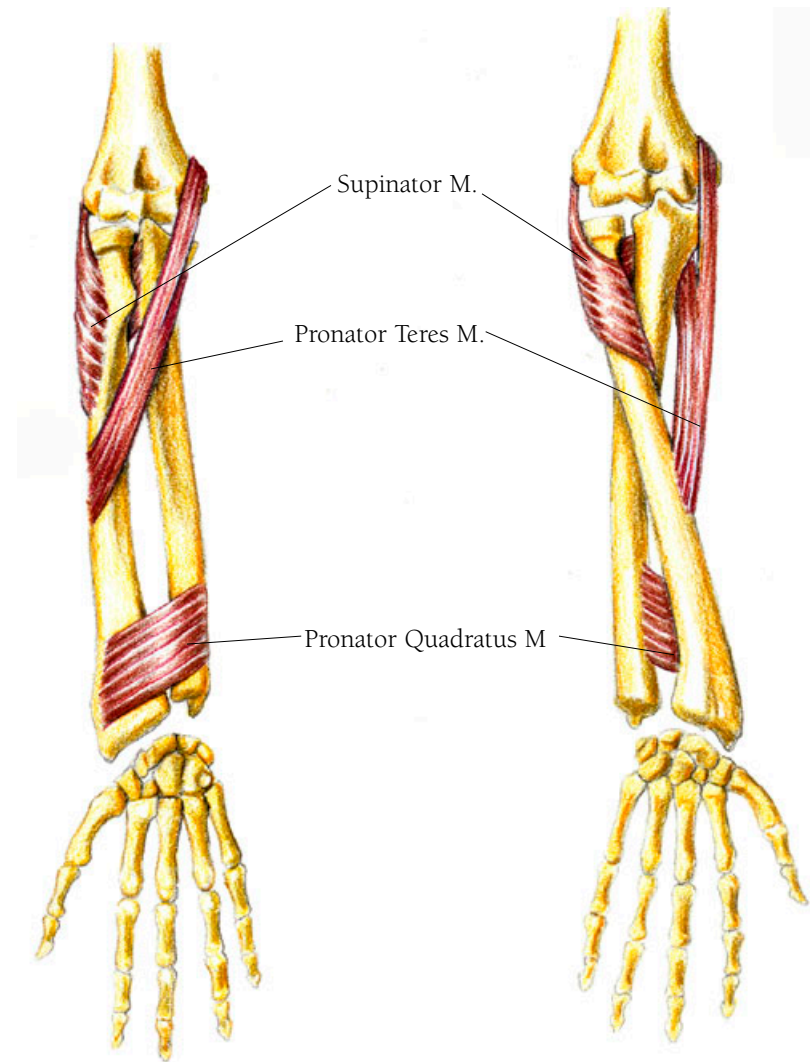
The pronator teres muscle assists in turning the lower arm from the hand facing up to the hand facing in a down position, especially when the arm is raised. It arises on the medial (inside) aspect of the epicondyle of the humerus and the coronoid process of the ulna, wraps around the radius and inserts in the middle of the outside of the shaft of the radius.

\* \* \*

*Epi condyle* comes from the Greek for “upon the knuckle.”

### THE PRONATOR QUADRATUS MUSCLE

Both the teres and the quadratus muscles assist in pronation of the arm and hand—that is in turning the hand and lower arm so the hand faces down when the arm is bent. Found just above the wrist it arises on the inner surface of the ulna, passes along the palmar side of the arm and inserts on the outer surface of the radius.



## THE SUPINATOR MUSCLE

The supinator muscle turns your lower arm and hand from downward to upward facing positions. It arises from the top rear of the ulna and wraps around the radius to insert on its front surface.

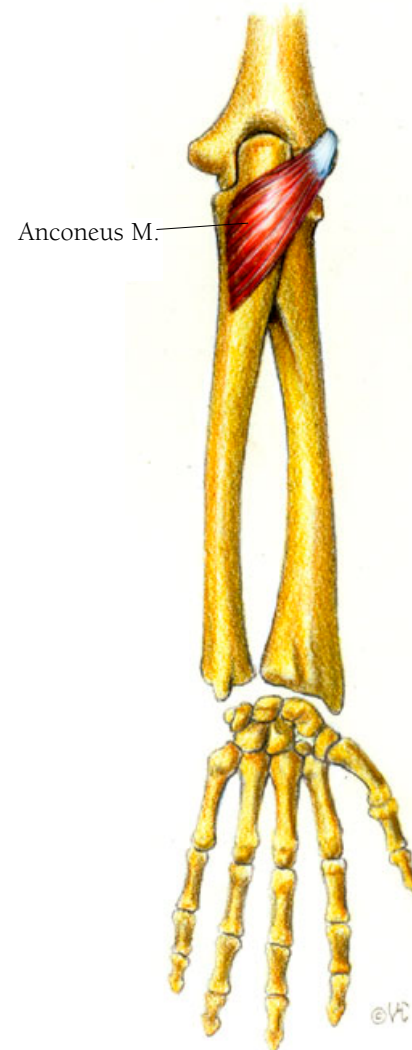
## Hand and Arm Illustration 46

### THE ANCONEUS MUSCLE

The anconeus muscle extends the elbow, helping to straighten the arm from a bent position. While appearing on the lower arm, it works synergistically with the triceps brachii muscle. It arises from the lateral or outside epicondyle of the humerus and crosses the elbow joint at the rear to insert on the olecranon of the ulna.

• • •

Anconeus derives from the Greek and Latin meaning elbow. *Ancos* in Greek means to bend.



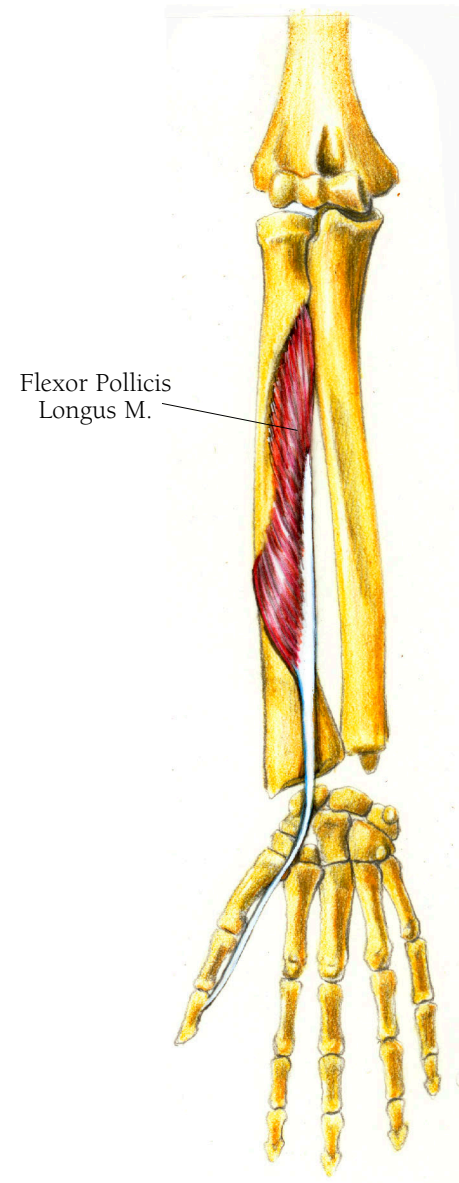
## *Arm and Hand Illustration 47*

### THE FLEXOR POLLICIS LONGUS MUSCLE

This muscle flexes (bends) the thumb arising near the top of the radius and along the interosseous membrane. Its fibers merge into a flat tendon that passes under the flexor retinaculum. The flexor retinaculum is a tendinous tissue covering the palmar side of the carpals, or wrist bones, forming a tunnel through which all the tendons from the flexor muscles pass in order to control finger movement. A&H-67 is an illustration of the flexor retinaculum. From there the tendon passes down the thumb to insert on the final or distal phalanx, the last little bone.

• • •

Pollicis comes from the Latin word *pollex*, meaning thumb. This muscle is “the long flexor of the thumb.” Interosseus is from the Latin and means “between the bones.” *Retinaculum* is the Latin for “hold fast, tether.”



You will see that the digits have muscles to extend, to flex, to abduct and adduct it. You could think of the flexors and extenders as the strings and the fingers are the like the puppets being controlled by them. If all the muscles controlling finger and thumb movement were in the hand, the hand would be much too bulky to be useful.

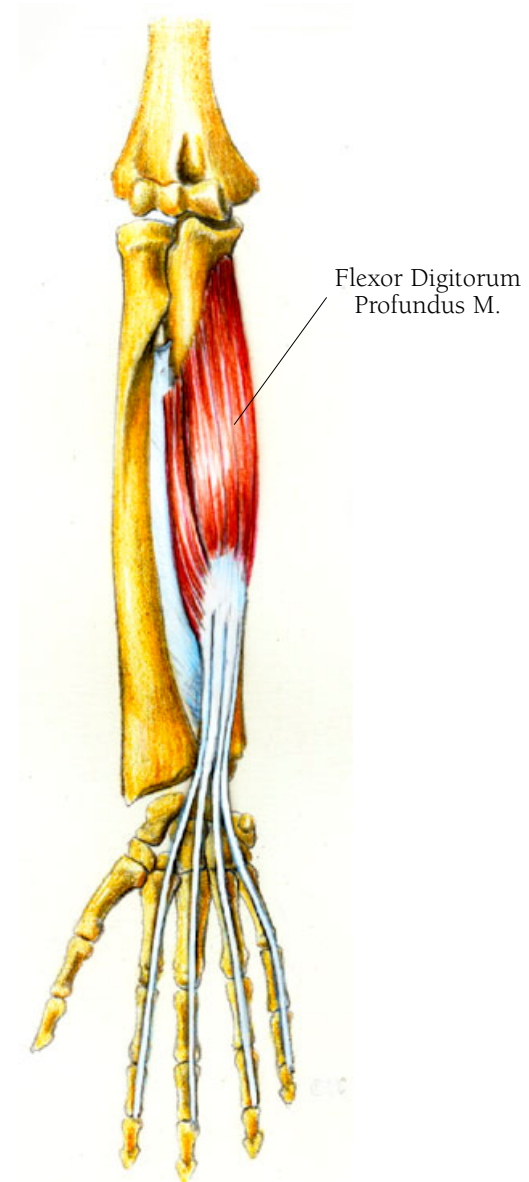
## Arm and Hand Illustration 48

### THE FLEXOR DIGITORUM PROFUNDUS MUSCLE

The flexor digitorum profundus muscle flexes the fingers. It arises on the ulna and the interosseous membrane. The muscle merges into a tendon that separates into 4 tendons which course down the arm, passing under the flexor retinaculum. Each tendon finally inserts on the distal phalanx at the end of each finger. The tendon for the index finger is slightly separated from the other three because the index finger is so important. All the tendons are encased in what are called synovial sheathes for protection and to keep them in line as they pass down the length of the fingers.

• • •

Synovial comes from the Greek word *syn* meaning “together with,” and *ovial*, which comes from *ovum*, the Latin word for egg. This tissue secretes a viscous fluid, something like the white of an egg, which lubricates the tendons so that they can move back and forth easily.





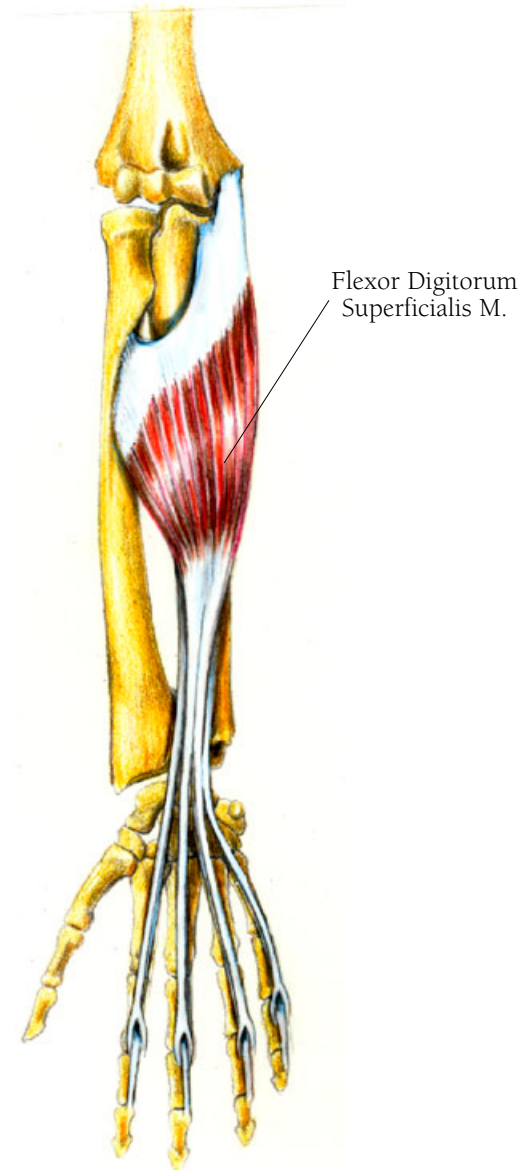
## Arm and Hand Illustration 49

### THE FLEXOR DIGITORUM SUPERFICIALIS MUSCLE

This muscle bends both the entire hand and each finger at the second joint. It has three heads, the first one arising on the inner epicondyle of the humerus, the second from the coronoid process of the ulna, and the third along a portion of the shaft of the radius. They all converge into one tendon which in turn becomes four tendons that pass under the flexor retinaculum and continue to each of the fingers. These insert on each side of the middle phalanx by separating at their ends allowing the tendons of the flexor digitorum profundus muscle to pass through.

• • •

*Digitus* means finger and *digitorum* “of the finger” in Latin.



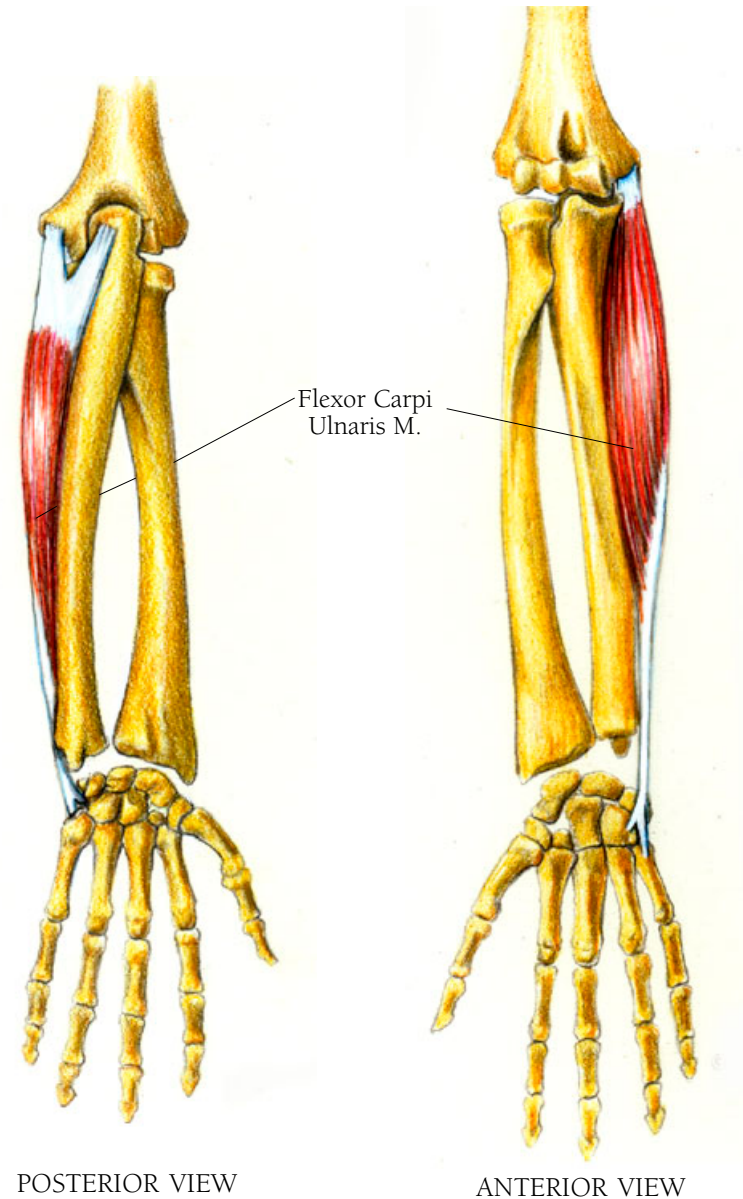
## *Arm and Hand Illustration 50*

### THE FLEXOR CARPI ULNARIS MUSCLE: ANTERIOR AND POSTERIOR VIEWS

The flexor carpi ulnaris muscle flexes the wrist bending it outward. It arises on the posterior side of the humerus, on its medial or inner epicondyle, and courses around the ulna to merge into a tendon which then inserts on two of the carpal bones and the fifth metacarpal bone.

• • •

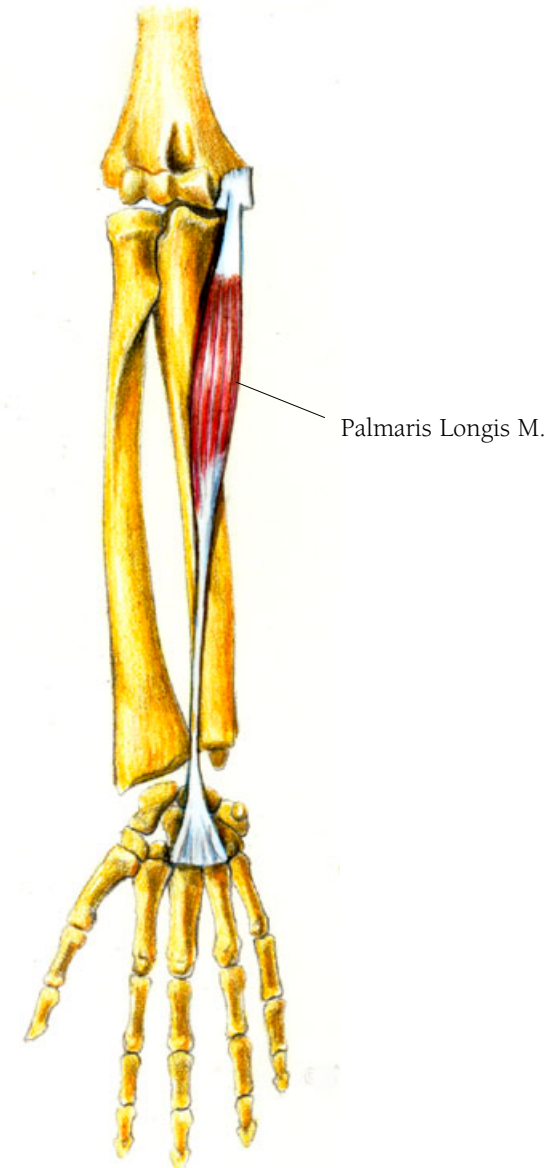
*Karpos* is Greek for wrist and *meta* means between.



## *Arm and Hand Illustration 5I*

### THE PALMARIS LONGUS MUSCLE

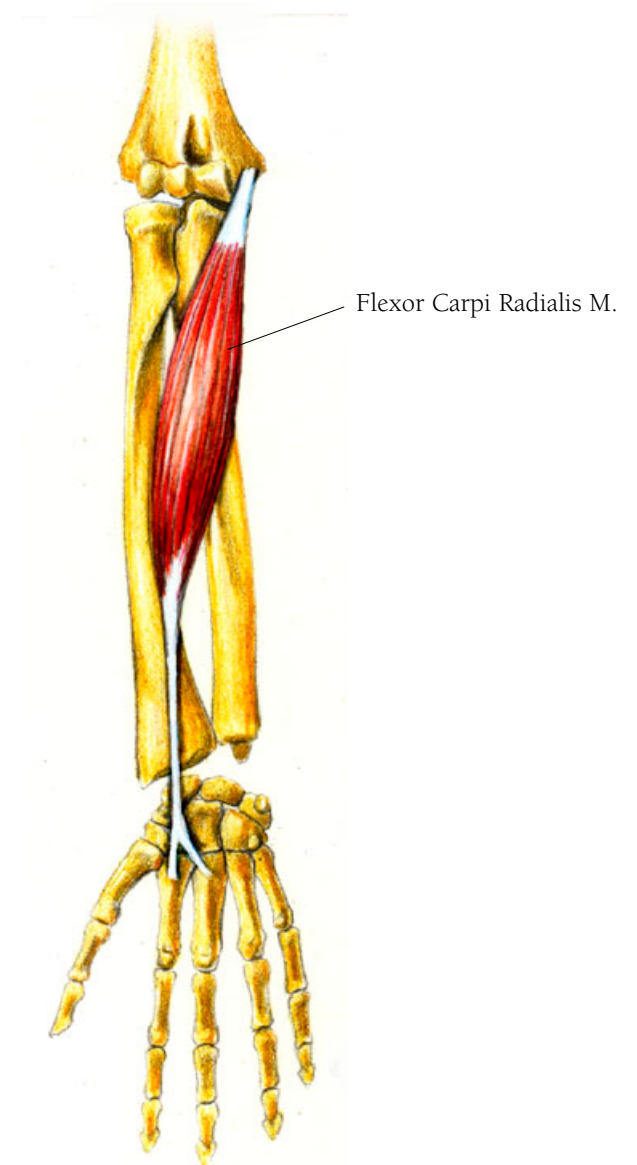
The palmaris longus muscle assists in bending the wrist. It arises on the medial epicondyle of the humerus and inserts as a tendon into the palmar aponeurosis.



## *Arm and Hand Illustration 52*

### THE FLEXOR CARPI RADIALIS MUSCLE

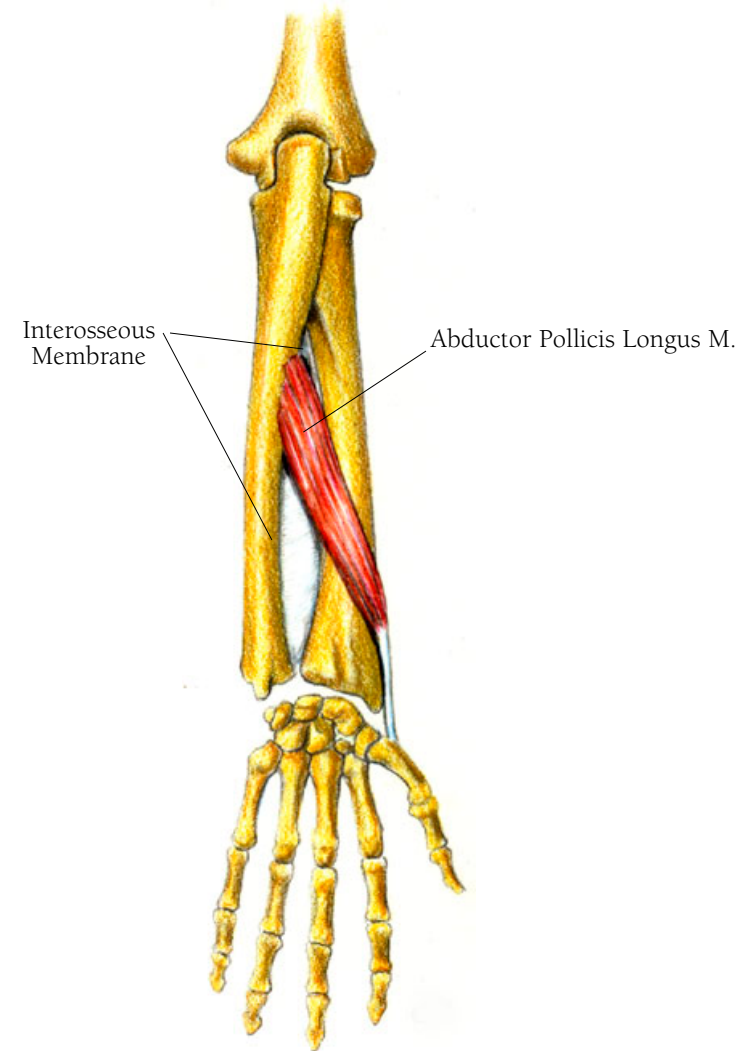
This muscle assists in bending the wrist forward and to the side. It also arises on the medial epicondyle of the humerus and inserts as a split tendon on the second and third metacarpals.



## *Arm and Hand Illustration 53*

### THE ABDUCTOR POLLICIS LONGUS MUSCLE

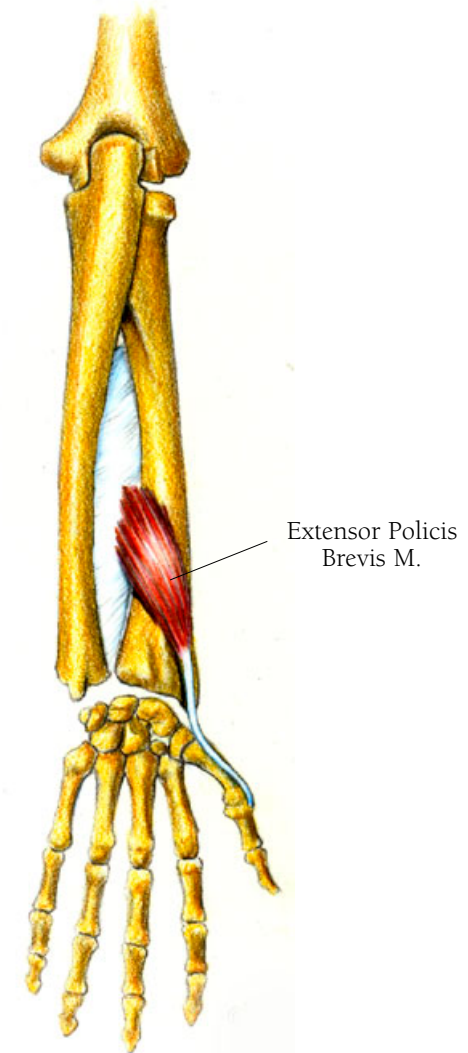
The abductor pollicis longus muscle assists in bending the thumb, and with it the wrist outward when the palm faces forward. It arises a little above mid shaft along the back of the radius and the interosseous membrane to merge into a tendon that inserts on the base of the first metacarpal, the bone that forms the base of the thumb.



## *Arm and Hand Illustration 54*

### THE EXTENSOR POLLICIS BREVIS MUSCLE

The extensor pollicis brevis muscle both extends the thumb and assists in bending the wrist outward. It arises on the back side of the radius and the interosseous membrane, wraps around to the inside of the radius, and courses downward as a tendon to insert at the base of the first phalanx of the thumb.



## Arm and Hand Illustration 55

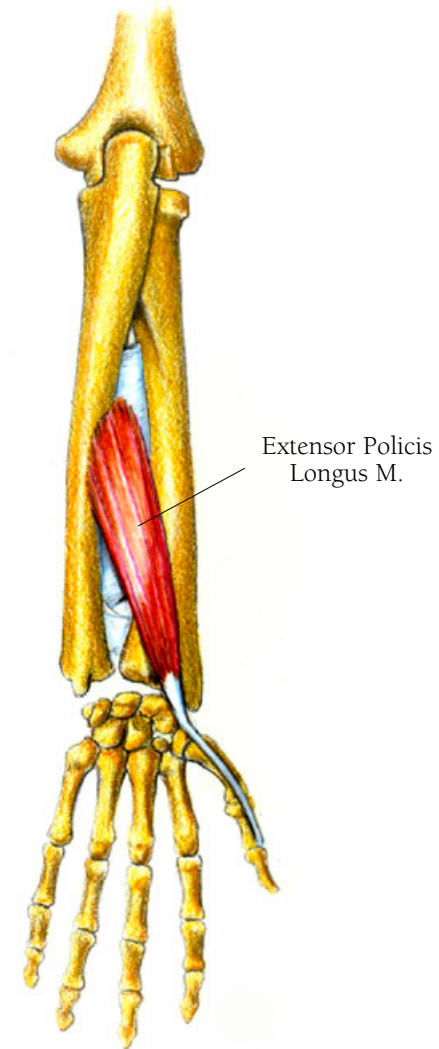
### THE EXTENSOR POLLICIS LONGUS MUSCLE

This muscle extends the thumb and also assists in moving the hand in the direction of the thumb—the forth of back and forth. It arises from the surface of the body of the ulna, just above the abductor pollicis longus, courses downwards and then crosses over the tendons of the extensor carpi radialis longus and brevis. It inserts at the base of the last phalanx of the thumb, creating with the extensor pollicis brevis a triangular indented shape known as the “anatomical snuff box.” It seems the little indentation at the end of the thumb, just in front of the wrist, caused by the extension of the thumb, was used in earlier times as a place from which to sniff one’s snuff.

• • •

Pollicis is derived from the Latin word *pollex*, meaning thumb.

What is the difference between abduction and extension of the thumb? Abduction means movement away from the body. Extension is movement of the body part backward from its normal position. Extension is what you’re doing when you are thumbing a ride. When you’re thumbing your nose, that’s abduction.



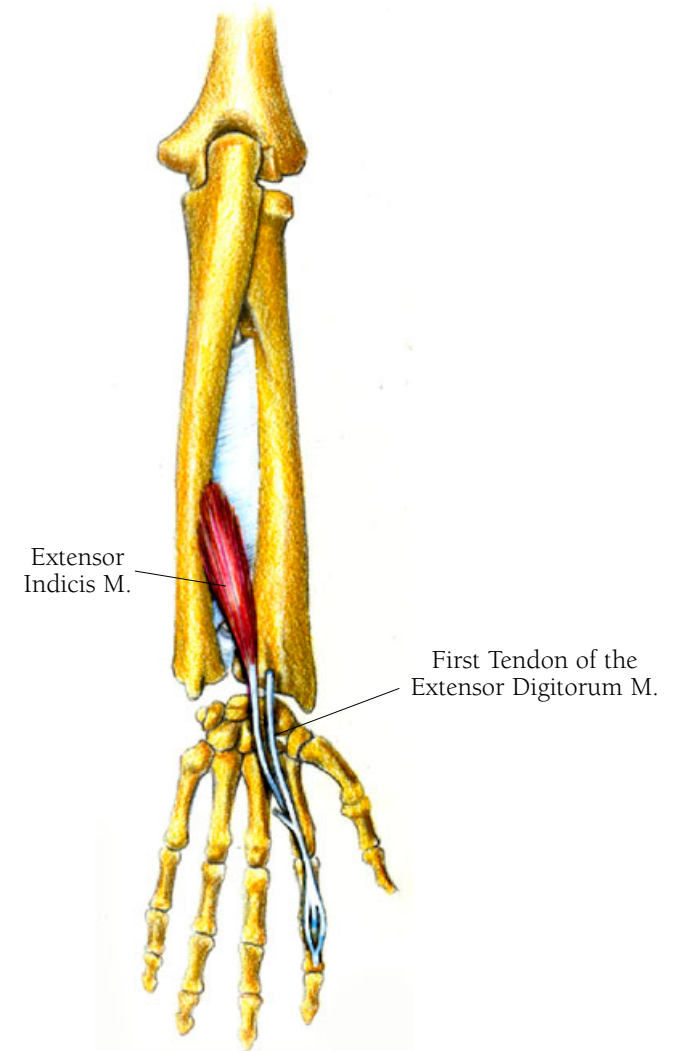
## Arm and Hand Illustration 56

### THE EXTENSOR INDICIS MUSCLE

The extensor indicis muscle extends the first or pointer finger, even slightly bending it backward. It arises on the rear surface of the shaft of the ulna, about two thirds of the way down, and from the interosseous membrane. It ends its independent course at the first phalanx of the index finger, where it joins the first tendon of the extensor digitorum muscle, from beneath.

• • •

*Index, indicis*, is Latin for “that which points out.”





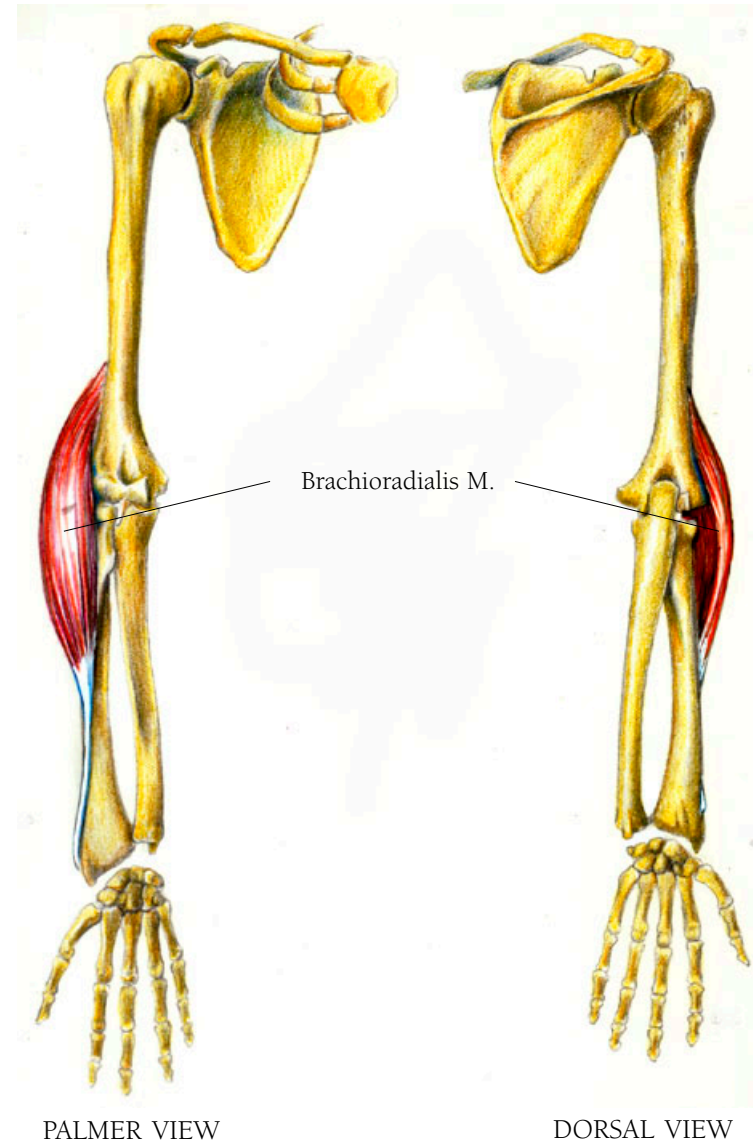
## Arm and Hand Illustration 57

### THE BRACHIORADIALIS MUSCLE

This muscle raises the forearm up, bending the elbow. It arises from the lateral side of the epicondyle of the humerus and inserts on the styloid process of the radius, the flared lower end of the radius.

• • •

*Brachio* is Latin for “of the arm” and *radialis* refers to the bone called the radius.



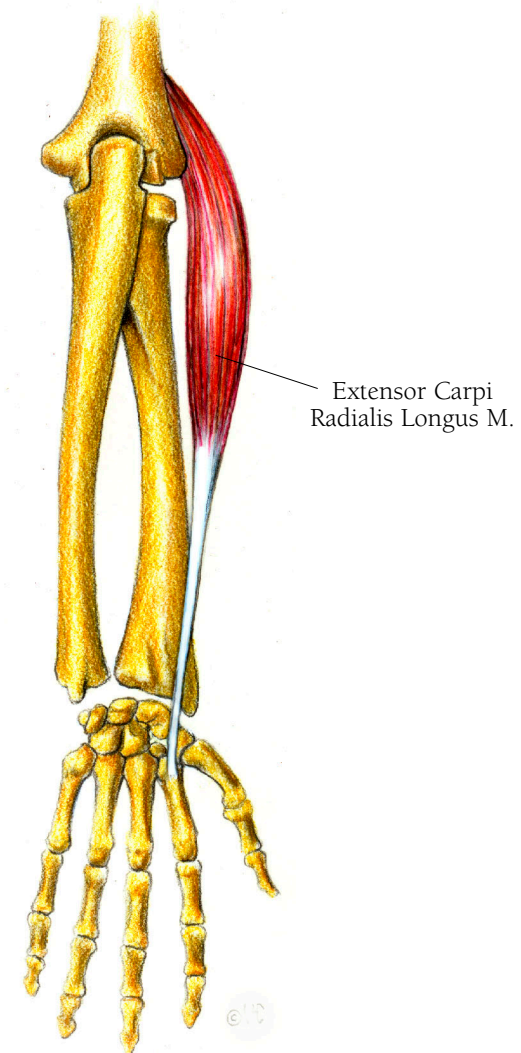
## Arm and Hand Illustration 58

### THE EXTENSOR CARPI RADIALIS LONGUS MUSCLE

This muscle extends the wrist and bends it toward the body when the palm is facing back. It arises from the lateral epicondyle of the humerus, (same as the brachioradialis but just beneath it). It inserts on the base of the second metacarpal bone located at the base of the index finger.

• • •

*Carpi* is the plural form of *carpus*, Latin for wrist.



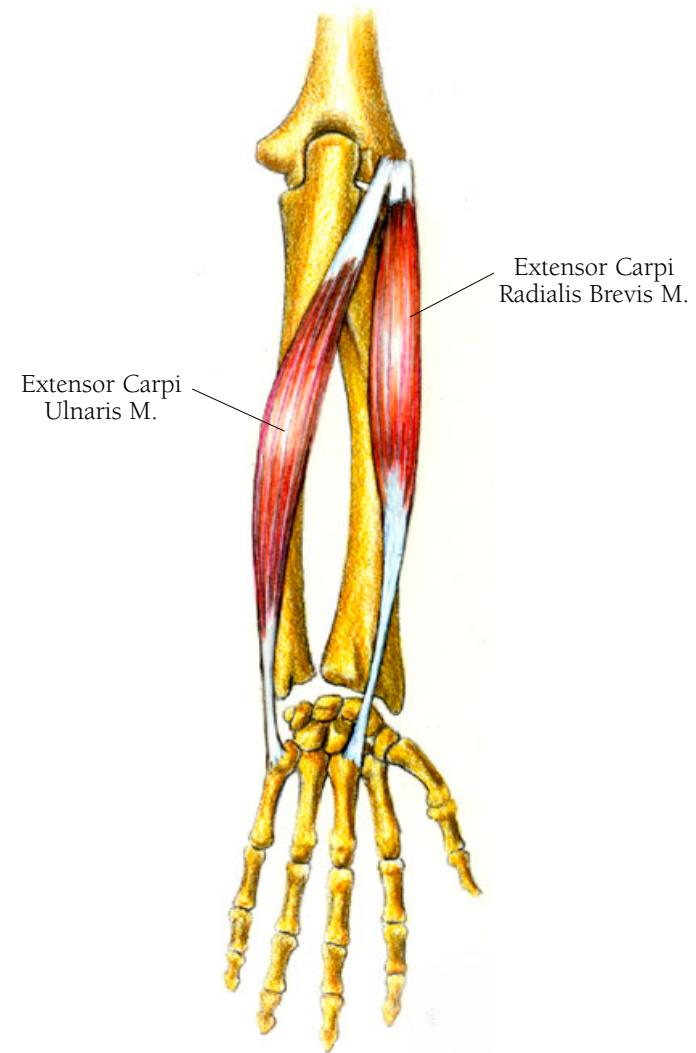
## *Arm and Hand Illustration 59*

### THE EXTENSOR CARPI ULNARIS MUSCLE

The extensor carpi ulnaris muscle extends and bends the hand outward as when you put your hands up to signal “stop.” Like the extensor carpi radialis longus muscle, it arises from the lateral epicondyle of the humerus, sharing a common tendon with that muscle as well as the following one, the extensor digitorum. It passes along the outside of the ulna to insert as a tendon on the base of the fifth metacarpal.

### THE EXTENSOR CARPI RADIALIS BREVIS MUSCLE

This muscle extends the wrist by bending the hand back as if you were shyly raising your hand in class. Like the extensor carpi radialis longus muscle and the extensor carpi ulnaris muscle, it arises from the lateral epicondyle of the humerus and inserts as a tendon on the base of the third metacarpal.



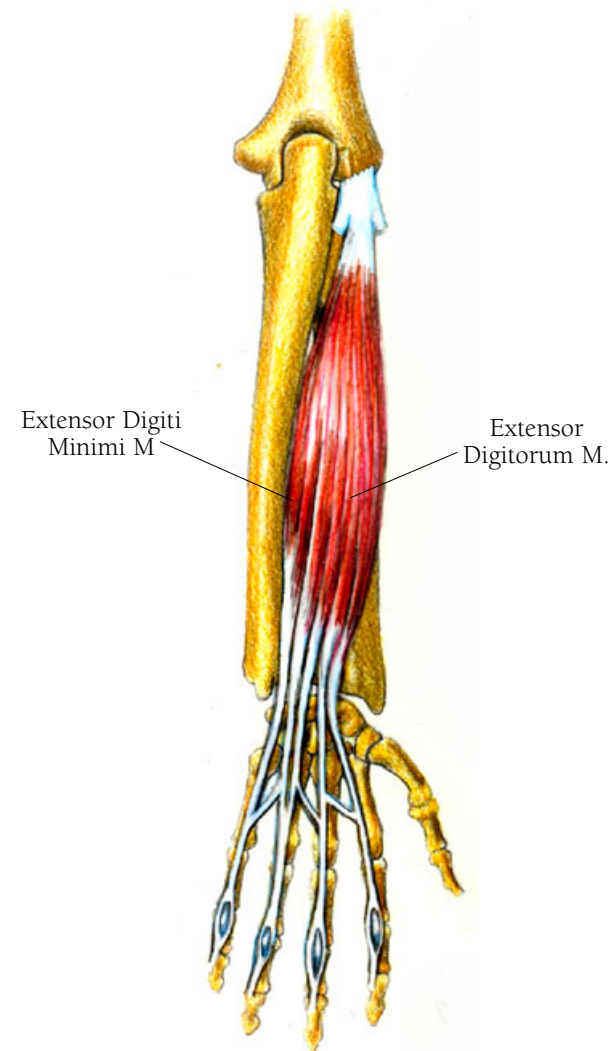
## *Arm and Hand Illustration 60*

### THE EXTENSOR DIGITORUM MUSCLE

The extensor digitorum muscle extends all of the joints over which it passes, assists in spreading the fingers, and plays a major role in the coordination of finger movement. It arises from the common tendon shared by the last three muscles discussed, on the lateral epicondyle of the humerus, and passes down over the radius to divide into four tendons which pass over the carpal bones of the wrist. Each of these tendons then inserts at the base of the middle phalanx of each finger.

### THE EXTENSOR DIGITI MINIMI MUSCLE

The extensor digiti minimi muscle enhances the function of the extensor digitorum. It arises from the common tendon discussed above, on the lateral epicondyle of the humerus, passes down the radius, and crosses over the carpals at an angle to join the most lateral of the tendons of the extensor digitorum. It inserts, with the tendon of the extensor digitorum, on the base of the middle phalanx of the little finger.

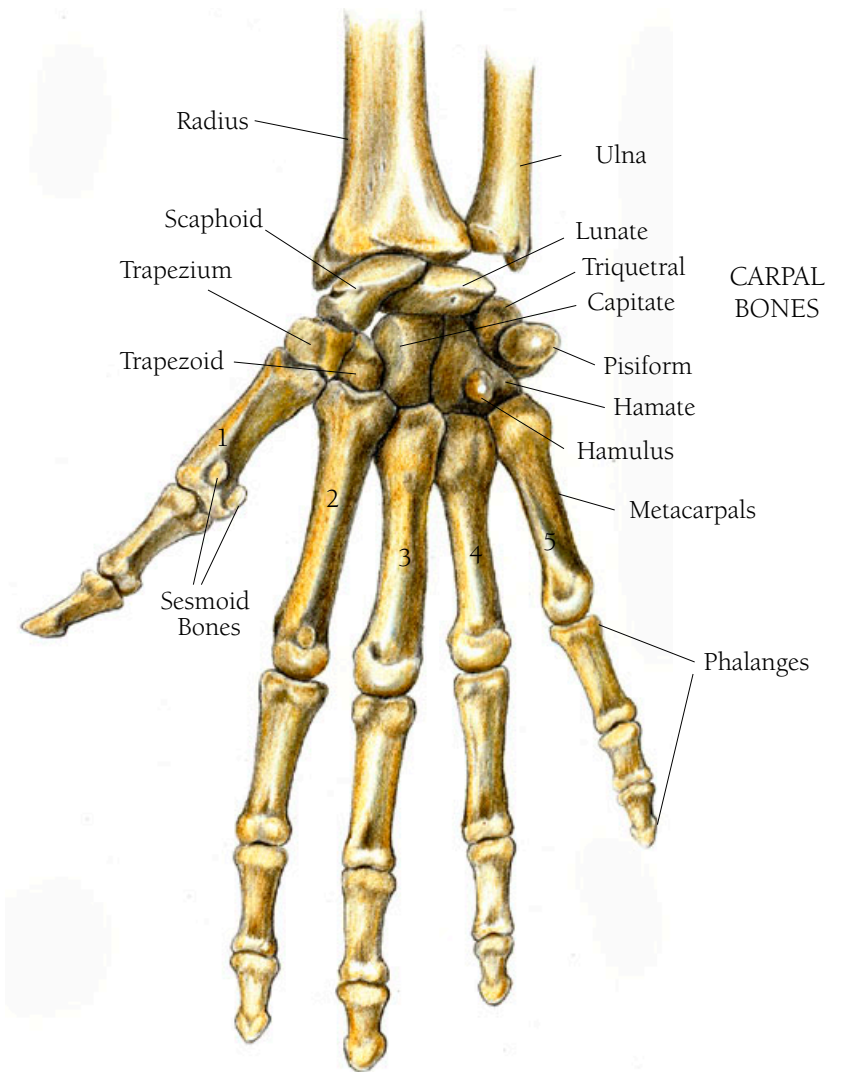


The tendons of the extensor muscles are enclosed in synovial sheaths. I am not going to show the synovial sheaths in the illustrations because they would prevent your seeing the continuity of the tendons from the arm to the hand to the fingers. Covering the tendons at the wrist like a half bracelet is a fascia called the extensor retinaculum, from the Latin for “that which holds back the extensors.” Unlike the flexor retinaculum, which is tendinous and has muscle attachments, this tissue serves only to contain the extensor tendons.

## Arm and Hand Illustration 6I

### THE BONES OF THE RIGHT HAND AND WRIST: PALMAR VIEW

The bones of the hand and wrist are divided into three areas, the carpals, the metacarpals, and the phalanges. There are eight pebble like bones in the wrist called the carpal bones. These are aligned in two rows of four each. All of them articulate with each other except for the pisiform which sits on top of the triquetral bone. Going from the articulation with the radius to those articulating with the metacarpals, they are: the scaphoid, which articulates with the radius; the lunate; the triquetral; and the pisiform. In the inner or proximal row are the trapezium, found at the base of the thumb, the trapezoid, the capitate, and the hamate bones. There are two little sesmoid bones on the distal end of the metacarpal of the thumb and another, the hamulus, a projection on the hamate bone in the wrist. The metacarpals form the body of the hand and are long and narrow with knobby ends. The phalanges form the fingers and the thumb. The thumb has two phalanges called the proximal and distal bones. The other fingers have three called the proximal, middle and distal bones. Proximal means nearest the center of the body; distal means furthest from the center of the body.

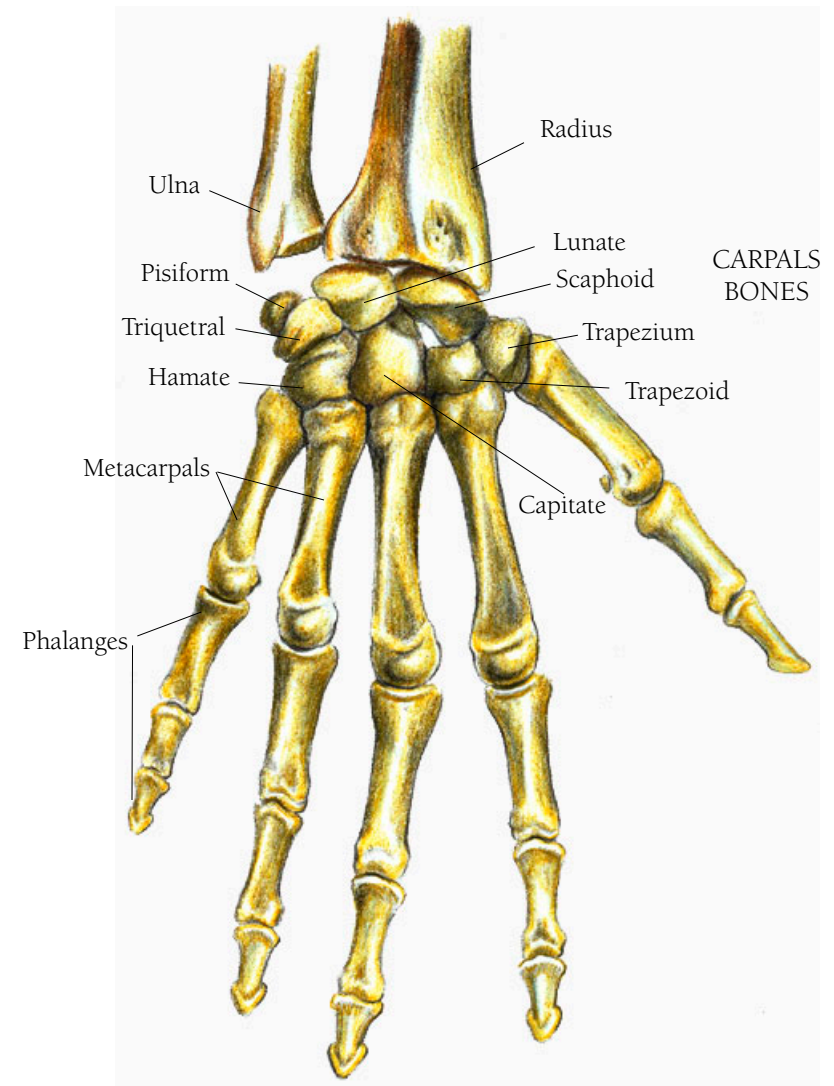


PALMER VIEW

## Arm and Hand Illustration 62

### THE BONES OF THE HAND AND WRIST, DORSAL VIEW

Carpal is from the Latin *carpus*, meaning wrist. Scaphoid means “resembling a boat” and is from the Greek *skaphe*, *skaphos*, meaning boat. Lunate means crescent-shaped like a half moon, from the Latin *luna* meaning moon. Triquetral is from the Latin *triquetrus*, meaning three cornered. Pisiform is from the Latin *pisum* and *-form*, meaning “shaped like a pea.” Trapezium, from the Greek *trapezion*, means a shape having four sides, no two of which are parallel. A trapezoid is a four-sided figure with two parallel sides. Capitate is from the Latin *caput*, meaning head. Hamate is from the Latin *hamatus*, meaning hooked or “having a hook,” *hamus*, meaning hook in Latin. This bone has a projection that is hook-like. The *meta-* in metacarpal comes from the Latin and Greek for among or between. This places the metacarpals between the carpals and the phalanges. Phalanges comes from the Latin and Greek *phalanx*, meaning “a line of battle or a battle array.” In Latin *phalanger*, means “a bone between two joints of the fingers or toes.” Palmar comes from the Latin *palmaris*, meaning the “palm of the hand.”

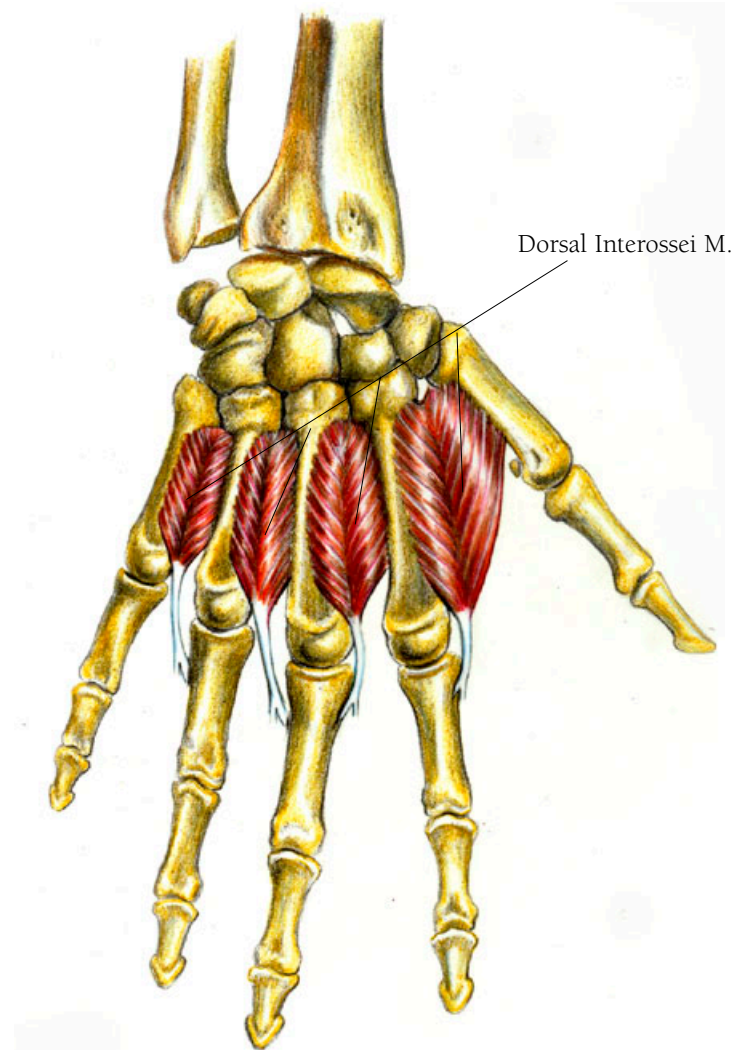


DORSAL VIEW

## *Arm and Hand Illustration 63*

### THE DORSAL INTEROSSEI MUSCLES

The dorsal interossei muscles assist in the abduction or spreading of the fingers. They arise from the adjacent surfaces of the metacarpal bones and insert at the base of the innermost phalanges of all fingers except the little one. They feather out between each set of metacarpals. They arise on the metacarpals with the fibers meeting in a middle line that then forms tendons. These insert on the proximal ends of the first phalange of the fingers.

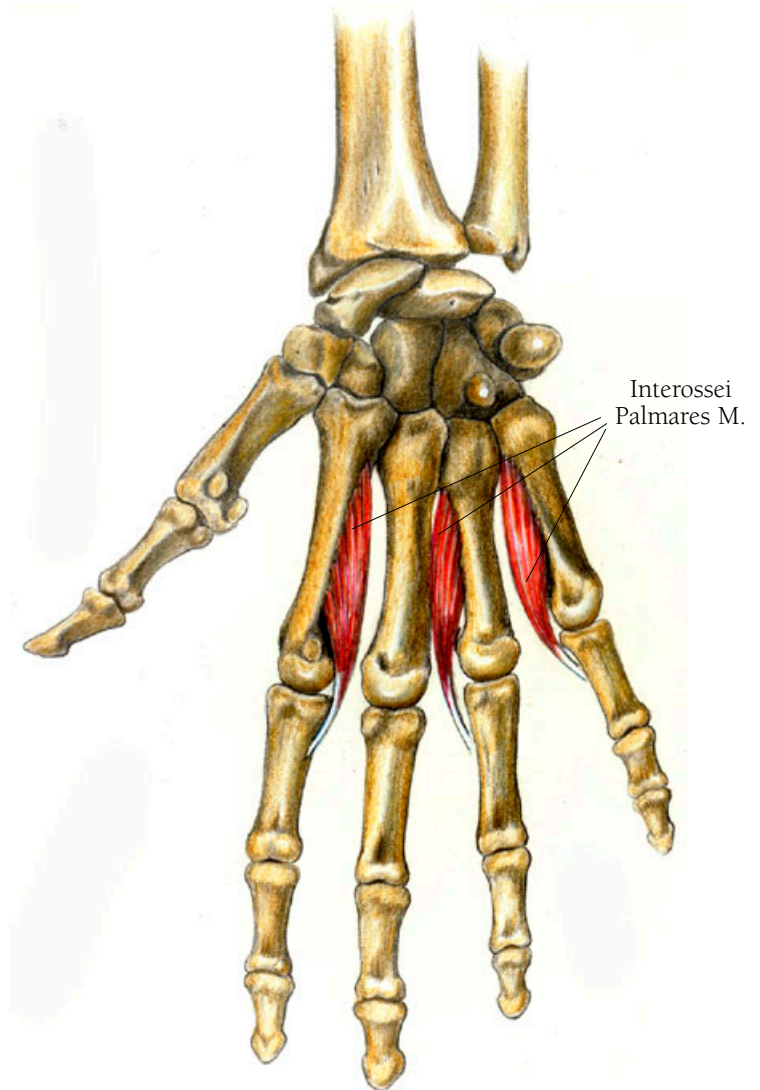




## *Arm and Hand Illustration 64*

### THE INTEROSSEI PALMARES MUSCLES

These small muscles assist in moving the fingers towards the middle of the hand. They arise on the shafts of second, fourth and fifth metacarpals and pass on the palmar side of these bones to insert at the bases of the first or innermost phalanges of the same fingers and on same side. The one associated with the index finger arises and inserts on the left side of the bones in the right hand, the other two arise and insert on the right side.



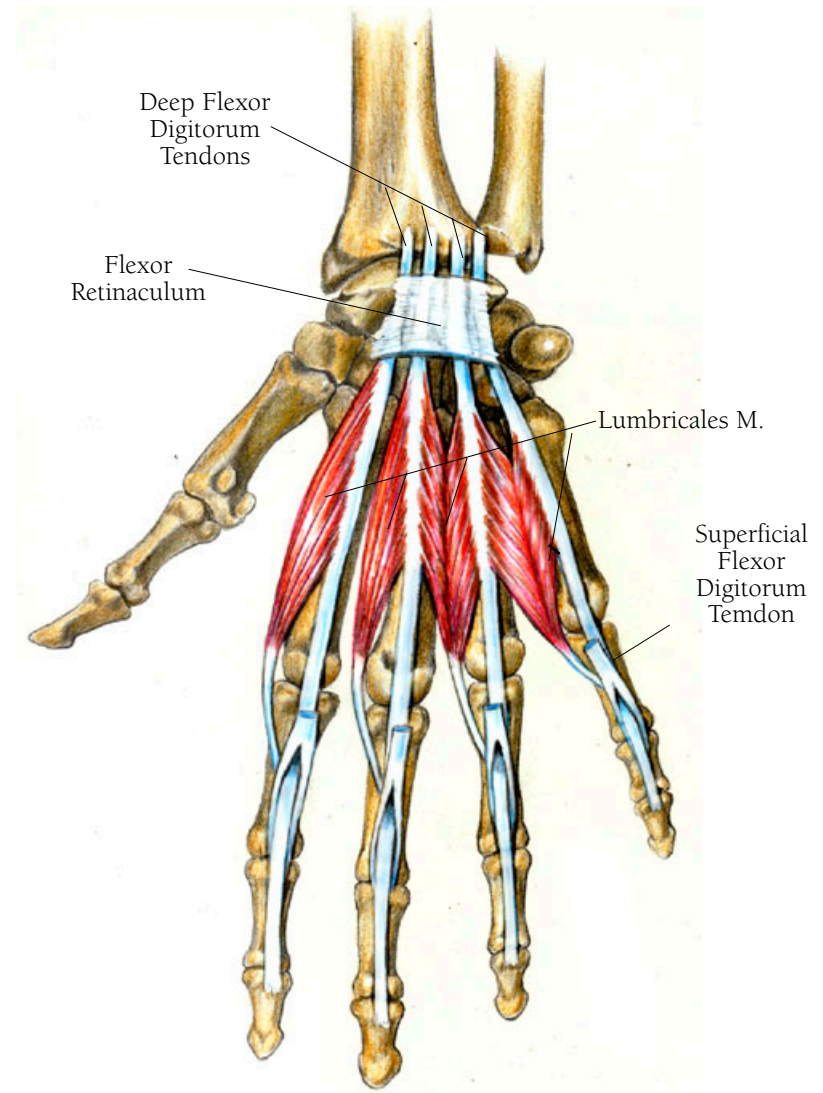
## Arm and Hand Illustration 65

### THE LUMBRICALES MUSCLES OF THE HAND

The lumbricales muscles move the fingers so that they can hold a pencil. They arise from the palmar part of the tendons of the flexor digitorum muscle, the muscle tendon that divides into four tendons leading to the ends of the fingers, discussed above. They insert in the following manner: on the right hand, palm side up, the lumbrical originating from the tendon leading to index finger arises on the right side of the tendon and inserts into the right mid-side of the innermost phalanx. The next one, arising from the tendon leading to the middle finger, inserts mid shaft on the same side of the innermost phalanx of the middle finger. Between this tendon and the next one, the one leading to the ring finger, muscle fibers arise and join to form a tendon that inserts along right side of the mid-shaft of the innermost phalanx of the ring finger. The identical pattern is seen between the ring and little finger tendons: the insertion of these joined muscle fibers is along the right side of the shaft of the innermost phalanx of the baby finger.

• • •

*Lumbricale* is Latin for earthworm.



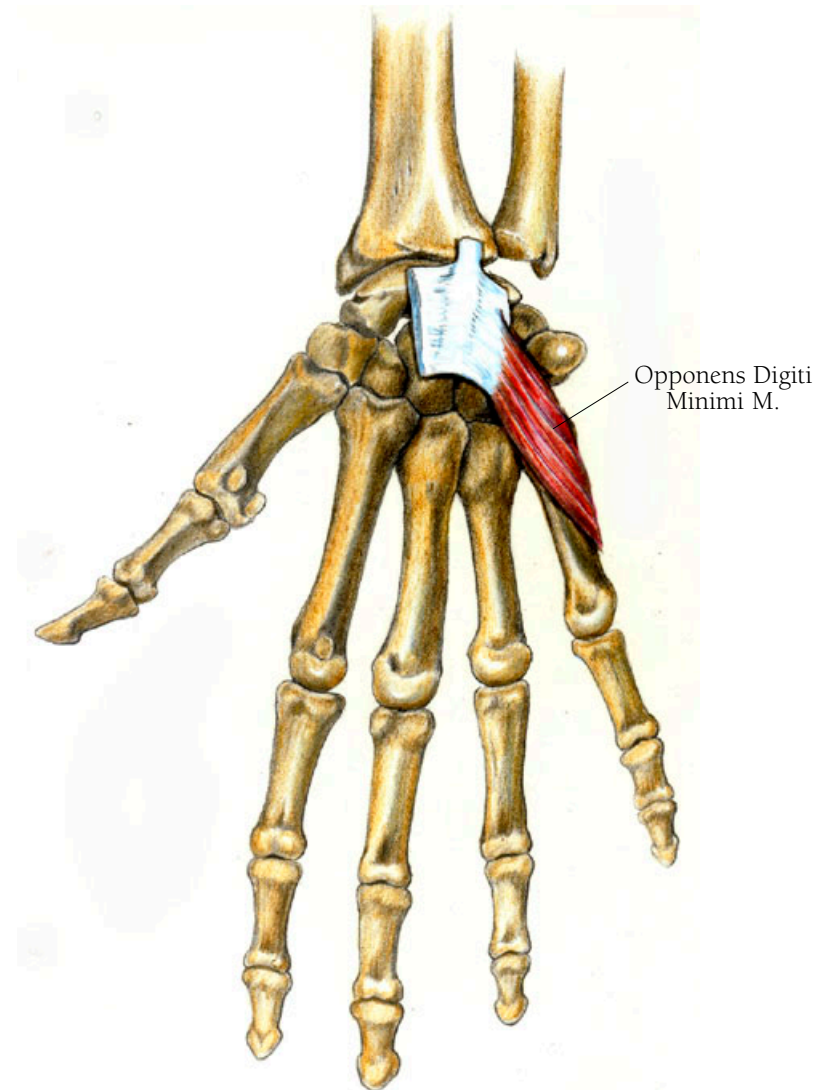
## Arm and Hand Illustration 66

### THE OPPONENS DIGITI MINIMI MUSCLE

The opponens digiti minimi muscle is the partner of the opponens pollicis, causing the little finger to oppose the thumb. Here oppose means to place against, to counter-balance. It arises from the transverse carpal ligament and inserts on the outer border of the fifth metacarpal bone.

• • •

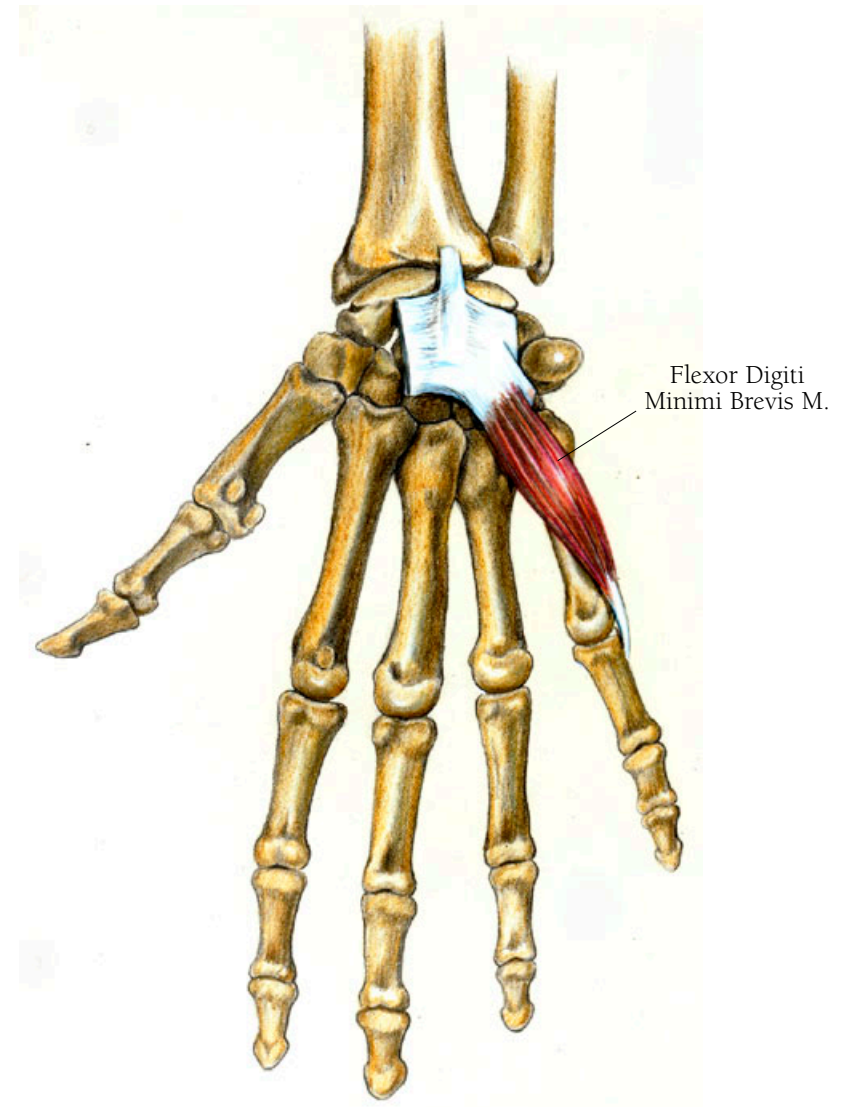
Opponens is from the Latin *ob-* against, *ponere-* to put or thrust: together meaning thrust against or oppose.



## *Arm and Hand Illustration 67*

### THE FLEXOR DIGITI MINIMI BREVIS MUSCLE

The flexor digiti minimi brevis muscle assists the little finger in bending. It arises from the hook of the hamate bone and nearby flexor retinaculum to insert, along with the abductor digiti minimi muscle, at the outer base of the fifth phalanx.



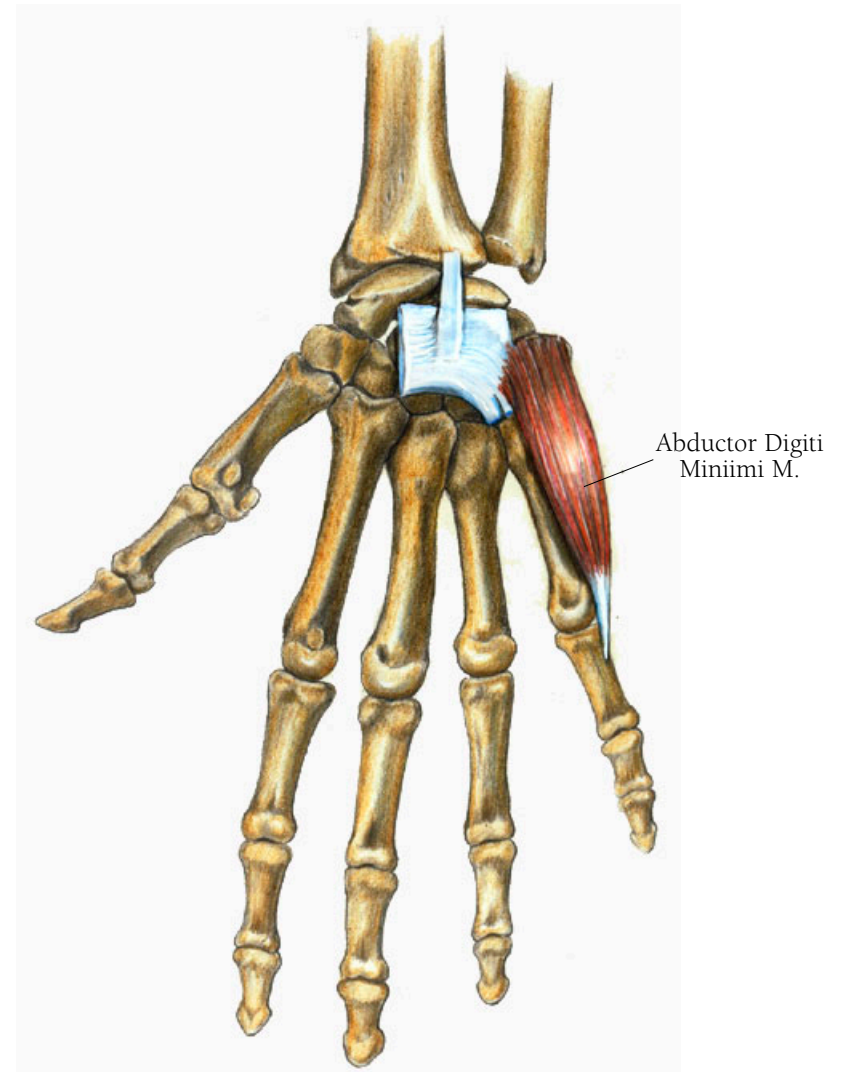
## *Arm and Hand Illustration 68*

### THE ABDUCTOR DIGITI MINIMI MUSCLE

This muscle moves the little finger away from the fourth finger, as when you spread out your fingers. It can also act as a flexor muscle, although sometimes a separate flexor muscle is found. The abductor digiti minimi muscle arises from the carpal bone called the pisiform and then traverses the fifth metacarpal to insert at the base of the first phalanx of the little finger.

• • •

*Pisum* in Latin means pea and *form* means shape.

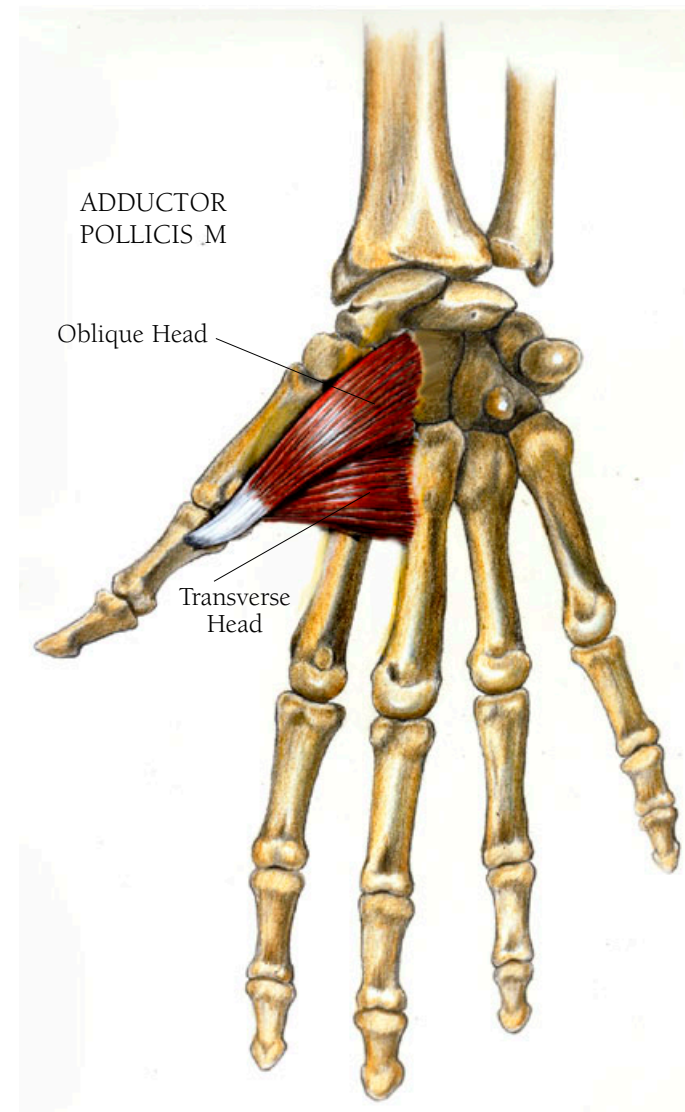


## *Arm and Hand Illustration 69*

### THE ADDUCTOR POLLICIS MUSCLE

This muscle allows you to grasp something. It arises in two heads. The transverse head arises from along the side of the third metacarpal bone, its fibers merging with its neighbors to insert at the base of the innermost phalanx of the thumb. The oblique head arises along the bottom half of the second metacarpal and then from the surfaces of the carpal bones that are just next to the second metacarpal. Its fibers merge to insert on the base of the inner portion of the first phalanx of the thumb.

It has been said that one of the reasons we developed to such a degree as a species can be traced to our opposable thumb and the advantage it gives us in being able to use our hands as a versatile tool. You should be able to understand better our remarkable dexterity after I have described all of the many muscles involved in the movements of the thumb which include muscles of the arm as well as in the hand.



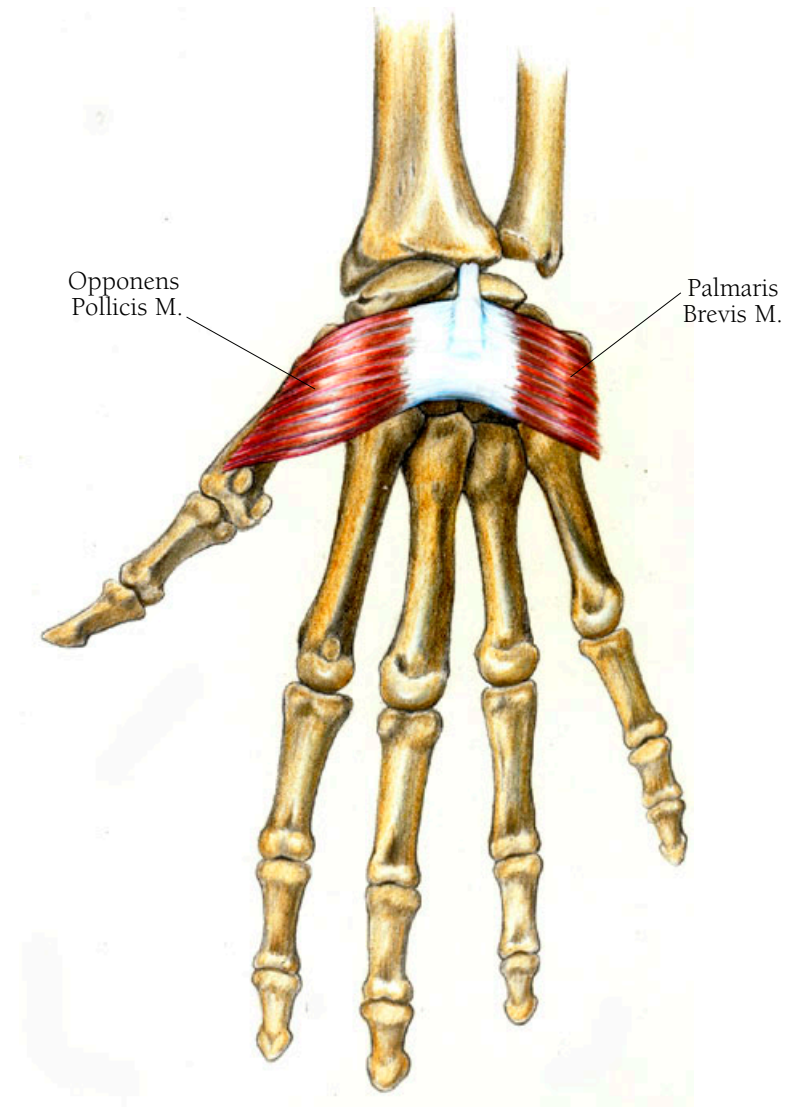
## *Arm and Hand Illustration 70*

### THE OPONENS POLLICIS MUSCLE

The opponens pollicis muscle moves the thumb so it can oppose the other fingers. It arises from the transverse carpal ligament which is also known as the flexor retinaculum, discussed above. Other muscles that arise from it: the flexor pollicis brevis and the opponens pollicis on the thumb side of the palm, and the flexor digiti minimi and the opponens digiti minimi on the outside of the hand, towards the little finger. The opponens pollicis muscle inserts along the outer border of the first metacarpal, the bone located in the palm at the base of the thumb.

### THE PALMARIS BREVIS MUSCLE

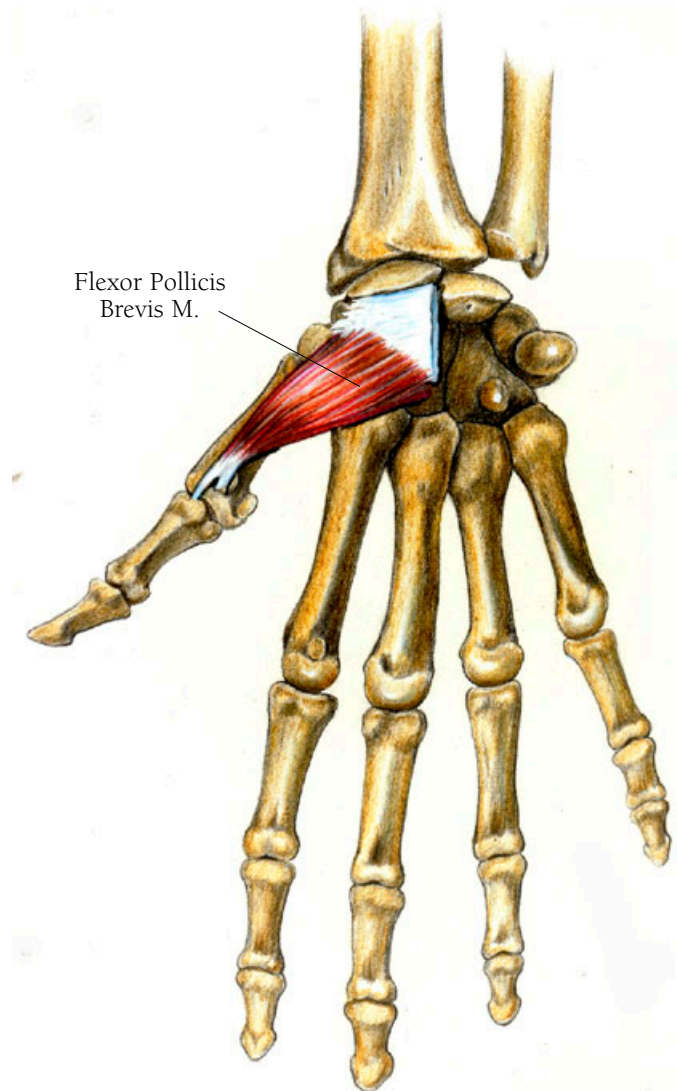
This muscle keeps the underlying muscles in place and pulls the skin toward the center of the palm when you make a fist. It arises from the flexor retinaculum, covers the opponens and abductor digiti minimi muscles, and inserts in the skin at the outer border of the palm.



## *Arm and Hand Illustration 7I*

### THE FLEXOR POLLICIS BREVIS MUSCLE

The flexor pollicis brevis muscle allows the thumb to move over the palm of the hand. It arises in two sections; the first begins under and slightly to the inside of the superficial part which arises from the flexor retinaculum; the second originates as small deep muscle fibers from the carpal bones just at the base of the fifth metacarpal bone. Both sections unite to insert at the base of the first phalanx.

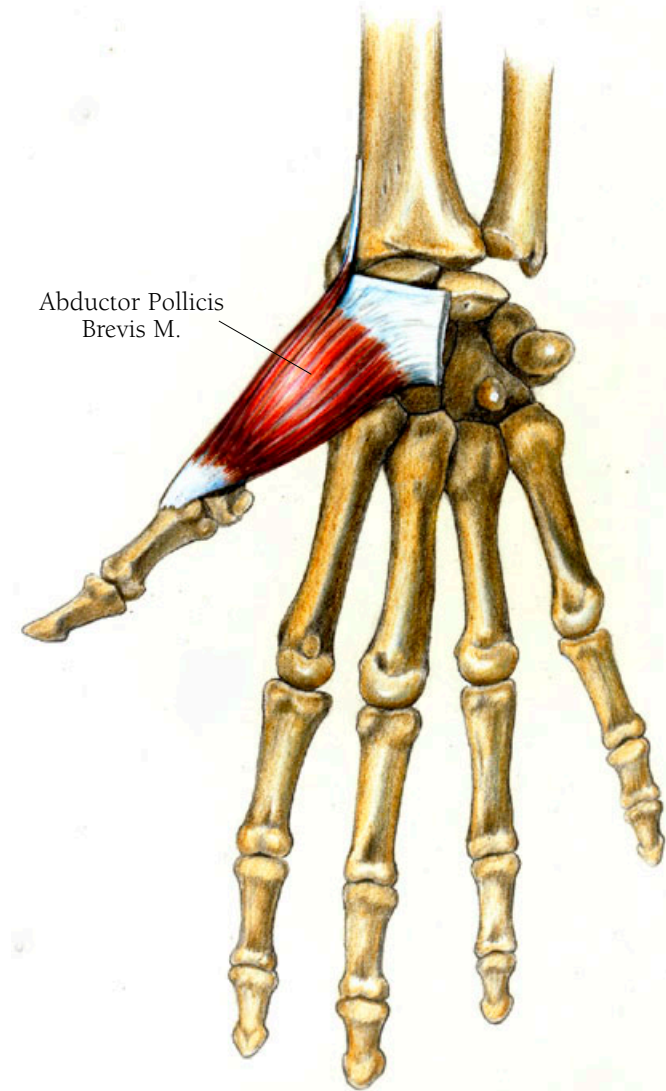




## *Arm and Hand Illustration 72*

### THE ABDUCTOR POLLICIS BREVIS MUSCLE

The abductor pollicis brevis muscle, the last of the seven thumb muscles, moves the thumb perpendicular to the palm of the hand. Arising on the flexor retinaculum it lies just over and adjacent to the flexor pollicis brevis muscle and inserts on the base of the first phalanx of the thumb.

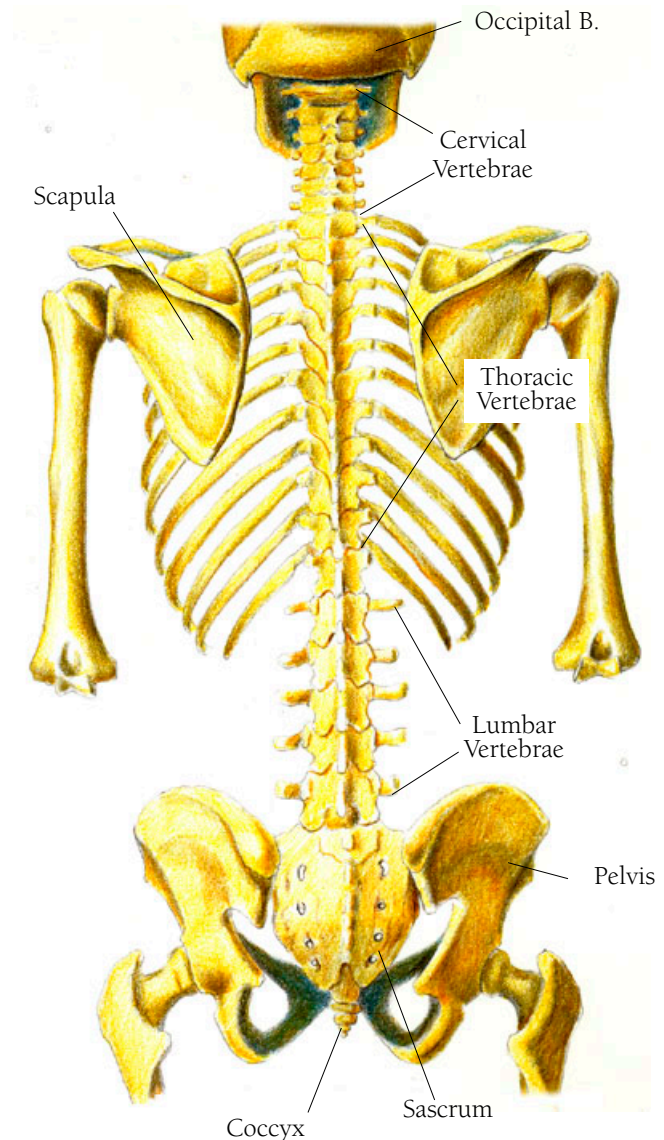


## Back and Thorax Illustration 73

### THE BONES OF THE BACK

The major bones of the back are the 24 vertebrae which make up the vertebral column. They are stacked one on top of the other, and become increasingly large as they descend, carrying more and more of the body weight. Seen from the side they make a gentle double S shape from top to bottom that ends with the sacrum, where a tail would hang if we still had one. The curves correspond to the different sections of the spinal column. The first curve corresponds to the neck and it is made up of seven cervical vertebrae. The top two vertebrae have their own names. The first which holds up the skull, is called the atlas (after the Greek god of that name who holds the heavens on his shoulders). The second, which assists in turning the head, is called the axis. The next twelve, completing the first S curve, are called the thoracic vertebrae and are the ones to which the ribs are attached. The last five, forming an opposing curve to the thoracic vertebrae, are the lumbar vertebrae. The sacrum completes the second S curve. It is formed as a fusion of the final five vertebrae.

The other bones involved with the musculature of the back are: the occipital bone of the skull; the scapulae; the ribs; and the pelvis.



• • •

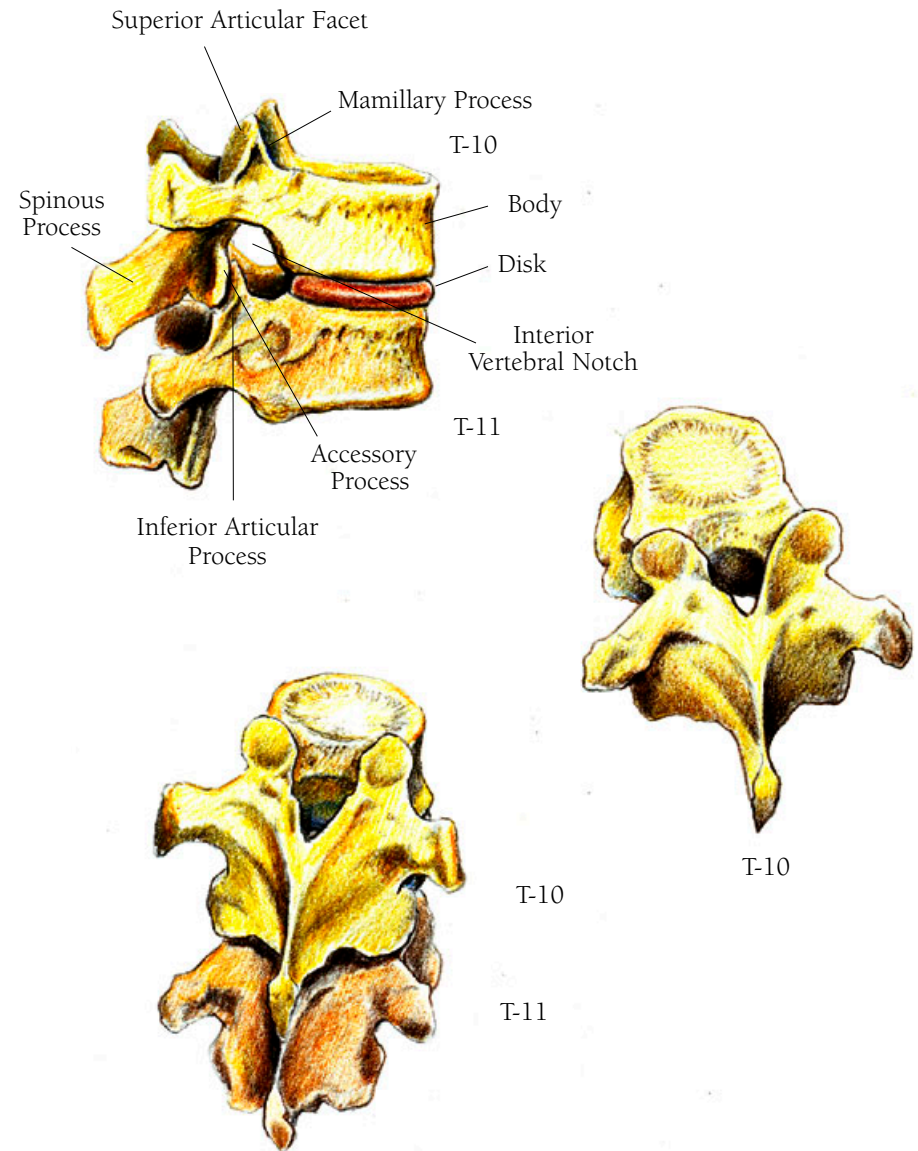
Vertebra is from the Latin *vertere*, to turn. Axis comes from the Greek *axon*, meaning axle. Cervical is from the Latin word *cervix*, meaning neck. *Thorax* is Greek for breast.

Lumbar is from the Latin word *lumbus*, meaning loin—lumbar meaning “of the loins.” *Sacrum* comes from the Latin word for “the sacred bone.”

## Back and Thorax Illustration 74

### THREE VIEWS OF THE TENTH AND ELEVENTH THORACIC VERTEBRAE

Because they have numerous jobs to perform these bones are enormously complex. They provide the structure for holding us erect. They also protect the spinal cord and allow for its branches to pass out through openings created by the neat fitting of one vertebra below the other in such a manner that the spinal cord and its fluid are contained and protected. The nerve branches emerge from between each pair of vertebrae to travel to all parts of the body. The body of each vertebra is drum shaped and cushioned by a disc of a softer, cartilaginous material that allows each vertebra to move over the other. On the sides of the body are facets—little dish-like formations—where the ribs attach. In the upper thoracic vertebrae these facets are shared—a demi facet in the one above and a demi facet in the one beneath. In the lower vertebrae, these facets are complete on each vertebra. On the back side of the vertebrae are various projections. The inferior articular surface of the upper vertebra articulates with the superior articular surface of the one below. There are two transverse processes, one on each side, like wings, which serve as muscle attachments and also provide a second articular surface for the rib as it begins arching out and around the body's



upper organs. On each vertebra, in the middle, between these processes, is a spinous process. In the cervical vertebrae these processes point obliquely downward. In the upper thoracic vertebrae they point outward but as the vertebrae descend, they point increasingly downward again. In the lumbar region they again point outward. When you look at the spine from the rear, with all vertebrae lined up, the transverse processes seem to form a gutter on each side of the spinous process. They are filled with very small muscles that zigzag back and forth, connecting one vertebra with the next or even with one several vertebrae away. These muscles not only serve to function in the way we move our torso; they also cushion and smooth over the projections of the vertebrae.

## Back and Thorax Illustration 75

### THE SPLENIUS CAPITIS MUSCLE

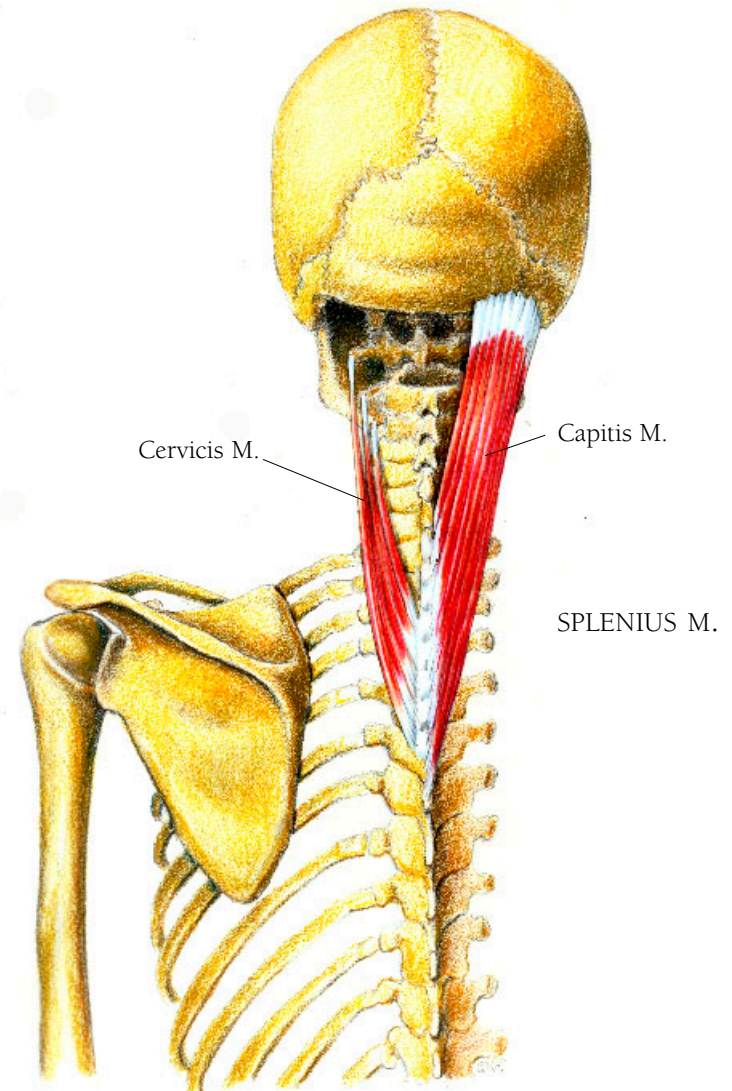
This muscle and the one next to it, the splenius cervicis, also assist in holding the head erect and in turning the head and neck to the side. It arises from the spinous processes of the top three or four thoracic vertebrae and the spinous process of the seventh, or bottom, cervical vertebra. It also arises from a ligament which attaches to the nuchal area at the mid-base of the occipital bone and descends to the end of the cervical spine. It then courses upwards and slightly laterally to insert in two places—as a tendon along the rough bone just below the superior nuchal line, and on the mastoid process.

• • •

Splenius is from the Greek word *splenion*, meaning bandage.

### THE SPLENIUS CERVICIS MUSCLE

This muscle arises from the spinous processes of the third, fourth, fifth and sixth thoracic vertebrae. As it rises it becomes three or four separate fiber bundles that insert tendinous fibers on the transverse processes of the upper three or four cervical vertebrae.



## Back and Thorax Illustration 76

### THE TRANSVERSOSPINALES MUSCLES

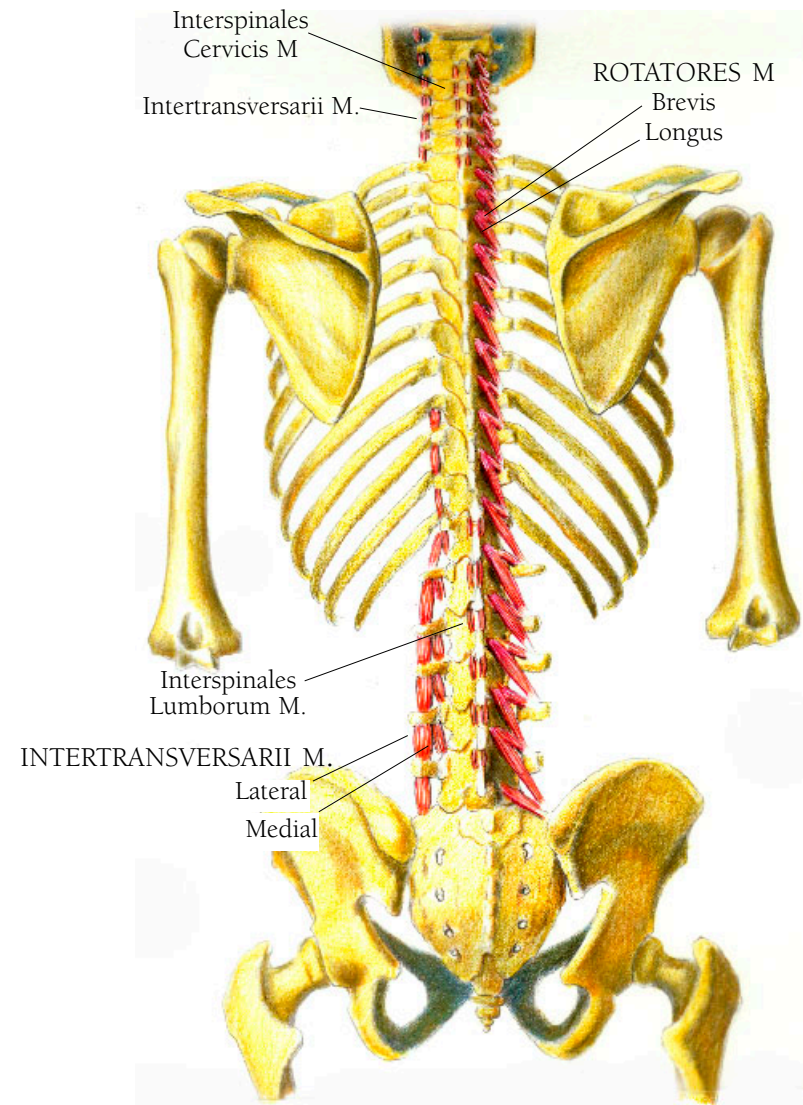
The transversospinalis group of muscles arise and insert on the vertebrae. They keep us erect, and allow our backs to twist and turn.

• • •

Transverse is from the Latin verb *transversieri*, “to turn across, cross over.”

### THE ROTATORES BREVIS AND THE ROTATORES LONGUS MUSCLES

Of the transversospinales group the deepest are the rotatores brevis and the rotatores longus muscles, very small muscles that assist in turning the spine, filling in the groove formed by the spinous processes and the transverse processes of the vertebrae. They form a zigzag pattern all the way from the sacrum to the axis. The brevis muscle arises from the transverse process of one vertebra and inserts at the base of the spinous process of the vertebra above it. The longus muscle arises also on the transverse process of one vertebra but skips a vertebra to insert on the spinous process of the second above it, giving it an oblique direction.



TRANSVERSOSPINALES MUSCLES

## THE INTERTRANSVERSARIII MUSCLES

The intertransversarii muscles bend the spine to the side, at the levels of the neck and the waist. At the level of the neck they are located between the transverse processes of the cervical vertebrae where they consist of a posterior and anterior set. At the level of the waist they appear between the transverse processes of the last three thoracic vertebrae and the first lumbar vertebra where they consist of a lateral and medial set.

## THE INTERSPINALES MUSCLES

The interspinales muscles give support in keeping the spine extended—straightened out. They lie between the spinous processes of all the cervical vertebrae except the atlas, down to and including the top two thoracic vertebrae. They then show up again on the bottom thoracic vertebra and between the five lumbar vertebrae.

• • •

The base of rotatores, *rota*, means wheel in Latin.



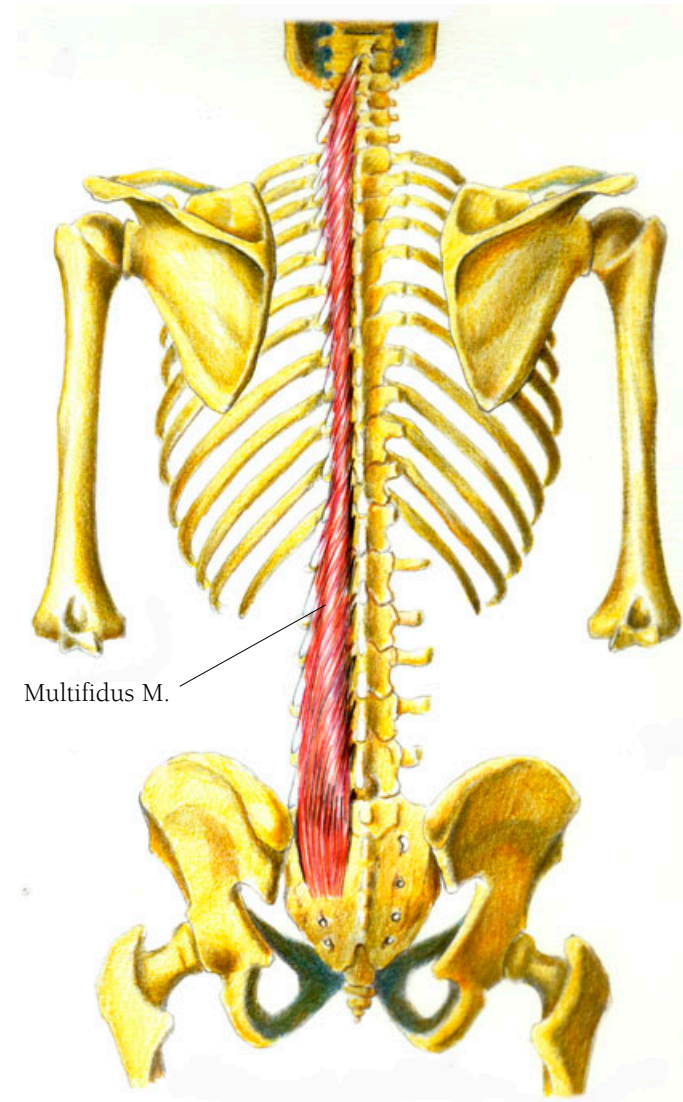
## Back and Thorax Illustration 77

### THE MULTIFIDUS MUSCLE

Forming the next layer of deep muscles is the multifidus muscle which extends and rotates the back. Because it comes in separate bundles, this muscle looks like many small muscles. It covers the deep layer of muscles I have just discussed and helps to fill up the grooves on each side of the bony vertebrae. It arises from the top of the sacrum, from the inner surface of the iliac spine of the pelvis, from the mammillary processes of the lumbar vertebrae, from the transverse processes of the thoracic vertebrae, and from the articular processes of the bottom four cervical vertebrae. Its fibers course upward crossing five vertebrae to insert on the spinous process of the fifth vertebra from where it started. This pattern of attachment applies from the fourth lumbar vertebra to the axis. Deeper fibers of this muscle cross fewer vertebrae.

• • •

Multifidus is from the Latin *multus* meaning many and *findere* meaning to cleave; thus it means “many cleavings” or “divided into many parts.”



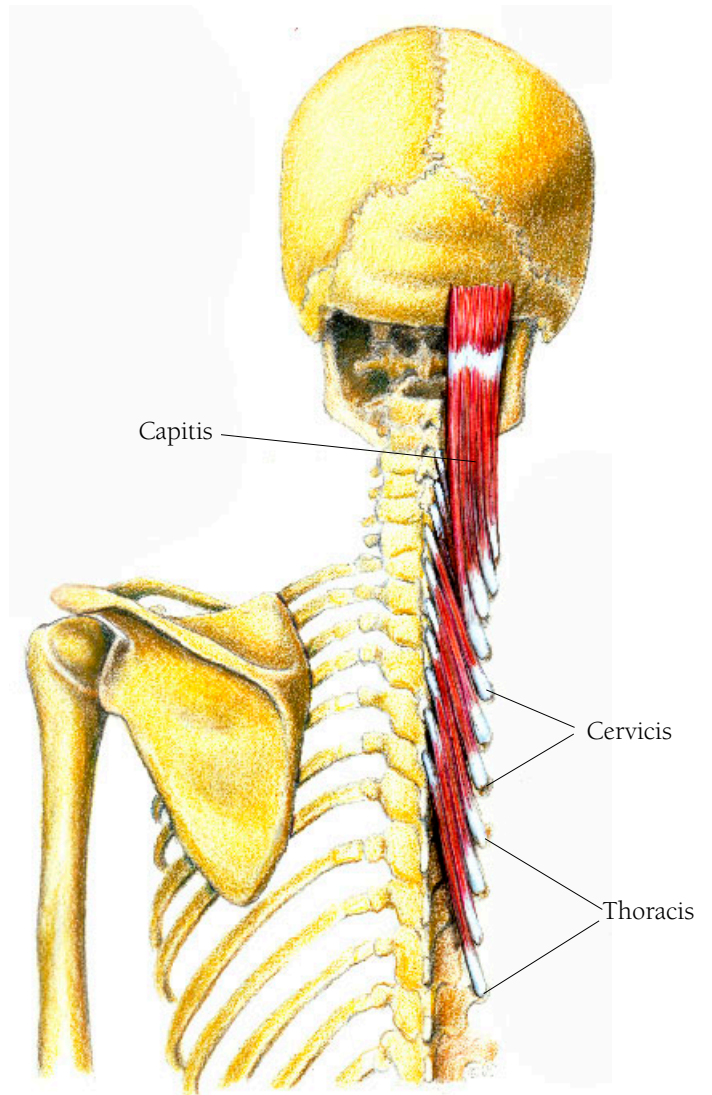
## Back and Thorax Illustration 78

### THE SEMISPINALES MUSCLES; CAPITIS, CERVICIS AND THORACIS

Running next to and over the multifidus muscle are the cervical and thoracic semispinales muscles. The capitis section is just above. The semispinales muscles assist in extending and rotating the spinal column. The capitis muscle assists in holding the head erect and in turning it. It arises from the transverse processes of the top six thoracic vertebrae and inserts in between the superior and inferior nuchal lines of the skull's occipital bone. It is divided into two sections by intersecting tendinous fibers near the axis. The thoracic fibers arise as tendons from the transverse processes of the eleventh or tenth to the sixth thoracic vertebrae and insert on the spinous processes of the top four thoracic vertebrae. The cervical fibers arise similarly from the transverse processes of the top five or six thoracic vertebrae and insert on the spinous processes of the fifth to the axis or second cervical vertebrae.

• • •

*Semi* is Latin, from the Greek *hemi*, meaning half or partly. *Spinales* is from the Latin *spinalis* meaning “of the spinal cord.” Unlike the Multifidus that covers the whole length of it, these muscles cover roughly half or part of the spinal column.



SEMISPINALES MUSCLES

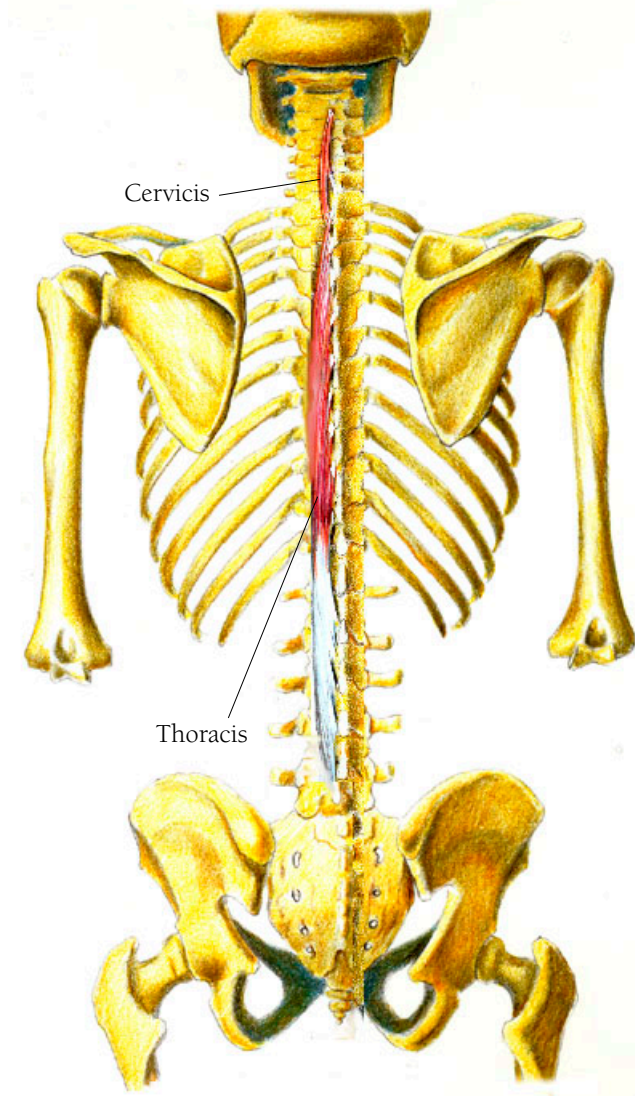
## Back and Thorax Illustration 79

### THE SPINALES MUSCLES

The spinales muscles have three parts—the capitis, the cervicis and the thoracis. The spinalis cervicis arises from the spinous processes of the top two thoracic vertebrae and the seventh cervical vertebrae to insert on the spinous process of the axis. The spinalis thoracis arises from the inner portion of the tendinous mass of the erector spinae and from the sacrum as well as from the spinous processes of the top two lumbar and bottom two thoracic vertebrae. It inserts into most or all of the spinous processes of the upper thoracic vertebrae. In dissection this muscle is hard to separate from the semispinales muscle which lies beneath it, especially the capitis portion, which blends with the semispinales capitis muscle.

• • •

*Dorsi* is Latin for “of the back.”

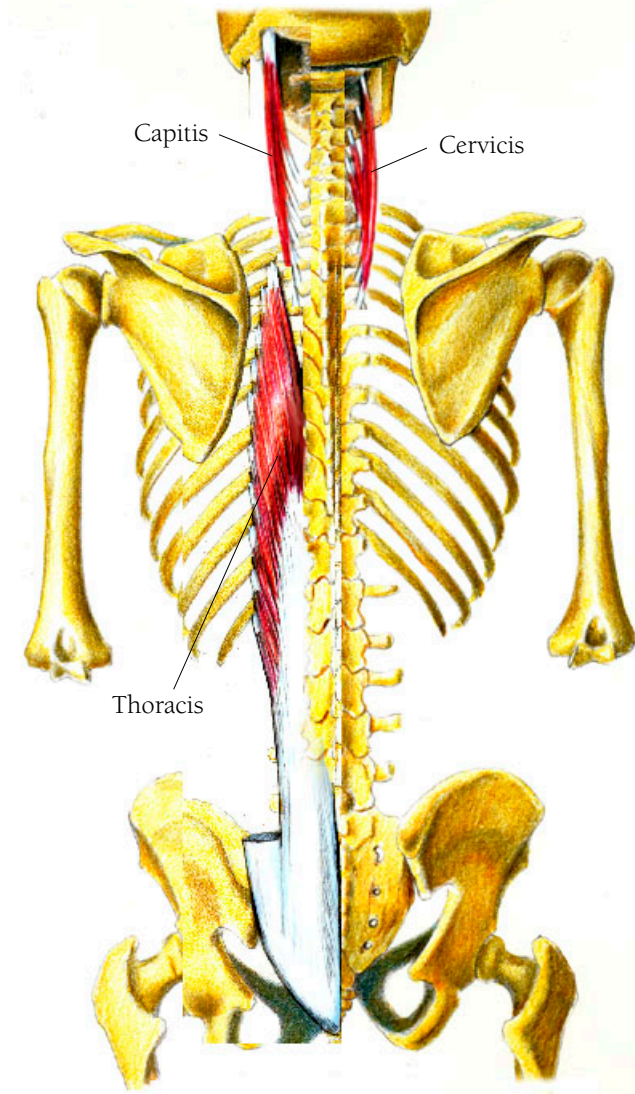


SPINALES MUSCLES

## Back and Thorax Illustration 80

### THE LONGISSIMUS DORSI MUSCLES

The longissimus dorsi muscle has three distinct parts, the capitis, the cervicis and the thoracis. The capitis muscle assists in holding the head erect as well as in rotating it toward the same side as the muscle which is contracting. It arises from the transverse processes of the top four thoracic vertebrae and courses upwards to insert on the mastoid process of the skull. The cervicis muscle assists in bending the top of the neck and helps in keeping the cervical spine erect. It arises as narrow tendons from the transverse processes of the top four thoracic vertebrae and rises upwards just lateral to the longissimus capitis muscle to insert on all of the transverse processes of the axis as far as the sixth cervical vertebra. The thoracis portion assists in backward and sideward bending. It also assists in keeping the spine erect as well as pulling the ribs downward, thus helping with breathing. The thoracic muscle arises from the tendinous mass covering the sacrum and lies lateral to the spinales dorsi. It courses upward inserting in two areas—medially it attaches to the transverse processes of the vertebrae, and laterally it attaches to the lower nine or ten ribs, just where they begin to curve away from the spine.



LONGISSIMUS DORSI MUSCLES

Longissimus dorsi means “longest of the back.” The longissimus goes from the sacrum to the base of the skull.

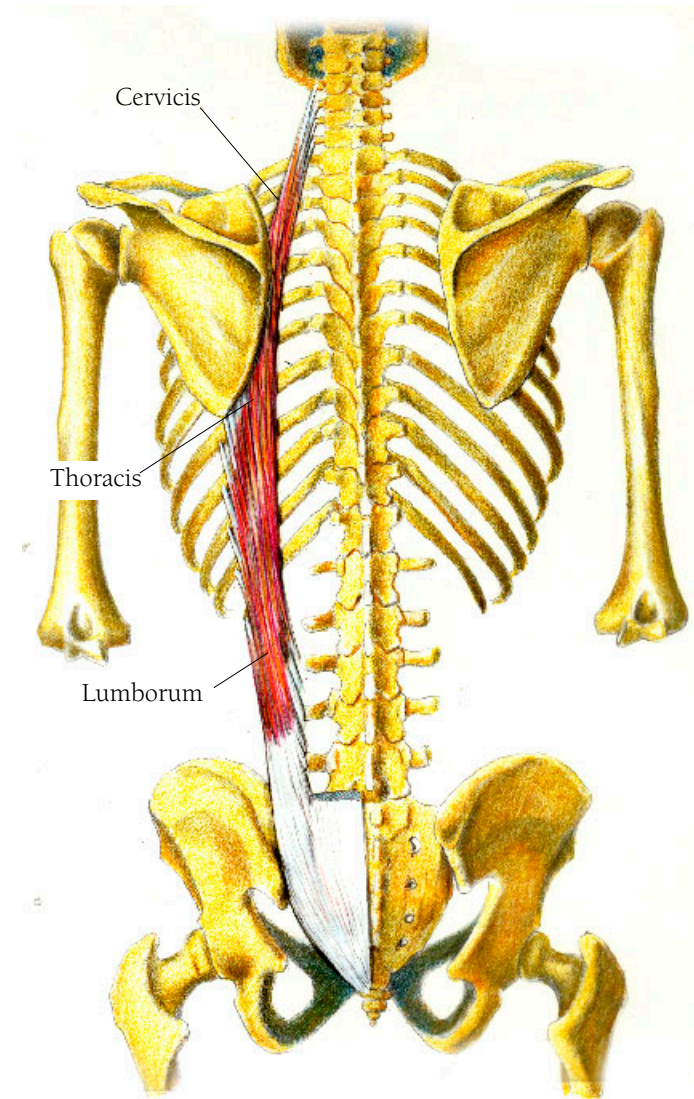
• • •

-Issimus on the end of a Latin word is equivalent to our -est ending of an adjective, meaning the most.

## Back and Thorax Illustration 8I

### THE ILIOCOSTALIS MUSCLES

The most lateral of this layer of muscles is called the iliocostalis muscle which assists in extending the back and bending sideward. It arises from the tendinous mass covering the sacrum just lateral to the spinalis dorsi and the longissimus dorsi, but is not contingent with those two, being somewhat separated from them. It has three parts. The first, the lumborum, arises from the fascia that covers the sacrum, and inserts onto the lower or inferior borders of the lower six or seven ribs. The second part, the thoracis, has fibers that arise from the upper borders of the lower six ribs just medial to where the lumbar fibers insert, and it inserts on the upper borders of the top six ribs and onto the transverse process of the lowest cervical vertebrae. The third part, the cervicis, has fibers which arise from the third through sixth ribs and insert onto the transverse processes of the fourth through sixth cervical vertebrae.



ILIOCOSTALIS MUSCLES

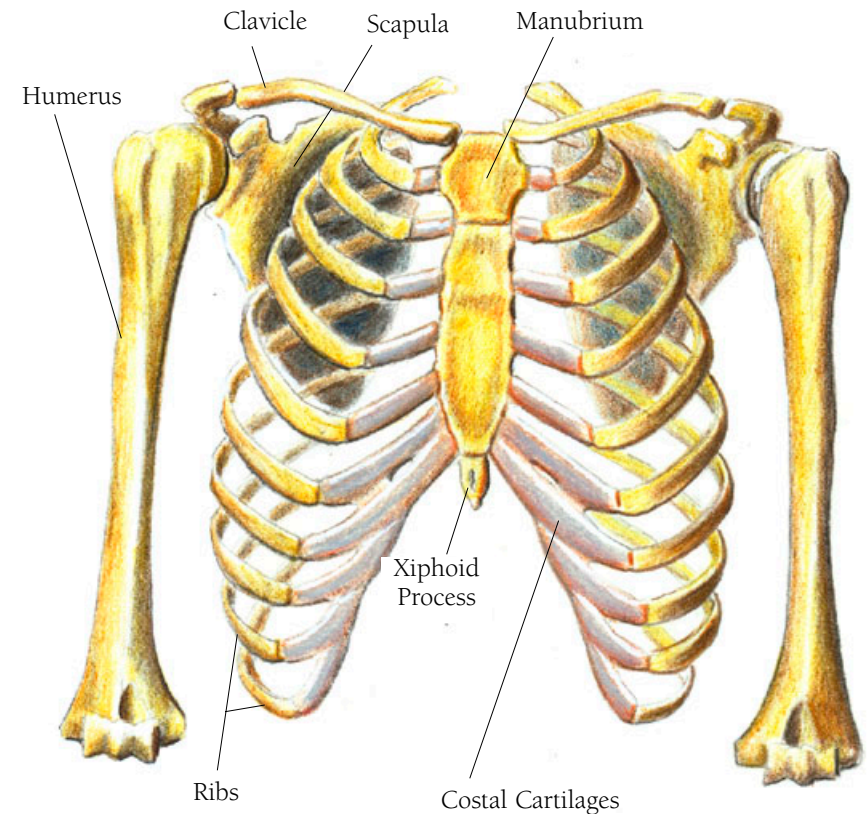
## Back and Thorax Illustration 82

### THE THORAX OR RIB CAGE

This illustration is a frontal view the rib cage with the bones of the shoulder girdle: the clavicle, the scapula, and the humerus. There are twelve ribs, ten of which are attached posteriorly to the spinal column and anteriorly to the sternum (one of the unpaired bones). The ribs do not directly attach to the sternum. Instead there are cartilaginous struts called the costal cartilages that attach to the sternum and to the ribs. Some struts are separate from each other while the lower ones are fused in varying patterns only one of which is shown here. Ribs 11 and 12 are the “floating,” attached to the spinal column but not to the sternum. Their muscle attachments keep them in place. The top of the sternum is called the manubrium and looks like a separate bone hinged or joined to the body of the sternum. At the bottom is the xiphoid process. The ribs embrace and contain some of our vital organs—the heart, the lungs and the esophagus—and form a protective structure for them. Assisted by the action of the diaphragm many of these muscles are involved with breathing.

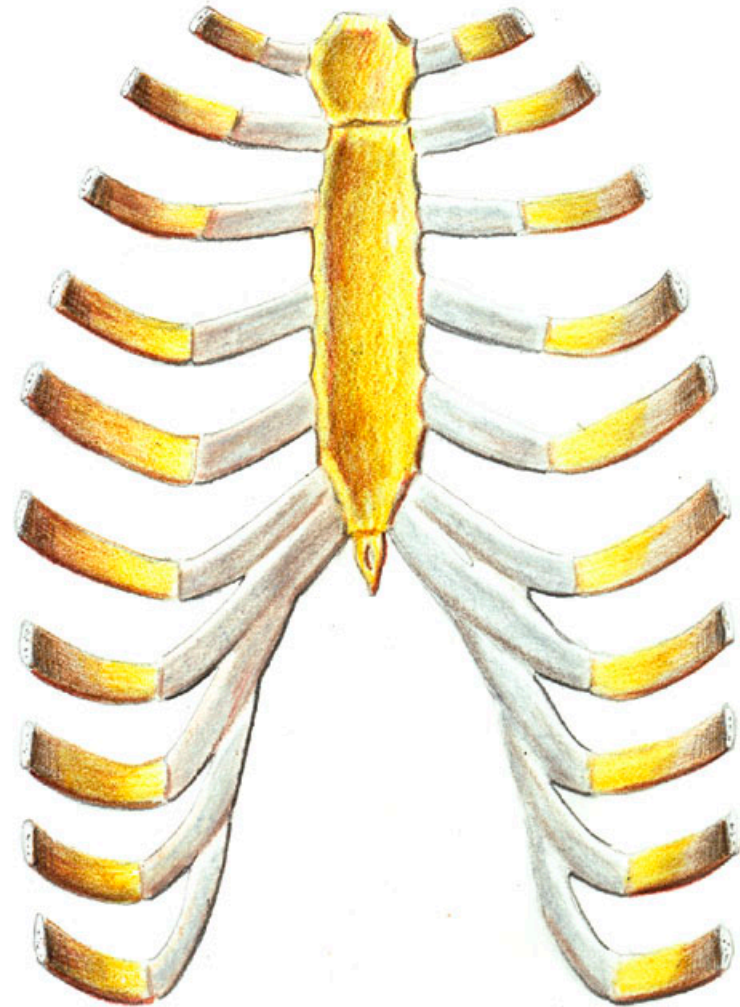
• • •

*Thorax* is Greek meaning chest or breastplate. *Sternum* is Latin and comes from the Greek word *sternon*, meaning breastbone. *Manubrium* is Latin for handle or haft.



## *Back and Thorax Illustration 83*

THE STERNUM, THE COSTAL CARTILAGES AND  
PART OF TEN RIBS, VENTRAL VIEW

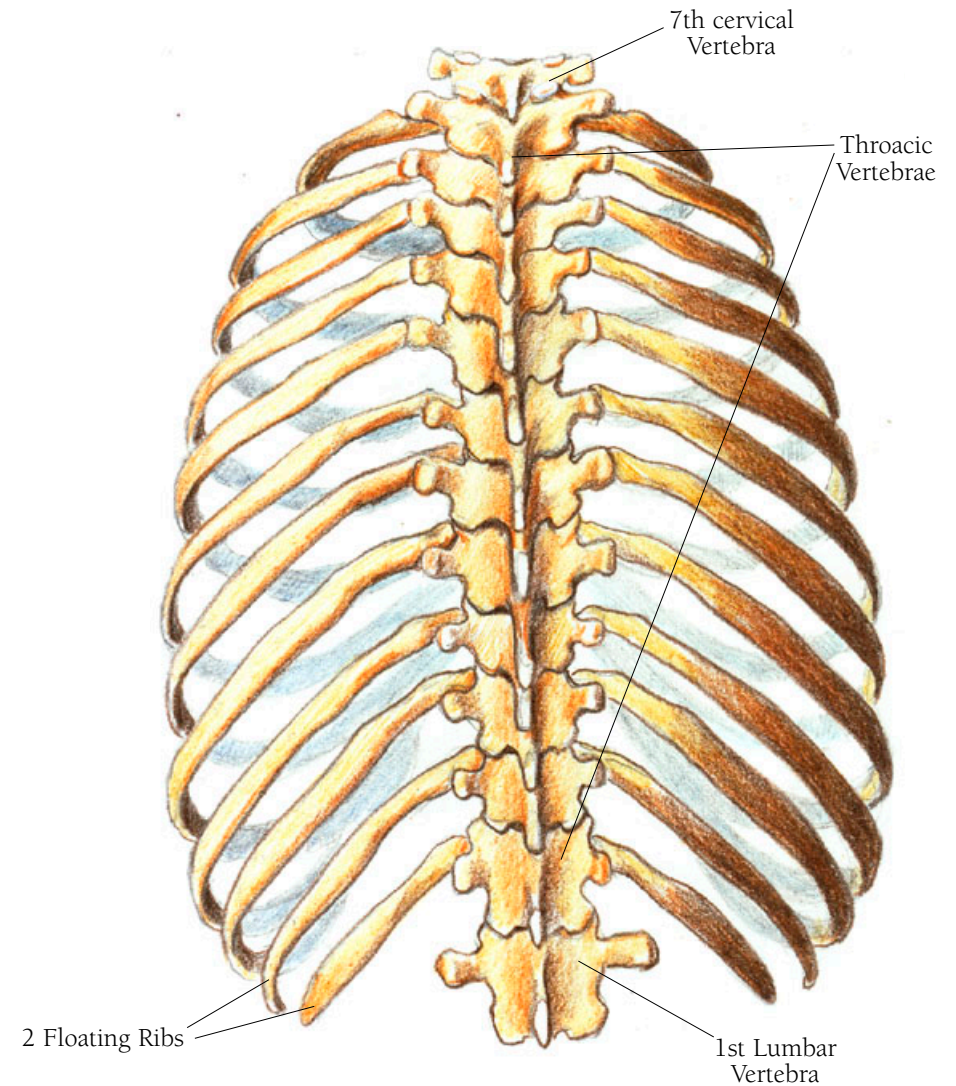




## Back and Thorax Illustration 84

THE RIBCAGE WITH THE SPINAL COLUMN, SHOWING THE SEVENTH CERVICAL VERTEBRA, THE TWELVE THORACIC VERTEBRAE, AND THE FIRST LUMBAR VERTEBRA, A POSTERIOR VIEW

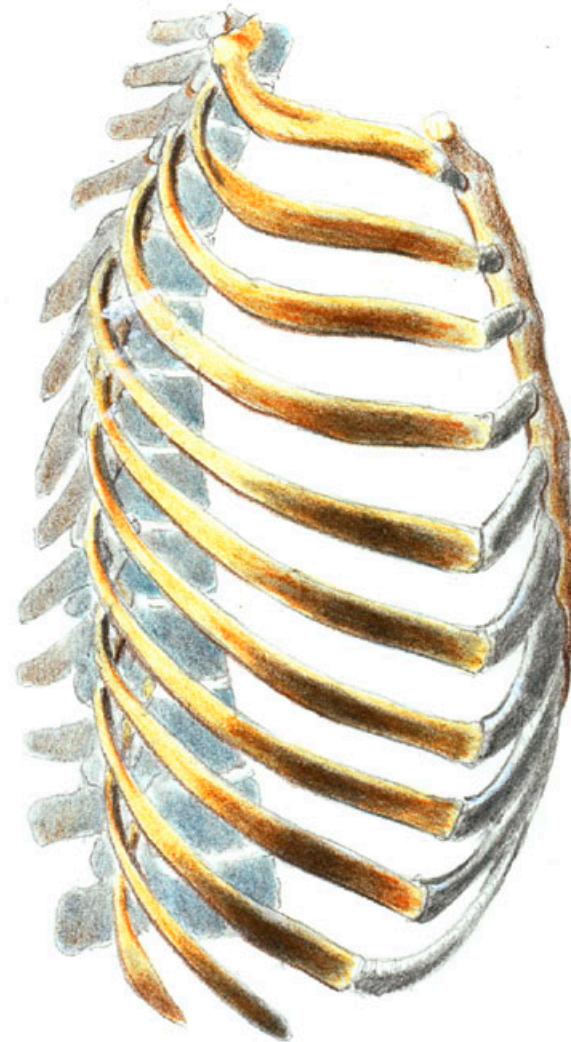
This view allows you to see the two floating ribs.



## *Back and Thorax Illustration 85*

THE RIB CAGE OR THORAX WITH THE TWELVE THORACIC VERTEBRAE, LEFT LATERAL VIEW

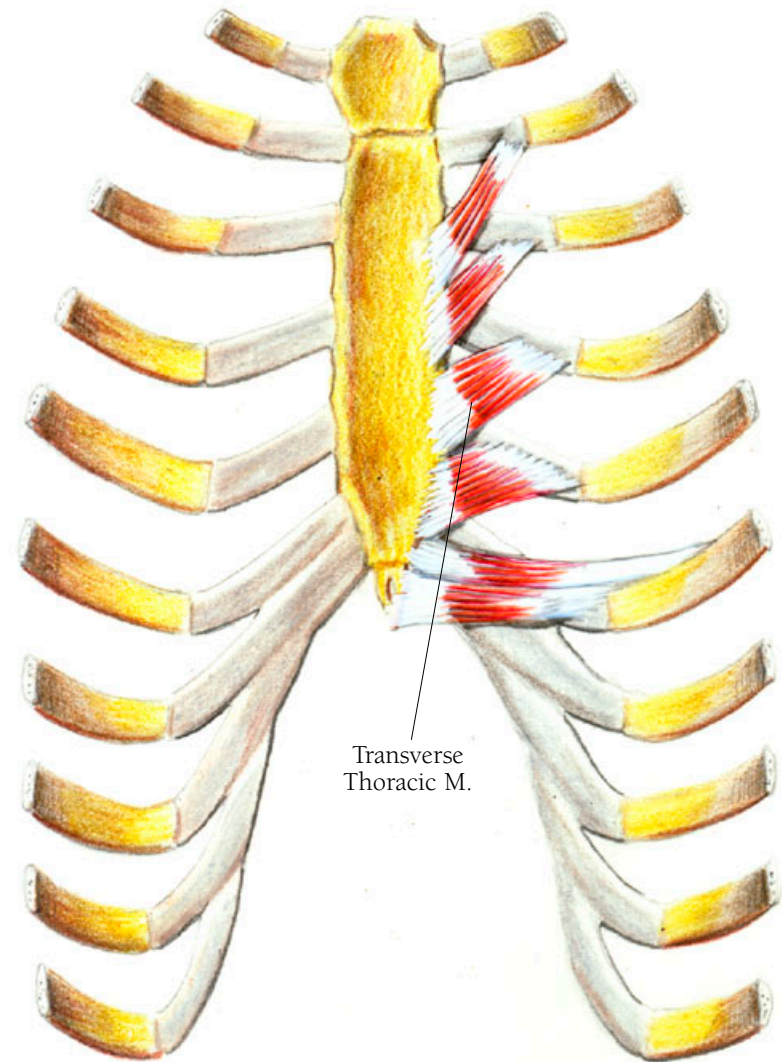
You can see the curve of the spinal column as well as the varying directions of the vertebrae's spinous processes.



## *Back and Thorax Illustration 86*

### THE TRANSVERSE THORACIC MUSCLE

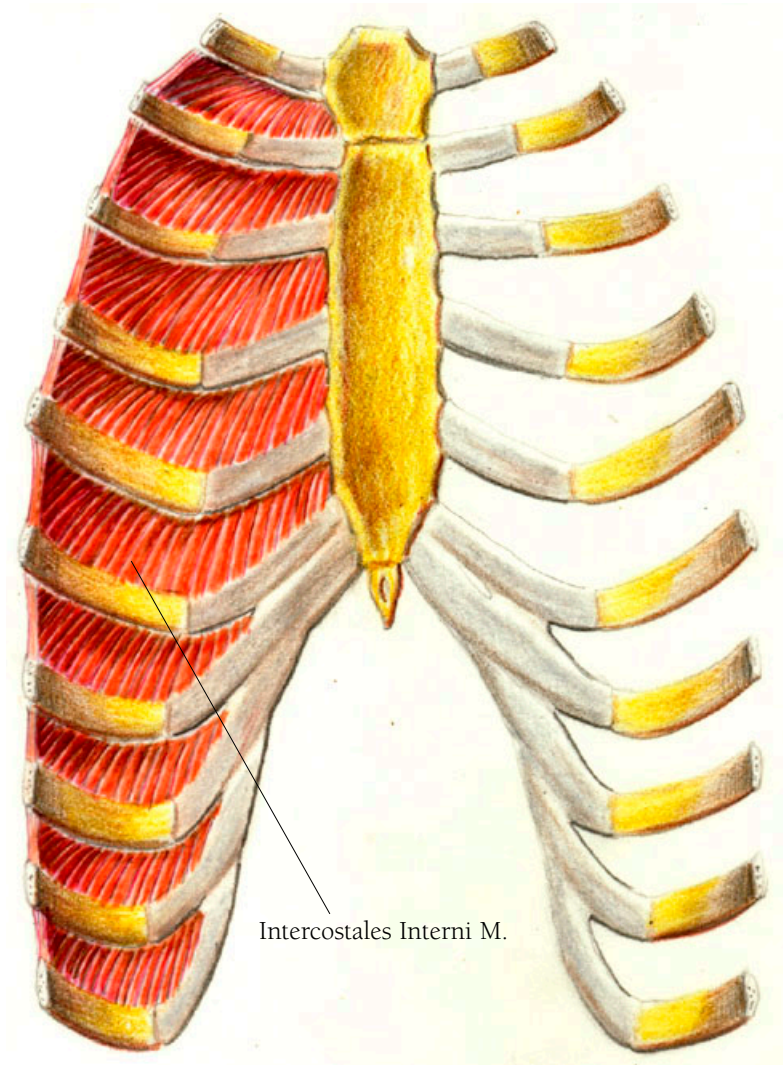
This muscle is a series of small muscles that assist in drawing the ribs downward, decreasing the size of the lungs and helping to express air or breath out. They arise on the inner surface of the sternum and on the xiphoid process to insert on the costal cartilages. There are about five of them and they insert in an almost horizontal direction on the sixth costal cartilage, with the angle of their directions becoming more vertical as they attach to each of the higher costal cartilages.



## Back and Thorax Illustration 87

### THE INTERCOSTALES INTERNI MUSCLES

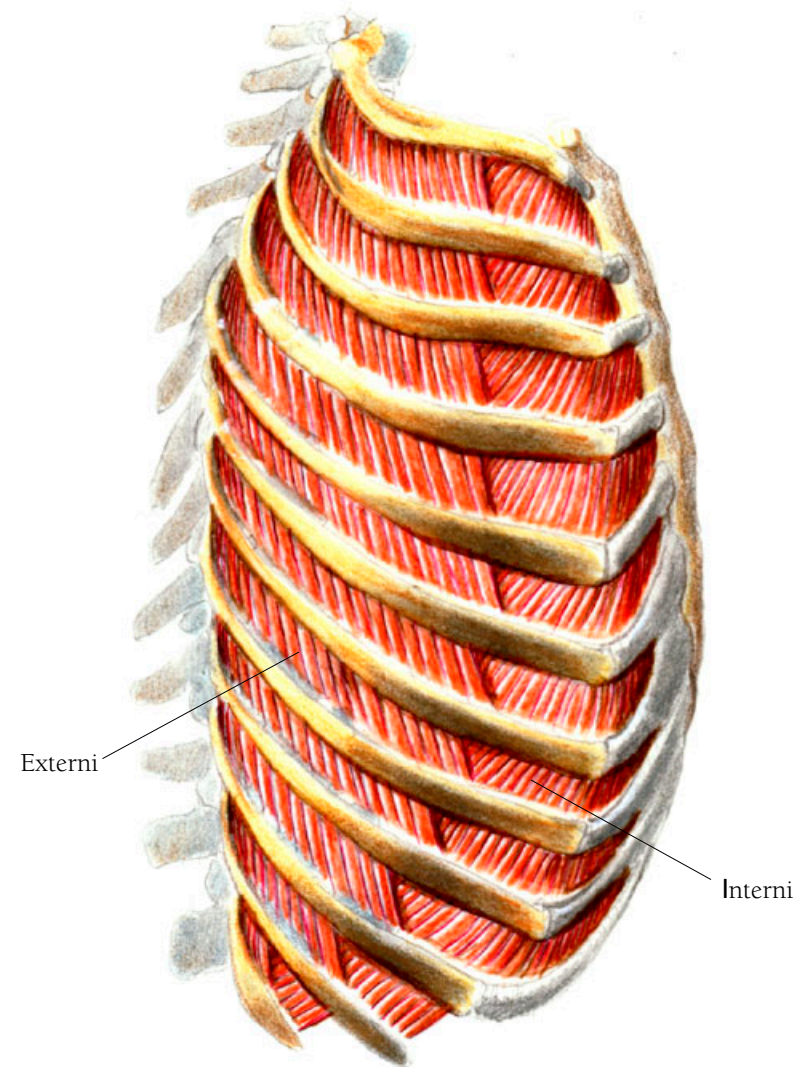
There are two layers of intercostal muscles and the view here shows the innermost layer, the intercostales interni muscles. These muscles draw the ribs together compressing the chest and lungs to expel air in the breathing out part of respiration. There are eleven on each side positioned between each of the twelve ribs. While their direction is almost vertical at the sternal end, they run more and more obliquely as they travel around the bend of the ribs. Running perpendicular to the intercostales externi muscles they arise from the lower inner surface of each rib as well as from the costal cartilage to insert on the upper surface of the rib below.



## Back and Thorax Illustration 88

### THE INTERCOSTALES EXTERNI MUSCLES

The eleven paired intercostales externi muscles lie right on top of and perpendicular to the intercostales interni muscles and are a bit thicker. Along with the action of the scalenus muscle which attaches to the first rib, they act to lift the rib cage, expanding it in the breathing-in part of respiration. They arise on the lower border of each rib and insert on the upper border of the rib below.



INTERCOSTALES MUSCLES

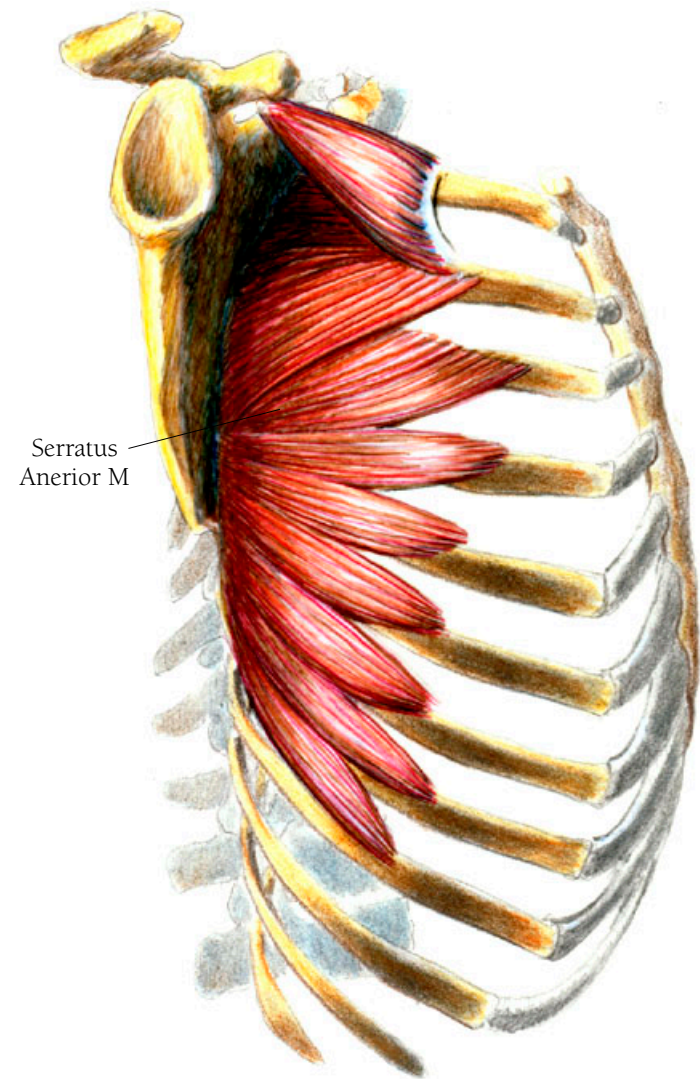
## Back and Thorax Illustration 89

### THE SERRATUS ANTERIOR MUSCLE

Even though this is called the serratus anterior muscle, it appears on the side of the chest wall. It rotates the scapula, allowing for a full range of arm movement. It arises from the outer surface and upper border of the first nine ribs and it courses around the rib cage in the form of about nine different bundles to join in a sheath of muscle which inserts all along the inner border of the scapula, from its upper to lower tip. The next two muscles described below are also serratus muscles, this time appearing posteriorly. Both get their names from their saw-tooth-like appearance which is enhanced in the anterior muscles as they interdigitate with the abdominal muscles.

• • •

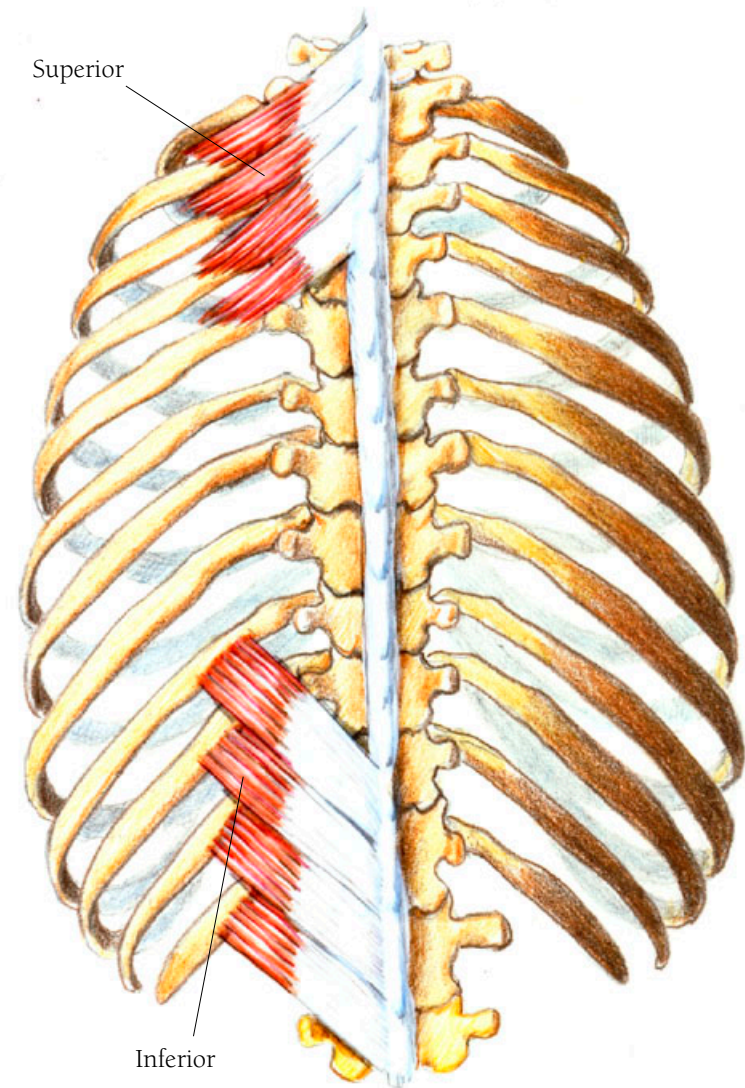
*Serratus* is Latin for “notched, toothed or saw-like.”



## Back and Thorax Illustration 90

### THE SERRATUS POSTERIOR MUSCLES, SUPERIOR AND INFERIOR

There are two pairs of serratus posterior muscles, one superior and the other inferior. The superior serratus posterior muscles lift the ribs, increasing the chest cavity to enhance inspiration (breathing in). The superior serratus posterior muscle arises from the spinous processes of the last or seventh cervical vertebra and the first three thoracic vertebrae as four separate muscles which lie next to each other. Each one arises as an aponeurosis or tendinous sheath-like tissue from the ligamentum nuchae, the ligament that comes down from the base of the skull to cover the spinous processes of the cervical vertebrae. The muscle groups course obliquely outward and downward as flat muscles to insert along the upper borders of the second to the fifth ribs. The lower muscle is quite separate from the upper one by about three ribs' distance. It pulls the ribs outward and downward. It arises from the spinous processes of the last two thoracic vertebrae and the first two lumbar vertebrae as four separate muscles lying next to each other. Like the superior muscle, they arise as an aponeurosis and about half way in their upward and outward path they become flat muscles that insert on the lower borders of the ninth to the twelfth ribs.

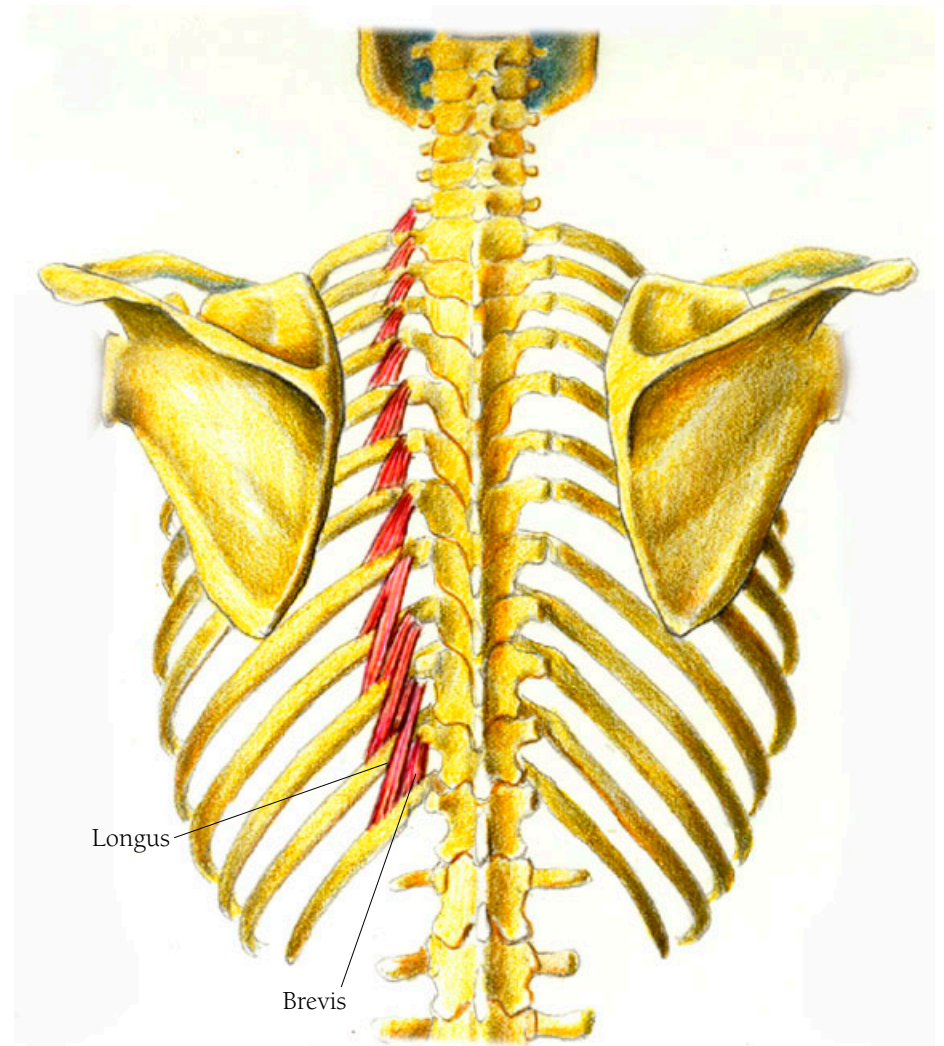


SERRATUS POSTERIOR MUSCLES

## Back and Thorax Illustration 9I

### THE LEVATORES COSTORUM MUSCLES

The levatores costorum muscles are deeper than the posterior serratus muscles. They lie just beneath the longissimus dorsi muscle discussed in the section on the back. As Latin translation tells us, they are rib lifters, thus assisting in breathing in. They also help to keep the back erect and to aid in its rotation as well. There are twelve of them. They arise as attachments to the spinous processes of the last cervical vertebra and eleven of the thoracic vertebrae. In the case of the bottom four, there are two parts to each little muscle bundle, a brevis and a longus, not unlike the rotatores seen above in the section on the back. The brevis, or short, fibers insert on the rib adjacent to the spinous process from which they arose. The longus fibers travel obliquely downward to insert two ribs below the spinous process from which they arose.



LEVATORES COSTORUM MUSCLES



## Back and Thorax Illustration 92

### THE PECTORALIS MINOR MUSCLE

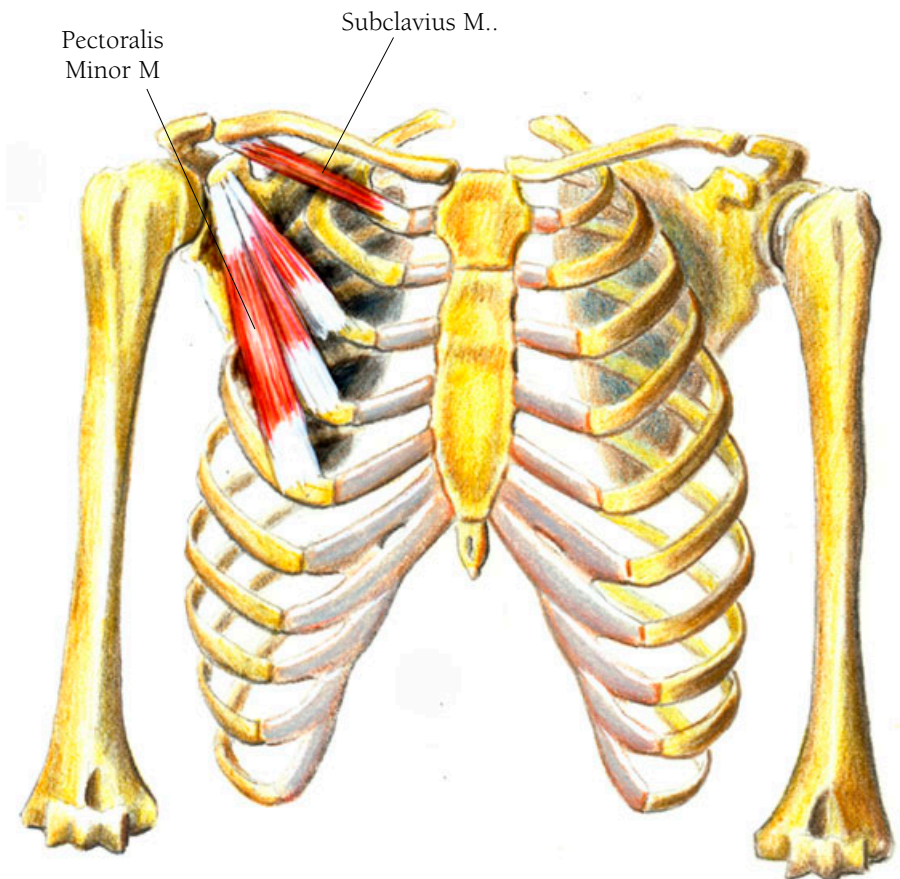
The pectoralis minor muscle is a rib lifter, helping to breathe in. It also assists in rotating the scapula by pulling the arm in towards the body. It arises as three bundles of fibers from the upper borders of the third to fifth ribs, just next to the junctures with the costal cartilages. As the three bundles of muscles course upwards they converge into a tendon which attaches on the coracoid process of the scapula.

### THE SUBCLAVIUS MUSCLE

The subclavius muscle, which brings the shoulder forward and down, arises where the first rib joins with its costal cartilage and courses outward to insert on the underside of the clavicle.

• • •

*Subclavious* is Latin for “under the clavicle.”



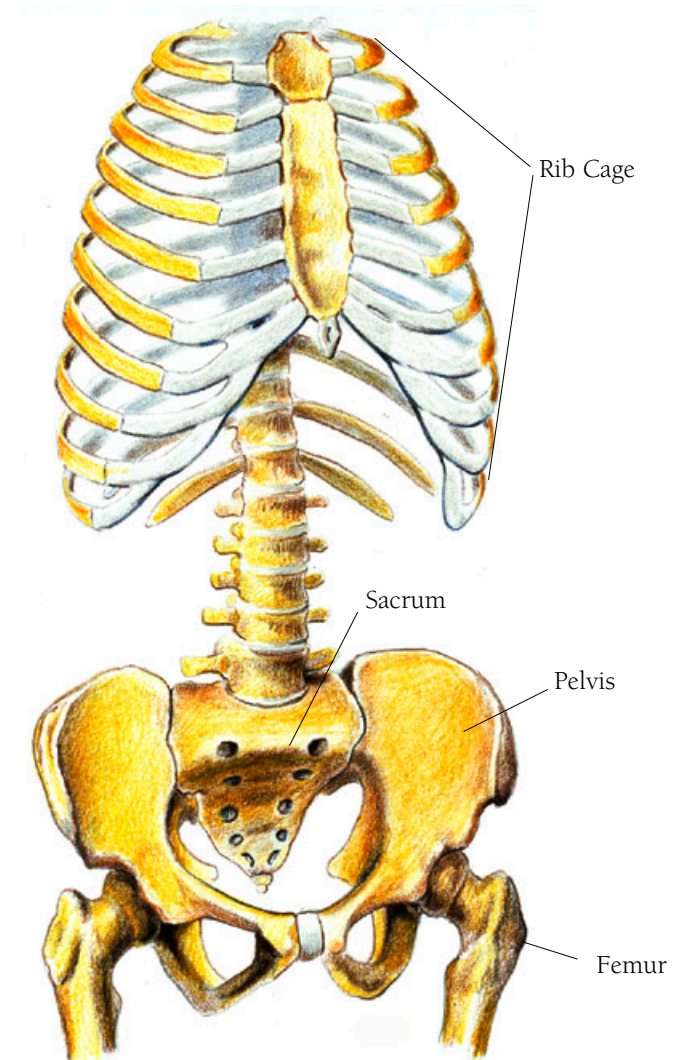
## *The Abdomen and Pelvis*

### THE ABDOMEN

Unlike the thorax, the abdominal organs are not protected by a bony structure. Except for the spinal column, there is no bony protection between the bottom of the ribs to the top of the pelvis although the pelvis is positioned so that there is more of a barrier in the rear than in the front. Therefore the covering and protection of the viscera—stomach, large and small intestines, liver, gall bladder, spleen, kidneys, bladder, and in women the ovaries and uterus—is very important. As well as creating movement, the muscles that wrap around the abdomen protect all of these internal organs. Many of these muscles are attached to broad, tough, fascial tissues which aid in this protective function. I shall to some degree illustrate and mention these.

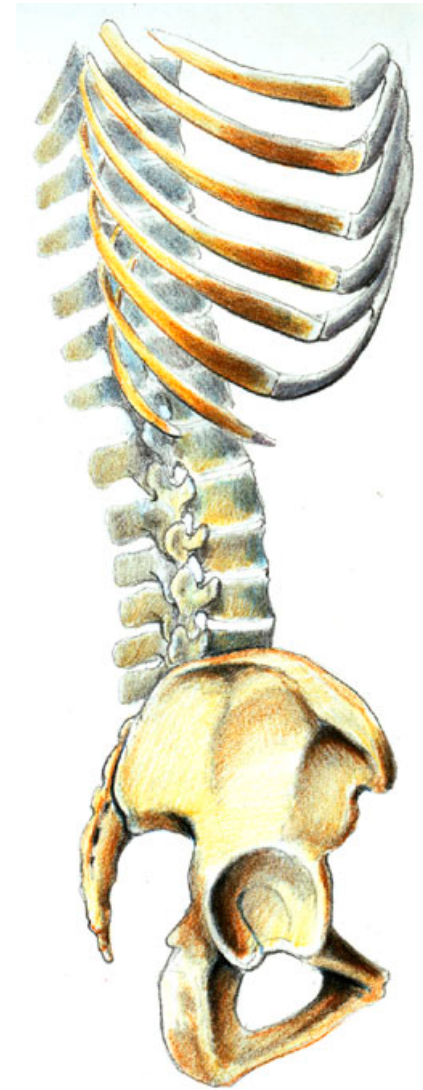
## *Abdomen and Pelvis Illustration 93*

THE TORSO FROM A  $\frac{3}{4}$  FRONT VIEW;  
THE RIB CAGE WITH THE STERNUM;  
THE SPINAL COLUMN WITH THE SACRUM,  
SHOWING HOW IT ARTICULATES WITH THE  
PELVIS; THE TOP OF THE FEMUR, SHOWING  
HOW IT ARTICULATES WITH THE PELVIS



## *Abdomen and Pelvis Illustration 94*

THE TORSO SEEN FROM THE SIDE

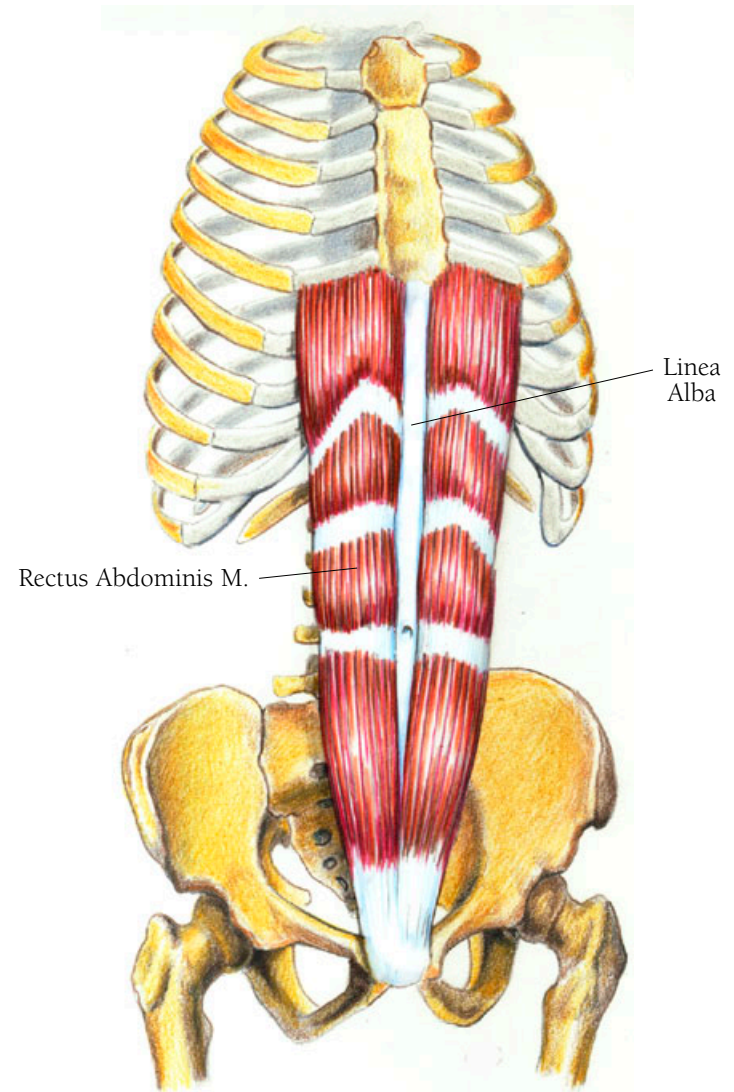


## Abdomen and Pelvis Illustration 95

### THE RECTUS ABDOMINIS MUSCLE

This pair of muscles are the famous 'Abs' which ripple up the front of the abdomen when a man or woman is in good trim. These muscles assist in curving your back by drawing the sternum closer to the pelvis. They are what get sucked in when you told to hold in your tummy. They also help to keep the internal organs in place. Since the small intestine is particularly vulnerable to being moved in any way, this protection is vitally important.

The rectus abdominis muscles arise in tendinous form from the crest of the pubic bone with some fibers of one of the pair interlacing with the other. This interlacing prevents any weakness across the front of the abdomen. They rise upwards as broad bands to cover the abdominal area and insert on the cartilaginous portions of the fifth, sixth and seventh ribs. Each muscle has three tendinous intersections. The first intersection appears at about where the navel is located. The third, the highest one, near the xiphoid process, that tag end of the sternum. The second, or middle intersection, appears halfway between the other two. The upper three sections of muscle are nearly of equal in size whereas



the strip from the pubis to the first intersection is longer and narrower. The two bands of muscle are separated by a tendinous strip called the linea alba.

• • •

*Linea alba* is Latin for “white line.”

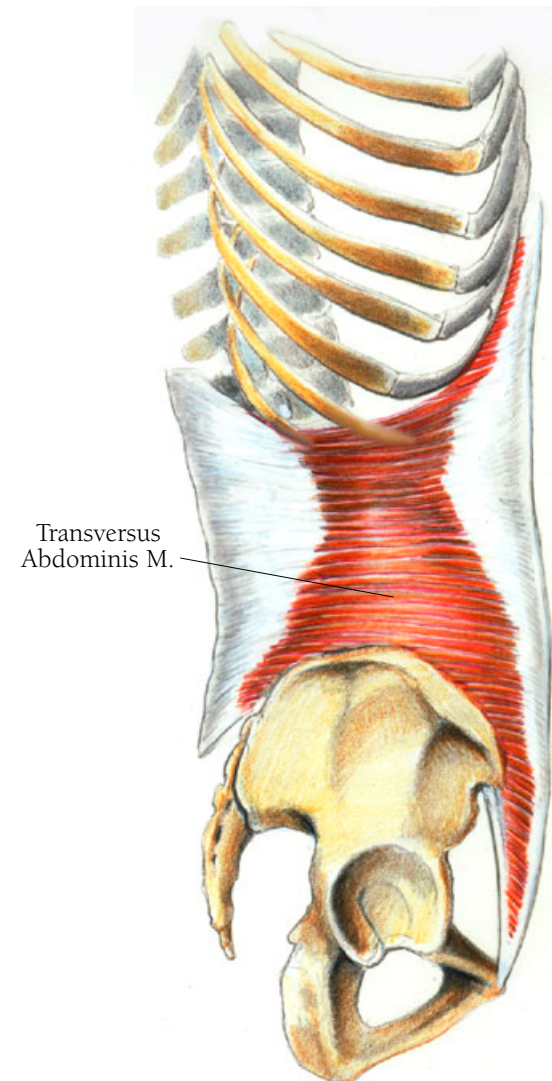
## Abdomen and Pelvis Illustration 96

### THE TRANSVERSUS ABDOMINIS MUSCLE

The transversus abdominis muscle is the innermost layer of abdominal muscles, whose principle action is to compress the internal organs. It arises from the inguinal ligament, along the inner border of the iliac crest of the pelvis; from a broad fascia called the thoracolumbar fascia; and from the inner side of the cartilaginous portions of the lowest six ribs. The middle part of this muscle has fibers that travel horizontally, those above head obliquely upward, and those below go obliquely downward. All fibers insert into an aponeurosis which inserts into the linea alba and is part of the fascia covering the rectus abdominis muscle.

• • •

*Transversus* is Latin for “turning across.” *Abdominis* is Latin for “the belly—the region between the ribs and the pelvis.”

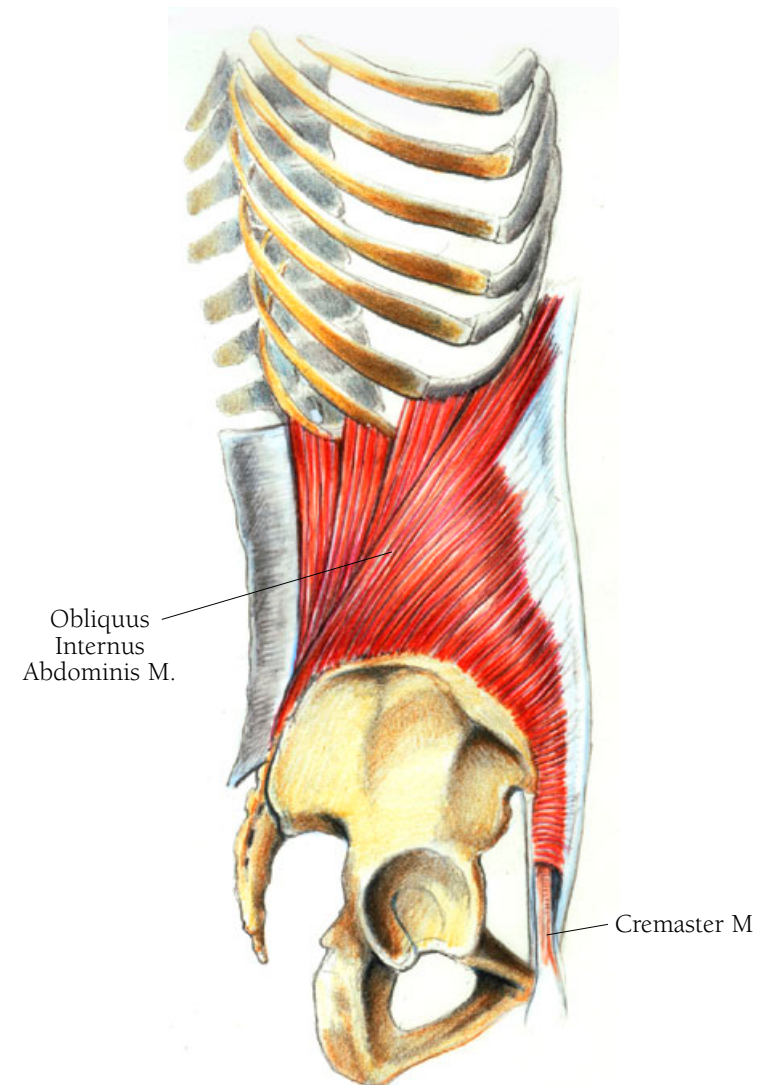


## Abdomen and Pelvis Illustration 97

### THE OBLIQUUS INTERNUS ABDOMINIS MUSCLE

The obliquus internus abdominis muscle is the most important of the abdominal muscles for holding the internal organs in place. It is also the muscle that pushes downward when a woman is in labor. It arises along with the transversus abdominis muscle from the inguinal ligament, from a fascia attached to the iliac crest of the pelvis, and from the lower part of the thoracolumbar fascia. It ascends obliquely across the abdomen to cover the transversus abdominis muscle. Its upper fibers insert onto the lower borders of the costal cartilages of the bottom four ribs while the remaining fibers insert into an aponeurosis which covers the abdominal rectus muscles. It ends by inserting in the linea alba.

This illustration also shows the cremaster muscle. *Kremaster* is Greek for suspender and this muscle is a suspender for the testicle. There is no counterpart in women.



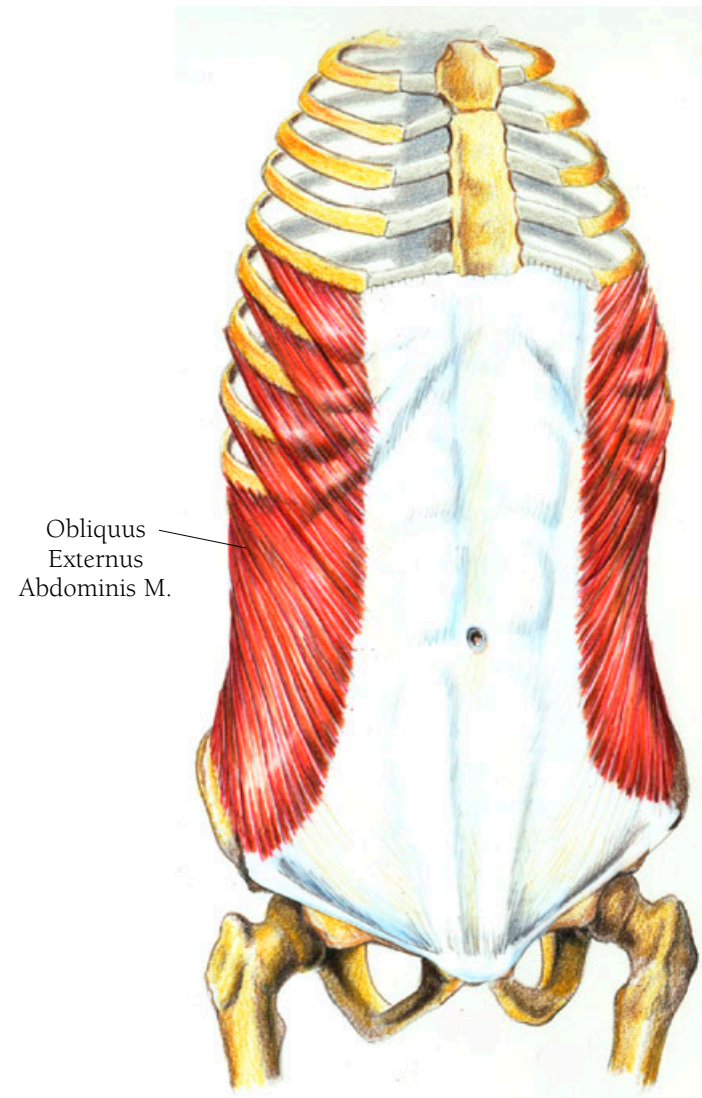


## *Abdomen and Pelvis Illustration 98*

### THE OBLIQUUS EXTERNUS ABDOMINIS MUSCLE

This muscle, the largest and the outermost layer of the anterior abdominal muscles, helps to hold the viscera in place, assists in breathing out, and plays a part in turning the torso. It wraps around the side of the body and some of the front as well, with its fibers obliquely descending from back to front. These fibers are almost perpendicular to the fibers of the muscle beneath, the obliquus internus abdominis muscle. The muscle arises along the outer surfaces of the lower eight ribs, and its bundles of fibers interdigitate with the serratus anterior muscle which attaches to the bottom five ribs. The most lateral aspect of this muscle has fibers that run almost vertically, arising from the last rib to insert on the iliac crest of the pelvis. The remaining fibers of the obliquus externus muscle insert into an aponeurosis which acts as the outermost wall of the central abdomen and covers the rectus muscles.

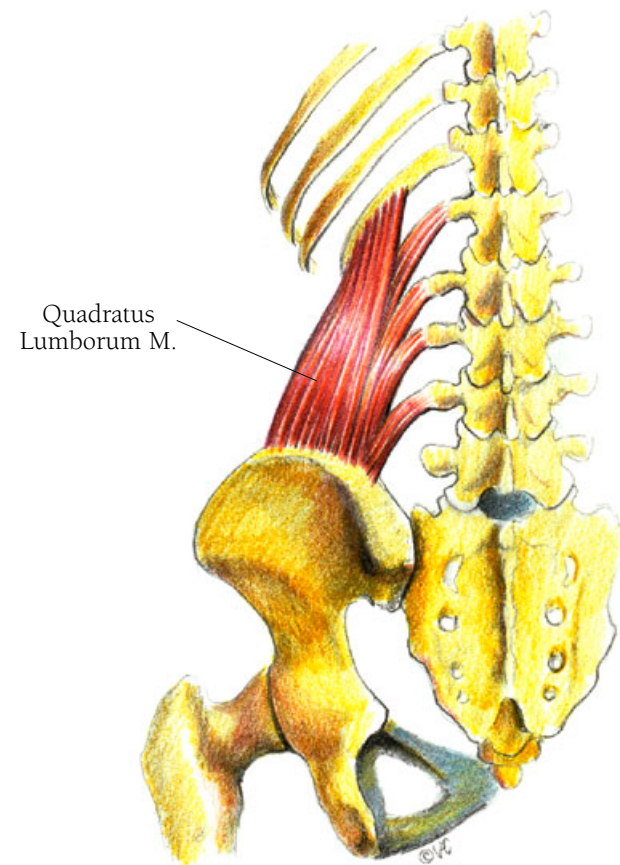
The central fascia of the aponeuroses is the linea alba. The linea alba is the insertion band for all the anterior abdominal muscles and is, therefore, very thick and dense. The only thing that penetrates it is the belly button.



## *Abdomen and Pelvis Illustration 99*

### THE QUADRATUS LUMBORUM MUSCLE

The quadratus lumborum muscle pulls downward on the lowest rib to help bend the spinal column in the direction of the muscle doing the pulling. It also aids in expiration—forced breathing out. It arises from the iliac crest and rises upward to insert on the lower border of the twelfth rib and the tips of the transverse processes of the first four lumbar vertebrae.



## *The Abdomen and Pelvis*

### **THE PELVIS**

One could consider all the muscles in this area as upper leg muscles, playing an important role in maintaining our posture. All contribute to moving the upper thigh, and some facilitate hip rotation.

## Abdomen and Pelvis Illustration 100

### THE PELVIS, ANTERIOR VIEW

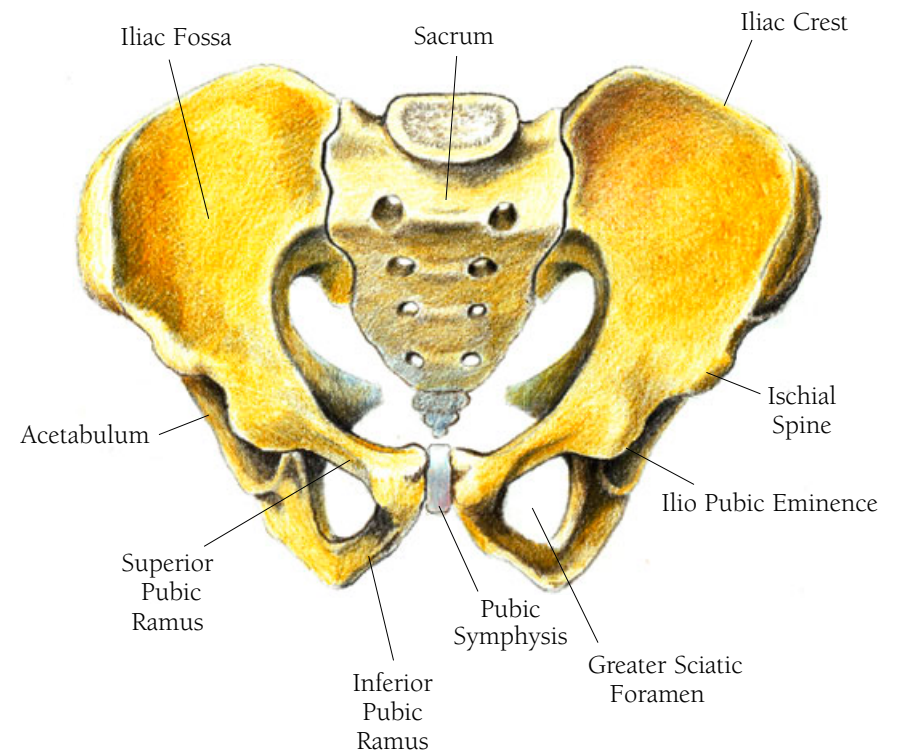
The pelvis is made up of two identical mirror-image bones called the innominate bones to which the sacrum is joined from behind. They are joined to each other in the front by a band of cartilage known as the pubic symphysis. You can also see where the head of the femur fits into the socket called the acetabulum. The male pelvis and the female pelvis are differently shaped because the female pelvis must provide an opening wide enough for giving birth. It is the female pelvis that I show.

• • •

*Innominate* is Latin for unnamed, anonymous, secret.

*Symphysis* is Latin from, the Greek for growing together.

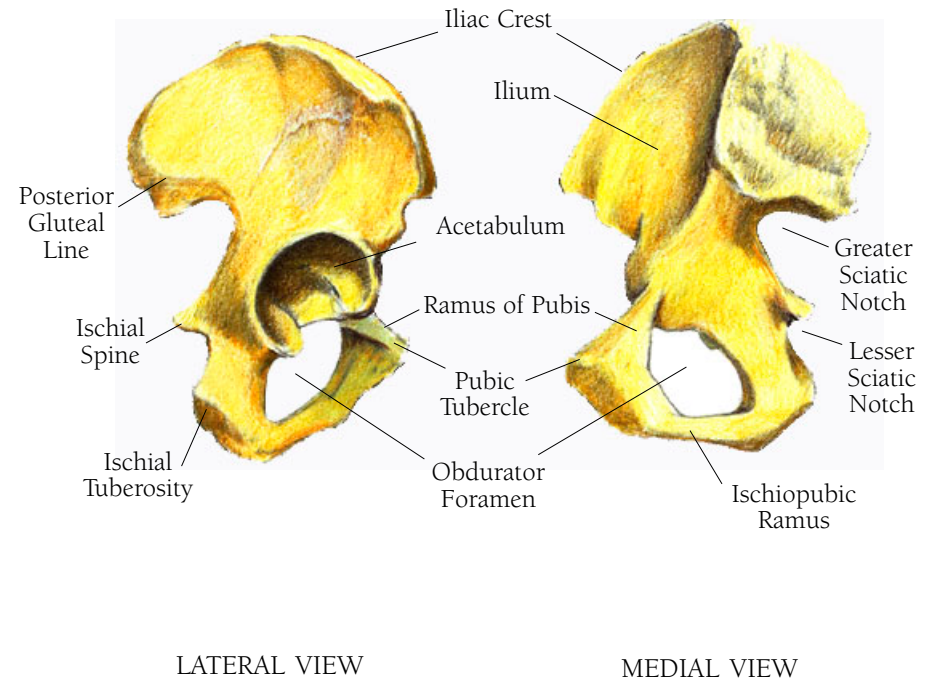
Pubic is from the Latin *pubis* meaning “signs of adulthood,” referring to pubic hair. *Acetabulum* is Latin for a vinegar cup, or “any cup shaped thing.” *Acetum* is Latin for vinegar. Pelvis is from the Latin, meaning basin or funnel shaped.



## *Abdomen and Pelvis Illustration IOI*

THE RIGHT INNOMINATE BONE, LATERAL VIEW

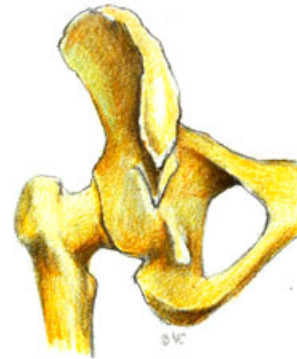THE RIGHT INNOMINATE BONE, MEDIAL VIEW



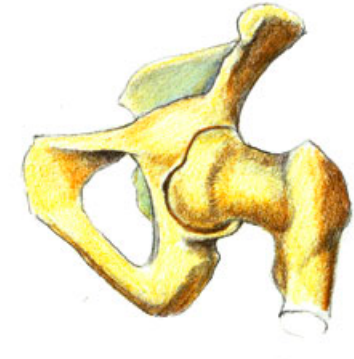## *Abdomen and Pelvis Illustration 102*

THE PELVIS, POSTERIOR INFERIOR VIEW, SHOWING THE TOP PORTION OF THE FEMUR WITH ITS HEAD IN THE ACETABULUM

THE PELVIS, ANTERIOR INFERIOR VIEW, SHOWING THE TOP PORTION OF THE FEMUR WITH ITS HEAD IN THE ACETABULUM



INFERIOR POSTERIOR VIEW



INFERIOR ANTERIOR VIEW

## *Abdomen and Pelvis Illustration 103*

The psoas major, the psoas minor and iliacus muscles are sometimes considered one, called the Iliopsoas muscle. I shall treat them separately, but show them together.

### THE PSOAS MAJOR MUSCLE

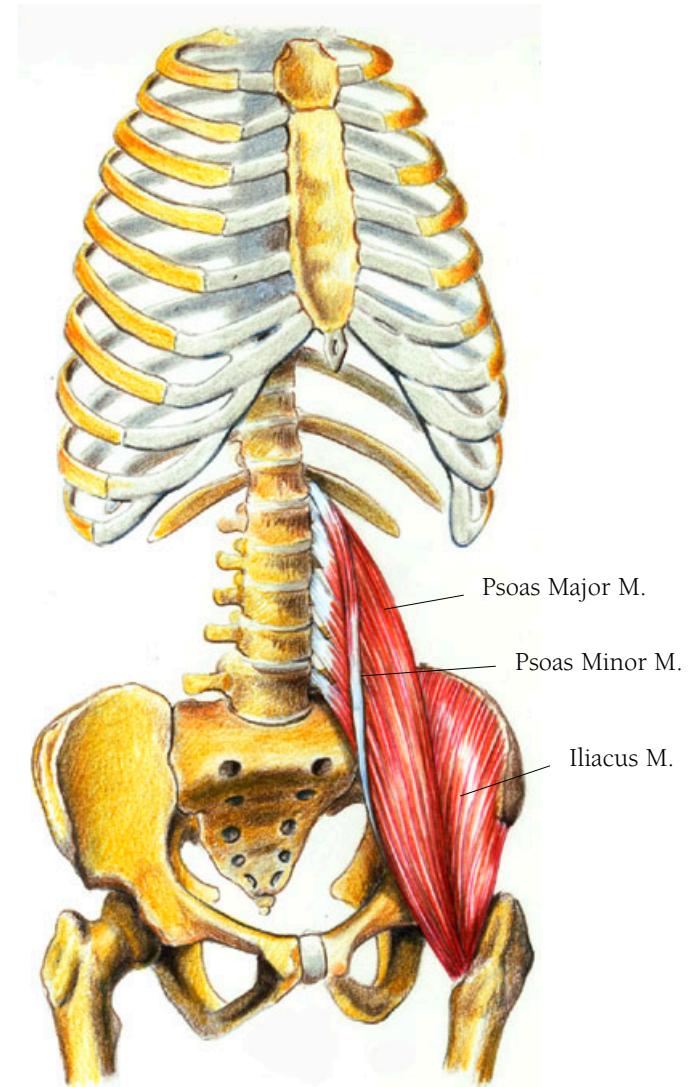
This muscle brings the leg up frontally and helps in curving the spine. It arises from the inner surfaces of all the lumbar vertebrae's transverse processes and from the sides of the bodies of the last thoracic and all the lumbar vertebrae. It then courses downwards into the pelvic area, getting narrower as it goes, and inserts on a protrusion of the upper rear part of the femur called the lesser trochanter.

• • •

*Psoa* is Greek for “muscle of the loins”.

### THE PSOAS MINOR MUSCLE

The psoas minor muscle arises from the sides of the bodies of the last thoracic and first lumbar vertebrae and lies over the psoas major muscle as a thin bundle. It ends in a long tendinous insertion on the iliopectineal eminence of the pelvis. Sometimes this muscle cannot be found in dissection.



## THE ILIACUS MUSCLE

The iliacus muscle bends the thigh. It arises from the inner border of the iliac crest of the pelvic bone and from the upper fossa of the ilium of the pelvis. It inserts on the tendon of the psoas major muscle where that muscle inserts on the femur. Other fibers insert just around the lesser trochanter.

• • •

*Ilium* comes from the Latin *ilium* or *ileum* meaning flank or groin.



Rather than cause specific movements, this next group of muscles—the obturators, the gemelli, the quadratus femoris, and the piriformis—are short muscles that act together to maintain proper posture. They function more like flexible and elastic ligaments than like muscles.

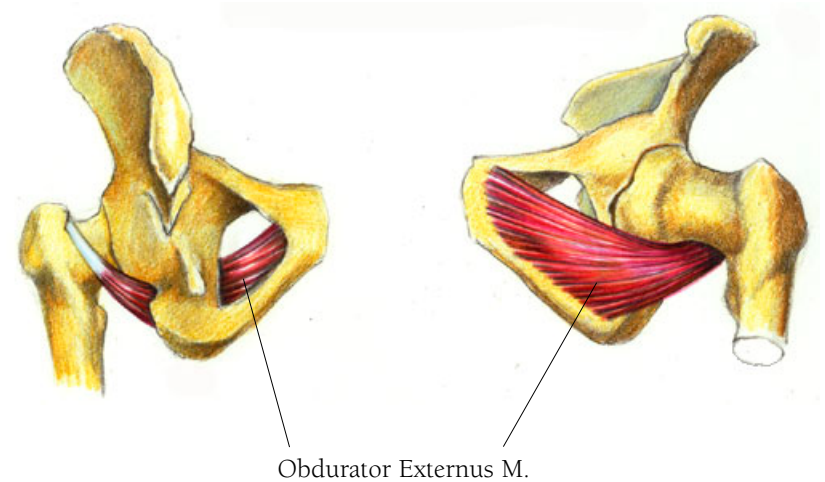
## *Abdomen and Pelvis Illustration 104*

### THE OBTURATOR EXTERNUS MUSCLE

There are two obturator muscles, one internus and one externus—internal and external. The obturator externus muscle arises from the pubic and ischial rami. It covers the obturator foramen as a broad flat muscle which converges and travels under the neck of the femur to insert in the fossa of the trochanter on the femur. A fossa is an indentation of bone.

• • •

Obturator comes from the Latin *obdurare*, to harden or be inflexible. *Ischium* is Latin for hip joint and *ramus* is Latin for branch. The ischial ramus is the bony part that hurts when you've sat too long on a hard seat. Fossa comes from the Latin word for trench.



## Abdomen and Pelvis Illustration 105

### THE OBTURATOR INTERNUS MUSCLE

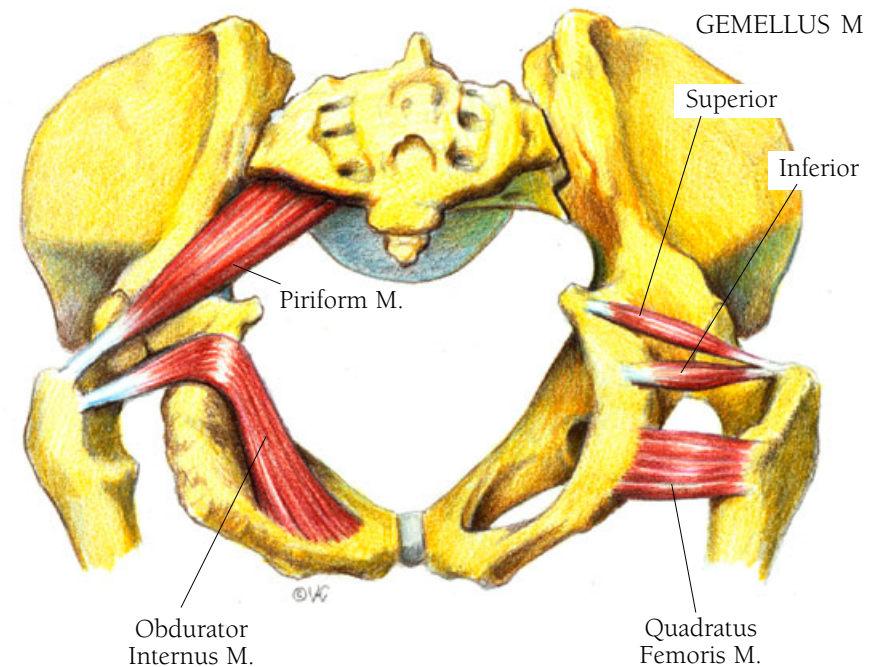
Lying partly within the basin of the pelvis, this muscle arises in attachments all around the obturator foramen, its fibers converging toward the groove formed between the ischial spine and the ischial tuberosity on the pelvis. It then curves around the lesser sciatic notch and ends in a tendon which inserts on the surface of the greater trochanter on the femur.

• • •

*Trochanter* is Greek, meaning “the runner.” It also refers to the ball of the femur which fits into the hip socket. *Foramen* is Latin for opening or hole.

### THE GEMELLUS MUSCLE, SUPERIOR AND INFERIOR

These two muscles are above and below the obturator internus muscle, with their tendinous fibers combining with the obturator’s tendinous insertion on the greater trochanter. The superior muscle arises from the undersurface of the ischial spine and the inferior one from the ischial tuberosity. Both muscles embrace the obturator internus muscle from above and below.



• • •

*Gemellus* is the Latin diminutive of *geminus* meaning a twin.

### THE QUADRATUS FEMORIS MUSCLE

The quadratus femoris muscle arises from the outer, upper aspect of the ischial tuberosity and passes behind the neck of the femur to insert on the crest of the trochanter and onto the bone below.

### THE PIRIFORMIS MUSCLE

This muscle arises along the front surface of the sacrum in three projections that surround the middle two foramina. It passes obliquely out of the pelvic girdle and through the greater sciatic foramen to insert as a rounded tendon on the crest of the greater trochanter.

• • •

Piriformis is derived from the Latin words *pirum* and *forma* to mean pear shaped.

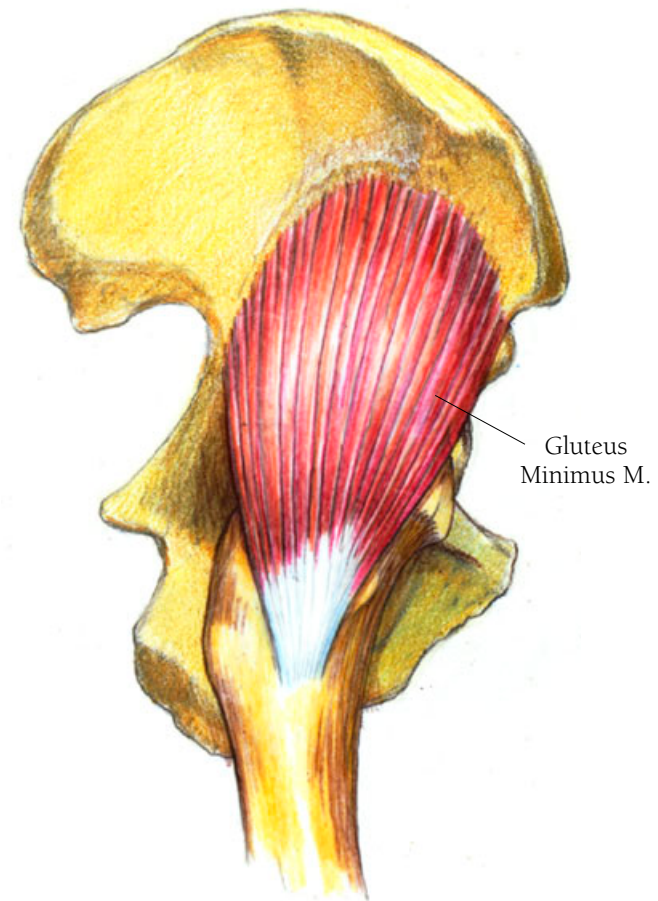
## *Abdomen and Pelvis Illustration 106*

### THE GLUTEUS MINIMUS MUSCLE

Along with the gluteus medius muscle, the gluteus minimus assists in abducting, or lifting, the thigh outwards and they play an important part in keeping the torso upright when the foot of the opposite side is off the ground during walking and running. Both muscles work to keep the body erect when you stand with one foot raised. The gluteus minimus muscle, the deepest of the three gluteus muscles, arises from a broad area on the outer surface of the ilium and then descends, narrowing to a tendon that inserts on a ridge on the greater trochanter.

• • •

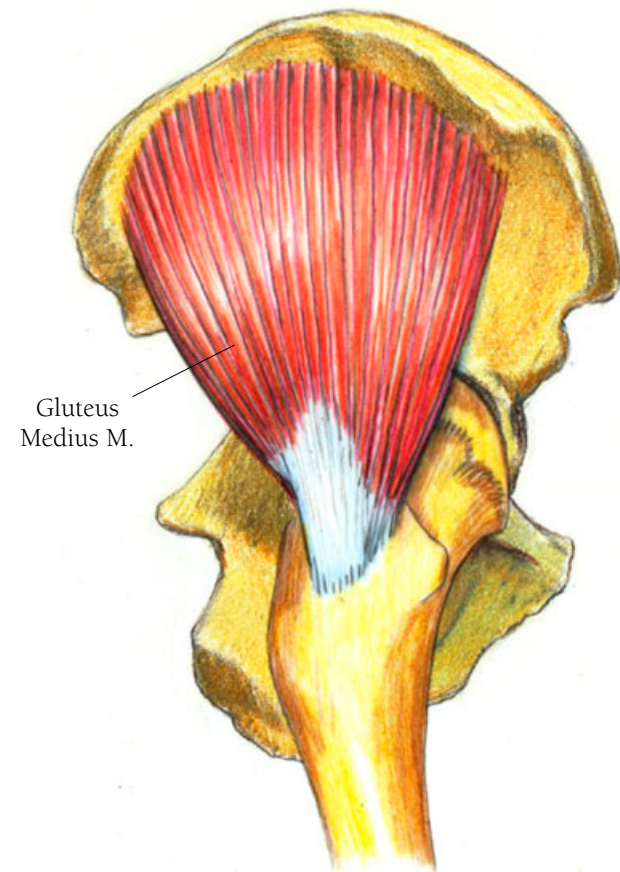
*Gluteus* comes from the Greek *glutos* which means buttocks. *Gluteus minimus* thus means the smallest buttocks muscle.



## *Abdomen and Pelvis Illustration 107*

### THE GLUTEUS MEDIUS MUSCLE

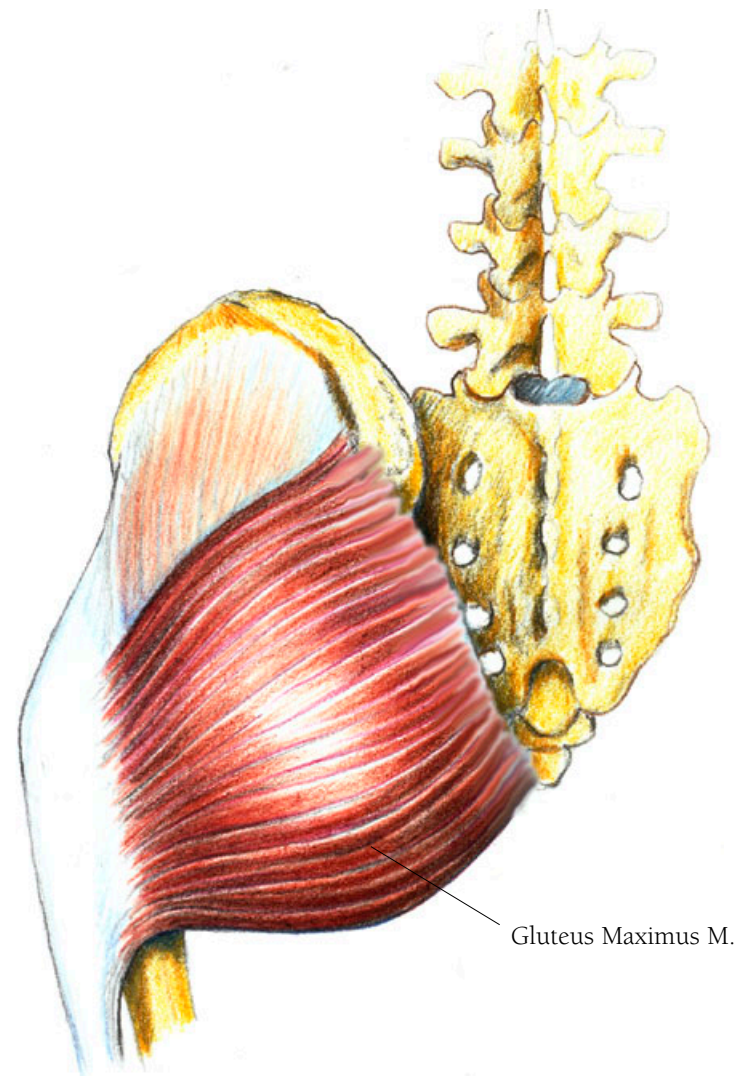
Lying just over the gluteus minimus, this muscle arises from the outer surface of the ilium, over an area just behind (or posterior to) the gluteus minimus. It too is fan shaped but thicker and broader than the minimus. In descending it narrows to form a tendon which attaches on the greater trochanter just behind and above where the gluteus minimus muscle inserts.



## *Abdomen and Pelvis Illustration 108*

### THE GLUTEUS MAXIMUS MUSCLE

The gluteus maximus muscle, which forms the shape of the buttocks, is the largest, thickest, and most superficial of the three gluteus muscles. It brings the leg back to a straight position after you lift it forward and also helps to right the body after you bend over. In addition, it helps you to walk, climb stairs and lift your leg sideways. Its large size is characteristic of homo sapiens in comparison with other primates. The reason this muscle is so developed in humans is that it is crucial to maintaining our upright stance. It arises from the posterior portion of the ilium, from the posterior part of the iliac crest, from the aponeurosis of the erector spinae which is attached to the sacrum, from the bony surface of the sacrum, from the side of the coccyx, and from the fascia which covers the gluteus medius. It travels obliquely out and down to cover most but not all of the gluteus medius muscle and ends in a broad tendinous sheath. This sheath passes over the greater trochanter to join with the iliotibial tract of the fascia lata, a structure which I shall discuss below in the section on the upper leg.



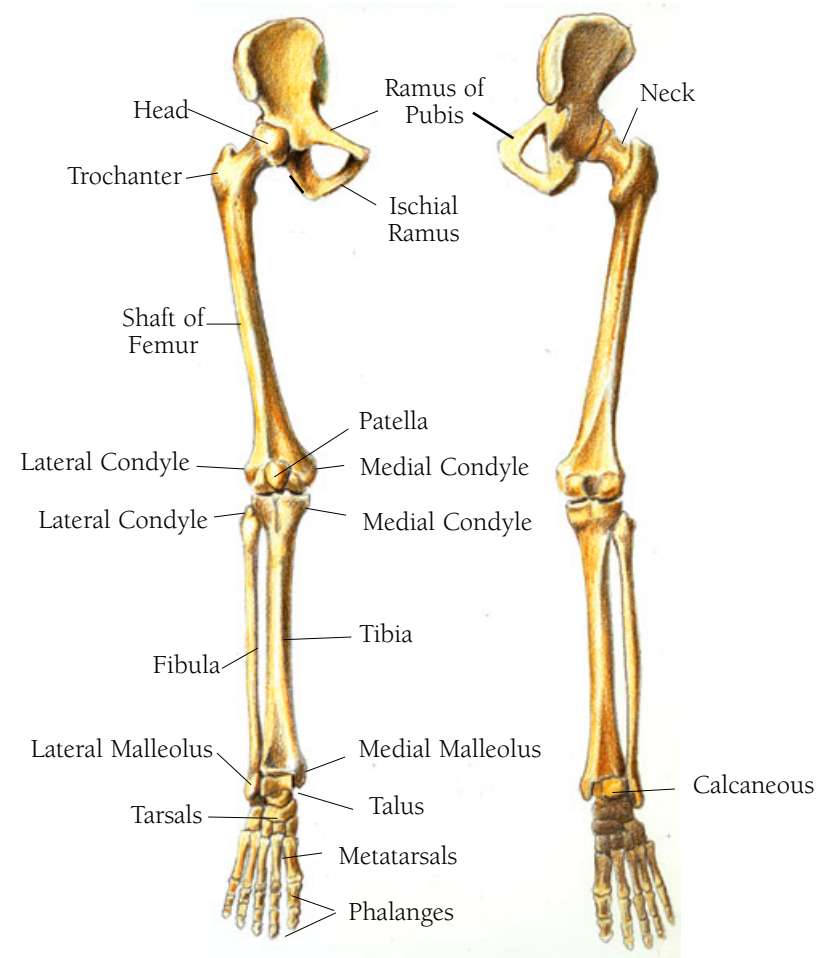
## Leg and Foot Illustration 109

### THE BONES OF THE RIGHT LEG AND PELVIS, ANTERIOR AND POSTERIOR VIEWS

Here you see the right side of the pelvis or innonimate bone, the femur, the tibia and fibula, the patella, and the bones of the ankle and foot. The features you should note on the pelvis are the inferior and superior rami of the pubis and the ischial ramus. The features to note of the upper leg, or the femur are: the head of the femur which fits neatly into the acetabulum, the socket provided by the pelvis; the neck, which provides the leg bone sufficient distance out from the pelvis so that the leg can move about, the trochanter found at the base of the neck, the shaft, which descends down to the knee area where it broadens into the medial and lateral condyles. The patella is in front sitting just between the two condyles. The femur is found at the base of the neck, the shaft, which descends down to the knee area where it broadens into the medial and lateral condyles. The patella is in front sitting just between the two condyles.

• • •

*Trochanter* is Greek for runner. *Femur* is Latin for thigh. *Patella* comes from the Latin *patina*, meaning pan, and the verb *patere*, meaning “to be open.”



ANTERIOR VIEW

POSTERIOR VIEW

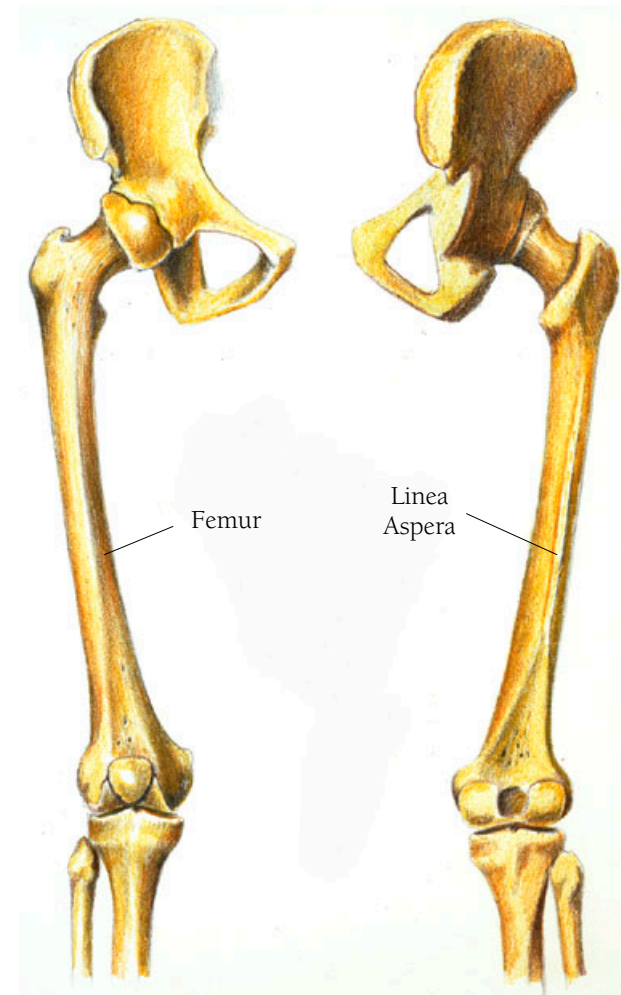
## Leg and Foot Illustration IIO

### THE BONES OF THE RIGHT THIGH, ANTERIOR AND POSTERIOR VIEW

A cross section of the shaft of the femur shows it to be three sided. One side is in front and the other two meet in the back at the linea aspera. The two rear sides meet as two rough edges which split as they descend, one becoming the lateral condylar line and the other the medial condylar line.

• • •

*Linea aspera* in Latin means “rough line.”



ANTERIOR VIEW

POSTERIOR VIEW

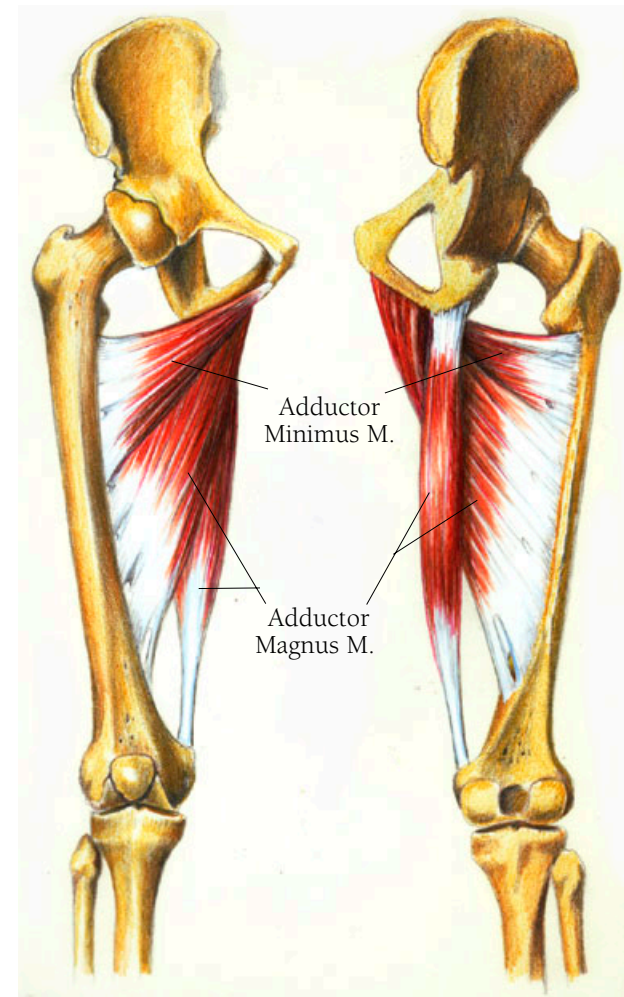


## Leg and Foot Illustration III

### THE ADDUCTOR MAGNUS AND ADDUCTOR MINIMUS MUSCLES

The adductor magnus muscle and the adductor minimus work together. “Adduction” means to bring toward the center. When you are standing and your leg is out, gravity more than by muscular action will bring it down. However, if you are lying down or sitting with your legs open, bringing them together requires work of these muscles. The adductors also assist in maintaining posture and in rotating the thigh—turning the thigh inward.

This three part muscle arises in a continuous line on the inferior ramus of the pubis and the ischial ramus. The fibers arising from the inferior ramus run almost horizontally to the shaft of the femur to insert onto the gluteal tuberosity, just above where the linea aspera begins. This part is sometimes referred to as the adductor minimus. The fibers that arise from the ischial ramus insert along the medial side of the linea aspera, on the posterior side of the shaft of the femur. The fibers that arise from the ischial tuberosity descend as a thick round muscle that feeds into a round tendon which inserts on the medial condyle of the femur.



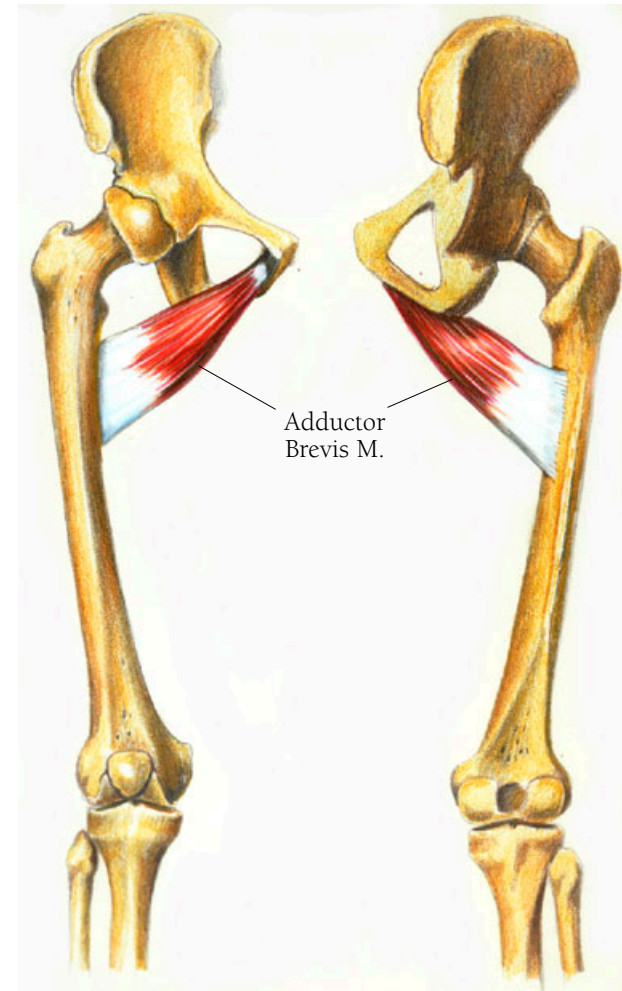
ANTERIOR VIEW

POSTERIOR VIEW

## *Leg and Foot Illustration II2*

### THE ADDUCTOR BREVIS MUSCLE

The adductor brevis muscle arises as a small attachment to the inferior ramus of the pubis. It travels obliquely out and down, gradually broadening to insert along a line just below the lesser trochanter, not far from where linea aspera begins. Its place of insertion is just lateral to where the upper part of the magnus muscle inserts.



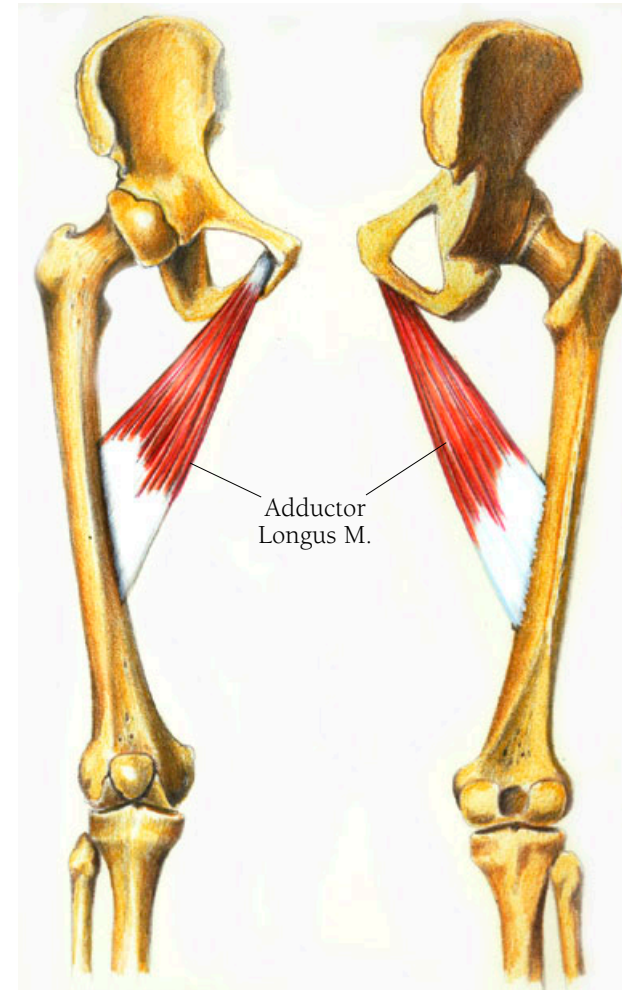
ANTERIOR VIEW

POSTERIOR VIEW

## *Leg and Foot Illustration III*

### THE ADDUCTOR LONGUS MUSCLE

The adductor longus muscle arises as a tendon on the front of the pubis and descends obliquely, and more downward than the brevis muscle, to insert almost parallel to and very close to the insertion of the magnus muscle, discussed above.



ANTERIOR VIEW

POSTERIOR VIEW

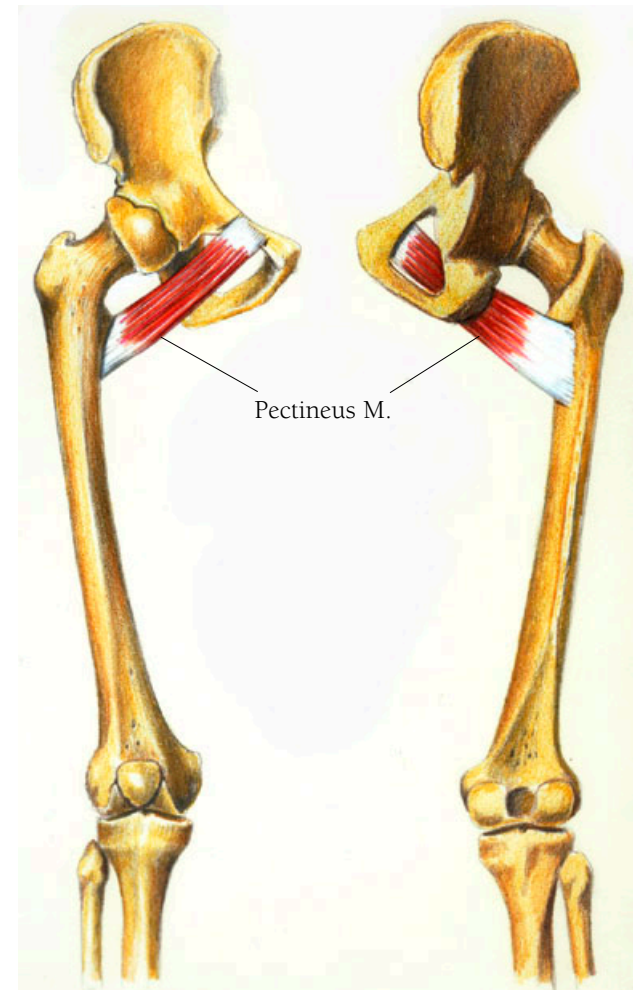
## Leg and Foot Illustration II4

### THE PECTINEUS MUSCLE

As with the adductors, I have illustrated the pectineus muscle from the posterior and anterior views so that you can see both the origin and the insertion. This muscle is also an adductor working with the three muscles mentioned above. It also helps to flex the thigh. It arises from the pubis and courses laterally and a bit downwards to insert on the back of the femur in a line that begins just below the lesser trochanter and descends to where the linea aspera begins.

• • •

*Pecten* is Latin for pubic bone.



ANTERIOR VIEW

POSTERIOR VIEW

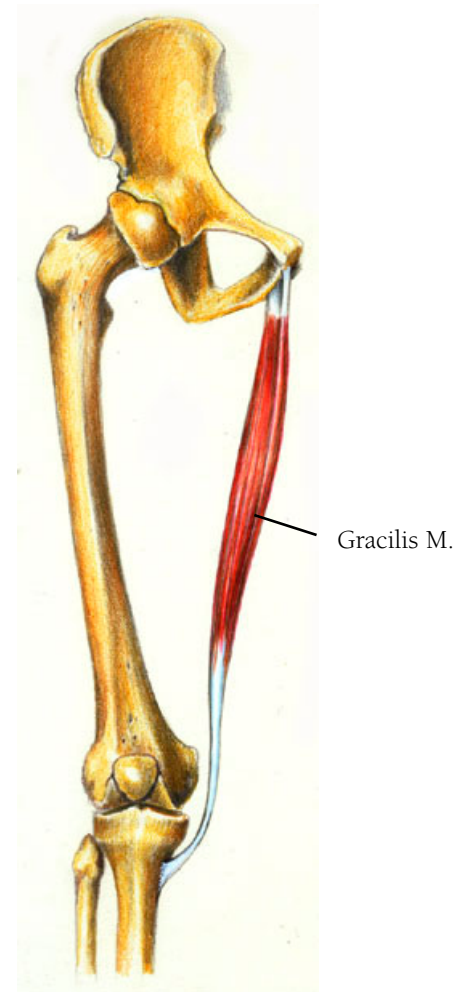## Leg and Foot Illustration 115

### THE GRACILIS MUSCLE

This narrow flat muscle helps to bend the leg (flexion) and turn it inward (medial rotation). It arises from the pubis, along the lower border of the pubic ramus and the ischial ramis. Its fibers course downward to end in a round tendon which first descends over the medial condyle of the femur and then passes behind and around the medial condyle of the tibia. The insertion appears as fibers spread out over the surface of the tibia just below the medial condyle.

• • •

*Gracilis* is Latin for slender.



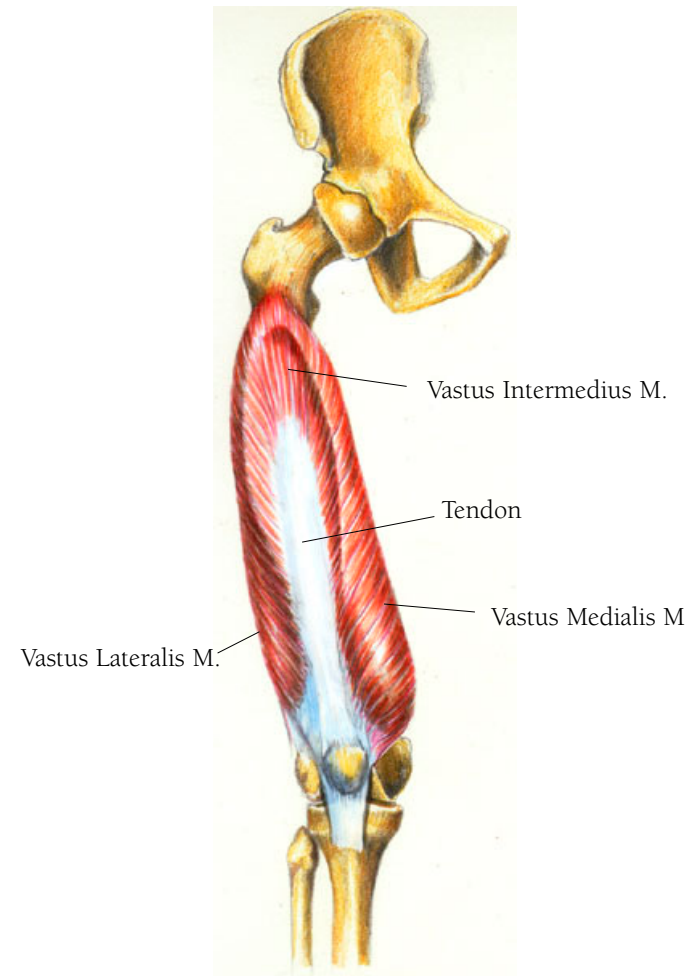
## Leg and Foot Illustration II6

### THE VASTUS INTERMEDIUS, THE VASTUS LATERALIS AND THE VASTUS MEDIALIS MUSCLES

The vastus intermedius, the vastus lateralis and the vastus medialis muscles appear to be one muscle surrounding a large tendoninous sheath. They are three quarters of the group of muscles called the quadriceps. There is a fourth muscle of this group, the rectus femoris muscle which I will discuss with the following illustration. However I will describe the actions of this muscle group as a whole. They act together to straighten the leg by extending the knee. The rectus portion of this group assists in bending the thigh. The group also allows you to bend your thigh and straighten your leg at the same time.

The vastus intermedius muscle arises from the front and the lateral side of the upper two thirds of the femur's shaft. Its fibers insert into an aponeurosis-like tendon which covers about half of the lower shaft of the femur. The fibers insert into the lateral border of the patella and others on the lateral condyle of the tibia.

The vastus medialis and lateralis muscles are a pair, one on each side of the tendon. The medialis muscle fibers arise as a narrow band from just beneath the greater trochanter and



THREE OF THE QUADRACEPS MUSCLES

along the medial side of the linea aspera. They then curl around while descending with the most of the upper fibers inserting into the tendinous aponeurosis I wrote of above—the tendon associated with the vastus intermedius. The lower fibers insert along the medial border of the patella. The lateralis muscle fibers arise just beneath the greater trochanter and half way along the lateral side of the linea aspera and curl around in almost a mirror image of the medialis. The upper fibers insert into the aponeurosis of the vastus intermedius and the lower ones become tendinous fibers that insert along the lateral border of the patella. These fibers become the tendon which covers the patella and contribute to the fascia which forms the capsule of the knee joint. Some fibers continue descending to attach to the lateral condyle of the tibia.

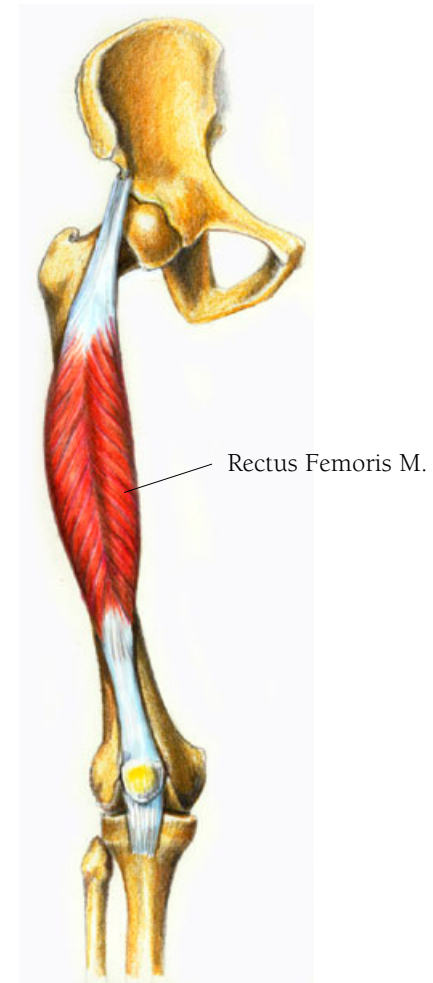
• • •

*Quadri* is Latin for four and *-ceps* is from the Latin *caput* meaning head—i.e., four heads. *Vastus* is Latin, meaning “of large extent,” and *intermedius* means “in the middle.”

## *Leg and Foot Illustration II7*

### THE RECTUS FEMORIS MUSCLE

The Rectus Femoris muscle is the fourth of the Quadriceps muscles and originates as two tendons. It originates at the anterior inferior iliac spine. Behind it is a smaller and flatter tendon which begins at a point just above the acetabulum and the capsule of the hip joint. The two tendons form an aponeurosis which merges into the muscle's fibers. The muscle ends as a flat tendon which inserts at the superior edge of the patella. When you look at the previous illustration of the lateralis and medialis, you can see where the rectus femoris neatly fits on top of those muscles and their tendon, the lateralis and the medialis on either side of the rectus femoris.





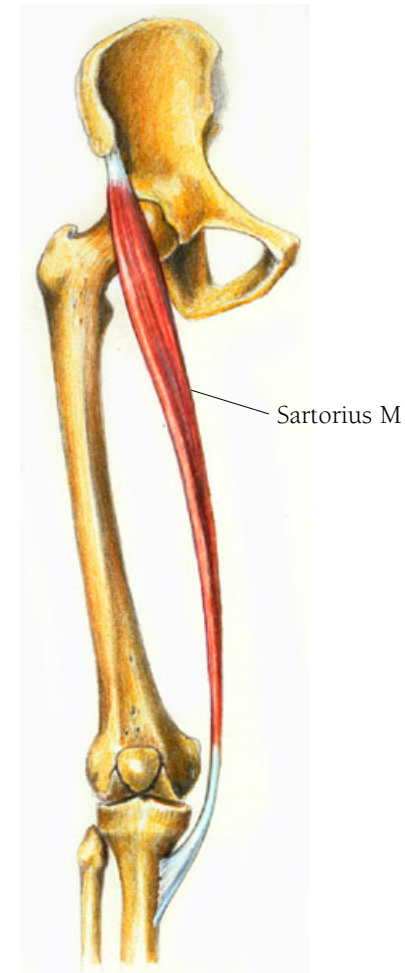
## Leg and Foot Illustration II8

### THE SARTORIUS MUSCLE

The sartorius muscle helps to flex the knee and the thigh and plays a role in moving the leg outward (abduction) and in outward rotation. It also assists in the motion needed to cross one leg over the other and helps us climb stairs. It plays a very small part in walking. After arising on the tip of the anterior superior iliac spine (that's the bone you can feel on each side of your lower abdomen) and the notch just below it, it crosses over the quadriceps muscle at an oblique downward angle and then descends to cover the medial side of the knee joint as a flat tendon. This tendon has fibers that join the capsule of the knee joint. Further down it becomes a broad aponeurosis which attaches to the upper, medial side of the tibia, just in front of the attachments of the semitendinosus and gracilis muscles. The sartorius muscle is the longest single in the body. It looks like a strap in its shape and functions to hold all the muscles beneath it in place.

• • •

Its name is from the Latin *sartor* meaning “tailor.”



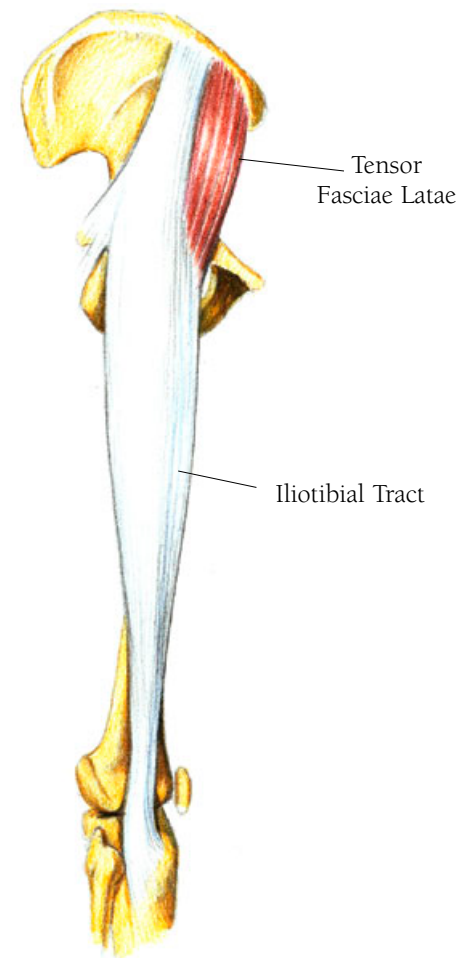
## Leg and Foot Illustration II9

### THE TENSOR FASCIAE LATAE MUSCLE

The tensor fasciae latae helps to extend the knee and to keep our posture upright. As well as having fibers that arise along the iliac crest, it arises from just beneath the origin of the sartorius muscle. It inserts into a large band of tendon called the iliotibial tract or the fasciae latae. The iliotibial tract, or fasciae latae, travels from its origin on the iliac crest to its insertion on the lateral condyle of the tibia. The muscle works in conjunction with the fasciae latae.

• • •

*Tensor fasciae latae*, from Latin means “stretcher of the side fascia.” Tensor comes from the Latin verb *tendere*, meaning to stretch. The word tendon has the same origin.

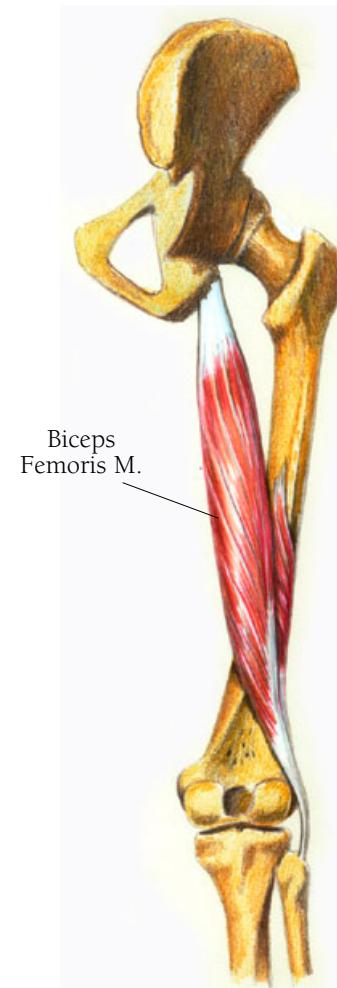


There are three muscles of the posterior leg which comprise what are called the hamstrings—the biceps femoris muscle, the semitendinosus muscle, and the semimembranosus muscle. Acting as knee flexors, they assist in moving the upper leg backward (extension of the thigh). With their insertions on either side of the knee these muscles work together to rotate the knee, to maintain a stance with the knees slightly bent, to limit just how far one can bend over when trying to touch the toes without bending the knees, and by straightening out the lower curvature of the spine to curve the pelvis forward when sitting.

## *Leg and Foot Illustration 120*

### THE BICEPS FEMORIS MUSCLE

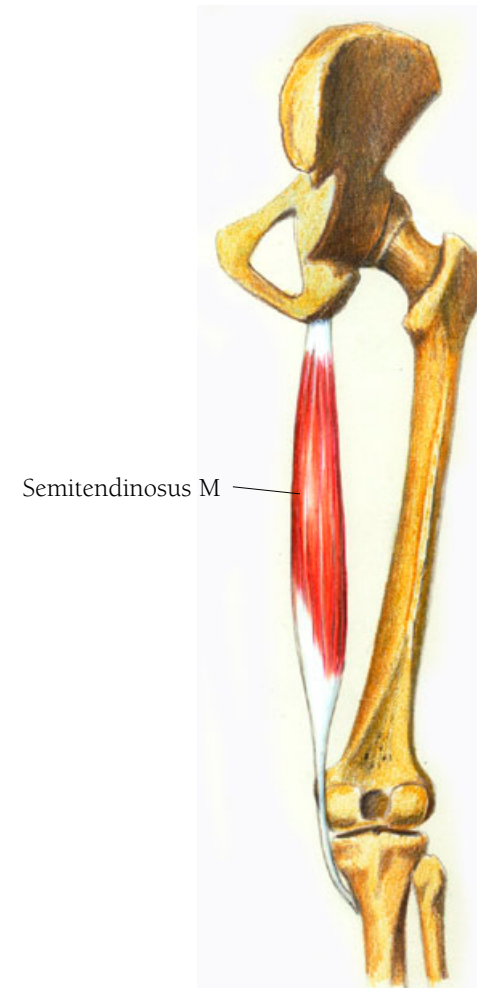
The biceps femoris muscle arises as two heads. A long round head arises from the ischial tuberosity as a tendon which is shared with the semitendinosus muscle. A short head arises from the outside edge of the linea aspera, about one third of the way down the posterior shaft of the femur. The fibers of the short head feed into those of the long head, which descends and ends in an aponeurosis and tendon. The tendon passes over the lateral condyle of the femur, crosses the joint to insert on the head of the fibula.



## *Leg and Foot Illustration 121*

### THE SEMITENDINOSUS MUSCLE

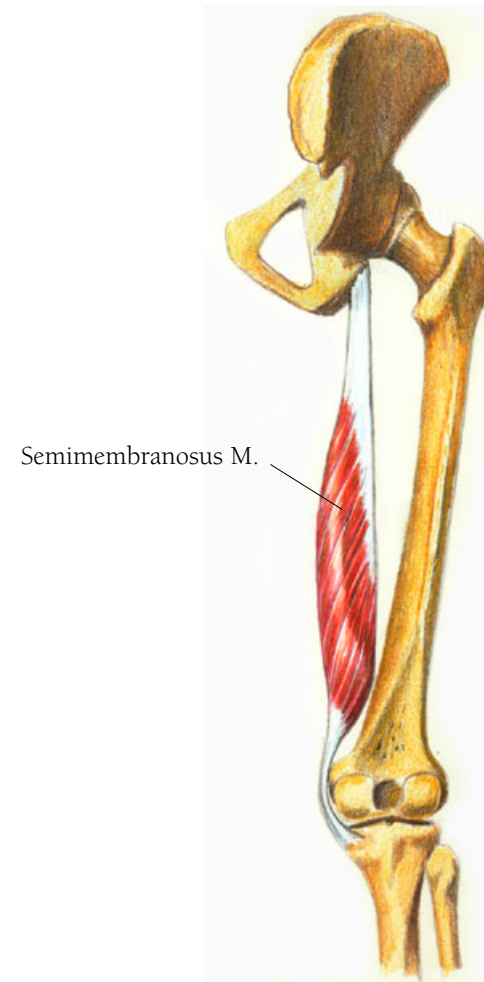
This muscle arises from the ischial tuberosity of the pelvis as a tendon shared with the biceps femoris and descends as a long round muscle on the medial side of the femur. It becomes a round tendon around the middle of the thigh and descends to curl behind the medial condyle of the femur and to insert on the upper shaft of the tibia.



## *Leg and Foot Illustration 122*

### THE SEMIMEMBRANOSUS MUSCLE

This muscle arises as a flat long tendon just in front of the semitendinosus muscle on the ischial tuberosity of the pelvis and descends as a round long muscle. The muscle ends as a rounded tendon which crosses the knee joint, then separates into five different attachments. The main insertion is on the posterior portion of the medial condyle of the tibia.



## THE LOWER LEG

There are many similarities between the lower leg and the lower arm, and the foot and the hand, with some of the muscles and bones of each even having the same names. However there are enormous differences in their functions. The hand is a tool with many capacities. The foot is used only for standing and locomotion. I'm dividing the lower leg muscles into three major groups: the anterior group found on the front of the lower leg, the lateral group found on the outside, and the posterior group on the rear of the lower leg. The posterior group has two layers, the deep and superficial muscles of the calf.

## Leg and Foot Illustration 123

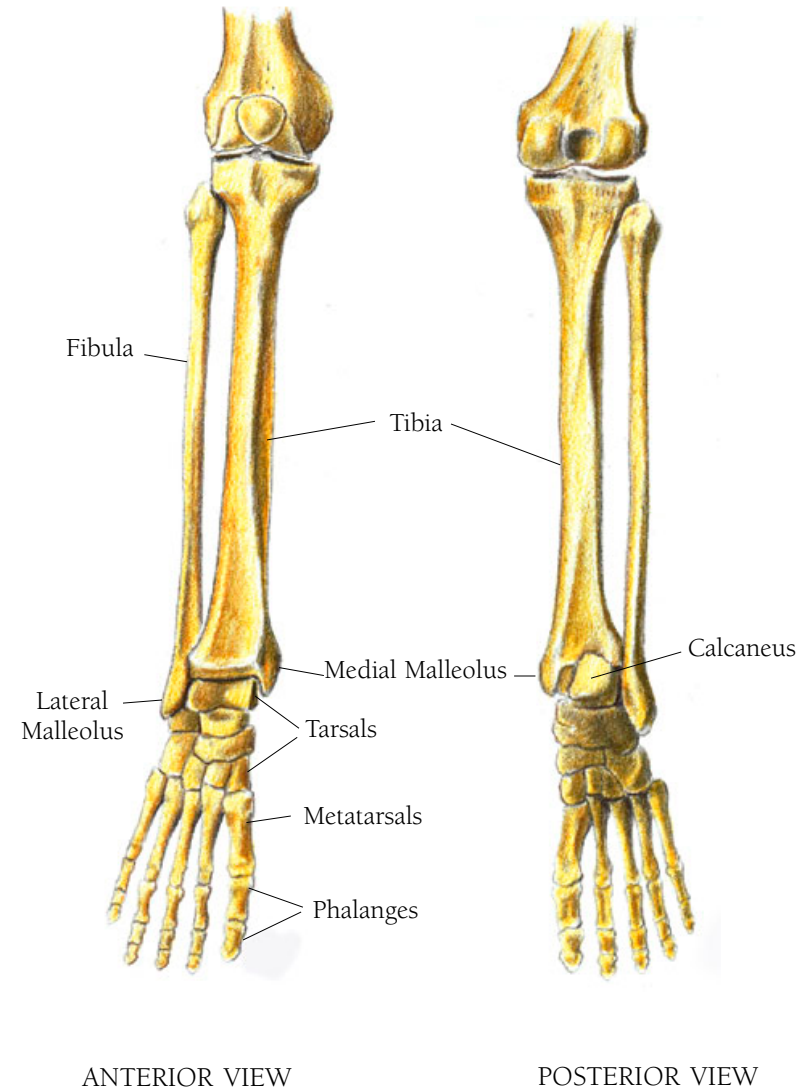
### THE BONES OF THE LOWER LEG, ANTERIOR VIEW AND POSTERIOR VIEWS

The major bones of the lower leg are the tibia and the fibula. I shall discuss the tarsals, metatarsals and phalanges in the section on the foot. The tibia is what we call the shin bone. Its shape in cross section is triangular, with the posterior side being the base of the triangle. The shin bone is unprotected by muscle, which is why a kick in the shins is so painful.

The fibula is the smaller bone and it is the lateral or outside bone of the two. Its distal end, called the lateral malleolus, forms the ankle bone.

The lower leg cannot rotate like the lower arm. The side to side movement of the foot and the rotation in the lower leg are much more constrained than in the arm. The major movement is all in a line, comparatively speaking. The function of the legs has to do with standing, stabilizing the body, and enabling locomotion. People who lose the use of their arms and hands or who never had it, are able to develop remarkable dexterity with their legs and feet, but that doesn't come naturally.

Most of the muscles of the lower leg are the flexors and extensors of the foot and their tendinous insertions are on



the bones of the foot. As in the hand there are retinaculae, tissues which serve as braces to hold the tendons in place as they curve from leg to foot. Some of these muscles facilitate toe movement, others contribute to foot movement. There are two little muscles that assist in knee movement. We'll start with them.

• • •

*Tibia* is Latin meaning pipe or flute; the Romans made their first pipes of bone. *Fibula* is Latin for a clasp or a pin used for fastening garments. *Malleolus* is the diminutive of *malleus*, Latin for hammer.



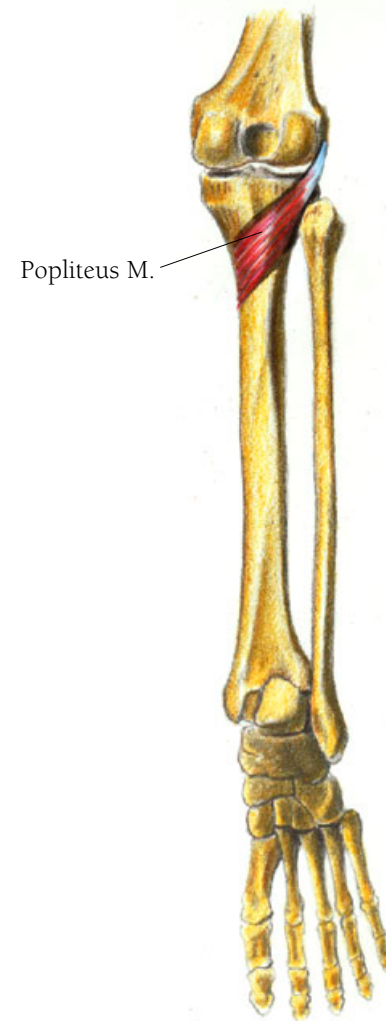
## Leg and Foot Illustration 124

### THE POPLITEUS MUSCLE

The popliteus muscle causes medial rotation of either the femur or the tibia. It also unlocks the knee joint when the leg is fully extended and beginning to bend and furthermore aids in keeping the femur from pushing forward when you crouch. This muscle arises as a tendon from the lateral condyle and the capsule of the knee joint of the femur. It descends across the joint medially and broadens as a short, flat, triangular muscle to insert on the medial side of the tibia just below the medial condyle and above the soleal line.

• • •

Popliteus comes from the Latin *poples*, meaning ham.



## Leg and Foot Illustration 125

### THE PLANTARIS MUSCLE

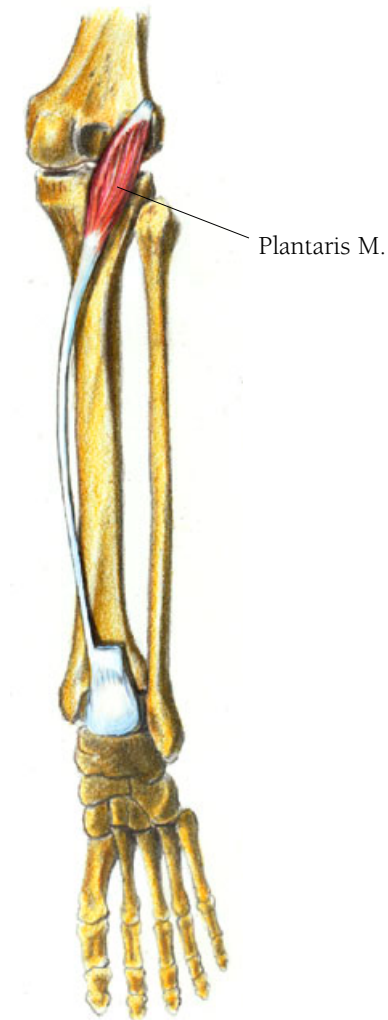The plantaris muscle which helps to flex of the ankle and the knee, lies between the soleus and gastrocnemius muscles which I shall soon discuss. It arises as a small tendon from the lateral epicondyle of the femur and the lower part of the end of the lateral condylar line and as it descends obliquely and laterally almost over the popliteus muscle, it forms a small fusiform muscle that covers the joint. It then becomes a small round tendon which passes obliquely between the soleus and gastrocnemius muscles to go alongside of and merge with the tendo calcaneus—or the achilles tendon.

• • •

*Plantaris* is Latin, meaning “the sole of the foot.”

This muscle is the equivalent of the palmaris longus in the arm/hand, and in other animals its equivalent continues to merge with the plantar fascia of the sole of the foot. It seems to have a more important role in the anatomy of these animals.

Because human specimens were hard to obtain in ancient times anatomical studies were often done on animals. When

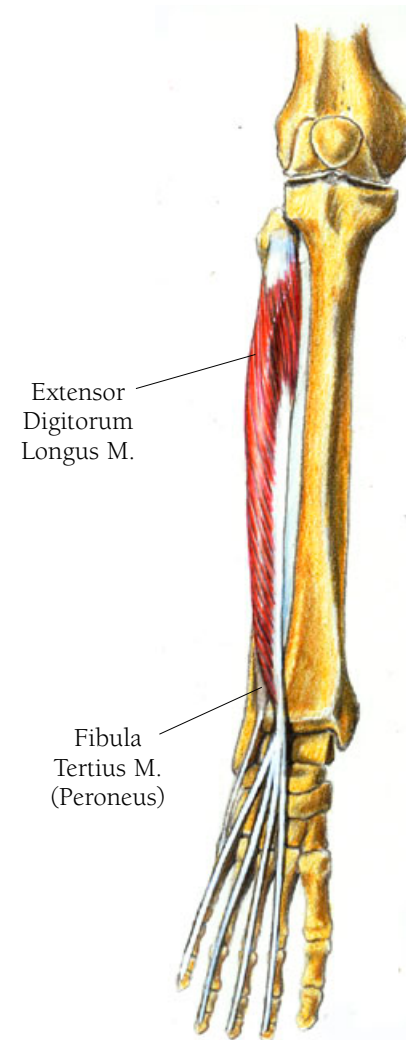


studying anatomy the ancients found that there were many equivalents between animals and humans in bone and muscle structures, and their understanding of these structures and the naming of them was often based on their animal studies.

## Leg and Foot Illustration 126

### THE EXTENSOR DIGITORUM LONGUS MUSCLE

When you bend your toes and foot up, the extensor digitorum is at work. In fact you can feel it tense up along the outer front side of your lower leg as you lift your foot and toes. It works in conjunction with the extensor digitorum brevis, which I will discuss in the section on the foot, as well as with the peroneus tertius and the flexor hallucis longus muscles. This muscle has a very complicated area of origin since it arises on both the tibia and the fibula as well as on the interosseous membrane that joins these two bones. At its most superior aspect, fibers arise from the lateral condyle of the tibia and cross over to the fibula, where they run down the medial side of the bone for almost three quarters of its length. These fibers then feed into a tendon, like the feathers on one side of a quill. As in the wrist, there are two retinaculi, which serve to hold in place the various tendons that travel from the leg to the foot. All of the tendons which run from the muscles of the lower leg to insert on the foot are encased in synovial sheaths at the level of the ankle. I have not shown them because they would obscure the connection of the muscles with their insertions. The tendon of the extensor digitorum longus passes under the superior extensor retinaculum, becomes encased in its synovial sheath and



then divides into four tendons which emerge from their sheaths at the ankle, just beyond the inferior extensor retinaculum. From here the four tendons course over the dorsal aspect of the foot, covering the second, third, fourth and fifth metatarsal bones and end in insertions on the top of the medial tarsal bones and further on to the distal tarsal bones of each toe. (The first or big toe has its own muscle-tendon system just as the thumb does.)

#### THE FIBULA TERTIUS MUSCLE

The fibula tertius muscle assists the extensor digitorum longus in lifting or bending the foot upwards as well as in lifting the outside of the foot and helping the foot clear the ground when walking. Its muscular end is a part of the extensor digitorum and it continues down the fibula on the medial surface to its most distal portion where it forms a tendon. This tendon is bound by the superior extensor retinaculum and shares with it the same synovial sheath. The tendon takes a slightly lateral course to insert on the dorsal (top) side of the base of the fifth metatarsal bone.

• • •

This muscle used to be called the peroneus which comes from the Greek word *perone* meaning “small and pointed like a clasp.” It refers to the fibula, which, as you saw in the discussion of the bones, is what fibula meant in Latin.

Greeks wore toga-like garments which the Romans emulated, and the clasp which held them in place resembled the fibula, or, more accurately, the fibula resembled the clasp. *Tertius* is Latin for third. (There are two other Peroneus muscles, a longus and brevis, discussed below).

## Leg and Foot Illustration 127

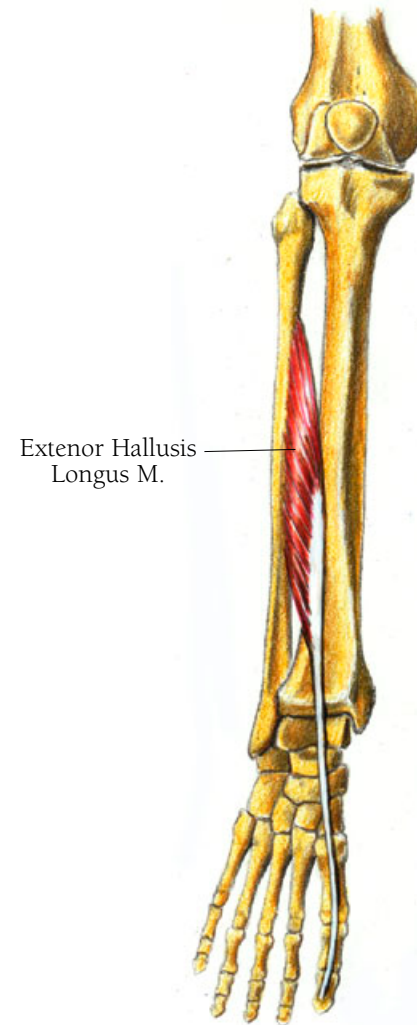
### THE EXTENSOR HALLUCIS LONGUS MUSCLE

This muscle lifts the big toe and helps to lift the whole foot by flexing the ankle. When you bend your big toe up or lift your foot up without moving your leg you can feel this muscle tighten in the mid lower leg, right beside the shinbone.

This muscle arises along a thin line which runs down the medial/anterior side of the fibula beginning a little below the head of the fibula and ending just above the malleolus (ankle bone). Its fibers course obliquely downward to attach to a tendon which continues downward, going beneath the superior extensor retinaculum, through the inferior extensor retinaculum, and over the first metatarsal and the proximal phalanx to insert at the superior base of the distal phalanx.

• • •

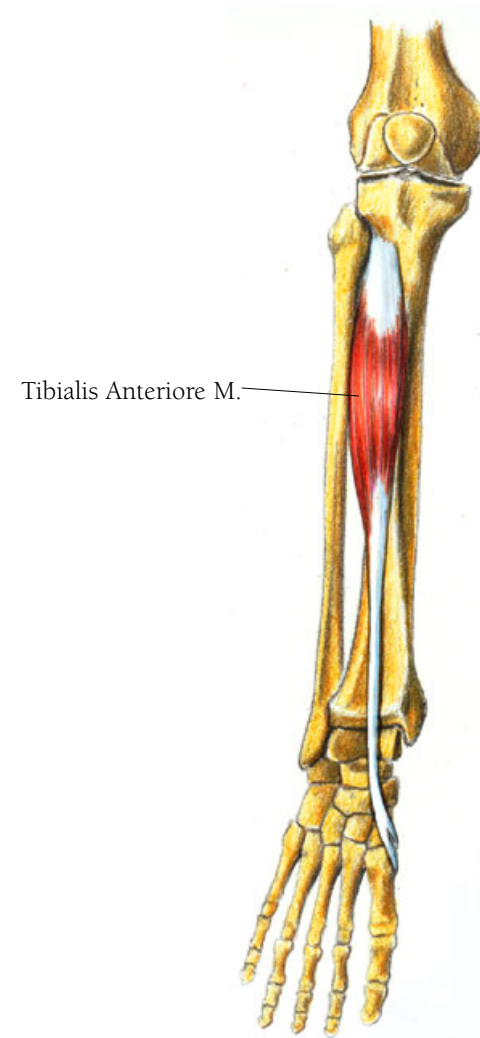
Hallucis comes from the Latin word *hallex* meaning “the big toe, the great toe.”



## Leg and Foot Illustration 128

### THE TIBIALIS ANTERIORE MUSCLE

This muscle is a dorsiflexor of the foot, meaning that it helps to lift and invert the foot or, turn the sole of the foot medially. While it seems to have no role in standing, it does play a role in walking and running by helping to lift the toes off the ground. It plays a similar and opposite role to the peroneus tertius which, as mentioned above, turns the foot outward. It arises on the tibia, just beneath the lateral condyle and from an area that runs about one half to two thirds the way down the shaft of the tibia on its lateral aspect. Its fibers course downwards to form a round tendon which passes under the two extensor retinaculi. The tendon then passes over the tarsal bones to the inner side of the foot where it splits. One slip (tendinous fascia) passes around and under the first cuneiform bone to insert on its base. The other curls around and under the first metatarsal to insert on the lower base of that bone.



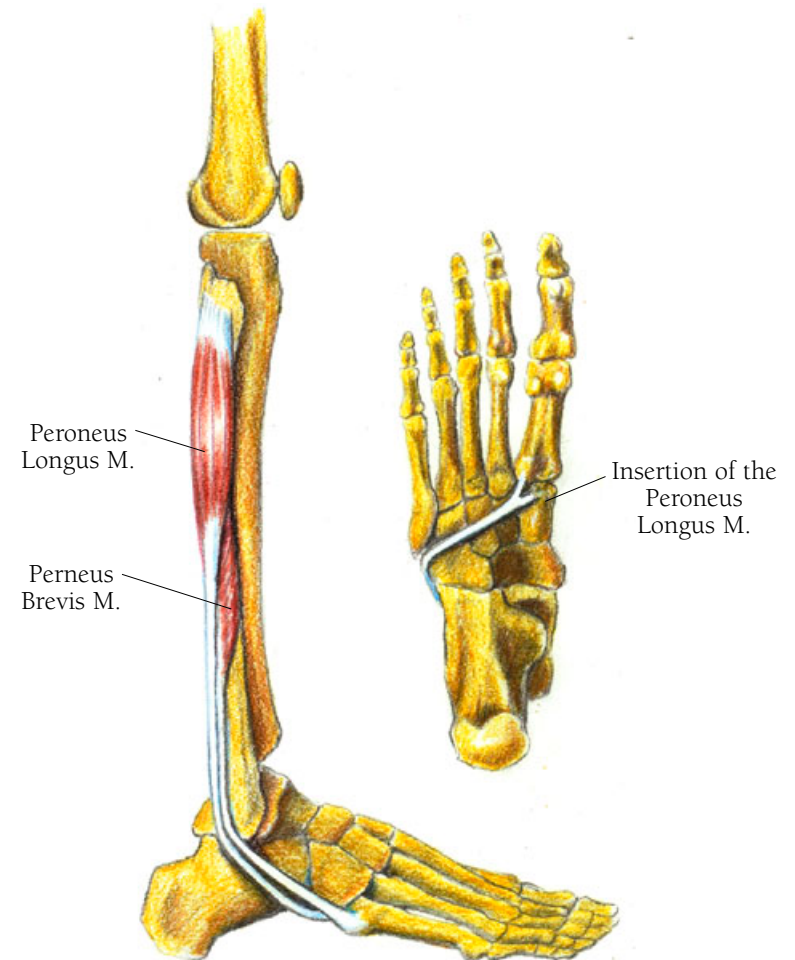
## Leg and Foot Illustration 129

### THE PERONEUS (FIBULA) BREVIS MUSCLE

The peroneus brevis muscle is a stabilizer which acts to restrict the foot's inversion (turning the sole of the foot) thus easing the strain on the ligaments of the tibialis anterior muscle. It helps to steady you when you stand. I will discuss its other actions when I address the longus muscle, coming up next. It arises along the lower two thirds of the fibula's lateral shaft and runs under and along side the lower tendon of the fibula longus. It then descends to merge into a tendon which passes just behind the lateral of the fibula malleolus (the ankle bone) and inserts on the lateral base of the fifth metatarsal bone.

### THE PERONEUS (FIBULA) LONGUS MUSCLE

This muscle, along with the peroneus brevis, everts the foot (lifting the outside edge of the foot). It is also a natural arch supporter. Both muscles are active when you tip toe and lift your foot, and work with the fibula tertius when you walk. The more superficial of the two muscles, the longus, arises along the upper two thirds of the lateral shaft starting at the head of the fibula. Its fibers course downward to merge into a tendon about midway down the shaft of the fibula and lies



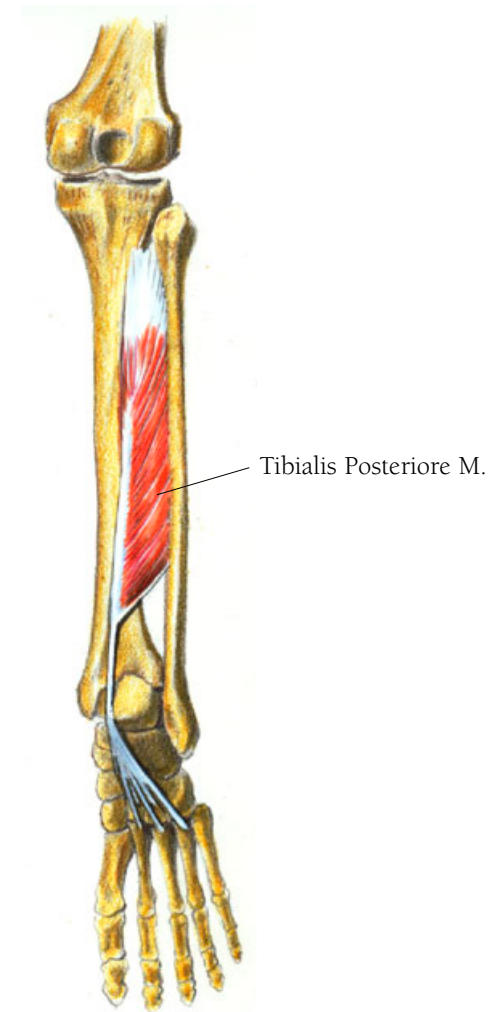


just posterior to the tendon of the brevis. Both the longus and the brevis tendons share a synovial sheath that curves around the lateral malleolus of the fibula (the outside ankle bone) and they both course forward, that of the brevis attaching to the fifth metatarsal and the longus tendon passing under the foot just behind that metatarsal bone. The longus tendon then crosses all the other metatarsals to split and insert on the inferior bases of the first metatarsal and the first cuneiform bone.

## Leg and Foot Illustration 130

### THE TIBIALIS POSTERIORE MUSCLE

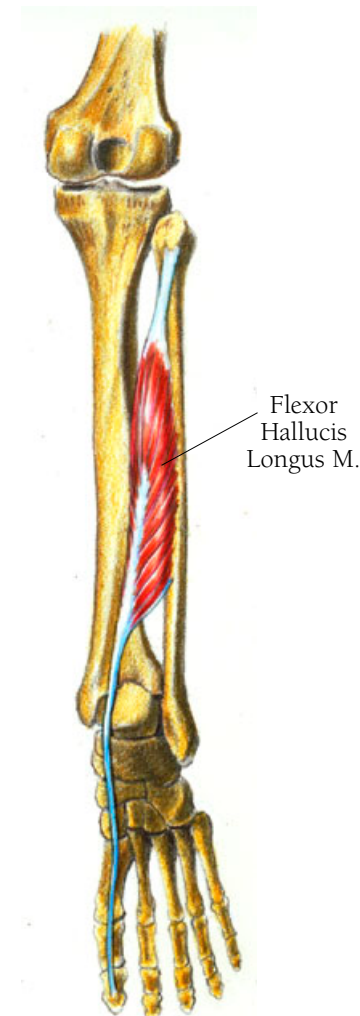
The tibialis posteriore muscle, the deepest in the posterior group is a major flexor of the foot helping the sole of the foot to bend back. It also may participate somewhat in supporting the arch as well as in maintaining your balance when you walk and stand, keeping you from swaying. Since its origin and insertion are both complex the illustration should be particularly helpful here. It arises along the upper two thirds of the fibula's shaft on the side facing the tibia, and along more than half of the tibia's shaft, the side facing the tibia. The muscle fibers feed into a tendon from either side. The tendon then courses around the medial malleolus (the inner ankle bone) and along side, then beneath the calcaneus (heel bone) and tarsals to divide into many slips. The upper tendinous division inserts on the tuberosity of the navicular bone, while slips of the lower tendon insert on the intermediate cuneiform bone and the inferior bases of the first, second, third and fourth metatarsal bones.



## Leg and Foot Illustration 131

### THE FLEXOR HALLUCIS LONGUS MUSCLE

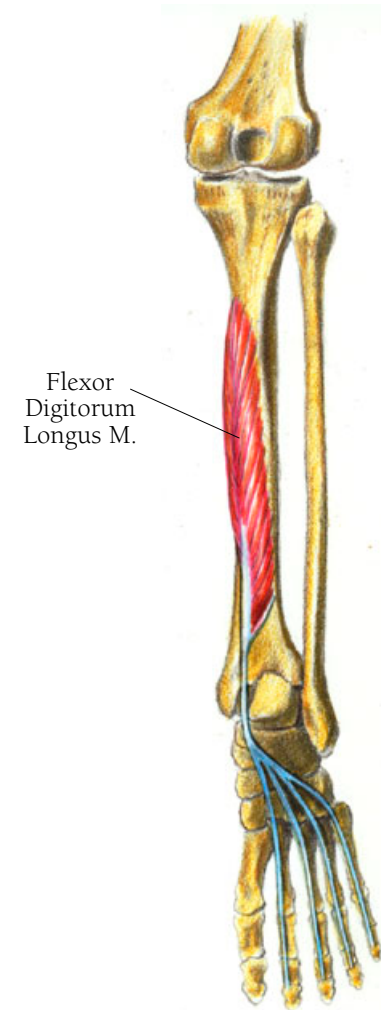
Try bending your big toe down without bending all the others. It's almost impossible. I shall discuss the action of this muscle with that of the next one, the flexor digitorum longus, because they work almost entirely together. The flexor hallucis longus muscle arises along the shaft of the fibula, beginning a little below the head of the fibula, and its fibers, like those of the tibialis posteriore, feed into a tendon. This tendon travels downward and slightly medially into a groove behind the medial malleolus, and then in a groove behind the talus, and finally in another groove on the medial side of the calcaneus, where it begins its path on the plantar side (bottom) of the foot. On the plantar base of the first metatarsal are two sesmoid bones, one on either side. The tendon passes between them to insert at the plantar base of the first distal phalanx.



## Leg and Foot Illustration 132

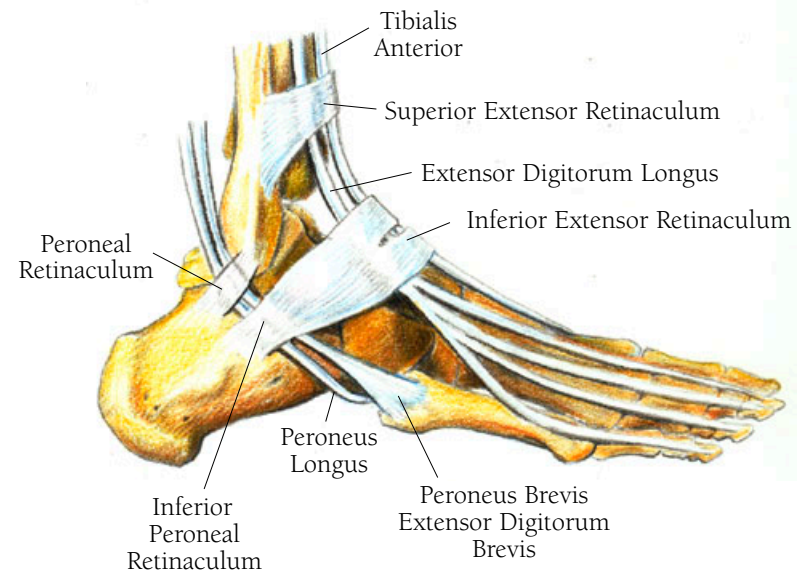
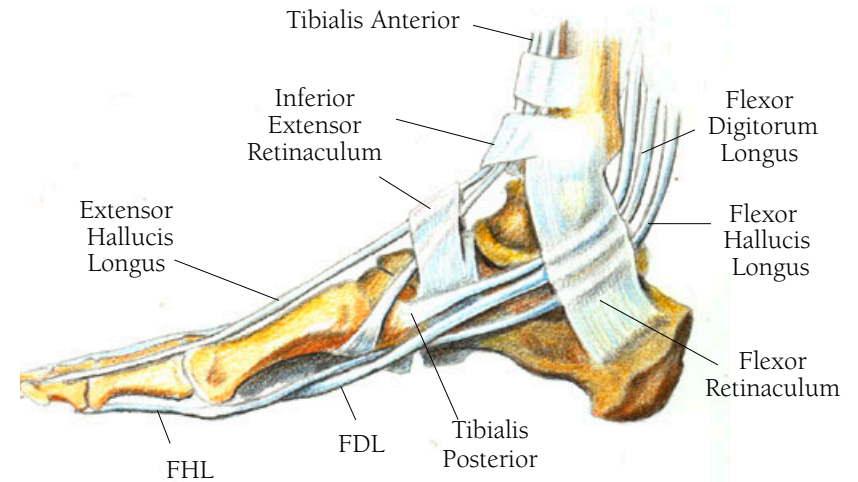
### THE FLEXOR DIGITORUM LONGUS MUSCLE

The flexor digitorum longus muscle, along with the flexor hallucis longus, helps bend the foot down and back. When you lift your foot, the two muscles can curl the toes, and when you stand they keep the bottom of your foot in firm contact with the ground by spreading the area of the foot that touches the ground. The flexor digitorum arises along the posterior two thirds of the tibia's shaft. Its fibers feed from both sides into a tendon which runs almost down the entire length of the muscle. The tendon then descends and passes behind the medial malleolus in the same groove as the tibialis posterioe. Each tendon has its own synovial sheath passing under the flexor reticulum at which point the tendon curves forward to course beneath the sole of the foot crossing the tendon of the flexor hallucis longus in its oblique and forward path. It then separates into four tendons each of which goes to insert at the bases of the distal phalanxes of the second, third, fourth, and fifth toes. It sometimes has a small adjoining tendon with the big toe. (The flexor digitorum brevis, which I shall discuss in Illustration 144, has tendons which course over those of the longus and end at the plantar bases of the proximal phalanges. These split and insert onto the bases of the middle phalanges, creating a little passageway for the longus tendons.)



## Leg and Foot Illustration 133

THE MEDIAL AND LATERAL ASPECT OF THE FOOT SHOWING THE TENDINOUS EXTENSIONS OF ALL THE FLEXOR AND EXTENSOR MUSCLES ON THE LOWER LEG WHICH CONTROL THE MOVEMENT OF THE FOOT AND ANKLE, AND THE RETINACULAE WHICH KEEP THEM IN PLACE



The soleus and the gastrocnemius muscle are more superficial and much bigger than the deeper muscles, creating the recognizable shape of the lower leg. Both muscles merge into the the tendo calcaneus, known as the Achilles tendon.

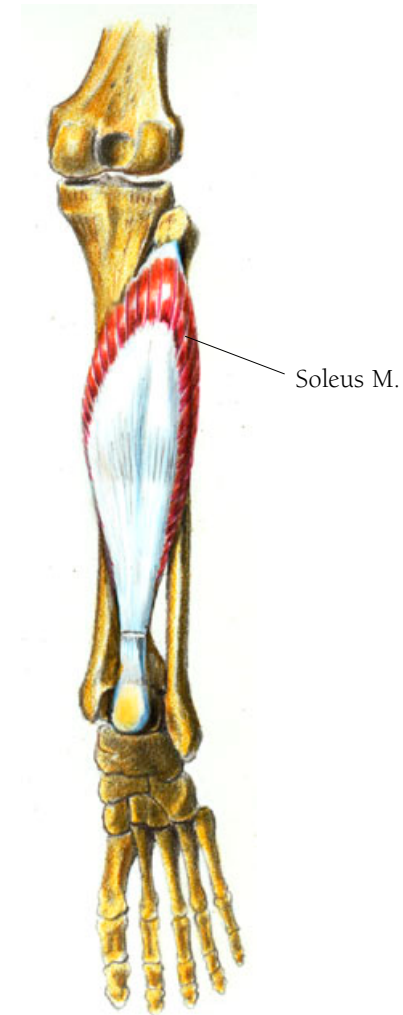
## *Leg and Foot Illustration 134*

### THE SOLEUS MUSCLE

The soleus muscle and the gastrocnemius muscle are plantarflexors, which means they bend the foot back. The soleus acts to hold your leg firmly on your foot when you are standing. It arises from the posterior head of the fibula and down about a quarter of its shaft. Further on it arises from a fibrous band between the two bones and then along the soleal line on the tibia. Its fibers feed into a large tendon feeding in from above and both sides of the tendon. The tendon joins with the Achilles tendon or tendo calcaneus, the tendon for the gastrocnemius muscle lying superficial to the soleus muscle. The tendons join and insert on the calcaneus bone, the heel bone.

• • •

*Soleus* or *solea* is Latin for sole, as in fillet of sole.



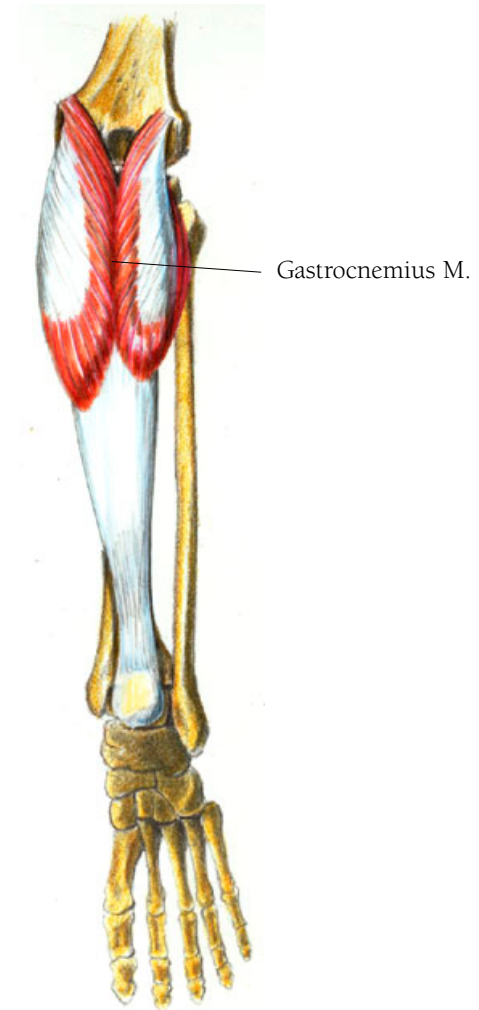
## Leg and Foot Illustration 135

### THE GASTROCNEMIUS MUSCLE

The gastrocnemius muscle is a less powerful plantarflexor than the soleus muscle. It also a knee flexor, helping to bend the knee, and provide propulsion when you walk, run, and jump. It has two parts. The medial head arises as a tendon on the medial condyle of the femur, and the lateral head arises on the lateral condyle of the femur. The muscle forms two bellies that lie side by side and end mid-calf in an aponeurosis which gradually merges to become the Achilles tendon at the place where it merges with the tendon of the soleus.

• • •

*Gastrocnemius* is Latin from the Greek words *gaster* meaning stomach or belly, and *kneme* meaning that part of the leg between knee and ankle.



## THE FOOT

There are similarities between the hand and the foot. Instead of the hand's carpal and metacarpal bones you have tarsal and metatarsal bones in the foot, and, whereas the hand is like an extension of the arm, the foot is at right angles to the leg forming a platform on which you stand.



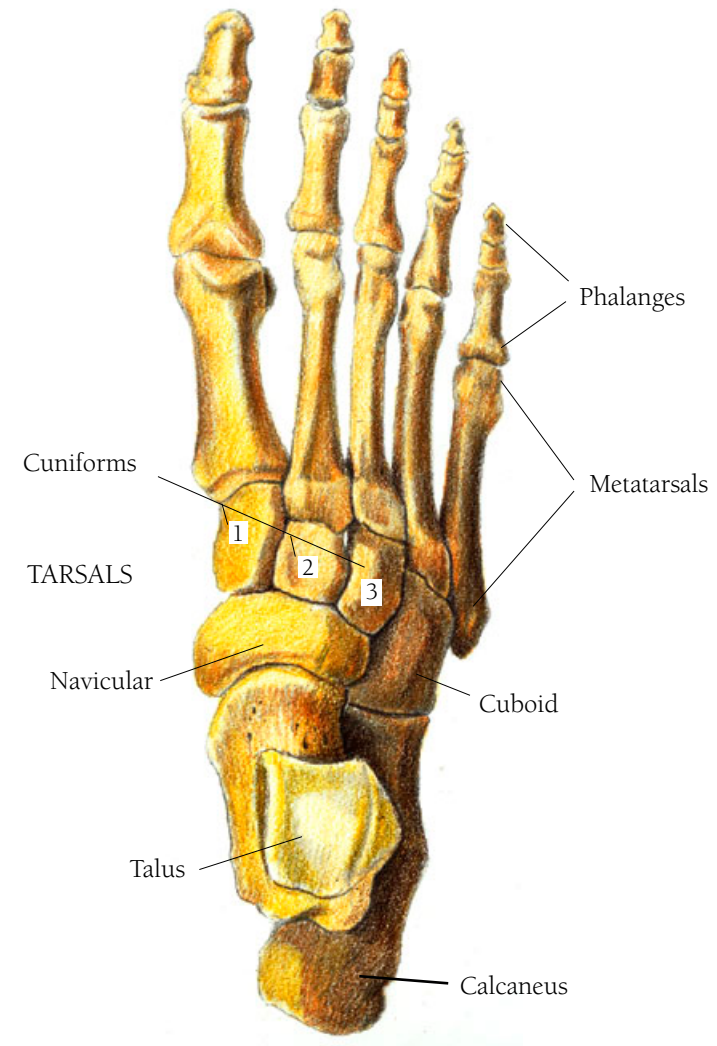
## Leg and Foot Illustration 136

### THE BONES OF THE FOOT, DORSAL VIEW

Going from the heel to the toes, you can see the calcaneus, the talus, the lateral, intermediate and medial cuneiform bones; the navicular; and the cuboid bones. Called the tarsal bones, the bones in this group are the equivalent of the carpal bones of the wrist. They are the bones which make the transition from the leg to the foot. The next five bones make up the body of the foot and are called the metatarsal bones. They are the equivalents of the metacarpals of the hand. The first metatarsal lines up with the big toe, the fifth with the little toe. The final group are called the phalanges as are the equivalent bones in the fingers. The big toe, like the thumb just has only a proximal and distal phalanx as the other toes have a proximal, medial, and distal phalanges.

• • •

Tarsal comes from the Greek *tarsos*, meaning flat surface or “the area of the foot between the toes and the heel.” *Talus* is Latin for heel or ankle bone, and *calcaneus* is Latin for heel bone. Cuneiform is from the Latin *cuneus*, *cunei*, meaning “wedge, becoming wedge shaped.” Navicular comes from Latin *navicularis*, meaning boat shaped. Cuboid comes from the Greek *kyboiedes*, meaning cube shaped.



DORSAL VIEW

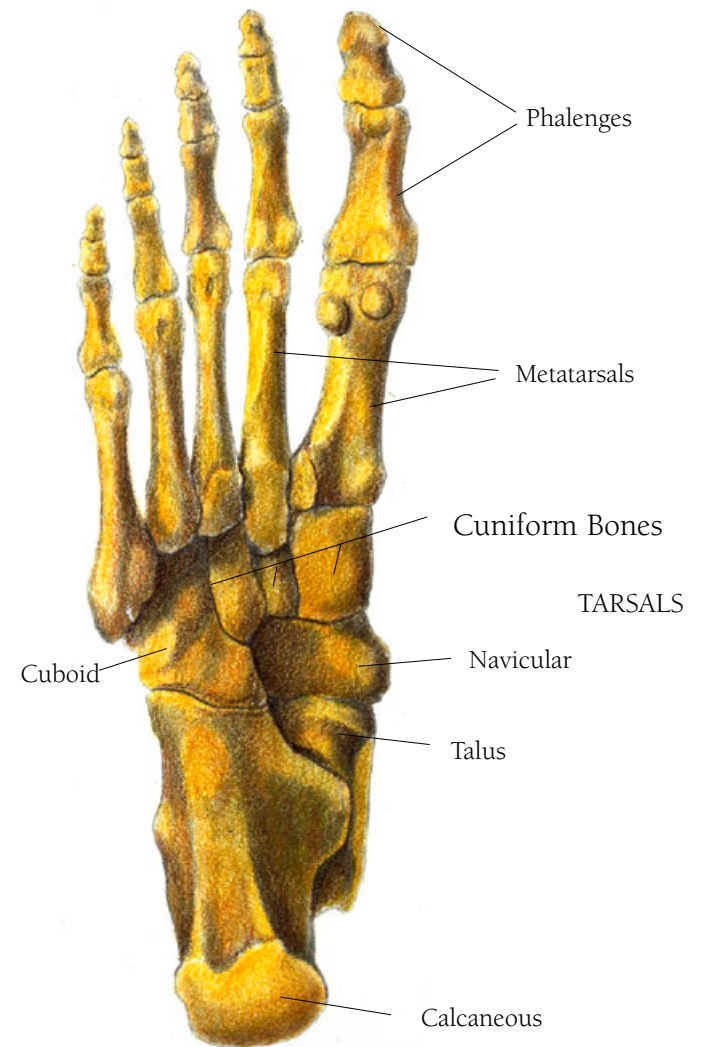
## Leg and Foot Illustration 137

### THE BONES OF THE FOOT, PLANTAR VIEW

Since the foot is not just an extension of the leg but is perpendicular to it, plantar refers to the bottom of the foot and dorsal refers to the top. The back of the foot would be the heel; the front, the toes.

• • •

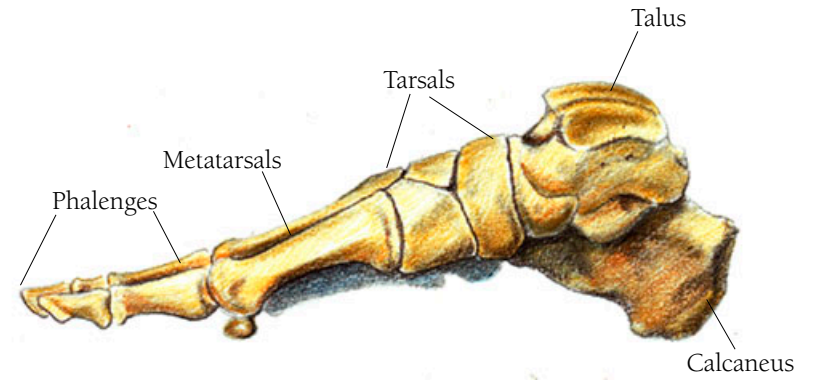
Plantar comes from the Latin *plantaris*, meaning the “sole of the foot.”



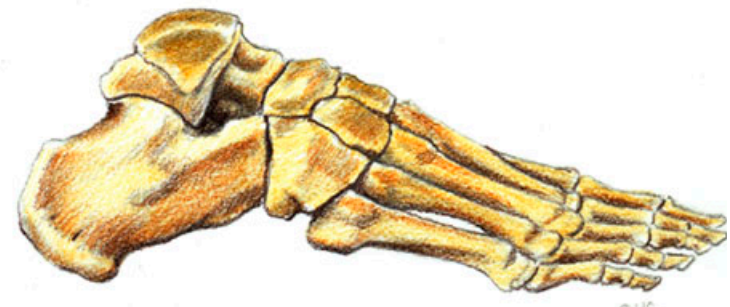PLANTAR VIEW

## Leg and Foot Illustration 138

THE BONES OF THE FOOT, MEDIAL VIEW  
THE BONES OF THE FOOT, LATERAL VIEW



MEDIAL VIEW



LATERAL VIEW

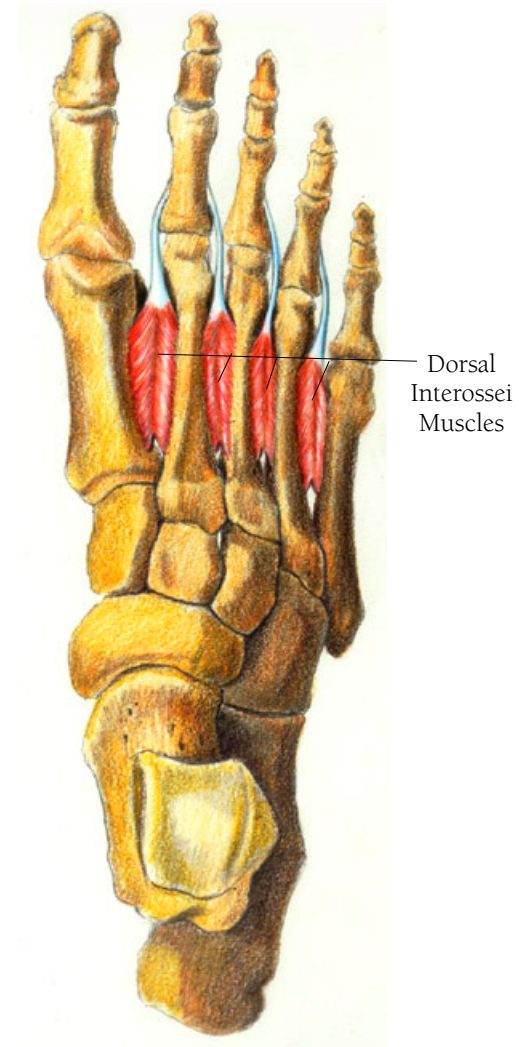
## Leg and Foot Illustration 139

### THE DORSAL INTEROSSEI MUSCLES

Lying between the metatarsal bones, these muscles help to spread the toes, and keep the metatarsals bound together. There are four of them, and they all arise along adjacent shafts of the metatarsals, with the fibers running in and forward to meet in a line and merge near the end of the metatarsal bone to form a tendon. The tendon that comes from between the first and second metatarsals, inserts at the medial base of the second proximal phalanx. The tendon that comes from between the second and third metatarsals, inserts on the lateral base of the second phalanx. The one that comes from between the third and fourth metatarsals inserts on the lateral base of the third proximal phalanx and the one from between the fourth and fifth metatarsals inserts at the lateral base of the fourth proximal phalanx.

• • •

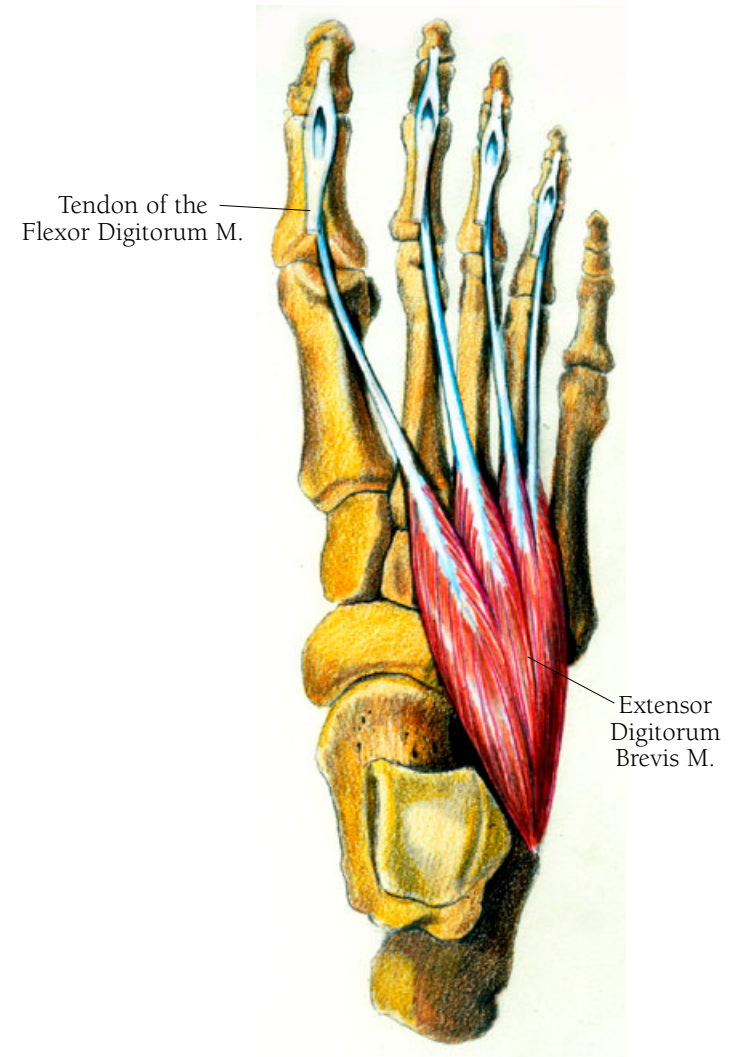
*Interossei* is Latin for “between bones.”



## Leg and Foot Illustration 140

### THE EXTENSOR DIGITORUM BREVIS MUSCLE

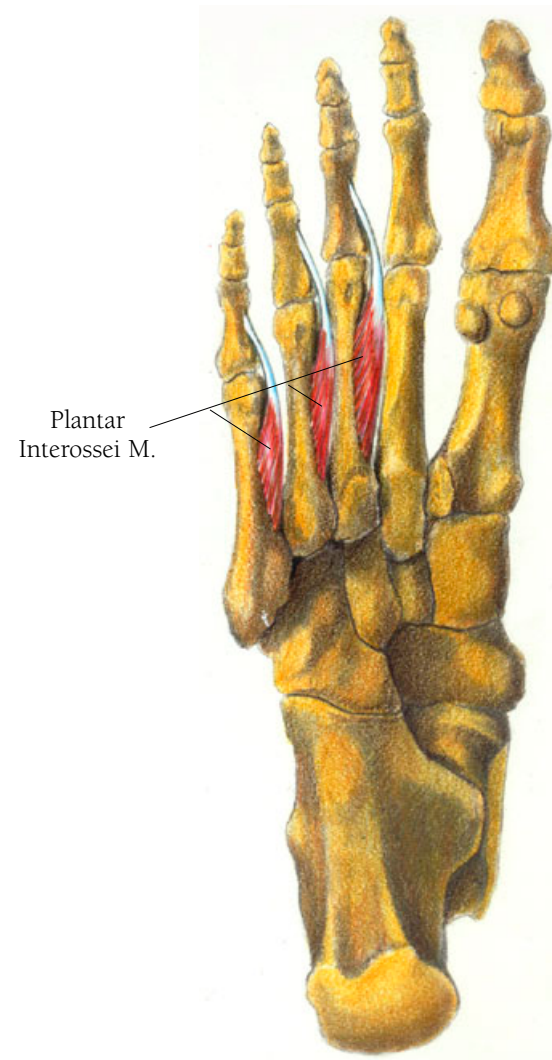
The extensor digitorum brevis muscle flexes (lifts upward) the first four toes (the baby toe does not have an extensor muscle). It arises from the anterior and dorsal surface of the calcaneus bone, and it wraps around and over the top of the foot, covering the lateral dorsal aspect, in an oblique direction towards the toes and then separating into four parts which merge into four tendons. These tendons are roughly the same length as the metatarsals which they cross in order to insert into the bases of the proximal phalanges of the big toe and those of the the next three toes, after joining with the tendons of the extensor digitorum longus muscle.



## *Leg and Foot Illustration 141*

### THE PLANTAR INTEROSSEI MUSCLES

Making up the deepest layer of the plantar muscles, these lie underneath the third, fourth, and fifth metatarsal bones rather than between them and they work together with the interossei muscles to flex or bend the toes downward, including the little toe. They are also toe spreaders. When the phases of walking are analyzed, there is a propulsion phase where the toes bend down to push the foot off the ground. The plantar interossei muscles are part of that action. They arise along the length of the shaft of each metatarsal bone and insert along the sides of the proximal phalanges of the same toe.



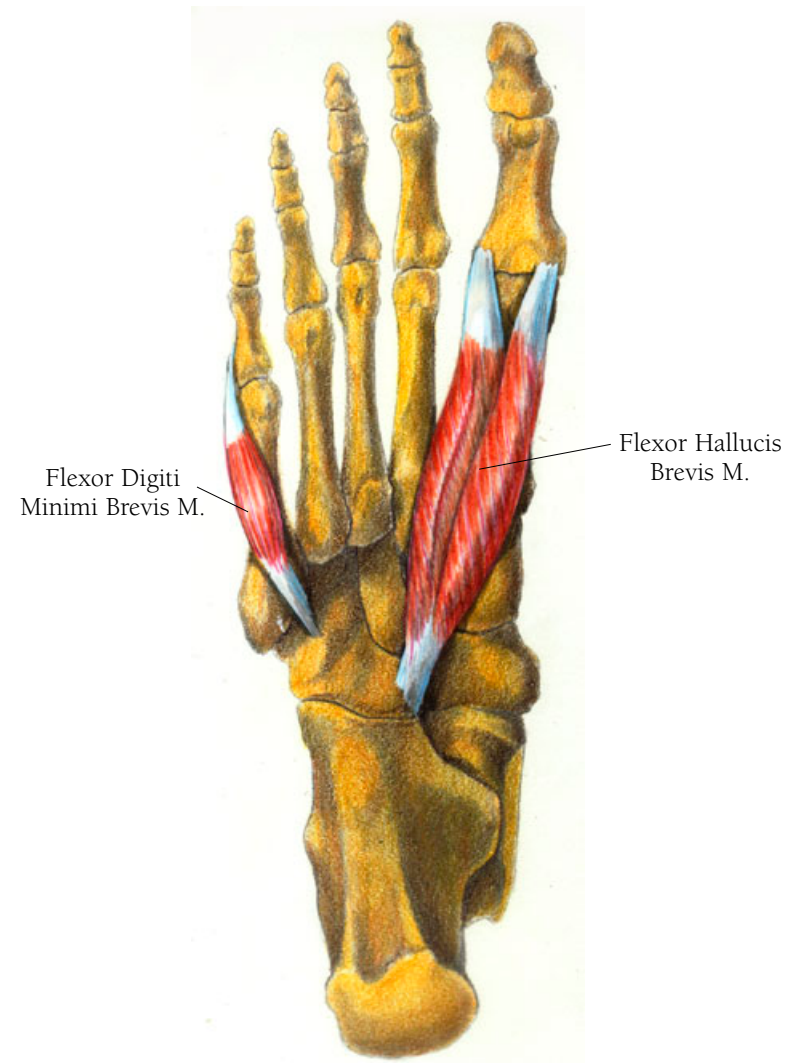
## Leg and Foot Illustration 142

### THE FLEXOR HALLUCIS BREVIS MUSCLE

The flexor hallucis brevis muscle, which bends the big toe, arises as two tendons from the plantar surface of the cuboid bone and the lateral cuneiform bone. It runs forward to insert some fibers around the sesmoid bones at the distal end of the first metatarsal and continues over the joint to insert on each side of the base of the proximal phalanx. The medial head's tendinous fibers join those of the abductor hallucis, and the lateral head's tendinous fibers join those of the adductor hallucis in their insertions, those two muscles to be discussed further on.

### THE FLEXOR DIGITI MINIMI BREVIS MUSCLE

The Flexor digiti minimi brevis muscle bends the little toe downward. It arises on the lateral, plantar surfaces of the cuboid and the fifth metatarsal bone. Its fibers course forward under the fifth metatarsal bone and insert as a tendon on the lateral side of the proximal phalanx. The tendon's fibers blend with those of the abductor digiti minimi muscle which you shall see in the final layer of the plantar foot muscles.

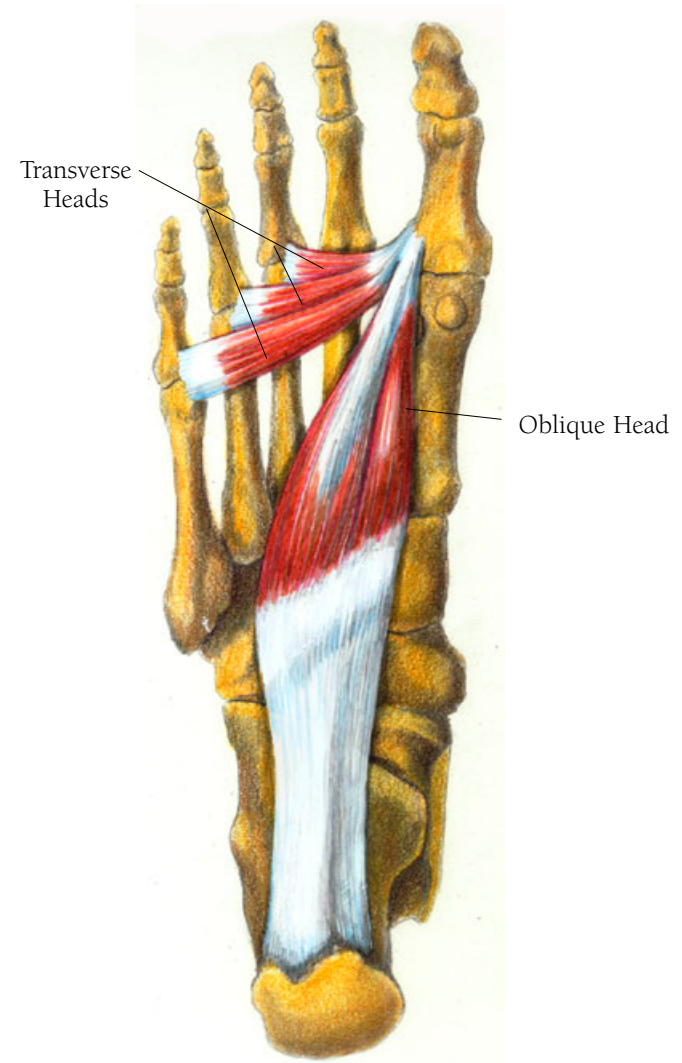


## Leg and Foot Illustration 143

### THE ADDUCTOR HALLUCIS MUSCLE

The adductor hallucis muscle bends the big toe medially—towards the little toe. It plays an important role in walking by aligning the big toe. Without the big toe, walking becomes very difficult. Along with the tibialis posterior, the peroneus longus and the flexor hallucis longus muscles it forms your natural arch support. It works better in some people than others given how many people have flat feet.

It has two parts. The first, called the oblique head, arises from the plantar bases of the second, third, and fourth metatarsal bones and from the sheath covering the tendon of the peroneus longus muscle where it crosses the bottom of the foot. This part of the muscle has medial and lateral parts, but the separation is subtle, not obvious like the flexor hallucis brevis just discussed above. It courses toward the big toe. There its tendon joins the tendon of the other part of this muscle, the transverse head. The transverse head is in three parts, arising from the ligaments that bind the joints between the metatarsals and proximal phalanges of the third, fourth and fifth toes. The muscle's fibers course toward the big toe. They merge into tendons that join with the tendon of the oblique head to insert on at the base of the lateral side of the big toe's





proximal phalanx. The fibers of the tendinous part of the oblique head blend with those of the tendon of the flexor hallucis brevis in their attachments to the lateral sesimoid bone located at the distal end of the first metatarsal bone.

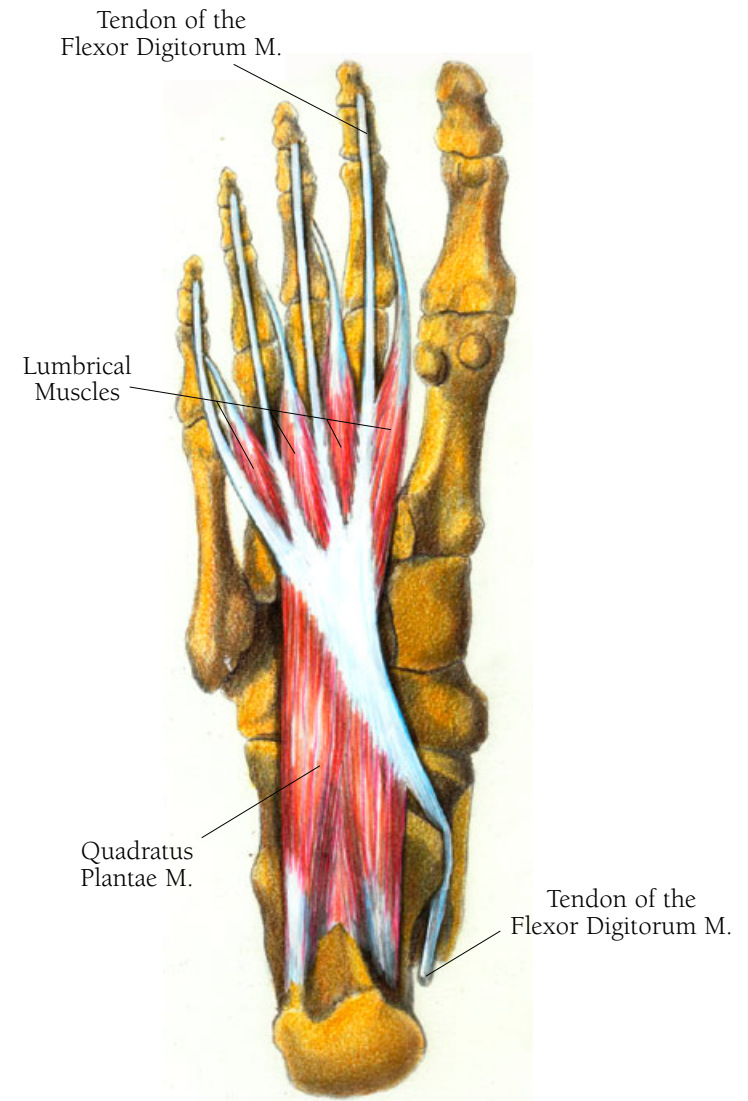
## Leg and Foot Illustration 144

### THE LUMBICALE MUSCLES

The lumbicale muscles of the foot are equivalent to the lumbricales of the hand. These are flexor muscles, which, by pushing the toes off the ground, work with the interossei muscles in the propulsion phase of walking. Arising from the tendons of the flexor digitorum longus muscle, they fill up the spaces between the second, third, and fourth tendons. From the branching of each tendon they reach to the end of the various metacarpals, at which point the muscle fibers become tendons that cross the medial side of the joints between the second, third, fourth, and fifth metacarpals and their proximal phalanges to insert along the sides of those proximal metacarpals. The most medial lumbrical is an exception; there is no tendon medial to it so it arises only on the medial side of the first tendon. The other muscle fibers are bipennate, meeting in the center then merging at the tendon.

### THE QUADRATUS PLANTAE MUSCLE

The action of this muscle is particularly interesting because it modifies the flexor digitorum longus muscle by aligning the



tendons of the latter along the phalanxes of the toes. The flexor digitorum longus muscle's tendons arrive at the bottom of the foot from the medial side, or under the arch, in an oblique direction. The quadratus muscle corrects this slant, so that the tendons of the flexor digitorum are lined up over each of the toes. The quadratus plantae muscle arises as two heads on either side of the calcaneous bone, both of which join and course forward to insert either on the tendon of the flexor digitorum longus or on a layer of fascia which lies just beneath it and sometimes on both. There is a lot of variation in the insertion patterns of this muscle, but all have to do with the main tendon or the separated tendons of the flexor digitorum longus.

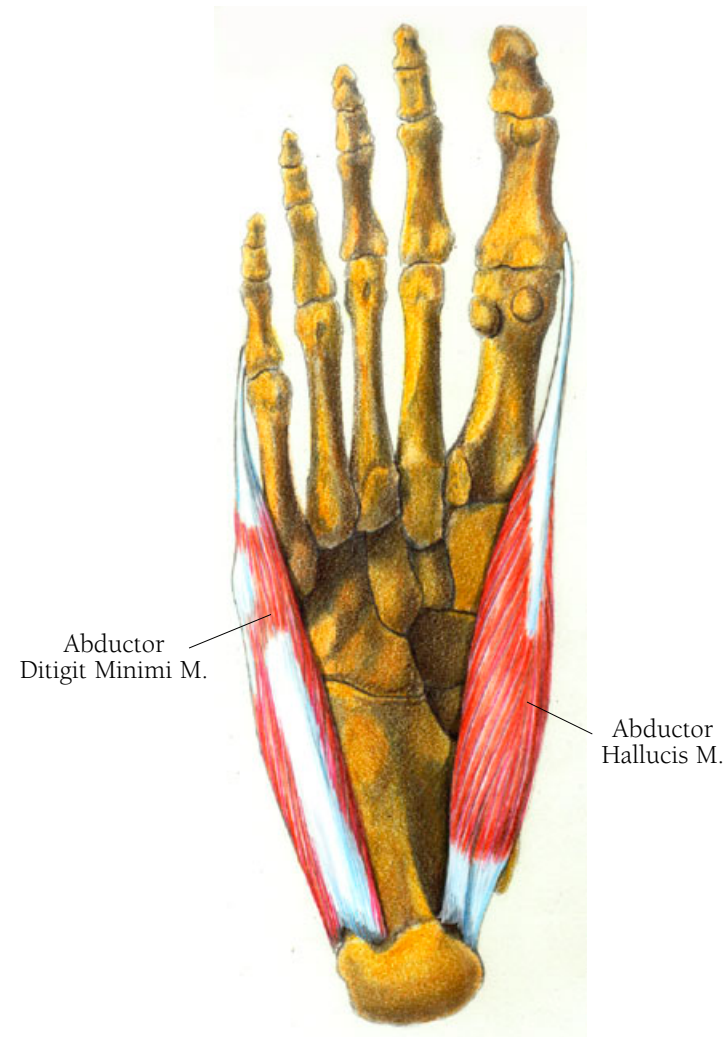
## Leg and Foot Illustration 145

### THE ABDUCTOR HALLUCIS MUSCLE

The abductor hallucis muscle assists in moving the big toe downward and toward its neighboring toes. It arises from the medial side of the calcaneus bone, with a most of its origin coming from the flexor retinaculum. Some fibers come from the plantar aponeurosis as well. Lying alongside the tarsal bones the muscle merges into a tendon which runs along the medial side of the first metatarsal and to insert at the base of the proximal phalanx alongside the tendon of the flexor hallucis brevis.

### THE ABDUCTOR DIGITI MINIMI MUSCLE

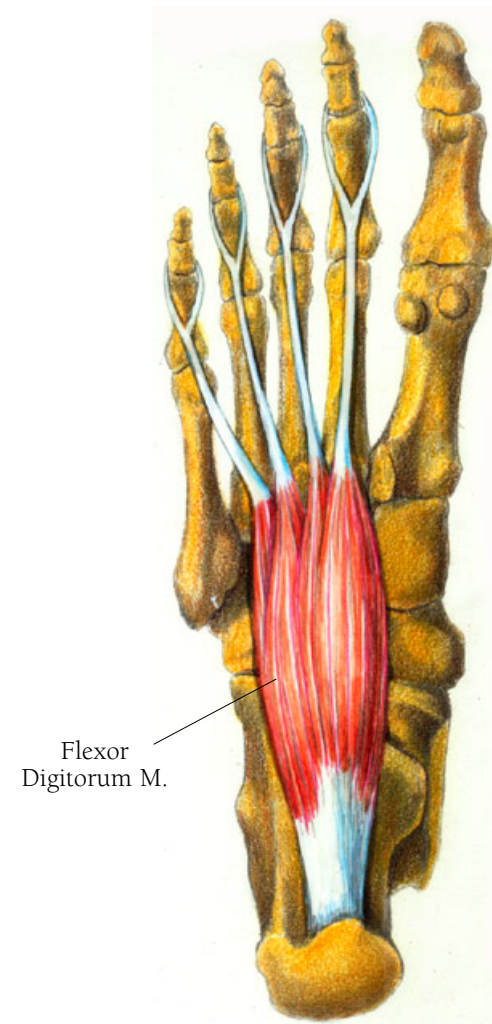
When you spread your toes apart, this muscle is performing. It can also act as a flexor, playing a role in the concerted effort of bending your toes. Arising on the lateral side of the calcaneus bone as well as from the plantar aponeurosis, it lies along the outside of the foot and merges into a tendon about half way along the side of the fifth metatarsal bone. It then crosses the joint between the fifth metatarsal and the proximal phalanx to insert at the lateral base of the proximal phalanx.



## Leg and Foot Illustration 146

### THE FLEXOR DIGITORUM BREVIS MUSCLE

This muscle assists in bending downward all your toes except the big one. It arises on the calcaneus bone, just between the abductor digiti minimi and the abductor hallucis muscles, and, like these two muscles, has fibers attaching to the plantar aponeurosis. Its fibers course forward to cover the bottom of the tarsal bones and merge into the four tendons which run down each of the four metatarsal bones. Each of the four tendons divides at about the mid point of the proximal phalanx to insert at the medial and lateral bases of the middle phalanges. This division, or splitting, provides a tunnel-like passage for the tendons of the digitorum longus to pass through.



A last word on the bottom of the foot: the usual way that the action of a muscle is studied is to place an electrode over it or a needle attached to an electrode into it. The needle/electrode is then attached to a mechanism that registers the electrical activity created when the muscle is at work. It is easy to measure the movements of the foot when it is off the ground. The problem arises when the foot is on the ground or meets the ground as when standing, walking, running or jumping. As a result I found the information about the actions of these muscles more speculative than that of all the other muscles. But this is a book about where muscles are and what happens when they shorten, as seen one by one. When you move, it is almost impossible to tell which muscles are in use. They work in concert directed by our brain without our being aware of the incredible orchestration of events in even one simple gesture.

• • •