



Netter's Surgical Anatomy and Approaches

**Conor P. Delaney, MD, MCh,
PhD, FRCSI, FACS, FASCRS**

Chief, Division of Colorectal Surgery
Vice-Chair, Department of Surgery
Surgical Director, Digestive Health Institute
University Hospitals Case Medical Center
Jeffrey L. Ponsky MD Professor of Surgical Education
Case Western Reserve University School of Medicine
Cleveland, Ohio

Illustrations by

Frank H. Netter, MD

Contributing Illustrators

Carlos A. G. Machado, MD
Kristen Wienandt Marzejon, MS, MFA
James A. Perkins, MS, MFA
John A. Craig, MD

ELSEVIER
SAUNDERS

ELSEVIER
SAUNDERS

1600 John F. Kennedy Blvd.
Ste. 1800
Philadelphia, PA 19103-2899

NETTER'S SURGICAL ANATOMY AND APPROACHES
Copyright © 2014 by Saunders, an imprint of Elsevier Inc.

ISBN: 978-1-4377-0833-2

No part of this publication may be reproduced or transmitted in any form or by any means, electronic or mechanical, including photocopying, recording, or any information storage and retrieval system, without permission in writing from the publisher. Details on how to seek permission, further information about the Publisher's permissions policies and our arrangements with organizations such as the Copyright Clearance Center and the Copyright Licensing Agency can be found at our website: www.elsevier.com/permissions.

This book and the individual contributions contained in it are protected under copyright by the Publisher (other than as may be noted herein).

Permission for Netter Art figures may be sought directly from Elsevier's Health Science Licensing Department in Philadelphia, PA: phone 1-800-523-1649, ext. 3276, or (215) 239-3276; or email H.Licensing@elsevier.com

Notices

Knowledge and best practice in this field are constantly changing. As new research and experience broaden our understanding, changes in research methods, professional practices, or medical treatment may become necessary.

Practitioners and researchers must always rely on their own experience and knowledge in evaluating and using any information, methods, compounds, or experiments described herein. In using such information or methods they should be mindful of their own safety and the safety of others, including parties for whom they have a professional responsibility.

With respect to any drug or pharmaceutical products identified, readers are advised to check the most current information provided (i) on procedures featured or (ii) by the manufacturer of each product to be administered, to verify the recommended dose or formula, the method and duration of administration, and contraindications. It is the responsibility of practitioners, relying on their own experience and knowledge of their patients, to make diagnoses, to determine dosages and the best treatment for each individual patient, and to take all appropriate safety precautions.

To the fullest extent of the law, neither the Publisher nor the authors, contributors, or editors, assume any liability for any injury and/or damage to persons or property as a matter of products liability, negligence or otherwise, or from any use or operation of any methods, products, instructions, or ideas contained in the material herein.

ISBN: 978-1-4377-0833-2

Senior Content Strategist: Elyse O'Grady
Senior Content Development Manager: Marybeth Thiel
Publishing Services Manager: Patricia Tannian
Senior Project Manager: John Casey
Senior Design Manager: Steven Stave

Printed in China

Last digit is the print number: 9 8 7 6 5 4 3 2 1



Working together
to grow libraries in
developing countries

www.elsevier.com • www.bookaid.org

In memory of my father,

Peter Vincent Delaney,

whose love of surgery and its ability to help others led me to this field

About the Artists

Frank H. Netter, MD

Frank H. Netter was born in 1906, in New York City. He studied art at the Art Students' League and the National Academy of Design before entering medical school at New York University, where he received his MD degree in 1931. During his student years, Dr. Netter's notebook sketches attracted the attention of the medical faculty and other physicians, allowing him to augment his income by illustrating articles and textbooks. He continued illustrating as a sideline after establishing a surgical practice in 1933, but he ultimately opted to give up his practice in favor of a full-time commitment to art. After service in the United States Army during World War II, Dr. Netter began his long collaboration with the CIBA Pharmaceutical Company (now Novartis Pharmaceuticals). This 45-year partnership resulted in the production of the extraordinary collection of medical art so familiar to medical professionals worldwide.

In 2005, Elsevier, Inc. purchased the Netter Collection and all publications from Icon Learning Systems. Over 50 publications featuring the art of Dr. Netter are available through Elsevier, Inc. (in the US: www.us.elsevierhealth.com/Netter and outside the US: www.elsevierhealth.com)

Dr. Netter's works are among the finest examples of the use of illustration in the teaching of medical concepts. The 13-book *Netter Collection of Medical Illustrations*, which includes the greater part of the more than 20,000 paintings created by Dr. Netter, became and remains one of the most famous medical works ever published. *The Netter Atlas of Human Anatomy*, first published in 1989, presents the anatomical paintings from the Netter Collection. Now translated into 16 languages, it is the anatomy atlas of choice among medical and health professions students the world over.

The Netter illustrations are appreciated not only for their aesthetic qualities, but, more important, for their intellectual content. As Dr. Netter wrote in 1949, "... clarification of a subject is the aim and goal of illustration. No matter how beautifully painted, how delicately and subtly rendered a subject may be, it is of little value as a *medical illustration* if it does not serve to make clear some medical point." Dr. Netter's planning, conception, point of view, and approach are what inform his paintings and make them so intellectually valuable.

Frank H. Netter, MD, physician and artist, died in 1991.

Learn more about the physician-artist whose work has inspired the Netter Reference collection: <http://www.netterimages.com/artist/netter.htm>

Carlos Machado, MD

Carlos Machado was chosen by Novartis to be Dr. Netter's successor. He continues to be the main artist contributing to the Netter collection of medical illustrations.

Self-taught in medical illustration, cardiologist Carlos Machado has meticulously updated some of Dr. Netter's original plates and has created many original paintings of his own in the style of Netter as an extension of the Netter collection. Dr. Machado's photorealistic expertise and keen insight into the physician-patient relationship informs his vivid and unforgettable visual style. His dedication to researching each topic and subject he paints places him among the premier medical illustrators at work today.

Learn more about his background and see more of his art at: <http://www.netterimages.com/artist/machado.htm>

Preface

The *Atlas of Human Anatomy* by Frank H. Netter, MD, has been the pinnacle of demonstrating the anatomy of the human body for generations of students. To those who would wish to perform or understand surgical procedures, however, there has been no direct link between the beautiful images created by Dr. Netter and the surgical procedures being performed. In *Netter's Surgical Anatomy and Approaches*, we try to address a request by many *Netter* users to tie these anatomical diagrams to the procedures they perform.

This book presents the curriculum of basic and common general surgical procedures in chapters that portray the relevant anatomy for each procedure. In his very first edition, Dr. Netter stated that “anatomy of course does not change, but our understanding of anatomy and its clinical significance does.” Consequently, in some cases we have been able to pair the anatomy demonstrated in his illustrations with a modern intraoperative photograph or radiographic image. For some chapters, a new *Netter*-style illustration has been created to demonstrate a key anatomical point for an operative procedure or to show a key surgical perspective or orientation that is not captured in the original *Netter* images. The result is a volume that covers the most important and commonest areas in surgery, addressing common procedures in the head and neck, endocrine surgery, upper and lower gastrointestinal surgery, hepatobiliary surgery, surgery for hernias, vascular surgery, access and emergency procedures, breast and oncology surgery, and urology and gynecology.

A book like this would not be possible without the help of many people. Being fortunate to work at institutions such as University Hospitals Case Medical Center and Case Western Reserve University, I elected to enlist the support of my faculty colleagues in many different surgical specialties. It is only with the guidance and assistance of the editorial team of Jerry Goldstone, Jeffrey Hardacre, Julian Kim, Pierre Lavertu, Mark Malangoni, Jeffrey Marks, Christopher McHenry, Lee Ponsky, Michael Rosen, Christopher Siegel, and Sharon Stein, and the direction and guidance of the ever-patient Marybeth Thiel at Elsevier that this project has been completed.

On behalf of my co-editors and I, we hope you enjoy *Netter's Surgical Anatomy and Approaches*.

Conor P. Delaney, MD, MCh, PhD

Video Contents

1. Neck Dissection (*Chapter 1*)
2. Tracheotomy (*Chapter 2*)
3. Thyroidectomy and Parathyroidectomy (*Chapter 3*)
4. Gastric Bypass (*Chapter 11*)
5. Laparoscopic Cholecystectomy (*Chapter 12*)
6. Appendectomy (*Chapter 19*)
7. Right Colectomy (*Chapter 21*)
8. Left Colectomy (*Chapter 22*)
9. Low Anterior Resection with Total Mesorectal Excision and Anastomosis (*Chapter 24*)
10. Carotid Endarterectomy (*Chapter 32*)
11. Abdominal Aortic Aneurysm (*Chapter 33*)
12. Oblique Femoral Artery Exposure for EVAR (*Chapter 36*)
13. Posterior Popliteal Artery Exposure (*Chapter 38*)
14. Retroperitoneal Sarcoma (*Chapter 50*)
15. Radical Prostatectomy (*Chapter 54*)

Contributors

EDITOR

Conor P. Delaney, MD, MCh, PhD, FRCSI, FACS, FASCRS

Chief, Division of Colorectal Surgery
Vice-Chair, Department of Surgery
University Hospitals Case Medical Center
Professor of Surgery
Case Western Reserve University School of Medicine
Cleveland, Ohio

SECTION EDITORS

Jerry Goldstone, MD, FACS, FRCSEd

Division Chief Emeritus
Division of Vascular Surgery and Endovascular Therapy
University Hospitals Case Medical Center
Professor of Surgery
Case Western Reserve University School of Medicine
Cleveland, Ohio

Jeffrey M. Hardacre, MD, FACS

Section Head, Pancreatic Surgery
University Hospitals Case Medical Center
Associate Professor of Surgery
Case Western Reserve University School of Medicine
Cleveland, Ohio

Julian A. Kim, MD

Chief, Division of Surgical Oncology
University Hospitals Case Medical Center
Program Director, Case Surgery
Charles Hubay Professor of Surgery
Case Western Reserve University School of Medicine
Cleveland, Ohio

Pierre Lavertu, MD

Director of Head and Neck Surgery
Department of Otolaryngology—Head and Neck Surgery
University Hospitals Case Medical Center
Professor
Case Western Reserve University School of Medicine
Cleveland, Ohio

Mark A. Malangoni, MD, FACS

Associate Executive Director
American Board of Surgery
Adjunct Professor of Surgery
University of Pennsylvania
Philadelphia, Pennsylvania

Jeffrey M. Marks, MD, FACS

Director of Surgical Endoscopy
University Hospitals Case Medical Center
Associate Professor, Department of Surgery
Case Western Reserve University School of Medicine
Cleveland, Ohio

Christopher R. McHenry, MD

Vice Chairman, Department of Surgery
MetroHealth Medical Center
Cleveland, Ohio

Lee E. Ponsky, MD, FACS

Leo and Charlotte Goldberg Chair in Advanced Surgical Therapies
Director, Urologic Oncology and Minimally Invasive Therapies Center
Urology Institute
University Hospitals Case Medical Center
Associate Professor, Urology
Case Western Reserve University School of Medicine
Cleveland, Ohio

Michael J. Rosen, MD, FACS

Professor of Surgery
Chief, Division of GI and General Surgery
Director, Case Comprehensive Hernia Center
University Hospitals Case Medical Center
Associate Professor of Surgery
Case Western Reserve University School of Medicine
Cleveland, Ohio

Christopher T. Siegel, MD, PhD

Associate Professor of Surgery
Division of Transplant and Hepatobiliary Surgery
University Hospitals Case Medical Center
Cleveland, Ohio

Sharon L. Stein, MD, FACS

Associate Program Director, General Surgery
Surgical Director, Inflammatory Bowel Disease Center,
Digestive Health Institute
University Hospitals Case Medical Center
Assistant Professor of Surgery
Division of Colorectal Surgery
Case Western Reserve University School of Medicine
Cleveland, Ohio

CONTRIBUTORS

Mujjahid Abbas, MD

Staff Surgeon
Louis Stokes Cleveland Veterans Administration Medical
Center
Cleveland, Ohio

Robert Abouassaly, MD, MSc

Assistant Professor
Urology Institute
University Hospitals Case Medical Center
Cleveland, Ohio

Matthew T. Allemang, MD

Department of Surgery
University Hospitals Case Medical Center
Cleveland, Ohio

Henry R. Baele, MD

Assistant Professor of Surgery
Department of Surgery, Division of Vascular Surgery
University Hospitals Case Medical Center
Cleveland, Ohio

Jeffrey A. Blatnik, MD

General Surgery Resident
Allen Research Scholar
University Hospitals Case Medical Center
Cleveland, Ohio

Joshua I. S. Bleier, MD

Assistant Professor of Surgery
Division of Colon and Rectal Surgery
Hospital of the University of Pennsylvania
Philadelphia, Pennsylvania

Walter S. Cha, MD, FACS

Cleveland Clinic General Surgery
Digestive Disease Institute
Cleveland, Ohio

Bradley J. Champagne, MD

Associate Professor
Case Western Reserve University School of Medicine
Cleveland, Ohio

Edward Cherullo, MD

Vice Chairman, Clinical Operations
Program Director, Urology Institute
University Hospitals Case Medical Center
Associate Professor of Urology
Case Western Reserve University School of Medicine
Cleveland, Ohio

Jeffrey A. Claridge, MD, MS

Associate Professor of Surgery
Division of Trauma, Critical Care, and Burns
MetroHealth Medical Center
Cleveland, Ohio

John J. Como, MD, MPH

Associate Professor of Surgery
Division of Trauma, Critical Care, and Burns
MetroHealth Medical Center
Cleveland, Ohio

Robert L. DeBernardo, MD

Assistant Professor
Division of Gynecologic Oncology
Seidman Cancer Center
Case Western Reserve University School of Medicine
Cleveland, Ohio

Samuel J. DeJoy, DMD, MD

Assistant Professor of Anesthesiology
Case Western Reserve University School of Medicine
MetroHealth Medical Center
Cleveland, Ohio

Thomas J. Edwards, BSc, MBBS, MSc, FRCS

Consultant, Colorectal Surgeon
Taunton Hospitals NHS Trust
Somerset, England

Heidi L. Elliott, MD

Department of Surgery
University Hospitals Case Medical Center
Cleveland, Ohio

Bruce L. Gewertz, MD

Surgeon-in-Chief, H. & S. Nichols Endowed Chair in
Surgery
Chairman, Department of Surgery
Vice President for Interventional Services
Cedars-Sinai Medical Center
Los Angeles, California

Jason F. Hall, MD, MPH

Surgeon, Department of Colon and Rectal Surgery
Lahey Clinic
Burlington, Massachusetts;
Assistant Professor of Surgery
Tufts University School of Medicine
Boston, Massachusetts

Michael D. Holzman, MD, MPH

Associate Professor, Department of Surgery
Vanderbilt University Medical Center
Nashville, Tennessee

Harry A. Hoyen, MD

Associate Professor
Department of Orthopaedic Surgery
Case Western Reserve University
Cleveland, Ohio

Natalie E. Joseph, MD, FACS

Assistant Professor of Surgery
Case Western Reserve University School of Medicine
Division of Surgical Oncology
MetroHealth Medical Center
Cleveland, Ohio

Arielle Kanters, MD

Division of Pediatric Surgery
University Hospitals Case Medical Center
Cleveland, Ohio

Vikram S. Kashyap, MD, FACS

Chief, Division of Vascular Surgery and Endovascular
Therapy
Co-Director, Harrington Heart and Vascular Institute
University Hospitals Case Medical Center
Professor of Surgery
Case Western Reserve University School of Medicine
Cleveland, Ohio

Jonathan E. Kiechle, MD

Resident Physician
Urology Institute
University Hospitals Case Medical Center
Cleveland, Ohio

David M. Krpata, MD

Department of Surgery
University Hospitals Case Medical Center
Cleveland, Ohio

Matthew J. Kruse, MD

Department of Surgery
Cedars-Sinai Medical Center
Los Angeles, California

Jeremy M. Lipman, MD

Assistant Professor of Surgery
Case Western Reserve University School of Medicine
MetroHealth Medical Center
Department of Surgery
Cleveland, Ohio

Yi-Chun Carol Liu, MD

Resident Physician
Ear, Nose, and Throat Institute
University Hospitals Case Medical Center
Cleveland, Ohio

Mark L. Manwaring, MD

Colorectal Surgery
Department of Surgery
East Carolina University
Greenville, North Carolina

Eric L. Marderstein, MD, MPH

Director of Colorectal Surgery Services
Louis Stokes Cleveland VA Medical Center
Assistant Professor of Surgery
Division of Colorectal Surgery
University Hospitals Case Medical Center
Cleveland, Ohio

Evan R. McBeath, MD

Resident Physician
Ear, Nose, and Throat Institute
University Hospitals Case Medical Center
MetroHealth Medical Center
Louis Stokes Cleveland VA Medical Center
Cleveland, Ohio

Amy McDonald, MD, FACS

Assistant Professor of Surgery
Case Western Reserve University School of Medicine
Director, Trauma Intensive Care Unit
MetroHealth Medical Center
Cleveland, Ohio

Husein Moloo, MD, FRCS

Assistant Professor and Interim Chair
Division of General Surgery
University of Ottawa
Interim Chief, Division of General Surgery
Director, Minimally Invasive Surgery Program
The Ottawa Hospital
Ottawa, Ontario, Canada

Yuri W. Novitsky, MD

Co-Director, Case Comprehensive Hernia Center
Director, Surgical Research
Department of Surgery
University Hospitals Case Medical Center
Associate Professor of Surgery
Case Western Reserve University School of Medicine
Cleveland, Ohio

Raymond Onders, MD

Professor of Surgery
Director of Minimally Invasive Surgery
Margaret and Walter Remen Chair of Surgical
Innovation
University Hospitals Case Medical Center
Cleveland, Ohio

Melissa S. Phillips, MD

Assistant Professor
Department of Surgery
University of Tennessee Graduate School of Medicine
Knoxville, Tennessee

Gilles Pinault, MD, FACS

Department of Vascular Surgery
Case Western Reserve University School of Medicine
Louis Stokes Cleveland VA Medical Center
Cleveland, Ohio

Todd Ponsky, MD

Associate Professor of Surgery and Pediatrics
Division of Pediatric Surgery
Akron Children's Hospital
Akron, Ohio

Benjamin K. Poulose, MD, MPH

Assistant Professor, Department of Surgery
Vanderbilt University Medical Center
Nashville, Tennessee

Kimberly Resnick, MD

Assistant Professor, Division of Gynecologic Oncology
Department of Obstetrics and Gynecology
University Hospitals Case Medical Center
Cleveland, Ohio

Harry L. Reynolds, Jr., MD, FACS, FASCRS

Director, Section of Colon and Rectal Cancer Surgery
Division of Colon and Rectal Surgery
University Hospitals Case Medical Center
Associate Professor of Surgery
Case Western Reserve University School of Medicine
Cleveland, Ohio

Rod Rezaee, MD, FACS

Assistant Professor
Director, Microvascular Head and Neck Reconstructive
Surgery
Department of Otolaryngology—Head and Neck Surgery
University Hospitals Case Medical Center
Cleveland, Ohio

Alan A. Saber, MD, MS, FACS, FASMBS

Chief of Minimally Invasive Surgery
Medical Director of Bariatric and Metabolic Surgery
The Brooklyn Hospital Center
The Weill Medical College of Cornell University
The New York Presbyterian Healthcare System
New York, New York

Juan Sanabria, MD, MSc, FRCSC, FACS

Director, Pancreas Transplant Program
University Hospitals Case Medical Center
Assistant Professor of Surgery and Nutrition
Case Western Reserve University School of Medicine
Cleveland, Ohio

Edmund Q. Sanchez, MD

Surgical Director, Liver and Pancreas Transplant
Programs
Division of Transplant and Hepatobiliary Surgery
Department of Surgery
University Hospitals Case Medical Center
Cleveland, Ohio

Victor M. Sandoval, MD

Resident Physician
Department of Surgery
University Hospitals Case Medical Center
Cleveland, Ohio

James Schulak, MD

Director, Transplant Institute
Chief, Division of Transplant and Hepatobiliary Surgery
Department of Surgery
University Hospitals Case Medical Center
Cleveland, Ohio

Charles E. Smith, MD, FRCPC

Professor, Case Western Reserve University School of
Medicine
Director, Cardiothoracic and Trauma Anesthesia
MetroHealth Medical Center
Cleveland, Ohio

Christopher J. Smith, MD

Assistant Professor of Surgery
Division of Vascular Surgery
Case Western Reserve University School of Medicine
MetroHealth Medical Center
Cleveland, Ohio

Lee L. Swanstrom, MD, FACS

Division Chief, GI and Minimally Invasive Surgery
The Oregon Clinic
Clinical Professor of Surgery
Oregon Health and Sciences University
Portland, Oregon

William Tabayoyong, MD, PhD

Urology Institute
University Hospitals Case Medical Center
Cleveland, Ohio

Anthony Visoni, MD

General Surgery Resident
University Hospitals Case Medical Center
Cleveland, Ohio

John C. Wang, MD

Assistant Professor of Surgery
Case Western Reserve University School of Medicine
Division of Vascular Surgery and Endovascular Therapy
University Hospitals Case Medical Center
Cleveland, Ohio

Scott M. Wilhelm, MD, FACS

Associate Professor of Surgery
Department of Surgery
University Hospitals Case Medical Center
Cleveland, Ohio

Virginia Wong, MD, FACS

Assistant Professor of Surgery
Department of Surgery, Division of Vascular Surgery and
Endovascular Therapy
University Hospitals Case Medical Center
Cleveland, Ohio

Kenneth J. Woodside, MD

Director, Living Kidney Donor Program
Division of Transplant and Hepatobiliary Surgery
Department of Surgery
University Hospitals Case Medical Center
Cleveland, Ohio

Jessica Mae Yih, MD

Resident Physician
Urology Institute
University Hospitals Case Medical Center
Cleveland, Ohio

Chad A. Zender, MD, FACS

Assistant Professor
Department of Otolaryngology—Head and Neck Surgery
Case Western Reserve University School of Medicine
Cleveland, Ohio

Selective (Supraomohyoid) Neck Dissection, Levels I-III



Chad A. Zender, Evan McBeath, and Pierre Lavertu

INTRODUCTION

Neck dissection has been a standard method of removing at-risk or involved cancerous lymph nodes in the head and neck for more than 100 years. Crile first described the radical neck dissection in the early 1900s, but modifications by Bocca and others helped reduce the morbidity associated with lymph node removal, allowing for nerve and structure preservation when oncologically sound. This chapter discusses one of these modifications in detail, the *selective* or *supraomohyoid* neck dissection. A selective neck dissection, including levels I through III, is typically used for malignancies of the oral cavity in patients with N0 disease. When a larger nodal burden is present, an extended (levels I-IV) selective neck dissection or a modified radical neck dissection (levels I-V) is indicated. Lesions in the oral cavity that approach or cross the midline require treatment of both sides of the neck.

NECK ANATOMY FOR SURGICAL PLANNING

Understanding the regional lymphatic drainage pathways is critical when planning which type of neck dissection will be employed (Fig. 1-1). A supraomohyoid neck dissection is performed when treating patients who are at risk for micrometastasis in levels I, II, and III. The boundaries of levels I (submental and submandibular), II (upper jugular nodal chain), and III (midjugular nodal chain) are defined as follows:

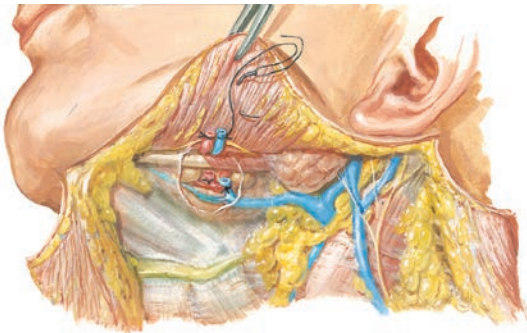
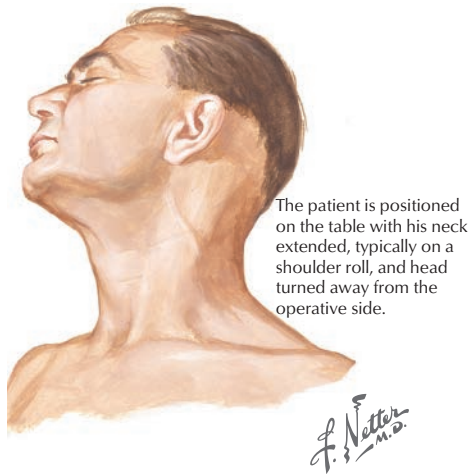
Level Ia: Bounded laterally by the medial aspects of the anterior belly of the digastric muscles, and ending medially at a line drawn from the mandible to the hyoid bone at the anatomic midline.

Level Ib: Bounded by the lateral aspect of the anterior belly of the digastric muscle, the medial aspect of the posterior belly of the digastric and stylohyoid muscles, and the inferior border of the mandibular body superiorly.

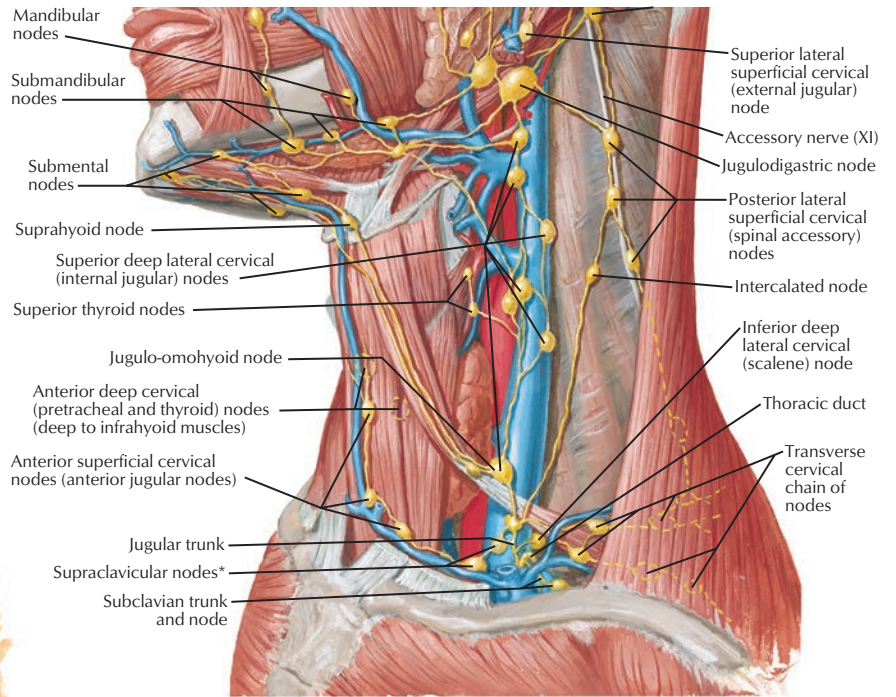
Level IIa: Bounded anteriorly and superiorly by the posterior belly of the digastric and stylohyoid muscles, posteriorly by the vertical plane defined by the spinal accessory nerve and sternocleidomastoid muscle (SCM), and inferiorly by the horizontal plane defined by the inferior border of the hyoid bone.

Level IIb: Bounded anteriorly by the jugular vein and inferiorly by the vertical plane defined by the spinal accessory nerve, posteriorly by the posterior border of the SCM, and superiorly by the skull base.

Level III: Bounded superiorly by the horizontal plane defined by the inferior border of the hyoid bone, inferiorly by the horizontal plane defined by the inferior border of the cricoid cartilage and/or the omohyoid muscle as it crosses the internal jugular vein, anteriorly by the lateral border of the sternohyoid muscle, and posteriorly by the posterior border of the SCM.



Superior flap dissected up along deep surface of anterior facial vein and facial (external maxillary) artery, thus elevating ramus marginalis mandibulae of facial nerve out of operating field. Vessels ligated and distal end of vascular stump sutured to undersurface of flap.



*The supraclavicular group of nodes (also known as the lower deep cervical group), especially on the left, are also sometimes referred to as the signal or sentinel lymph nodes of Virchow or Troisier, especially when sufficiently enlarged and palpable. These nodes (or a single node) are so termed because they may be the first recognized presumptive evidence of malignant disease in the viscera.

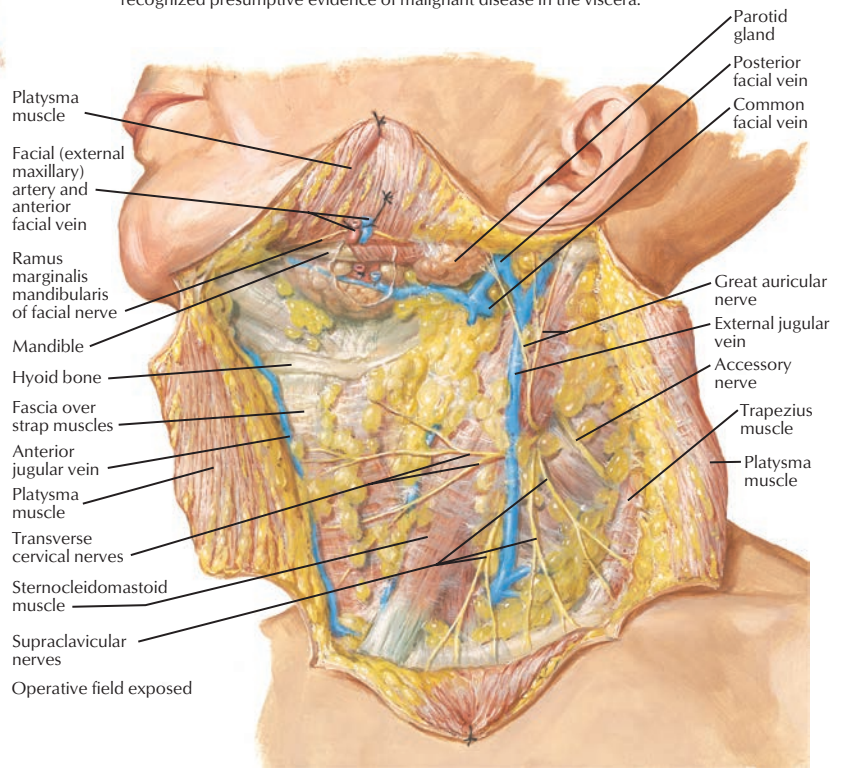


FIGURE 1-1 Patient positioning and anatomy in neck dissection.

INCISION PLANNING AND PATIENT POSITIONING FOR NECK DISSECTION

Positioning for a neck dissection includes extending the neck and turning the patient's head away from the surgeon. This usually entails placing a shoulder roll under the patient to facilitate adequate extension.

Various types of incisions may be employed. The authors typically use a "hockey stick" incision that extends from the mastoid tip down the middle of the SCM and then across the neck in a crease, which is usually over the lowest level that will be surgically treated. The incision can be brought across the midline to the contralateral neck in the same manner, creating an "apron" incision, which will allow access to both sides of the neck when indicated to treat bilateral neck disease.

Raising the Subplatysmal Flap

Skin and subcutaneous incisions are continued down through the subcutaneous fat and platysma muscle, but not through the superficial layer of the deep cervical fascia. A superior subplatysmal flap is then elevated up to the inferior border of the mandible. Care is taken to keep the plane of elevation immediately subplatysmal, to aid in identification and preservation of the marginal mandibular branch of the facial nerve. Laterally, the platysma muscle is not developed, and elevation must proceed over the external jugular vein and great auricular nerve. This allows for complete elevation of the flap (Fig. 1-2).

Inferior elevation is performed in a subplatysmal manner down below where the omohyoid crosses the jugular vein. This allows for complete exposure of level III and for incorporation of level IV if needed. The flap elevation can be extended down to within 5 to 10 mm of the clavicle to aid visualization.

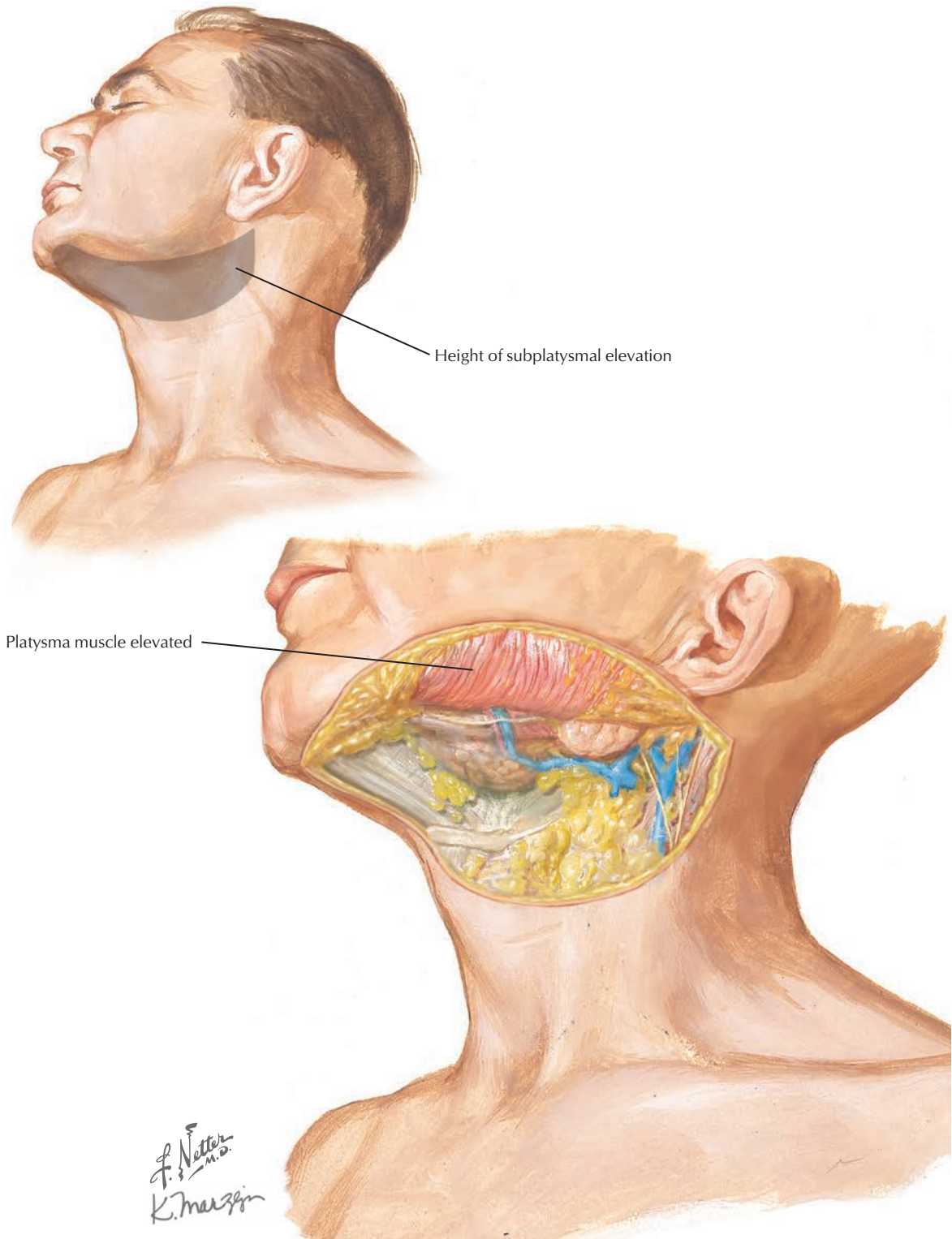


FIGURE 1-2 Flap elevation in neck dissection.

LEVEL IA-IB NECK DISSECTION

After flap elevation, expose the anterior belly of the digastric muscle by making a midline incision from below the mentum to the hyoid bone. It is important to include all the fibrofatty contents from the contralateral medial edge of the digastric muscle. The elevation continues to the medial aspect of the submandibular gland to complete the level Ia dissection (Fig. 1-3).

The marginal mandibular branch of the facial nerve can be located approximately 1 cm inferior to angle of the mandible. Incisions brought across the neck are always two finger-breadths below the angle to prevent inadvertent injury to this nerve. The marginal mandibular branch of the facial nerve lies between the superficial layer of the deep cervical fascia and the adventitia investing the anterior facial vein. The superficial layer of the deep cervical fascia is incised at the inferior border of the submandibular gland. It must be elevated and may be tacked to the platysma muscle to aid in elevation.

Care must be taken to preserve the marginal mandibular branch of the facial nerve and reflect it superiorly, along with the superficial layer of the deep cervical fascia, and to remove any submandibular retrovascular (perifacial) lymph nodes in the area. This is accomplished by developing a plane between the vein and superficial layer of the deep cervical fascia, keeping the fat pad that contains the facial nodes down in the specimen, along with the submandibular gland, and elevating and protecting the nerve.

At this point the anterior belly of the digastric muscle is isolated, and the gland and fibrofatty contents of level Ia are brought posteriorly across the mylohyoid muscle.

Retract the mylohyoid muscle; identify and preserve the lingual and hypoglossal nerves; then identify, ligate, and divide the submandibular duct, submandibular ganglion, and corresponding vasculature. Level I is released and left pedicled by the inferior fibrofatty attachments to levels II and III (Fig. 1-3).

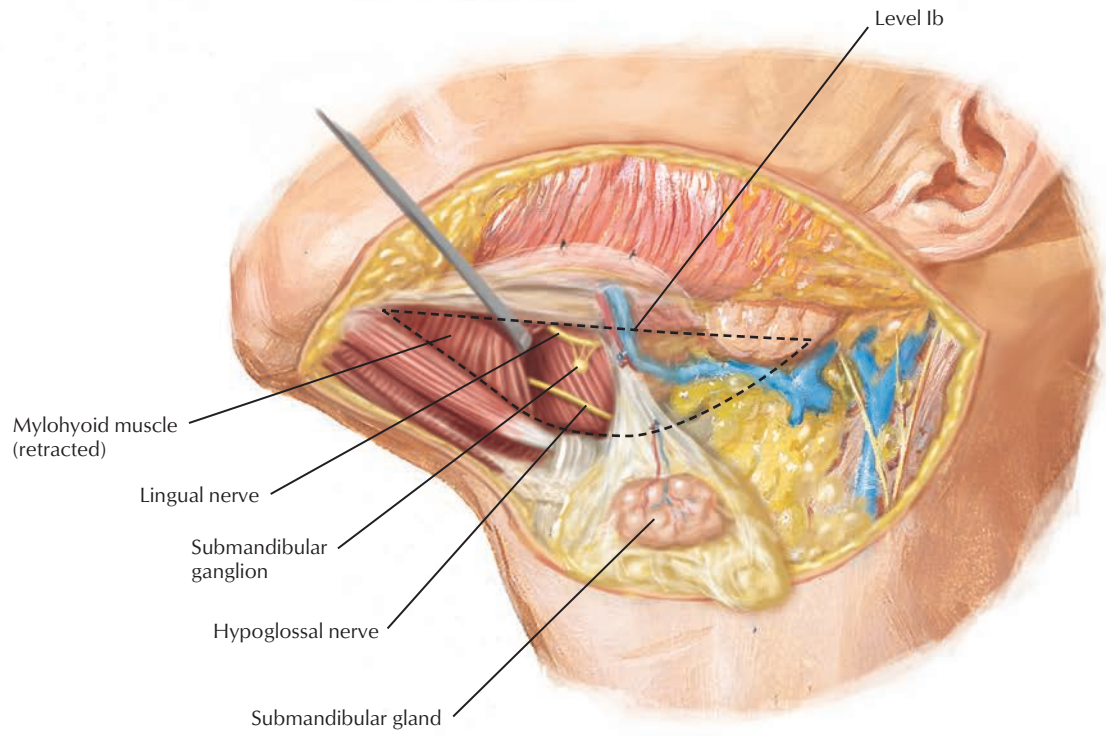
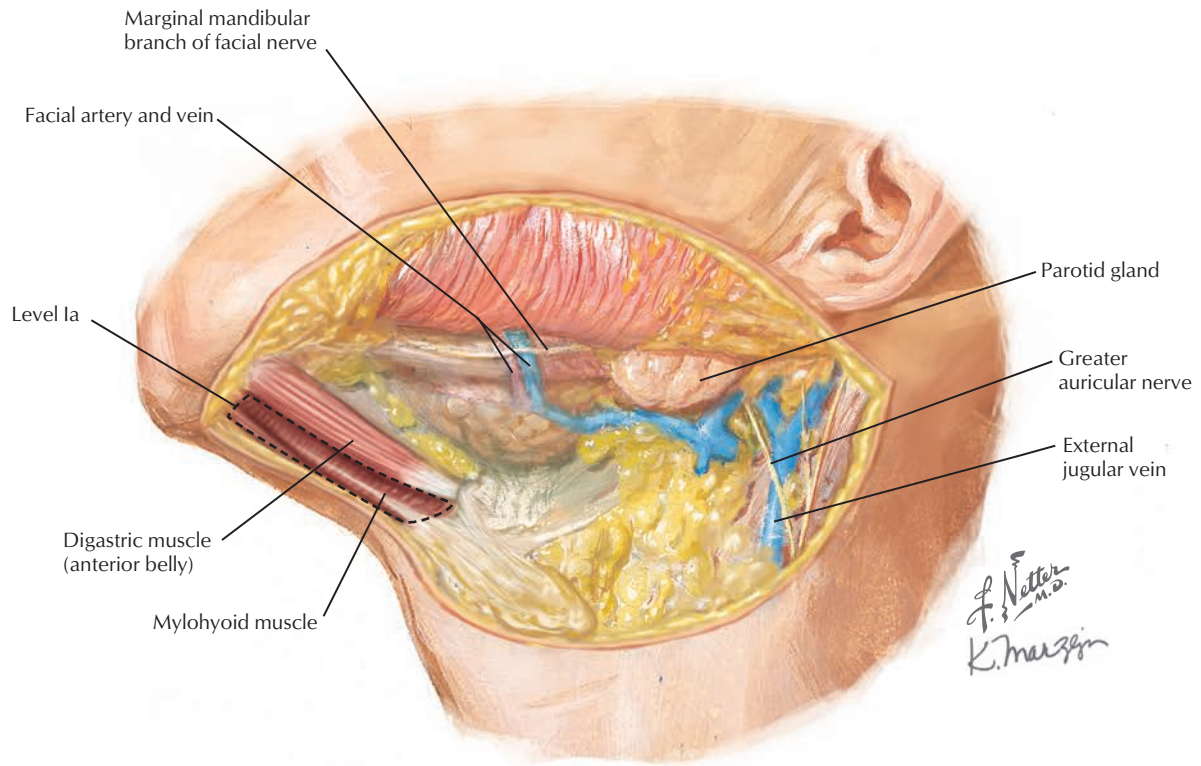


FIGURE 1-3 Dissection of level I (submental and submandibular regions).

LEVEL II-III NECK DISSECTION

Identify the posterior belly of the digastric muscle, creating the digastric tunnel back to the mastoid tip under the SCM (Fig. 1-4).

Incise the investing fascial layer along the anterior border of the SCM, ligating and dividing the external jugular vein in the process. An attempt should be made to preserve the greater auricular nerve, if not involved with disease.

Unwrap the SCM from its investing fascia. This is accomplished along a broad, superior-to-inferior plane, from the digastric muscle superiorly to the omohyoid muscle inferiorly.

Identify the spinal accessory nerve at its entrance into the SCM, and trace it under the posterior belly of the digastric muscle. The spinal accessory nerve typically passes lateral to the internal jugular vein just before diving under the posterior belly of the digastric muscle. The nerve will occasionally bisect or run deep to the jugular vein.

The spinal accessory nerve is released from the surrounding soft tissue, and then level IIb is released from the skull base, the back of the jugular vein, the SCM, and the deep cervical fascia. Level IIb is left attached to IIa and brought under the spinal accessory nerve.

Once the investing fascial layer is elevated off the SCM down to the level of the deep cervical rootlets, the dissection is taken medially across the rootlets from the omohyoid muscle to the spinal accessory nerve superiorly. Care must be taken to avoid injuring the spinal accessory nerve in this area as it exits the SCM posteriorly (Fig. 1-5).

Dissect levels II and III medially in a plane lateral to the cervical rootlets and the carotid sheath, which invests the carotid artery, internal jugular vein, and vagus nerve.

Once the elevation reaches the jugular vein, the fascia from the internal jugular vein is unwrapped. Branches of the vein may be ligated and divided as the specimen is brought medially. The ansa cervicalis will be transected during the inferior dissection as the specimen is brought across the jugular vein to the lateral aspect of the strap muscles. Superiorly, the hypoglossal nerve, which runs lateral to the carotid artery and medial to the jugular vein, must be protected under the digastric muscle. The ansa hypoglossi will likely need to be transected as the specimen is brought medially to the hyoid bone and strap musculature.

The specimen is then dissected away from the hypoglossal nerve and posterior belly of the digastric muscle until it can be easily removed. The anterior dissection will meet with the posterior dissection as the specimen is brought across the strap muscles, carotid artery, and jugular vein (Fig. 1-5).

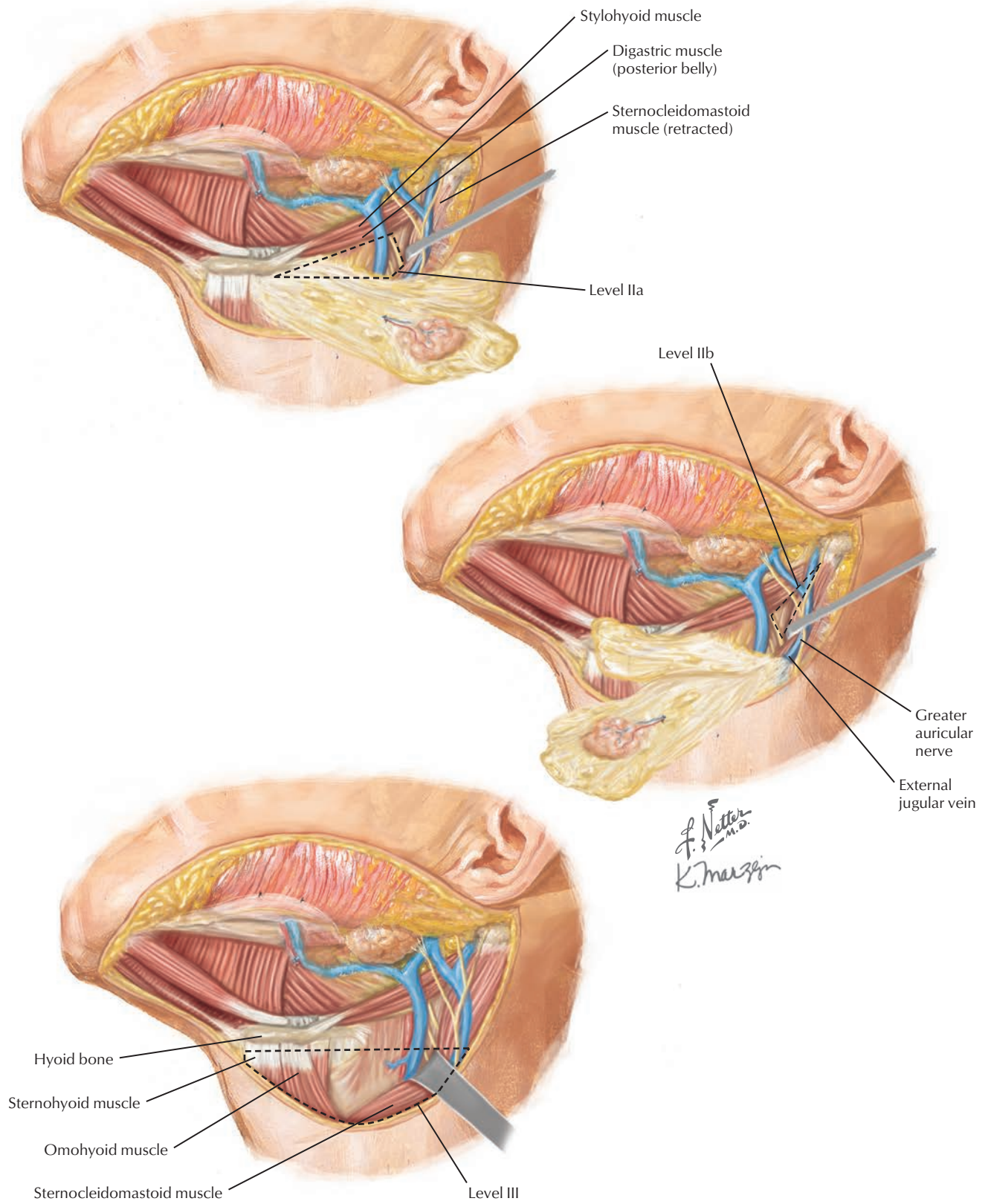


FIGURE 1-4 Dissection of levels II (upper jugular nodal chain) and III (midjugular nodal chain).

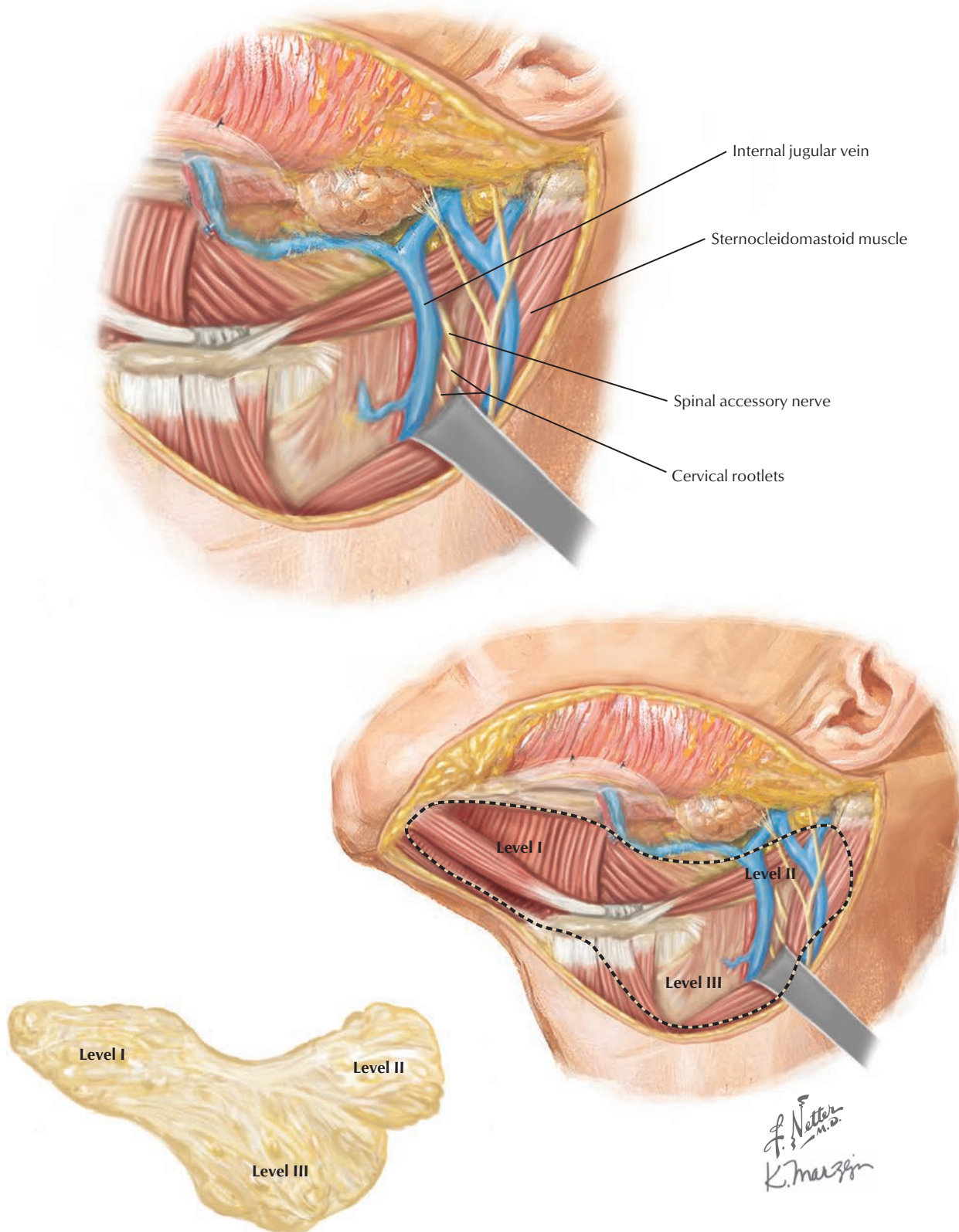


FIGURE 1-5 Lymphadenectomy (levels I-III).

SUGGESTED READINGS

- Janfaza P, editor. Cummings otolaryngology: head and neck surgery, 5th ed. Philadelphia: Saunders; 2010.
- Myers EN, editor. Operative otolaryngology: head and neck surgery, 2nd ed. Philadelphia: Saunders; 2008.

Tracheotomy and Cricothyrotomy



Rod Rezaee, Yi-Chun Carol Liu, and Pierre Lavertu

INTRODUCTION

Tracheotomy (tracheostomy) is one of the oldest surgical procedures known, with the first reference 3000 to 4000 years ago. Chevalier Jackson is credited with standardizing the tracheotomy procedure in 1932, outlining the individual steps for establishing a direct airway through the anterior neck tissues and into the trachea. Jackson had the foresight to consider potential surgical complications when he warned against placement of a high tracheotomy or cricothyrotomy (cricothyroidotomy). Although the procedure has evolved and now includes a percutaneous technique, this chapter focuses on *open* tracheotomy.

INDICATIONS AND PRINCIPLES OF TRACHEOTOMY

Indications for tracheotomy are multiple and include the need to bypass an airway obstruction caused by congenital anomaly, vocal cord paralysis, inflammatory disease, benign or malignant laryngeal pathology, laryngotracheal trauma, facial trauma, or severe sleep apnea refractory to other interventions. Additional indications for tracheotomy include the need to provide an airway for patients receiving mechanical ventilation for respiratory failure and for those with chronic aspiration secondary to inadequate cough. Tracheotomy may also allow for a more secure and comfortable airway for home ventilation in patients with neuromuscular or other chronic diseases.

Preoperative Considerations

Once a tracheotomy is planned, certain factors influence whether patients should have an open tracheotomy or a *percutaneous dilatational* tracheotomy, as first described by Ciaglia in 1985. Regardless of the tracheotomy method chosen, a patient's overall medical condition must be optimized, body habitus assessed, and coagulation profile addressed. Other preoperative factors to consider include the urgency of the procedure (emergency vs. elective); need for general or local anesthesia, adult or pediatric patient, current status of the airway (intubated vs. nonintubated patient), availability of proper equipment, patient portability, surgeon's experience (open vs. percutaneous technique), and capability of the institution to perform bedside procedures. This will determine which team performs the procedure and whether it will be done in the operating room or at the bedside in the intensive care unit.

SURGICAL ANATOMY AND TRACHEOTOMY PROCEDURE

External Anatomy

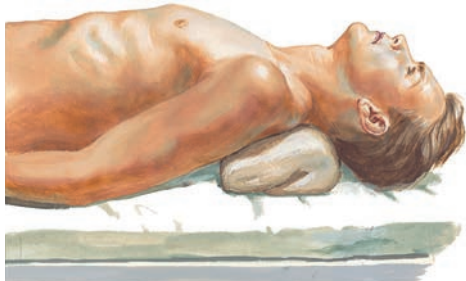The patient is placed in the supine position. The surgeon might consider placing the neck into slight extension, but this should not be too far past the neutral position, so that the skin incision remains in line with the tracheal incision. A shoulder roll may be used in some patients to assist with positioning (Fig. 2-1).

The thyroid notch superiorly, cricoid cartilage, and suprasternal notch inferiorly can usually be palpated and should be marked (Fig. 2-1). If an awake tracheotomy is being performed, the skin is injected with 1% lidocaine with 1:100,000 epinephrine solution for hemostasis and anesthesia. According to surgeon preference, this injection may also be done for general anesthesia patients. A vertical or horizontal incision is made in the midline of the neck, about 2 cm above the sternal notch, and is carried down until the strap muscles are visible.

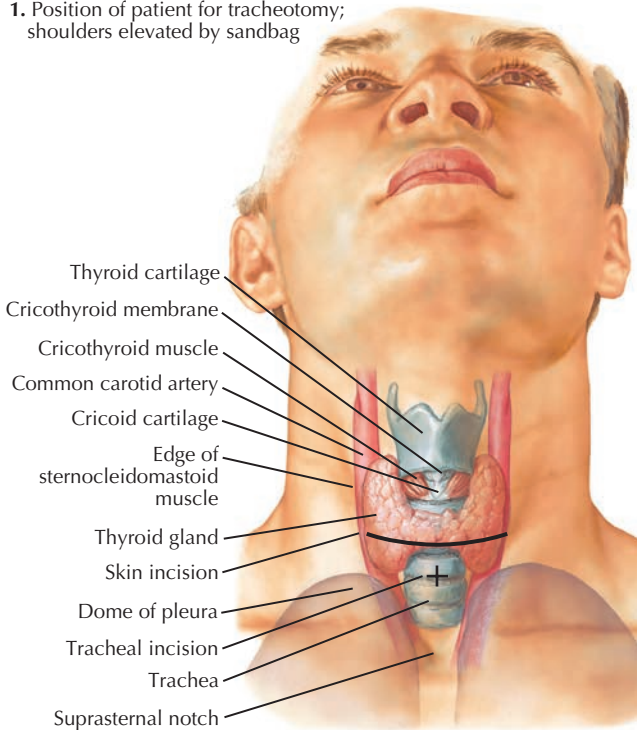
Strap Muscles and Midline Raphe

The anterior jugular veins are typically located on the strap musculature and may require ligation if encountered in the midline (Fig. 2-2). Small cricothyroid arteries traverse the superior aspect of the cricothyroid space, forming an anastomosis near the midline. This may cause problematic bleeding in the setting of emergent airway access or if dissection is carried out above the cricoid cartilage. In the lower neck, the surgeon must be aware that the innominate artery crosses over anterior to the trachea at the level of the thoracic inlet and is higher on the right side. Before dissection of the strap muscles, the surgeon should palpate for innominate pulsations in the suprasternal notch and should be cognizant of the pathway of the surgical dissection in the setting of a high-riding vessel.

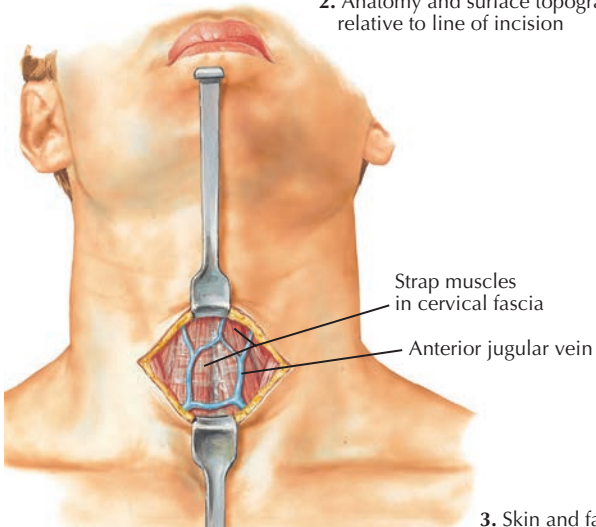
Midline dissection is essential for hemostasis and avoidance of paratracheal structures, including the great vessels of the neck. The midline raphe between the paired sternohyoid and sternothyroid muscles can be easily identified. Lateral retraction of the strap muscles along the midline raphe will expose the underlying thyroid gland. Palpation of the trachea can help maintain a midline course of dissection in those individuals with thick subcutaneous tissues.



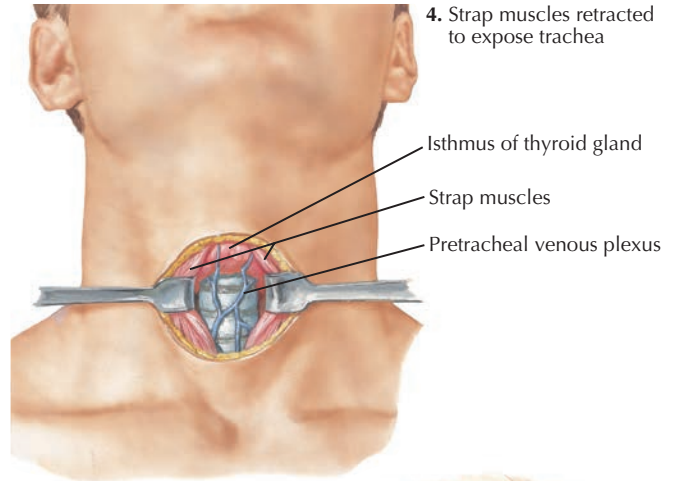
1. Position of patient for tracheotomy; shoulders elevated by sandbag



2. Anatomy and surface topography relative to line of incision

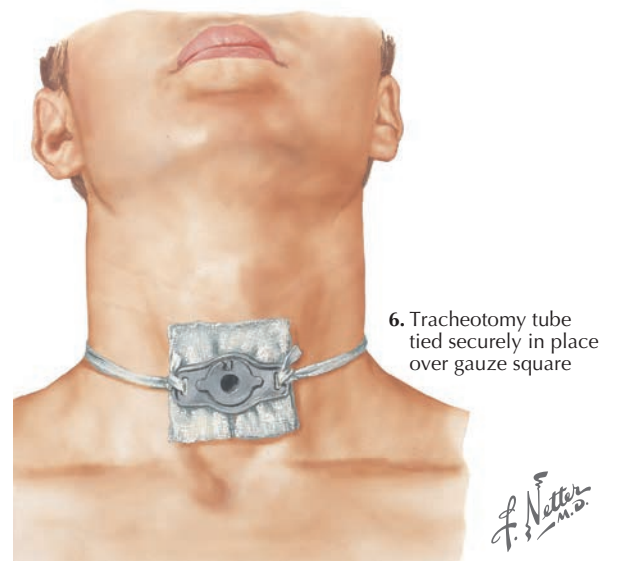
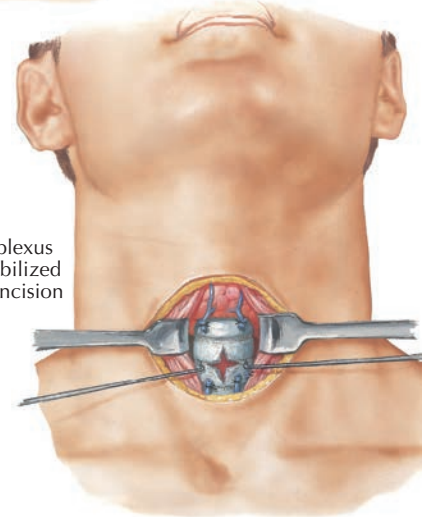


3. Skin and fat retracted



4. Strap muscles retracted to expose trachea

5. Pretracheal venous plexus divided. Trachea stabilized by hooks. Cruciate incision in trachea.



6. Tracheotomy tube tied securely in place over gauze square

F. Netter M.D.

FIGURE 2-1 Tracheotomy procedure, steps 1-6.

Thyroid Isthmus

The strap muscles are separated using blunt dissection and retracted to either side until the thyroid isthmus is visible. The isthmus of the thyroid gland generally lies across the first to fourth tracheal rings. It must be divided when overlying the tracheotomy site, because this will make reinsertion safer and easier in the setting of accidental dislodgement. The isthmus can be addressed in one of several ways. First, the fascial attachments of the thyroid to the anterior trachea may be dissected free, thus allowing the gland to be retracted above or below the planned entry site into the trachea. If the thyroid is enlarged and cannot be retracted out of the way, it will need to be divided by further dissecting it from the anterior tracheal wall in the immediate pretracheal plane to establish a bloodless plane of dissection. By identifying the bright-white layer of the tracheal cartilage, the surgeon will minimize bleeding from trauma to the posterior aspect of the gland.

Once the thyroid isthmus is elevated from the trachea, the surgeon may use two clamps on either side, then cutting in the midline with a Bovie cautery device. Once divided, the two ends of isthmus are then suture-ligated using a running or figure-of-eight 2-0 silk stitch. If available, other methods of dividing the gland include using the Harmonic scalpel or other device, based on surgeon preference. Use of cautery alone to divide the thyroid is discouraged, to minimize risk of postoperative hemorrhage.

Anatomy with Trachea Visualized

A cricoid hook may be used to help stabilize the position of the trachea before entering the airway. A hook may also be used to elevate the trachea out of the chest in the patient with kyphosis or a low-lying laryngotracheal complex. Once the anterior wall of the trachea is visualized, the space between the second and third tracheal rings is identified by palpation using a hemostat. A horizontal incision is made between the rings with a scalpel and can be extended laterally in each direction using scissors. Care is taken not to rupture the cuff of the endotracheal tube (ETT) by either deflating it before entering the airway or advancing it distally. It is preferable to maintain the ETT inflated during the procedure. It allows ventilation and minimizes the spray of blood and secretions into the surgical field.

Surgeon preference and age of the patient may influence the type of tracheal incision used. In children, a vertical incision may be used, but in adults the most common technique is to create an anterior tracheal window by removing a section of a single ring. Another technique creates an inferiorly based “trapdoor” flap (Björk flap) composed of an anterior portion of a single tracheal ring and interspace tissue below. After an intercartilaginous incision is made, scissors are used to cut downward on either side to create an inferiorly based flap of tracheal tissue. The superior edge of this flap is then stitched to the skin edge to exteriorize and secure the trachea. Although some consider this to be the safest method because the airway is secured to the skin, this may lead to future complications.

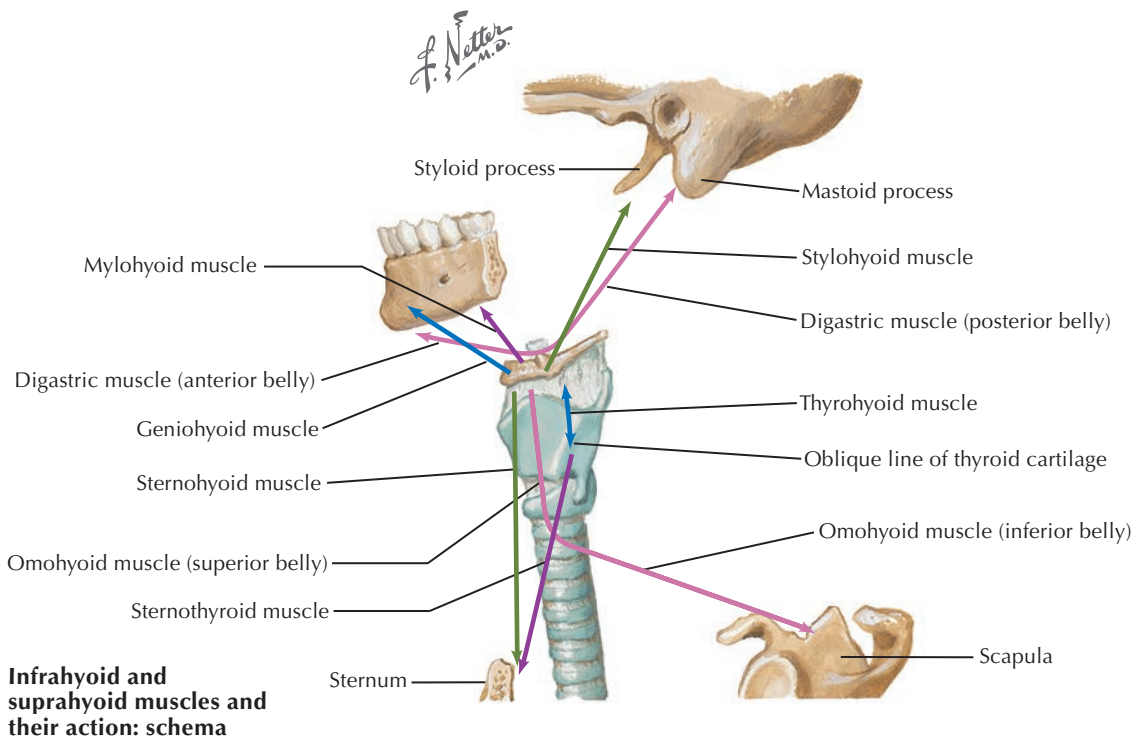
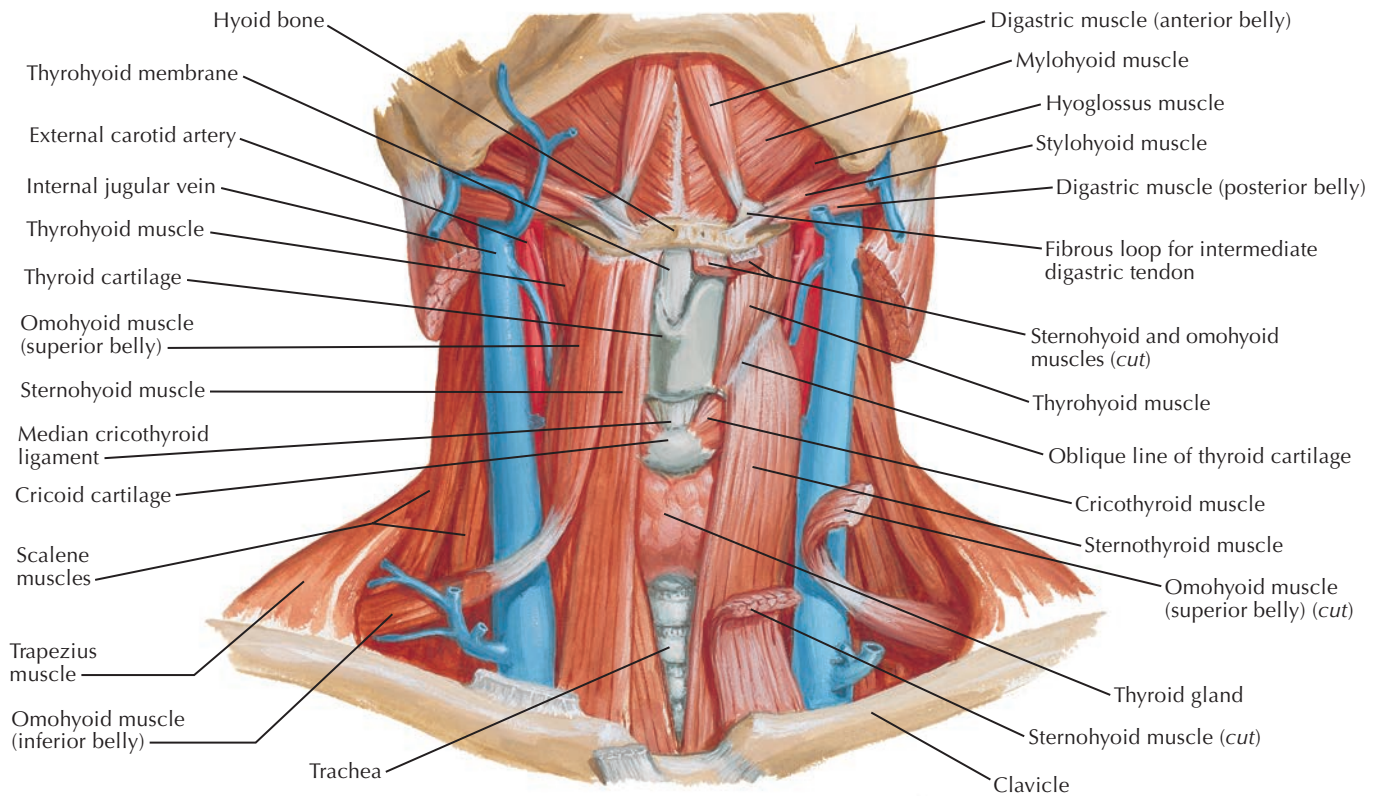


FIGURE 2-2 Infrahyoid and suprahyoid musculature for tracheotomy.

Anatomy with Tracheotomy Tube in Place

Once the airway is entered, the ETT is pulled out slowly by the anesthesiologist until it is just above the newly created tracheotomy. The tracheotomy tube or ETT is then placed through the opening into the trachea. After the airway is secured, as confirmed by CO₂ monitor or ventilator, the oral ETT is then removed. The tracheostomy tube is then sutured to the skin using 2-0 silk to minimize the risk of accidental dislodgement. In addition, a circumferential tie is placed and secured around the neck, allowing at least one finger to slide underneath to minimize constriction.

A flexible extension tube is used to connect the tube to the ventilator circuit to minimize unnecessary movement of the tube in the immediate postoperative period.

SUMMARY

Tracheotomy is used to establish a surgical airway in patients requiring prolonged mechanical ventilation. Surgeon mastery of anatomy and proper technique will maximize successful patient outcomes and minimize potential complications.

SUGGESTED READINGS

Bailey BJ. Head and neck surgery: otolaryngology. 4th ed. Philadelphia: Lippincott-Raven; 2006, pp 785-800.

Beatrous WP. Tracheostomy: its expanded indications and its present status. *Laryngoscope* 1968;78(3):3-55.

Pahor AL. Ear, nose and throat in ancient Egypt. *J Laryngol Otol* 1992;106(9):773-9.

Shapiro BA, Harrison RA, Trout CA. The artificial airway: clinical application of respiratory care, 2nd ed. Chicago: Year Book; 1979, pp 177-186.

Thyroidectomy and Parathyroidectomy



Christopher R. McHenry

THYROIDECTOMY

Thyroidectomy is the most common endocrine surgical procedure performed. It is indicated for nodular thyroid disease when fine-needle aspiration biopsy is malignant or suspicious for malignancy, consistent with a Hürthle or follicular cell neoplasm, persistent atypia/follicular lesion of undetermined significance, or is persistently nondiagnostic. Thyroidectomy is indicated for benign thyroid nodules that progressively increase in size, extend substernally, cause compressive symptoms, or impinge on the trachea, esophagus, recurrent laryngeal nerve, or major vessels. Thyroidectomy is also an option for treatment of thyrotoxicosis caused by a solitary hyperfunctioning nodule, multinodular goiter, or Graves' disease. The goal of thyroid surgery is to remove all diseased thyroid tissue safely, relieve symptoms, minimize recurrent disease, and prolong survival.

Surgical Anatomy for Thyroidectomy

The thyroid gland consists of two lobes and an isthmus (Fig. 3-1). Between 30% and 60% of patients also have a pyramidal lobe that forms as a result of the persistence of the embryologic thyroglossal duct. The principal blood supply to the thyroid gland comes from the inferior thyroid artery, a branch of the thyrocervical trunk and the superior thyroid artery, which is the first branch of the external carotid artery. The venous drainage of the thyroid gland is from the superior and middle thyroid veins, which empty into the internal jugular vein, and the inferior thyroid veins, which empty into the brachiocephalic veins.

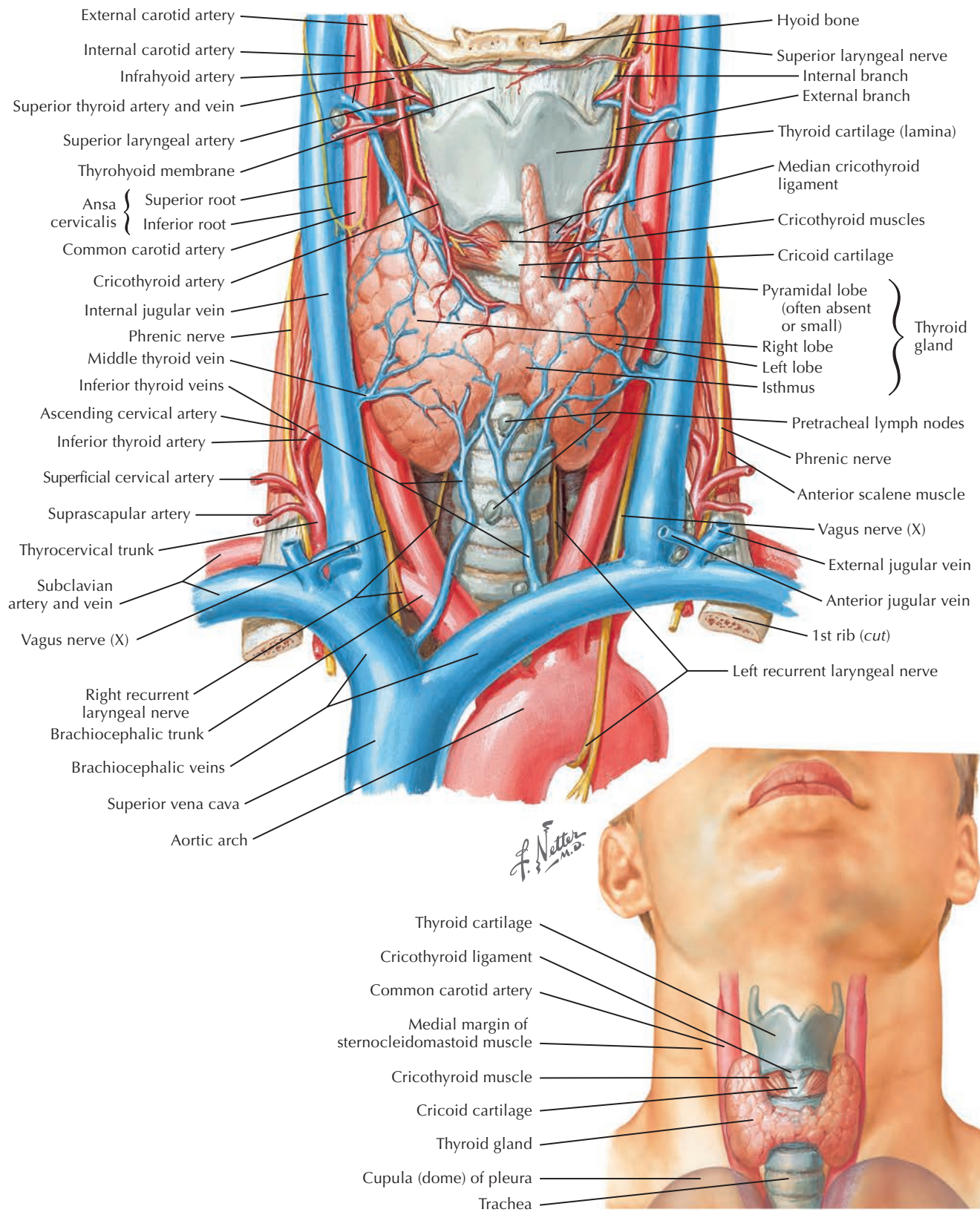
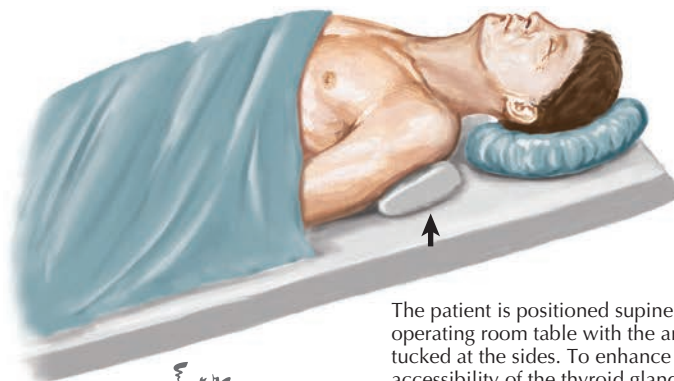
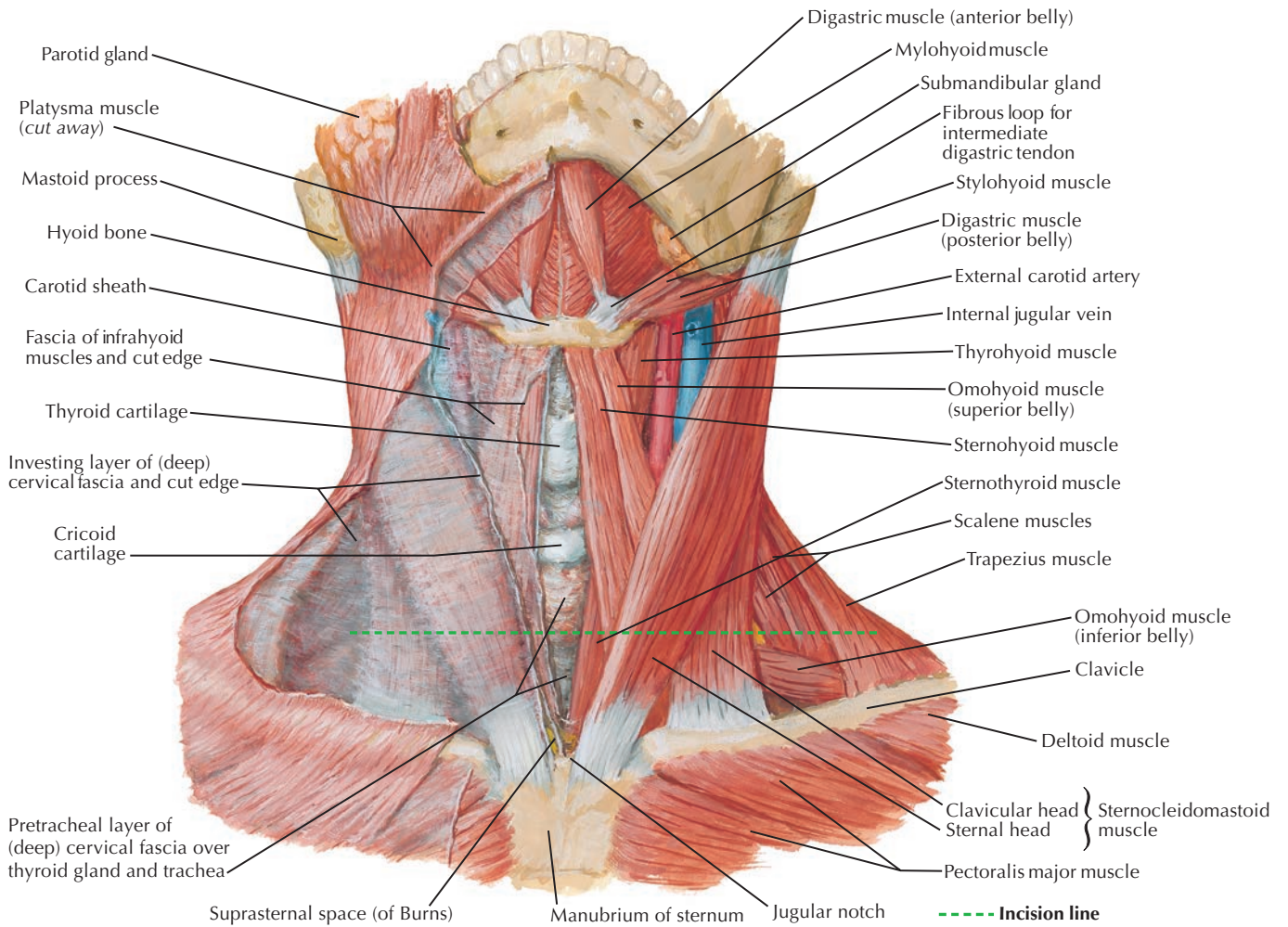


FIGURE 3-1 Thyroid gland, anterior view.

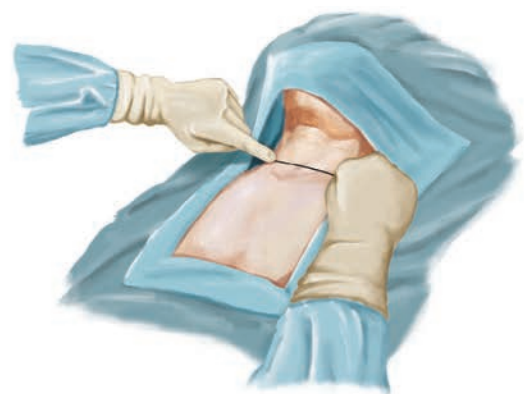Surgical Anatomy for Thyroidectomy—Cont'd

Determining the surface anatomy of the neck is necessary for proper placement of the skin incision (Figs. 3-1 and 3-2). The patient is positioned supine on the operating room table with the arms tucked at the side, a soft roll placed lengthwise beneath the shoulders, and the head in a soft-foam headrest with the neck extended (Fig. 3-2). Important landmarks that should be palpated include the prominence of the thyroid cartilage, the cricoid cartilage, and the sternal notch. The isthmus of the thyroid gland lies immediately below the cricoid cartilage. A transverse skin incision is made in a normal skin crease below the cricoid cartilage for an optimal cosmetic result.



*F. Netter M.D.
K. Margolin*

The patient is positioned supine on the operating room table with the arms tucked at the sides. To enhance the accessibility of the thyroid gland, the patient is positioned on a soft roll (arrow) placed lengthwise under the houlders, and the neck is extended on a soft-foam headrest. The bed is placed in reverse Trendelenburg position to decrease the venous pressure in the neck and reduce potential bleeding.



A silk suture is used to mark the site of the incision. Important anatomic landmarks are the thyroid cartilage, the cricoid cartilage, and the sternal notch. The site for the incision is being marked just below the cricoid cartilage.

FIGURE 3-2 Anatomic landmarks for thyroidectomy or parathyroidectomy incision.

Anatomy for Exposing the Thyroid Gland

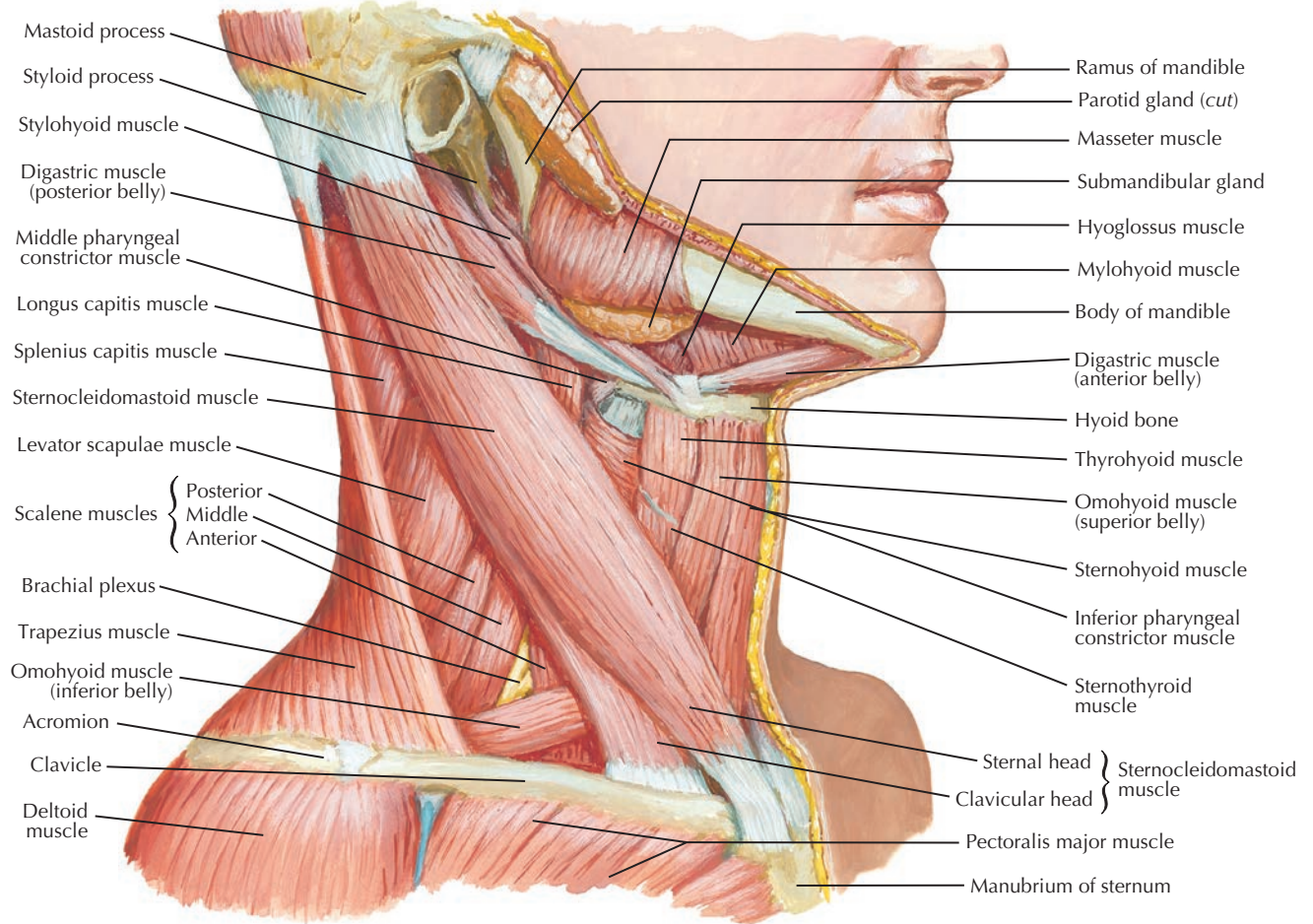
It is necessary to create a working space to remove the thyroid gland. This is accomplished first by dividing the subcutaneous tissue and platysma muscle to expose the sternal head of the sternocleidomastoid muscles laterally and the sternothyroid muscles in the midline of the incision (Figs. 3-2 and 3-3, *A*). Superior and inferior skin flaps are raised in the subplatysmal plane, anterior to the anterior jugular veins. The skin flaps are raised superior to the prominence of the thyroid cartilage, inferior to the sternal notch, and lateral to the sternal head of the sternocleidomastoid muscles.

The right and left sternohyoid muscles are separated along the median raphe from the thyroid cartilage superiorly to the sternal notch inferiorly. The median raphe is avascular and consists of the pretracheal or deep cervical fascia over the thyroid gland and trachea. The sternothyroid muscle is freed from the anterior surface of the thyroid lobe by dividing the intervening loose areolar tissue. The sternothyroid and sternohyoid muscles are retracted laterally, and the lobe of the thyroid gland is mobilized anteromedially. The sternohyoid and sternothyroid muscles may be divided when additional exposure is necessary, especially for patients with large goiters. The muscles are divided at the level of the cricoid cartilage to avoid injury to the ansa cervicalis, which enters the muscle inferiorly.

Anatomy for Mobilization of the Thyroid Lobe

Anteromedial traction is applied to the lobe of the thyroid gland, and the middle thyroid vein is divided (Fig. 3-3, *B*). The areolar tissue between the thyroid gland and the common carotid artery is separated using a combination of blunt and sharp dissection, allowing for further anteromedial mobilization of the thyroid gland. The superior thyroid artery and the superior thyroid veins are exposed by applying caudal and lateral traction to the thyroid parenchyma at the superior pole. This helps expose the cricothyroid space and facilitates the individual ligation of the superior-pole vessels close to the thyroid gland, staying lateral to the muscles of the pharynx and the larynx to avoid injury to the external branch of the superior laryngeal nerve (EBSLN).

A. Muscles of the neck (lateral view)



B. Parathyroid glands (right lateral view)

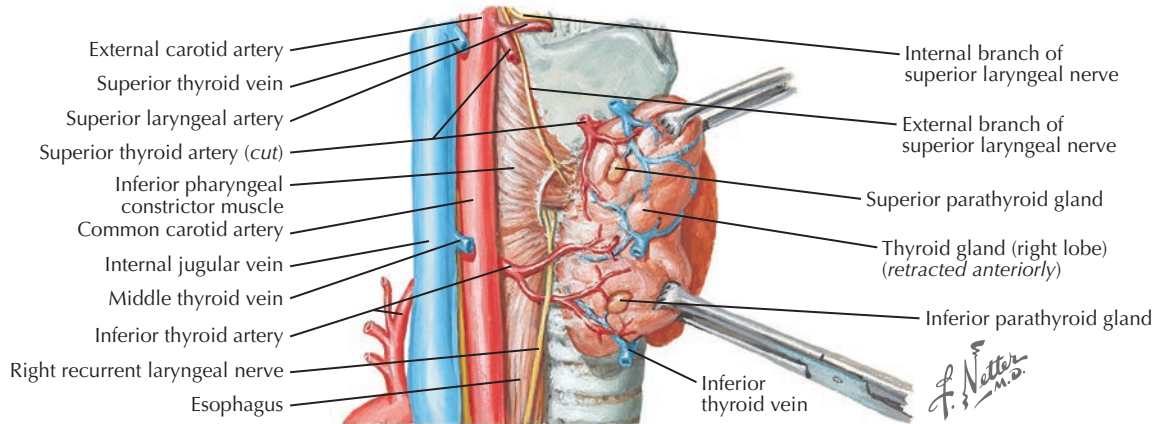


FIGURE 3-3 Surgical anatomy for thyroidectomy and parathyroidectomy.

Anatomy of the Superior Laryngeal Nerve

The superior laryngeal nerve is a branch of the vagus nerve from high in the neck (Fig. 3-4, *A and B*). At 2 to 3 cm above the superior-pole vessels, the superior laryngeal nerve divides into an internal branch that provides sensory innervations to the supraglottic area of the larynx and the base of the tongue and an external branch that provides motor innervation to the cricothyroid muscle.

The EBSLN is not routinely identified during thyroidectomy or parathyroidectomy. It is a thin nerve that usually travels along the medial border of the superior-pole vessels. It usually crosses the superior-pole vessels 1 cm or more above the junction of the vessels and the thyroid parenchyma. In 20% of patients the EBSLN crosses or is immediately adjacent to the superior-pole vessels at its junction with the thyroid gland, increasing the likelihood of injury and underscoring the importance of individual ligation of the vessels to preserve the EBSLN.

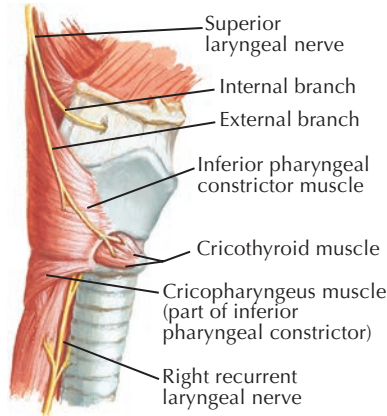
Anatomy of the Recurrent Laryngeal Nerve

The recurrent laryngeal nerves (RLNs) are branches of the vagus nerve from within the thorax (Fig. 3-4). The right RLN “recurs” around the right subclavian artery, and the left RLN recurs around the arch of the aorta. The RLNs ascend into to the neck from the thoracic inlet, passing from lateral to medial into the tracheoesophageal groove. The left RLN enters the neck in a more medial location than the right RLN, which has a more oblique course.

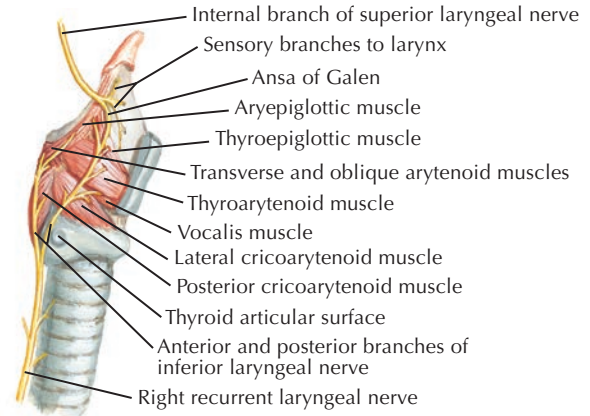
The RLN is identified inferior to the inferior thyroid artery, where its location is most constant. In the neck the RLN crosses the inferior thyroid artery and then maintains a paratracheal location for approximately 1 cm before passing posterior to the inferior edge of the inferior pharyngeal constrictor muscle to enter the larynx (see Fig. 3-3, *B*).

In 85% to 90% of patients, thyroid parenchyma tissue protrudes from the posterolateral margin of the lateral lobe of the thyroid gland, known as the *tubercle of Zuckerkandl* (Fig. 3-4, *C*). This is an important anatomic landmark because the RLN passes in the tracheoesophageal groove beneath the inferior portion of the tubercle of Zuckerkandl before it turns posteriorly to enter the larynx. Before entering the larynx, the RLN divides into two or more branches in 40% to 80% of patients (Fig. 3-4, *D*). The RLN innervates all the muscles of the larynx except the cricothyroid muscle.

A. Nerves of larynx

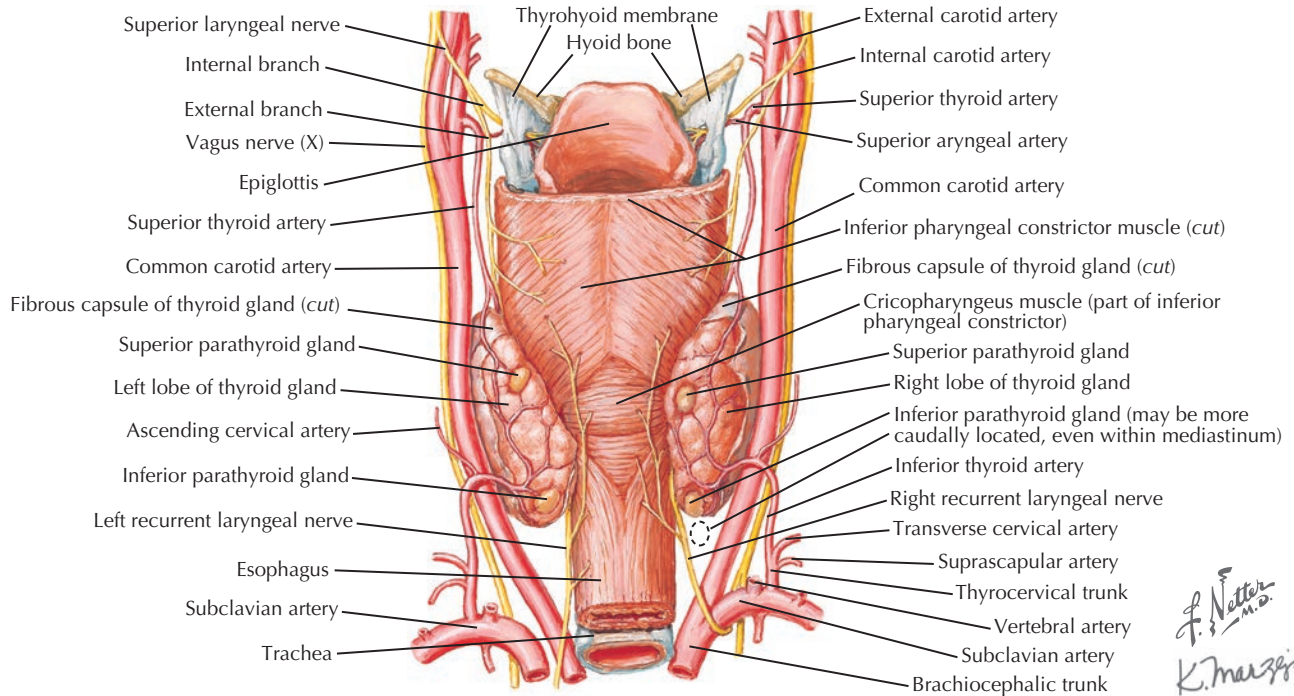


Right lateral view

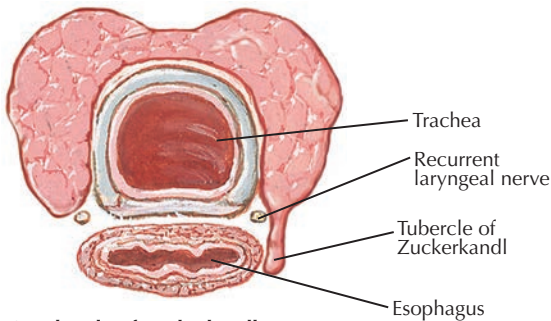


Right lateral view: thyroid cartilage lamina removed

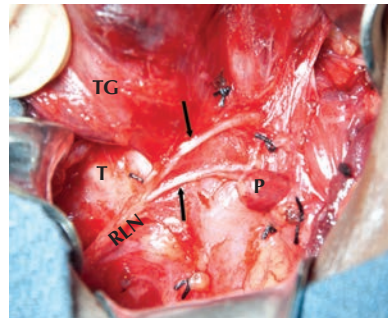
B. Parathyroid glands (posterior view)



F. Netter M.D.
K. Marzari



C. Tubercle of Zuckerkandl



D. Intraoperative photograph demonstrating the recurrent laryngeal nerve (RLN). An anterior motor branch and a posterior sensory branch are present in the normal paratracheal location (T=trachea). A normal right superior parathyroid gland is depicted (P). The thyroid gland (TG) has been mobilized anteromedially.

FIGURE 3-4 Anatomy of superior and recurrent laryngeal nerves.

Anatomy for Ligation of the Inferior Thyroid Artery and Preservation of the Parathyroid Glands

Whenever possible, the parathyroid glands should be preserved in situ by dissecting them downward, away from the capsule of the thyroid gland. Once the RLN has been exposed superior to the inferior thyroid artery, the branches of this artery are ligated close to the thyroid parenchyma, preserving the blood supply to the parathyroid glands. Truncal ligation of the inferior thyroid artery should be avoided.

When a parathyroid gland cannot be preserved in situ, it is removed and a small portion submitted for frozen-section examination to confirm the presence of parathyroid tissue. The remainder of the gland is minced and autotransplanted into a pocket of the sternocleidomastoid muscle. Ninety percent of freshly autotransplanted parathyroid glands retain function.

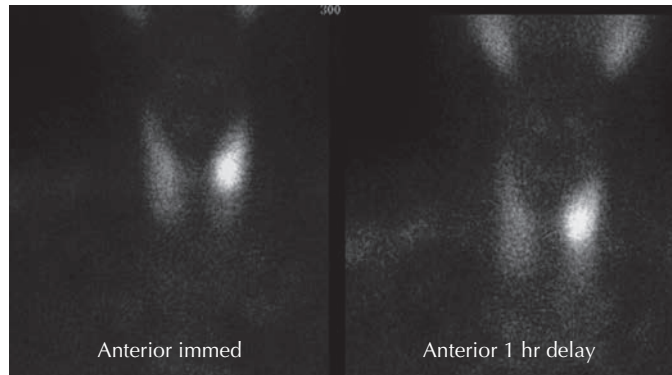
Once the thyroid lobe has been dissected away from the RLN, the ligament of Berry, connective tissue that suspends the thyroid gland to the trachea, is divided sharply. A small remnant of thyroid tissue can be left in place where the RLN contacts the thyroid parenchyma at the ligament of Berry, to preserve the integrity of the RLN. For patients undergoing a thyroid lobectomy and isthmusectomy, the thyroid gland is mobilized to the contralateral side of the trachea and divided. The cut edge of the contralateral lobe of the thyroid gland is oversewn. For patients undergoing total thyroidectomy, anteromedial mobilization of the contralateral thyroid lobe is begun.

PARATHYROIDECTOMY

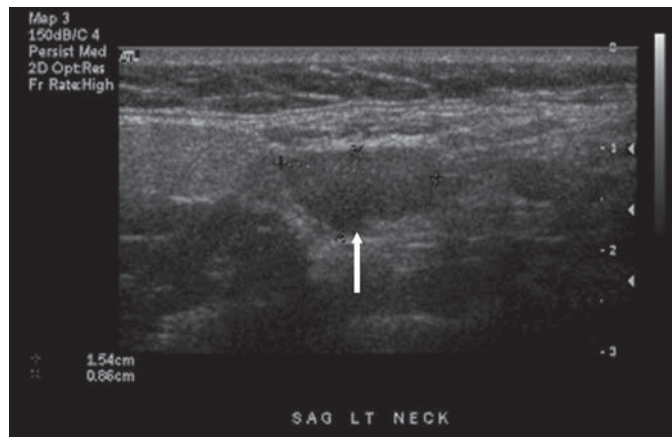Parathyroidectomy is indicated for treatment of primary, secondary, and tertiary hyperparathyroidism (HPT). Approximately 85% to 90% of patients with primary HPT have a single adenoma, whereas patients with secondary and tertiary HPT have parathyroid hyperplasia. Minimally invasive parathyroidectomy (MIP) is used to treat patients with primary HPT caused by a solitary adenoma, whereas bilateral neck exploration with subtotal parathyroidectomy or total parathyroidectomy and parathyroid autotransplantation is the standard treatment for parathyroid hyperplasia.

Photographs

Accurate preoperative parathyroid localization is a prerequisite for performing MIP. Technetium 99m sestamibi scintigraphy and high-resolution ultrasonography are the localizing procedures of choice (Fig. 3-5). Intraoperative parathyroid hormone (IOPTH) measurement is used to determine whether additional hyperfunctioning parathyroid tissue remains. A greater than 50% decline in IOPTH levels 10 minutes after excision of all hyperfunctioning parathyroid tissue is indicative of a curative parathyroidectomy. Failure of IOPTH levels to decline by more than 50% indicates that residual hyperfunctioning tissue remains and that further exploration is necessary.



Technetium 99m sestamibi scan demonstrating an abnormal focus of radiotracer accumulation seen in the left side of the neck on immediate and 1 hour delayed images.



Static sonographic image in the sagittal plane demonstrating a homogeneous, hypoechoic mass inferior to the left lobe of the thyroid gland that corresponded to a left inferior parathyroid adenoma.

FIGURE 3-5 Preoperative imaging of neck: scintigram (*top*) and sonogram (*bottom*).

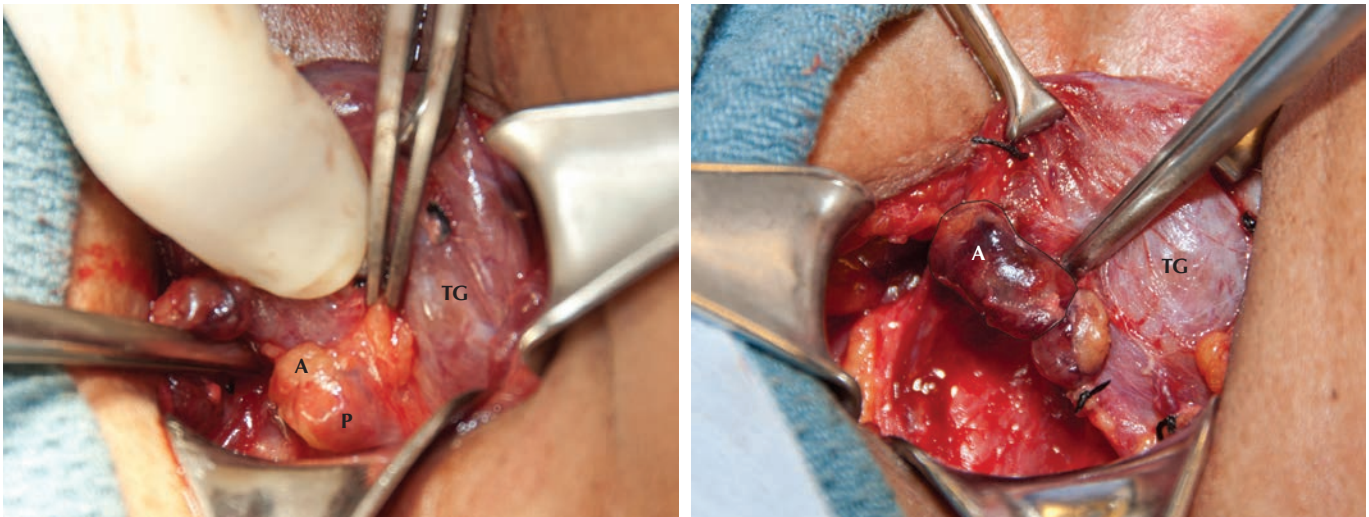
Anatomy and Embryology of Parathyroid Glands

A normal parathyroid gland is oval, bean shaped or spherical, yellow-tan in color, 5 mm in maximum dimension, and weighs 35 mg or less. It is usually surrounded by adipose tissue (Fig. 3-6, A). A parathyroid gland can be flattened in appearance, especially when it is within the capsule or adherent to the thyroid gland.

The superior parathyroid glands are usually posterior and superior to the RLN, approximately 1 cm cephalad from the junction of the RLN and inferior thyroid artery at the level of the cricoid cartilage, where the RLN enters posterior to the inferior pharyngeal constrictor muscle (see Fig 3-3, B). The superior glands are often found in a subcapsular location. The inferior parathyroid glands are usually anterior to the RLN along the posterolateral aspect of the inferior pole to the thyroid gland, approximately 1 cm caudal to the junction to the RLN and inferior thyroid artery. The inferior parathyroid glands are less often subcapsular. The inferior thyroid artery is the principal blood supply to the parathyroid glands, although they may also obtain blood supply from the superior thyroid artery and small vessels from the capsule of the thyroid gland.

The steps necessary to expose the parathyroid glands are similar to those used for thyroidectomy, except a smaller incision is used (2.5 to 4.0 cm). Superior and inferior skin flaps are raised; the strap muscles are separated in the midline; and the lobe of the thyroid gland is mobilized and retracted anteromedially. The search for an enlarged parathyroid gland begins with an exploration of the normal anatomic locations for the superior and inferior parathyroid glands (Fig. 3-6, B). Division of the middle thyroid vein and the superior-pole vessels is generally unnecessary, but this may be helpful in exposing parathyroid glands, especially in ectopic locations.

The inferior parathyroid glands and the thymus develop from the third bronchial pouch (Fig. 3-6, C). The superior parathyroid glands and the lateral lobes of the thyroid gland develop from the fourth bronchial pouch. Inferior parathyroid glands undergo extensive migration with the primordium of the thymus and eventually become located on the dorsolateral surface of the inferior pole of the thyroid lobe. These superior parathyroid glands undergo minimal migration and become located on the dorsomedial surface of the superior pole of the thyroid gland.



A. A normal superior parathyroid gland (P) surrounded by adipose tissue (A) is demonstrated with the thyroid gland (TG) retracted anteromedially.

B. A left inferior parathyroid adenoma (A) is depicted in its normal anatomic position with the thyroid gland (TG) mobilized anteromedially.

C. Development of the thyroid and parathyroid glands

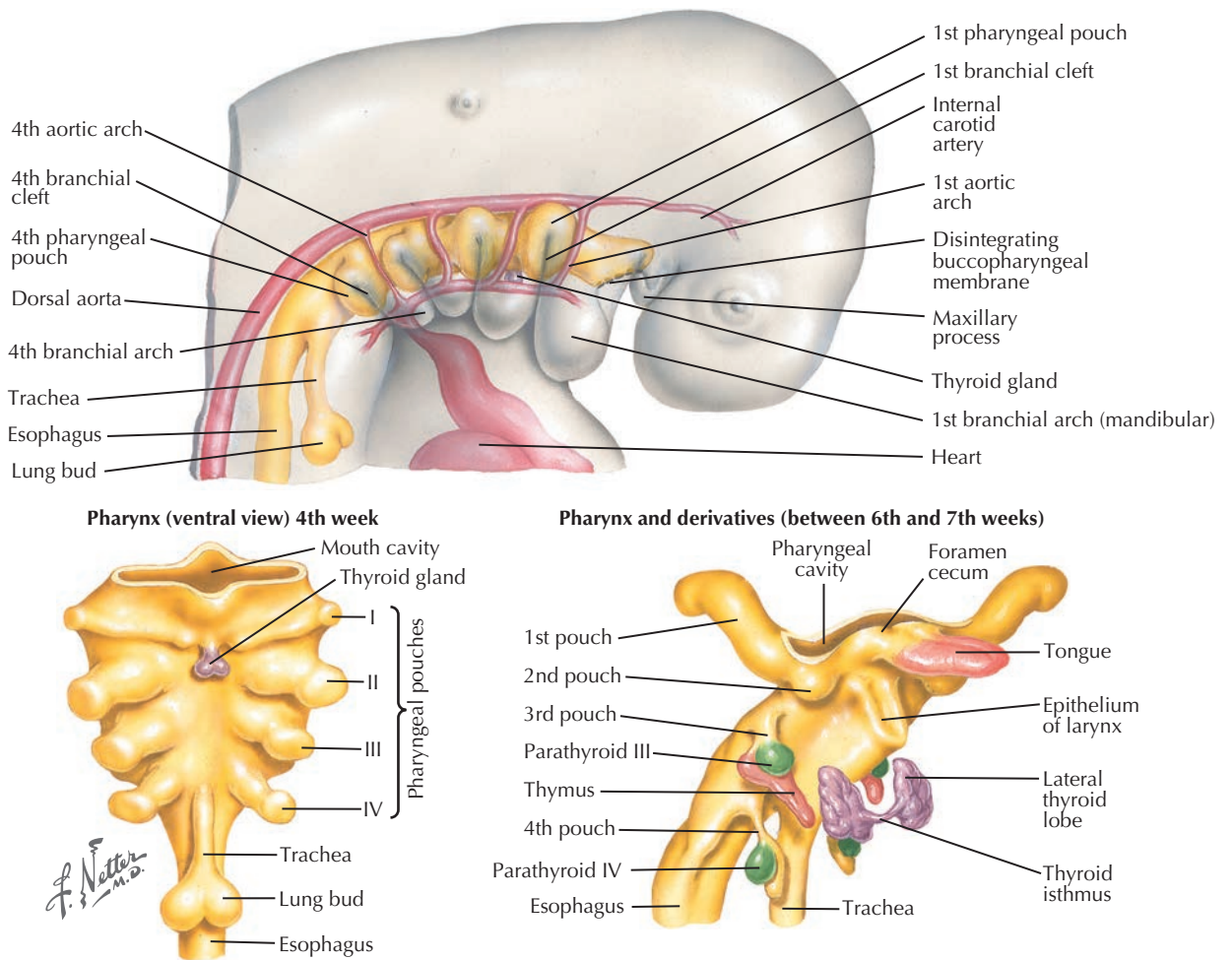


FIGURE 3-6 Anatomy and embryology of parathyroid glands.

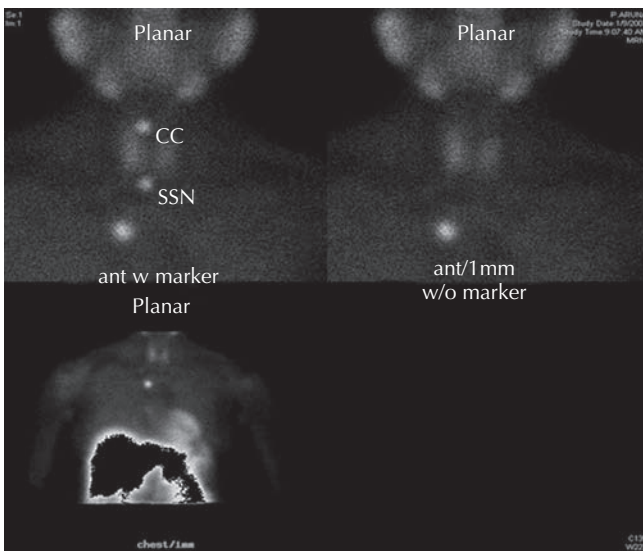
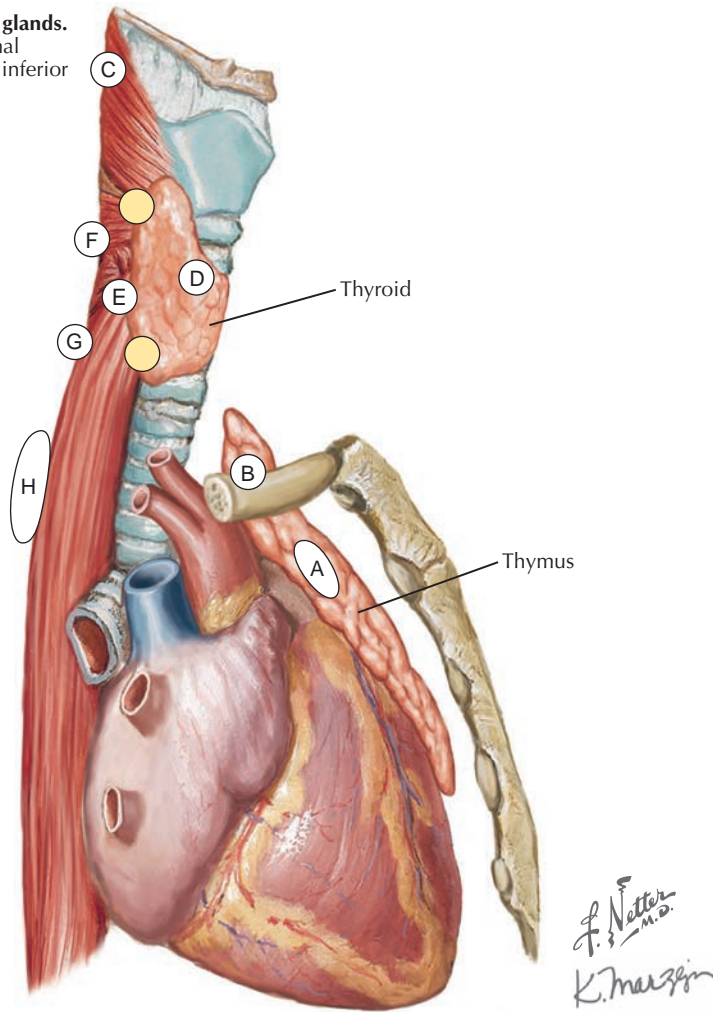
Anatomy and Embryology of Parathyroid Glands—Cont'd

The inferior parathyroid glands, because of their extensive embryologic migration, are more often present in ectopic locations. The most common location for an ectopic inferior parathyroid gland is within the thymus (Fig. 3-7, top, circled A). Other sites include the thyrothymic ligament and the anterosuperior mediastinum (B), undescended in a submandibular location (C), or within the thyroid gland (D). The most common ectopic location for a superior parathyroid gland is in the tracheoesophageal groove (E). Ectopic superior parathyroid glands may also be found in a retropharyngeal (F), retroesophageal (G), posterior mediastinal (H), or intrathyroidal (D) location. Preoperative localization is important to identify ectopic glands, particularly the retrosternal, intrathyroidic adenoma (Fig. 3-7, bottom scans and photo) or the undescended submandibular adenoma.

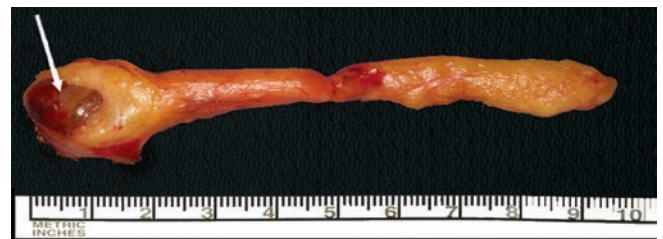When resecting abnormal parathyroid tissue, care should be taken not to enter the capsule of the gland. Violation of the capsule of an abnormal parathyroid gland can lead to recurrent HPT from soft tissue implantation of parathyroid cells, known as *parathyromatosis*. In patients with a solitary adenoma, mobilization of the adenoma is completed before taking the blood supply. Before taking the blood supply of the adenoma, blood is obtained from the internal jugular or a peripheral vein for IOPTH measurement. The main blood supply to the adenoma is ligated and additional blood obtained 5 and 10 minutes after excision of the adenoma for IOPTH measurement. A greater than 50% decline in IOPTH compared with the preexcisional or preoperative value is indicative of cure of the HPT, and no additional exploration is necessary.

The management of patients with parathyroid hyperplasia should consist of subtotal parathyroidectomy or total parathyroidectomy with parathyroid autotransplantation. The operative approach is primarily based on surgeon preference. When a subtotal parathyroidectomy is performed, the parathyroid remnant should be created first and its viability confirmed before resecting other glands. A search for supernumerary glands, which occur in 10% to 15% of patients, should be routinely performed with either approach. Because a supernumerary gland is most often found in the thymus, a routine transcervical thymectomy should also be performed.

Sites for ectopic parathyroid glands.
Open circles depict the normal location for the superior and inferior parathyroid glands.



Technetium 99m sestamibi images demonstrating an abnormal focus of radiotracer accumulation in a retrosternal location on the right. In the first image, radiopaque markers are present on the cricoid cartilage (CC) and the suprasternal notch (SSN).



Intrathyroidic parathyroid adenoma (*arrow*) that corresponds to the abnormal focus of radiotracer accumulation seen on the technetium images.

FIGURE 3-7 Anatomic sites for ectopic parathyroid adenoma, with images of abnormal focus and a corresponding specimen.

SUGGESTED READINGS

- Ander S, Johansson K, Lennquist S, Smed S. Human parathyroid blood supply determined by laser Doppler flowmetry. *World J Surg* 1994;18(3):417-20.
- Irvin GL 3rd, Prudhomme DL, Deriso GT, Sfakianakis G, Chandarlapaty SK. A new approach to parathyroidectomy. *Ann Surg* 1994;219:574-9.
- McHenry CR. Thyroidectomy for nodules and small cancers. In: Duh QY, Clark OH, Kebebew E, editors. *Atlas of endocrine surgery techniques. Surgical Techniques Atlas Series*. Philadelphia: Saunders; 2010, pp 3-24.
- Phitayakorn R, McHenry CR. Parathyroidectomy: overview of the anatomic basis and surgical strategies for parathyroid operations. *Clin Rev Bone Miner Metab* 2007;5:89-102.
- Phitayakorn R, McHenry CR. Incidence and location of ectopic abnormal parathyroid glands. *Am J Surg* 2006;191(3):418-23.

Laparoscopic Adrenalectomy

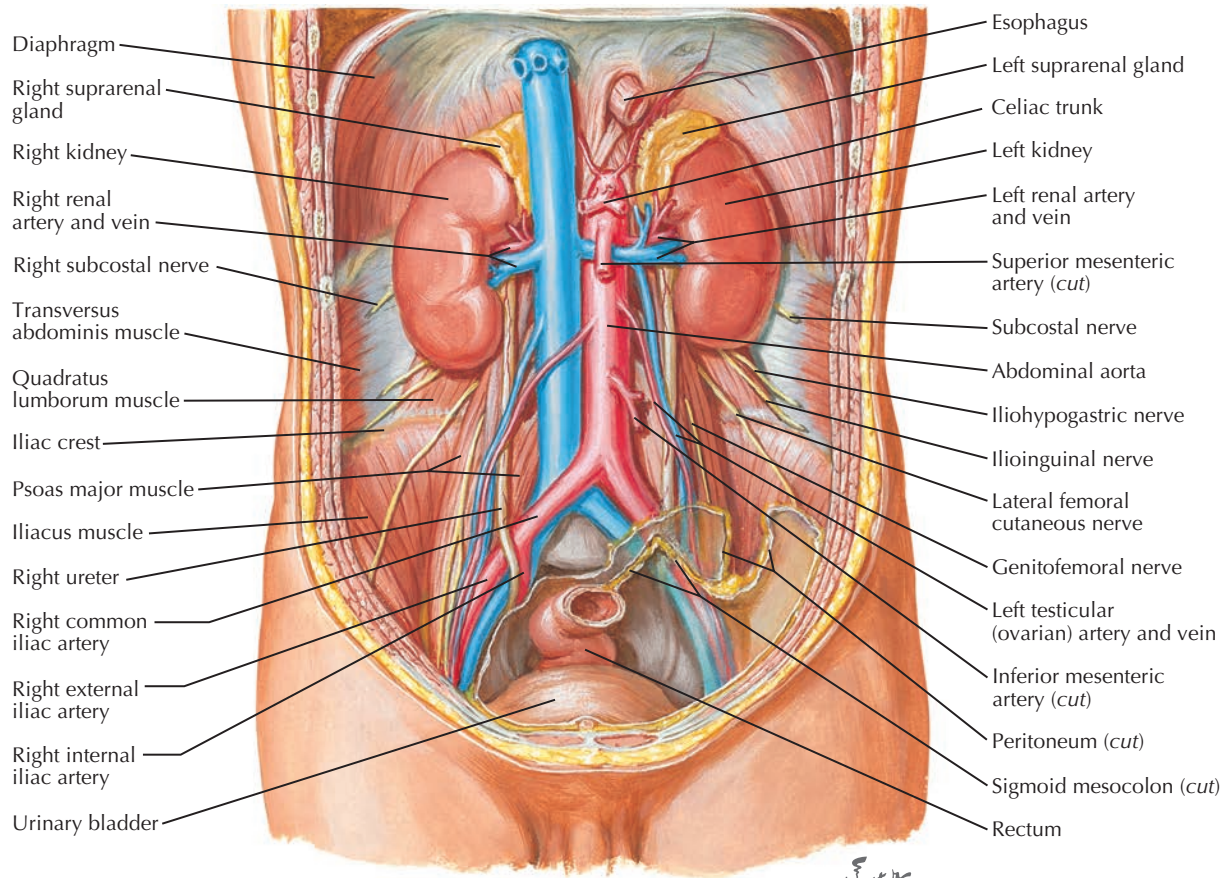
Scott M. Wilhelm

INTRODUCTION

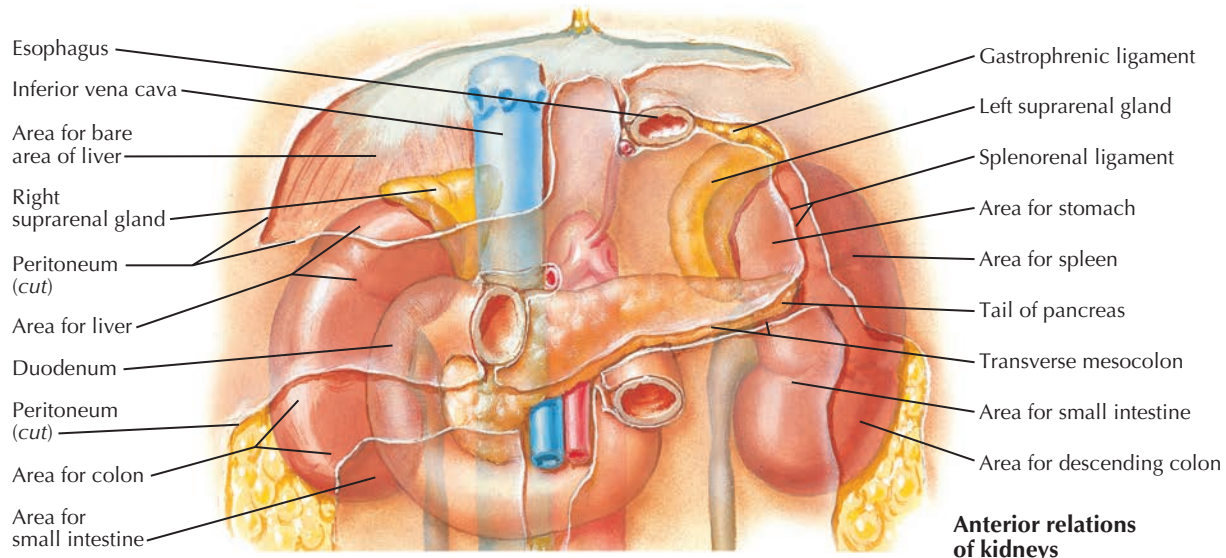
The adrenal glands reside in the retroperitoneum just above the kidneys (Fig. 4-1). Histologically, the adrenal glands are divided into an outer cortex comprising three layers—zona glomerulosa, zona fasciculata, and zona reticularis—and an inner medulla (Fig. 4-2). These histologic layers correspond to various hormones produced by the adrenal glands.

When considering which adrenal tumors may require surgical resection and which can be monitored, physicians can determine the need for surgical intervention using the following three general categories:

1. Functional tumors based on excessive hormone production: hyperaldosteronism or Conn syndrome, hypercortisolism or Cushing syndrome, sex hormone-producing tumors, or pheochromocytomas, which lead to excess catecholamine production.
2. Tumors suspicious for malignancy: primary adrenocortical cancer (ACC) or adrenal metastases.
3. Tumors that initially do not meet criteria for categories 1 or 2 but continue to increase in size and volume on interval radiographic follow-up at a rate concerning for a malignant process, or become hypersecretory on repeat laboratory testing.



F. Netter M.D.



Anterior relations of kidneys

FIGURE 4-1 Adrenal glands in situ, anterior views.

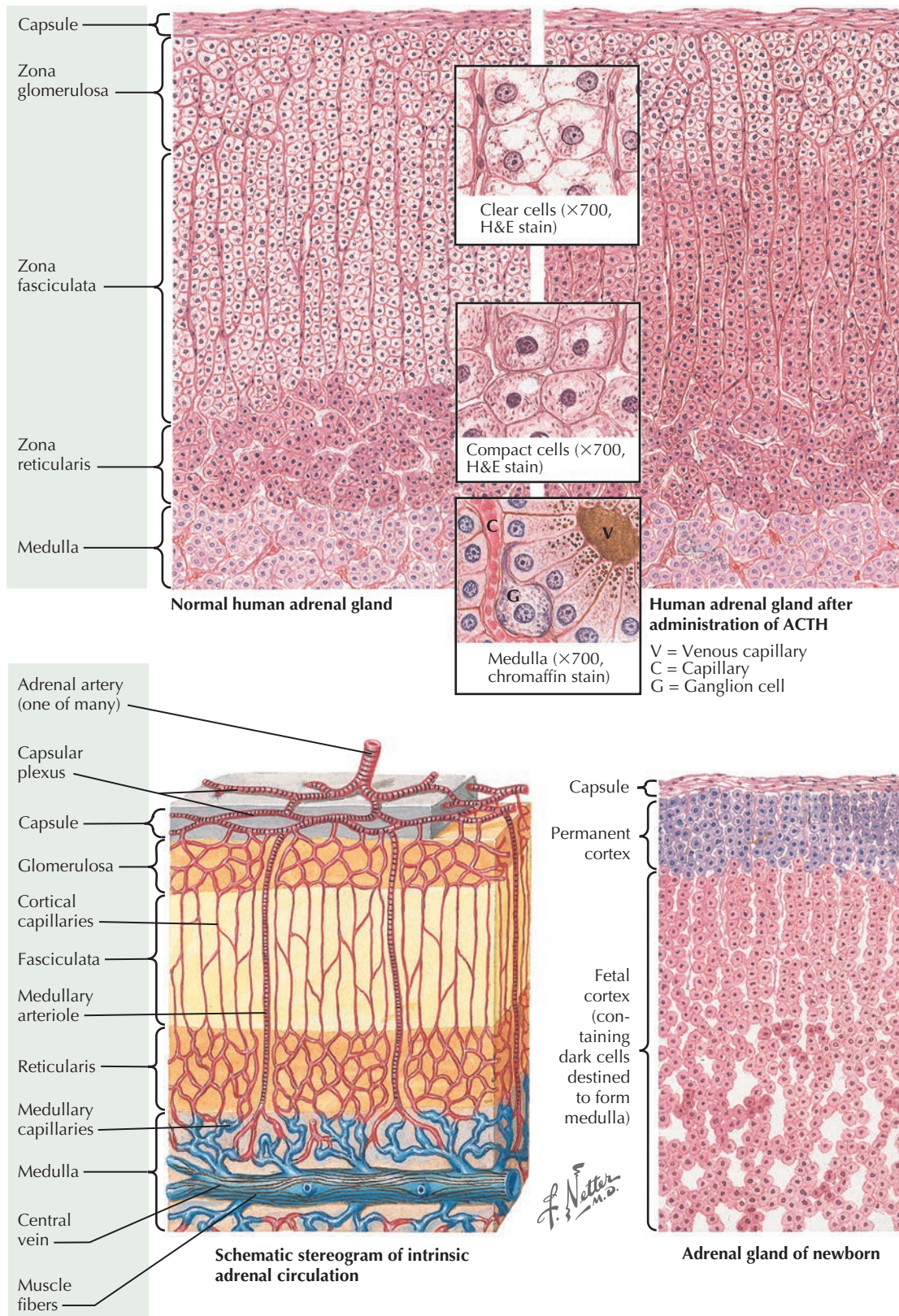


FIGURE 4-2 Histology of adrenal glands. ACTH, Adrenocorticotrophic hormone; H&E, hematoxylin and eosin.

SURGICAL PRINCIPLES

The “gold standard” for adrenalectomy has become the transabdominal laparoscopic adrenalectomy. The only current contraindication to the laparoscopic approach is malignancy in the form of adrenocortical carcinoma, which should be approached by an open technique to ensure adequate en bloc tumor resection.

To begin the transabdominal laparoscopic approach, the patient is positioned in the lateral decubitus position to allow gravity to assist with the dissection. A patient requiring right adrenalectomy is placed into a left lateral decubitus position in a jackknife position. Four laparoscopic ports are used, with a 10- to 12-mm port along the lateral border of the right rectus muscle at approximately the level of the umbilicus for the camera and three 5-mm ports along the costal margin. The port closest to the xiphoid process is used for a liver retractor, and two working ports are used for the operative dissection. For left adrenalectomy, the patient is reversed into the right lateral decubitus position, and because there is no need for retraction of the liver, three ports can be triangulated for the operative procedure (Fig. 4-3).

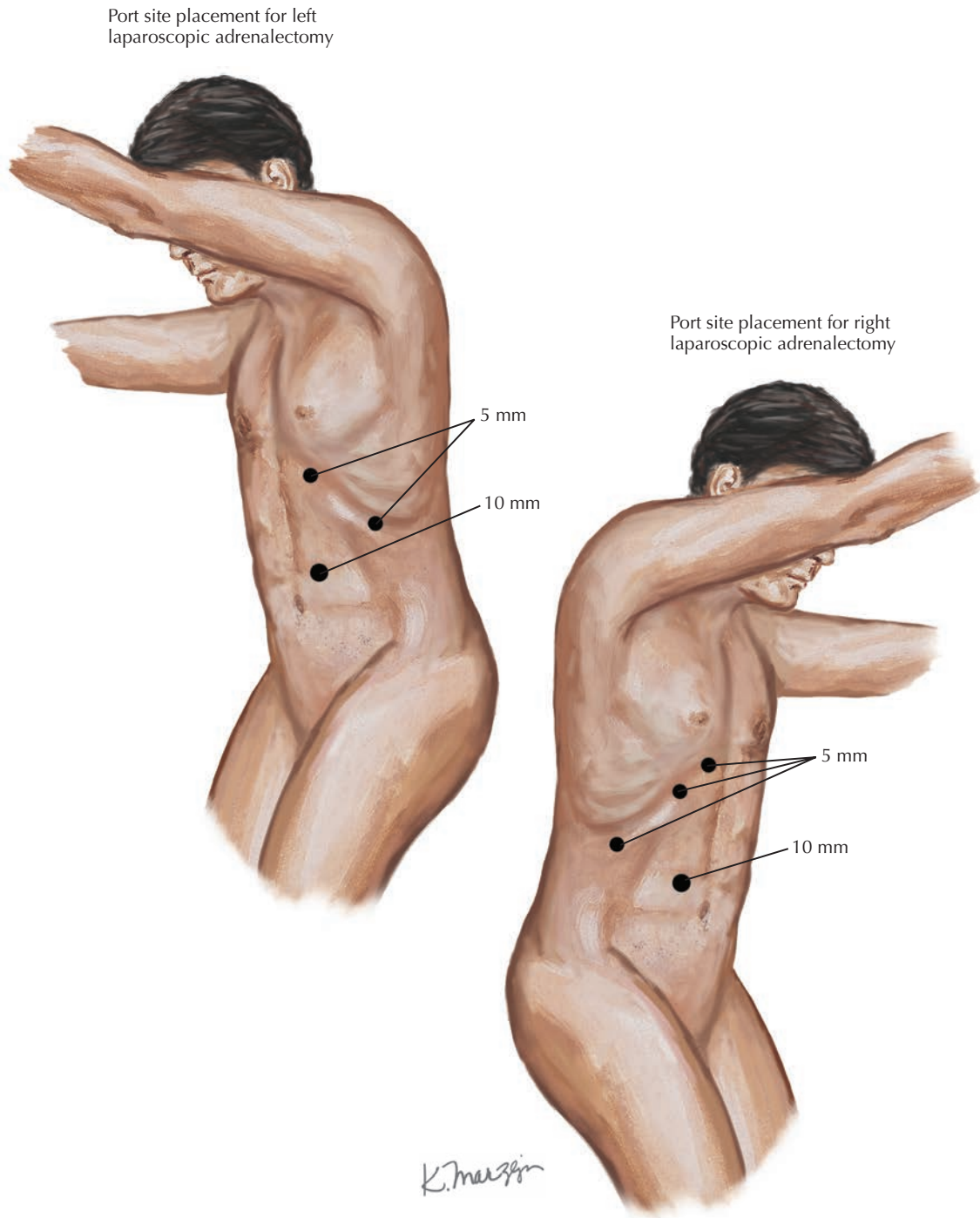


FIGURE 4-3 Port site placement for transabdominal laparoscopic adrenalectomy. Patient is in lateral decubitus position with ipsilateral arm supported.

SURGICAL TECHNIQUE

Right Laparoscopic Adrenalectomy

After the ports are placed (Fig. 4-3), a liver retractor is used to elevate the liver superiorly and medially to expose the superior border of the right adrenal gland. The retroperitoneal fascia is then incised from the lateral border of the inferior vena cava (IVC) out to the right triangular ligament of the liver. Figure 4-4 shows a cutaway view of the retroperitoneum with the liver removed to illustrate the right adrenal gland, kidney, and IVC. The line of incision would be just inferior to the liver (Fig. 4-5).

Once the superior border of the adrenal gland is cleared, the next goal is identification of the right adrenal vein as it enters the IVC. The vein generally enters along the medial border of the right adrenal gland at about the 2 o'clock position on the gland, as viewed in a cranio-caudal position (Fig. 4-6). The right adrenal vein should then be divided with surgical clips. The remaining adrenal attachments and vasculature can then be divided in the retroperitoneum by standard techniques with surgical clips or an energy device such as the Harmonic scalpel or Ligasure.

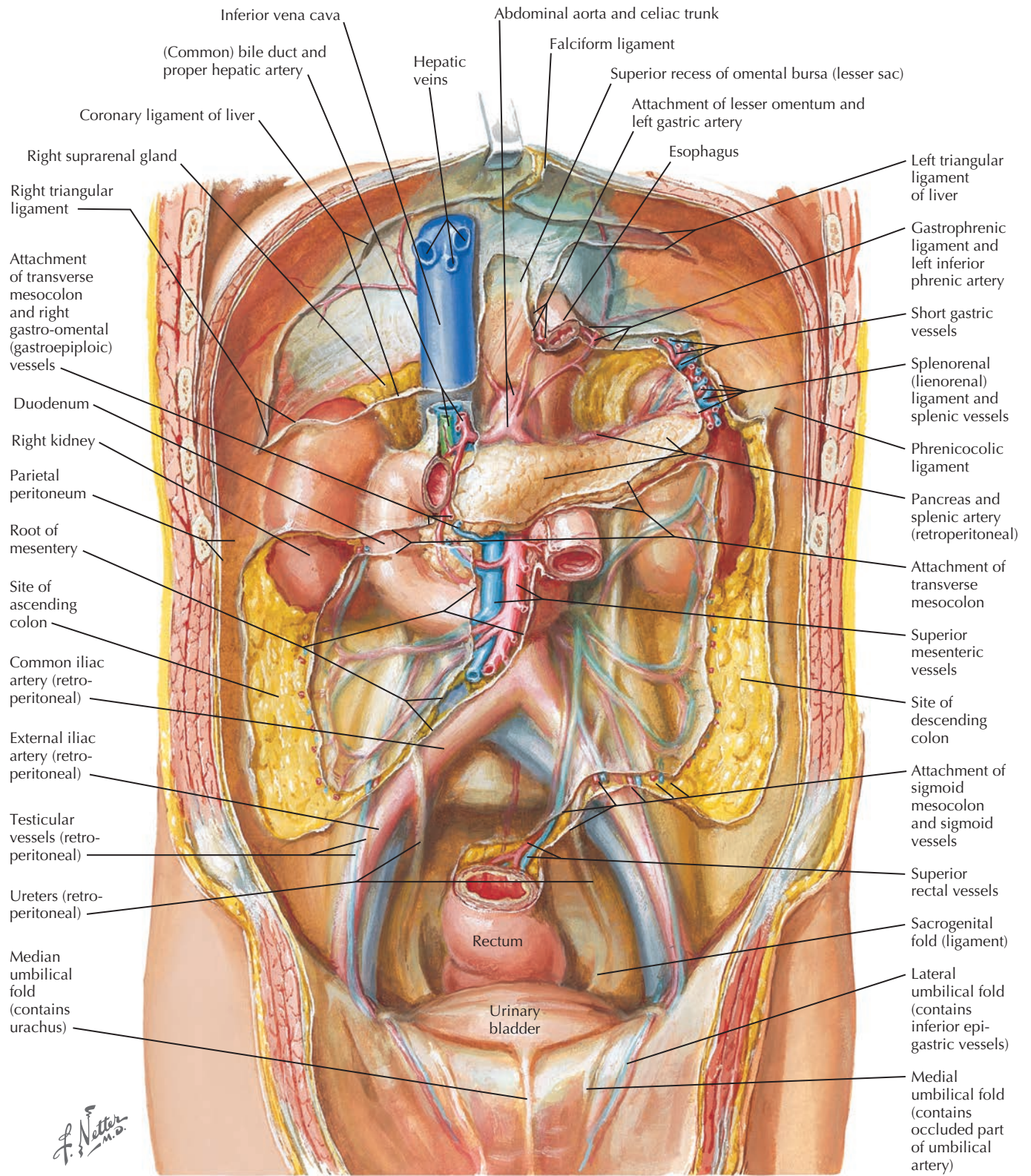
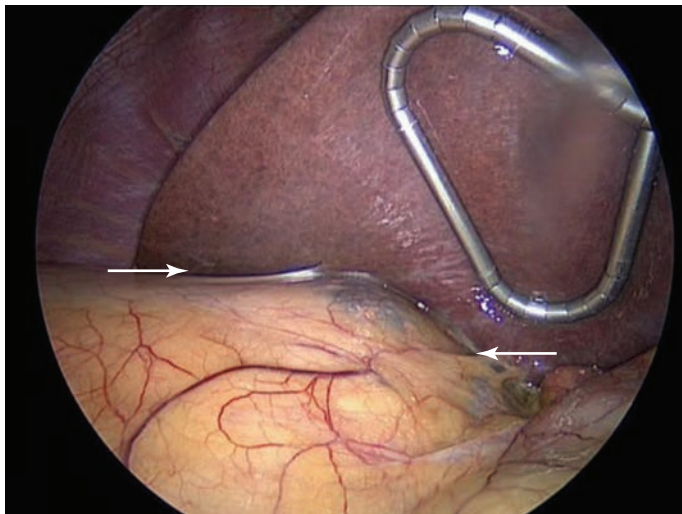
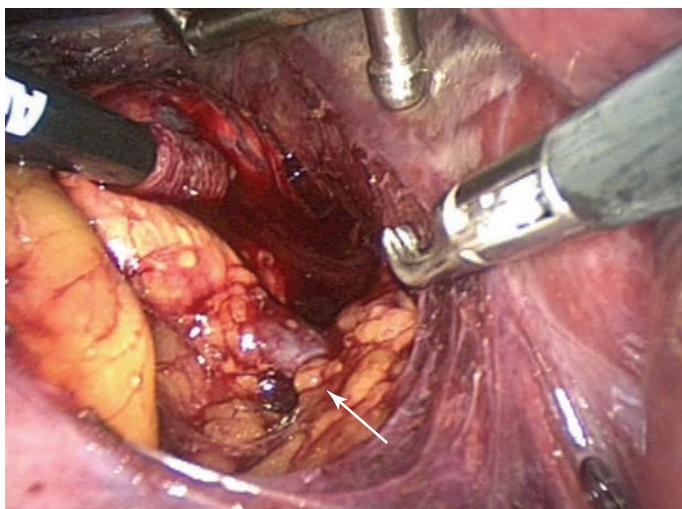


FIGURE 4-4 Peritoneum of posterior abdominal wall.



A. The liver is retracted superiorly to expose the right adrenal mass. The retroperitoneum overlying the mass would be incised between the two arrows to expose the superior border of the gland.



B. Right adrenal vein exiting the right adrenal gland into the IVC (arrow).

FIGURE 4-5 Right laparoscopic adrenalectomy technique. IVC, Inferior vena cava.

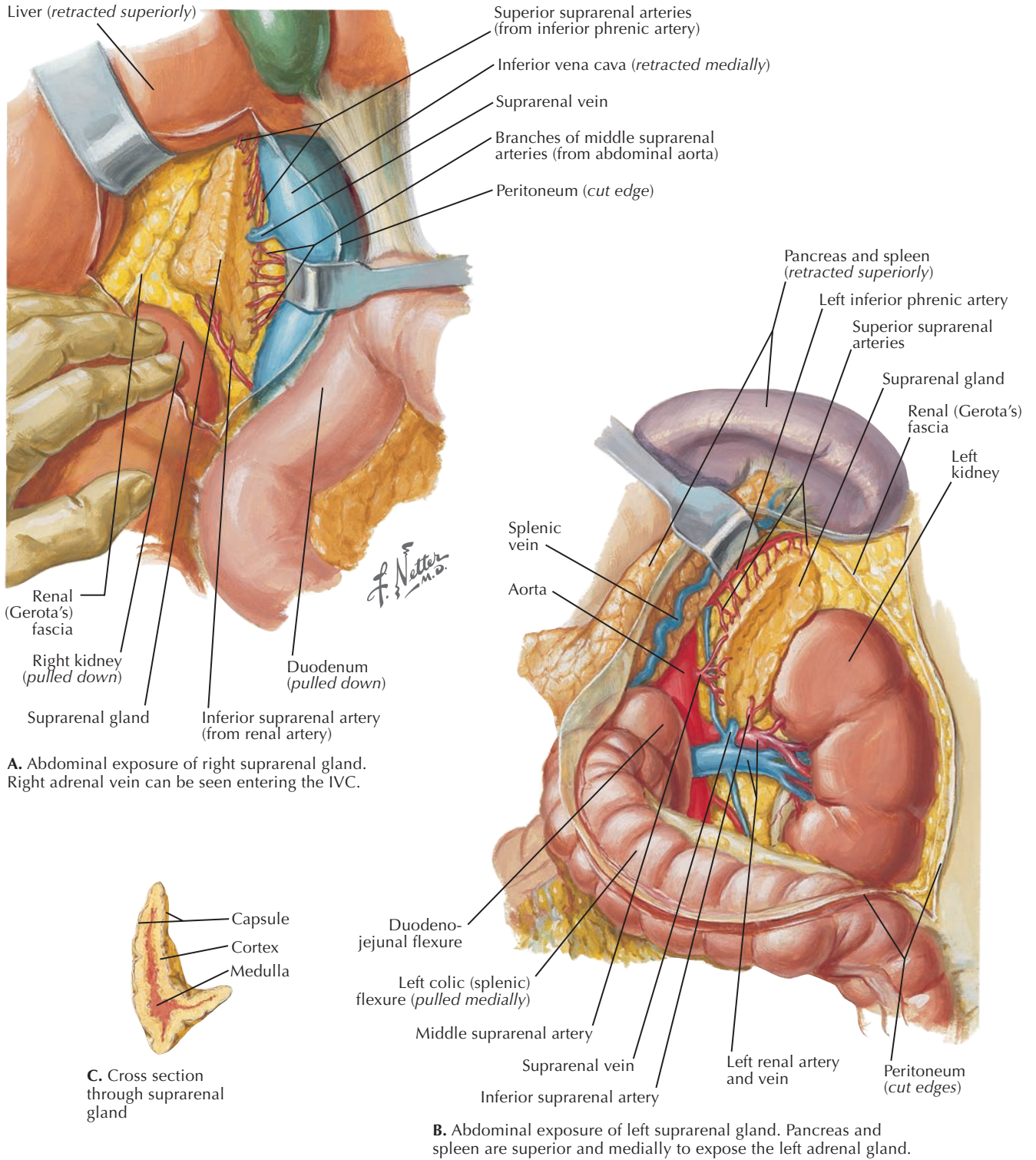
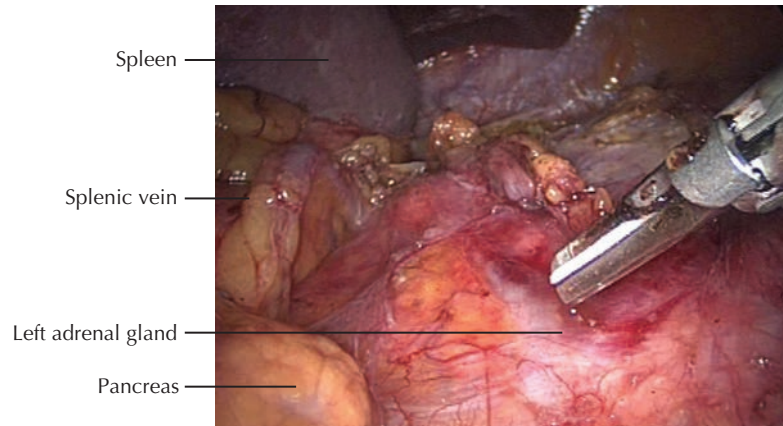


FIGURE 4-6 Arteries and veins of suprarenal glands in situ. IVC, Inferior vena cava.

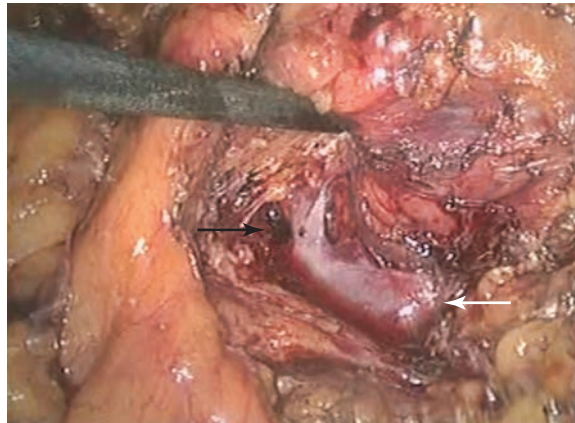
Left Laparoscopic Adrenalectomy

After ports are placed (see Fig. 4-3), the first step is to “take down” the splenic flexure of the colon and divide a portion of the gastrocolic ligament to expose the inferior border of the pancreas and Gerota’s fascia overlying the left adrenal gland and kidney. Next, the lateral attachments of the spleen are divided, allowing the spleen and pancreas to be rotated superiorly off the left adrenal gland as a unit (Fig. 4-7, A).

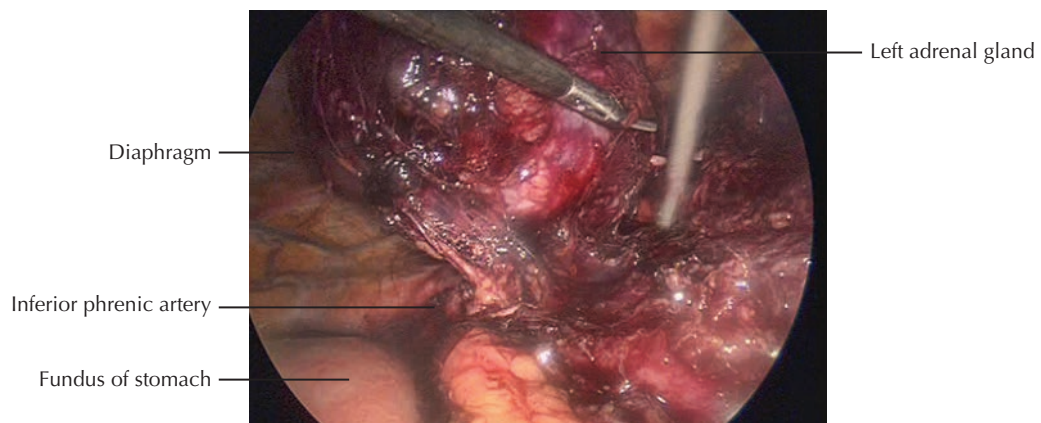
The left adrenal vein is identified as it exits the left adrenal gland and enters into the left renal vein (Fig. 4-7, B). The left adrenal vein is then divided with surgical clips. The remaining attachments to the retroperitoneum and arterial branches can then be divided with an energy device or surgical clips, as described previously for the right adrenalectomy. It is important to note the left inferior phrenic artery and vein as they descend from the diaphragm to the superior pole of the left adrenal gland, which can be prominent and may need to be divided with surgical clips (Fig. 4-7, C).



A. Pancreas, splenic vein, and spleen are seen rolled superiorly off the left adrenal gland.



B. Left adrenal vein (*black arrow*) seen entering the left renal vein (*white arrow*).



C. The left adrenal gland has been freed of all its attachments except for the superior adrenal artery (also known as the inferior phrenic artery) as it descends from the diaphragm. The fundus of the stomach can also be seen.

FIGURE 4-7 Left laparoscopic adrenalectomy technique.

SUGGESTED READINGS

Assalia A, Gagner M. Laparoscopic adrenalectomy. *Br J Surg* 2004;91(10):1259-74.

Barresi R, Prinz RA. Laparoscopic adrenalectomy. *Arch Surg* 1999;134:212-7.

Kebebew E, Siperstein AE, Clark OH, Duh QY. Results of laparoscopic adrenalectomy for suspected and unsuspected malignant adrenal neoplasms. *Arch Surg* 2002;137:948-53.

Mazzaglia PA, Veziridis MP. Laparoscopic adrenalectomy: balancing the operative indications with the technical advances. *J Surg Oncol* 2010;101(8):739-44.

National Institutes of Health (NIH). 2002 Consensus Development program. <http://consensus.nih.gov/2002/2002adrenalincidentalomas021html.htm>

Esophagectomy

Lee L. Swanstrom

INTRODUCTION

Franz Torek performed the first successful esophagectomy in 1913, after this high-risk surgery had been described 30 years with no patient survivors. Improvements in technique and patient care have reduced the mortality and morbidity, but esophagectomy remains one of the most dangerous surgeries performed, with a mortality rate of 4% to 10% and a complication rate of 20% to 60%. This dramatic risk profile results from (1) difficult anatomic position of the esophagus (Fig. 5-1), (2) involvement of three body cavities in the resection, (3) tenuous blood supply of all reconstruction options, and (4) nutrition impact on the surgical patient.

INDICATIONS

Because of the associated morbidity, most esophagectomies are performed on cancer patients (Fig. 5-2, *A and B*). Benign indications arise from absolute loss of function caused by end-stage motility disorders or from refractory strictures (Fig. 5-2, *C*). Worldwide, the primary esophageal cancer is squamous cell type, the result of dietary insults or smoking. In North America, however, this is no longer true: 80% or more of esophageal cancers are now *adenocarcinomas* related to gastroesophageal reflux and Barrett syndrome (metaplasia).

Radical resectional surgery remains the only cure for invasive esophageal cancers that are relatively resistant to radiation and chemotherapy. Neoadjuvant chemoradiation, however, is gaining popularity as a treatment for stage II and stage III cancers, although the survival benefit is not great. Overall, the 5-year survival rate for esophageal cancer is dismal: 18% for all patients and 25% for those able to have surgery.

Preemptive esophagectomy for patients with Barrett syndrome with high-grade dysplasia once was the most frequent indication for esophagectomy at most high-volume centers. This is no longer the case; endoscopic treatments such as radiofrequency ablation and cryotherapy are now effective low-morbidity alternatives.

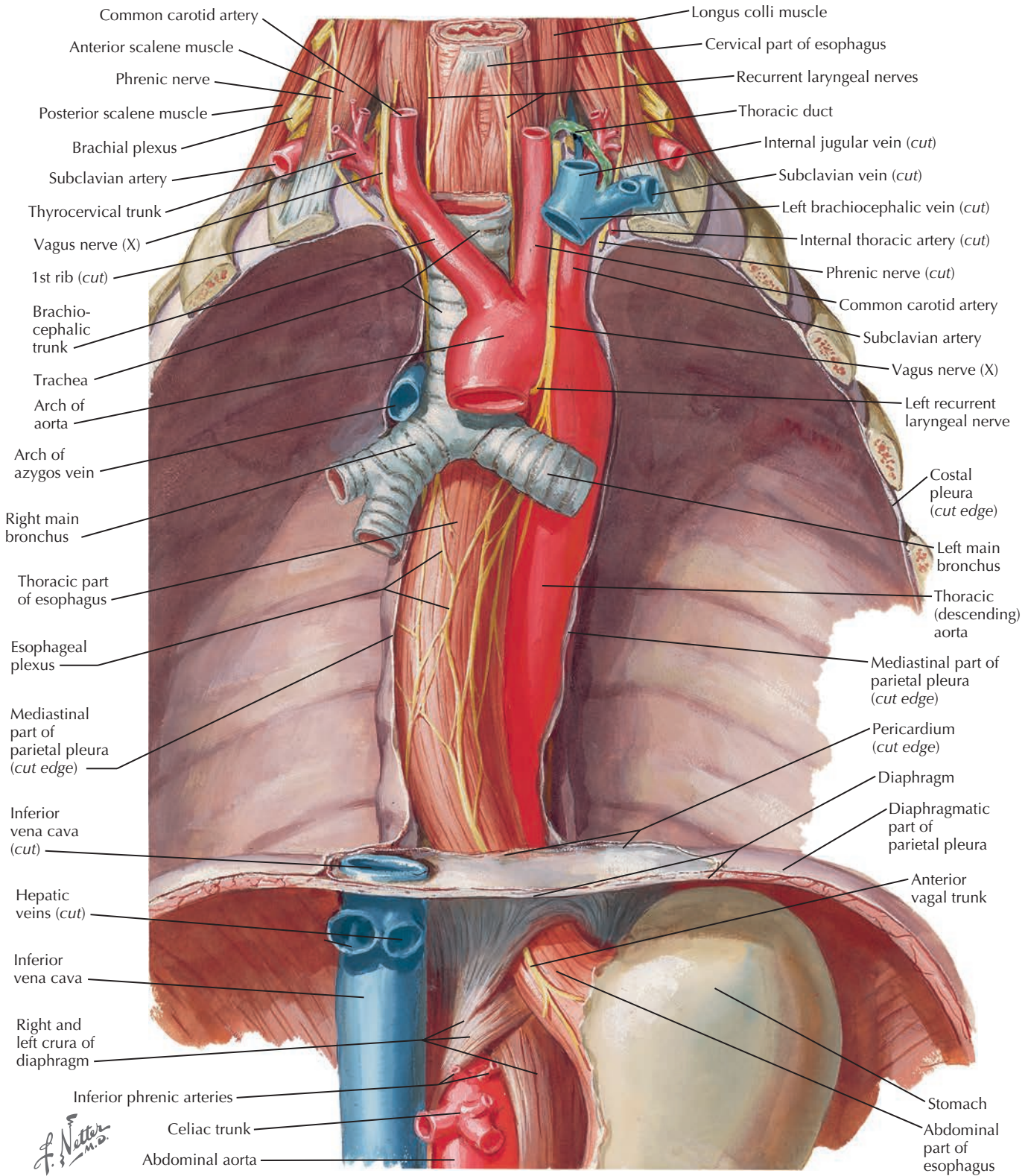
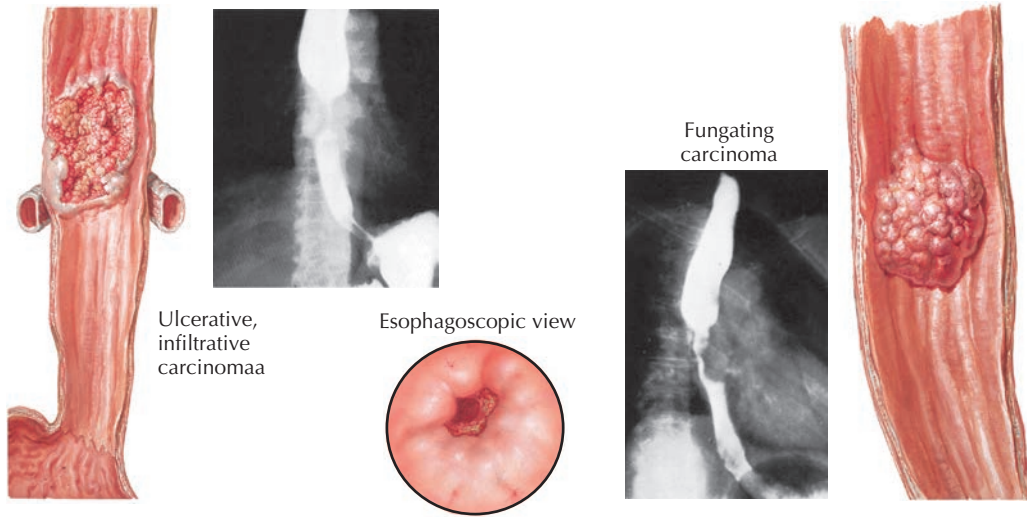
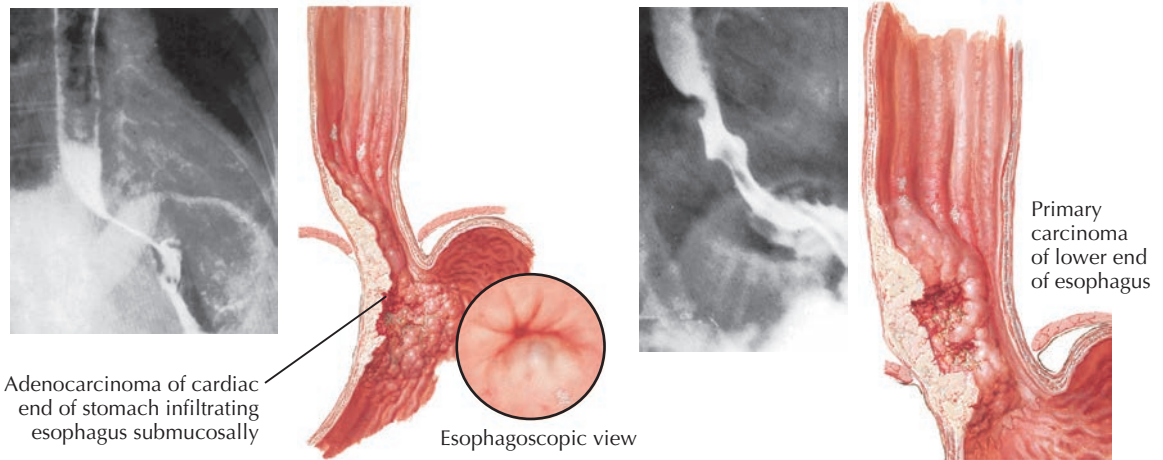


FIGURE 5-1 Esophagus in situ.

A. Malignant tumors of midportion of esophagus



B. Malignant tumors of distal portion of esophagus



C. Esophageal stricture

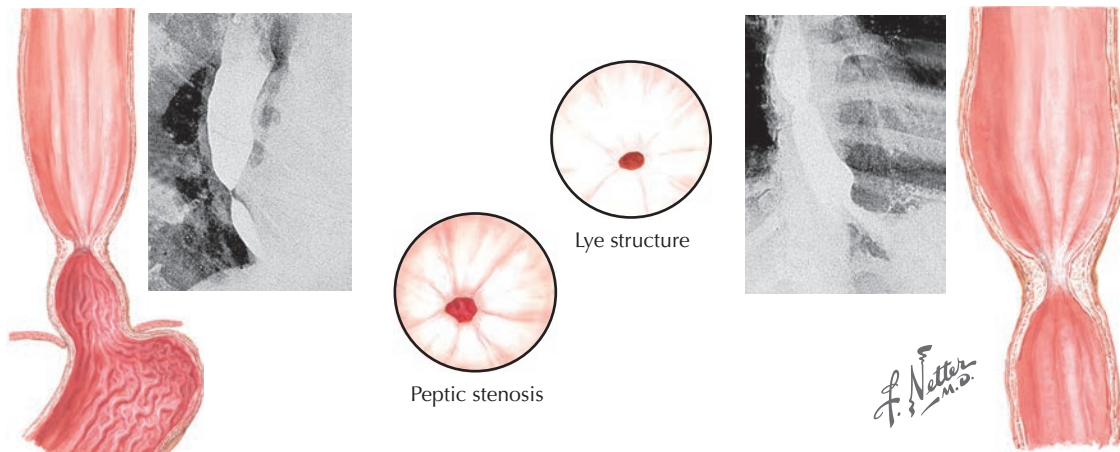


FIGURE 5-2 Indications for esophagectomy.

SURGICAL APPROACHES

Active controversy surrounds the necessity for surgery, with minimalists stressing the morbidity of radical surgery and the poor survival statistics for patients with esophageal cancers. Recently, however, the trend has been for more radical en bloc resections, which offer survival advantages for patients with some early-stage cancers.

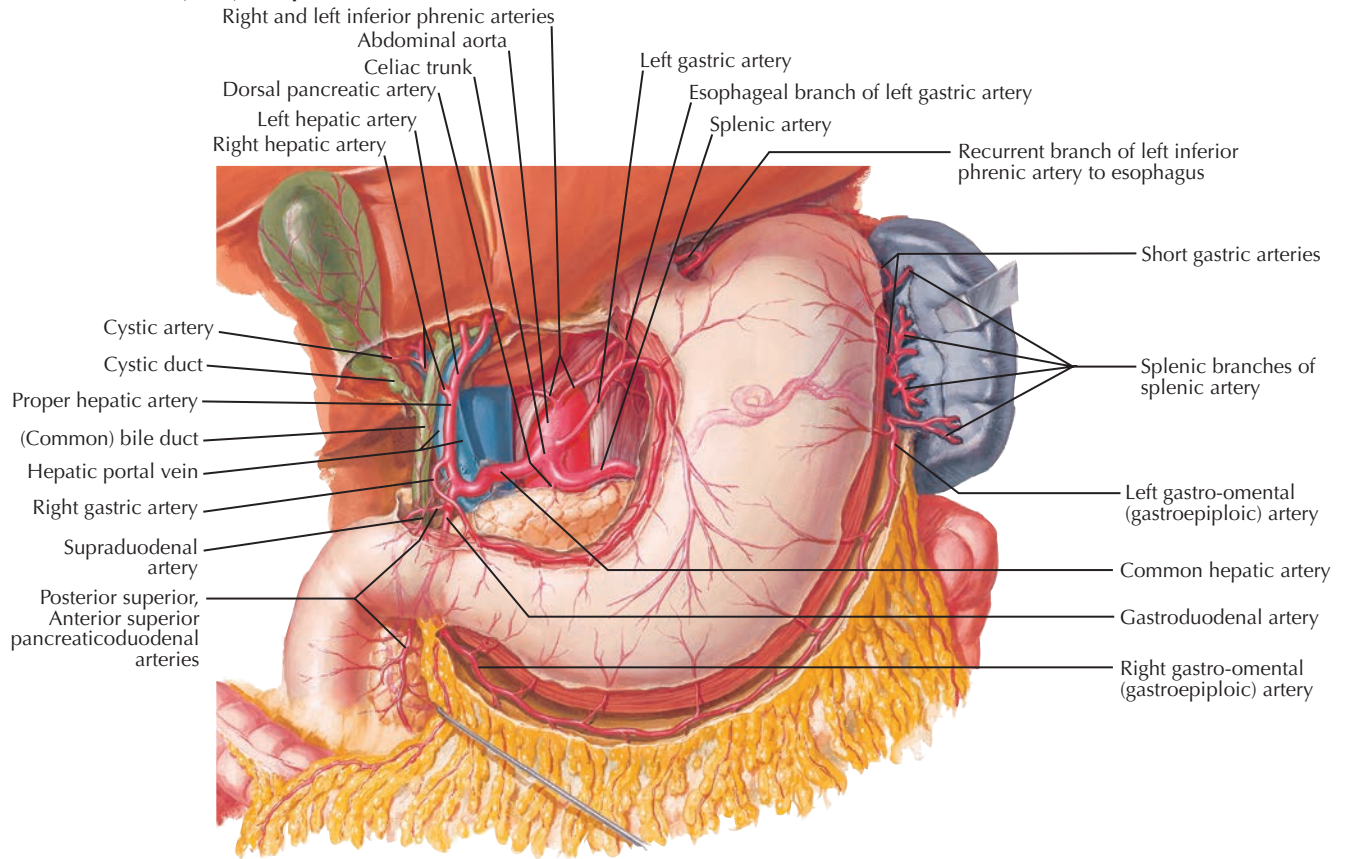
The three main approaches to esophagectomy are *transhiatal*, *Ivor Lewis*, and “three-hole,” or *modified McKeown*. Increasingly, all three approaches are performed with laparoscopy or thoracoscopy for an approach called *minimally invasive esophagectomy* (MIE). Choosing among the three approaches depends partly on the surgical indication (e.g., transhiatal approach for benign and low-grade cases), stage of cancer, and location of the tumor. The approach is mostly determined by institutional and surgeon preference, because no overwhelming evidence exists to demonstrate that one approach is dramatically better than the others.

Reconstruction of the resected esophagus is most often performed using the stomach, either tubularizing it or as a “whole-stomach” interposition. Less frequently, a colonic interposition is used, and, rarely, a jejunal interposition, often with microvascular augmentation. Because the vascularity of any of these conduits is tenuous at best, the surgeon needs to be familiar with the other esophageal replacement options.

TRANSHIATAL ESOPHAGECTOMY

The transhiatal esophagectomy is performed with the patient supine and the left side of the neck prepped and exposed. Either an upper midline incision or, increasingly, a five-port laparoscopic access is performed. Exploration is performed to rule out disseminated tumor, which would obviate resection in most cases. The greater curvature of the stomach is retracted anteriorly, and the gastrocolic omentum is divided from the spleen to the hepatic flexure, wide of the gastroepiploic blood supply, which is critical for the viability of the gastric graft (Fig. 5-3, A). Once the greater curvature is fully mobilized, the retrogastric adhesions to the peritoneum are divided. The lesser curvature of the stomach is then mobilized, a Kocher maneuver is performed to mobilize the duodenum, and the gastrohepatic ligament is divided near its attachment to the liver (Fig. 5-3, B). This exposes the D1 node area, which is routinely dissected.

A. Arteries of stomach, liver, and spleen



B. Arteries of stomach, duodenum, pancreas, and spleen

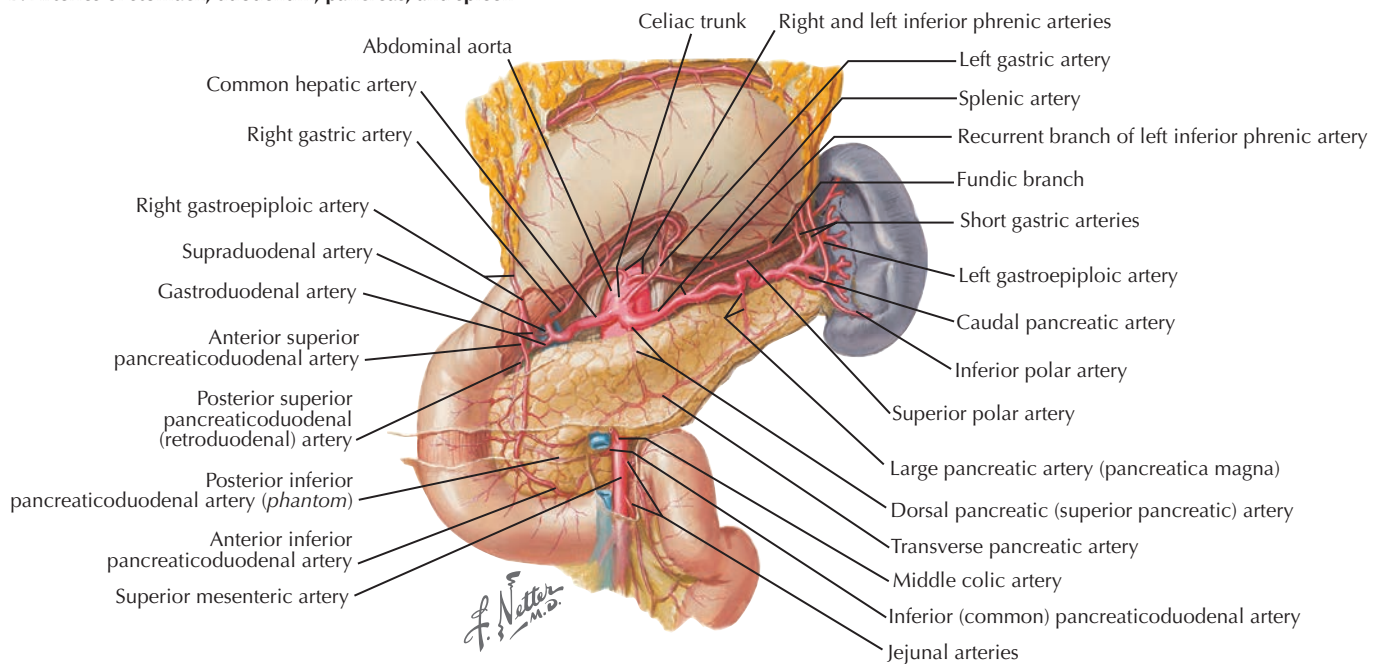


FIGURE 5-3 Anatomy of the lesser curve, second portion of the duodenum, and gastrohepatic ligament (stomach is rotated cephalad).

TRANSHIATAL ESOPHAGECTOMY—Cont'd

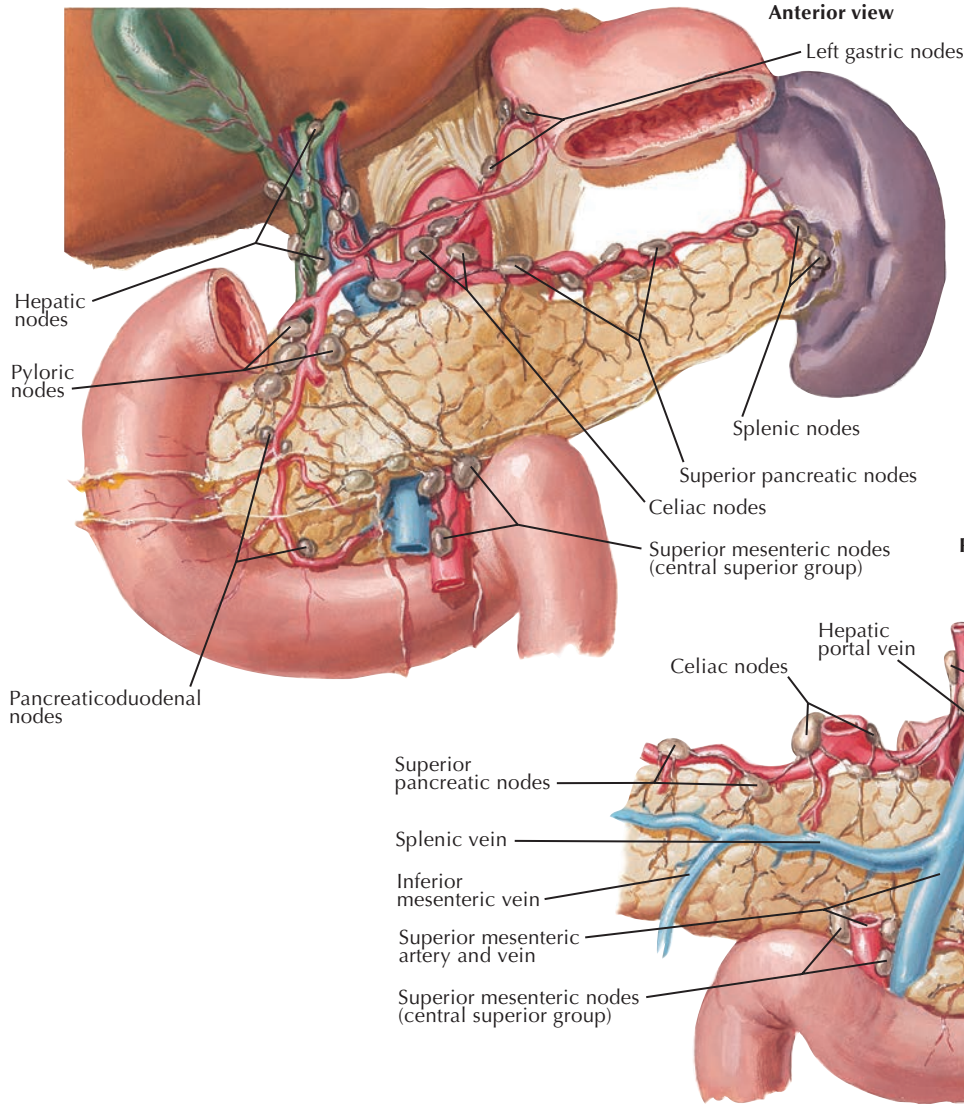
Node dissection margins include the porta hepatis (hepatic portal) structures, the hepatic artery, and the vena cava (Fig. 5-4, A). Dense nodal tissue around the base of the left gastric artery is dissected, and the coronary vein and left gastric artery are divided with an energy sealing device, stapler, or suture ligation. Node tissue is left in continuity with the specimen. The hiatus is typically opened by excising a rim of the hiatal musculature and entering the mediastinum in the plane of the mediastinal pleura, pericardium, and preaortic and prespinal planes. This maneuver is more feasible with a laparoscopic approach and allows good lymphatic clearance of the lower mediastinum.

Open transhiatal surgery is performed by the surgeon, with the smallest hand on the team cupping the esophagus in the extended fingers and bluntly stripping the esophagus up to the proximal mediastinum. Care must be taken at the upper end of the blind dissection to avoid injury to the recurrent laryngeal nerve or membranous portion of the trachea (see Fig. 5-1).

Laparoscopic mediastinal dissection is performed by advancing the angled laparoscope into the mediastinum with the surgeon's instruments. At the same time, a 5- to 7-cm incision is made in the left side of the neck from the sternal notch along the anterior margin of the sternocleidomastoid muscle (Fig. 5-4, B). The platysma muscle is divided and the sternocleidomastoid is retracted laterally (Fig. 5-4, C). After dividing the omohyoid muscle, the esophagus is located and surrounded by a soft drain. The upper mediastinal dissection is performed with lubricated gauze on a long, curved vascular clamp to meet with the dissection from below.

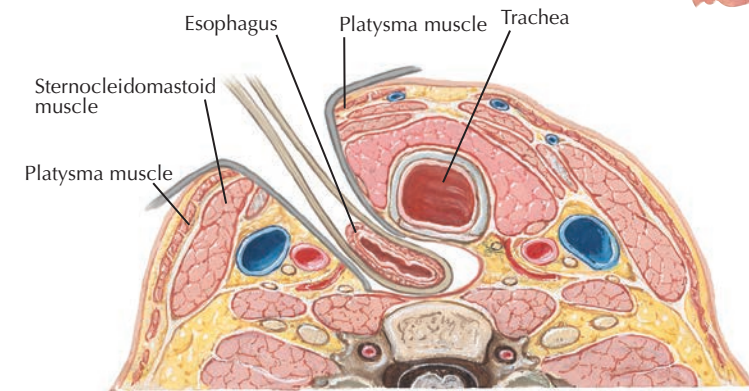
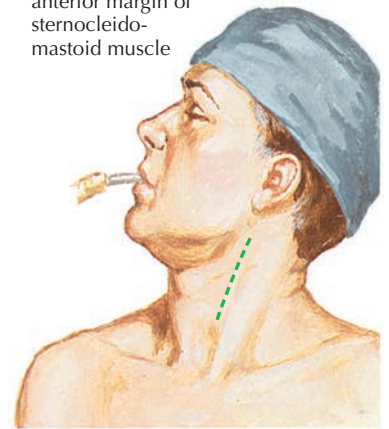
The gastric conduit is prepared by grasping the longest portion of the gastric cardia and stretching it into the left upper quadrant. Starting at the "crow's foot," a green load linear staple is used to divide the stomach parallel to the greater curvature to create a 3- to 4-cm gastric conduit (Fig. 5-4, D). Once transected, the specimen is placed in a plastic specimen bag and withdrawn through the neck. A chest tube is inserted through the neck and into the abdomen, and the gastric conduit is sutured to it and pulled up into the neck. A hand-sewn or stapled anastomosis is created to restore continuity.

A. Lymph vessels and nodes of pancreas

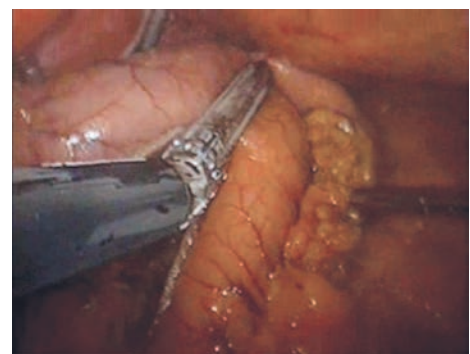


B. Patient position

Head to side; incision along anterior margin of sternocleidomastoid muscle



C. Surgical approaches to esophagectomy



D. A green load linear staple is used to divide the stomach parallel to the greater curve to create a 3- to 4-cm gastric conduit.

FIGURE 5-4 Transhiatal esophagectomy.

IVOR LEWIS AND MCKEOWN APPROACHES

The McKeown and Ivor Lewis approaches both require transthoracic access, either by a posterolateral thoracotomy in the 6th intercostal space or by thoracoscopy. The Ivor Lewis approach is defined by an intrathoracic anastomosis, whereas the McKeown procedure brings the anastomosis up to the neck. The order in which the dissection is performed also differs between techniques. The Ivor Lewis approach addresses the gastric mobilization first, then proceeds with the thoracic (or thoracoscopic) mobilization and intrathoracic anastomosis. The modified McKeown procedure uses right thoracoscopy or thoracotomy to dissect out the mediastinal esophagus, with or without an en bloc lymph node dissection.

The patient is then repositioned to allow the abdominal dissection and gastric conduit creation. In this procedure the left side of the neck is exposed, often by a second operating team, and a gastric conduit is created along the greater curve of the esophagus. This is then brought to the neck to perform the anastomosis.

Ivor Lewis Esophagectomy

The patient is positioned supine for the Ivor Lewis esophagectomy, and in the case of a laparoscopic procedure, in split-leg position. The abdomen is accessed through an upper abdominal incision or by five-port upper abdomen laparoscopic placement.

After a careful staging examination, the left lobe of the liver is retracted to expose the stomach. For potentially curative resections for cancer, we routinely perform a D1 or D2 lymph node dissection. For benign resections, the goal is to stay on the stomach and esophagus to prevent ancillary damage.

The gastrocolonic omentum is divided, staying 1 to 2 cm away from the critical gastroepiploic vessels of the greater curvature of the stomach (see Fig. 5-3, A). This dissection is extended medially past the second portion of the duodenum and laterally to the inferior pole of the spleen. This allows the stomach to be reflected anteriorly, exposing the lesser sac to allow the surgeon to check for metastatic disease, and exposes the right gastric artery to allow dissection of station 8 lymph nodes, if indicated (see Fig. 5-4, A). The greater curvature of the stomach is further mobilized by dividing the short gastric vessels, once again wide of the gastric margin. This dissection is taken to the left crus. For the lesser curvature, the gastrohepatic omentum is divided from the 2nd part of the duodenum up to the right crus. The base of the left gastric artery is identified either from the right side of the stomach or from underneath the stomach. It is skeletonized and divided to provide access to the preaortic plane, which will be extended into the mediastinum.

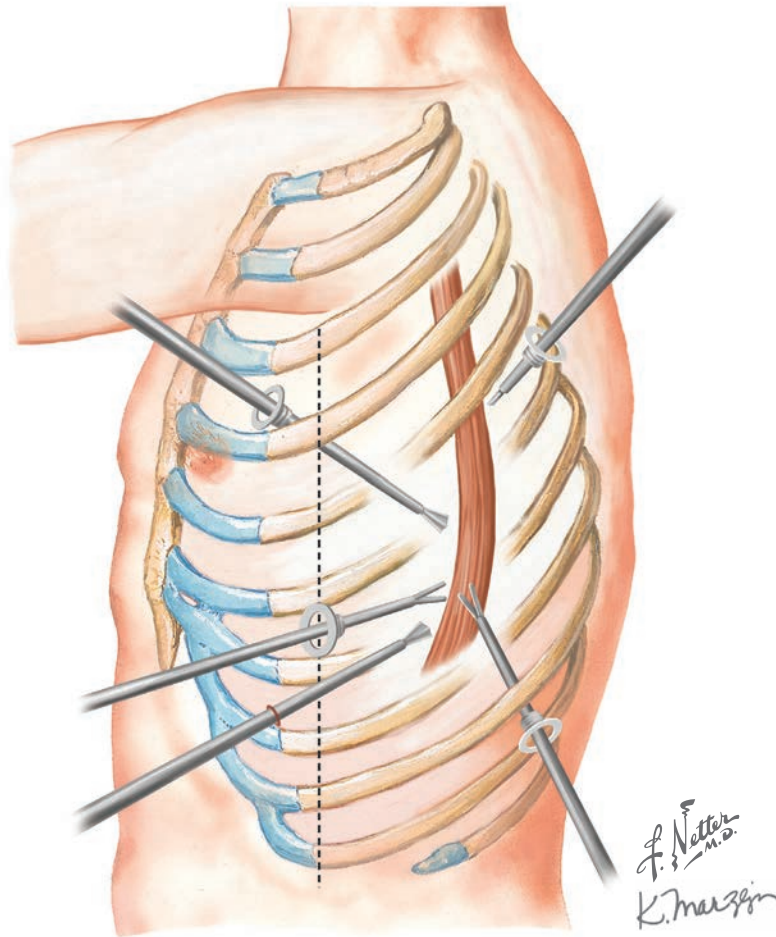


FIGURE 5-5 Ivor Lewis esophagectomy: five-port laparoscopic placement.

Ivor Lewis Esophagectomy—Cont'd

The gastric interposition is created by stapling the stomach as described for transhiatal esophagectomy, except that the final staple load to separate the fundus is not fired. The esophageal hiatus is dissected several centimeters into the mediastinum. Lastly, a feeding jejunostomy tube is placed by tacking the jejunum to the anterior abdominal wall and accessing it percutaneously with a guidewire and then a dilator with peel-away sheath that allows placement of a 12-Fr catheter. Addition of a pyloroplasty to improve gastric emptying is controversial. In general, if a wide gastric tube or whole-stomach pull-up is used, a pyloroplasty is performed. If a narrow gastric tube is created, theoretically a pyloroplasty is unnecessary because physical properties enable better emptying.

The patient is then repositioned in a left lateral decubitus position to allow access to the right side of the chest (5th intercostal posterolateral thoracotomy or four-port thoracoscopy). The right mediastinal pleura is widely excised in continuity with the esophagus. The esophagus is isolated away from the tumor and surrounded by a plastic drain for retraction. A wide resection of the esophagus is performed, incorporating surrounding node-bearing tissues with the specimen (Fig. 5-5). The esophagus is divided above the azygos vein, high in the mediastinum, with an endoscopic linear cutting stapler. The specimen is pulled up into the chest, along with the attached gastric conduit. A staple or hand-sewn anastomosis is performed, according to surgeon preference.

Modified McKeown (Three-Hole) Esophagectomy

The modified McKeown approach begins with thoracic mobilization. Therefore, if not routinely used by the surgeon, it is certainly the best choice for middle and upper cancers or when thoracic staging is important to determine resectability.

The three-hole procedure begins with the patient in the left lateral decubitus position with the arm carefully positioned overhead. A 5th or 6th intercostal posterolateral thoracotomy is done or a four-port thoracoscopic access is created. Wide resection of the right mediastinal pleura leaves the pleura with the esophagus, particularly over the area of the tumor. The azygos vein is typically divided with ties or a vascular stapler (Fig. 5-6, A). The esophagus is surrounded with a drain for retraction, and with the use of cautery or ultrasonic coagulating shears, the esophagus with all of its surrounding lymph node-bearing tissues is progressively mobilized.

Controversy surrounds the required extent of the dissection. Some argue that both the azygos vein and thoracic duct need to be resected with the periesophageal tissue, whereas others believe that only the periesophageal nodes require resection (Fig. 5-6, B). The proximal dissection should be taken as far as possible into the thoracic outlet and the distal dissection down to the crura.

Particular care must be taken throughout the mediastinal dissection because there are multiple critical structures, particularly in the more proximal mediastinum. In the area of the carina the particularly dense and vascular node tissue can bleed, and proximally the membranous trachea can be easily injured, with disastrous results. The aortic arch, recurrent laryngeal nerve, pulmonary hilum, and pericardium also must be safeguarded.

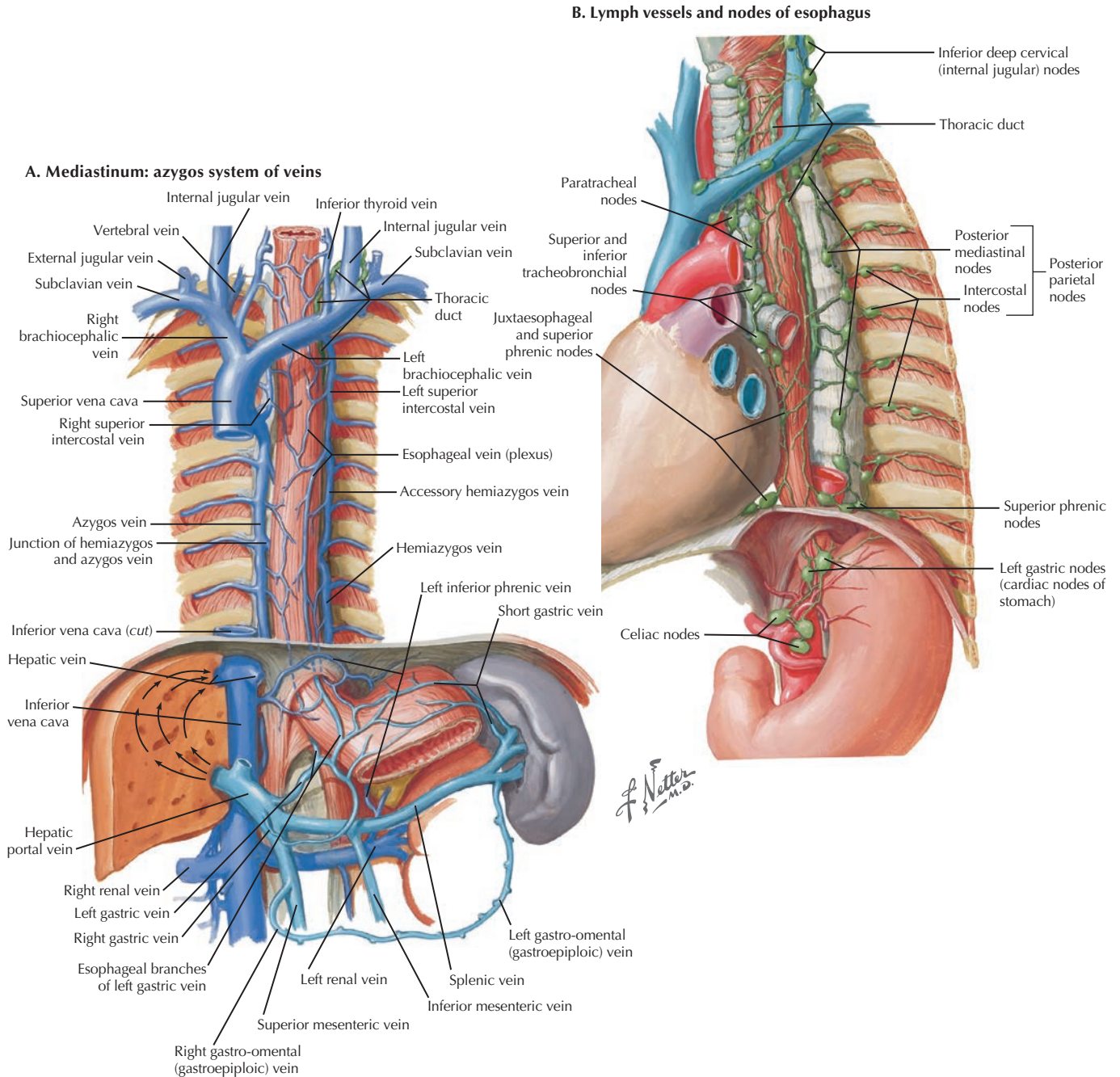


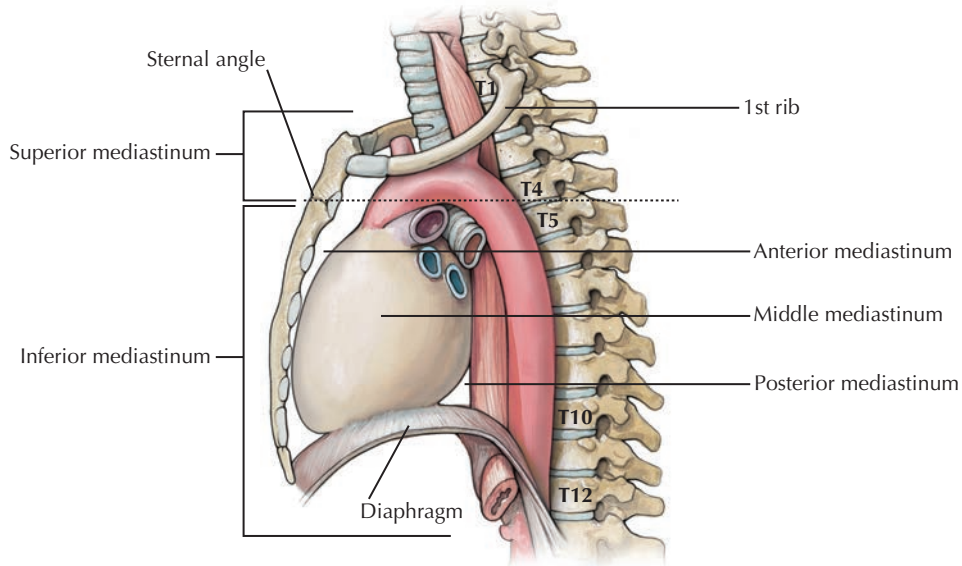
FIGURE 5-6 Modified McKeown esophagectomy: azygos system of veins and esophageal lymph nodes/vessels.

Modified McKeown (Three-Hole) Esophagectomy—Cont'd

Once the thoracic dissection is complete, a chest tube is left inside the patient and the chest is closed. The patient is repositioned supine as described for transhiatal esophagectomy. Gastric mobilization is done and an interposition conduit is created as previously described. Once again, the final staple load to transect the stomach is not done. A second team will typically open the left side of the neck and surround the esophagus.

The upper esophageal dissection is performed by staying on the esophagus and using mostly blunt dissection. Care must be taken to avoid the recurrent laryngeal nerve in this area as well (Fig. 5-7, B). Small tumors can be brought out through the neck incision, pulling the interposition up at the same time. Larger cancers should be pulled into the abdomen, placed in an impermeable specimen bag, and withdrawn through a small abdominal incision. The anastomosis is performed with staples (circular or double linear firing) or is hand-sewn. Drains are placed and the incisions are closed.

A. Subdivisions and mediastinum



B. Nerves of heart

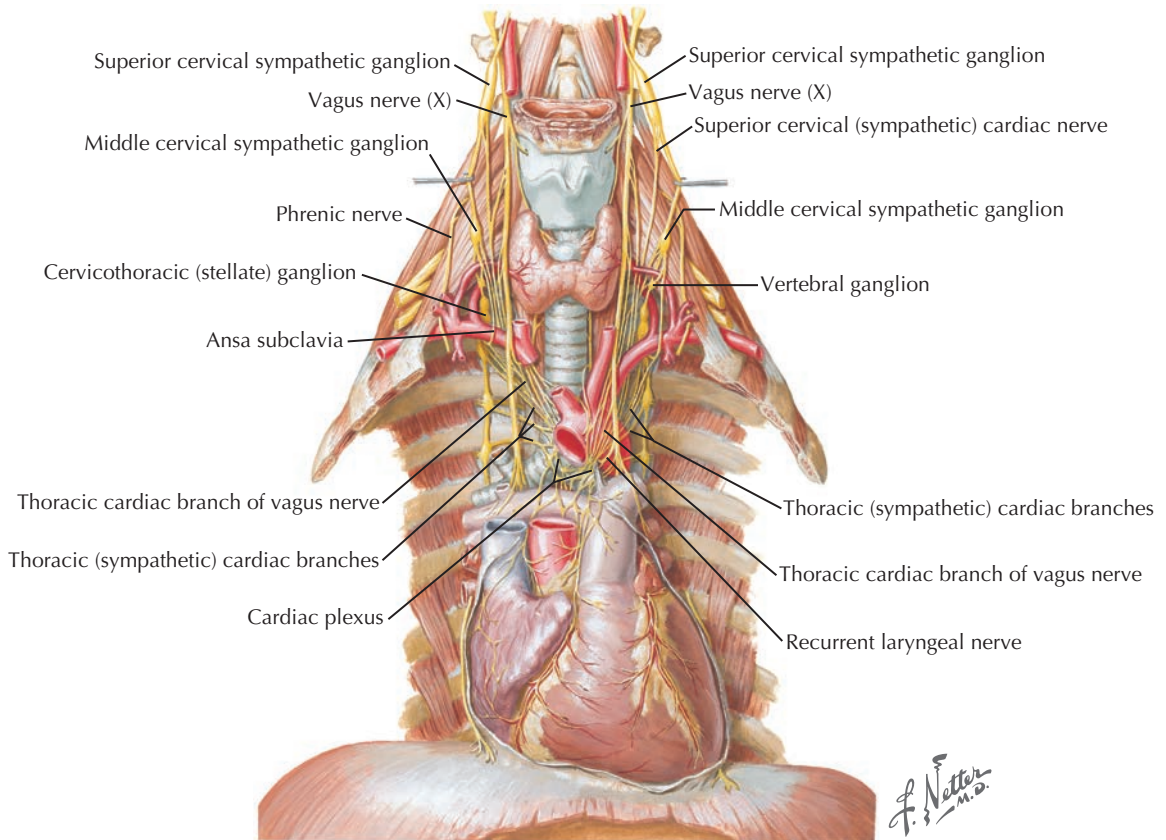


FIGURE 5-7 Subdivisions of mediastinum and cardiac nerves. *T*, Thoracic vertebra.

SUGGESTED READINGS

- Bogoevski D, Bockhorn M, Koenig A, et al. How radical should surgery be for early esophageal cancer? *World J Surg* 2011;35(6):1311-20.
- Briez N, Piessen G, Bonnetain F, et al. Open versus laparoscopically assisted oesophagectomy for cancer: a multicentre randomised controlled phase III trial: the MIRO trial. *BMC Cancer* 2011;11:310.
- Defoe SG, Pennathur A, Flickinger JC, et al. Retrospective review of patients with locally advanced esophageal cancer treated at the University of Pittsburgh. *Am J Clin Oncol* 2011;34(6):587-92.
- Jaroszewski DE, Williams DG, Fleischer DE, et al. An early experience using the technique of transoral OrVil EEA stapler for minimally invasive transthoracic esophagectomy. *Ann Thorac Surg* 2011;92(5):1862-9.
- Ng T, Vezeridis MP. Advances in the surgical treatment of esophageal cancer. *J Surg Oncol* 2010;101(8):725-9.
- Palmes D, Brüwer M, Bader FG, et al. Diagnostic evaluation, surgical technique, and perioperative management after esophagectomy: consensus statement of the German Advanced Surgical Treatment Study Group. *Langenbecks Arch Surg* 2011;396(6):857-66.
- Wajed SA, Veeramootoo D, Shore AC. Surgical optimisation of the gastric conduit for minimally invasive oesophagectomy. *Surg Endosc* 2012;26(1):271-6.

Nissen Fundoplication

Benjamin K. Poulouse and Michael D. Holzman

INTRODUCTION

Gastroesophageal reflux disease (GERD) remains one of the most common diseases for which patients seek medical attention. Identifying suitable candidates for surgical management of GERD is a complex process involving documentation of pathologic reflux, assessment of esophageal motility, and discussion of postoperative expectations with patients. The surgical approach to GERD serves to reestablish the original anatomic barriers to reflux, supplemented by fundoplication. The 360-degree fundoplication originally proposed by Rudolph Nissen in the mid-20th century remains the standard by which interventional approaches to GERD are measured.

SURGICAL PRINCIPLES

The goals of successful surgical management of GERD are to restore the intraabdominal esophagus, repair the diaphragmatic crura, and reestablish a competent lower esophageal sphincter. A thorough understanding of hiatal anatomy, upper abdominal organ relationships, and mediastinal structures is critical to safe and effective operations for GERD (Figs. 6-1 to 6-3). Restoration of the lower esophageal sphincter is usually accomplished with a “floppy” 360-degree (Nissen) fundoplication formed around the distal esophagus.

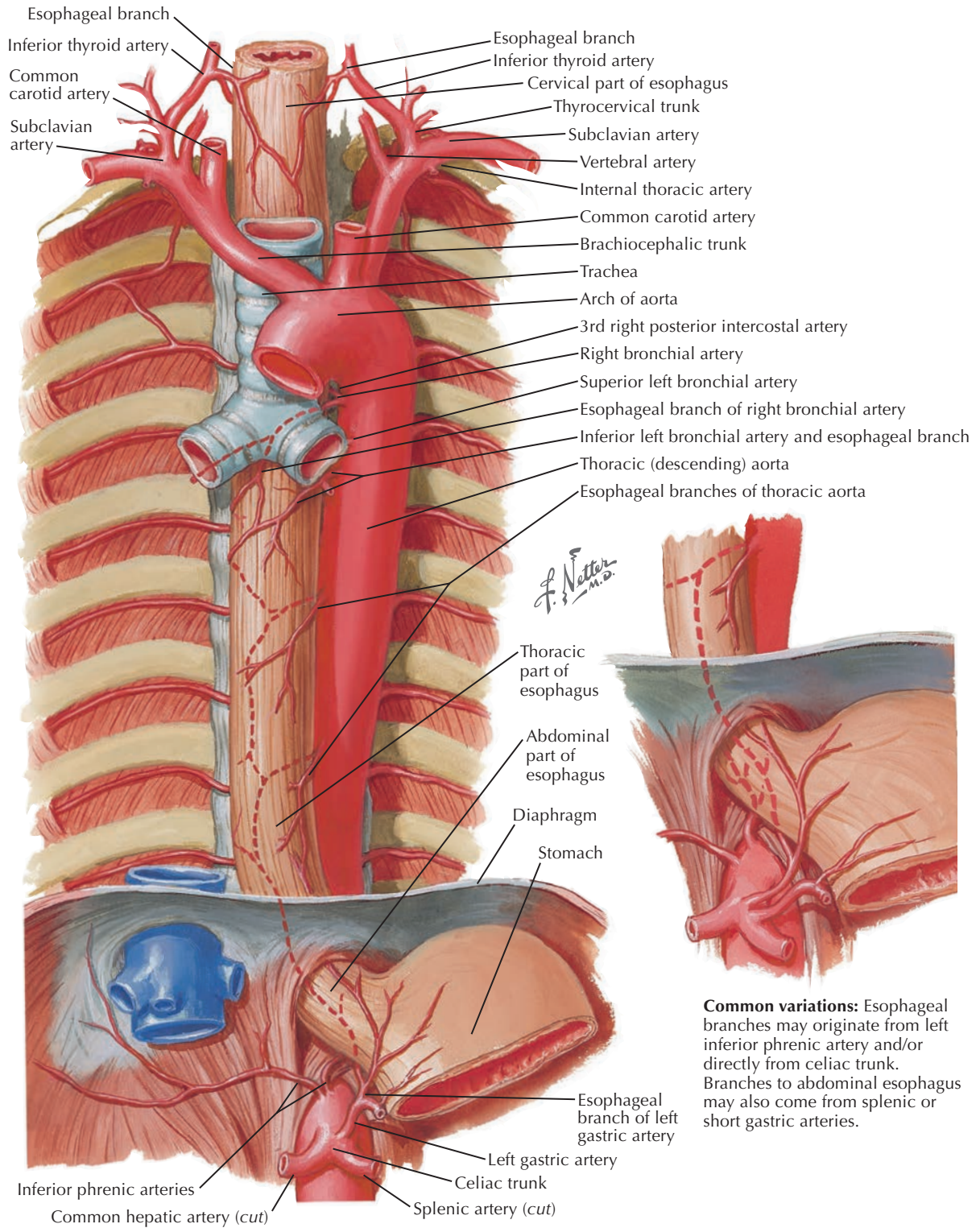


FIGURE 6-1 Arteries of esophagus.

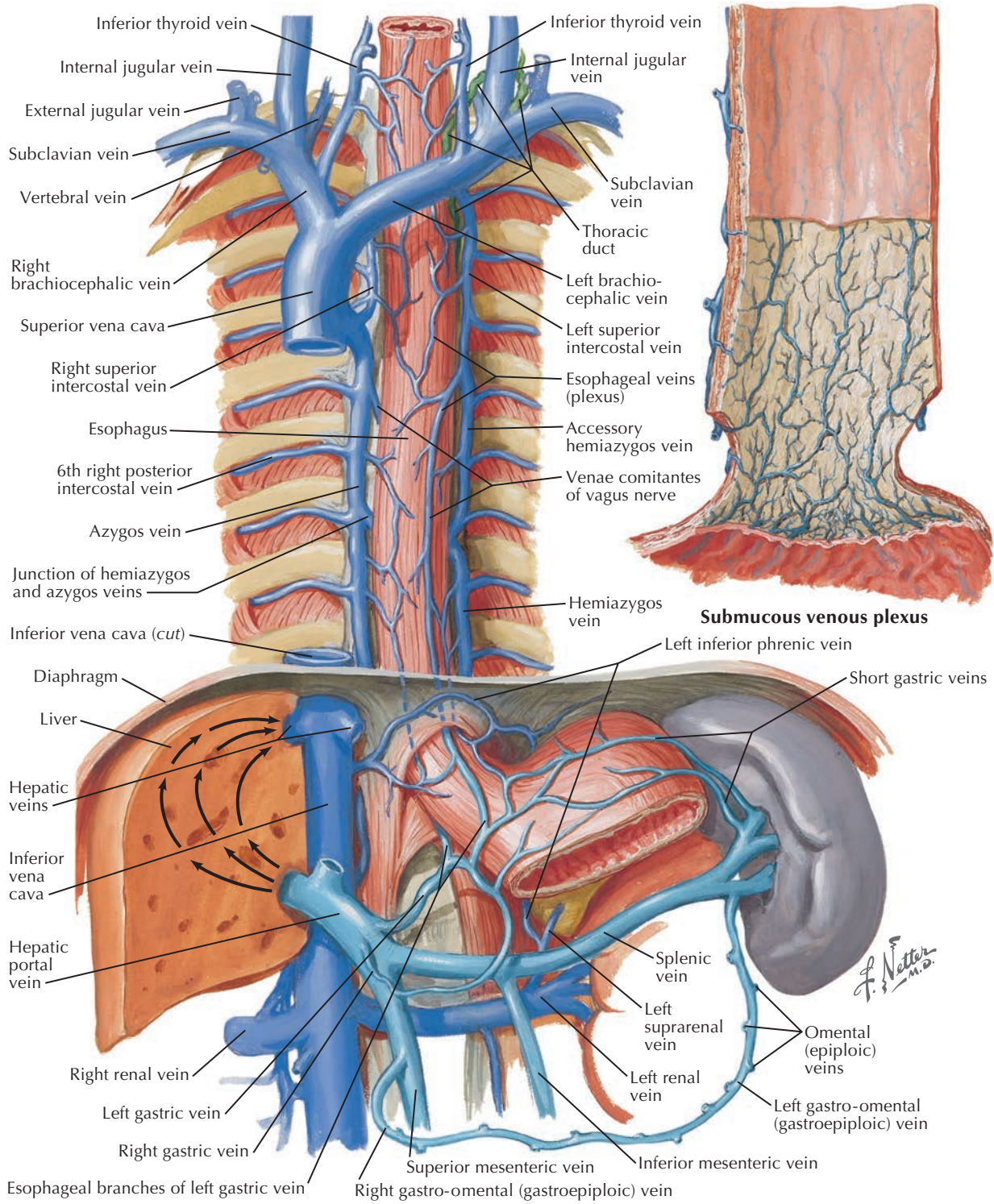


FIGURE 6-2 Veins of esophagus.

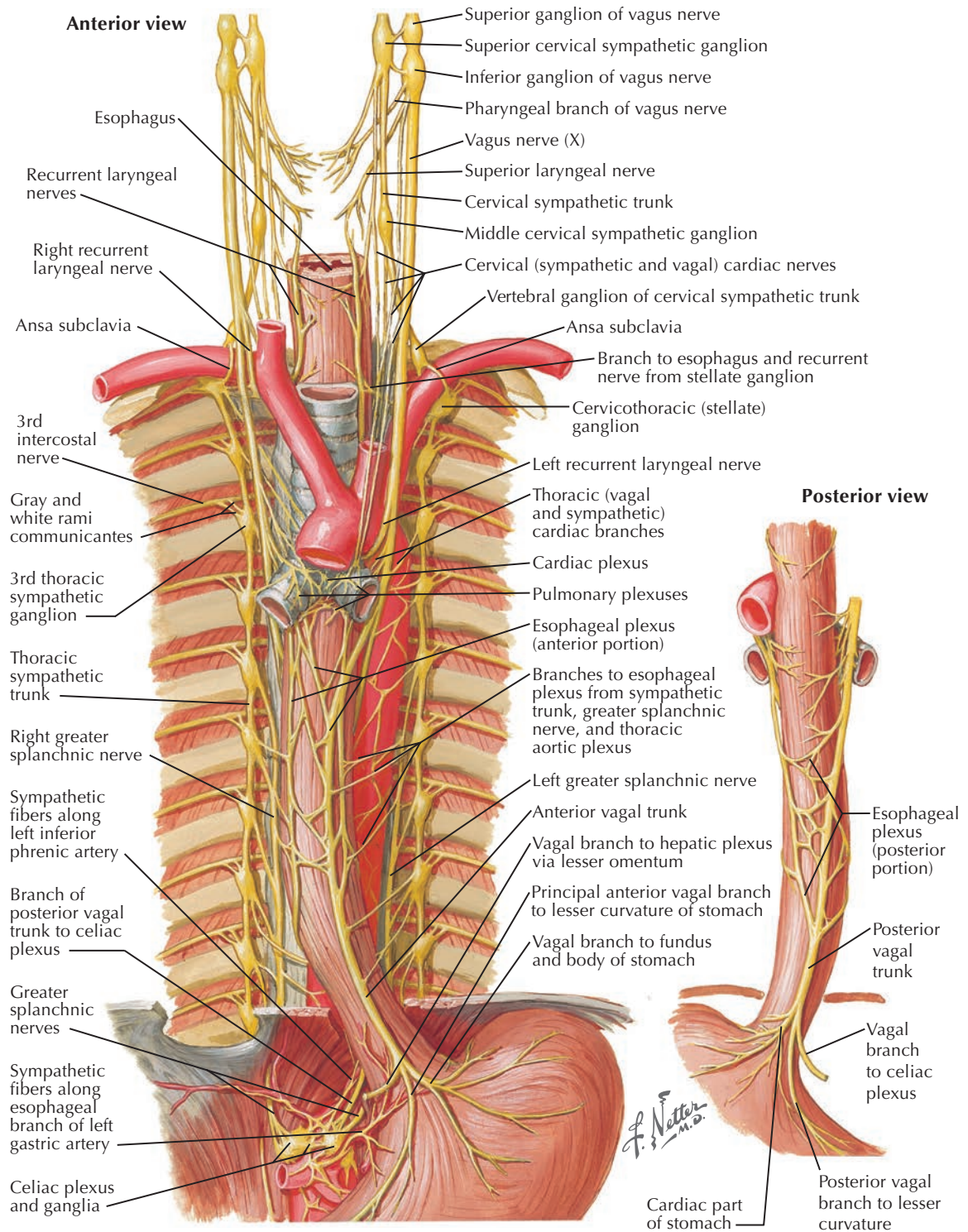
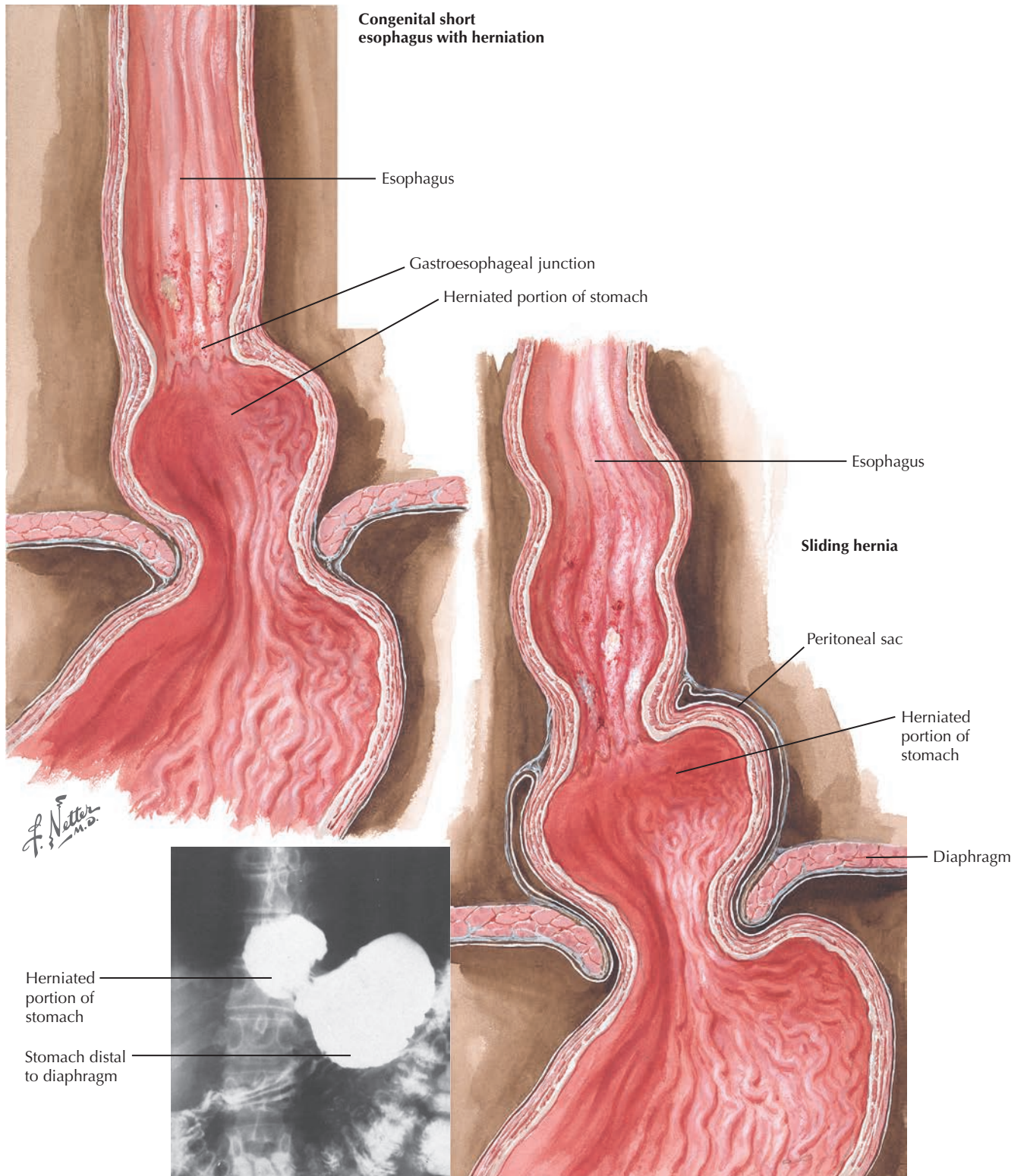


FIGURE 6-3 Innervation of esophagus.

PREOPERATIVE STUDIES

Preoperative studies include upper endoscopy, upper gastrointestinal (GI) series, esophageal manometry, and pH testing. Esophageal impedance may help identify patients with pathologic nonacid reflux. Patients with chronic nausea and emesis may benefit from a gastric emptying study to ascertain whether gastroparesis contributes to their symptomatology.

Upper endoscopy can reveal intraluminal pathology that can alter surgical decision making and can help ascertain anatomic changes that would impact the operation for GERD. The most common anatomic abnormality seen in this setting is the *sliding*, type I hiatal hernia (Fig. 6-4). Upper endoscopy can also reveal a shortened esophagus. The upper GI series also helps define anatomic abnormalities and is useful when more complex hiatal hernias are noted (types II-IV). Testing for acid exposure, nonacid reflux, and assessment of esophageal motility are also important nonimaging modalities that help in preoperative decision making.



The most common anatomic abnormalities encountered during the operative management of gastroesophageal reflux disease include the sliding hiatal hernia and shortened esophagus.

FIGURE 6-4 Sliding hiatal hernia.

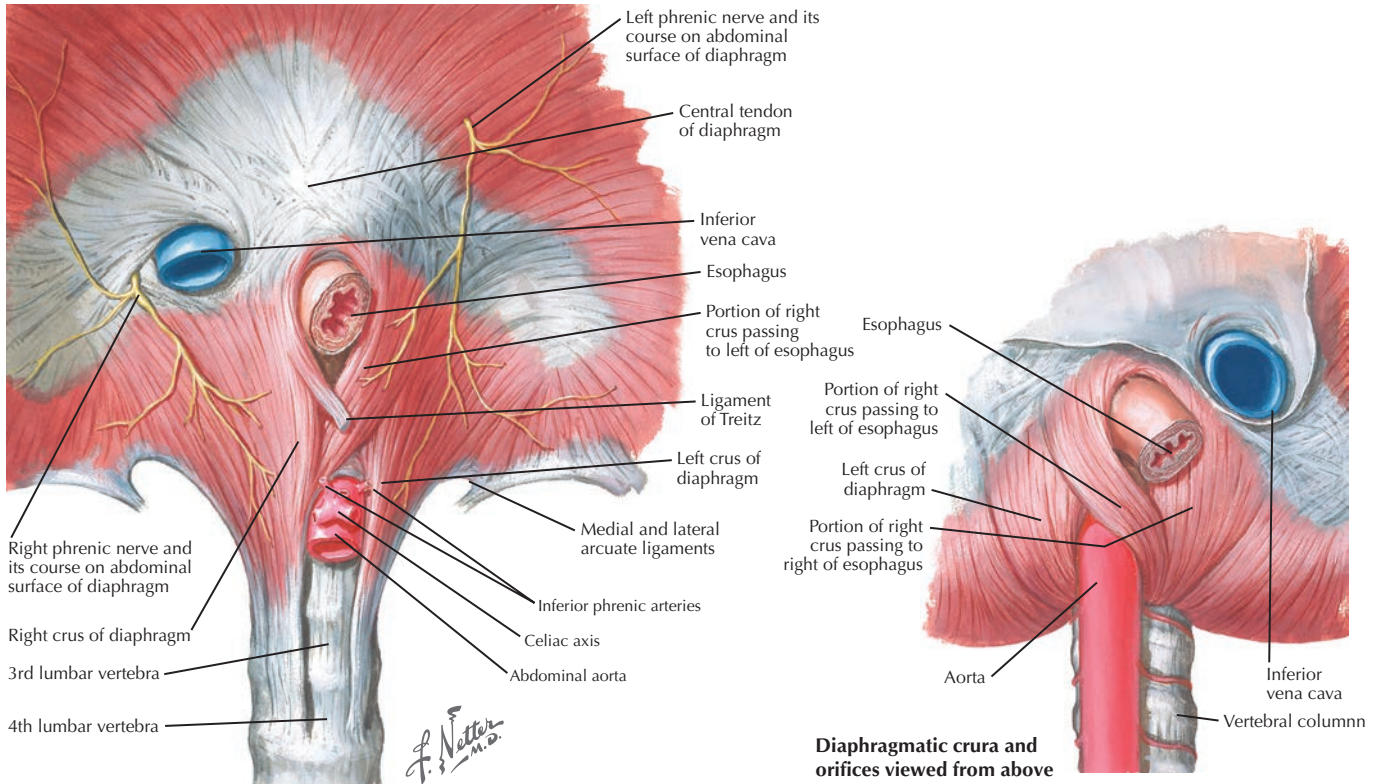
ANATOMY FOR ESOPHAGEAL MOBILIZATION

Adequate esophageal mobilization is important to ensure that sufficient esophagus is present within the abdomen for fundoplication. The end goal of these steps is to confirm at least 4 to 5 cm of esophagus below the diaphragm with circumferential mobilization of the esophagus from surrounding tissues and structures.

Diaphragmatic Crura (Superior and Inferior Views)

In most patients the fibers of the right crus of the diaphragm encircle the esophagus, making the right and left pillars of the right crus the pertinent structures of the esophageal hiatus (Fig. 6-5, *A*). Abdominal exposure of the right crus is usually obtained by retraction of the left lobe of the liver anteriorly and by incision of the filmy pars flaccida. The right pillar is usually readily identified and bluntly separated from the esophagus (Fig. 6-5, *B*). If a sizable hiatal hernia is encountered, the plane between the hernia sac and mediastinal structures is developed while preserving healthy endoabdominal fascia overlying the pillars of the crus.

A. Relationships of the right and left crura of the diaphragm. Note that the right and left pillars of the right crus form the esophageal hiatus.



Diaphragmatic crura and orifices viewed from below

Diaphragmatic crura and orifices viewed from above

B. Anterior retraction of the liver and division of the pars flaccida facilitate exposure of the right pillar of the right diaphragmatic crus.

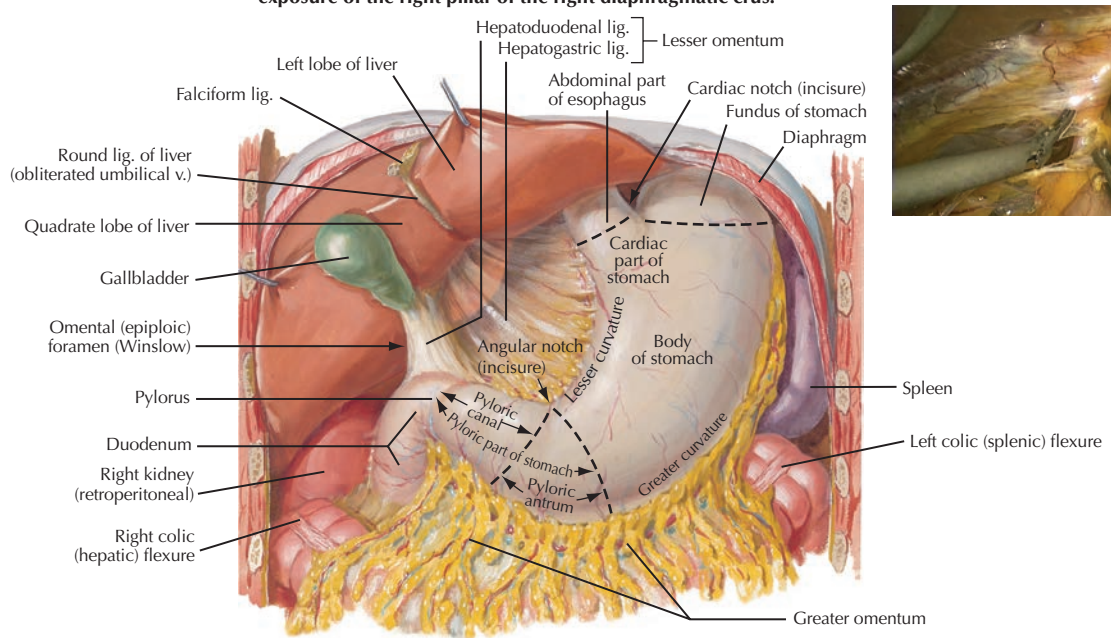
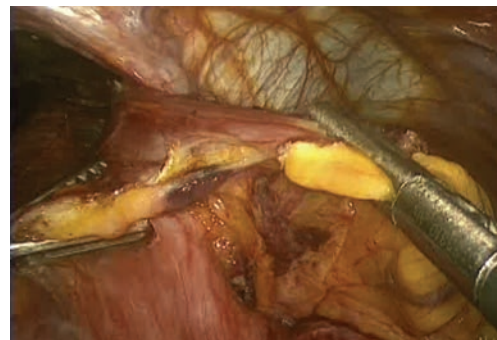
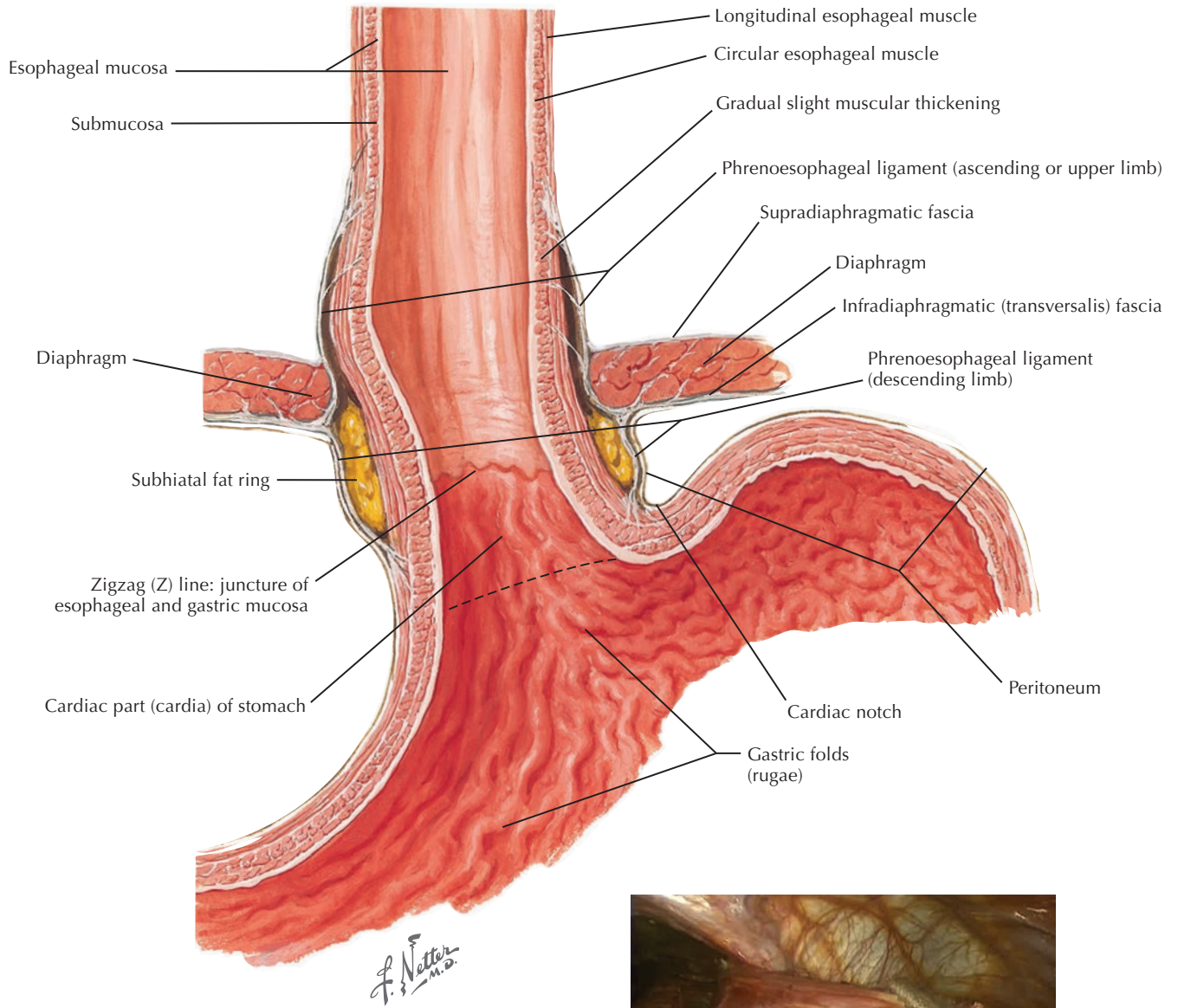


FIGURE 6-5 Anatomy for esophageal mobilization.

Phrenoesophageal Ligament

Division of the phrenoesophageal ligament is required to free the esophagus from its immediate surrounding attachments. [Figure 6-6](#) shows the relationship of the phrenoesophageal ligament to the esophageal hiatus. Division of this ligament for more complete esophageal exposure often requires excision of the fatty tissue anterior to the esophagus. Care is taken to preserve the anterior vagus nerve.

Phrenoesophageal ligament and relation to the esophageal hiatus. Complete mobilization of the esophagus requires division of the phrenoesophageal ligament.



The sac is completely mobilized from the mediastinum and separated from the crural pillars, leaving endoabdominal fascia on the pillars.

FIGURE 6-6 Anatomy for esophageal mobilization—cont'd.

ANATOMY FOR GASTRIC MOBILIZATION

Once the right pillar of the right crus is exposed and the phrenoesophageal ligament divided, the left pillar is then approached by mobilizing the greater curvature of the stomach. The goals of this step are to separate the esophagogastric junction completely from the left pillar of the crus and to ensure circumferential esophageal mobilization.

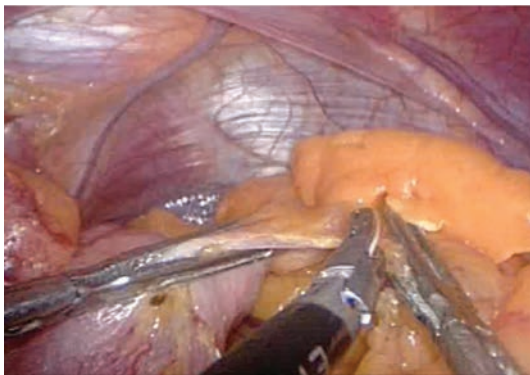
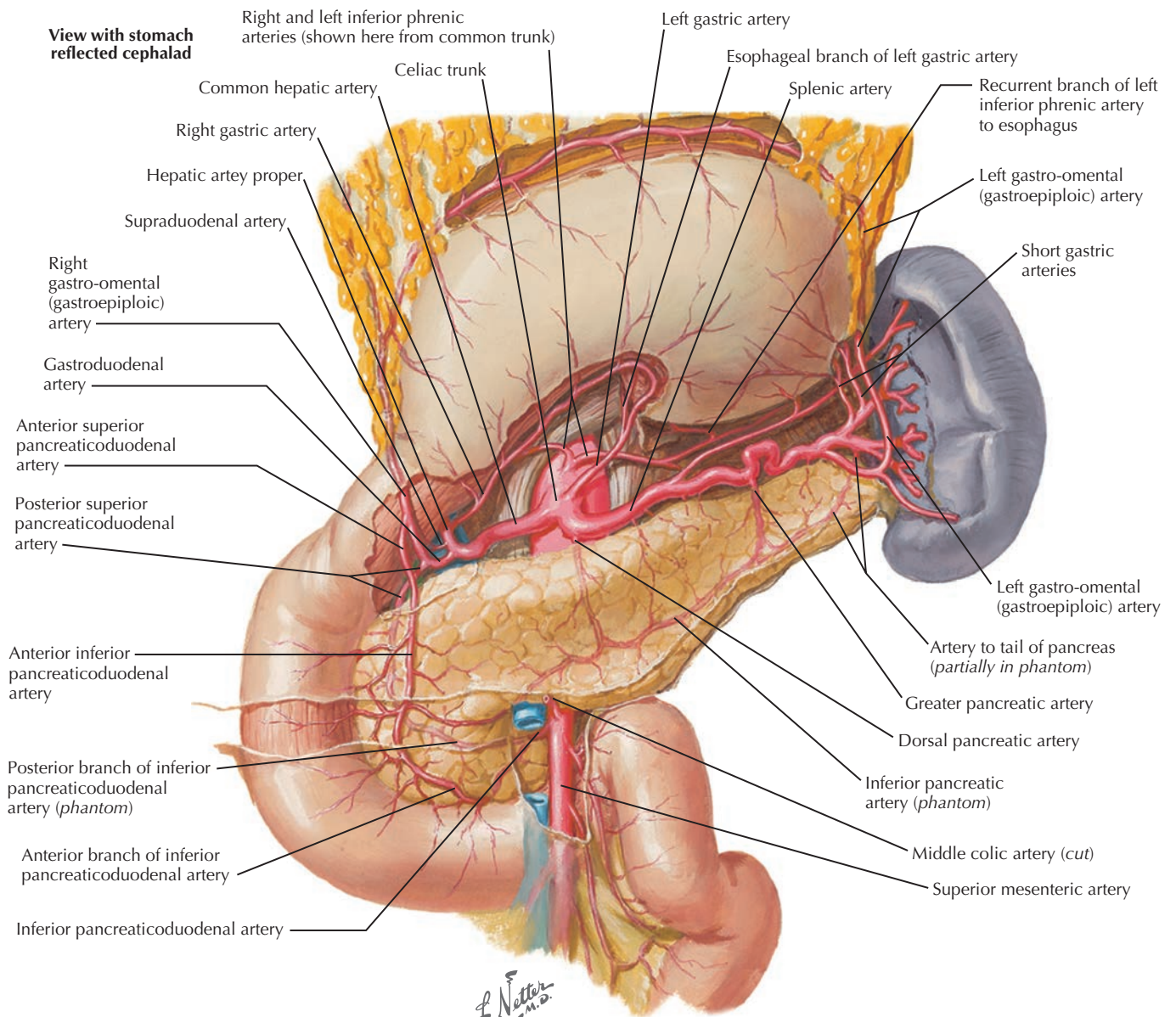
Short Gastric Vessels

Dissection commences at the level of the inferior pole of the spleen, about 1 cm from the greater curve. At this point the short gastric vessels are divided using an appropriate energy source (ultrasonic shears or bipolar electrocautery), and the lesser sac is entered (Fig. 6-7). As the short gastric vessels are divided cephalad, care is taken to avoid splenic or gastric injury while ensuring hemostasis. As the left pillar is approached, it is critical to ensure hemostatic transection of the short gastric vessels because hemorrhage in this area can be difficult to control. Posterior gastric attachments to the pancreas are also divided to ensure adequate gastric mobilization.

Dissection of the Left Pillar and Mobilization of Retroesophageal Space

After division of the short gastric vessels along the greater curve of the stomach, the left pillar of the diaphragmatic hiatus is identified. The esophagus and stomach are bluntly separated from the left pillar.

If a sizable hiatal hernia is present, the posterior sac is mobilized from the mediastinum at this step. Complete circumferential esophageal mobilization of the esophagus is ensured. It is often necessary to reflect the esophagus to the left and return to the right side of the esophagus to ensure circumferential mobilization of the esophagus. Care is taken to identify and preserve the posterior vagus nerve. The confluence of the right and left pillars is dissected away from the posterior esophagus.



Mobilization of greater curve of stomach. The greater curve is retracted toward the right of the patient to facilitate exposure of short gastric vessels.

FIGURE 6-7 Anatomy for gastric mobilization.

ANATOMY FOR CRURAL CLOSURE AND 360-DEGREE FUNDOPPLICATION

Proper closure of the diaphragmatic crura helps minimize herniation of the stomach into the mediastinum. Critical steps to adequate creation of a 360-degree (Nissen) fundoplication include identification of the posterior gastric fundus and creation of the fundoplication around intraabdominal esophagus.

Crural Closure

Thick bites of crura are taken with nonabsorbable suture, ensuring healthy bites of endoabdominal fascia as well as muscle (Fig. 6-8, A). Pledgets can be used to buttress tenuous tissue. Care is taken not to injure the aorta posteriorly or the inferior vena cava to the right of the hiatus. An adequate opening is left to allow passage of a 58- to 60-Fr bougie to prevent dysphagia.

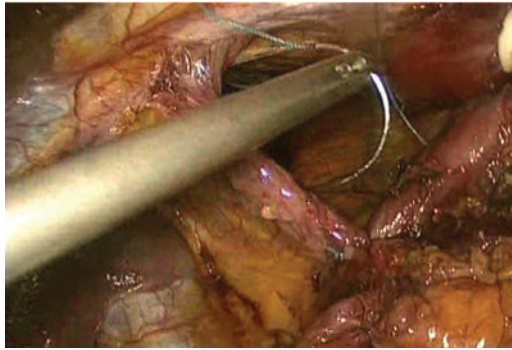
Identification of Posterior Gastric Fundus

The mobilized greater curvature of the stomach is identified and followed cephalad until the posterior gastric fundus is visualized. This is “fed” from left to right through the retroesophageal space while maintaining anterior traction on the esophagus (Fig. 6-8, B). Care is taken to ensure that the posterior fundus is passed behind the esophagus, and that the fundus is not simply passed behind the stomach itself. This can be facilitated by performing the “shoe-shine” maneuver, which helps to confirm the position of the anterior and posterior fundus for plication (Fig. 6-9, A). Adequate mobilization is ensured such that the posterior fundus does not retract readily back through the retroesophageal space.

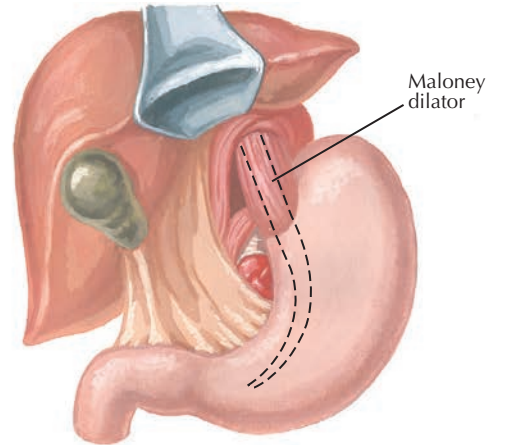
Fundoplication Created around Esophagus

Nonabsorbable mural sutures are placed on each side of the fundoplication, taking mural esophageal bites superiorly to create a 2-cm fundoplication (Fig. 6-9, B). These sutures are placed such that the entire wrap is performed around the esophagus. A floppy fundoplication is preferred; careful passage of a bougie can help assess the “floppiness” of the fundoplication. Upper endoscopic evaluation is then performed to confirm adequate formation and position of the fundoplication (Fig. 6-9, C).

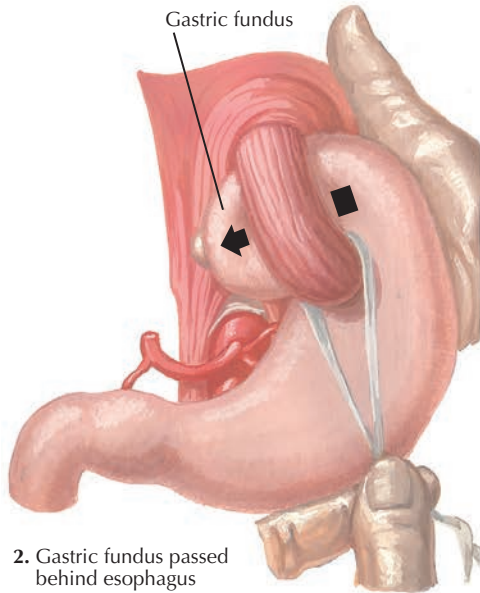
A. Crural closure. Thick bites of crural pillars are taken with nonabsorbable suture, ensuring traversal of endoabdominal fascia to help prevent recurrence.



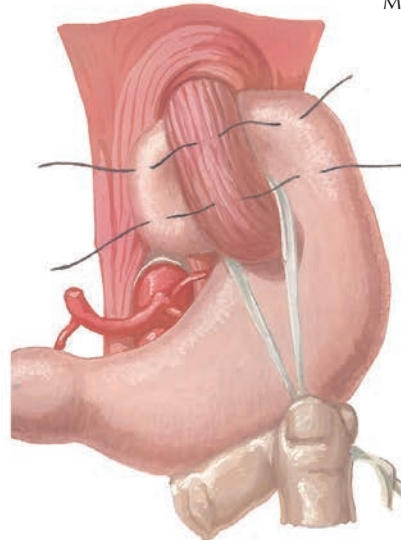
B. Posterior gastric fundus



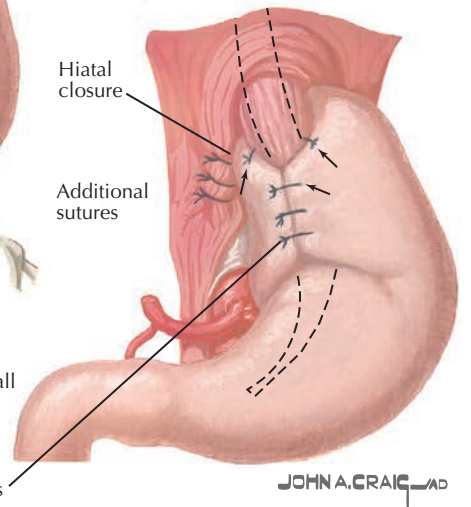
1. Esophagogastric junction exposed through upper abdominal incision. Hernia reduced and Maloney dilator passed into stomach.



2. Gastric fundus passed behind esophagus

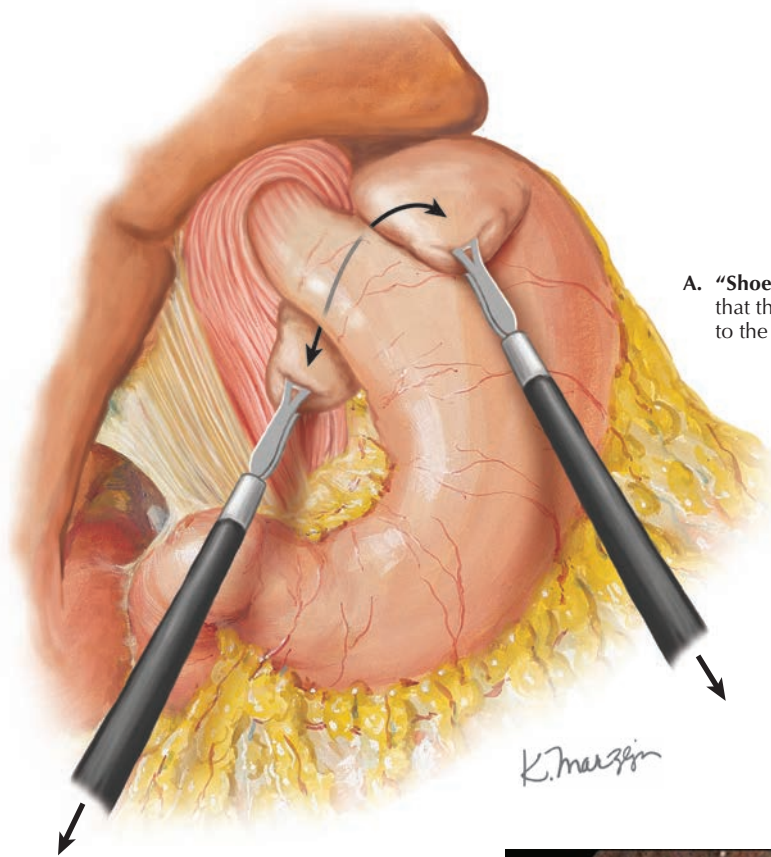


3. Heavy interrupted silk sutures passed through seromuscular layers of fundus, lightly incorporating anterior esophageal wall

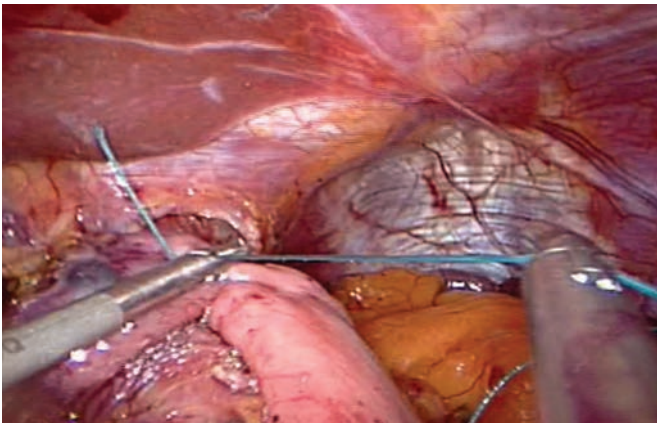


4. Sutures tied, creating 360-degree fundoplication around distal esophagus

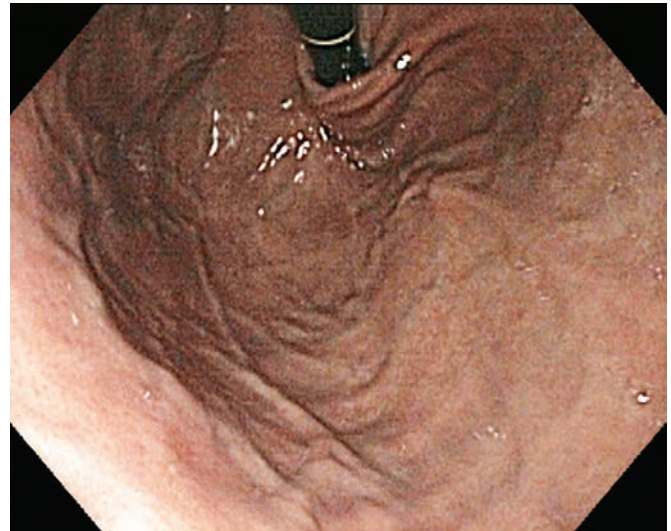
FIGURE 6-8 Crural closure, Nissen (360-degree) fundoplication, and gastropexy.



A. "Shoe-shine" maneuver. Used to verify that the gastric fundus slides easily posterior to the esophagus and is adequately mobilized.



B. **Creation of 360-degree Nissen fundoplication.** The posterior fundus of the stomach is brought around the esophagus and sutured anteriorly with nonabsorbable suture; muscular bites of esophagus are taken superiorly, and the posterior aspect of the fundoplication may be sutured to the crural closure for fixation. The "shoe-shine" maneuver helps ensure that the anterior fundus and posterior fundus are used for the plication.



C. **Endoscopic appearance of Nissen fundoplication.** Note that the fundoplication is confirmed to be created around the esophagus without twisting.

FIGURE 6-9 Laparoscopic Nissen (360-degree) fundoplication and endoscopy.

SUGGESTED READINGS

- DeMeester TR, Bonavina L, Albertucci M. Nissen fundoplication for gastroesophageal reflux disease: evaluation of primary repair in 100 consecutive patients. *Ann Surg* 1986;204(1): 9-20.
- Nissen R. [Hiatus hernia and its surgical indication]. *Deutsche Medizinische Wochenschrift* 1955;80(14):467-9.

Truncal and Highly Selective Vagotomy

Melissa S. Phillips

INTRODUCTION

Vagotomy was once the “gold standard” for patients with duodenal and gastric ulcers. However, the widespread use of medical techniques to manage ulcer disease has dramatically decreased the need for elective surgical intervention. The development of effective acid suppression medications, including histamine receptor blockers and proton pump inhibitors, has helped with this evolution in treatment. Also playing an important role is the recognition, diagnosis, and treatment of *Helicobacter pylori* as a factor in the development of peptic ulcer disease. Now used much less often than in the past, surgical management is reserved for patients who have failed maximum medical therapy and undergone treatment and eradication of *H. pylori* and for those presenting with complications of peptic ulcer disease, including bleeding, perforation, and gastric outlet obstruction.

Excessive gastric acid production contributes to the formation of duodenal and gastric ulcers. When medical therapy is inadequate, surgical intervention is designed to interrupt the neural pathway responsible for this. Options include *truncal* vagotomy, *selective* vagotomy, and *highly selective* (or proximal gastric) vagotomy. Knowledge of the general anatomy of the upper abdomen, specifically the innervation of the stomach, as well as the pathophysiology of complications, is vital to all surgeons caring for patients with this disease process.

CLINICAL INDICATIONS

Acute ulcer disease presents as acute gastrointestinal hemorrhage or perforation (Fig. 7-1). Knowledge of the anatomy of the stomach and its surrounding arterial supply can help predict the complication of ulceration (Fig. 7-2). Erosion of the ulcer posteriorly into the gastroduodenal artery can lead to life-threatening hemorrhage, presenting as tachycardia, hypotension, and hematemesis. Anterior erosion can lead to perforation of the duodenal wall with an acute abdomen, including tachycardia, abdominal tenderness with guarding and rigidity, and pneumoperitoneum on upright chest radiograph. In a more chronic scenario, recurrent episodes may lead to gastric outlet obstruction from repeated scarring.

Less severe presentations of peptic ulcer disease often include complaints of burning epigastric abdominal pain. Definitive diagnosis and elimination of other conditions can be made by upper gastrointestinal endoscopy or upper gastrointestinal series (Fig. 7-3). Any gastric ulcerations seen on endoscopy should be biopsied at multiple sites around the border to determine if the lesion harbors a malignancy. Patients should be evaluated for the presence of *H. pylori* and treated if positive. They should also undergo medical treatment with acid suppression medication before surgery is considered. Patients with persistent severe disease, especially after maximal medical therapy and treatment for *H. pylori*, should be considered for a definitive acid-reducing procedure.

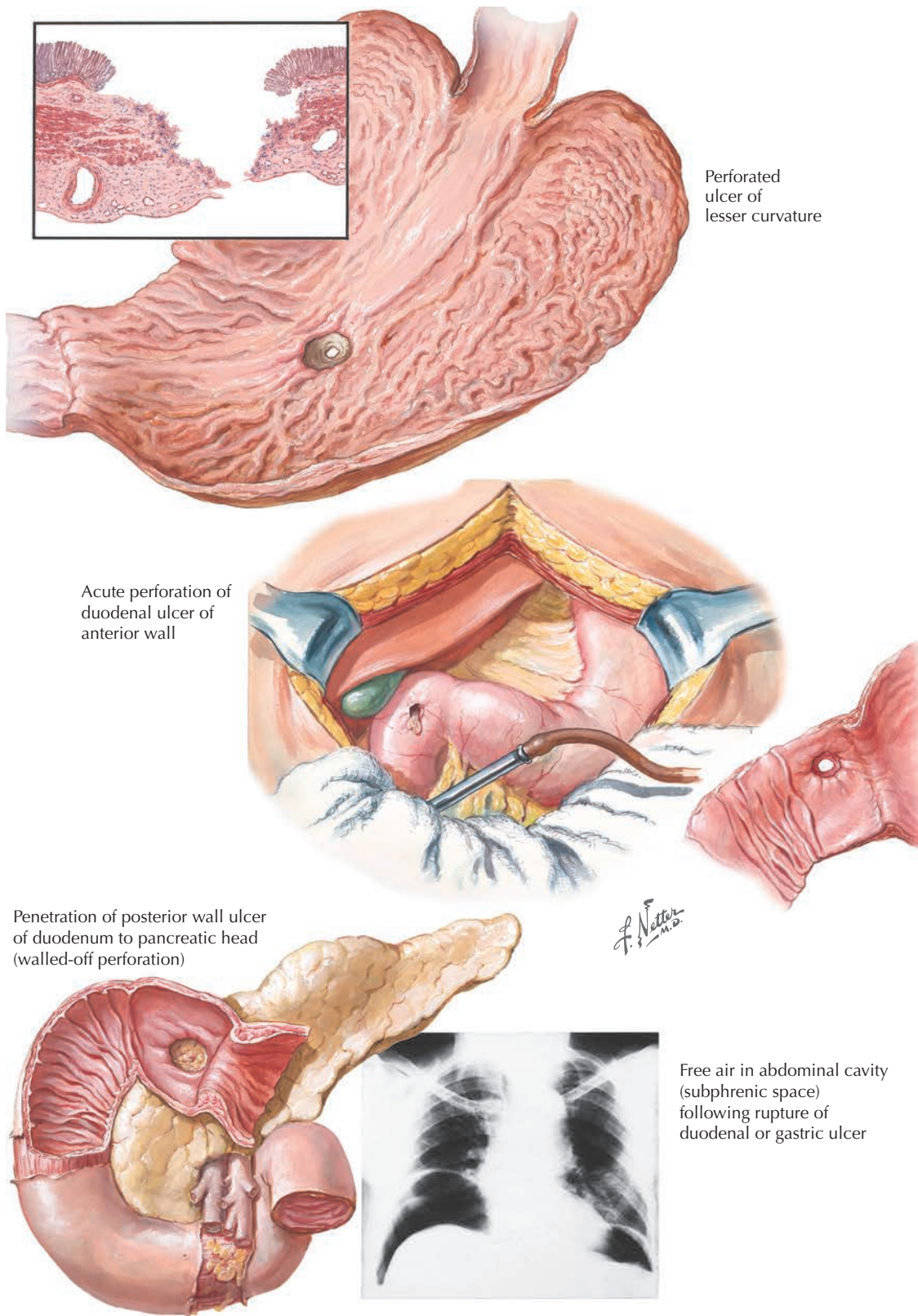


FIGURE 7-1 Complications of gastric and duodenal ulcers.

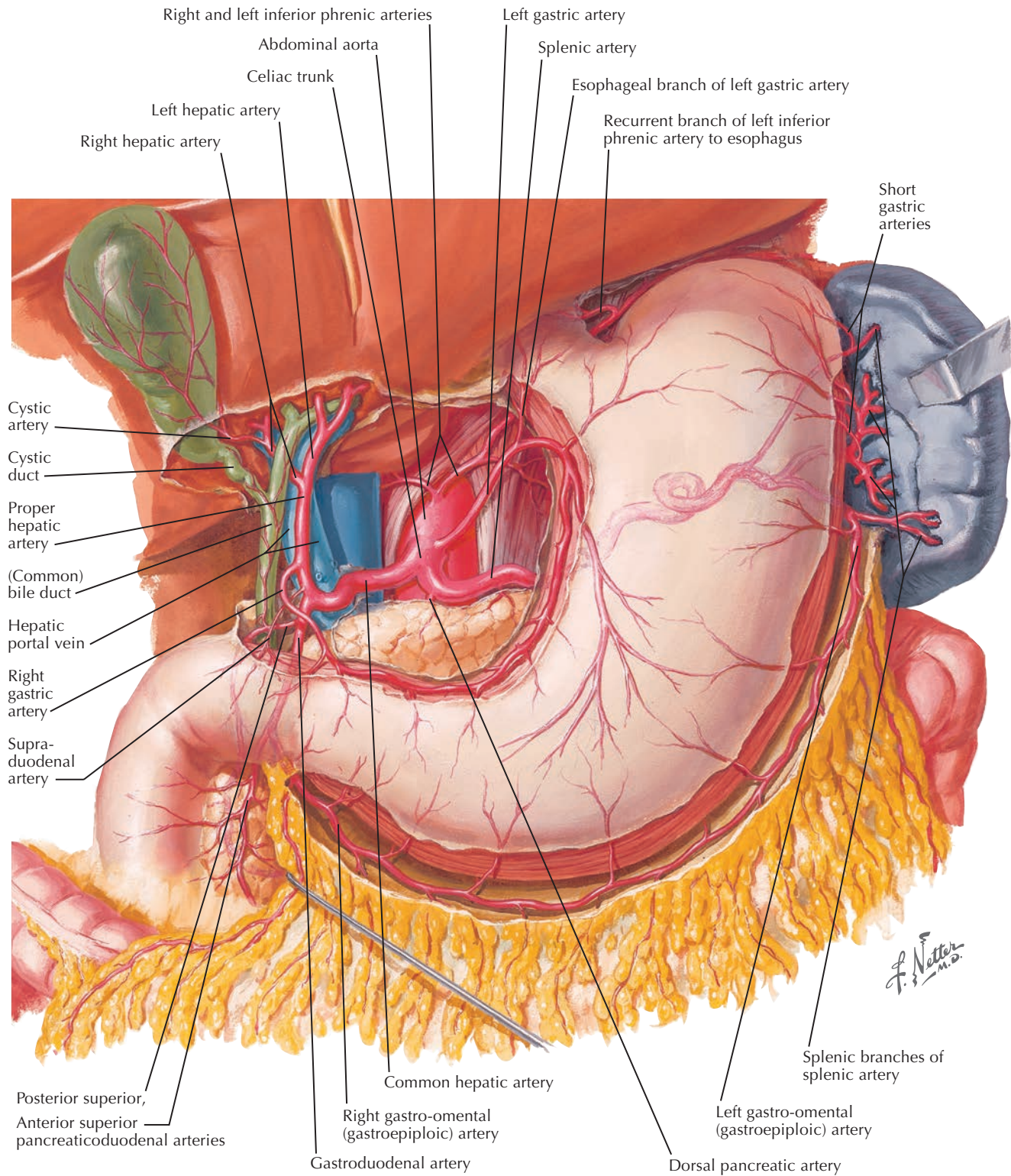


FIGURE 7-2 Arterial supply of stomach.

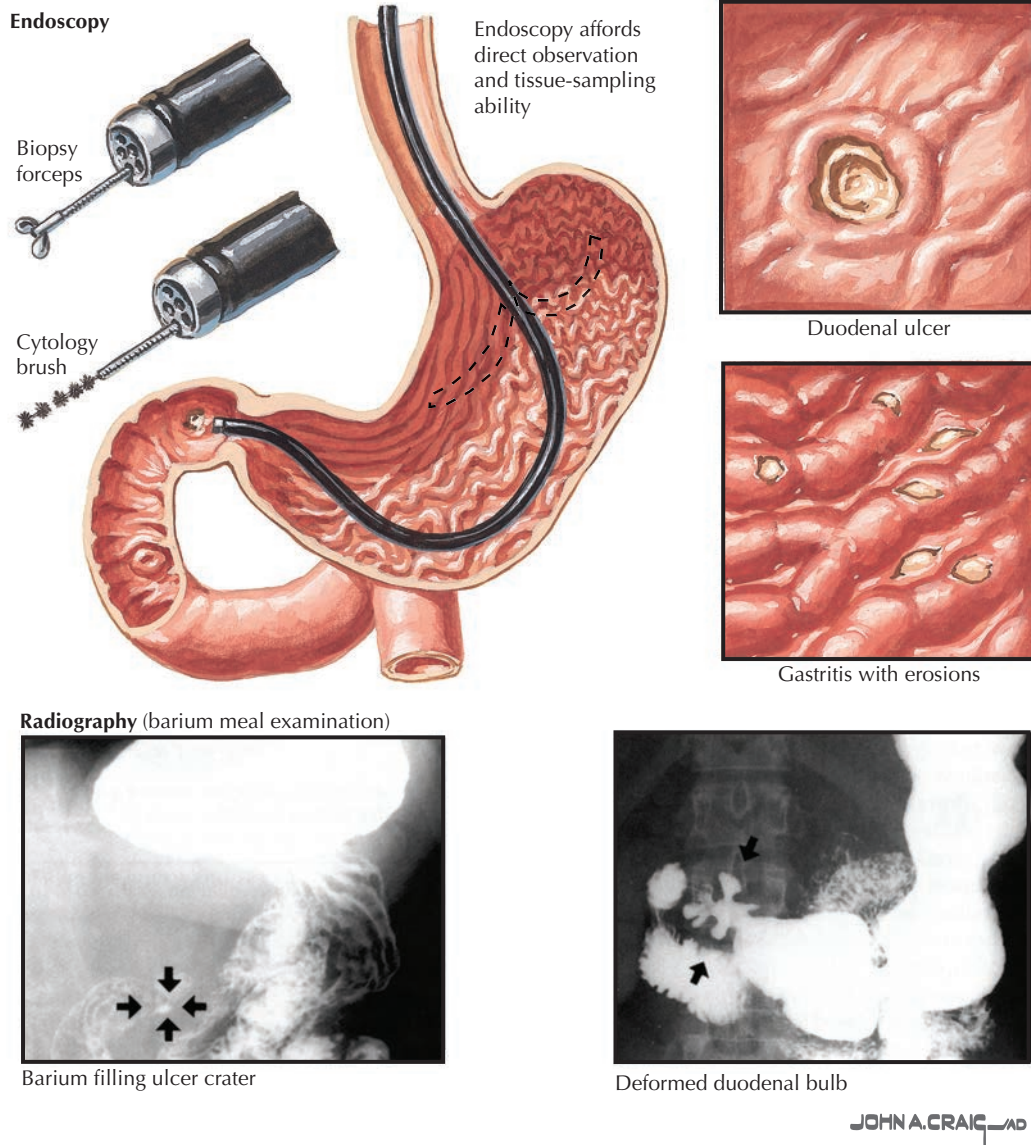


FIGURE 7-3 Endoscopic and upper gastrointestinal evaluation.

SURGICAL DECISION MAKING

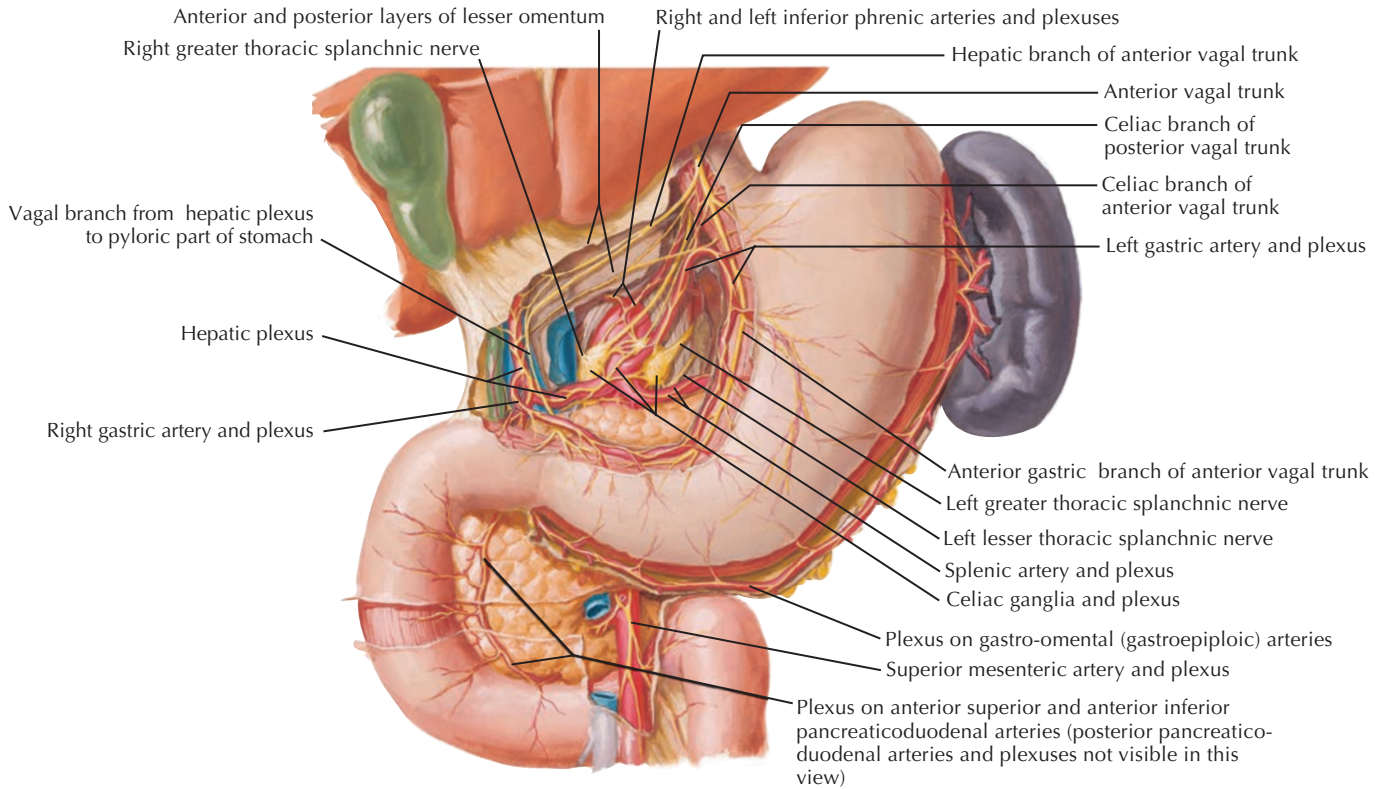
The decision regarding which procedure is performed depends on multiple factors, including patient age, risk for ulcer recurrence, severity of symptoms, clinical status, and body mass index. Truncal vagotomy has a higher rate of cure but also a higher rate of postvagotomy side effects, such as dumping syndrome, diarrhea, and problems with gastric emptying. Conversely, highly selective vagotomy has a lower incidence of side effects but a higher ulcer recurrence rate, as high as 15% at 5 years. Recognizing and applying patient-specific factors as well as balancing these risks are essential in selecting the appropriate procedure.

INNERVATION OF STOMACH

Sympathetic innervation parallels the arterial supply of the stomach (Fig. 7-4, A). Parasympathetic innervation is controlled by the vagus nerve, with one trunk on the right and one on the left that enter from the thoracic cavity with the esophagus (Fig. 7-5). As the vagus nerve enters the abdomen, the two nerves rotate so that the left trunk becomes anterior and the right trunk posterior to the esophagus. Both trunks innervate the stomach along the lesser curvature. Vagal stimulus to the stomach induces the parietal cells to secrete hydrochloric acid and control the motor activity of the stomach (Fig. 7-6).

The left/anterior vagus nerve continues to give off a branch that innervates the gallbladder, biliary tract, and liver. The right/posterior vagus nerve continues to innervate the pancreas, small intestine, and proximal colon. The right branch gives off a small branch behind the esophagus called the “criminal nerve of Grassi” that, if not divided, can lead to recurrent disease (Fig. 7-4, B). The vagus nerve also supplies motor function to the circular muscle fibers of the antrum and pylorus, which is why a drainage procedure is important after truncal vagotomy (see Chapter 10).

A. Association of innervation and arterial supply – anterior view



B. Innervation of the stomach – posterior view

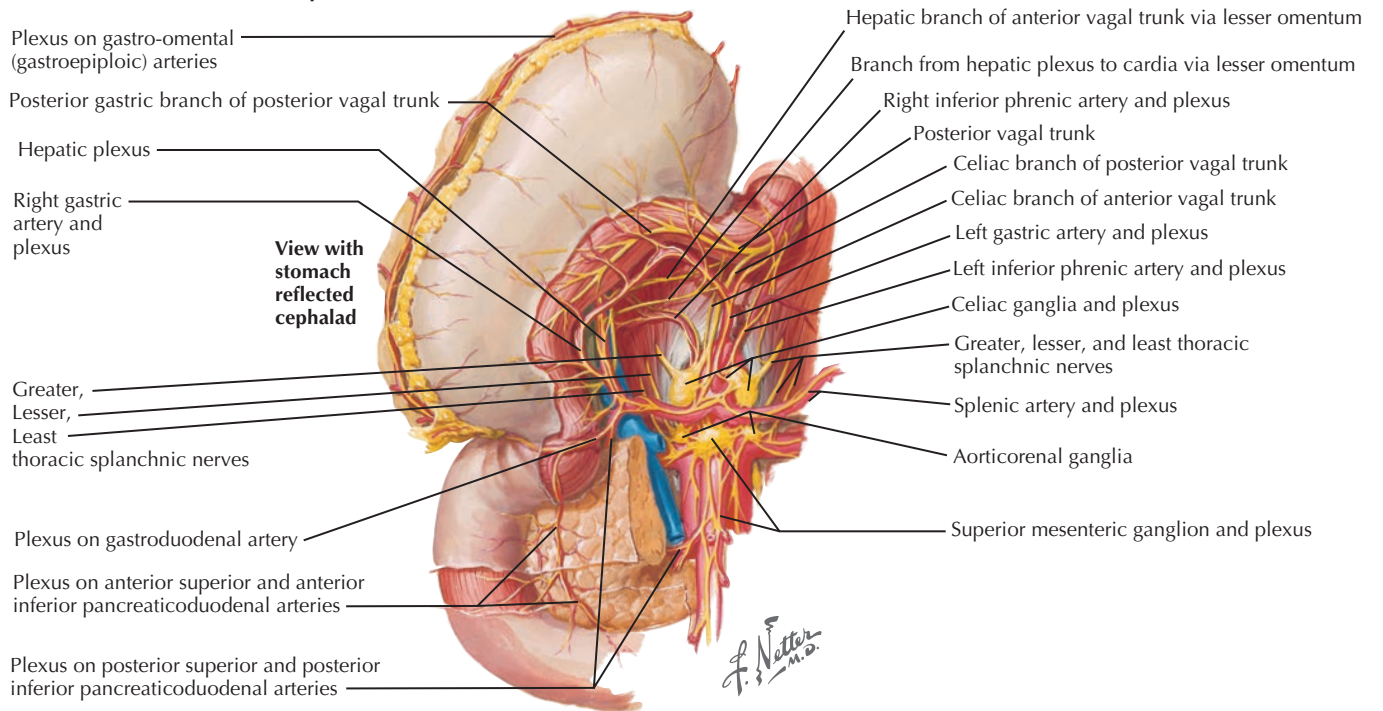


FIGURE 7-4 Innervation and arterial supply of stomach.

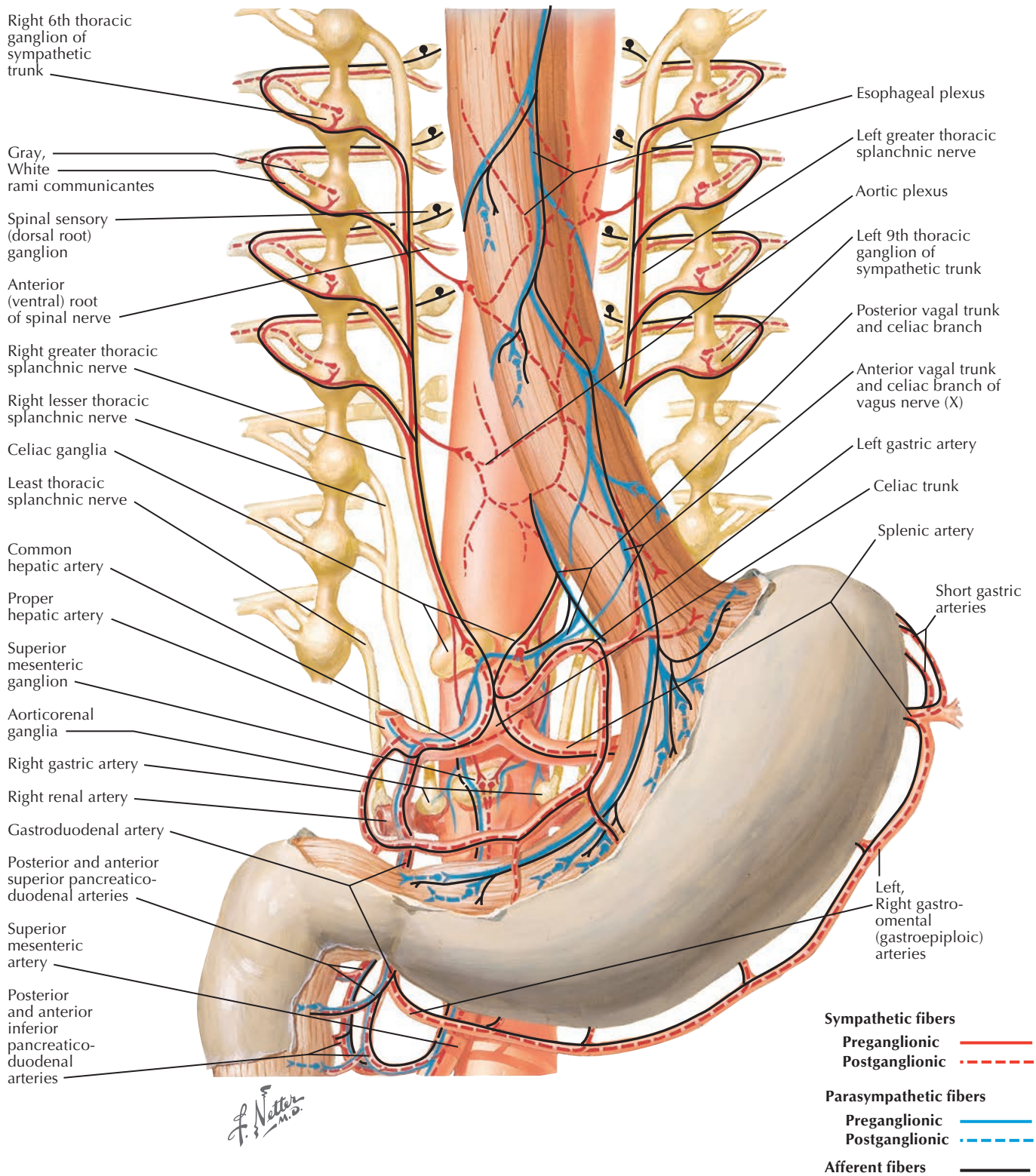
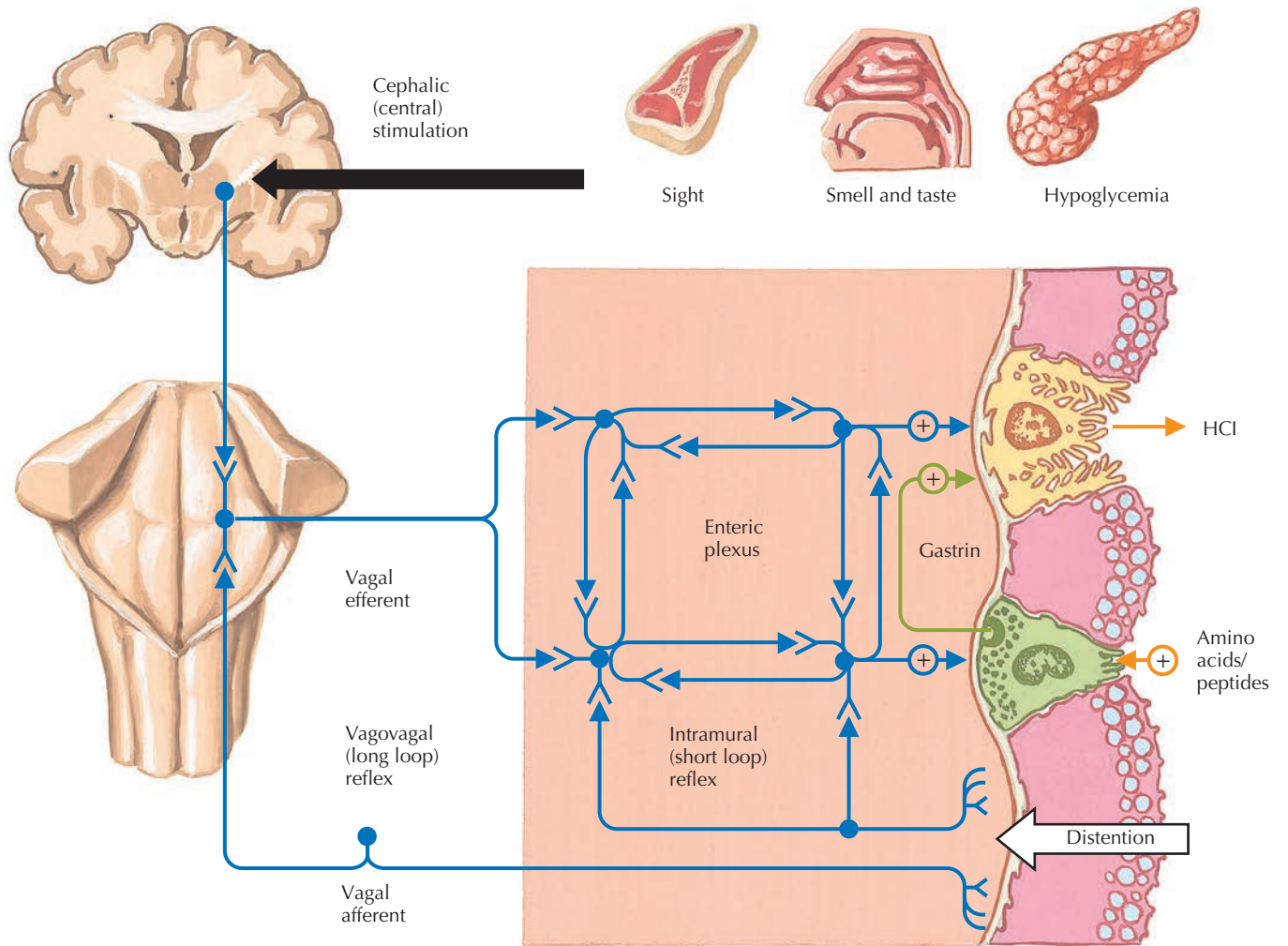


FIGURE 7-5 Innervation of stomach and duodenum.



Gastric acid secretion initiated and modulated by nervous system via central stimulation through vagal efferents and enteric plexus and by intramural (short) feedback loop and a second (long, or vagovagal) feedback loop, both stimulated by gastric antral distention

JOHN A. CRAIG MD

FIGURE 7-6 Vagal control of gastric secretion. *HCl*, Hydrochloric acid.

TRUNCAL VAGOTOMY

Truncal vagotomy involves complete transaction of the vagus nerve at or above the level of the diaphragmatic hiatus. Figures 7-4 and 7-5 illustrate the anatomic site for division. This approach denervates not only the parietal cells but also the abdominal viscera, including the antral pump and pyloric sphincter mechanism. Because the truncal vagotomy disrupts gastric motility, a gastric drainage procedure is required for gastric emptying. The most common procedure is a pyloroplasty, although antrectomy with reconstruction is another viable option, as is gastrojejunostomy (see Chapters 5 and 8).

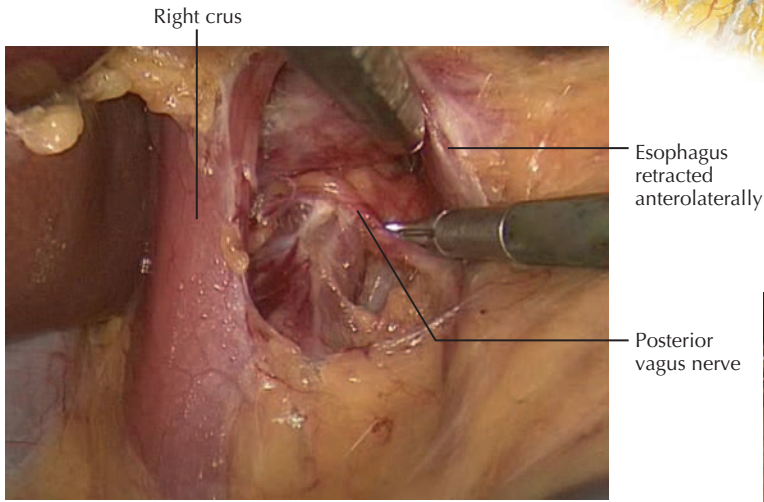
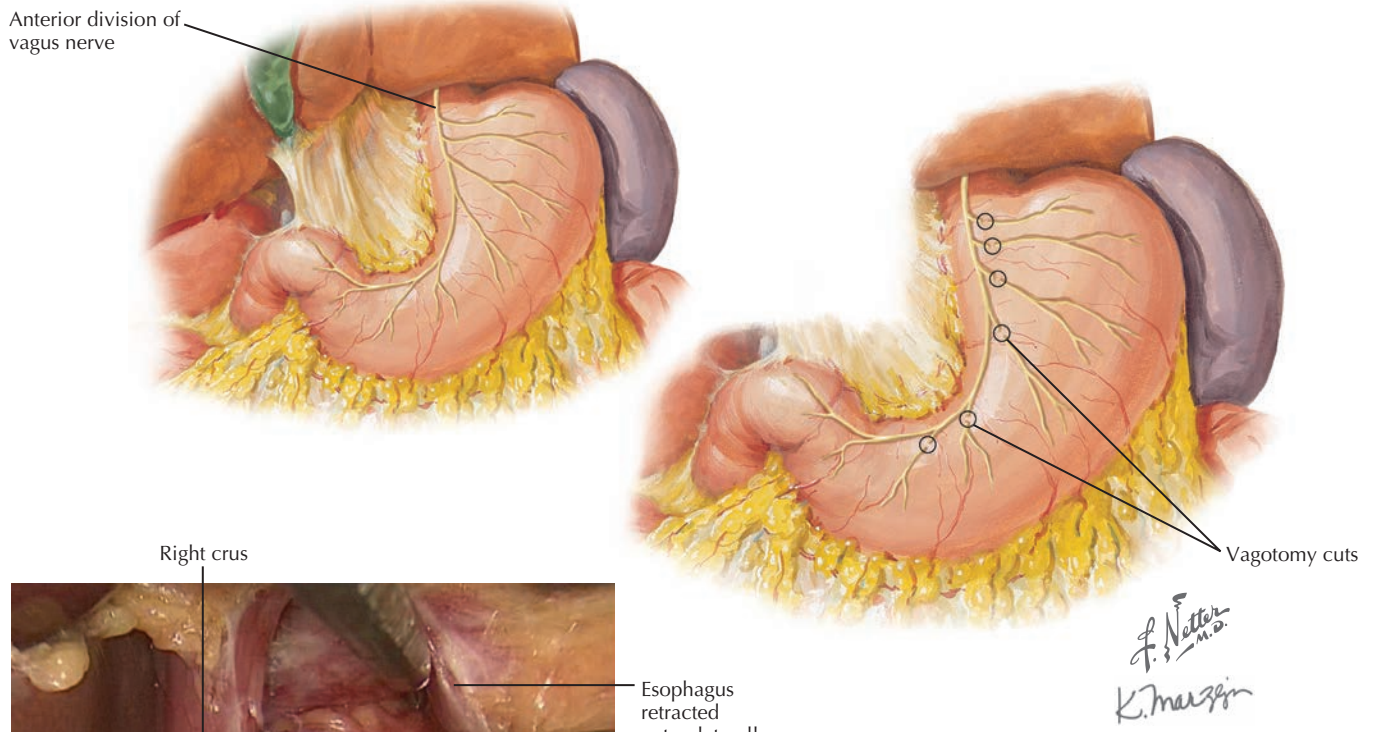
The surgical approach for truncal vagotomy involves adequate mobilization of the left lobe of the liver to allow for exposure of the diaphragmatic hiatus. The phrenoesophageal ligament is opened with electrocautery, and gentle downward traction on the stomach aids with visualization. Exposure is accomplished through traction right and posteriorly and for the left (anterior) nerve and traction left and anteriorly for the right (posterior) nerve (Fig. 7-7). Once identified, the main trunk is then clipped both proximally and distally and divided, removing a segment at least 2 cm in length for pathologic confirmation.

HIGHLY SELECTIVE VAGOTOMY

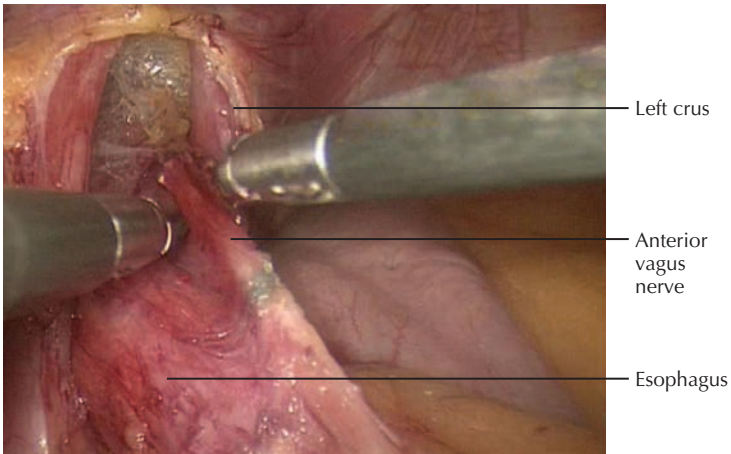
Highly selective vagotomy, also referred to as *proximal gastric* vagotomy or *parietal cell* vagotomy, divides only the branches of the vagus nerve that innervate the parietal cell mass. Figure 7-4 illustrates the anatomic site for division. The preservation of the “crow’s foot” (terminal and most distal divisions of vagus nerve) allows the antral pump and pyloric sphincter mechanisms to remain intact, eliminating the need for a gastric emptying procedure.

The surgical approach begins by examining the lesser curve of the stomach to identify the left gastric vessels and the gastric branch of the anterior vagus nerve (Fig. 7-7). Division of the distal branches of the vagus nerve occurs on the stomach side of the left gastric artery, leaving the crow’s foot, typically located near the incisura angularis (angular or gastric notch), intact for gastric emptying. This dissection starts approximately 7 cm proximal to the pylorus and should be continued to the gastroesophageal junction, taking care to stay close to the stomach and leave the main trunk of the vagus nerve intact. The distal esophagus should be denervated for 6 cm in length to ensure adequate parietal cell signal disruption.

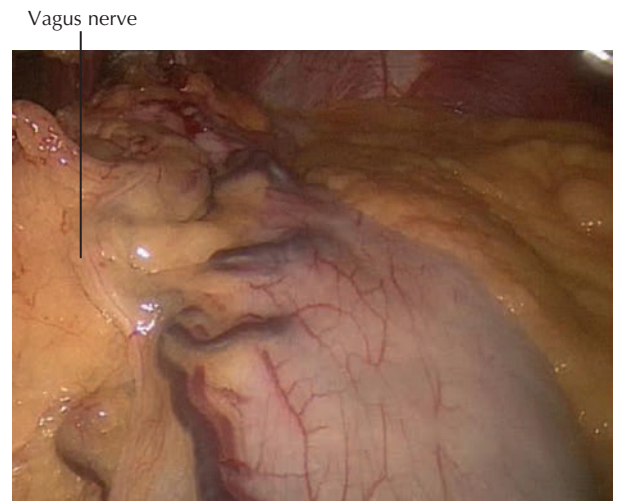
The posterior gastric branch of the vagus nerve can be identified through the lesser sac or by rotating the stomach and should be divided in a similar manner. Care must be taken to identify the criminal nerve of Grassi, a branch of the right/posterior vagus nerve. Lack of division of this branch can lead to continued parietal cell stimulation and resultant recurrent peptic ulcer disease.



Posterior vagus nerve as identified for truncal vagotomy



Anterior vagus nerve as identified for truncal vagotomy



Vagus nerve along lesser curvature as identified for selective vagotomy

FIGURE 7-7 Truncal and highly selective vagotomies.

SUGGESTED READINGS

- Bertleff MJ, Lange JF. Laparoscopic correction of perforated peptic ulcer: first choice? A review of literature. *Surg Endosc* 2010;24(6):1231-9.
- Donahue PE. Parietal cell vagotomy versus vagotomy-antrectomy: ulcer surgery in the modern era. *World J Surg* 2000;24(3):264-9.
- Steger AC, Galland RB, Spencer J. Remaining indications for vagotomy with drainage or antrectomy in duodenal ulcer. *Ann R Coll Surg Engl* 1987;69(1):24-6.
- Zittel TT, Jehle EC, Becker HD. Surgical management of peptic ulcer disease today: indication, technique and outcome. *Langenbecks Arch Surg* 2000;385(2):84-96.

Gastrectomy

Jeffrey M. Hardacre

INTRODUCTION

The number and types of gastric procedures performed by surgeons-in-training have changed dramatically over time. With the advent of histamine receptor (H₂) blockers and proton pump inhibitors, as well as the discovery of *Helicobacter pylori*, surgery for peptic ulcer disease has all but disappeared, with the exception of emergency operations for perforation or bleeding. Concomitant with the decrease in the surgical treatment of ulcer disease has been the dramatic decrease in the incidence of gastric cancer in the United States. Opposing these decreasing trends in the surgical treatment of gastric disease has been the explosion in bariatric surgery during last 10 to 15 years.

Even though many more bariatric procedures are performed than standard gastric resections, the ability to perform partial and total gastrectomy must be part of the surgeon's armamentarium. Currently, about 21,000 new cases of gastric cancer occur each year in the United States.

PRINCIPLES OF GASTRIC CANCER TREATMENT

The treatment of gastric cancer depends on a number of factors; the most important are histologic type and location. This chapter focuses on surgical approaches to the treatment of *gastric adenocarcinoma*.

The treatment of gastric cancer begins with accurate staging. This includes a complete patient history and physical examination, upper gastrointestinal (GI) endoscopy, and computed tomography (CT) of the chest, abdomen, and pelvis. Endoscopic ultrasound may be useful, particularly when neoadjuvant therapy is being considered. Staging laparoscopy is appropriate, because CT-occult disseminated disease may be found in as much as 30% of patients. Palliative resection usually is not needed with current endoscopic interventions.

Surgical resection, including en bloc removal of lymph nodes and adherent organ(s), remains the mainstay of gastric cancer treatment. However, prospective randomized trials have shown that (1) surgery followed by chemoradiation therapy or (2) chemotherapy followed by surgery followed by more chemotherapy are both better than surgery alone. Given the propensity for gastric cancer to spread within the wall of the stomach, gross margins of 5 to 6 cm are usually needed to ensure negative final, histologic margins. The American Joint Committee on Cancer recommends that at least 16 lymph nodes be assessed for staging.

SURGICAL APPROACH FOR GASTRECTOMY

The abdomen is explored to evaluate for metastatic disease, usually through an upper midline incision, although some surgeons prefer a chevron incision. Laparoscopic-assisted approaches to gastric resection are increasingly used. [Figure 8-1](#) shows the stomach in situ with its relationship to surrounding structures. [Figures 8-1, 8-2, and 8-3, A](#), show the arterial and venous anatomy pertinent to gastric resection.

Once disseminated disease is excluded, dissection begins with mobilization of the stomach. The lesser sac is entered by taking the omentum off the transverse colon, keeping the omentum with the stomach. This approach provides wide exposure of the posterior aspect of the stomach and lesser sac ([Figs. 8-2 and 8-3](#)) and allows the surgeon to assess for any posterior invasion by the tumor.

Next, the lesser omentum is divided, keeping the lymphatic tissue with the stomach. Care must be taken to look for a replaced left hepatic artery coming off the left gastric artery.

At this point, an assessment is made as to the extent of resection that will be required. Distal tumors ([Fig. 8-4, A](#)) are treated with *distal/subtotal* gastrectomy, and proximal tumors ([Figure 8-4, B](#)) with *total* gastrectomy. Achieving negative margins for tumors along the lesser curvature of the stomach is more difficult than for tumors along the greater curvature of the stomach; thus, lesser curve tumors more often require total gastrectomy.

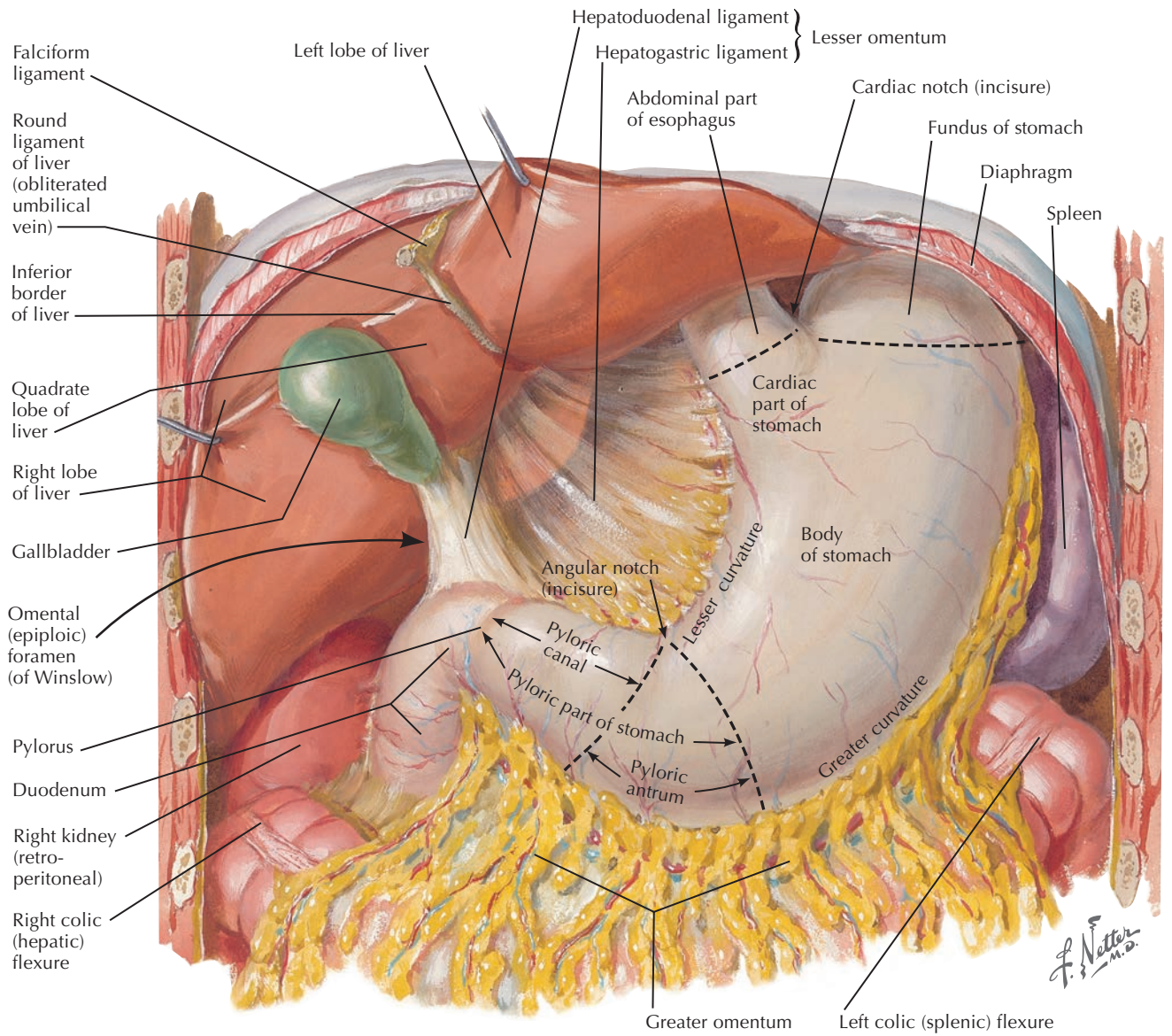


FIGURE 8-1 Stomach in situ.

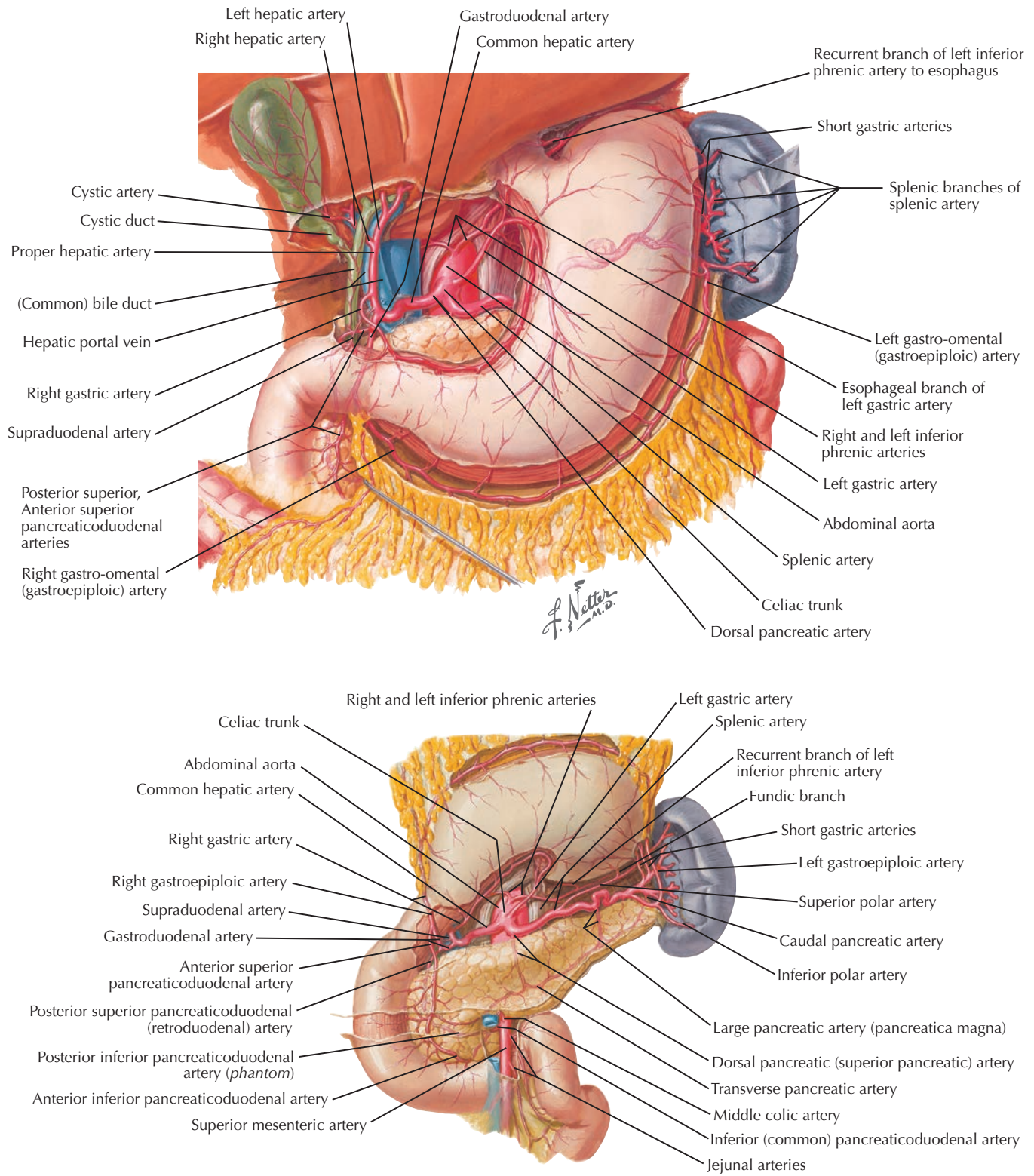
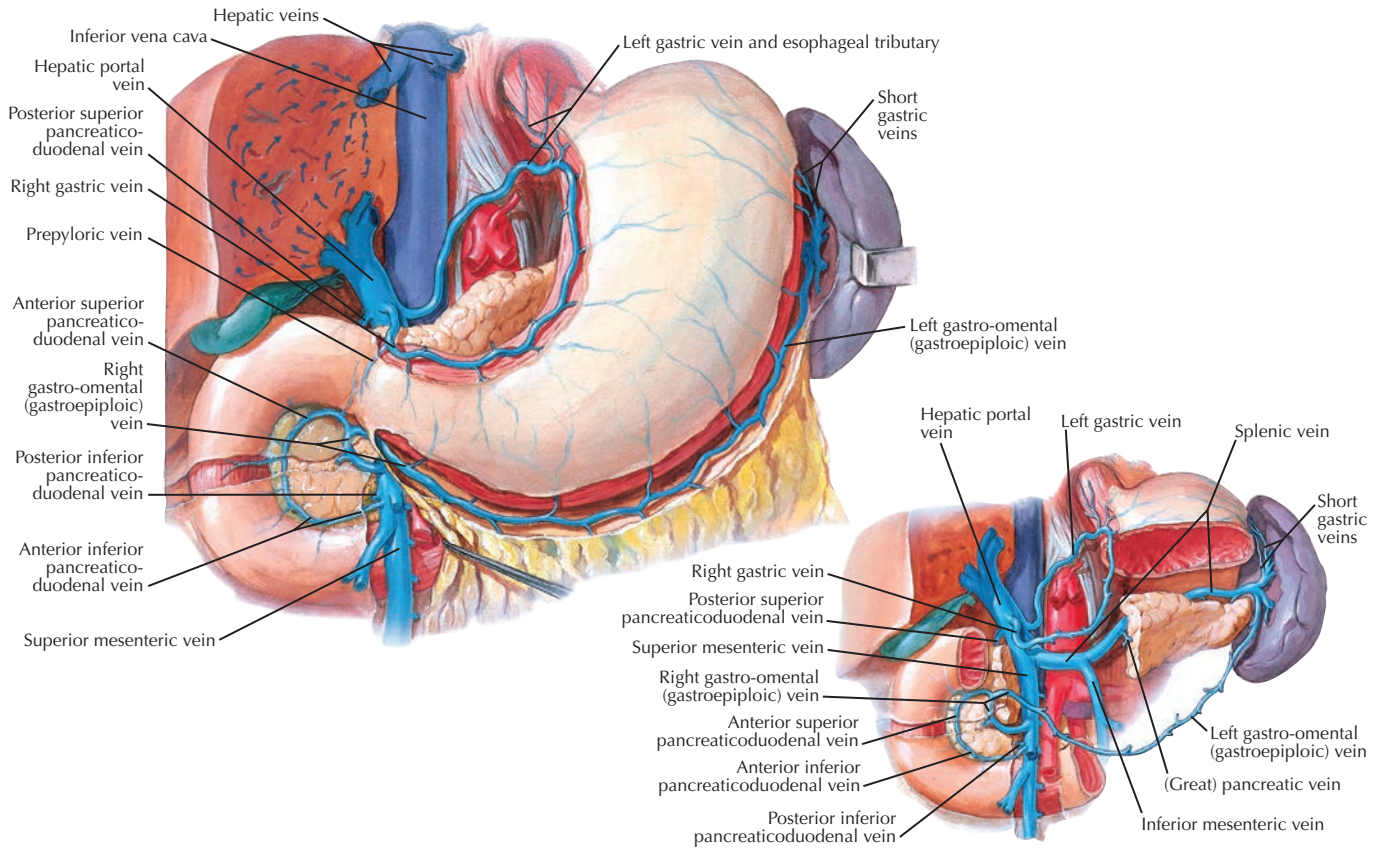


FIGURE 8-2 Arterial supply of stomach.

A. Venous drainage of stomach



B. Lymphatic drainage of stomach

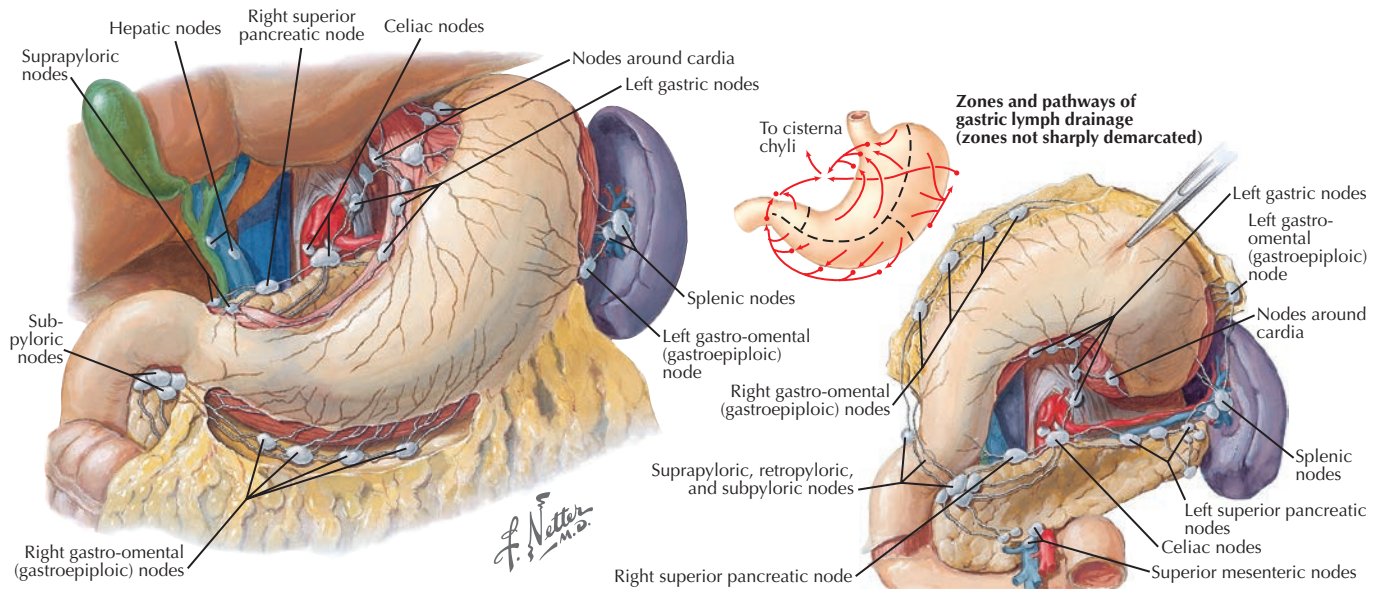


FIGURE 8-3 Venous and lymphatic drainage of stomach.

SURGICAL APPROACH FOR GASTRECTOMY—Cont'd

The duodenum is divided with a surgical stapler. The duodenal stump may be left as a simple staple line, or it may be oversewn by using simple Lembert sutures or by burying the staple line and suturing the duodenum to the capsule of the pancreas. The left gastric artery is taken at its origin; in some patients, this is best done along the lesser curvature of the stomach or with the stomach retracted cranially (see Fig. 8-2). Proximal transection is achieved with multiple firings of the surgical stapler. If a total gastrectomy is performed and a circular-stapler anastomosis is planned, the purse-string staple device may be used for the proximal transection. Both proximal and distal margins are assessed through frozen section, and further resection is undertaken if necessary.

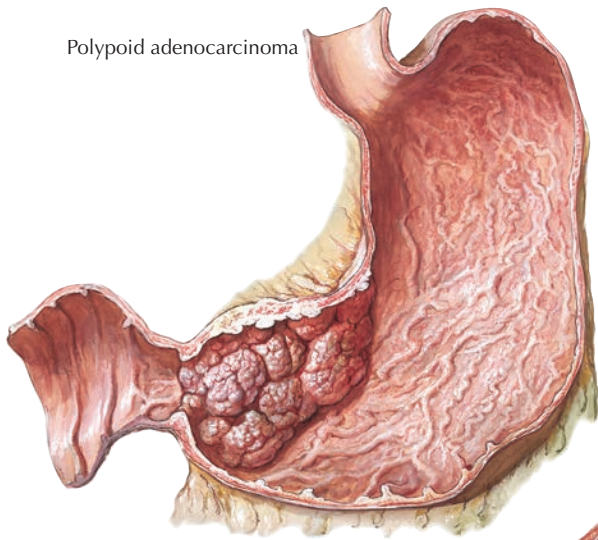
While performing the resection, the surgeon must be cognizant not only of margins but also of the extent of lymphadenectomy. Figure 8-3 highlights the 16 lymph node basins. A D1 lymphadenectomy refers to removal of the perigastric lymph nodes. A D2 lymphadenectomy adds removal of nodes along the left gastric, celiac, and splenic arteries, as well as the nodes in the splenic hilum. A D3 lymphadenectomy adds removal of nodes in the hepatic portal (porta hepatis) and the periaortic regions.

Controversy persists regarding the appropriate extent of lymphadenectomy, with the competing issues being appropriate staging and survival benefit versus increased surgical morbidity and mortality. Two Western prospective randomized trials have shown no survival benefit when doing a D2 versus a D1 lymphadenectomy, while having greater morbidity associated with the D2 dissection (see [Suggested Readings](#)). Despite this, treatment guidelines published by the National Comprehensive Cancer Network recommend a D2 versus a D1 lymphadenectomy.

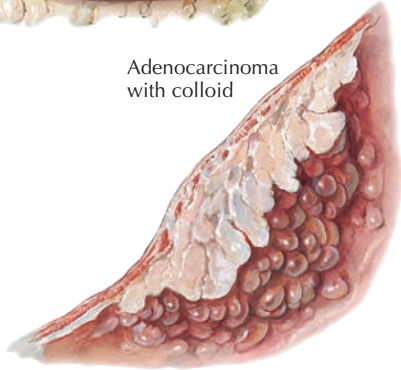Reconstruction after a distal gastrectomy is usually accomplished with a Billroth II gastrojejunostomy (Fig. 8-4, C). This instrument is generally favored over a Billroth I (gastroduodenostomy) reconstruction because of concerns regarding anastomotic tension as well as potential tumor recurrence. Reconstruction after a total gastrectomy may be performed with either a Roux-en-Y esophagojejunostomy or a loop esophagojejunostomy with a distal enteroenterostomy, with the hope of diverting bile and pancreatic juice from the esophagus. Some favor formation of a jejunal pouch as a “neostomach,” but this has shown no clear benefit. For either a distal or a total resection, the jejunum may be brought up for reconstruction in an antecolic or a retrocolic manner. Drains are not routinely placed after a gastrectomy.

A. Distal gastric cancer

Polypoid adenocarcinoma

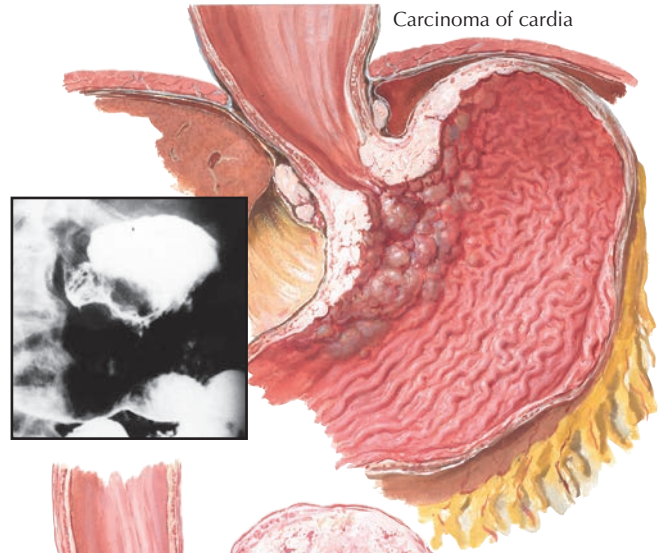


Adenocarcinoma with colloid

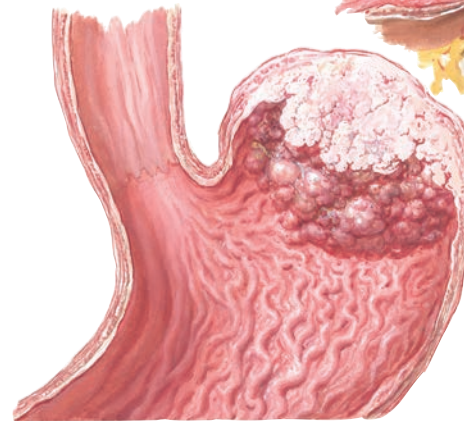

B. Proximal gastric cancer

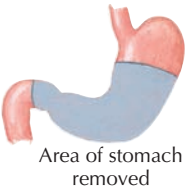Carcinoma of cardia



Carcinoma of fundus

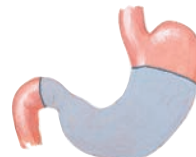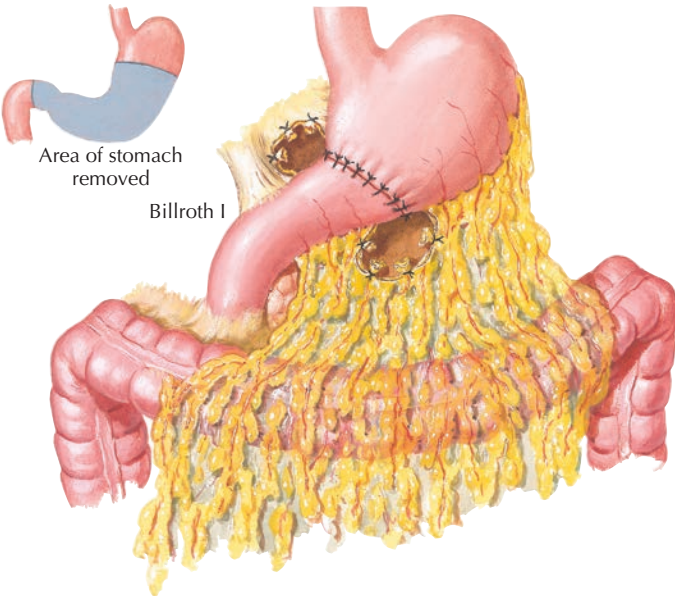


C. Reconstruction after distal gastrectomy



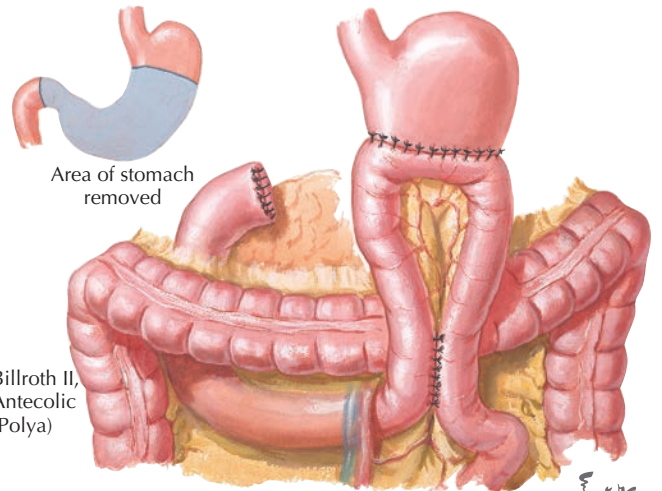
Area of stomach removed

Billroth I



Area of stomach removed

Billroth II, Antecolic (Polya)



F. Netter M.D.

FIGURE 8-4 Distal and proximal gastric cancer and reconstruction.

SUGGESTED READINGS

- Bonenkamp JJ, Hermans J, Sasako M, van de Velde CJ. Extended lymph node dissection for gastric cancer. *N Engl J Med* 1999;340:908.
- Cunningham D, Allum WH, Stenning SP, et al. Perioperative chemotherapy versus surgery alone for resectable gastroesophageal cancer. *N Engl J Med* 2006;355:11.
- Cuschieri A, Fayers P, Fielding J, et al. Postoperative morbidity and mortality after D1 and D2 resections for gastric cancer: preliminary results of the MRC randomised controlled surgical trial. *Lancet* 1996;347:995.
- Cuschieri A, Weeden S, Fielding J, et al. Patient survival after D1 and D2 resections for gastric cancer: long-term results of the MRC randomized surgical trial. *Br J Cancer* 1999;79:1522.
- Hartgrink HH, van de Velde CJ, Putter H, et al. Extended lymph node dissection for gastric cancer: who may benefit? Final results of the randomized Dutch Gastric Cancer Group trial. *J Clin Oncol* 2004;22:2069.
- MacDonald JS, Smalley SR, Benedetti J, et al. Chemoradiotherapy after surgery compared with surgery alone for adenocarcinoma of the stomach or gastroesophageal junction. *N Engl J Med* 2001;345:725.

Heineke-Mikulicz Pyloroplasty and Duodenotomy for Bleeding Ulcer

Jeffrey M. Marks

INTRODUCTION

Surgery for bleeding duodenal ulcers is required less often now as a result of advances in endoscopic and interventional radiology techniques and acid suppression agents. When these measures fail to control a bleeding ulcer, however, surgical exposure of the intraluminal posterior wall of the duodenum is required to provide hemostasis.

PRINCIPLES OF TREATMENT

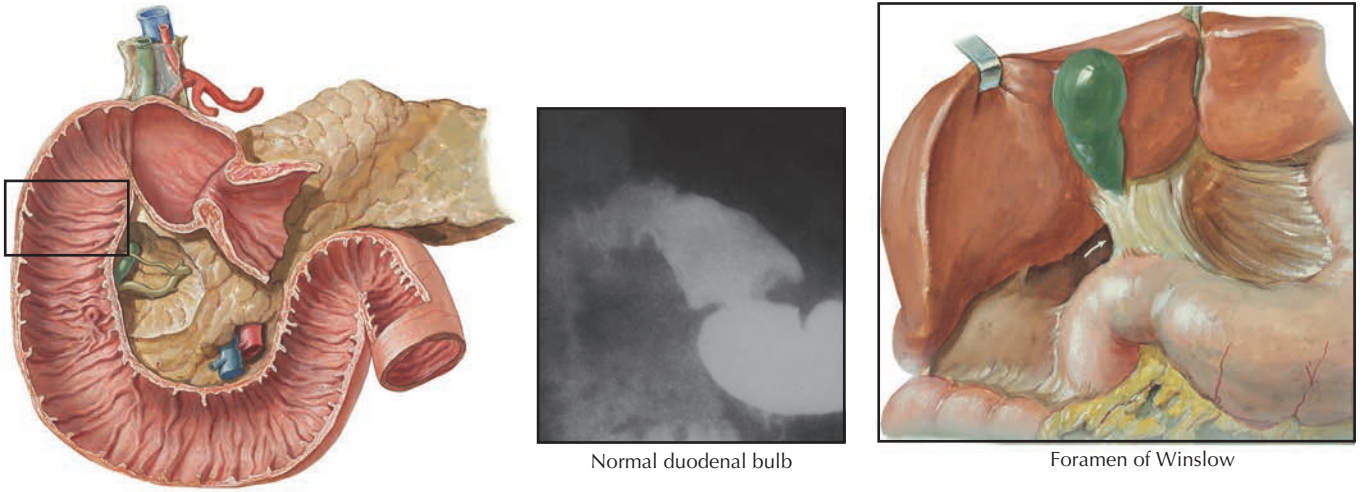
Patients with upper gastrointestinal bleeding (UGIB) may have either hematemesis or melena/hematochezia, depending on the volume and briskness of the bleeding. Multiple sources for UGIB are well described, including esophageal or gastric varices, gastritis or gastric ulcers, and duodenal ulcers. Comorbid diseases such as portal hypertension, renal failure, and chronic pancreatitis, as well as chronic nonsteroidal antiinflammatory drug (NSAID) use, may help to predict the etiology.

Patients who are seen with symptoms of UGIB initially require full clinical assessment and hemodynamic stabilization. Depending on the amount of blood loss, this may include multiple blood transfusions, medical support of blood pressure, and endotracheal intubation. In patients seen with blood per rectum, placement of a nasogastric tube and aspiration of gastric contents may help confirm an upper GI source for bleeding if clear, nonbloody bile is seen. A nonbloody and nonbilious aspirate does not exclude a postpyloric source of bleeding.

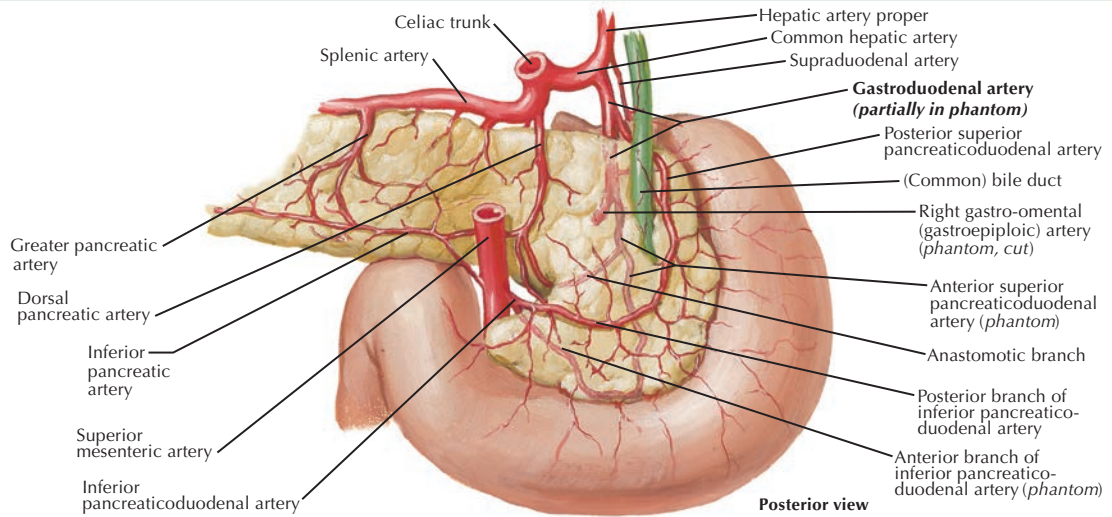
Duodenal ulcers that result in bleeding are usually positioned in the posterior duodenal bulb (Fig. 9-1, A). There are numerous submucosal arterial vessels around the duodenum, but invasion of the *gastroduodenal artery* is the predominant source for massive duodenal ulcer bleeding (Fig. 9-1, B).

After stabilization of the patient, the first diagnostic (and often therapeutic) intervention is upper endoscopy (Fig. 9-1, C). Multiple endoscopic adjuncts for providing hemostasis are available, including clips, cautery, and injection of sclerotherapy agents. If these endoscopic approaches are unsuccessful and the patient continues to have evidence of bleeding from an identified duodenal ulcer, radiologic interventions are typically used. The gastroduodenal artery is accessed with transarterial catheters through the celiac trunk, and the site of bleeding is then identified and treated with a combination of intraluminal coils, foams, and autologous clots. Vasoactive medications can also be delivered by a subselective catheter left in place with its tip into the gastroduodenal artery to assist in hemostasis.

A. Duodenal bulb and mucosal surface of duodenum



B. Blood supply of stomach and duodenum



C. Endoscopic view of duodenum

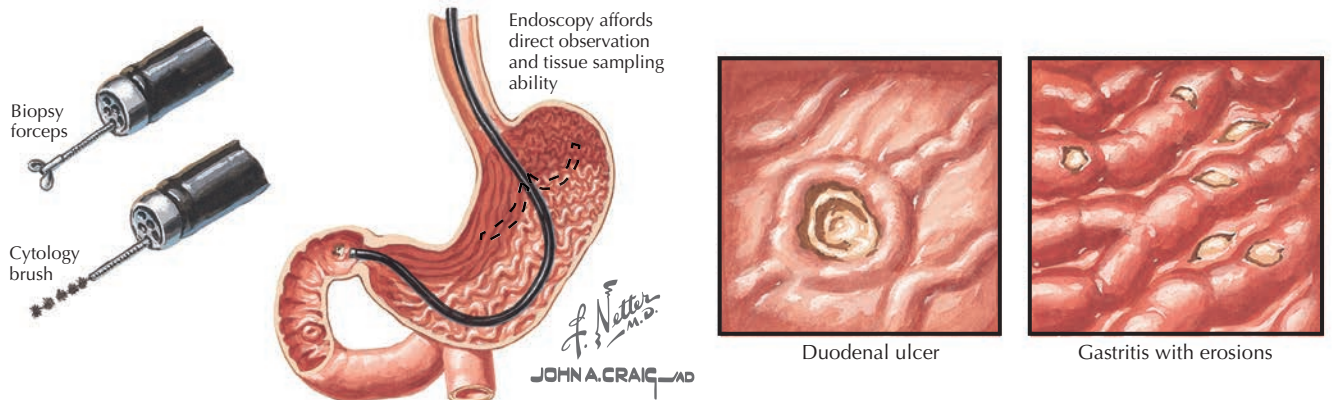


FIGURE 9-1 Duodenal bulb, blood supply, and endoscopic view.

SURGICAL APPROACH

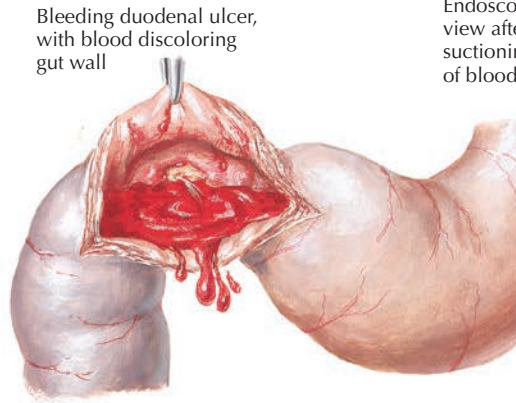
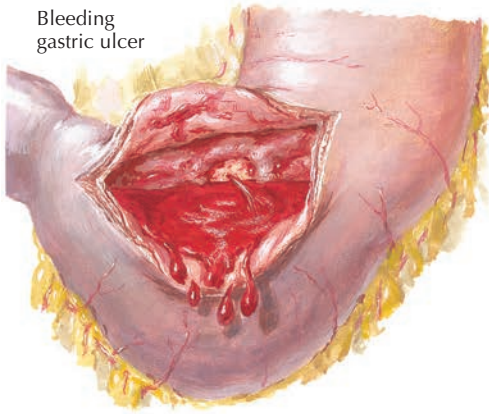
The surgical approach to the duodenum is usually performed using an open upper midline or right subcostal abdominal incision. Laparoscopic approaches have also been described. Although the majority of the duodenum is in the retroperitoneum, the duodenal bulb and first portion of the duodenum are intraperitoneal structures. Incising the lateral attachments to the second and third portions of the duodenum allows elevation of the duodenum and pancreas to provide improved exposure of the duodenal bulb region. Mobilization of the hepatic flexure of the colon is sometimes necessary to access the retroperitoneal areas of the duodenum.

Incision of the lateral attachments of the second portion of the duodenum, called a *Kocher maneuver*, allows better control as well as laxity of tissues at the level of the pylorus. Structures adjacent to the duodenum include the inferior vena cava, common bile duct, pancreas, gastroduodenal artery, and portal vein. The pancreas sits adjacent to the “C loop” of the duodenum, and the other structures are posterior to the duodenum.

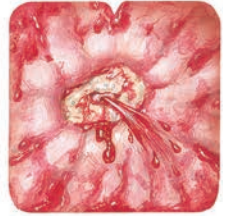Bleeding duodenal ulcers are often located in the posterior pyloric bulb and penetrate into the gastroduodenal artery, which lies just posterior to the duodenum (see Fig. 9-2, A). Access to these ulcers is best achieved using a longitudinal incision across the pylorus, including several centimeters of both the stomach and the duodenum. This procedure is termed a *pyloromyotomy* (Fig. 9-2, B). Once the duodenum has been entered at this site, control of the bleeding posterior ulcer is achieved by placement of sutures in the four quadrants around the ulcer. It must be remembered that the common bile duct is just lateral and posterior to this site, so sutures should not be placed too deep (Fig. 9-3).

After suture control of a bleeding duodenal ulcer through a pyloromyotomy, the gastroduodenotomy or pyloromyotomy must be closed. To avoid narrowing of this site, as well as to provide adequate drainage if a truncal vagotomy is also performed, the longitudinal incision is closed in a transverse orientation. This repair is called a *Heineke-Mikulicz pyloroplasty* (Fig. 9-4).

A. Bleeding lesions of stomach and duodenum



Endoscopic view after suctioning of blood



B. Duodenitis and duodenal ulcers seen via a pyloromyotomy

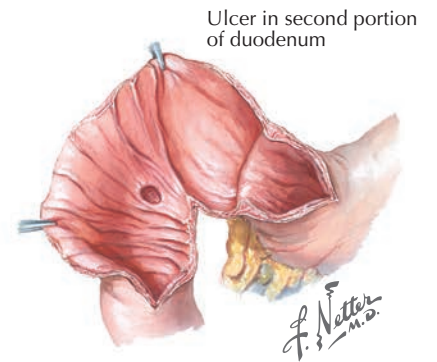
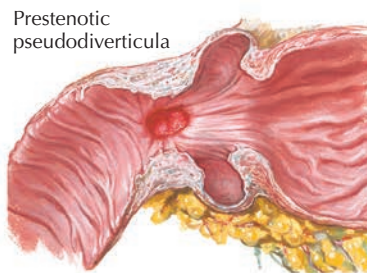
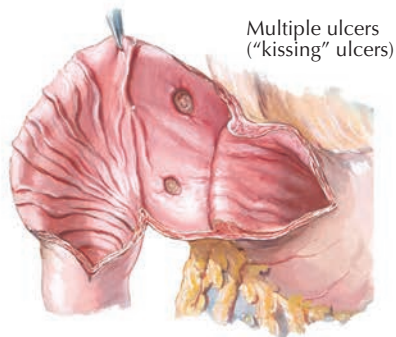
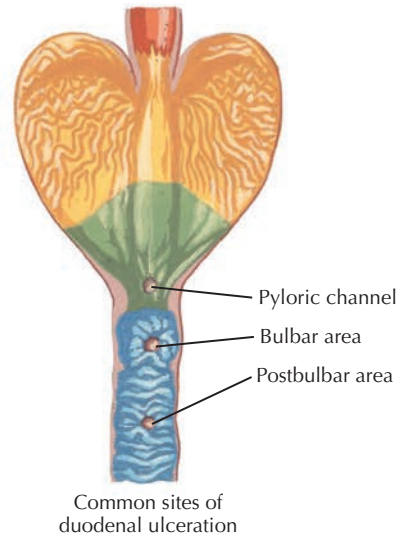
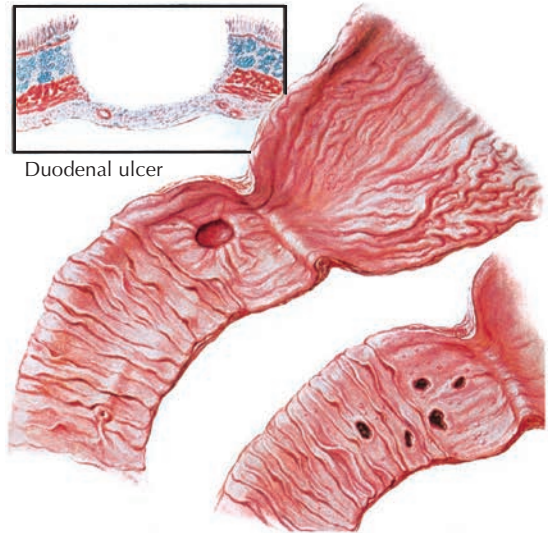
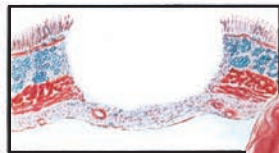
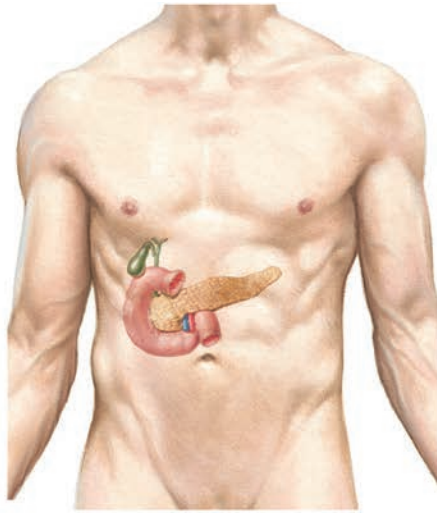


FIGURE 9-2 Duodenal ulcers.



Position of duodenum and pancreas

F. Netter M.D.
C. Machado M.D.

Duodenum and pancreas in situ: anterior view

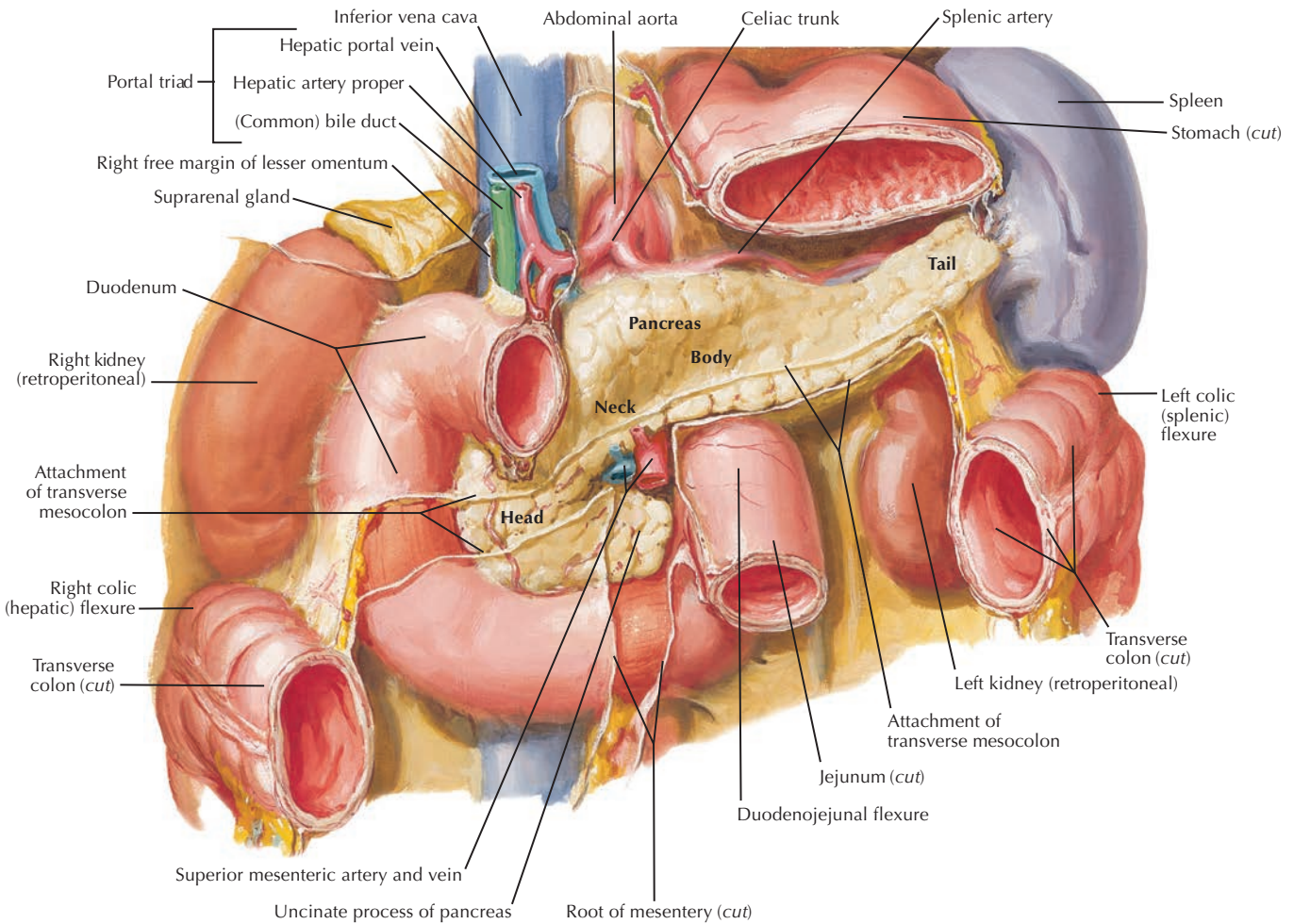


FIGURE 9-3 Anatomy of structures adjacent to duodenum.

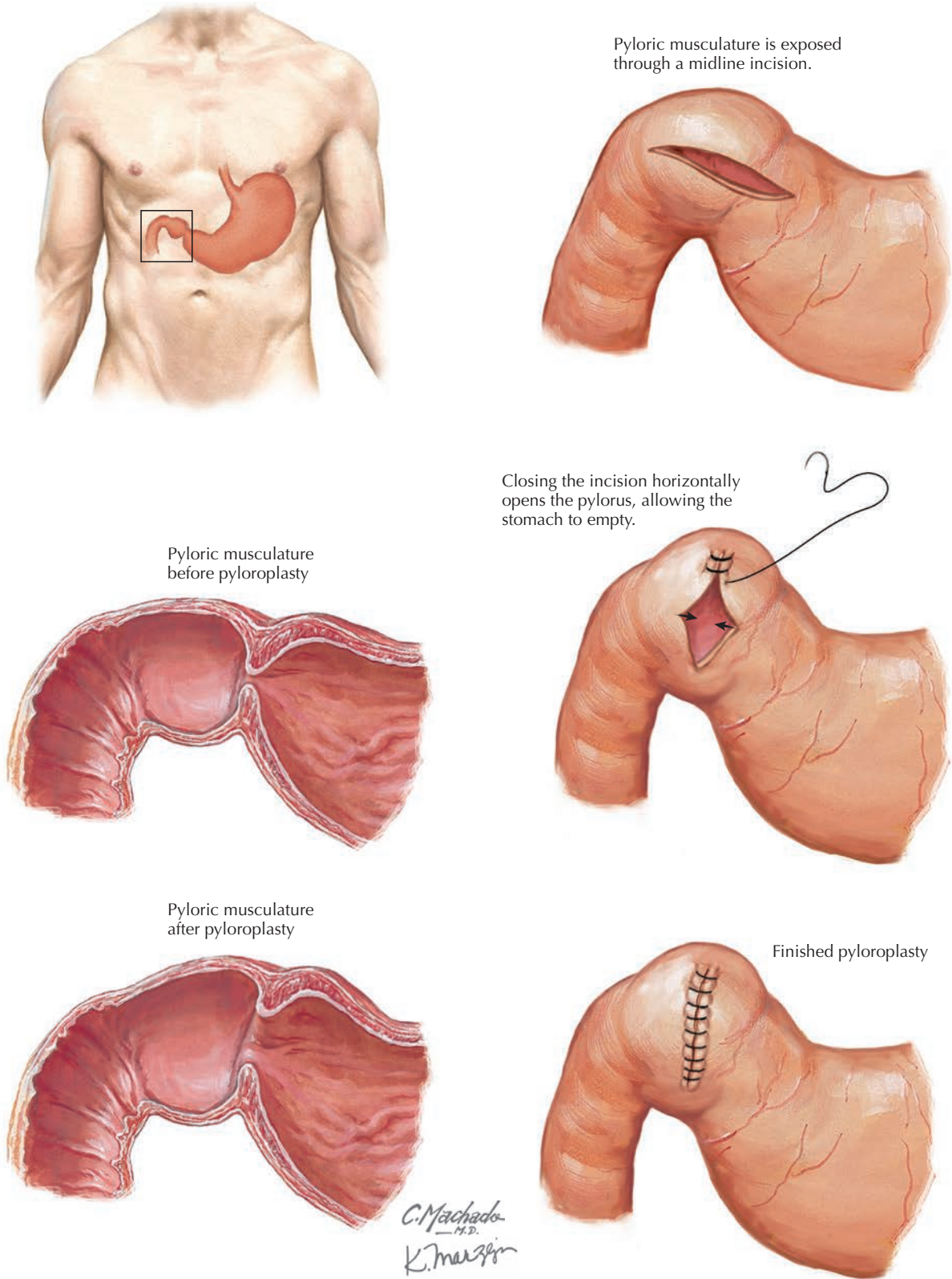


FIGURE 9-4 Pyloroplasty construction.

SUGGESTED READINGS

- Hunt PS, McIntyre RL. Choice of emergency operative procedure for bleeding duodenal ulcer. *Br J Surg* 1990;77(9):1004-6.
- Jawaid W, Abdalwahab A, Blair G, Skarsgard E, Webber E. Outcomes of pyloroplasty and pyloric dilatation in children diagnosed with nonobstructive delayed gastric emptying. *J Pediatr Surg* 2006;41(12):2059-61.
- Millat B, Hay JM, Valleur P, Fingerhut A, Fagniez PL. Emergency surgical treatment for bleeding duodenal ulcer: oversewing plus vagotomy versus gastric resection—a controlled randomized trial. French Associations for Surgical Research. *World J Surg* 1993;17(5):568-73; discussion 574.
- Sharma KK, Ranka P, Goyal P, Dabi DR. Gastric outlet obstruction in children: an overview with report of Jodhpur disease and Sharma's classification. *J Pediatr Surg* 2008;43(10):1891-7.

Pyloromyotomy for Pyloric Stenosis

Arielle Kanters and Todd Ponsky

INTRODUCTION

Pyloric stenosis occurs in approximately 3 of every 1000 births in the United States and is a common cause of gastric outlet obstruction in infants. First described in 1911, the Ramstedt approach to pyloric stenosis repair (extramucosal pyloromyotomy) has been the surgical standard of care until recently. This technique involves splitting the antropyloric mass while leaving the mucosa intact. Morbidity of the Ramstedt procedure is less than 10% and the mortality rate is less than 0.5%. The laparoscopic modification of the Ramstedt procedure has gained great support in recent years, and some argue that it has improved morbidity and mortality rates compared with the traditional open approach.

Pyloric stenosis results from hypertrophy of the musculature surrounding the pylorus, but the etiology is currently unknown. Possible causes include compensatory work hypertrophy from increased gastric mucosa, neurologic degeneration, and aberrant endocrine signaling. Strong evidence exists for many of these theories, indicating a multifactorial etiology. Risk factors for pyloric stenosis include gender, race, family history, maternal age, birth order, and maternal feeding patterns.

CLINICAL PRESENTATION AND DIAGNOSIS OF PYLORIC STENOSIS

A diagnosis of pyloric stenosis depends on both patient history and physical examination. Most patients will initially be seen with progressive, nonbilious projectile vomiting at 2 to 8 weeks of age. Patients may show signs of metabolic alkalosis, dehydration, and malnutrition, depending on duration of symptoms. On examination, visible peristaltic waves at the epigastrium and a palpable mass in the left upper quadrant may be present when the abdominal wall is relaxed. The mass is typically olive shaped, smooth, hard, and about 1 to 2 cm in size (Fig. 10-1). The hypertrophied pylorus can also be appreciated using ultrasonography or an upper gastrointestinal (GI) contrast study.

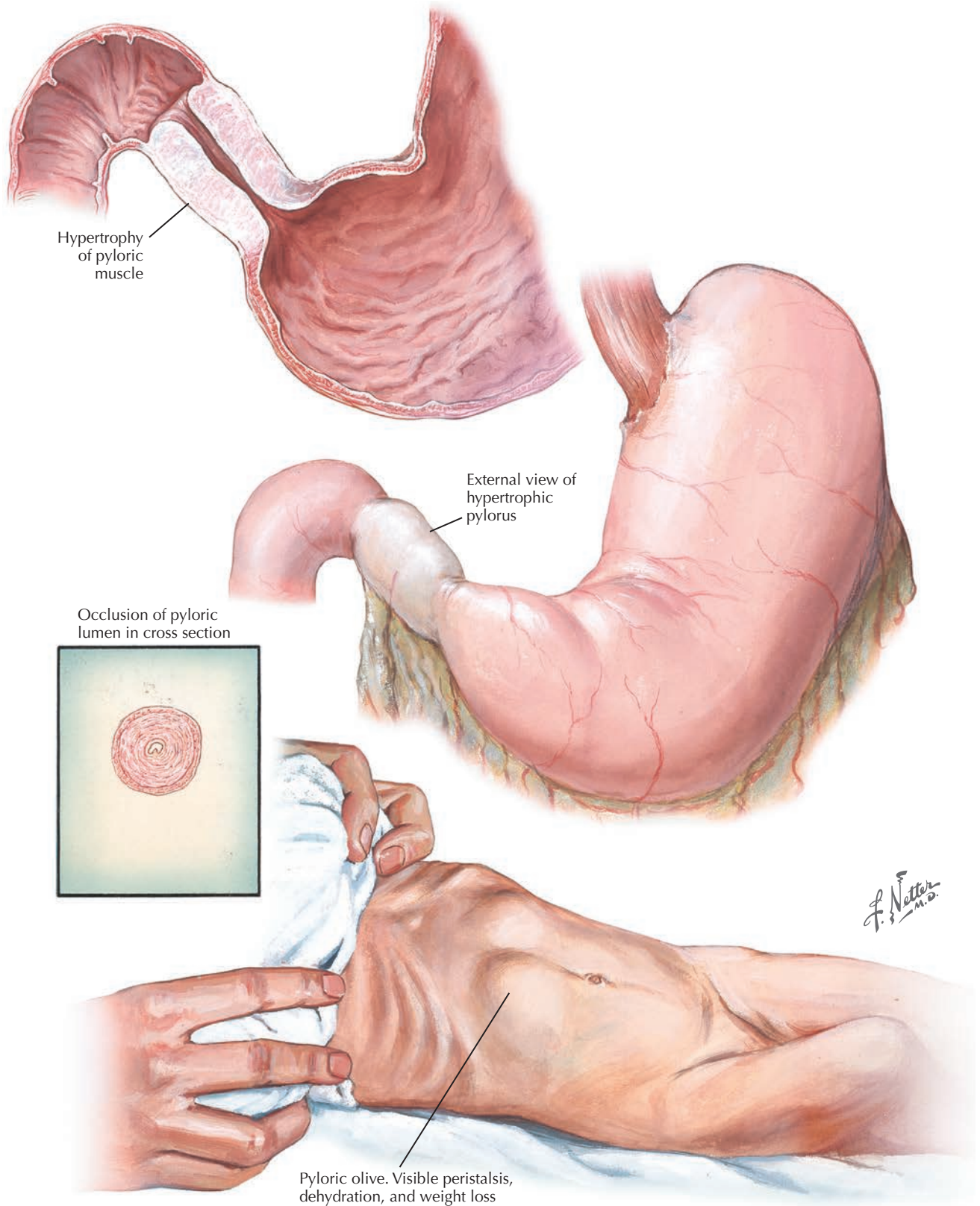


FIGURE 10-1 Hypertrophic pyloric stenosis.

PREOPERATIVE IMAGING OF PYLORIC STENOSIS

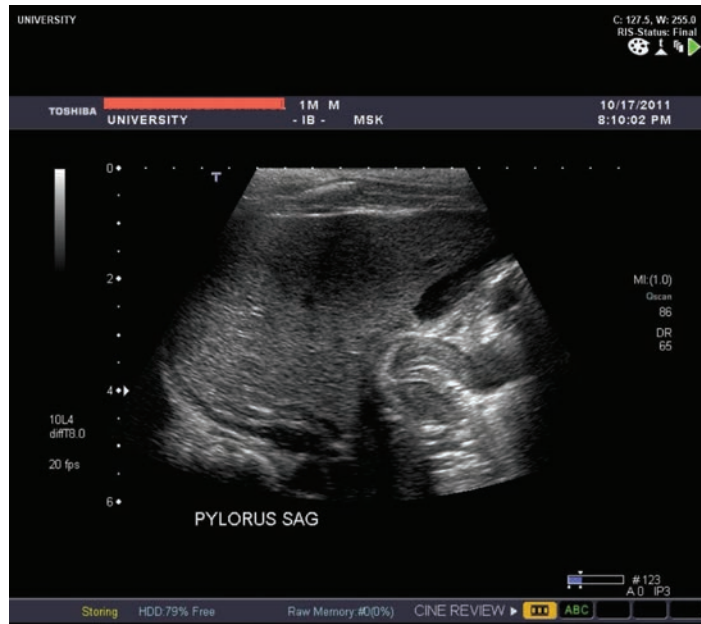
The ultrasonographic criteria for pyloric stenosis include an elongated pyloric channel (14 to 20 mm), an enlarged pyloric diameter (>12 mm), and a thickened muscle wall (>3 mm) (Fig. 10-2, A). A contrast study will demonstrate a distended stomach with a narrowed and elongated pyloric channel. These findings are often referred to as the “string” sign or “double track” sign. Upper GI studies can also show “shoulders” at the proximal end of the pylorus, indicating the hypertrophied muscle bulging into the gastric lumen, and a pyloric “beak” at the pyloric entrance to the antrum (Fig. 10-2, B).

PRINCIPLES OF PYLOROMYOTOMY

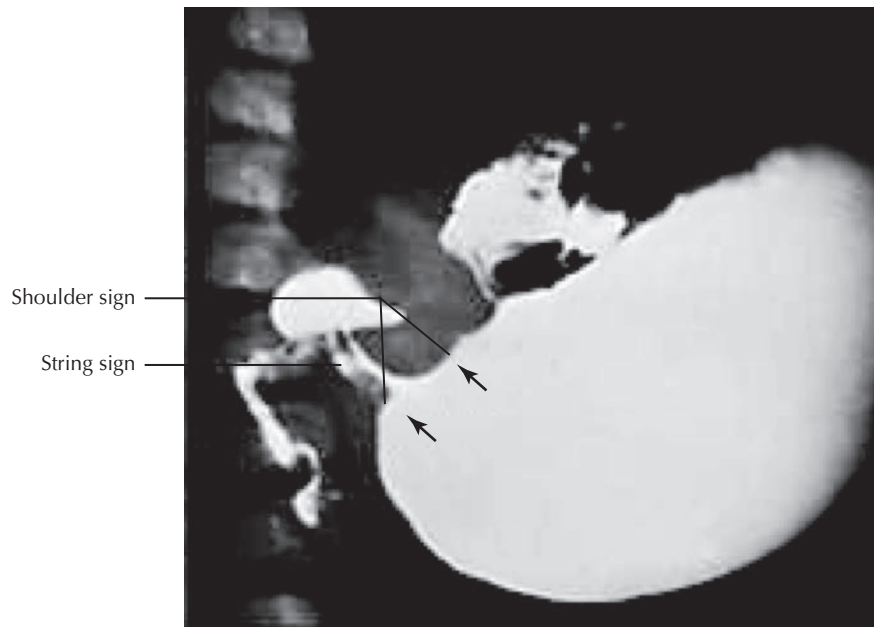
Before surgical intervention can be considered, it is important to assess and treat any signs of dehydration, metabolic alkalosis, or malnutrition, which can result from prolonged emesis. Although pyloric stenosis can be self-limiting, the standard of care in the United States is pyloromyotomy, performed as an open or laparoscopic procedure. The Ramstedt extramucosal pyloromyotomy is the classic open approach and can be performed through a number of incisions, including transverse right upper quadrant, Robertson gridiron, or circumbilical. Of the three, the circumbilical incision offers superior cosmetic results and decreased perioperative morbidity.

First described by Alain in 1991, the laparoscopic approach has been widely supported and has gained significant popularity in recent years. . Proponents of minimally invasive surgery cite many benefits, including faster recovery time, decreased postoperative pain, sooner return to feeding, and earlier discharge from the hospital. Advocates of the open approach argue that the two approaches have comparable recovery time, and that the laparoscopic approach has a greater complication rate, including mucosal injury, incomplete myotomy, increased operative time, and increased expense to the patient.

A. Ultrasound of pyloric stenosis



B. Upper GI contrast study



Characteristic findings of hypertrophic pyloric stenosis in a 7-week-old boy with a 4-week history of vomiting. The pyloric canal is narrow, demonstrating a double string sign. Indentation of the hypertrophied muscle on the lesser curvature is identified by the double arrows.

FIGURE 10-2 Ultrasonography and upper gastrointestinal contrast studies of pyloric stenosis. (B from Goske MJ, Schlesinger AE. Hypertrophic pyloric stenosis. In Slovis TL, editor. *Calley's pediatric diagnostic imaging*. St Louis: Mosby; 2008.)

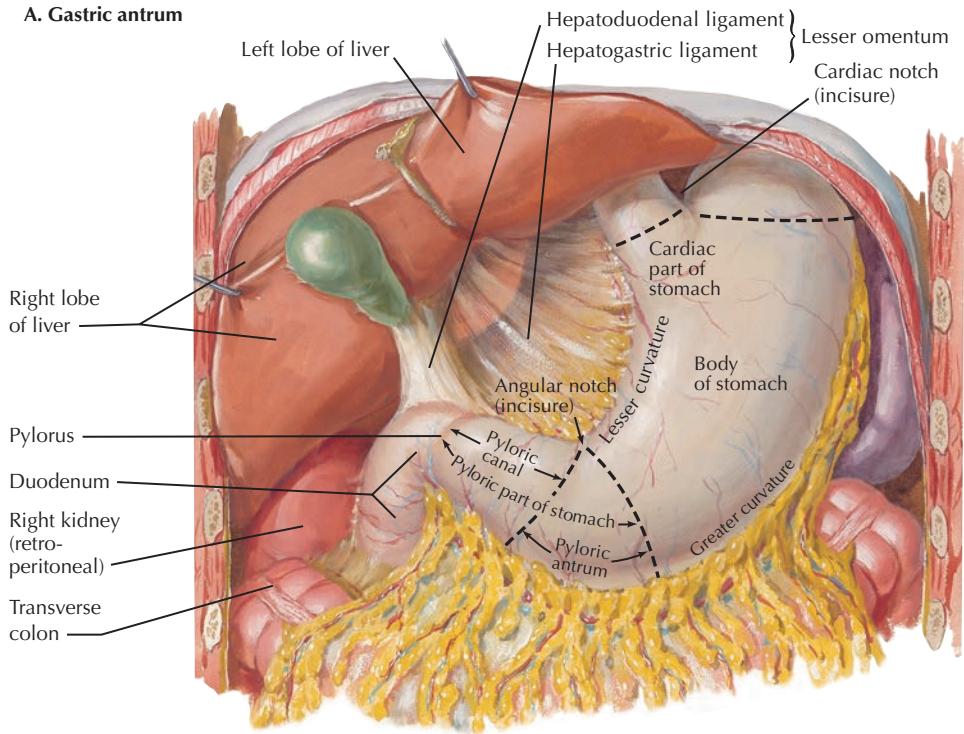
OPEN SURGICAL APPROACH

The open pyloromyotomy can be performed through a small, right upper quadrant incision. Alternatively, the surgeon may choose to enter the abdomen through a circumbilical incision. With this technique, an omega-shaped incision is made in a supraumbilical skin fold, through which the midline fascia is identified and exposed one-third to one-half the distance from the umbilicus to the xiphoid. To visualize the pylorus, the omentum must first be mobilized using gentle traction, thereby exposing the transverse colon. With the transverse colon displaced caudally, the gastric antrum is visible (Fig. 10-3, A).

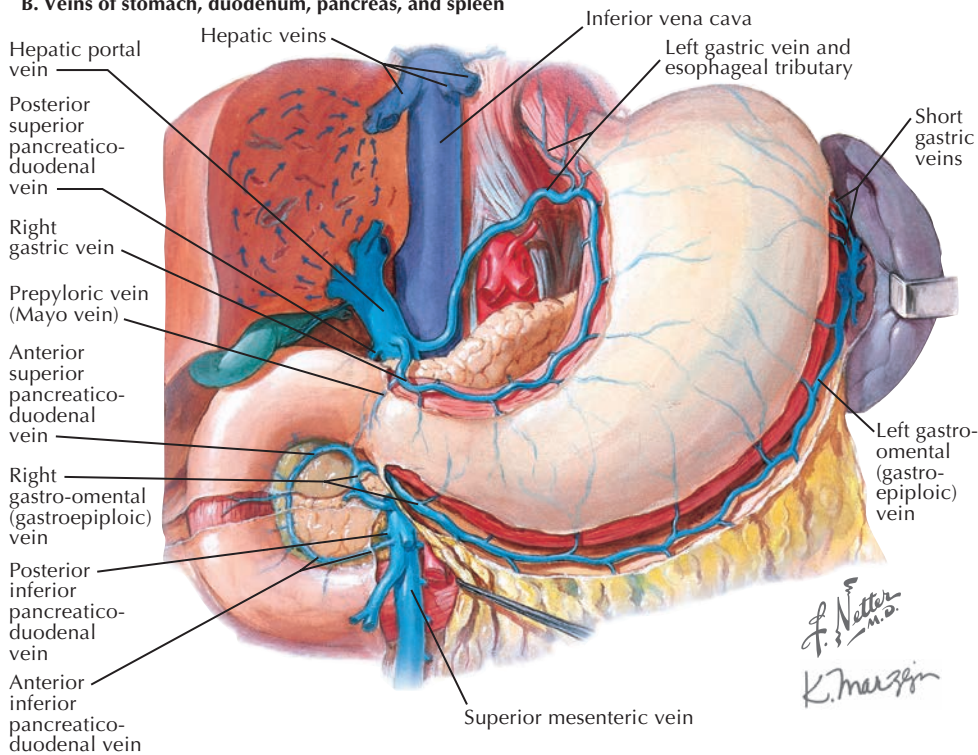
Gently grasping the greater curvature of the stomach with a sponge, the surgeon brings the pylorus into the wound by inferior and lateral traction on the stomach. The surgeon identifies the gastroduodenal junction by the prepyloric vein (Fig. 10-3, B). The surgeon secures the duodenal portion of the pylorus with the index finger of the nondominant hand and makes a 1- to 2-cm longitudinal incision along the plane of the transverse muscle fibers, from the proximal thickening of the muscle to within 3 mm of the antrum. The incision is taken through the serosal and muscle layers using blunt dissection, then widened using a Benson spreader until the submucosa bulges into the cleft (Fig. 10-3, C). Care should be taken to avoid injury to the distal pylorus, because the duodenal mucosa is fragile.

On completion of the myotomy, the two sides of the hypertrophied pylorus should move independently. Before closing the peritoneum and fascia of the transversalis muscle, the surgeon assesses the pylorus for leaks by filling the stomach with 60 to 100 mL of air. The air is then gently milked toward the antrum while the duodenum is sealed off with compression. Bubbles or bile-stained fluid would indicate leakage and thus mucosal injury. Any mucosal disruption must be repaired immediately and can be closed with fine nonabsorbable sutures. The fascial layers and skin are closed routinely.

A. Gastric antrum



B. Veins of stomach, duodenum, pancreas, and spleen



C. Open pyloromyotomy

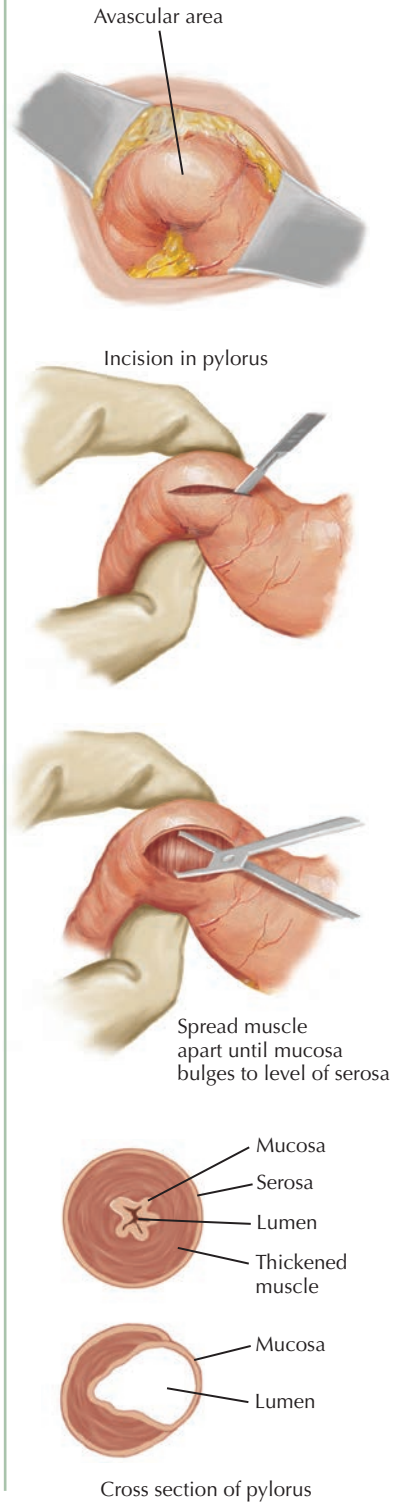


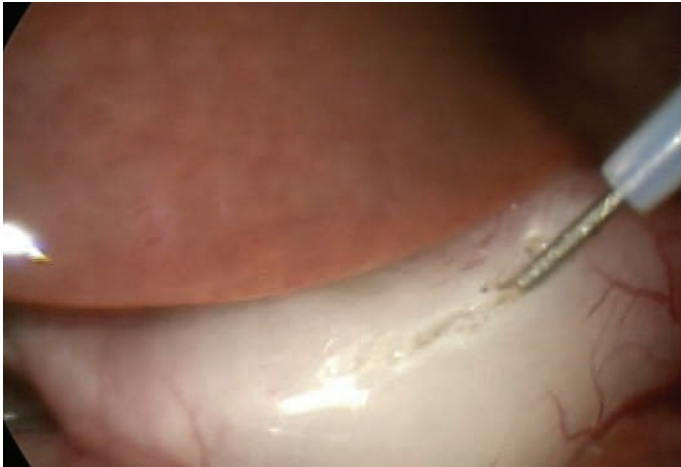FIGURE 10-3 Open pyloromyotomy.

LAPAROSCOPIC APPROACH

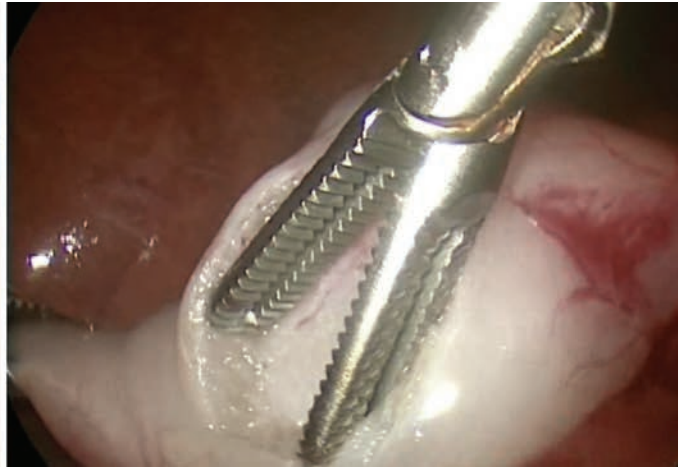The infant is placed in the supine position on the operating table with folded towels under the head and back to maintain reverse Trendelenburg position, allowing the intestines to fall away from the upper abdomen.

The umbilicus is entered bluntly with a fine mosquito clamp. A 3-mm, 4-mm, or 5-mm trocar, followed by a 30-degree telescope, is inserted through the umbilicus, and two 3-mm stab incisions are created in the left and right epigastrium (Fig. 10-4). A knife blade exposed to no more than 3 mm, or an extended-length, insulated Bovie electrocautery device with 3 mm of exposed blade, is placed in the left upper quadrant incision, while a pyloric grasper is inserted into the right upper quadrant incision. The grasper is used to secure the distal pylorus, and an incision is made along the anterior surface of the pylorus, extending from the prepyloric vein to the antrum of the stomach. The blunt blade of the knife or cautery blade is pushed into the myotomy incision, then rotated 60 to 90 degrees, thereby breaking down the muscular wall. As the incision is made deeper, the knife is replaced by the pyloric spreader. The myotomy is complete when the two cut edges move independently (Fig. 10-4).

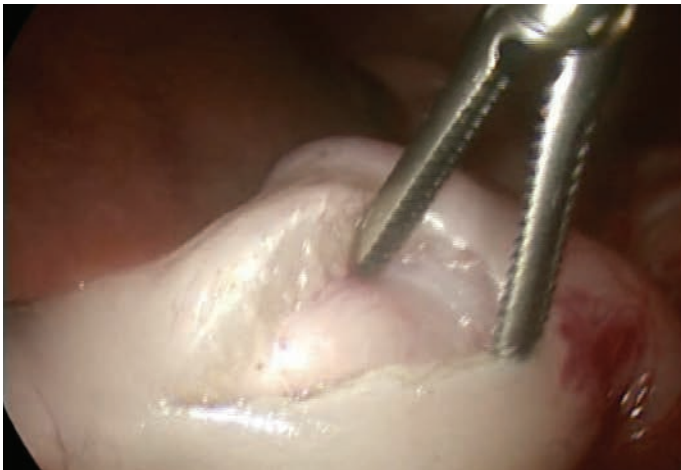As with the Ramstedt approach, the stomach is inflated with air while the duodenum is obstructed to test for injury to the mucosa. This approach also confirms that air can pass smoothly from the antrum to the stomach. If present, damage to the mucosa can be repaired with a single layer of nonabsorbable suture at the site of injury and covered with an omental patch. The incisions are closed routinely.



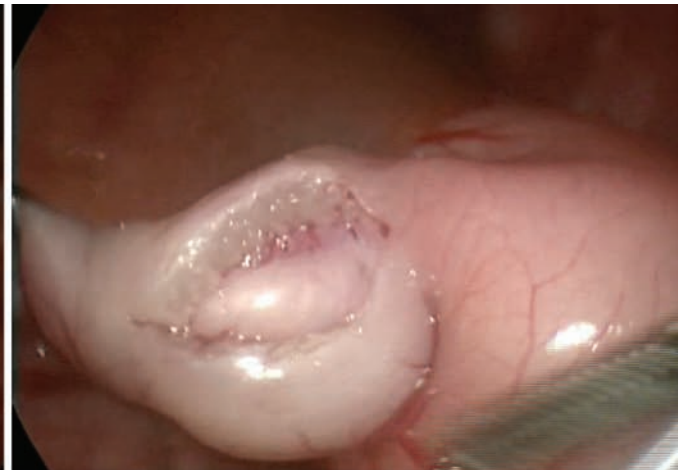1. A 3-mm-deep incision is made from the prepyloric vein to the antrum of the stomach.



2. A pyloric spreader is used to separate the two ends of the myotomy incision.



3. The myotomy is complete when the two edges move independently.



4. The mucosa can be seen bulging to the level of the serosa.

FIGURE 10-4 Laparoscopic approach to pyloric stenosis repair.

SUGGESTED READINGS

- Adibe O, Nichol P, Flake A, Mattei P. Comparisons of outcomes after laparoscopic and open pyloromyotomy at a high volume pediatric teaching hospital. *J Pediatr Surg* 2006;41(10):1676-8.
- Aspelund G, Langer J. Current management of hypertrophic pyloric stenosis. *Semin Pediatr Surg* 2007;16:27-33.
- Bufo AJ, Merry C, Shah R, et al. Laparoscopic pyloromyotomy: a safer technique. *Pediatr Surg Int* 1998;13(4):240-2.
- Campbell BT, McLean K, Barnhart DC, Drongowski RA, Hirschl RB. A comparison of laparoscopic and open pyloromyotomy at a teaching hospital. *J Pediatr Surg* 2002;37(7):1068-71.
- Hall NJ, Ade-Ajayi N, Al-Roubaie J, et al. Retrospective comparison of open versus laparoscopic pyloromyotomy. *Br J Surg* 2004;91(10):1325-9.
- Hussain M. Sonographic diagnosis of infantile hypertrophic pyloric stenosis: use of simultaneous grey-scale and colour Doppler examination. *Int J Health Sci* 2008;2(2):143-50.
- St Peter SD, Holcomb GW 3rd, Calkins CM, et al. Open versus laparoscopic pyloromyotomy for pyloric stenosis: a prospective, randomized trial. *Ann Surg* 2006;244(3):363-70.

Laparoscopic Roux-en-Y Gastric Bypass



Alan A. Saber

INTRODUCTION

Obesity is a major health problem worldwide and has reached an epidemic proportion in Western society. A major risk factor for many diseases, obesity is associated with significant morbidity and mortality.

Bariatric surgery is currently the only modality that provides significant, long-term weight loss for the patient who is morbidly obese, with resultant improvement in obesity-related comorbidities. Gastric bypass is becoming the “gold standard” for surgical management of morbid obesity in the United States.

SURGICAL CRITERIA

Surgery for obesity should be considered a treatment of last resort after dieting, exercise, psychotherapy, and drug treatments have failed. National Institutes of Health (NIH) criteria for surgical treatment include a body mass index (BMI) of greater than 40 kg/m² or a BMI of greater than 35 kg/m² in combination with high-risk comorbid conditions.

SURGICAL ANATOMY

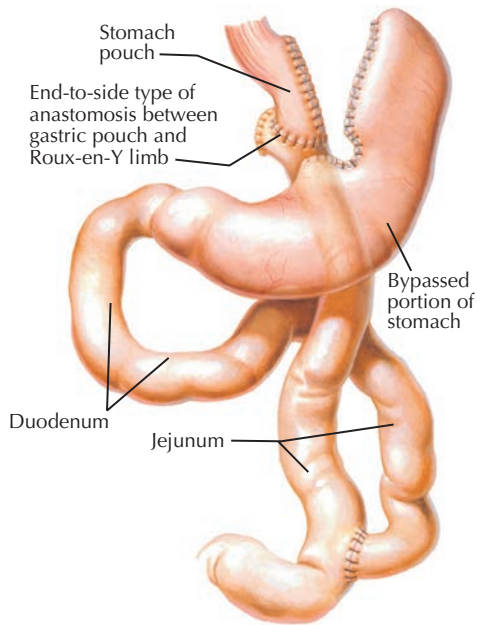
Gastric bypass is the most common bariatric procedure. It has two components, restrictive and malabsorptive, which are both demonstrated in the depiction of a Roux-en-Y gastric bypass (Fig. 11-1, A). Because these patients are by definition morbidly obese, the excessive intra-abdominal fat can make identification of the anatomy difficult. This chapter describes the anatomic landmarks during Roux-en-Y gastric bypass procedure.

The restrictive component of gastric bypass depends on manufacture of a constricted, vertically oriented 20-mL gastric pouch, based on the lesser curvature of the stomach. The lesser curvature musculature is thick and less likely to distend than the fundus of the stomach (Fig. 11-1, B).

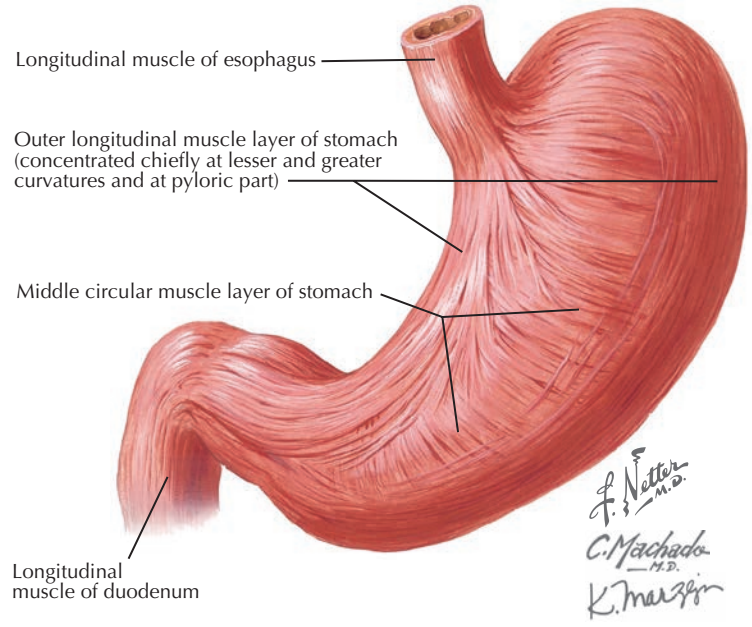
Identification and dissection of the *angle of His* (the angle between the fundus and abdominal esophagus) is a crucial step during construction of the gastric pouch. The angle of His is just to the left of the midline and the gastroesophageal fat pad of Belsey. Transection of the stomach at the angle of His will separate the gastric fundus from the gastric pouch, because the gastric fundus can distend, with resultant weight gain (Fig. 11-1, C). This approach also avoids stapling of the esophagus.

The anterior and posterior nerves of Latarjet descend along the lesser curvature of the stomach and usually lie 0.5 to 1 cm from the gastric wall. On opening the gastrohepatic ligament, the surgeon must perform dissection perigastrically to avoid injury of the anterior or posterior nerve of Latarjet. Injury of these nerves may result in delayed emptying of the distal stomach. Retrogastric adhesions are taken down to allow complete mobilization of the stomach, eliminate any redundant posterior wall of the pouch, and exclude the fundus from the gastric pouch.

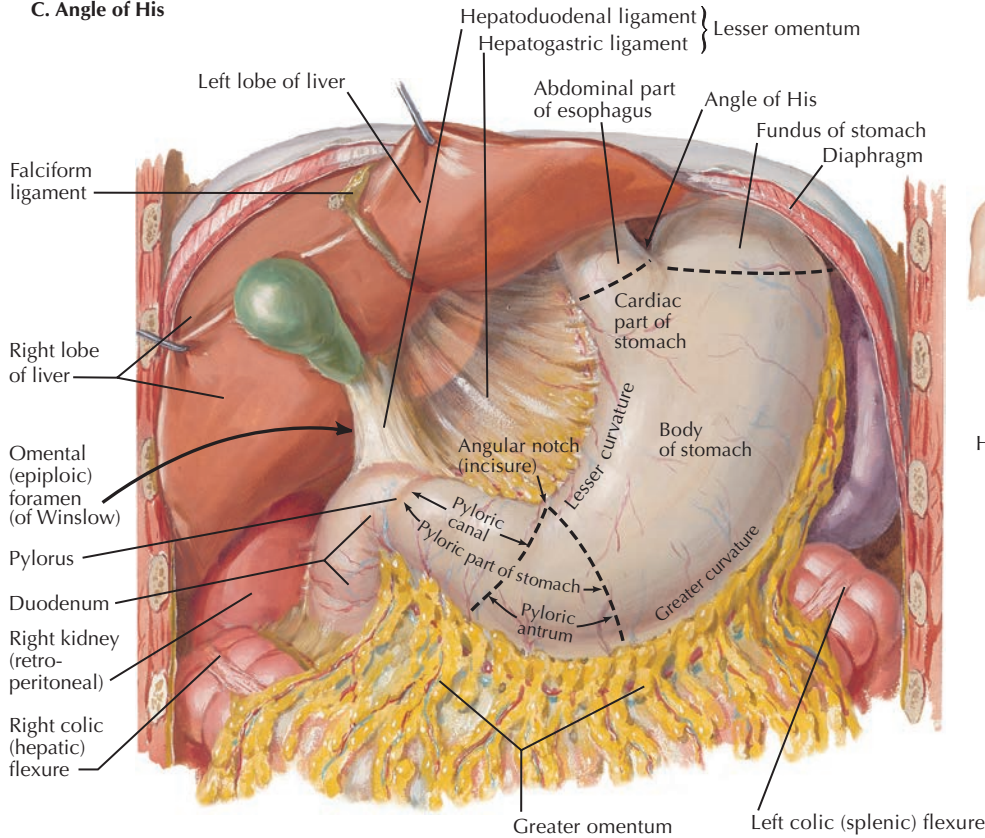
A. Roux-en-Y gastric bypass



B. Stomach musculature



C. Angle of His



Variations in position and contour of stomach in relation to body habitus

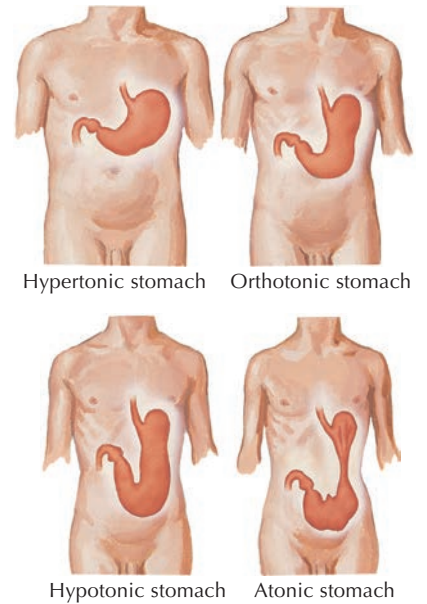


FIGURE 11-1 Roux-en-Y bypass, stomach musculature, and angle of His.

SURGICAL ANATOMY—Cont'd

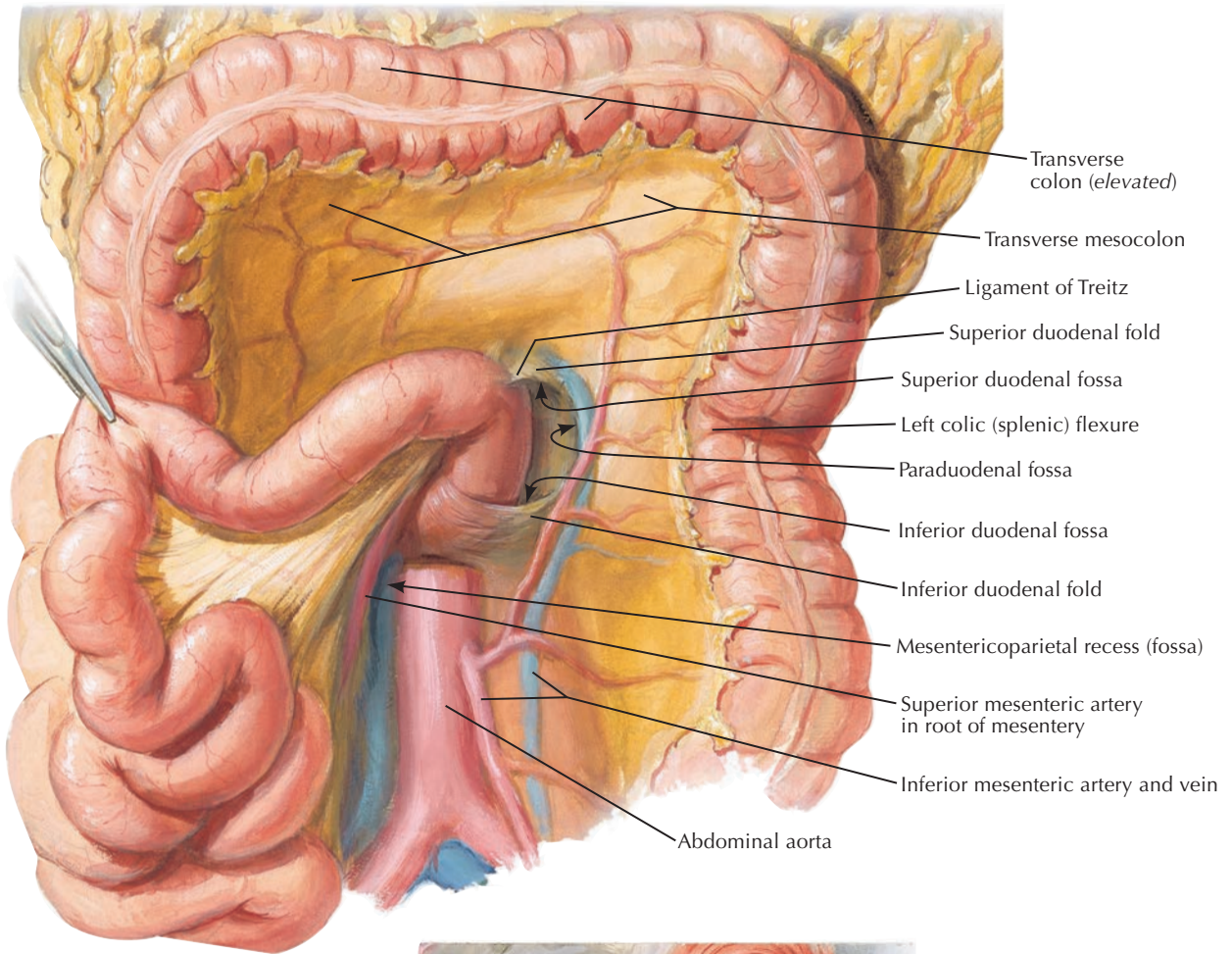
Three options to bring the Roux limb up to the gastric pouch are antecolic antegastric, retrocolic retrogastric, and retrocolic antegastric. Retrocolic retrogastric is the shortest path to the gastric pouch (tension free), whereas antecolic antegastric is the simplest of the three approaches.

The greater omentum is divided vertically in the midline, starting from the inferior edge of the omentum to the transverse colon. This approach will decrease the tension on antecolic antegastric Roux limb.

The ligament of Treitz is identified to the left of midline, with the inferior mesenteric vein to its left (Fig. 11-2). On creating a retrocolic path for the Roux limb, a defect in the transverse mesocolon must be anterior and to the left of ligament of Treitz to avoid injury to the middle colic vessels and to the pancreas.

The left gastric artery is the main arterial supply to the gastric pouch, which arises from the celiac artery. Initially, it runs superiorly and to the left to approach the gastroesophageal junction, where it gives rise to esophageal branches, turns inferiorly to follow the lesser curvature of the stomach, and terminates by anastomosing with the much smaller right gastric artery. In 25% of cases, the left gastric artery also gives rise to the left hepatic artery (or accessory left hepatic arteries), which runs through the superior part of the gastrohepatic ligament (Fig. 11-3, A; see also Fig. 6-4).

During Roux-en-Y gastric bypass, several internal defects must be closed with running non-absorbable suture to avoid internal hernia. These defects include Peterson's defect (between Roux limb mesentery and transverse mesocolon), intermesenteric defect, and the defect in the transverse mesocolon (in retrocolic technique) (Fig. 11-3, B). Bleeding and leakage may also occur but are minimized with good surgical technique. Late fistulization from the small gastric pouch remnant to the large residual stomach is an unusual cause of failure.



F. Netter M.D.

Exposure of suspensory muscle of duodenum (ligament of Treitz)

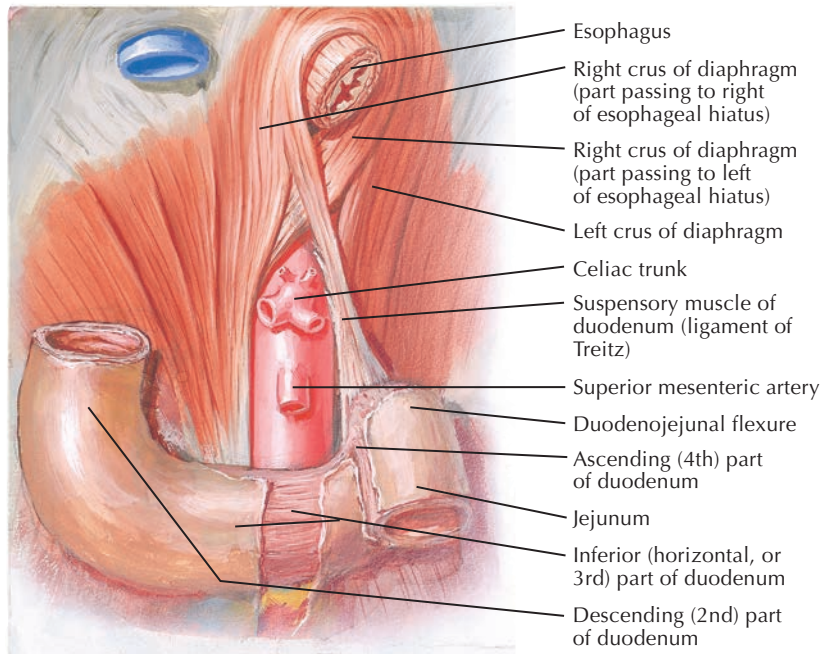
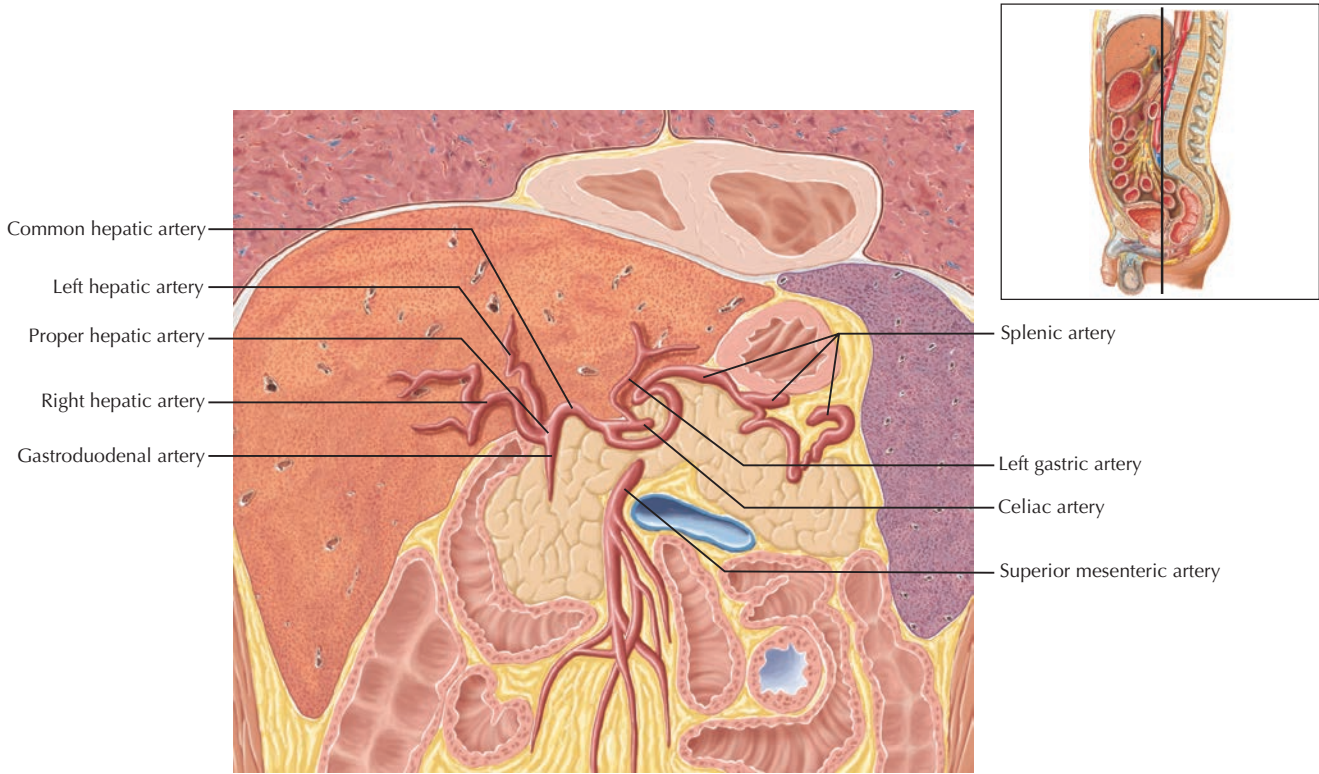


FIGURE 11-2 Roux-en-Y approach and ligament of Treitz.

A. Cross section of abdominal vasculature (coronal view)



B. Potential herniation sites

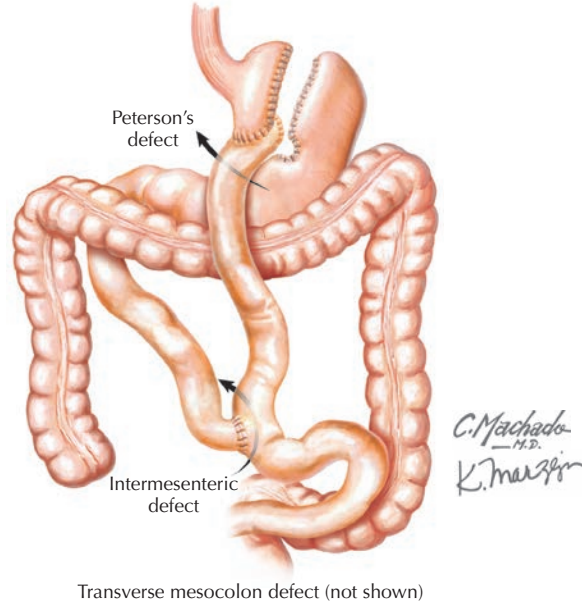


FIGURE 11-3 Gastric arterial supply and closing of internal defects.

SUGGESTED READINGS

Higa KD, Boone KB, Ho T, Davies OG. Laparoscopic Roux-en-Y gastric bypass for morbid obesity: technique and preliminary results of our first 400 patients. *Arch Surg* 2000;135(9):1029-33.

Saber AA, Jackson O. Omental wrap: a simple technique for reinforcement of the gastrojejunostomy during Roux-en-Y gastric bypass. *Obes Surg* 2007;17(1):15-8.

Sarr MG. Open Roux-en-Y gastric bypass: indications and technique. *J Gastrointest Surg* 2004;8(4):390-2.

Laparoscopic and Open Cholecystectomy



Juan Sanabria

INTRODUCTION

Removal of the gallbladder is one of the most common surgeries performed in United States. More than 650,000 cholecystectomies are done each year, with the majority accomplished by laparoscopic techniques. Indications for cholecystectomy include benign and malignant processes. By far the most frequent indication for cholecystectomy is symptomatic gallstone disease.

GALLBLADDER ANATOMY

The gallbladder is an ovoid bag located in the gallbladder fossae of the liver capable of storing up to 50 mL of bile. The gallbladder has a fundus, body, and infundibulum, and it continues by the cystic duct to join the common hepatic duct (CHD) and form the common bile duct (CBD) (Fig. 12-1).

The right hepatic artery passes behind the CHD, where the cystic artery originates, and reaches the gallbladder at the cystic node level. This represents the most common anatomic variation but is present in only 50% to 70% of patients. The surgeon must be aware of all anatomic variations of the biliary tree and hepatic artery to avoid injury to the CBD and vascular structures (Figs. 12-2 and 12-3).

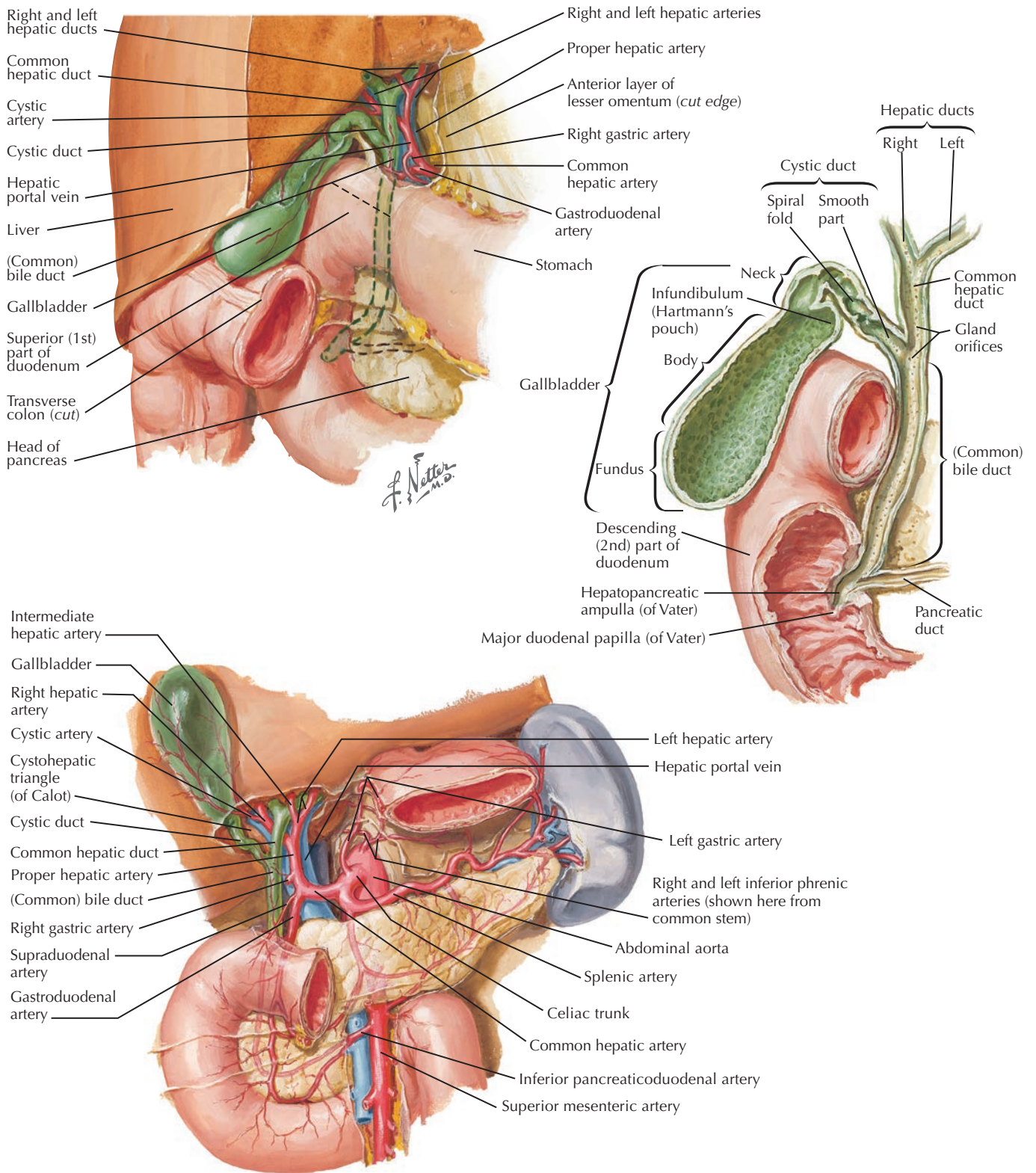
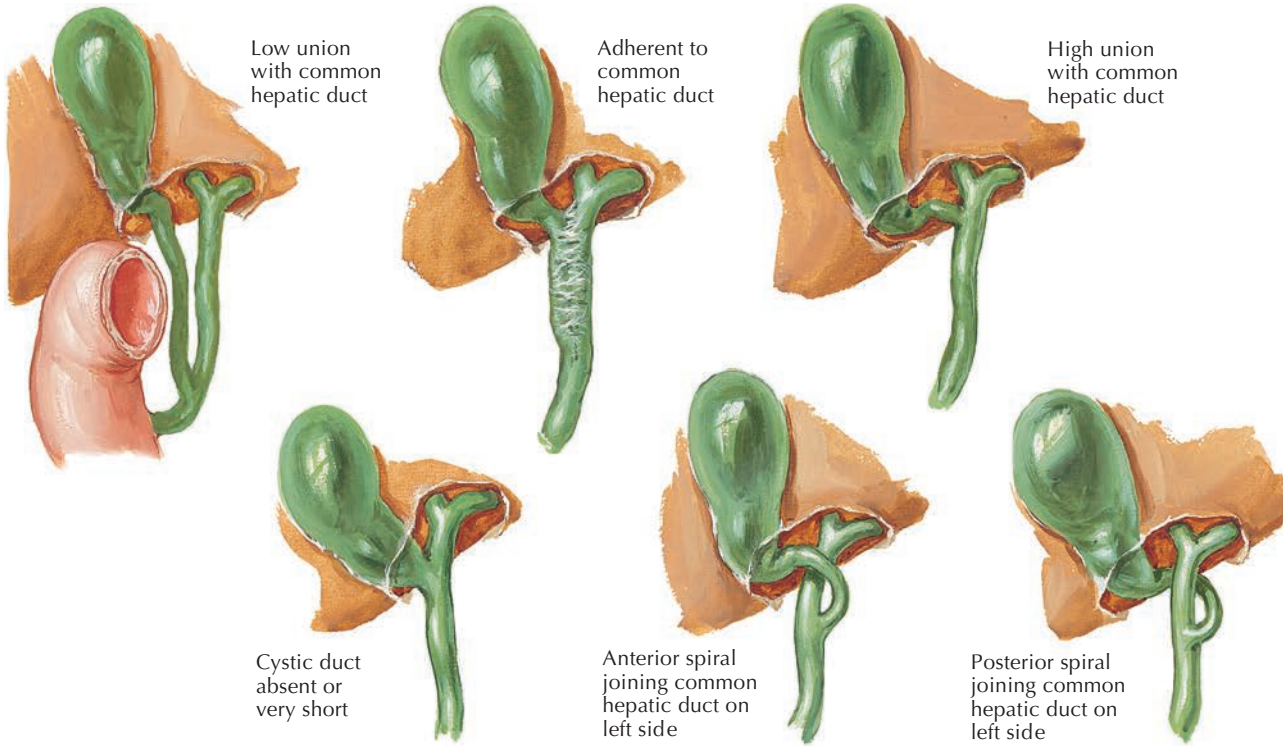


FIGURE 12-1 Gallbladder and extrahepatic bile ducts and arterial supply.

Variations in cystic duct



Accessory (aberrant) hepatic ducts

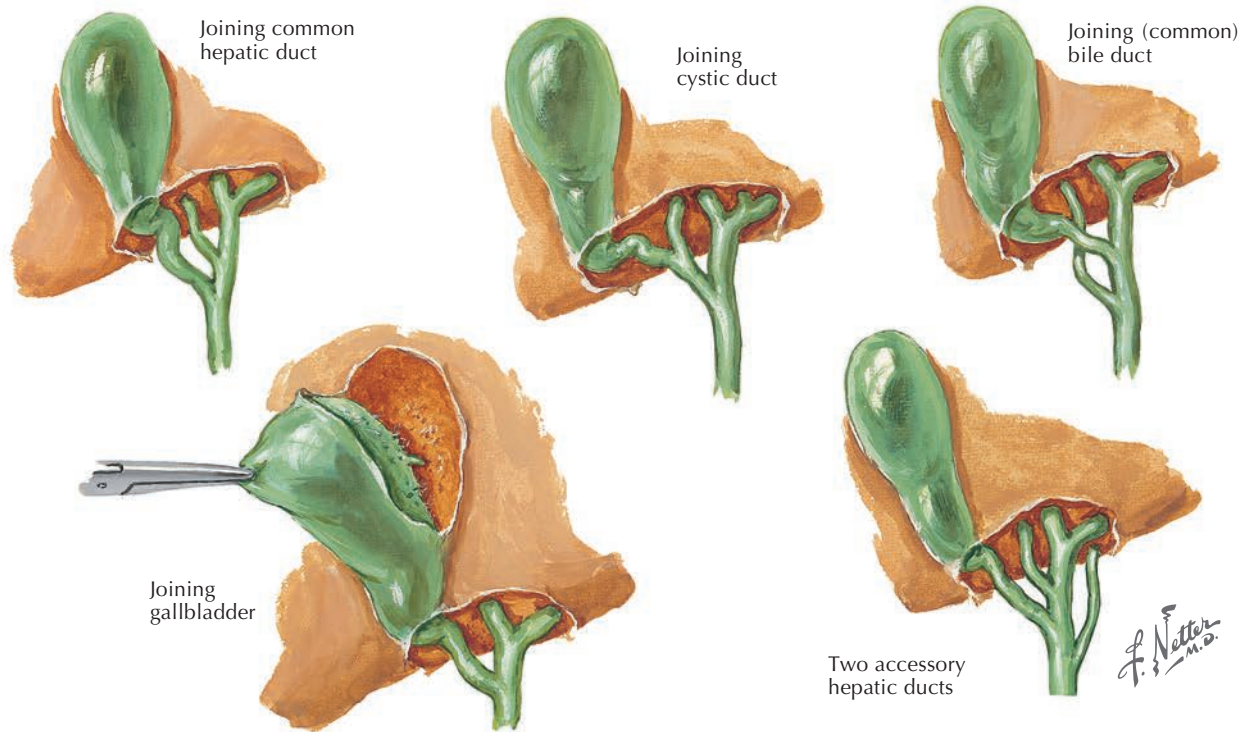


FIGURE 12-2 Variations in cystic and hepatic ducts.

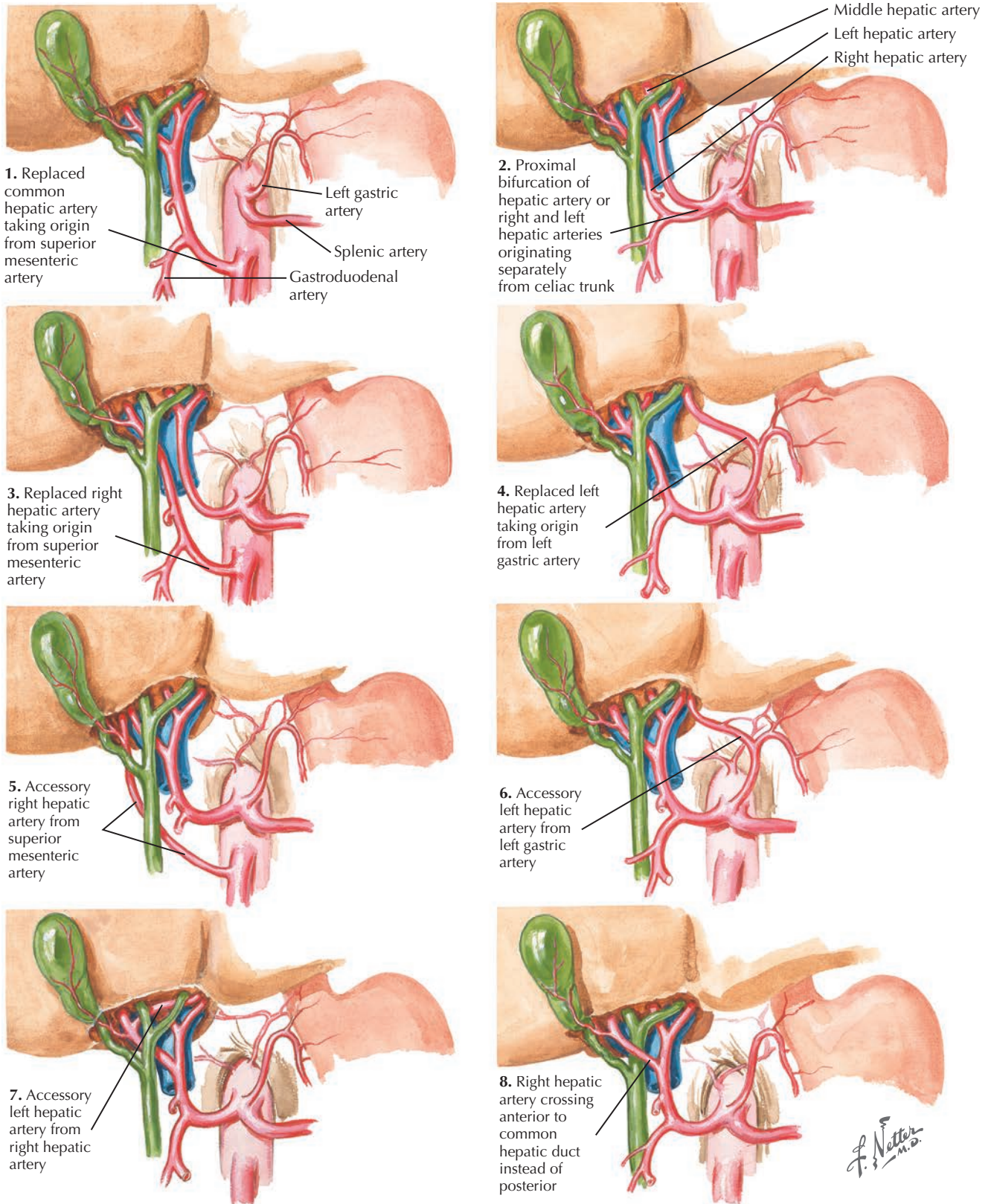


FIGURE 12-3 Hepatic artery variations.

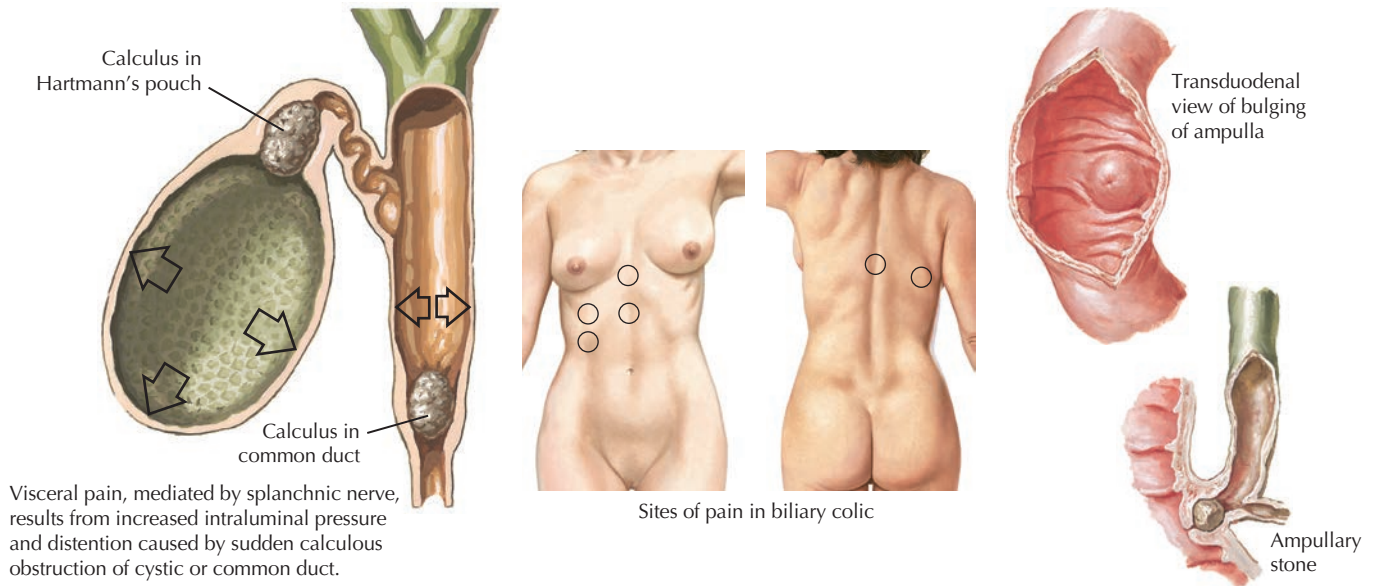
SYMPTOMATIC GALLSTONES: CLINICAL MANIFESTATIONS

Although more than 60% of adults older than 60 have gallstones in Western countries, only 20% become symptomatic. The hallmark of symptomatic gallstone disease is abdominal pain, usually in the right upper quadrant (RUQ), with radiation to the back, right shoulder, or epigastrium (Fig. 12-4). Pain classically occurs 30 minutes to 2 hours after the ingestion of a fatty meal and varies in severity. Pain typically is not constant and may be associated with nausea and vomiting. This presentation as *biliary colic* could progress to an acute inflammatory state promoted by the impaction of a stone in the neck of the gallbladder (see Fig. 12-1).

Patients with acute cholecystitis have constant RUQ pain, tenderness at deep palpation (a surrogate of Murphy sign), hyperthermia, and elevated white blood cell count (Fig. 12-4). The stone may pass to the CBD, causing obstruction and development of jaundice. A patient with RUQ pain, fever, leukocytosis, and jaundice, with or without mental changes and hemodynamic compromise, has *cholangitis*, a true surgical emergency. Other stones produce distal obstruction of the CBD and pancreatic duct, causing an acute episode of pancreatitis. However, most stones that reach the CBD pass into the duodenum, to be passed without consequence.

In another complication of gallstone disease, *gallstone ileus*, the stone erodes through the gallbladder wall and passes into the duodenum or colon. If the stone becomes impacted in the duodenum, it manifests as gastric outlet syndrome (Bouveret syndrome). More often, if it becomes stuck in the terminal ileum, the stone manifests as small bowel obstruction with pneumobilia.

Sudden obstruction (biliary colic)



Persistent obstruction (acute cholecystitis)

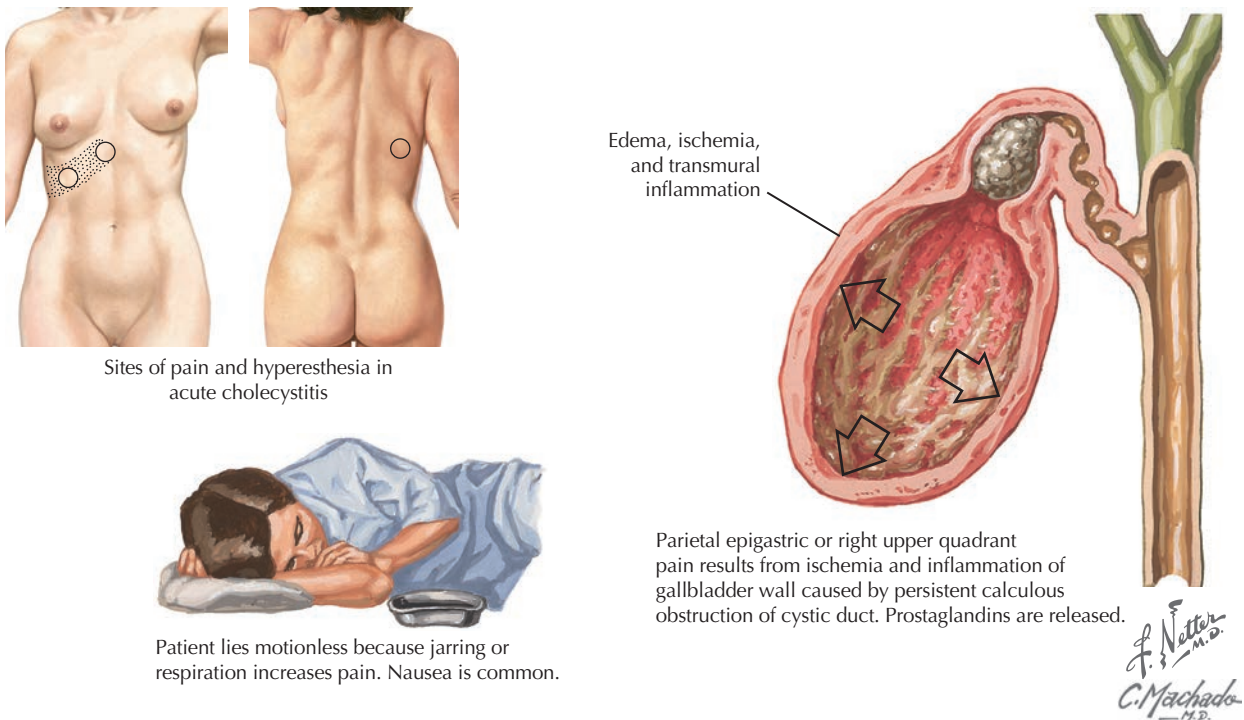


FIGURE 12-4 Cholelithiasis (gallstones).

LAPAROSCOPIC APPROACH

Indications for laparoscopic cholecystectomy include biliary colic, acute and chronic cholecystitis, cholangitis, and gallstones pancreatitis. The author recommends starting the planned procedure laparoscopically, but with a low threshold for conversion to open cholecystectomy in patients with suspected Mirizzi syndrome, gallbladder cancer, or unusual anatomic variation and patients with severe portal hypertension. The surgeon is positioned on the left side of the patient with a camera assistant at the surgeon's side and a second assistant on the right side.

Positioning and Trocar Placement

The patient is placed in a supine position. Pneumoperitoneum is achieved by the placement of a 10-mm umbilical trocar using the open technique or by the use of the Veress needle. The author favors the use of the open Hasson trocar technique. Once the gallbladder is visualized, one subxyphoid 5-mm or 10-mm trocar is placed, and as needed, one or two 5-mm trocars, in the RUQ. Infiltration of local anesthetic is recommended before trocar placement. Surgeons with advanced laparoscopic skills may place three trocars (only one RUQ trocar) or may use single-port techniques.

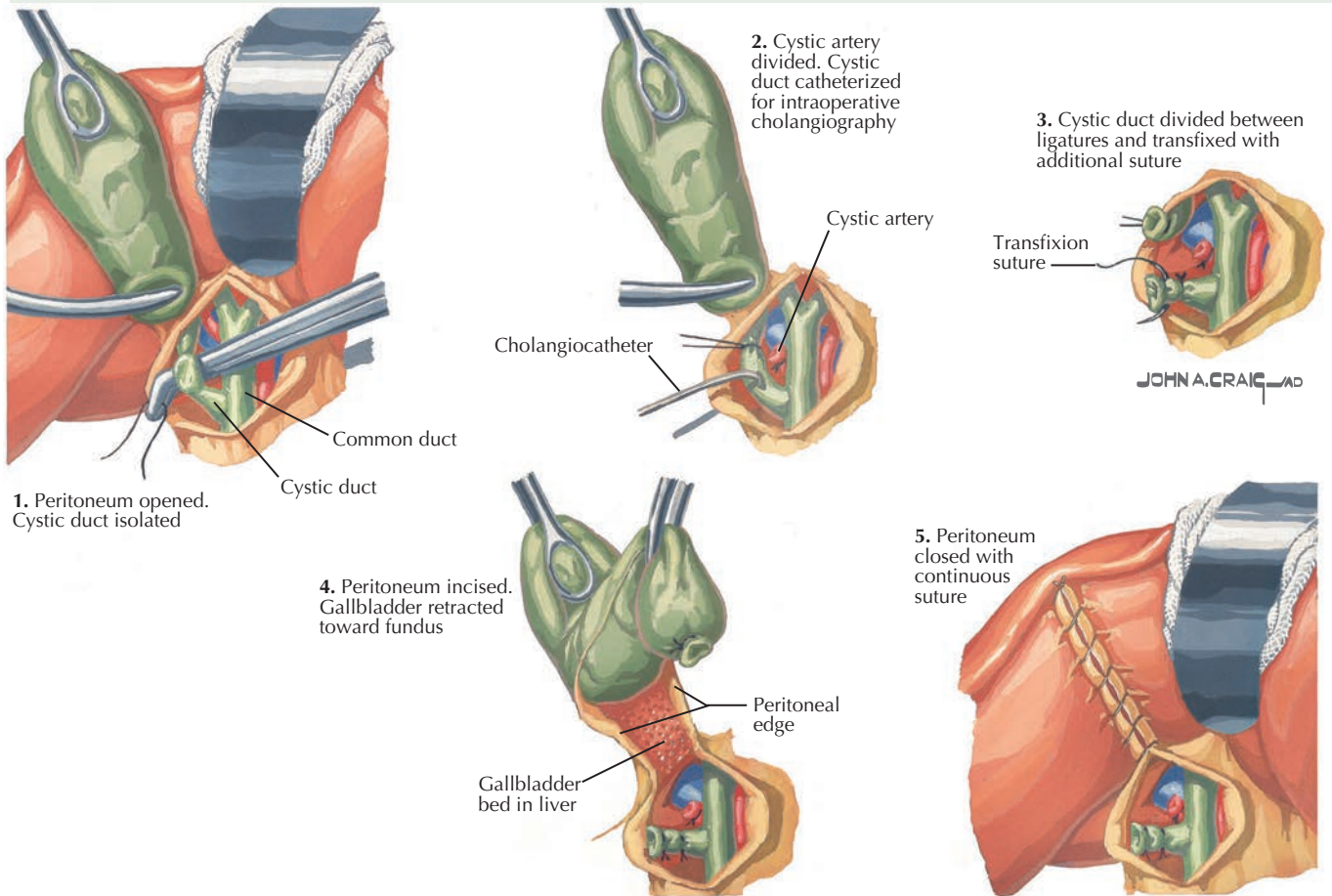
The Critical View

Ideal retraction of the gallbladder is exercised by its fundus in a cephalad fashion and by its neck in a lateral manner. Position of the patient with the head up (reverse Trendelenburg) and the right side up, in addition to a decompressed stomach, is recommended.

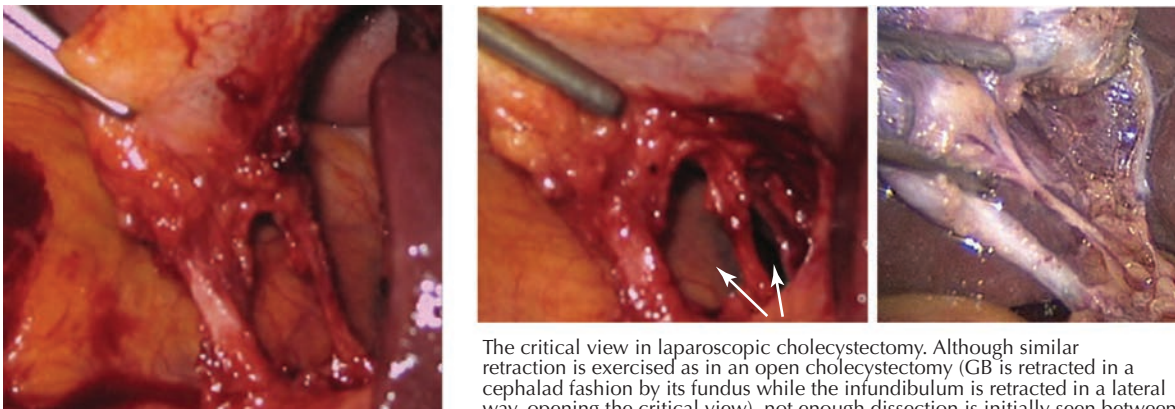
Once the cystic node is identified, division of the anterior and posterior peritoneal folds is performed, followed by blunt dissection of Calot's triangle until demonstration of (1) a tubular structure that goes from the gallbladder infundibulum toward the porta hepatis, (2) a tubular structure with arterial pulse running from the porta hepatis to the gallbladder, and (3) liver tissue in the background with no other structure in between (Fig. 12-5).

Once this critical view is confirmed, the cystic artery and the cystic duct are controlled and ligated. Intraoperative cholangiography (IOC) is performed at the surgeon's discretion. Some surgeons are "routine cholangiographers," whereas others employ selective cholangiography. Indications for IOC include unclear anatomy, history of CBD stones, and suspected malignancy.

Cholecystectomy



Critical view in open and laparoscopic cholecystectomy



The critical view in open cholecystectomy. Note the GB is retracted in a cephalad fashion by its fundus while the infundibulum is retracted in a lateral way, opening the critical view with demonstration of the cystic duct, artery, and no other structure in between.

The critical view in laparoscopic cholecystectomy. Although similar retraction is exercised as in an open cholecystectomy (GB is retracted in a cephalad fashion by its fundus while the infundibulum is retracted in a lateral way, opening the critical view), not enough dissection is initially seen between the cystic duct and cystic artery (*first arrow*) and between the cystic artery and the cystic plate on the liver (*second arrow*). Further dissection was performed with a clear demonstration of the critical view.

FIGURE 12-5 Cholecystectomy and the critical view. GB, Gallbladder.

Intraoperative Ultrasound and Cholangiography

The choice of imaging modality is determined by surgical indication and the practice styles of individual surgeons. Intraoperative ultrasound (IOU) has a high degree of sensitivity and specificity for intraluminal CBD defects, lymphadenomegaly, and vascular assessment. IOU also can be performed on both the liver and the pancreas. It requires a 12-mm trocar for the introduction of the laparoscopic probe. For the assessment of biliary anatomy, mucosal lesions, or intraluminal defects, IOC is favored (Fig. 12-6, *A*).

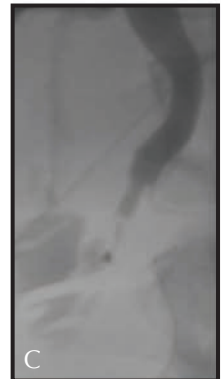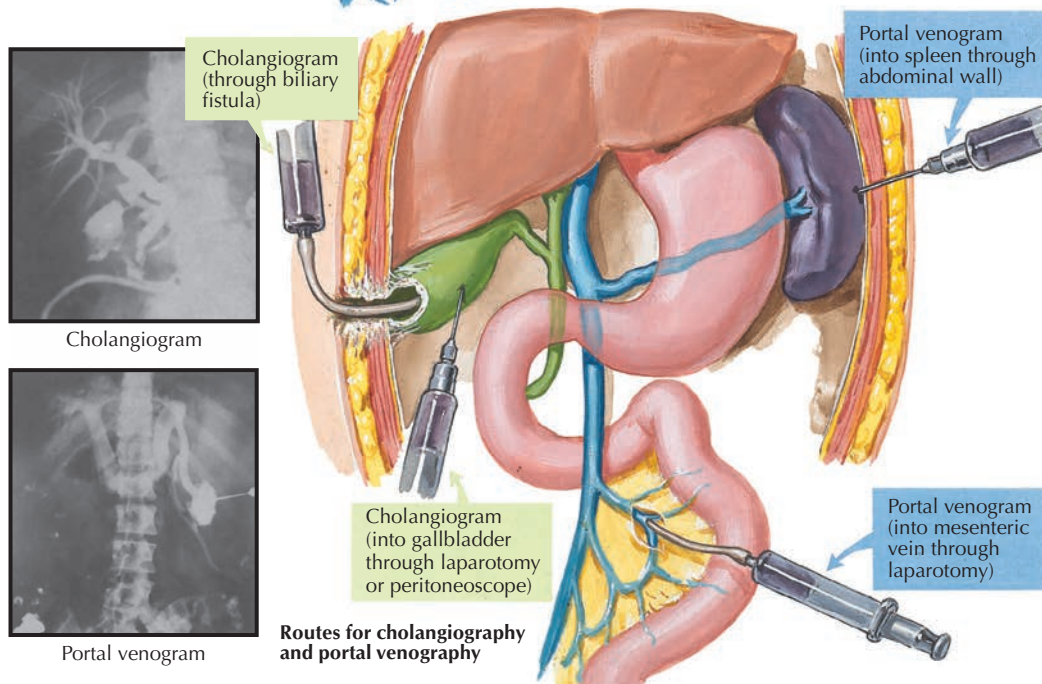
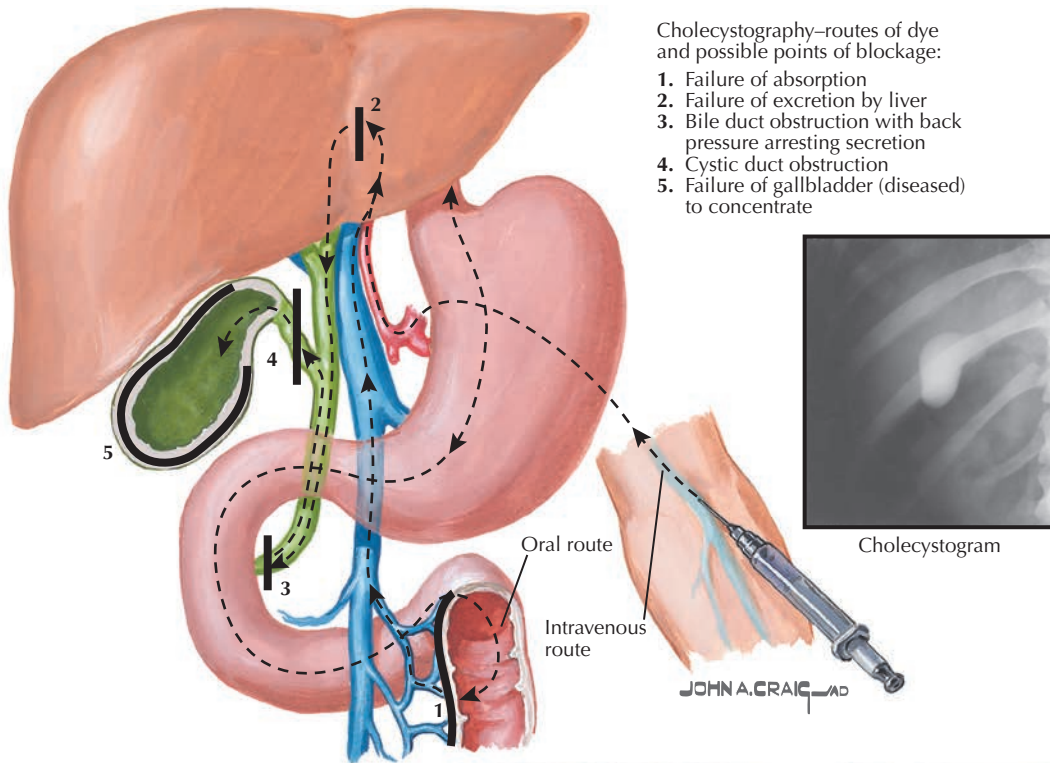
Familiarity with the different kits available for cholangiography is advised. The author uses a dynamic cholangiogram with fluoroscopy to observe the infusion of 50% diluted contrast through a preflushed soft, 5-Fr tube with a 1-mL occlusion balloon. Proper evaluation of a cholangiogram includes identification of the cystic duct with filling of the CBD (Fig. 12-6, *B*), passage of the contrast to the duodenum (12-6, *C*), visualization of the CHD and its bifurcation (12-6, *D*), and lack of mucosal abnormalities or luminal defects. In some patients, the administration of intravenous glucagon is required to achieve passage of contrast into the duodenum.

Meniscal morphology with obstruction should prompt the search for a CBD stone, and a mucosal abnormality signals possible malignancy (Fig 12-6, *E*). If segmental biliary duct injury is suspected, identification of all intrahepatic segmental ducts is mandatory.

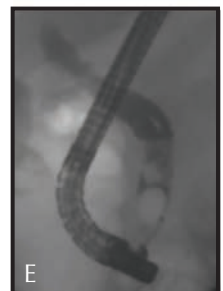
Gallbladder Removal and Extraction

The gallbladder is dissected from the liver bed with cautery, achieving complete hemostasis and ensuring no other tubular structures are divided (i.e., abnormal subsegmental bile ducts). The gallbladder is then placed in a plastic bag and removed under direct vision. The gallbladder specimen is opened in the operating room and verification of proper anatomy established.

A. Cholecystography, cholangiography, portal venography



B-D. Proper evaluation of a cholangiogram includes identification of the cystic duct with filling of the CBD (B), passage of the contrast to the duodenum (C), visualization of the CHD and its bifurcation (D), and lack of mucosal abnormalities or luminal defects.



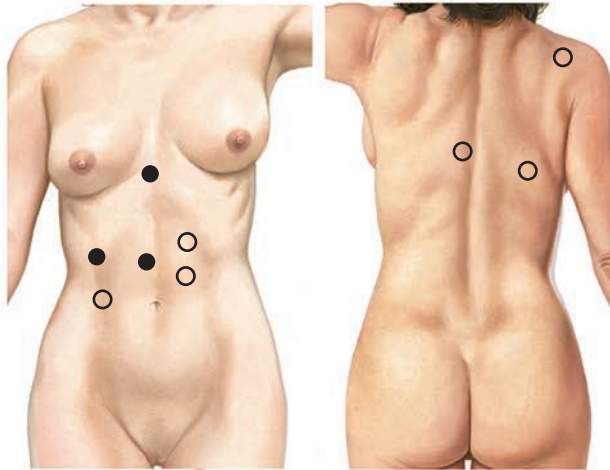
E. CBD stones during ERCP

FIGURE 12-6 Intraoperative imaging in cholecystectomy. *CBD*, Common bile duct; *CHD*, common hepatic duct; *ERCP*, endoscopic retrograde cholangiopancreatography.

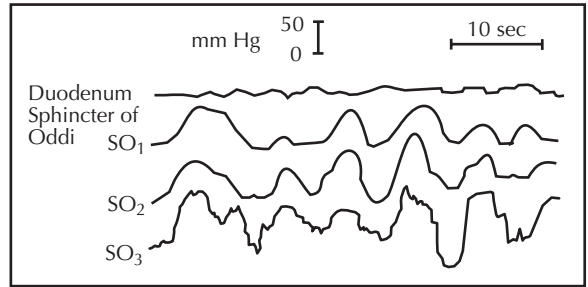
CONVERSION TO OPEN CHOLECYSTECTOMY

Open cholecystectomy is performed most commonly through a right subcostal incision (Kocher incision), but it can also be approached through an upper midline incision. The dissection starts exactly as described for the laparoscopic approach until the critical view is achieved (see [Fig. 12-5](#)). Caution should be exercised if vigorous traction of the cystic duct is performed, because it may result in avulsion of the cystic duct from the CBD or inclusion of the CBD during placement of the cystic duct clamp, as illustrated in [Figure 12-7](#).

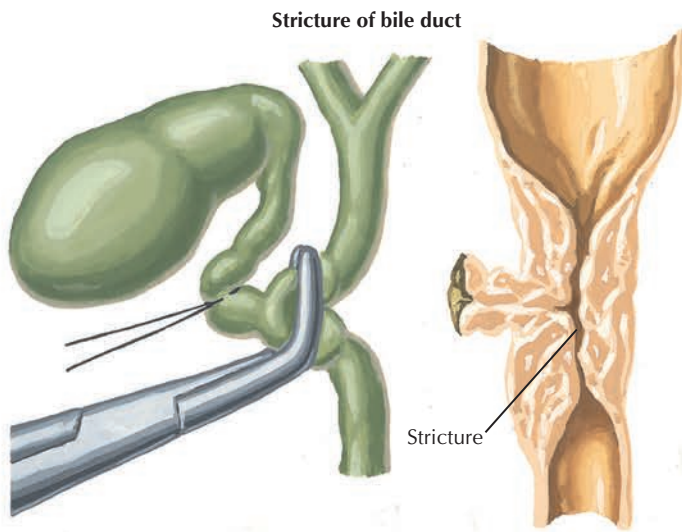
An alternative approach, used when severe inflammation is encountered at Calot's triangle, is to start the dissection at the fundus of the gallbladder and dissect toward the infundibulum, keeping the dissection as close as possible to the gallbladder wall. The fundocystic approach also has been suggested as a safer technique in difficult laparoscopic cholecystectomies. In exceptional cases where anatomic planes of dissection are not found because of severe inflammation or portal hypertension, the gallbladder can be drained of bile and stones, and the dissection could be carried down to the infundibulum following the mucosal lining. Such cases merit IOC to document proper identification of the anatomy.



Biliary colic may continue, resulting from variety of conditions



Manometric tracing shows tachyoddia



Inadvertent trauma to common duct at surgery can result in stricture and symptoms of obstruction

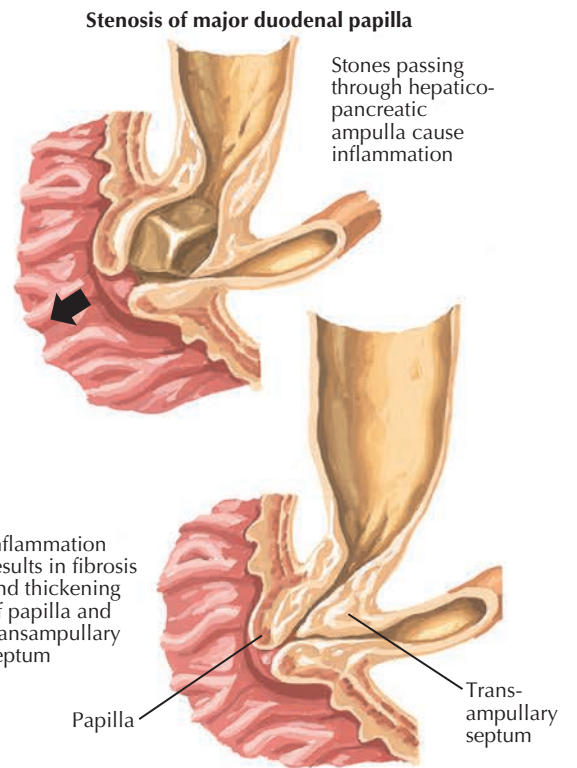


FIGURE 12-7 Postcholecystectomy syndromes.

SPECIAL CIRCUMSTANCES

Acute cholecystitis in the older population and in patients with diabetes can result in necrosis of the gallbladder wall or perforation and bile peritonitis. If the patient is unfit for surgery, resuscitation and percutaneous drainage can arrest the systemic inflammatory response to allow for an elective approach later. In these populations the acute inflammation of the gallbladder could be the result of stone pathology or ischemia (acalculous cholecystitis).

Symptomatic gallstone disease is a common surgical consultation in pregnant women. In general, surgery should be avoided during the first and last trimesters if possible. A laparoscopic approach is not contraindicated.

SUGGESTED READINGS

- Garden OJ. Iatrogenic injury to the bile duct. *Br J Surg* 1991;78(12):1412-3.
- Mercado MA, Domínguez I. Classification and management of bile duct injuries. *World J Gastrointest Surg* 2011;27;3(4):43-8.
- Sicklick JK, Camp MS, Lillemoe KD, et al. Surgical management of bile duct injuries sustained during laparoscopic cholecystectomy: perioperative results in 200 patients. *Ann Surg* 2005; 241(5):786-92; discussion 793-5.
- Strasberg SM, Hertl M, Soper NJ. An analysis of the problem of biliary injury during laparoscopic cholecystectomy. *J Am Coll Surg* 1995;180:101-25.

Common Bile Duct Surgery and Choledochoduodenostomy

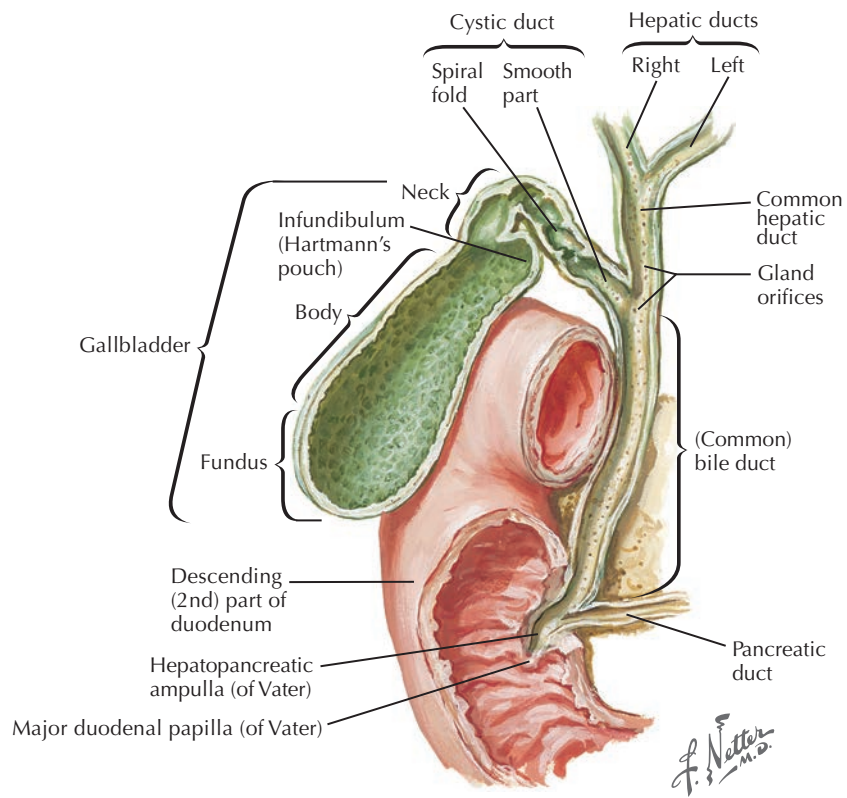
Walter S. Cha

INTRODUCTION

Approximately 15% of patients with gallbladder stones will also have stones within the common bile duct (CBD). Currently, the majority of patients with CBD stones can be managed by using endoscopic techniques. However, endoscopic management of CBD stones may be problematic with multiple large stones or stones above a stricture, in young patients, and in patients with difficult access to the ampulla of Vater (prior gastrectomy or Roux-en-Y gastric bypass). Patients who are not candidates for endoscopic or percutaneous procedures may require surgical intervention. Surgical approaches to the CBD include laparoscopic CBD exploration through a transcystic approach or a choledochotomy, open CBD exploration, and biliary-enteric anastomosis.

CYSTIC DUCT ANATOMY AND VARIANTS

In most individuals (64% to 75%) the cystic duct joins the hepatic duct at approximately a 40-degree angle (Fig. 13-1). Less frequently (17% to 23%) the cystic duct runs parallel to the hepatic duct for a distance and may even enter the duodenum separately. In 8% to 13% of individuals the cystic duct may enter the hepatic duct on the left side after passing in front of or behind the common hepatic duct. Infrequently, the gallbladder may be sessile, with little to no cystic duct.



Variations in cystic duct

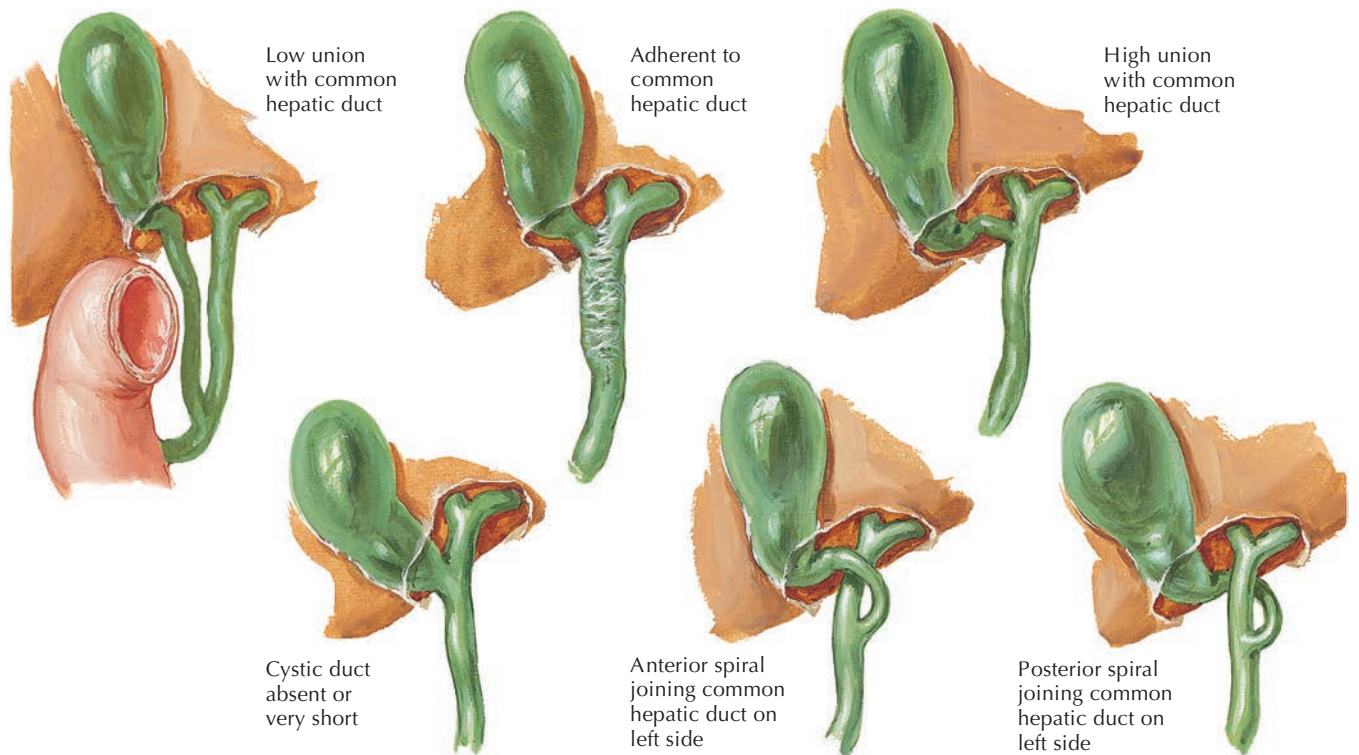


FIGURE 13-1 Cystic duct anatomy and variants.

LAPAROSCOPIC COMMON BILE DUCT EXPLORATION

If CBD stones are identified at laparoscopic cholecystectomy, laparoscopic CBD exploration may be warranted (Fig. 13-2). Successful laparoscopic CBD exploration avoids the risks associated with deferring treatment of a CBD stone or a subsequent endoscopic procedure.

Trocar placement for laparoscopic CBD exploration is similar to the port configuration used during laparoscopic cholecystectomy. An additional port in the right upper abdomen may be used for the choledochoscope or catheters.

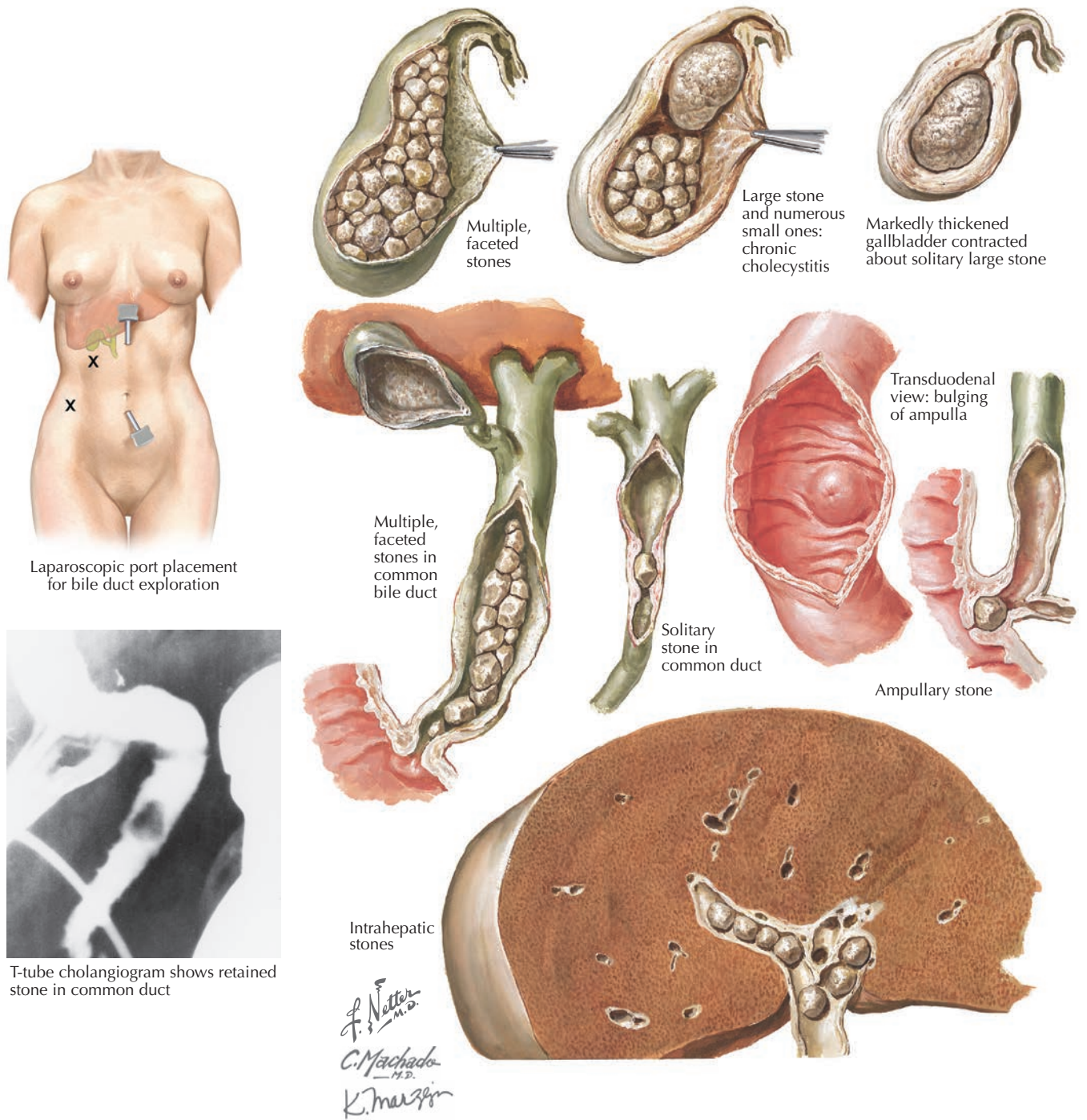


FIGURE 13-2 Choledocholithiasis: pathologic features.

Transcystic Approach

The transcystic approach to CBD exploration avoids a choledochotomy and eliminates the subsequent need for a T tube. After controlling the cystic duct on the gallbladder side, a cystic ductotomy is created and a cholangiocatheter placed. The cystic duct may need to be dilated with a balloon before subsequent interventions to extract calculi (Fig. 13-3, A).

The CBD is irrigated with saline to flush the stone. If unsuccessful, balloon catheters or wire baskets can be passed into the CBD under fluoroscopic guidance to capture and retrieve the stones. An additional option is antegrade balloon dilation of the sphincter under fluoroscopic guidance, followed by flushing to clear the duct of stones (Fig. 13-3, B-D). After clearance of the CBD, the cystic duct is ligated with clips or an endoloop.

Transductal/Choledochotomy Approach

Transcystic extraction may not be feasible with large stones, small cystic ducts, or stone locations in the proximal bile ducts. Laparoscopic choledochotomy may provide access to these stones for subsequent removal.

With the gallbladder retracted cephalad, a longitudinal incision is made on the anterior aspect of the distal CBD because blood supply to the duct is lateral. The length of the incision is typically limited to 1 cm or the size of the largest stone. The stones are cleared by flushing, followed by basket or balloon retrieval.

Choledochoscopy can be performed. The choledochotomy is typically closed over a T tube using laparoscopic suturing techniques and absorbable sutures (Fig. 13-3, E). Alternately, an antegrade stent can be placed through the sphincter, and the choledochotomy can be primarily closed without a T tube.

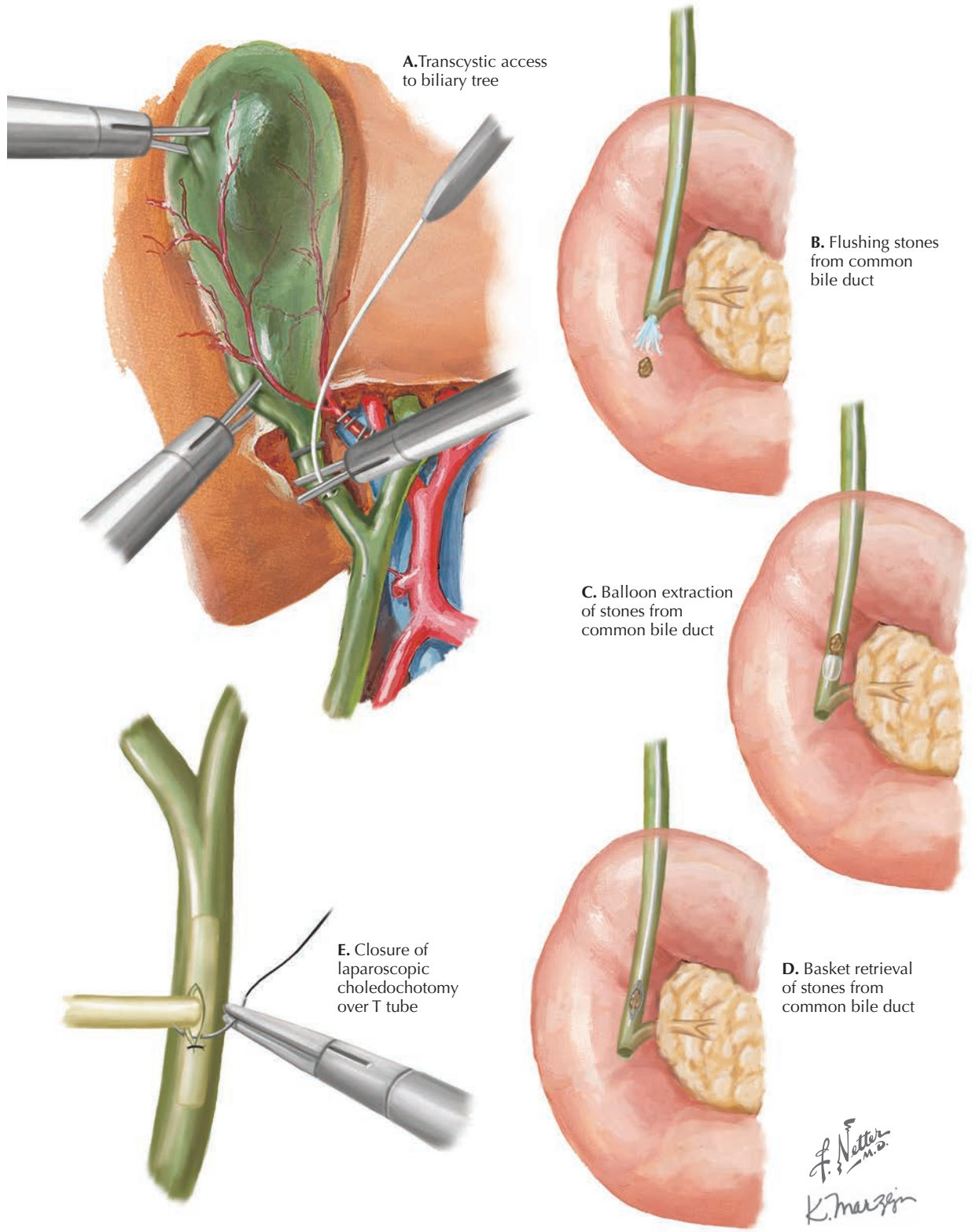
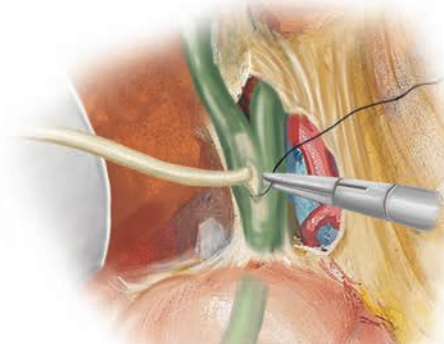
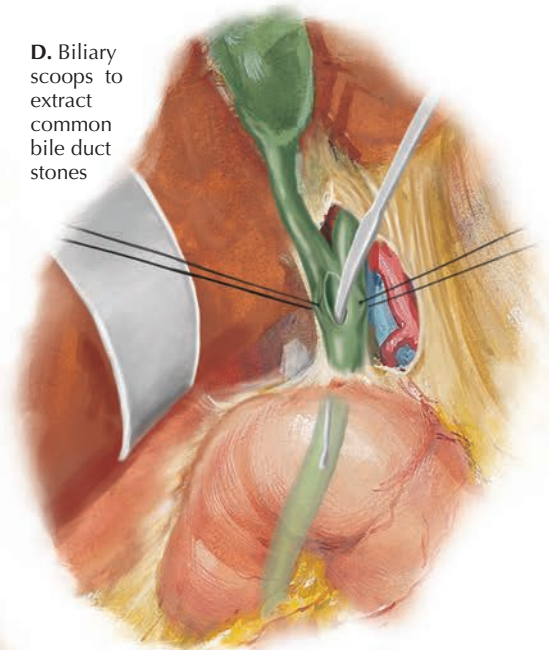
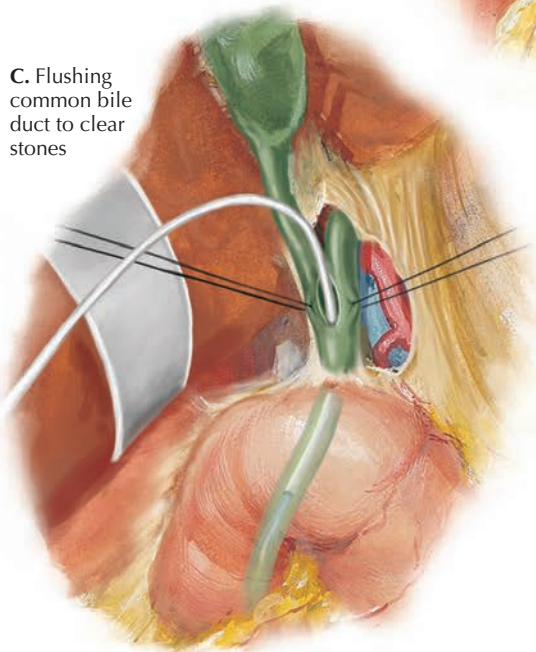
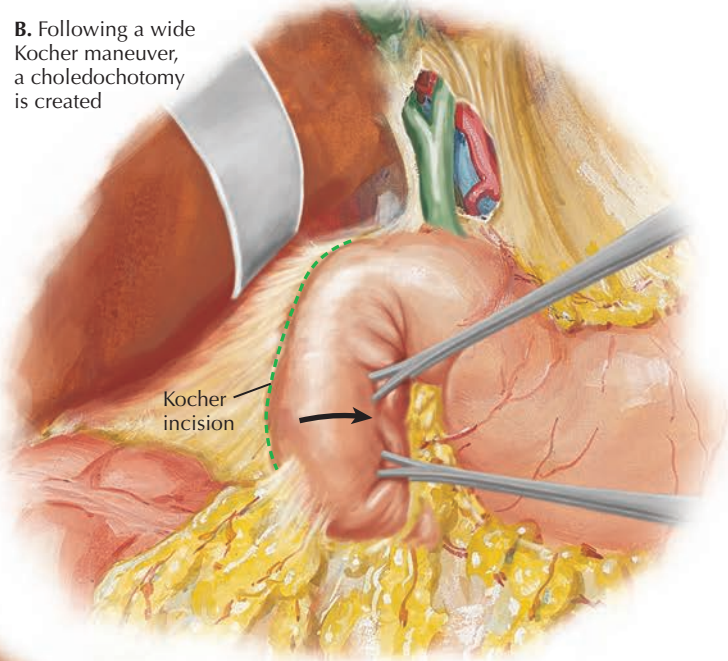
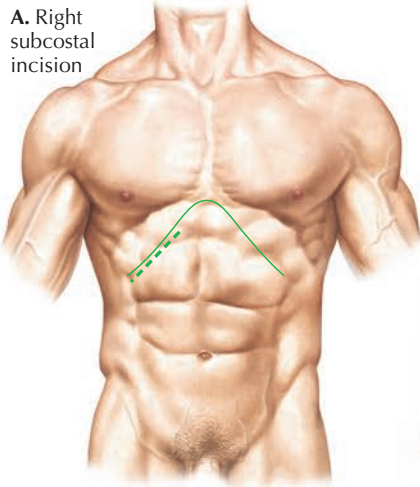


FIGURE 13-3 Transcystic and transductal/choledochotomy approaches.

OPEN COMMON DUCT EXPLORATION

When minimally invasive options are not feasible or fail, open CBD exploration may be warranted. In addition, open exploration may be performed at open cholecystectomy when CBD stones are identified. The procedure is generally performed through a right subcostal incision (Fig. 13-4, *A*). An upper midline incision may be used as an alternative. After a wide Kocher maneuver, a choledochotomy is created (Fig. 13-4, *B*). A variety of instruments can be used to extract the stones: irrigation catheters, balloon catheters, biliary scoops, stone forceps, Bakes dilators, and flexible choledochoscopes. After clearance of the CBD, the choledochotomy is closed over a T tube using absorbable sutures (Fig. 13-4, *C-E*).



F. Netter M.D.
K. Marzfan
C. Machado M.D.

FIGURE 13-4 Open common bile duct exploration.

CHOLEDOCHODUODENOSTOMY

Choledochoduodenostomy may be useful after common duct exploration if there is concern about retained stones, as well in patients with recurrent biliary stones or a distal biliary stricture.

A wide Kocher maneuver is performed and the CBD exposed. A choledochotomy of 2-cm length is made as close to the duodenum as possible. The biliary tree is cleared of calculi. A longitudinal duodenotomy is created, also 2 cm in length and adjacent to the choledochotomy (Fig. 13-5). An anastomosis is created between the CBD and the duodenum using synthetic absorbable sutures.

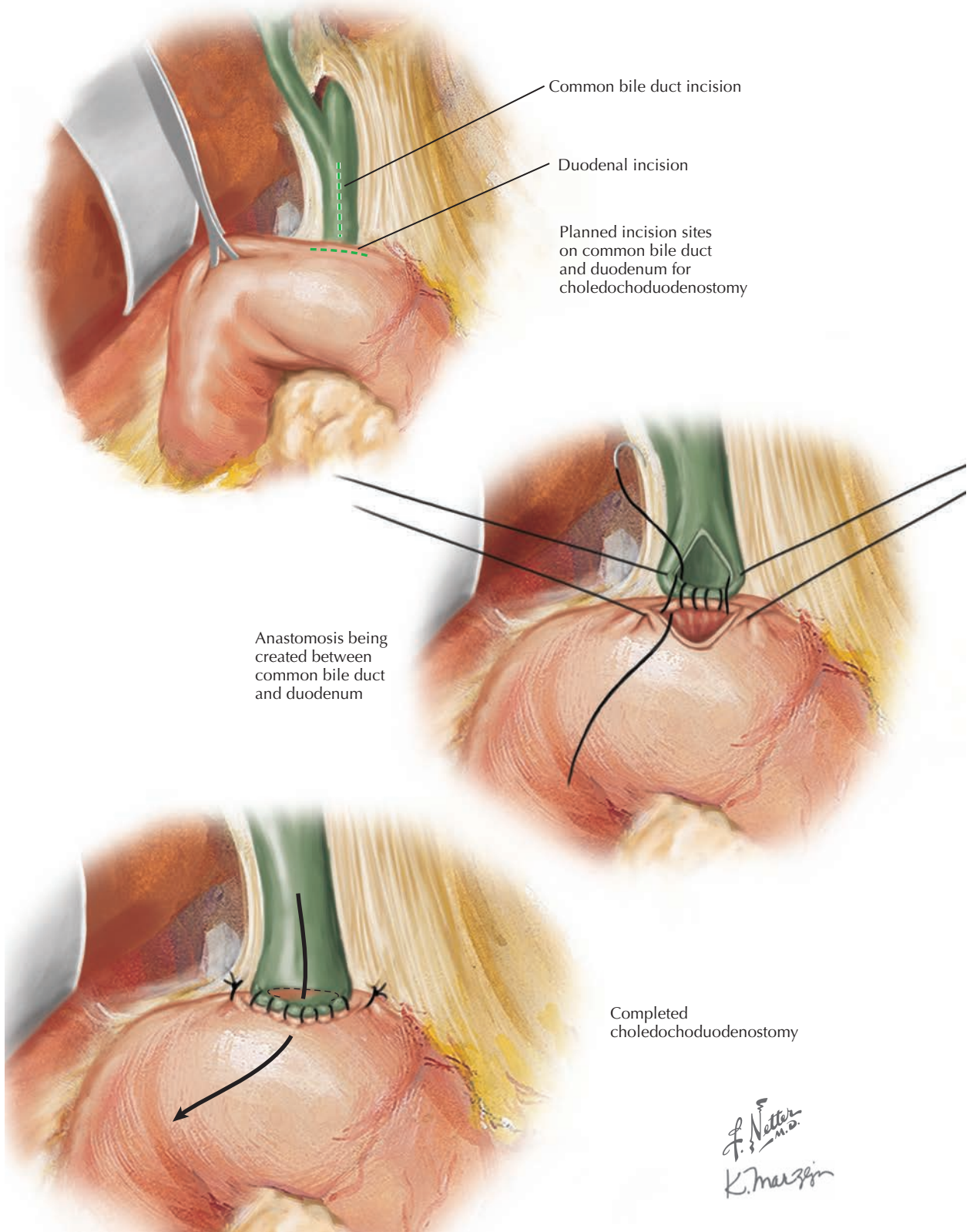


FIGURE 13-5 Choledochoduodenostomy.

SUGGESTED READINGS

Cameron J, Sandone C, editors. Atlas of gastrointestinal surgery, 2nd ed. Hamilton: BC Decker; 2007.

DeAretxabala X, Bahamondes J. Choledochoduodenostomy for common bile duct stones. *World J Surg* 1998;22:1171-4.

Extrahepatic biliary tract and gallbladder. In Skandalakis J, Colborn G, Weidman T, et al. *Skandalakis' surgical anatomy*. Athens: BMP; 2004.

Petelin JB. Laparoscopic common bile duct exploration. *Surg Endosc* 2003;17(11):1705-14.

Hepatectomy

Christopher T. Siegel

INTRODUCTION

Multiple factors have contributed to a significant increase in the current number of liver surgeries performed annually. Improvements in surgical and anesthetic techniques as well as in patient selection have reduced the mortality associated with liver resection to between 1% and 5% at experienced centers, with acceptable associated morbidity. The improved surgical outcomes associated with the increased incidence of newly diagnosed cancers of the liver and biliary tree, along with substantial improvement in the adjuvant treatment of metastatic colon cancer to the liver, has helped to establish liver resection as the primary treatment modality for many patients with hepatocellular carcinoma, cholangiocarcinoma, and metastatic colon cancer to the liver. Every resident and general surgeon should at least be familiar with the principles involved in liver resection, or hepatectomy.

SURGICAL PRINCIPLES

A major advance in the ability to perform liver resections is the understanding of the segmental anatomy of the liver, as described by Couinaud in 1957. In addition to the portal vein, the arterial supply, biliary drainage, and hepatic outflow must also be considered in planning the resection. Because of the significant variations in liver mass, vascular and biliary anatomy, tumor location, and extent of resection margin, adequate preoperative imaging is critical.

For primary liver tumors, a margin of 1 to 2 cm is preferred. The resection margin for metastatic lesions is somewhat more controversial, but recent studies on resection of colorectal liver metastasis demonstrated a survival advantage with a resection margin of at least 1 cm. When a liver resection is planned, the remnant liver needs to have adequate mass for the patient as well as adequate arterial, portal, and hepatic vein flow. The remnant must also have adequate biliary drainage.

The liver is composed of eight segments based on the portal inflow into the organ (Fig. 14-1). Segments I to IV constitute the left lobe (colored purple, blue, and green on illustration) and segments V to VIII, the right lobe. Preoperative understanding of the patient's underlying liver anatomy is critical when planning a liver resection. Because of the wide variability in all the hepatic vascular and biliary structures, as well as a considerable amount of variability in the relative sizes of the right and left lobes, imaging is performed to delineate the key structures that may be encountered during the resection (Fig. 14-2). The most useful studies are triple-phase computed tomography or a high-resolution magnetic resonance imaging with contrast (Fig. 14-3).

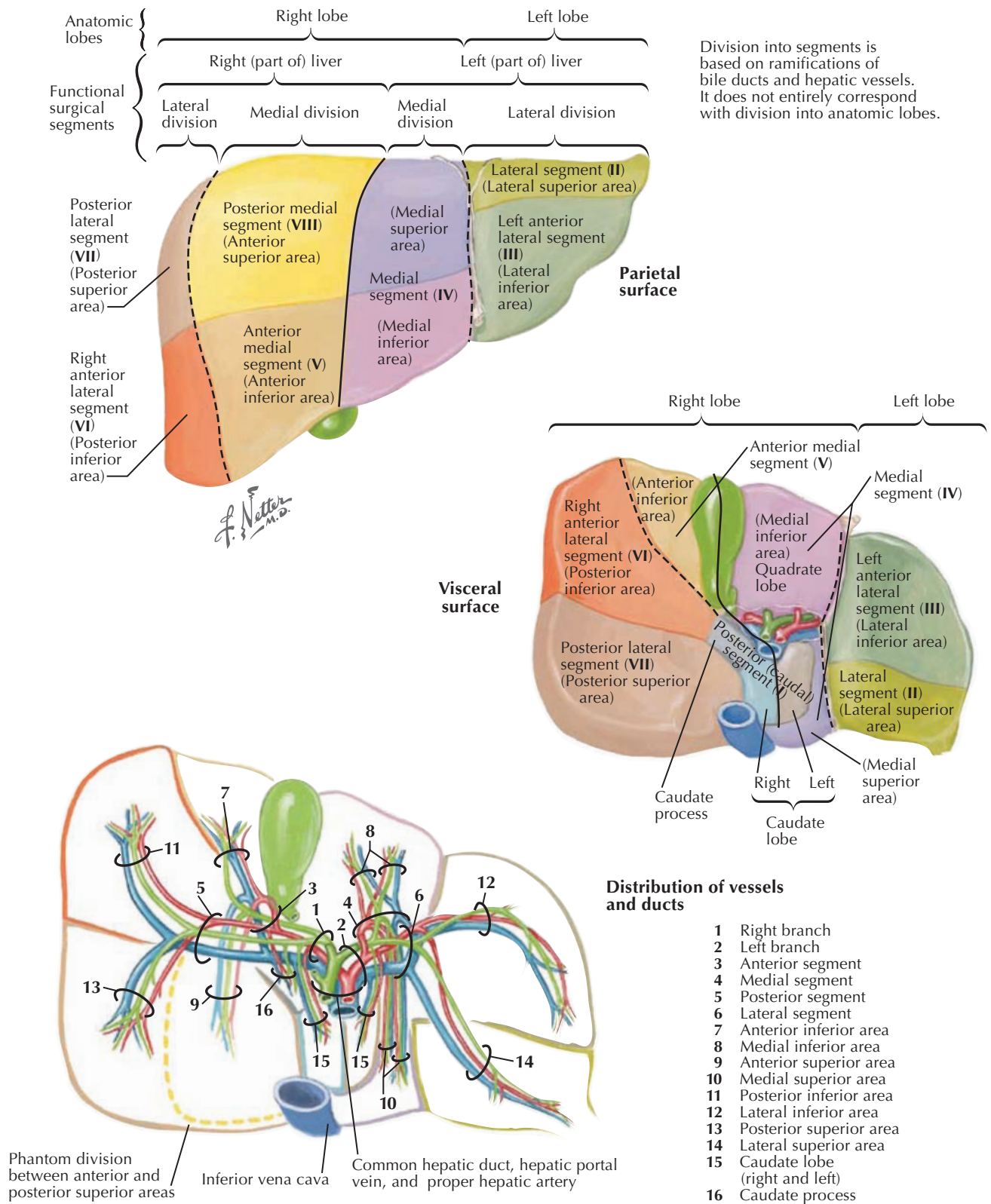


FIGURE 14-1 Liver segments and lobes: vessel and duct distribution.

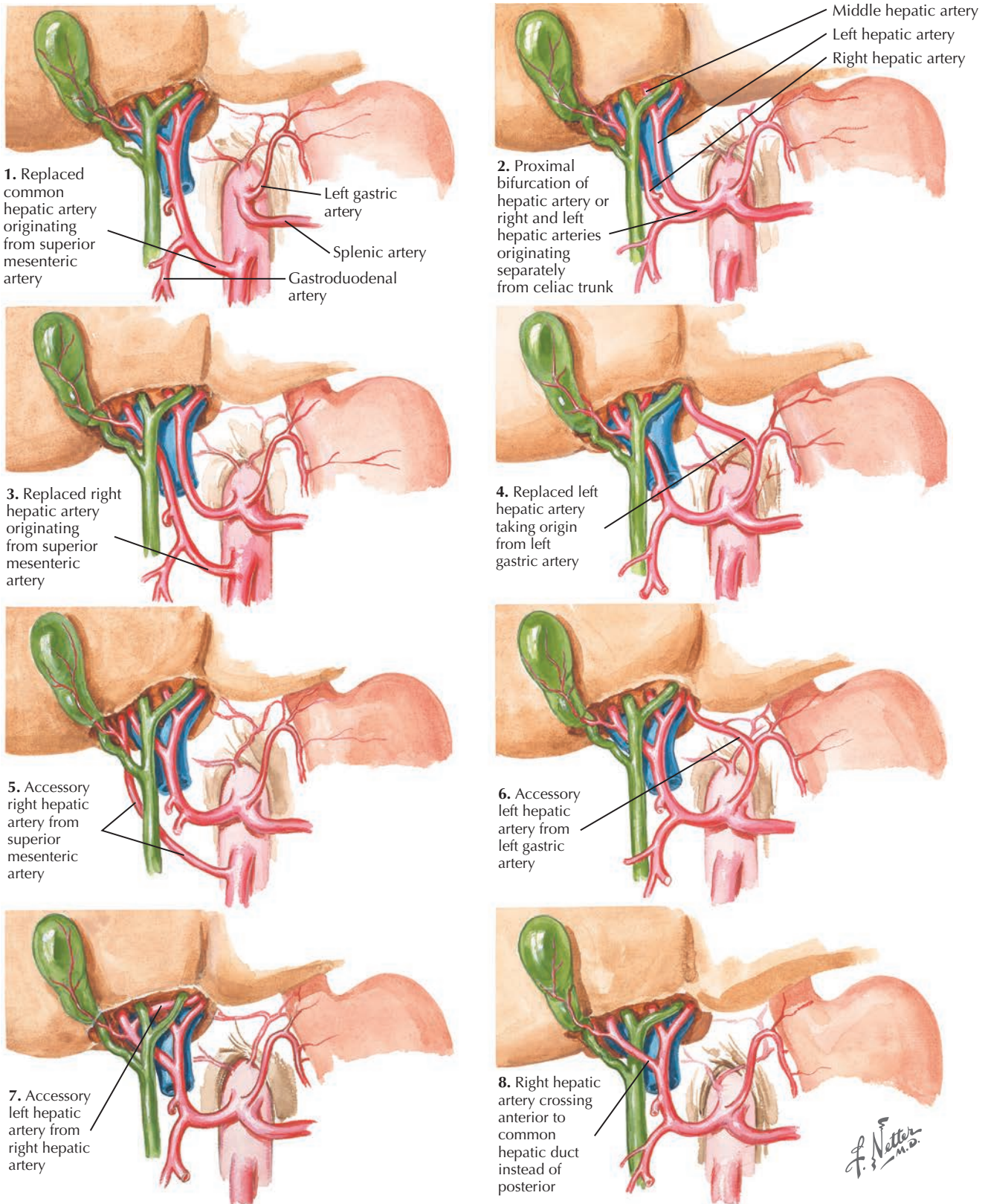


FIGURE 14-2 Variations in origin and course of hepatic artery and branches.

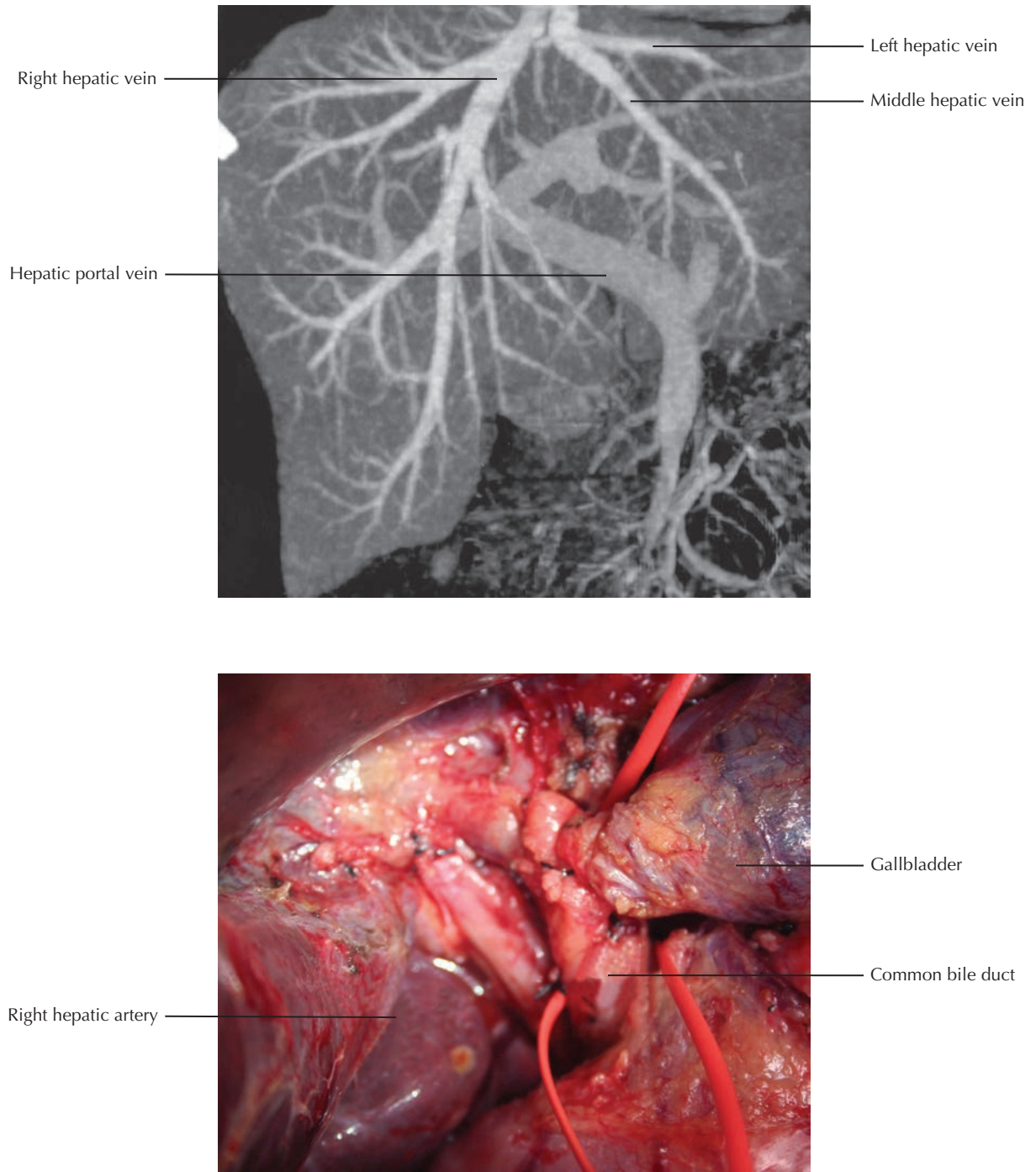


FIGURE 14-3 Hepatic artery: magnetic resonance image and surgical view. (CT image from Kamel IR, Liapi E, Fishman E. Liver and biliary system: evaluation by multidetector CT. *Radiol Clin North Am* 2005;43(6):977-97.)

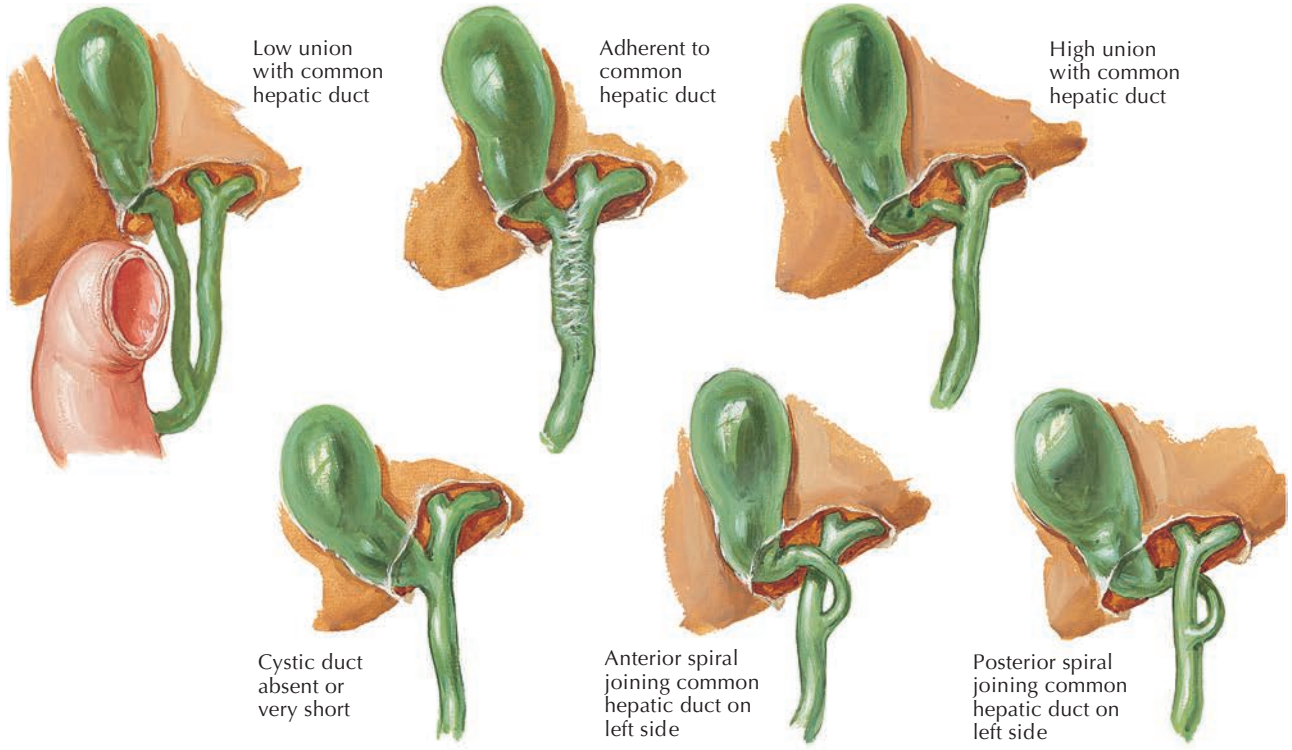
SURGICAL PRINCIPLES—Cont'd

Arterial supply to the liver is through the hepatic artery, which supplies branches to the right and left lobes. Variations in the arterial supply to the liver include an additional, accessory, or replaced right or left hepatic artery and an aberrant origin of the common hepatic artery (Fig. 14-4). The most common variants of the arterial blood supply to the liver include an additional or replaced right hepatic artery from the superior mesenteric artery. This vessel is usually one of the first branches off the superior mesenteric and courses behind the head of the pancreas, posterior to the portal vein and common bile duct, traveling directly into the right lobe of the liver.

The biliary tree also has significant variations, which can add to the risk of biliary leaks from the cut edge of the liver. *Bile leaks* are one of the more common and problematic complications of liver resection. Maintaining continent drainage of the remaining segments is critical in preventing biliary complications. Comparison of preoperative imaging with intraoperative cholangiogram can often help clarify areas of confusion.

Considerable variations exist in the relative size of the right and left lobes of the liver (Fig. 14-5). In addition to the size of each lobe, the underlying health of the liver parenchyma must also be factored into the decision regarding the minimum amount of liver that must remain for the patient to avoid liver insufficiency. Patients with cirrhosis or hepatic steatosis may need larger residual volumes after resection to maintain adequate function (Fig. 14-6).

Variations in cystic ducts



Accessory (aberrant) hepatic ducts

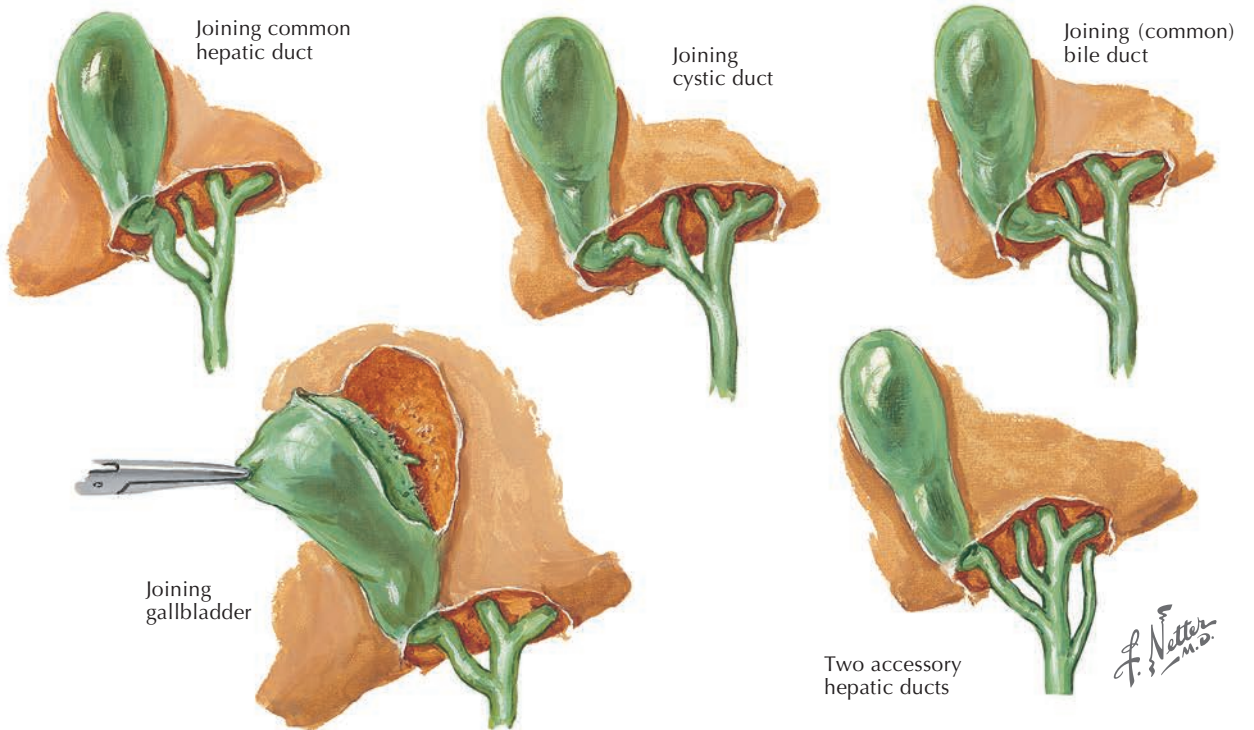
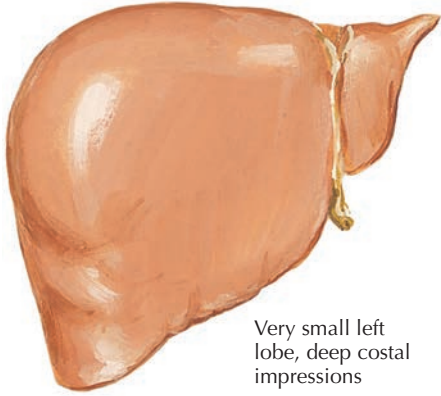
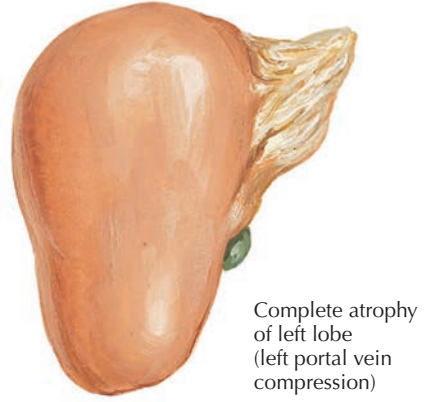


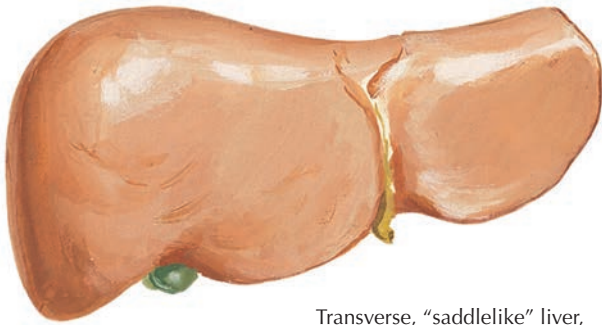FIGURE 14-4 Variations in cystic and hepatic ducts.



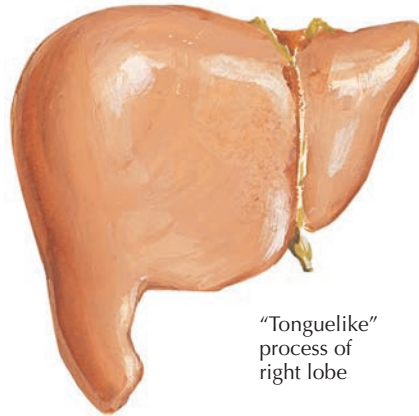
Very small left lobe, deep costal impressions



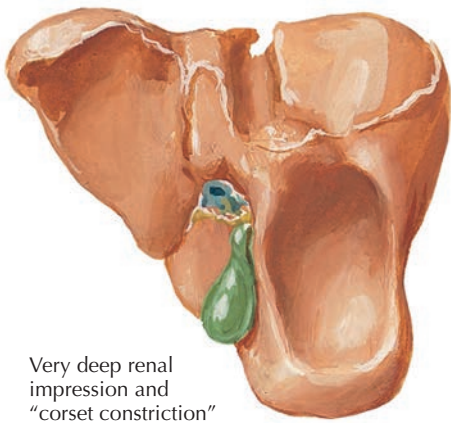
Complete atrophy of left lobe (left portal vein compression)



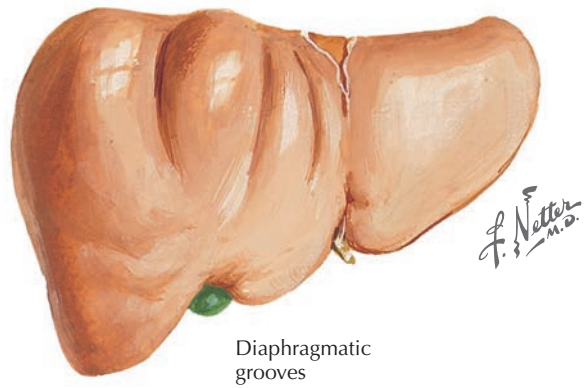
Transverse, "saddlelike" liver, relatively large left lobe



"Tonguelike" process of right lobe



Very deep renal impression and "corset constriction"



Diaphragmatic grooves

F. Netter M.D.

FIGURE 14-5 Variations in form of liver.

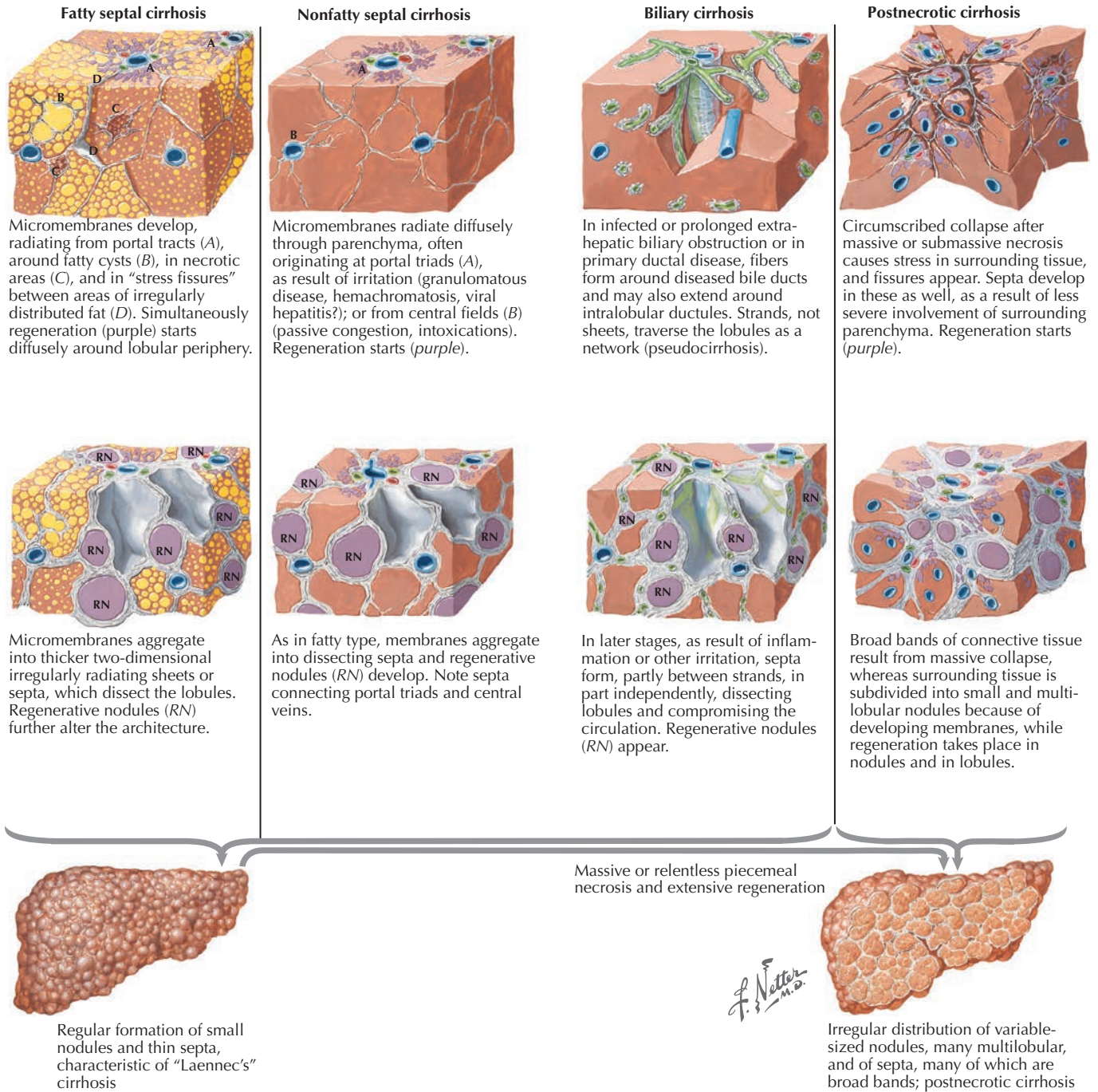


FIGURE 14-6 Cirrhosis I: pathways of formation.

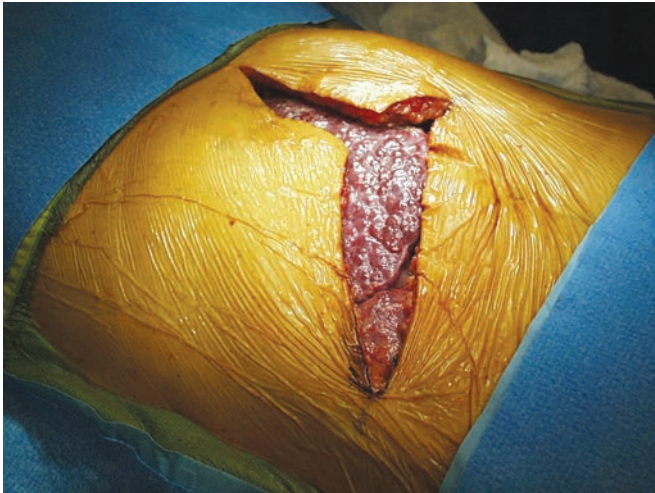F. Netter M.D.

RIGHT HEPATIC LOBECTOMY

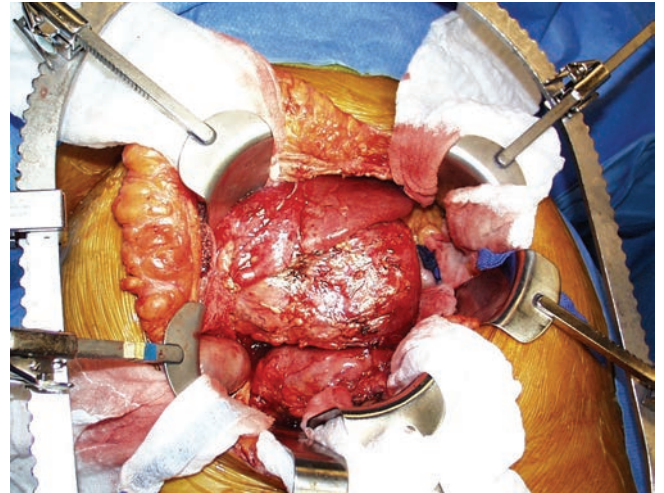
Various types of incisions can provide adequate exposure for a right lobe liver resection. One of the most common is the upper abdominal Mercedes incision, a bilateral subcostal incision with midline extension (Fig. 14-7, *A*). Other variations include midline, bilateral subcostal, or a right subcostal incision with upper midline extension. Adequate exposure with a self-retaining retractor is essential. To assist with fixation, Bookwalter upright posts can be placed in the right upper quadrant (RUQ) and in the left lower quadrant. This allows two-point fixation to the large ring and assists in optimization of surgical exposure (Fig. 14-7, *B*).

The liver dissection is begun in the hilum by mobilizing the gallbladder off the liver bed. The lateral border between segments IV and V approximates the dissection plane between the right and left lobes of the liver. The retroperitoneum and Gerota's fascia, attached to the posterior right lobe of the liver, are incised to prevent liver lacerations of segments VI and VII, as the mobilization of the right lobe is begun (Fig. 14-7, *C and D*).

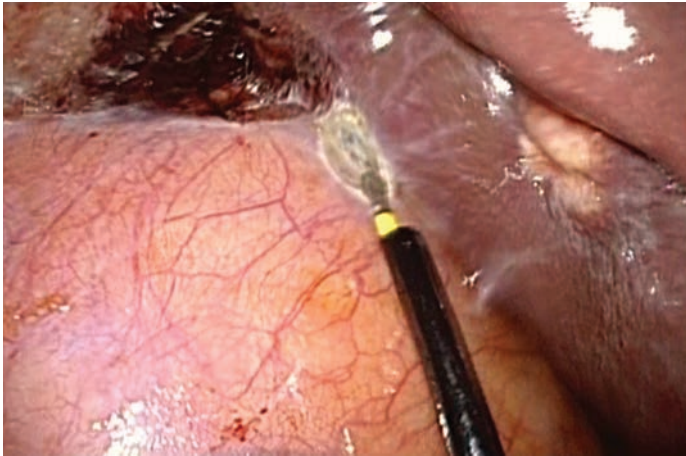Once the inferior right lobe is free, the triangular ligament is divided along the liver to mobilize the right lobe out of the retroperitoneum. This dissection is continued superiorly to the entrance of the right hepatic vein into the vena cava. This maneuver separates the right lobe from the diaphragm. The dissection is continued posteriorly until the vena cava and short hepatic veins are fully exposed. Small short hepatic veins can be ligated and divided; larger ones can be closed with a 2.5-mm vascular stapler or suture-ligated (Fig. 14-7, *E and F*).



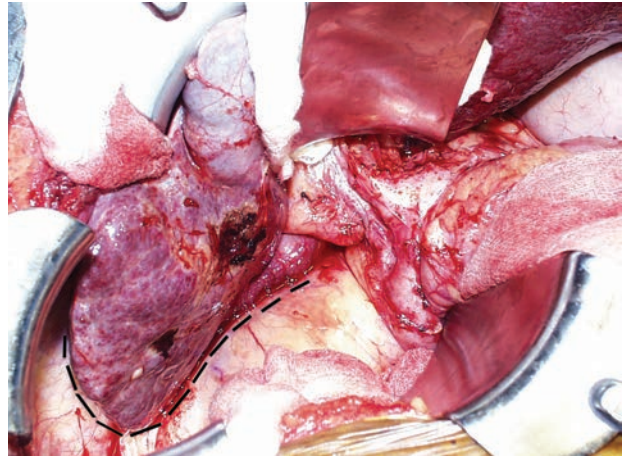
A. Mercedes incision



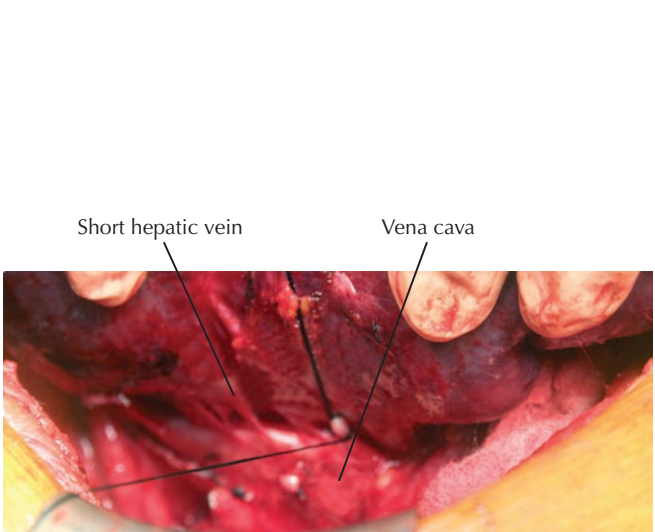
B. Exposure for surgery



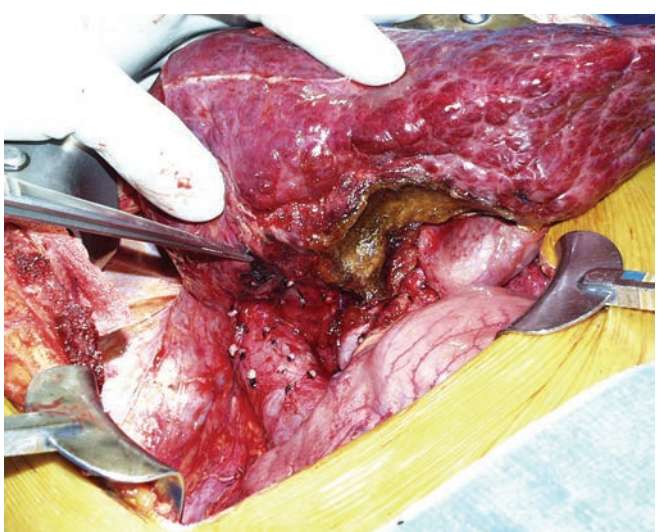
C. Open retroperitoneum with cautery



D. Retroperitoneal plane of dissection



E. Dissection of short hepatic veins



F. Right lobe dissected off vena cava

FIGURE 14-7 Right hepatic lobectomy.

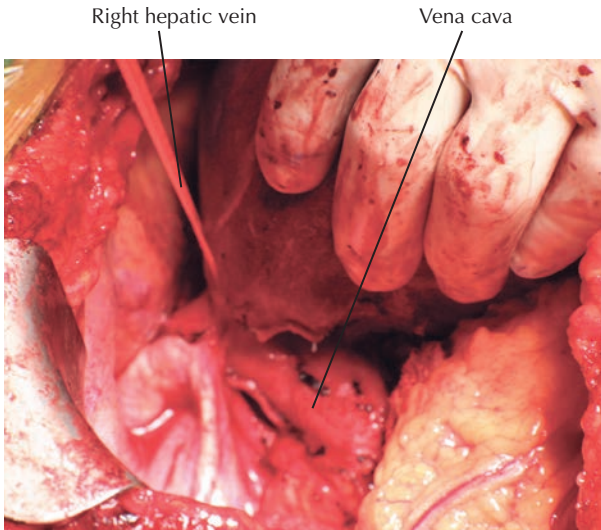
RIGHT HEPATIC LOBECTOMY—Cont'd

Once all the short hepatic veins are divided, the right hepatic vein can be encircled and controlled with a vessel loop (Fig. 14-8, *G*). At this time, attention returns to the hilum. The common bile duct can be followed to the bifurcation, and the right hepatic duct can be encircled with a vessel loop. Arterial branches lateral to the bile duct can be identified, ligated proximally and distally, and then divided. The bifurcation of the right and left portal vein branches can now be identified, and the right portal vein can be controlled proximally and distally, divided, and then oversewn, or it can be stapled with a vascular stapler (Fig. 14-8, *H and I*).

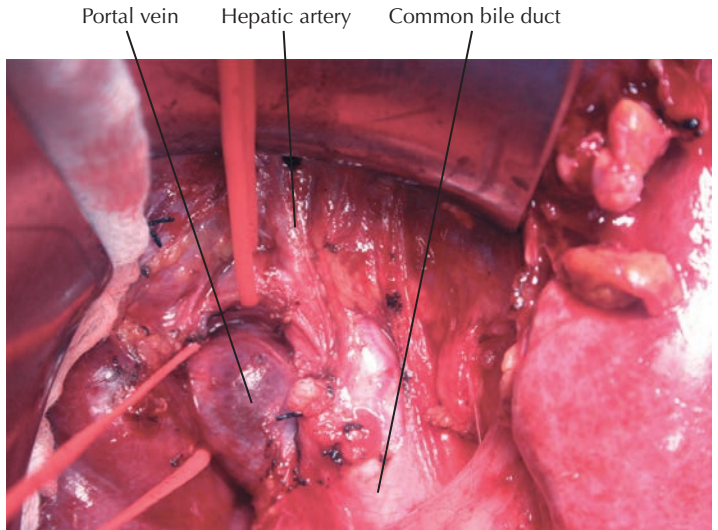
At this time, a demarcation plane should be evident on the surface of the liver. Although inflow vessels have been taken, better homeostasis can be obtained if inflow occlusion (i.e., Pringle maneuver) is performed.

After a 10-minute course of preischemic conditioning with an adequate recovery, the porta hepatis is clamped, the right hepatic vein is taken, and the liver parenchyma is divided (Fig. 14-8, *J*). Intraoperative ultrasound is useful at this point to mark a plane of dissection lateral to the middle hepatic vein and to mark branches from the right lobe that drain through the middle vein, if present. Liver parenchymal dissection can be done with a crush technique, an ultrasonic device, or high pressure water dissection (ERBE). Other techniques include using a stapler to divide the tissue or a bipolar cautery device.

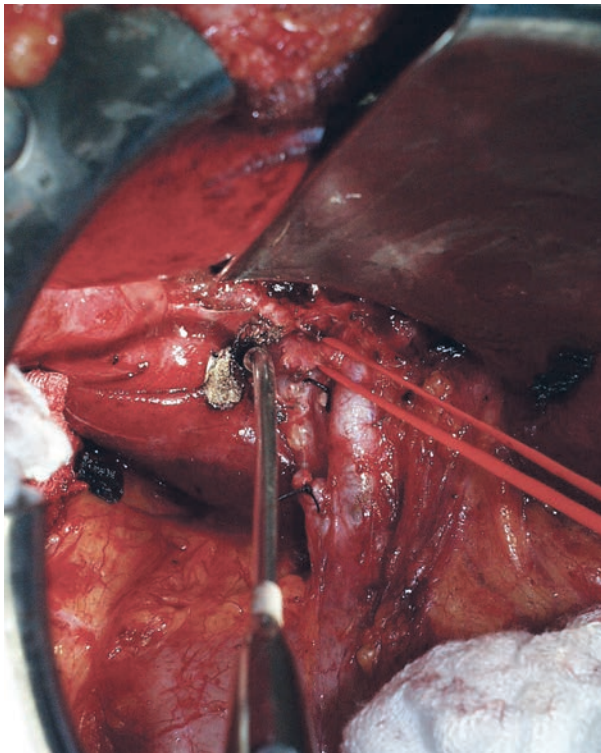
After the parenchymal dissection is complete, the liver edge is cauterized with argon beam coagulation and then coated with an absorbable layer of fibrin glue. The surgeon then removes the portal clamp in a graded manner while watching for bleeding sites. A drain is left along the cut edge of the liver in case of biliary leak.



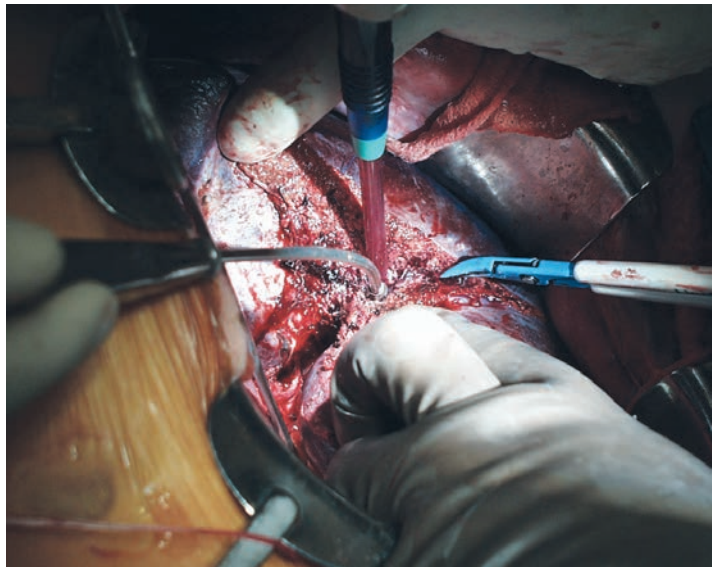
G. Control of right hepatic vein



H. Isolation and control of right portal structures



I. Isolation of right hepatic duct



J. Division of liver parenchyma

FIGURE 14-8 Right hepatic lobectomy—cont'd.

LEFT HEPATIC LOBECTOMY

The left lobe of the liver comprises segments I to IV. The segments are defined by the portal branches. The left lobe lends itself better to segmental resection than the right lobe because of the easy access to the segmental branches of the left portal system. Segmental resection of the left lateral segment (segment II-III) or segment II-III-IV requires dissection further out into the porta hepatis to preserve the branches to the remaining segments. The hilar structures enter the lobe between segments III and IVb. Often, a bridge of liver tissue overlying the structures will need to be divided if segmental resections are planned. This allows access to the segmental portal and bile duct branches. Anomalous arterial and biliary anatomy is common for the left lobe.

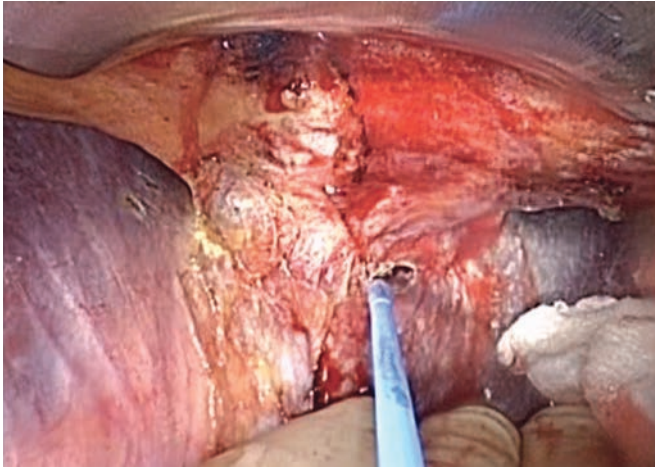
Accessory or replaced left hepatic arteries will arise from the left gastric artery and travel in the gastrohepatic ligament to the liver. If planning a segmental resection of the left lateral segment, knowledge of the anatomy of the bile duct to segment IV is important to avoid inadvertent ligation or injury to the draining duct.

Exposure for surgery can be performed with a bilateral subcostal incision, a bilateral subcostal with a midline extension, or a midline incision.

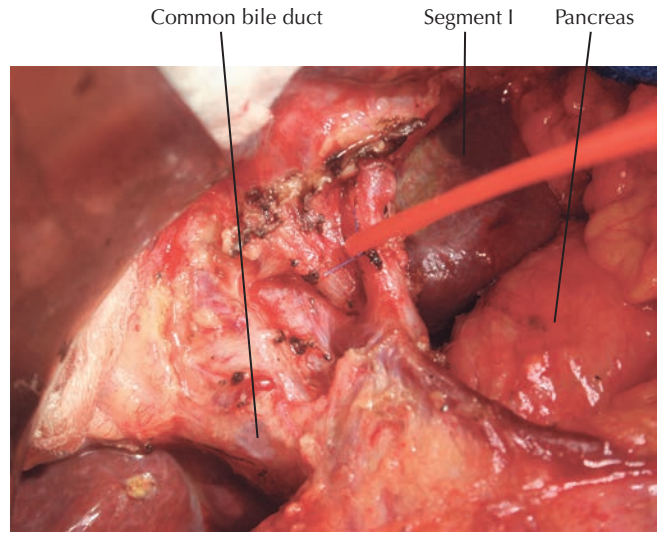
The left lateral segment of the liver is mobilized by dividing the left triangular ligament (Fig. 14-9, A). The left segment is then retracted laterally and the gastrohepatic ligament opened. If present, an accessory or replaced left hepatic artery will travel in the gastrohepatic ligament to the liver. It can be ligated at this point in the dissection; otherwise, the peritoneum over the proximal hepatic artery lymph node is incised and the hepatic artery exposed. The hepatic artery is dissected proximally into the hilum to expose the left hepatic artery (Fig. 14-9, B).

If a formal left hepatectomy is being performed, the left hepatic artery can be ligated after it leaves the main hepatic artery. If segment I is to be left, the artery should be taken after it gives off the branch to segment I. Often, segment IV will have a separate branch off the main hepatic artery. If a formal left hepatic lobectomy is to be performed, the main hepatic artery can be followed to the common bile duct to see if segmental arteries to segment IV are present (Fig. 14-9, C).

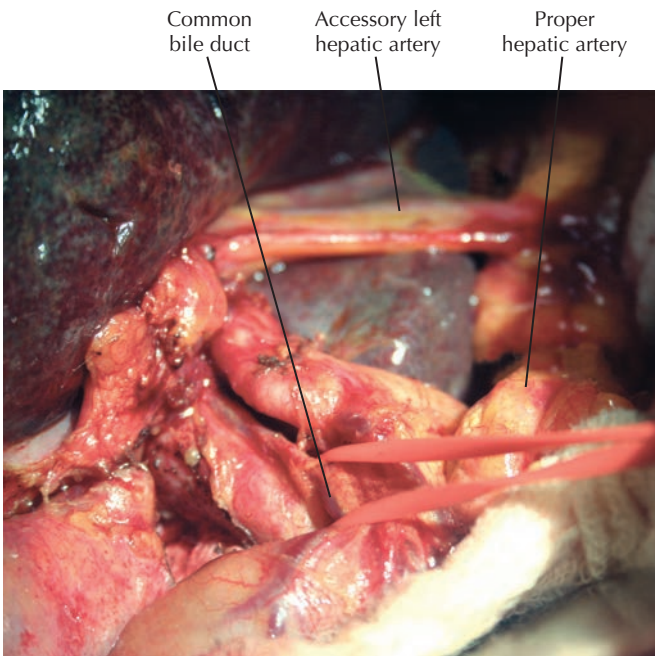
Once the left hepatic artery is taken, the gallbladder can be dissected off the liver bed and the cystic artery and duct ligated and divided. The common bile duct is then followed to the bifurcation, and the main left duct is encircled with a vessel loop (Fig. 14-9, D). If segment I is to be left, the duct must be taken distal to the segment I bile duct takeoff. The duct can be taken early if performing a formal left lobectomy. If segmental resections are planned, it is often better to leave the duct until the parenchymal dissection, to facilitate identification of small ducts that travel into segments to be left.



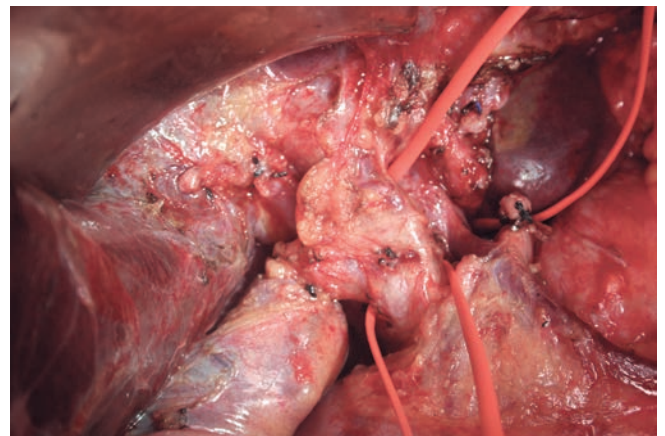
A. Mobilization of left triangular ligament



B. Isolation of left hepatic artery



C. Accessory left hepatic artery



D. Common bile duct

FIGURE 14-9 Left hepatic lobectomy.

LEFT HEPATIC LOBECTOMY—Cont'd

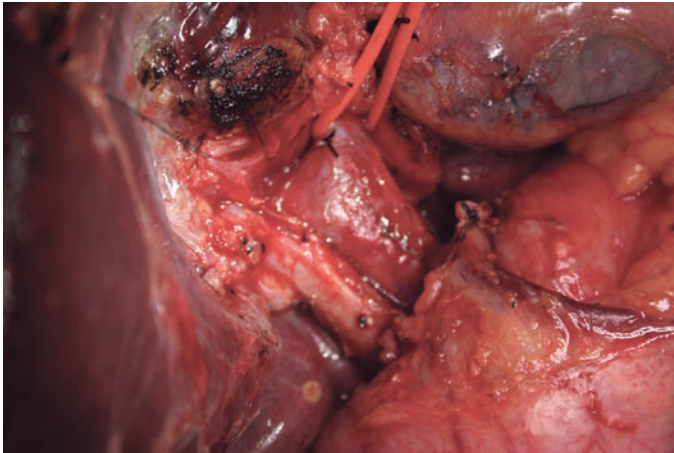
At this time, the main left portal vein can be identified and encircled with a vessel loop (Fig. 14-10, *E*). The portal vein can be taken with a stapler or can be controlled with clamps, divided, and then oversewn. If the caudate lobe is to be left, the portal branch to the caudate must be saved.

The caudate lobe is mobilized off the vena cava. Short hepatic vein branches are ligated and divided to mobilize the left lobe off the vena cava. Large short hepatic veins can be easily taken with an endovascular GIA stapler. Once the mobilization is complete, the caudate lobe and left segment can be retracted lateral to help expose the left and middle hepatic veins (Fig. 14-10, *F*). These can be dissected off the vena cava and marked with a vessel loop.

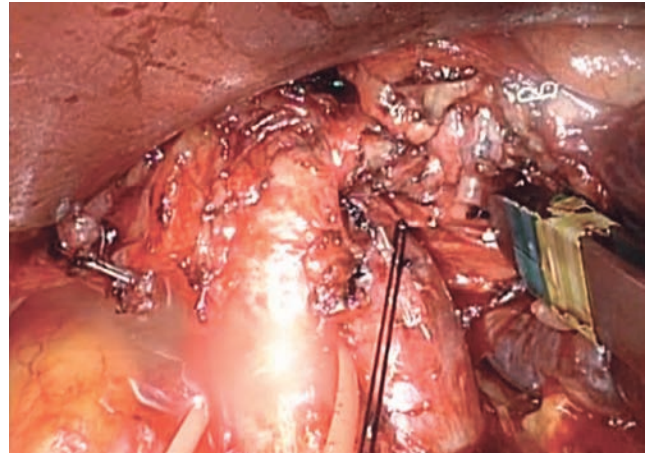
The veins can be controlled and divided either with a vascular GIA stapler or between vascular clamps.

The demarcation plane of the right and left lobes should be evident. Using intraoperative ultrasound, the resection plane lateral to the middle hepatic vein can be marked on the surface of the liver. Using a parenchymal transection technique, the liver parenchyma is divided (Fig. 14-10, *G*). Larger vessels encountered in the parenchymal dissection can be taken with a stapler or suture-ligated (14-10, *I*). Once the parenchymal dissection is complete, the cut surface is cauterized with argon beam coagulation and covered with absorbable fibrin glue (14-10, *J*). A Pringle maneuver or portal inflow occlusion can be performed during the parenchymal dissection if significant bleeding is encountered during the separation of the liver.

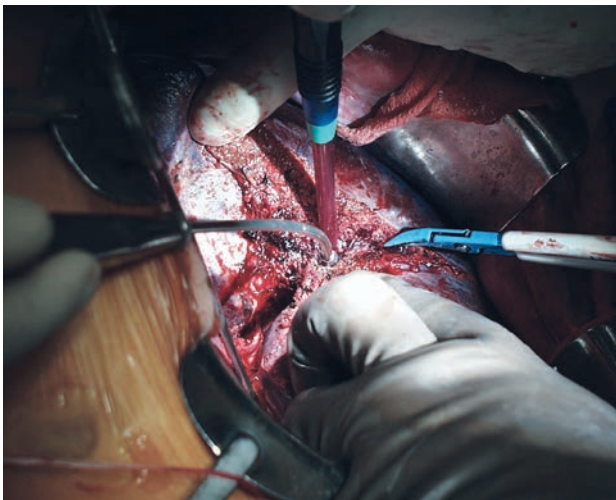
A drain is left along the cut surface of the liver at the conclusion of the procedure to monitor for bile duct leak.



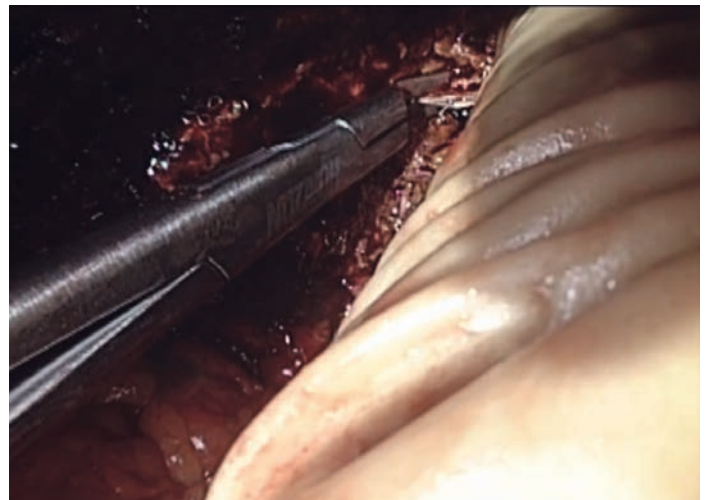
E. Left portal vein marked with vessel loop



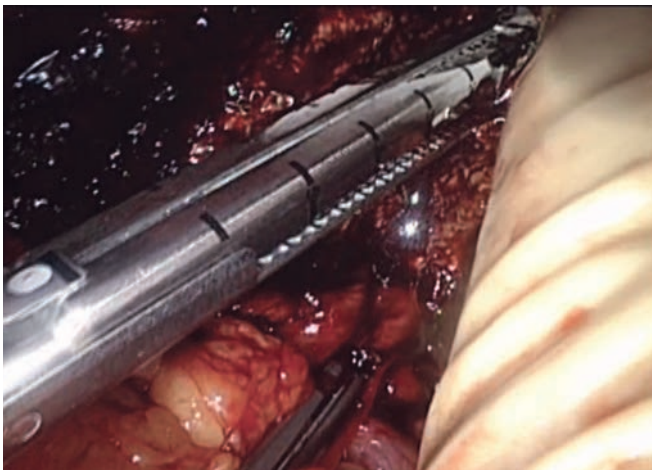
F. Mobilization of segment I



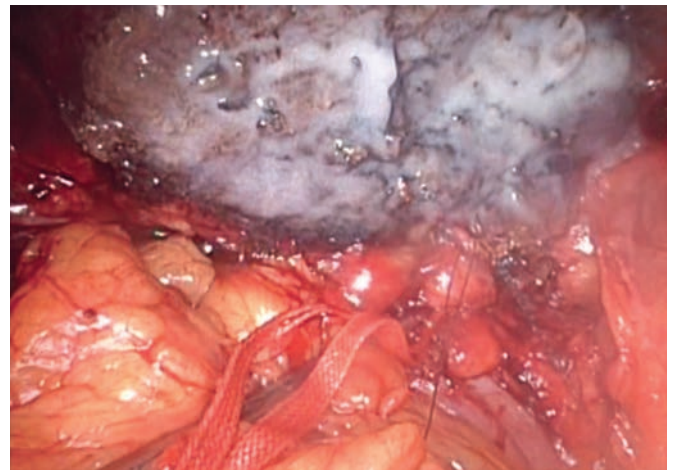
G. Parenchymal dissection



H. Hepatic vein branches crossing dissection plane



I. Stapling large venous structures



J. Fibrin glue on cut edge of liver

FIGURE 14-10 Left hepatic lobectomy—cont'd.

SUGGESTED READINGS

- Aragon RJ, Solomon NL. Techniques of hepatic resection. *J Gastrointest Oncol* 2012;3(1):28-40.
- Blumgart LH, Belghiti J. *Surgery of the liver, biliary tract, and pancreas*. 4th ed. Philadelphia: Saunders-Elsevier; 2007.
- Celinski SA, Gamblin TC. Hepatic resection nomenclature and techniques. *Surg Clin North Am* 2010;90(4):737-48.

Distal Pancreatectomy

Natalie E. Joseph

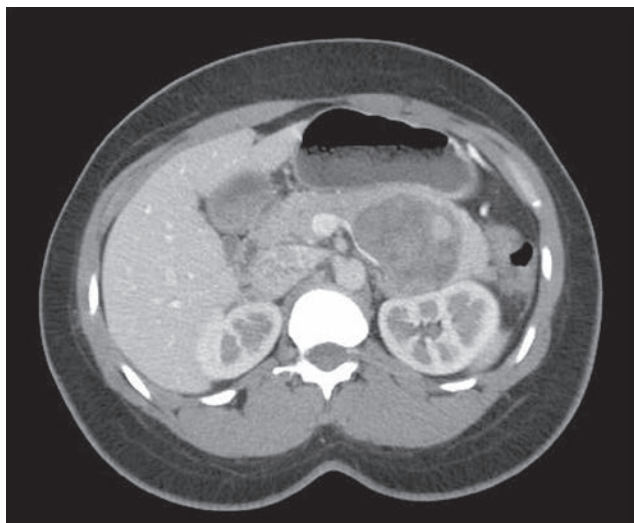
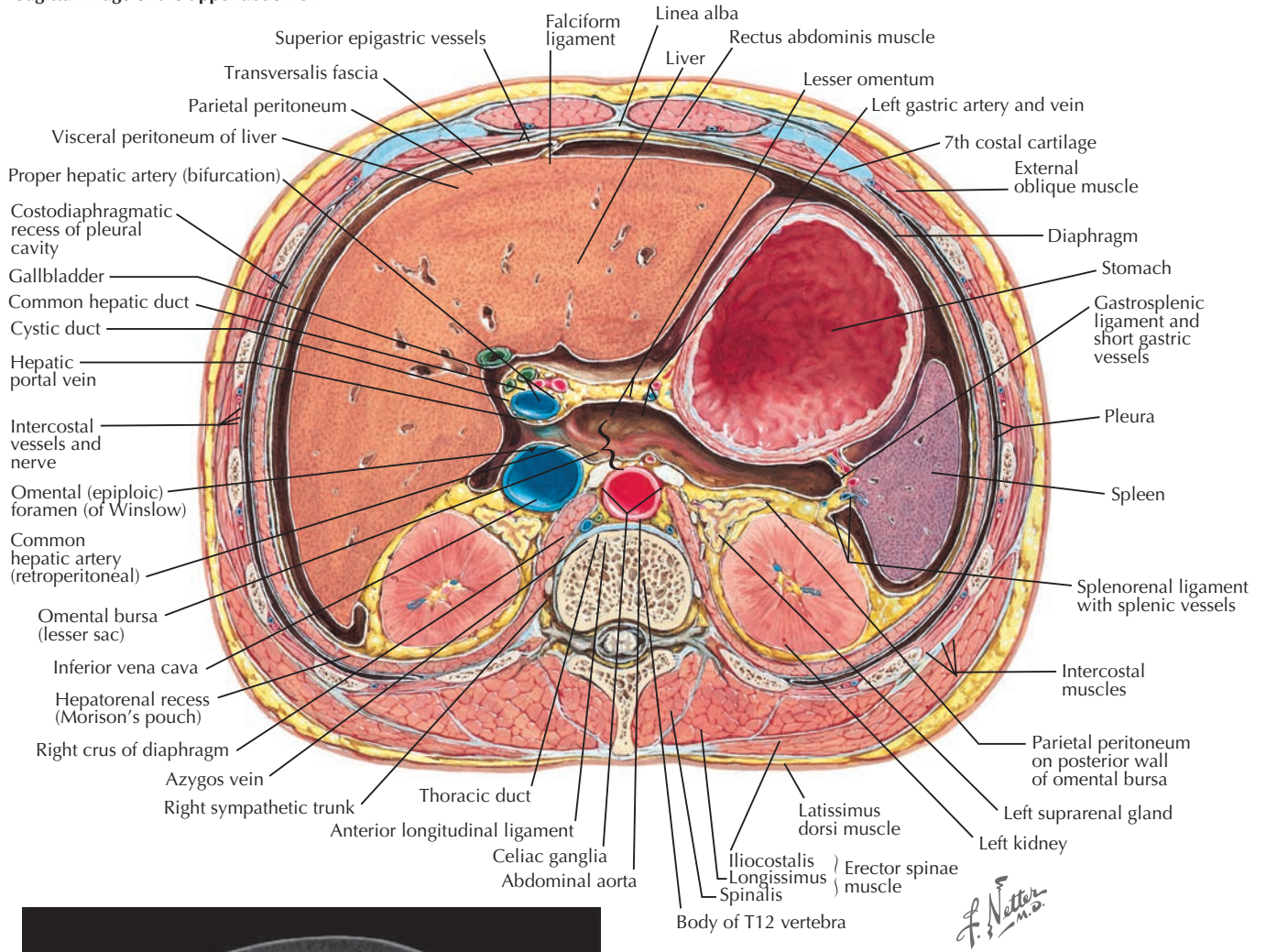
INTRODUCTION

Distal pancreatectomy is the term applied to resection of that portion of the pancreas extending to the left of the midline and not including the duodenum and distal bile duct. First described by Billroth in 1884, distal pancreatectomy is performed for various benign and malignant conditions involving the body and tail of the pancreas. These include inflammatory conditions such as chronic pancreatitis and symptomatic pseudocysts, pancreatic trauma, neuroendocrine tumors, pancreatic adenocarcinoma, solid neoplasms of indeterminate etiology, and cystic neoplasms of the pancreas. Because of the lower incidence of resectable malignant pancreatic neoplasms involving the body and tail of the pancreas, as well as the late appearance of clinical symptoms in this portion of the gland, distal pancreatectomy is performed less often than resection of the pancreatic head.

PREOPERATIVE EVALUATION

The indication for distal pancreatectomy will dictate preoperative workup and also influence surgical decision making. Multidetector, dynamic, contrast-enhanced computed tomography (CT) is the preoperative imaging modality of choice for all indications and is essential to surgical planning. CT provides detailed images of the pancreatic pathology and its relationship to surrounding organs, major vasculature, and pancreatic ducts, as well as the presence of metastatic disease (Fig. 15-1). Other modalities, such as endoscopic retrograde cholangiopancreatography (ERCP) and endoscopic ultrasound (EUS), may also be helpful when a definitive mass is not well visualized.

Sagittal image of the upper abdomen



CT scan demonstrating solid tumor in the tail of the pancreas

FIGURE 15-1 Anatomy for preoperative evaluation of pancreas.

SURGICAL APPROACH

The standard approach to resection of the body and tail of the pancreas is through an upper midline incision from the xiphoid process to just below the umbilicus. Alternatively, a bilateral subcostal incision can be used. The surgical approach depends on the indication, with several different approaches available.

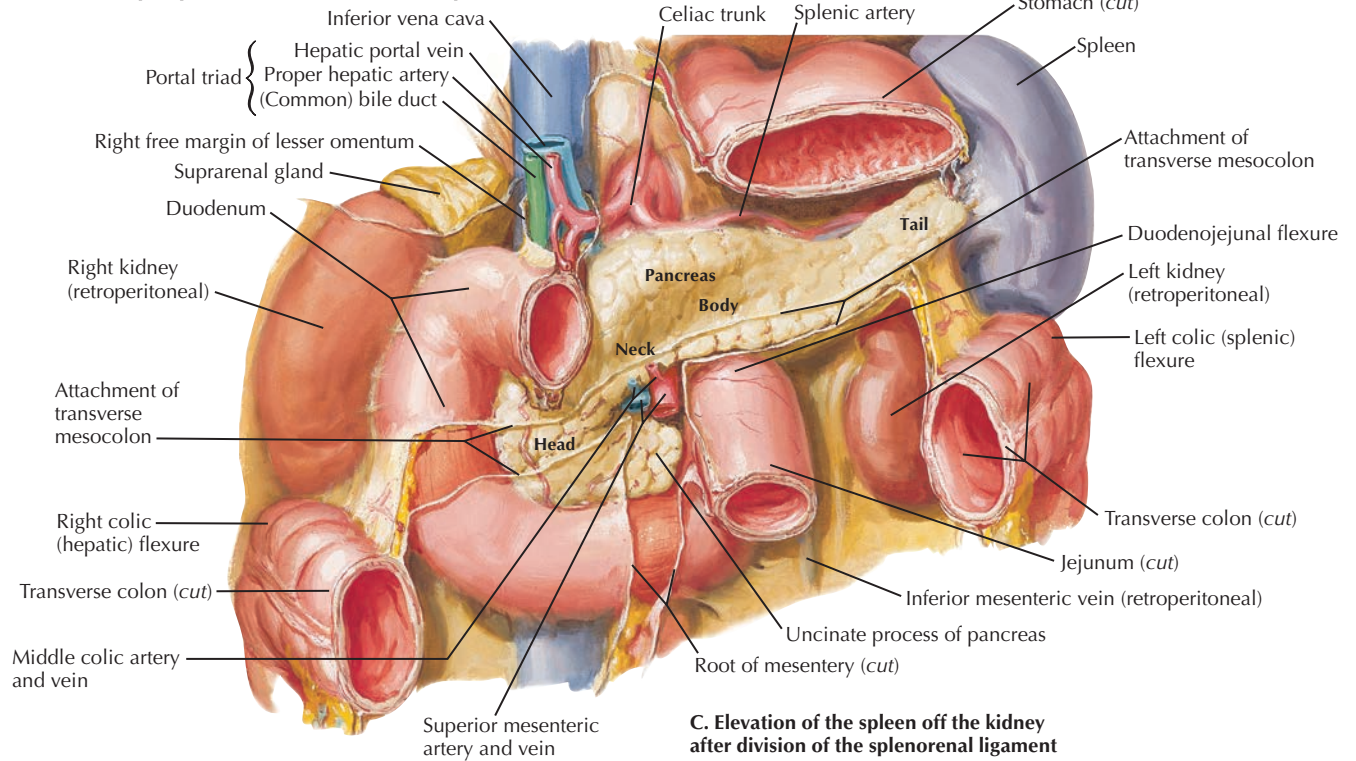
Open Retrograde Distal Pancreatectomy with Splenectomy

Retrograde distal pancreatectomy with splenectomy is the standard procedure for management of proven or suspected cancers in the body and tail of the pancreas, to ensure the adequacy of the lymph node dissection, or with tumors when the anatomic constraints dictate sacrificing the spleen (Fig. 15-2, A).

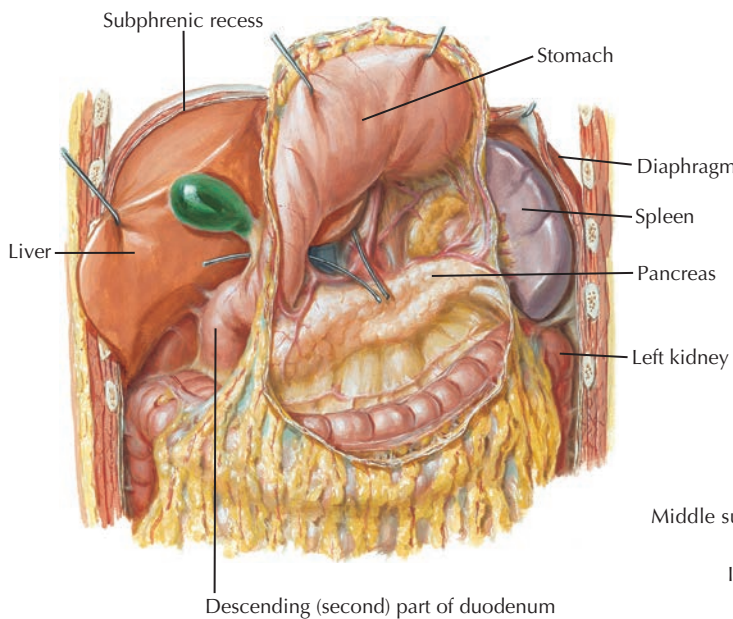
The pancreas is approached by opening the lesser sac through the gastrocolic ligament below the gastroepiploic vessels (Fig. 15-2, B). The peritoneum overlying the inferior border of the pancreas is divided lateral to the superior mesenteric vessels toward the tail. The splenocolic and splenorenal attachments are divided to mobilize the spleen anteriorly and to the right, separating it from splenic flexure of the colon and from Gerota's fascia (Fig. 15-2, C).

The short gastric vessels connecting the splenic hilum with the greater curvature of the stomach must be isolated and divided to facilitate mobilization of the tail of the pancreas. The dissection along the inferior margin of the pancreas is continued, and the inferior and posterior peritoneal attachments are divided. Care must be taken because there are numerous venous tributaries from the posterior aspect of the pancreas into the splenic vein. This dissection opens up the retroperitoneal window behind the pancreas.

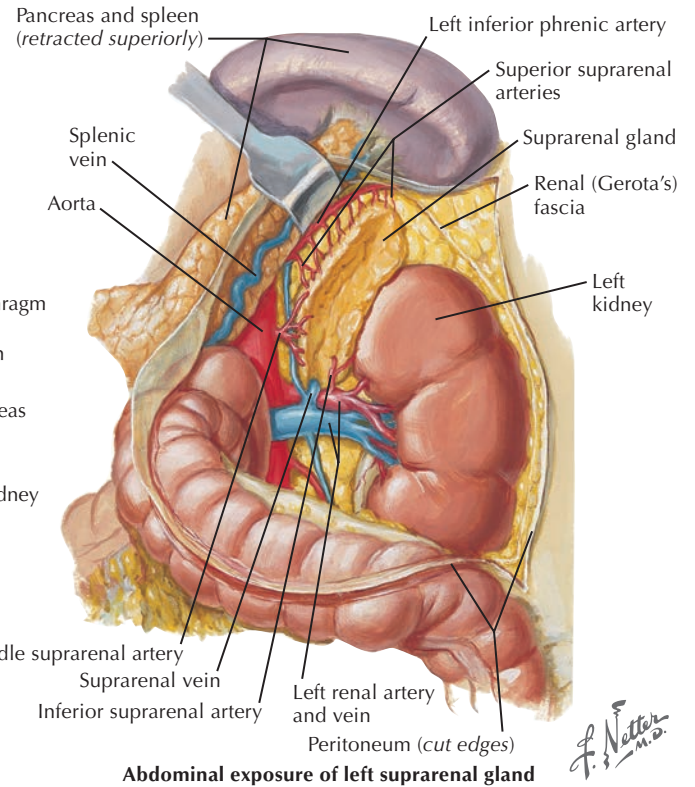
A. Relationship of pancreatic tail tumors to the spleen



B. Entering the lesser sac through the gastrocolic ligament



C. Elevation of the spleen off the kidney after division of the splenorenal ligament



Abdominal exposure of left suprarenal gland

F. Netter M.D.

FIGURE 15-2 Open retrograde distal pancreatectomy with splenectomy.

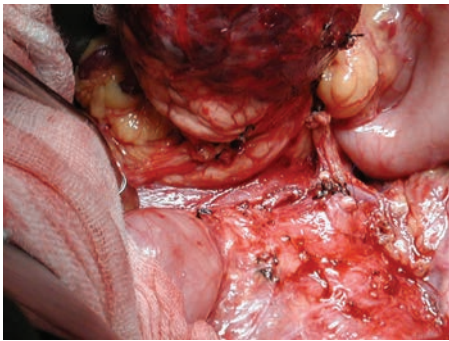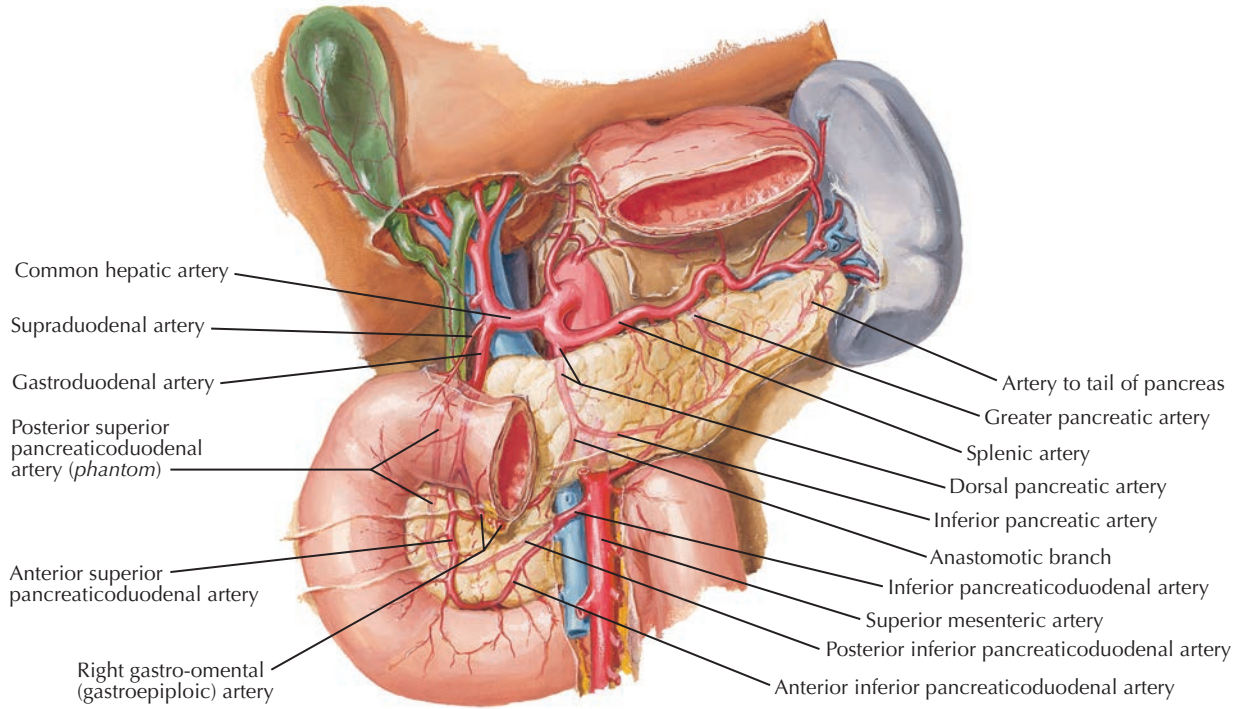
Division of Splenic Artery and Vein

Understanding the vascular anatomy of the pancreas is essential to safe technique (Fig. 15-3, *A*). The splenic artery is identified at its origin from the celiac trunk and traced distally along the posterosuperior border of the pancreas. It is divided just distal to its origin. The splenic vein is then isolated and divided just proximal to its confluence with the portal vein, preserving the inferior mesenteric vein if possible (Fig. 15-3, *B*).

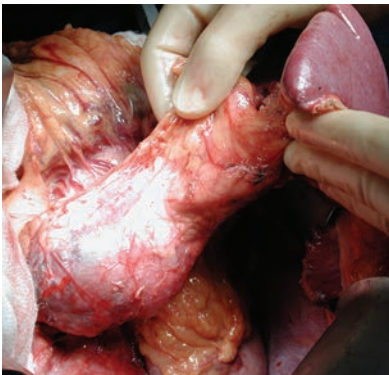
Division of Pancreas

The pancreas is rotated medially and the point of transection determined based on the location of the tumor. The pancreatic parenchyma may be divided using one of several techniques, including a gastrointestinal stapler or electrocautery. If well visualized, the pancreatic duct is oversewn (Fig. 15-3, *C and D*).

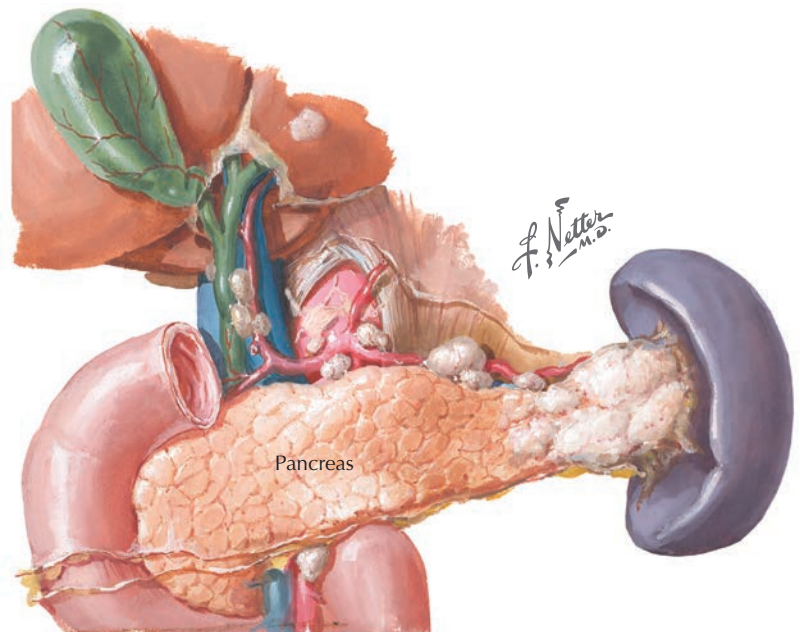
A. Blood supply of the pancreas



B. Intraoperative photograph of division of the splenic artery and vein



C. Intraoperative photograph showing the mobilized pancreas and spleen rotated medially



D. Carcinoma of tail adherent to spleen, metastases to lymph nodes and liver

FIGURE 15-3 Division of splenic artery and vein and pancreas.

Radical Antegrade Modular Pancreaticosplenectomy

The goals of pancreatic resection for cancer should be to perform a complete resection with clear margins and resection of regional lymph nodes (Fig. 15-4). Radical antegrade modular pancreaticosplenectomy (RAMPS), described by Strasberg in 2003, is a modified technique of distal pancreatectomy developed to allow for en bloc resection of the pancreas with an N1 lymphadenectomy. With this approach, dissection proceeds from medial to lateral (right to left), removing all nodal tissue surrounding the body and tail of the pancreas.

Division of Neck of Pancreas

The lesser sac is entered as previously described and the dissection carried to the origin of the right gastroepiploic artery. From the inferior border of the pancreas, the pancreatic neck is dissected off the superior mesenteric vein and the portal vein. The middle colic vein may be ligated to facilitate exposure. The hepatic artery is identified at the superior border of the pancreas and traced to identify the lymph nodes on the hepatic artery and portal vein. The gastroduodenal artery is ligated to expose the anterior surface of the portal vein, which is then dissected away from the neck of the pancreas; the neck is transected as previously described. The splenic artery and vein are then ligated and divided at their origins. The dissection is then extended posteriorly to include the retroperitoneal tissue and lymphatic tissue anterior to the left renal vein and all lymphatics to the left of the superior mesenteric artery and inferior to the celiac artery. The spleen is mobilized by dividing the splenorenal and splenocolic attachments.

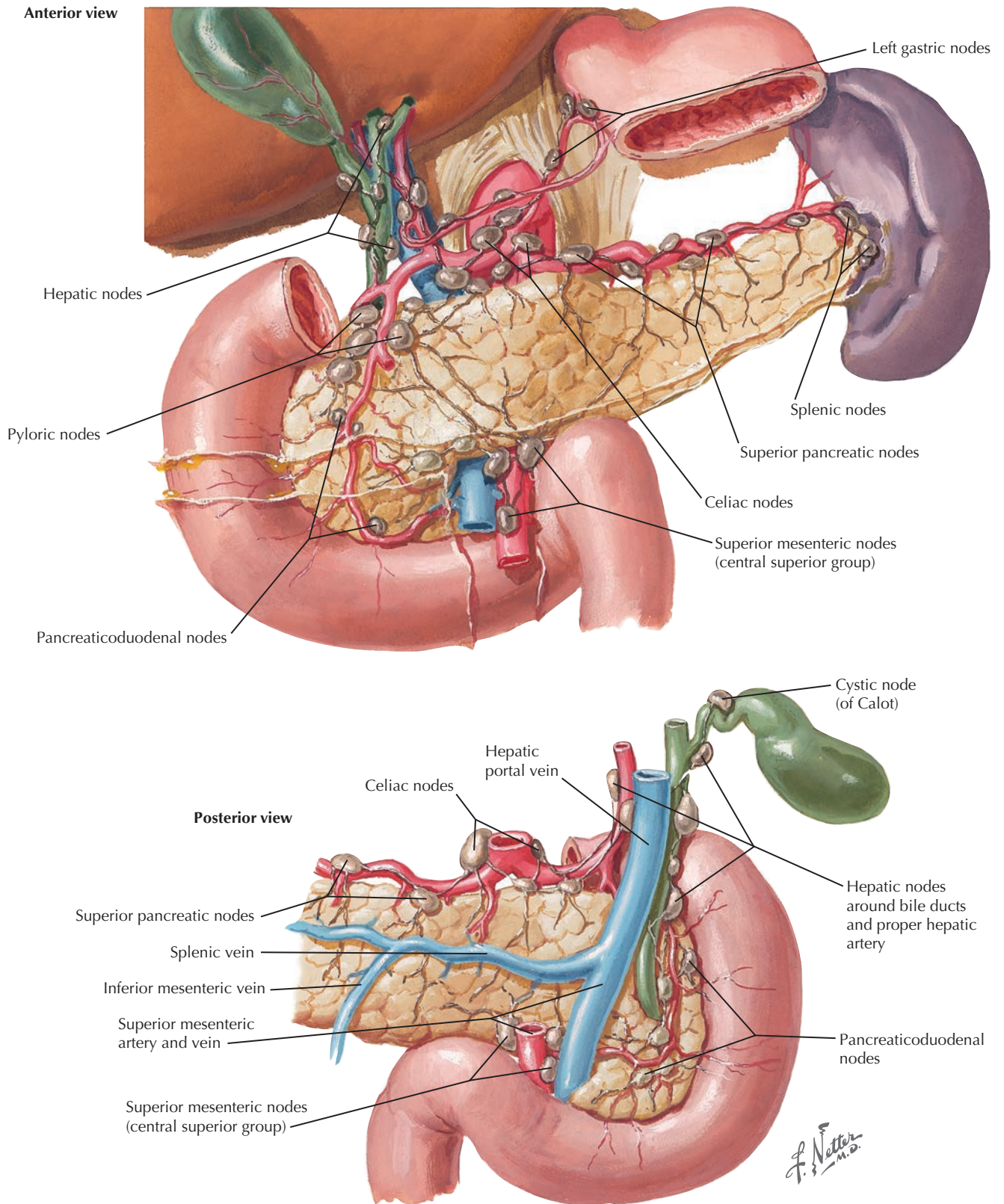


FIGURE 15-4 Lymphatic drainage of pancreas.

Distal Pancreatectomy with Splenic Preservation

Preservation of the spleen can be selectively applied in other benign conditions. Splenic preservation has the advantage of fewer infectious complications and no long-term risk of post-splenectomy sepsis. Distal pancreatectomy with splenic preservation can be performed using one of two techniques: (1) preserving the splenic artery and vein, by isolating and dividing the small branches between these vessels and the pancreas, or (2) ligating the splenic artery and vein with the pancreas, but preserving the collateral blood supply to the spleen provided by the short gastric and left gastroepiploic vessels, as described by Warshaw (see Suggested Readings).

If the spleen will be preserved, the surgical approach is similar to that for RAMPS. The lesser sac should be opened generously to allow for full exposure from the right gastroepiploic vessels medially, to the short gastric vessels laterally. The short gastric vessels are not divided when splenic preservation is planned. The lesser sac is opened, exposing the anterior aspect of the pancreas. The procedure can be carried out in a medial-to-lateral direction. An incision is made in the peritoneum along the inferior border of the body and tail of the pancreas, dissecting along the neck of the pancreas until the superior mesenteric vein and portal vein are exposed. The splenic vein is identified posteriorly.

An incision is then made along the superior edge of the pancreas to the left of the gastroduodenal artery. A plane is then developed between the portal vein and the neck of the pancreas by gentle blunt dissection. Once the opening is complete, a Penrose drain can be passed under the neck of the pancreas for anterior traction (Fig. 15-5). This facilitates mobilization of the splenic vein away from the proximal body of the pancreas. The small, fragile venous branches from the pancreatic parenchyma to the splenic vein should be divided. A distance of 2 to 3 cm is dissected laterally. The neck of the pancreas is divided, sparing the splenic vessels.

Once the pancreas is divided, the body of the pancreas is retracted superiorly to visualize the splenic artery. Small branches of the splenic artery should be controlled at this juncture to minimize bleeding. The distal pancreas is elevated off the splenic artery and vein. The remaining superior and inferior peritoneal attachments are divided to the level of the splenic hilum. The proximal jejunum may be in close proximity at this point and should be reflected inferiorly.

The final attachments of the pancreas can then be divided. The posterior margin of the dissection will be the splenic vein and artery. In the presence of larger tumors, sparing the splenic vessels may be difficult because of distortion in the course of the vessels.

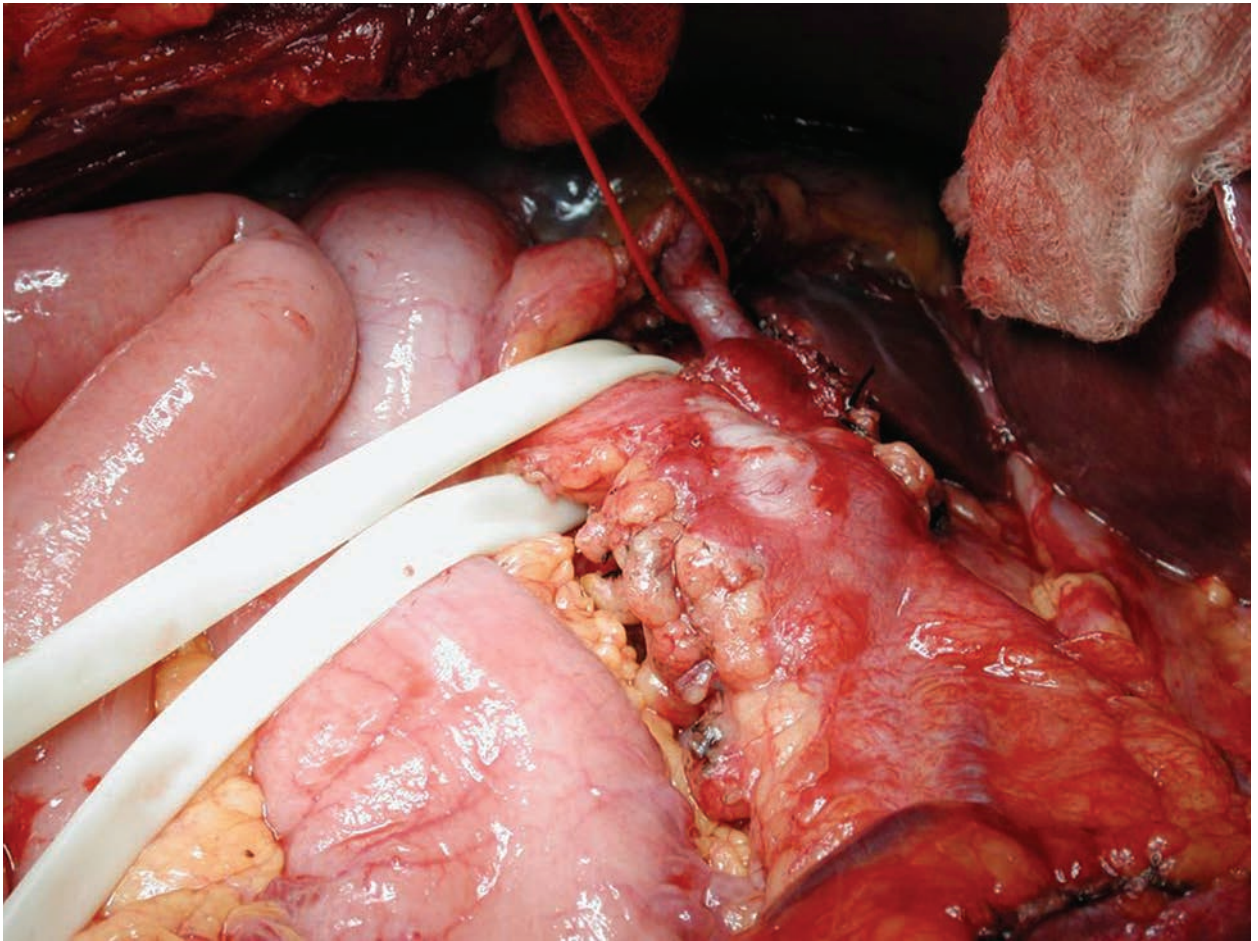


FIGURE 15-5 Mobilization of pancreas during spleen-preserving distal pancreatectomy.

LAPAROSCOPIC DISTAL PANCREATECTOMY

The last decade has seen increasing use of the laparoscopic approach to distal pancreatectomy, particularly in the management of cystic and benign lesions. The patient may be placed supine or in a modified lithotomy position with the left side elevated. If a laparoscopic resection will be performed, particular attention is paid to port placement, but the surgical approach is the same.

Trocar Placement for Laparoscopic Approach

Five ports are placed (Fig. 15-6); a 10-mm supraumbilical port is placed just to the left of midline. After the abdomen is insufflated, a 10- to 12-mm port is placed in the left midclavicular line, a 5-mm port in the subxiphoid area, a 5-mm trocar in the left anterior axillary line, and a 5-mm port in the right midclavicular line.

Laparoscopic Mobilization and Dissection

The majority of the dissection can be performed using a harmonic scalpel. The lesser sac is entered through the gastrocolic ligament. The spleen is mobilized by dividing the splenocolic attachments. The short gastric vessels are divided using clips or harmonic scalpel. The pancreas is freed from its superior attachments to identify the splenic artery.

The pancreas is then freed inferiorly and a window created posteriorly. The splenic artery and vein are then reflected off the pancreas, and the pancreas is divided using an endoscopic gastrointestinal stapler. The pancreas is reflected laterally, and the splenic vein and artery are sequentially divided using a vascular GIA stapler. The remaining splenic attachments are divided.

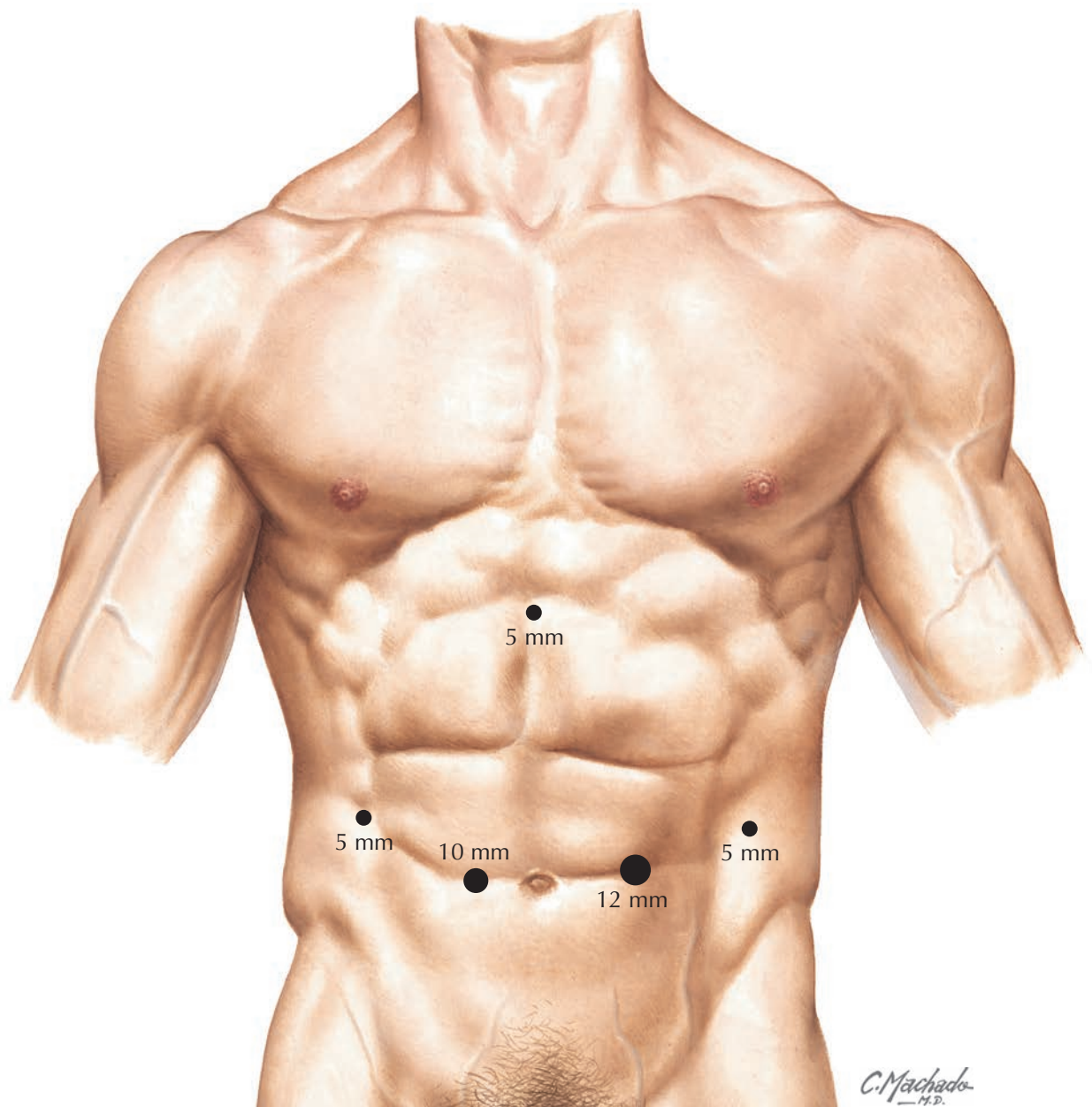


FIGURE 15-6 Port site placement for laparoscopic distal pancreatectomy.

SUGGESTED READINGS

- Bell RH, Denham EW. Distal pancreatectomy. In Clavien PA, Sarr MG, Fong Y, editors. Atlas of upper gastrointestinal and hepato-pancreato-biliary surgery. Berlin: Springer; 2007, pp 929-47.
- Fisher WE, Andersen DK, Bell RH, et al. Pancreas. In Brunicaudi FC. Schwartz's principles of surgery, 9th ed. New York: McGraw-Hill; 2010.
- Lillimoe KD, Kaushal S, Cameron JL, et al. Distal pancreatectomy: indications and outcomes in 235 patients. *Ann Surg* 1999;229:693-700.
- Napolitano C, Valvano L, Grillo M. Distal splenopancreatectomy: indications for surgery and technical notes. In *Surgical treatment of pancreatic diseases*. Milan: Springer; 2009, pp 321-8.
- Pierce RA, Spittler JA, Hawkins WG. Outcomes analysis of laparoscopic resection of pancreatic neoplasms. *Surg Endosc* 2007;21:579.
- Root J, Nguyen N, Jones B, et al. Laparoscopic distal pancreatic resection. *Am Surg* 2005;71:744.
- Schulick RD, Cameron JL. Cancer of the pancreas and other periampullary cancers. In *Main-got's abdominal operations*, 11th ed. New York: McGraw-Hill; 2007.
- Strasberg SM, Drebin JA, Linehan D. Radical antegrade modular pancreatectomy. *Surgery* 2003;133:521-7.
- Warshaw AL. Conservation of the spleen with distal pancreatectomy. *Arch Surg* 1988;123:550-3.

Pancreaticoduodenectomy

Jeffrey M. Hardacre

INTRODUCTION

Resection of tumors of the periampullary region has its origins in the writings of [Kausch \(1912\)](#) and [Whipple \(1935\)](#). Pancreaticoduodenectomy, or pancreatoduodenectomy, previously was accompanied by a mortality rate of 20% to 25%. Currently, however, most experienced pancreatic surgery centers report a mortality rate of 3% or less. Complication rates remain 20% to 50%, with the most troublesome complication being leakage at the pancreatic anastomosis.

The most common indication for pancreaticoduodenectomy is periampullary adenocarcinoma, predominantly of pancreatic duct origin. Cystic pancreatic neoplasms, particularly intraductal papillary mucinous neoplasms (IPMNs), have become a more frequent indication for pancreatic head resection.

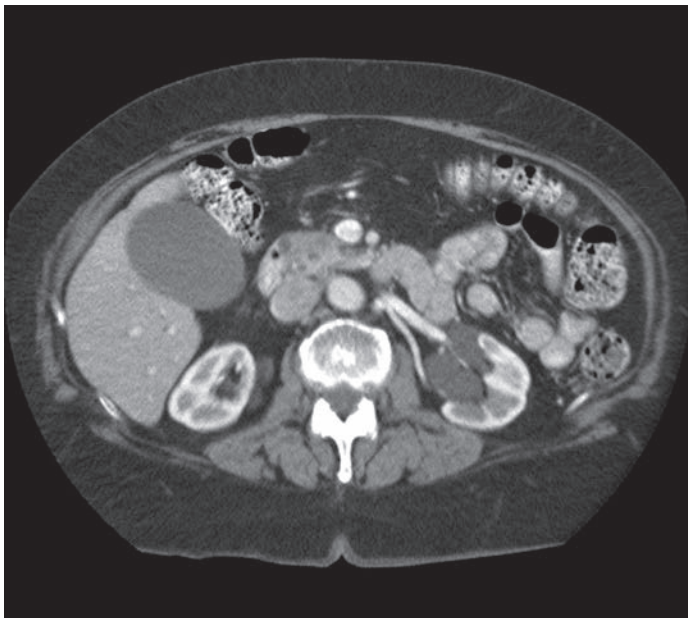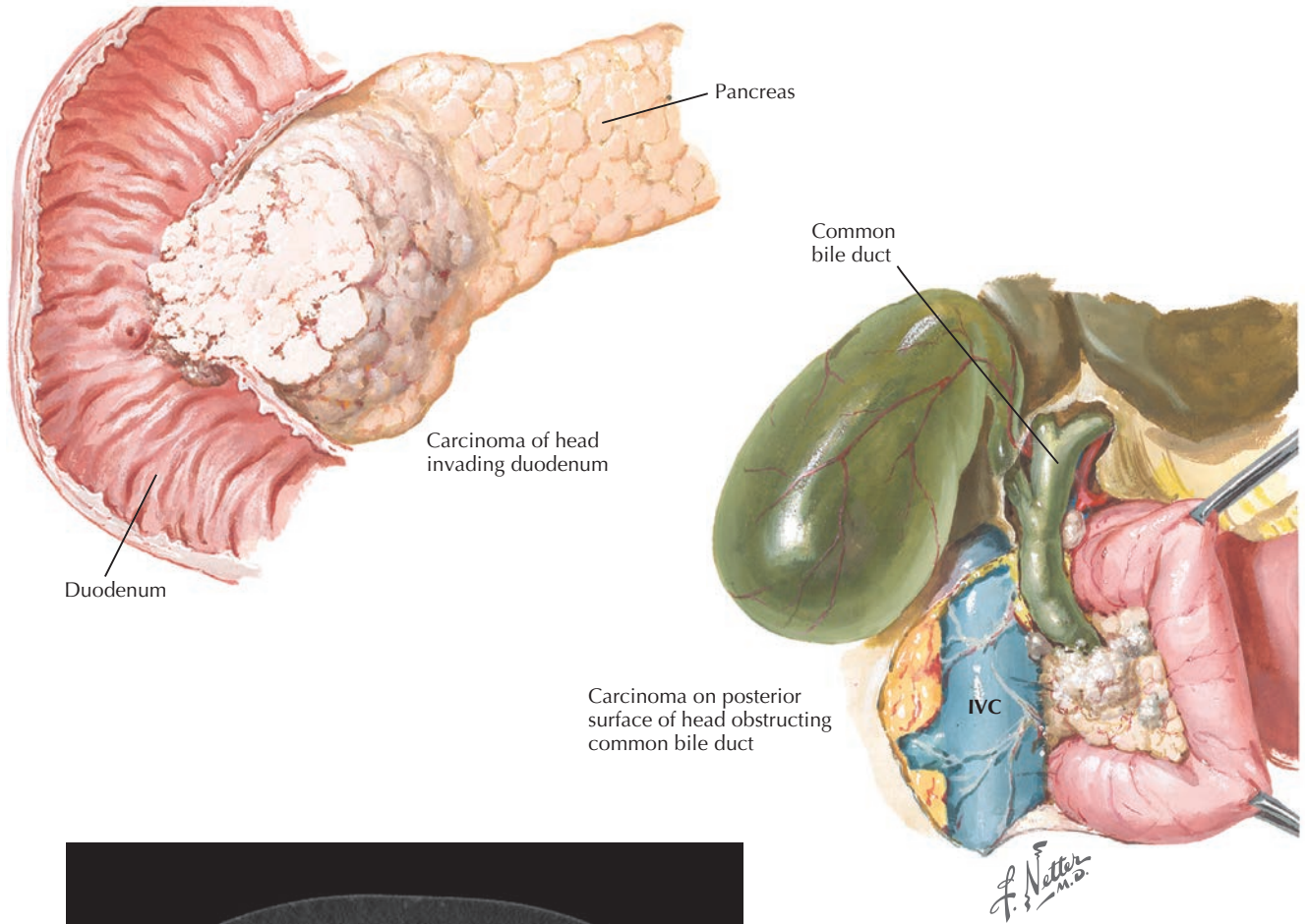
PRINCIPLES OF PANCREATIC CANCER TREATMENT

It is well established that pancreatic cancer is best treated in a multidisciplinary manner, using surgical resection, cytotoxic chemotherapy, and radiation therapy. Despite this approach, the survival rates have not changed dramatically during the past 3 decades.

The treatment of pancreatic cancer begins with accurate staging, including a complete history and physical examination. The most important component of staging is a multiphase computed tomography (CT) scan of the abdomen using a multidetector scanner (Fig. 16-1). With CT of the chest, this allows patients to be staged clinically as resectable (15% to 25%), borderline resectable or locally advanced/unresectable (30% to 40%), or metastatic (40% to 50%). Endoscopic ultrasound is rarely needed for staging purposes, and laparoscopy is favored by some authors. Debate continues about the utility of preoperative biliary decompression in jaundiced patients. Recently, laparoscopic approaches to pancreaticoduodenectomy have been described, but these remain nascent.

Pancreaticoduodenectomy is the mainstay of pancreatic head cancer treatment. No survival benefit has been shown when an extended lymphadenectomy is added, and no survival difference is seen when a classic pancreaticoduodenectomy is performed compared with a pylorus-preserving resection.

Most centers perform surgery first, followed by adjuvant therapy; however, some prefer a neoadjuvant approach to the treatment of pancreatic cancer. In the United States, chemotherapy combined with radiation therapy has historically been used most often in the adjuvant setting, whereas in Europe, chemotherapy alone is the standard adjuvant therapy. Given the still-poor outlook for patients, even with resected pancreatic cancer, novel therapies are desperately needed.



Multiphase computed tomography (C7)

FIGURE 16-1 Pancreatic cancer: clinical features.

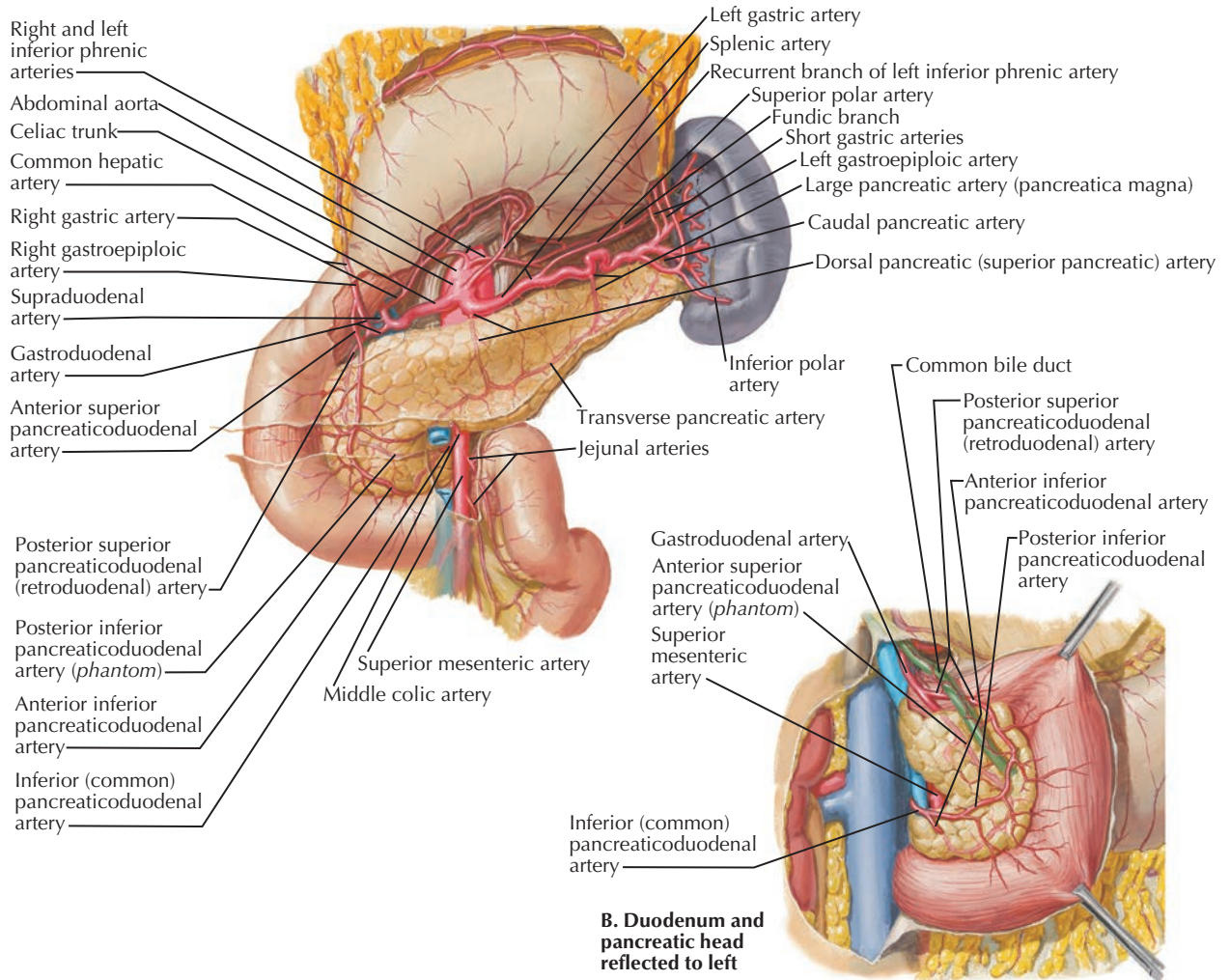
SURGICAL APPROACH

The abdomen is explored to evaluate for metastatic disease, either through an upper midline incision, diagnostic laparoscopy, or a chevron incision. If metastatic disease is found, or after thorough assessment, if a tumor is believed to be unresectable, many surgeons favor palliative biliary and duodenal bypasses, as well as a celiac plexus block.

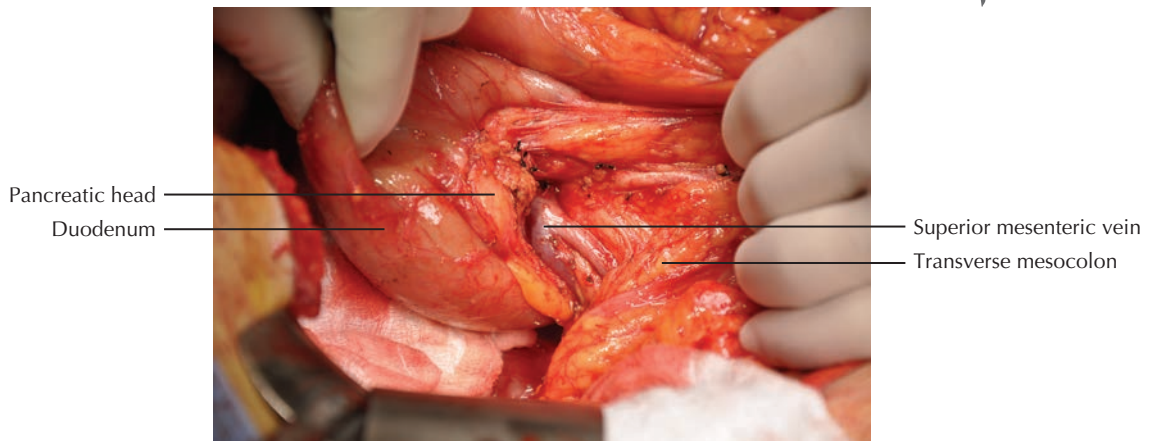
The dissection begins with a generous Kocher maneuver to lyse the lateral retroperitoneal attachments of the duodenum (Fig. 16-2, *A and B*). This elevates the duodenum and head of the pancreas out of the retroperitoneum. By taking the Kocher maneuver to its fullest extent, the surgeon identifies the superior mesenteric vein (SMV) in the groove between the head of the pancreas and the transverse mesocolon (Fig. 16-2, *C*). Further, the relationship of the tumor in the head of the pancreas to the SMV and superior mesenteric artery (SMA) is assessed. At this point, the surgeon should feel for evidence of a replaced or accessory right hepatic artery coming off the SMA (Fig. 16-3).

With the SMV identified, dissection is carried along this vessel cranially toward the inferior border of the pancreatic neck. The right gastroepiploic vein and its branches are identified and ligated, allowing the development of the plane posterior to the neck of the pancreas and anterior to the SMV (Fig 16-4).

A. Arteries of stomach, duodenum, pancreas, and spleen



B. Duodenum and pancreatic head reflected to left



C. Exposure of the superior mesenteric vein

FIGURE 16-2 Arterial supply of stomach and duodenum.

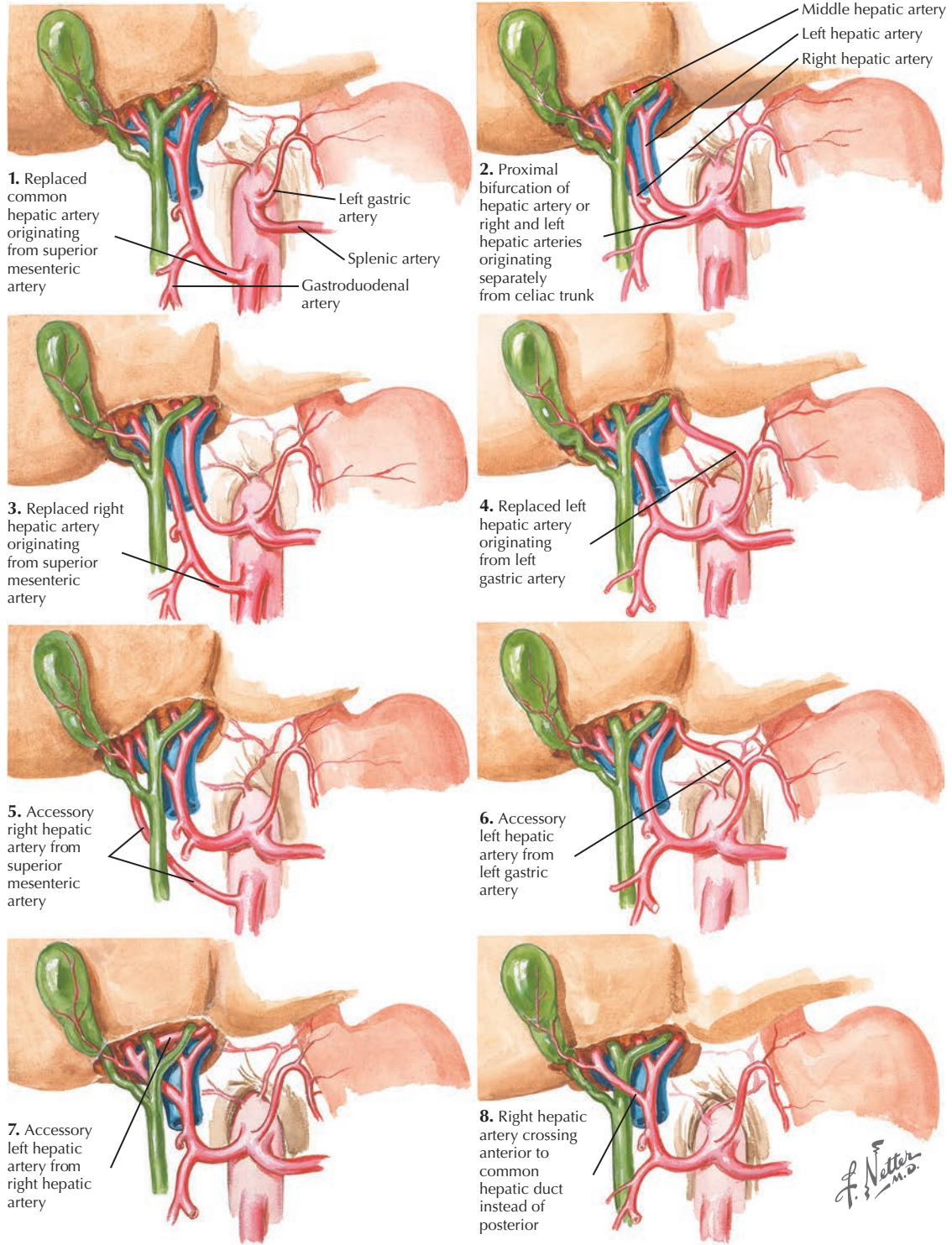


FIGURE 16-3 Variations in origin and course of hepatic artery and branches.

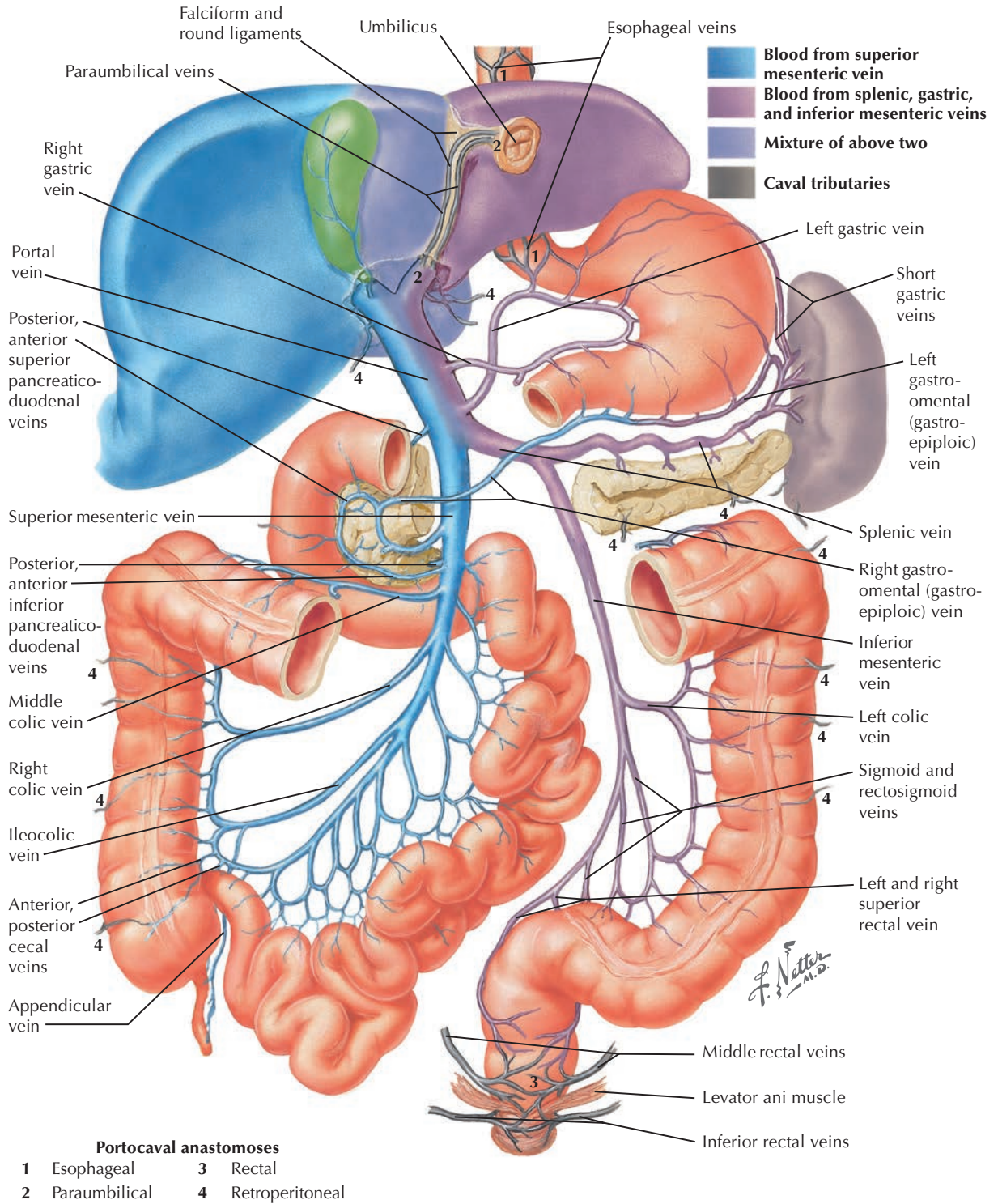


FIGURE 16-4 Hepatic portal vein tributaries: portocaval anastomoses.

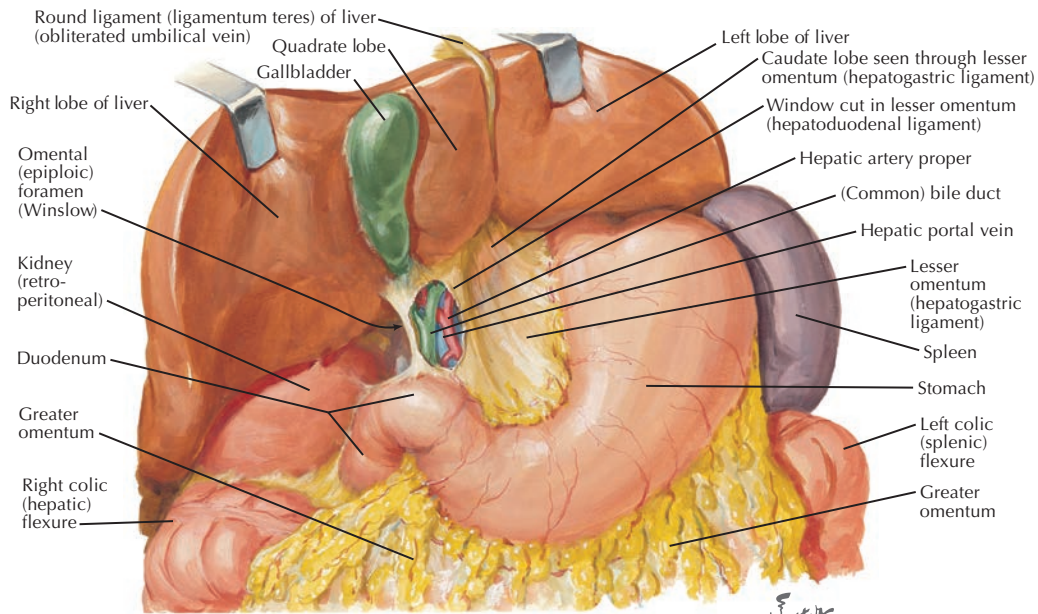
SURGICAL APPROACH—Cont'd

When the plane has been developed as far as possible from the inferior aspect, attention is turned to the hepatoduodenal ligament (Fig. 16-5, *A and B*). Care is taken to identify and preserve a replaced or accessory right hepatic artery. The common bile duct (CBD) is identified and encircled with a vessel loop. Some surgeons prefer to divide the CBD at this point. The gastroduodenal artery (GDA) is identified and encircled with a vessel loop as well (Fig. 16-5, *C*). Before ligating the GDA, the surgeon must be sure that when it is occluded, there is still a pulse in the hepatic artery going to the liver. Loss of that pulse may indicate an arcuate ligament syndrome, celiac stenosis, or variant arterial anatomy (see Fig. 16-3).

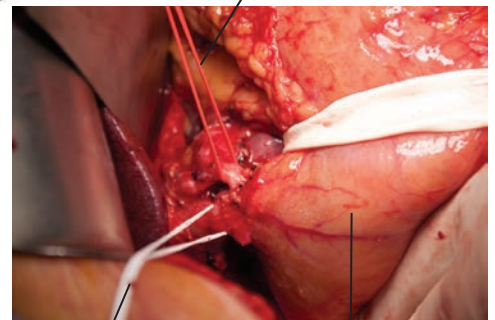
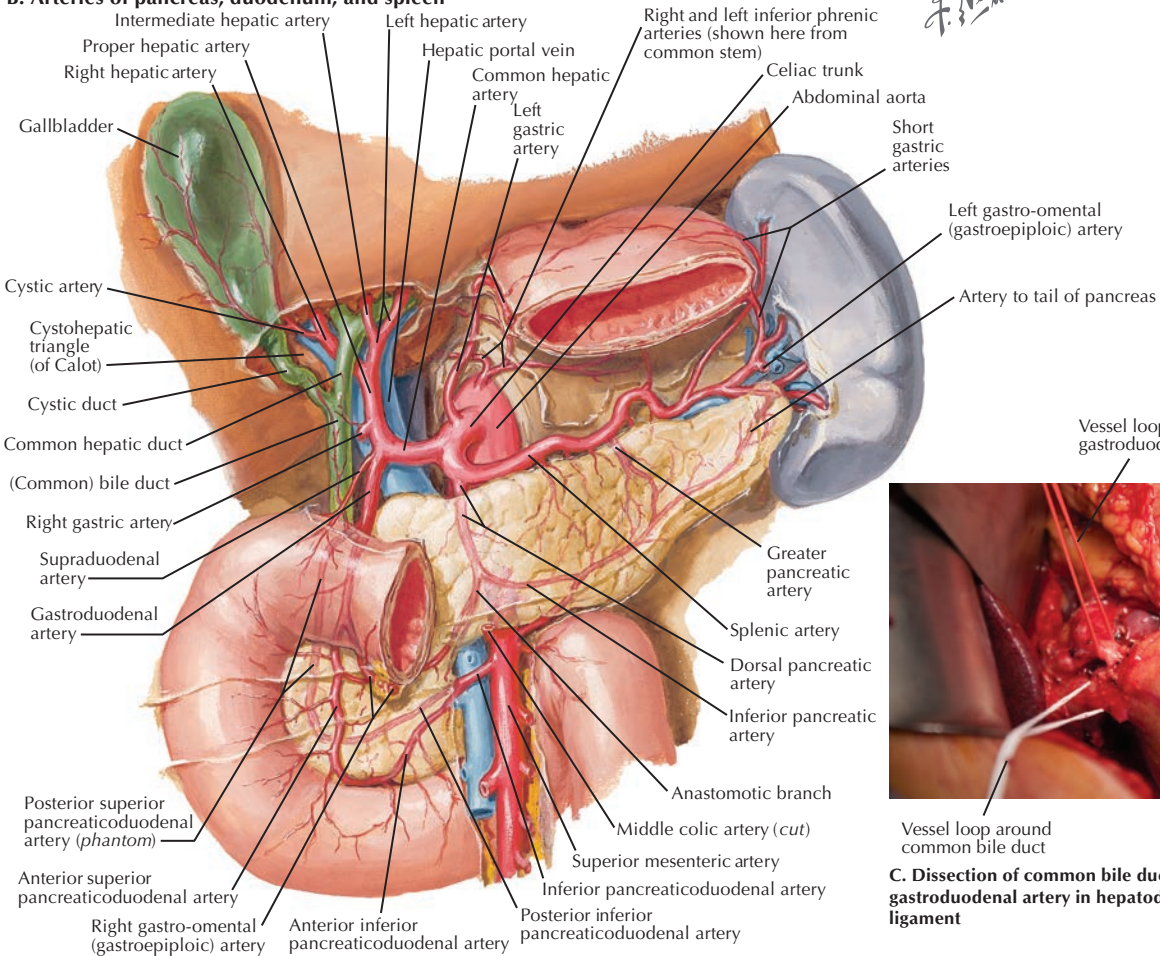
With the GDA ligated and the CBD retracted laterally or transected, the portal vein is easily identified. The plane posterior to the neck of the pancreas is then fully developed, connecting the dissection from inferior and superior. A Penrose drain is placed through that plane. With this plane developed and assessment confirming lack of SMV or SMA involvement, resectability has been confirmed.

If not done previously, the CBD is transected. Either the first portion of the duodenum (for a pylorus-preserving pancreaticoduodenectomy) or the distal stomach (for a classic pancreaticoduodenectomy) are dissected out and transected with a GIA stapler. The pancreatic neck is then transected and a margin sent from the remnant for frozen-section analysis.

A. Liver in Situ



B. Arteries of pancreas, duodenum, and spleen



C. Dissection of common bile duct and gastroduodenal artery in hepatoduodenal ligament

FIGURE 16-5 Liver and arterial anatomy of hepatoduodenal ligament for suprapancreatic dissection.

SURGICAL APPROACH—Cont'd

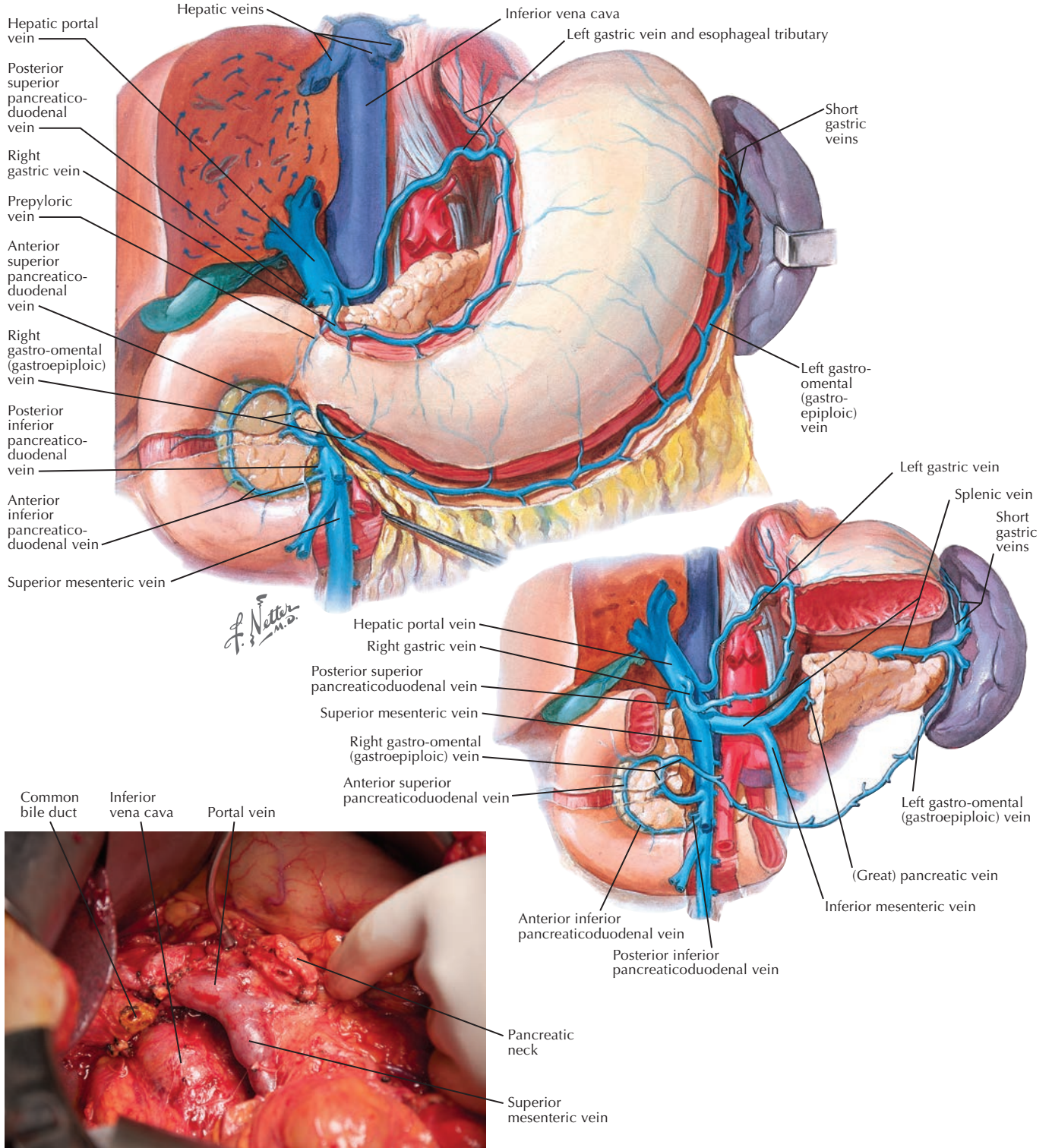
The duodenum and head of the pancreas are dissected away from the portal vein and SMV. There are few, if any, anterolateral small venous branches. The posterior superior pancreaticoduodenal vein is reliably identified and ligated (Fig. 16-6, A). The uncinete process is then dissected away from the SMA, taking care to ligate the pancreaticoduodenal arteries (see Fig. 16-2). Usually, one half to two thirds of the uncinete dissection is completed at this time.

Attention is then turned to the proximal jejunum, which is transected about 10 to 15 cm distal to the ligament of Treitz with a GIA stapler. The distal duodenal and proximal jejunal mesenteries are ligated, and then the bowel is fed underneath the SMA and SMV to the right upper quadrant. The uncinete dissection is completed, again flush with the SMA, and the specimen is marked and sent to pathology. While the surgeon is completing the uncinete dissection, the first jejunal branch off the SMV generally enters the vein on the right posterolateral surface and runs underneath the SMV to the patient's left. This branch can be problematic if not identified, and it usually is ligated. With the specimen removed, the operative field appears as shown in Figure 16-6, B.

Before reconstruction, a negative margin must be confirmed by frozen section for the pancreatic neck and bile duct. A frozen section of the uncinete (SMA margin) is not necessary because no more tissue can be taken from that area.

Reconstruction is generally done in the following order: pancreas, bile duct, duodenum/stomach. The jejunum is generally brought through a defect in the transverse mesocolon. In this case the ligament of Treitz is closed. Some surgeons bring the jejunum back through the ligament, underneath the SMA and SMV. The pancreatic and biliary anastomoses are universally done in a retrocolic manner. The duodenal/gastric anastomosis may either be done in a retrocolic or antecolic manner. Most surgeons leave one or two drains near the pancreatic and biliary anastomoses, but this practice is controversial.

A. Veins of stomach, duodenum, pancreas, and spleen



B. Operative field after specimen removed

FIGURE 16-6 Venous anatomy and the resection bed.

SUGGESTED READINGS

- Cameron JL. Rapid exposure of the portal and superior mesenteric veins. *Surg Gynecol Obstet* 1993;176:395.
- Farnell MB, Pearson RK, Sarr MG, et al. A prospective randomized trial comparing standard pancreatoduodenectomy with pancreatoduodenectomy with extended lymphadenectomy in resectable pancreatic head adenocarcinoma. *Surgery* 2005;138:618.
- Kausch W. Das Carcinom de papilla duodeni und seine radikale Entfernung. *Beiträge zur Klinischen Chirurgie* 1912;78:439.
- Lillemoe KD, Cameron JL, Hardacre JM, et al. Is Prophylactic gastrojejunostomy indicated for unresectable periampullary cancer? A prospective randomized trial. *Ann Surg* 1999;230:322.
- Lillemoe KD, Cameron JL, Kaufman HS, et al. Chemical splanchnicectomy in patients with unresectable pancreatic cancer: a prospective randomized trial. *Ann Surg* 1993;217:447.
- Neoptolemos JP, Stocken DD, Bassi C, et al. Adjuvant chemotherapy with fluorouracil plus folinic acid vs gemcitabine following pancreatic cancer resection. *JAMA* 2010;304:1073.
- Oettle H, Post S, Neuhaus P, et al. Adjuvant chemotherapy with gemcitabine vs observation in patients undergoing curative-intent resection of pancreatic cancer. *JAMA* 2007;297:267.
- Regine WF, Winter KA, Abrams RA, et al. Fluorouracil vs gemcitabine chemotherapy before and after fluorouracil-based chemoradiation following resection of pancreatic adenocarcinoma. *JAMA* 2008;299:1019.
- Whipple AO, Parsons WB, Mullins CR. Treatment of carcinoma of the ampulla of Vater. *Ann Surg* 1935;102:763.
- Yeo CJ, Cameron JL, Lillemoe KD, et al. Pancreaticoduodenectomy with or without distal gastrectomy and extended retroperitoneal lymphadenectomy for periampullary adenocarcinoma. Part 2. Randomized controlled trial evaluating survival, morbidity, and mortality. *Ann Surg* 2002;236:355.

Splenectomy

Christopher T. Siegel and Raymond Onders

INTRODUCTION

Nontraumatic splenectomy is usually indicated for patients with benign or malignant hematologic disorders who are not responding to medical therapy. Indications include idiopathic thrombocytopenic purpura (ITP) or other hematologic disorders that lead to splenic sequestration of platelets and red blood cells; patients with thrombotic thrombocytopenic purpura (TTP), hereditary spherocytosis, autoimmune hemolytic anemia, or symptomatic thalassemias may also respond to splenectomy. Splenectomy may also be a treatment option for malignancies such as primary lymphoma or metastatic disease to the spleen.

SURGICAL PRINCIPLES

The key to safe splenectomy is understanding the anatomy surrounding the spleen (Fig. 17-1). The spleen must be safely mobilized from all the surrounding structures to prevent common perioperative complications related to the splenic anatomy, including gastric injury or leak during division of short gastric vessels; pancreatitis or pancreatic fistula from the pancreatic tail during mobilization of the splenic hilum; colon injury during division splenic flexure; left pleural effusion or left pulmonary atelectasis from excessive diaphragm manipulation; and bleeding from short gastric vessels, splenic artery, or splenic vein.

During the postoperative period, splenic vein thrombosis can lead to inferior mesenteric vein or portal vein thrombosis, with serious consequences (Fig. 17-2, A). The most serious long-term complication of splenectomy is *sepsis*, which can be decreased with preoperative immunization for the common encapsulated organisms, including meningococcal, pneumococcal, and *Haemophilus influenzae* type B infections, either 2 weeks before or on the last day of admission after surgery.

In the preoperative period, radiologic imaging can be obtained in patients with an enlarged spleen to assist in surgical planning (Fig. 17-2, B). The surgical approach to splenectomy often depends on the size of the spleen. Clinical data for elective splenectomies support a purely laparoscopic approach for spleens less than 20 cm in size and a hand-assisted or open approach for larger spleens.

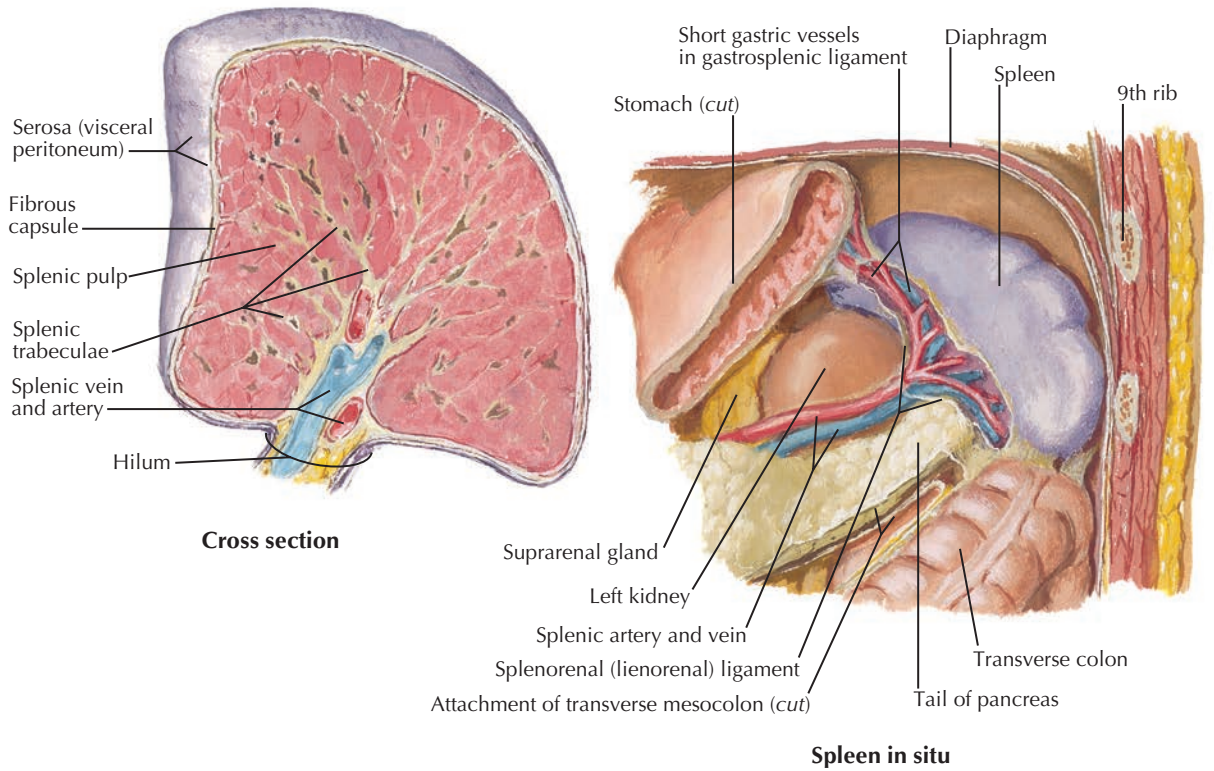
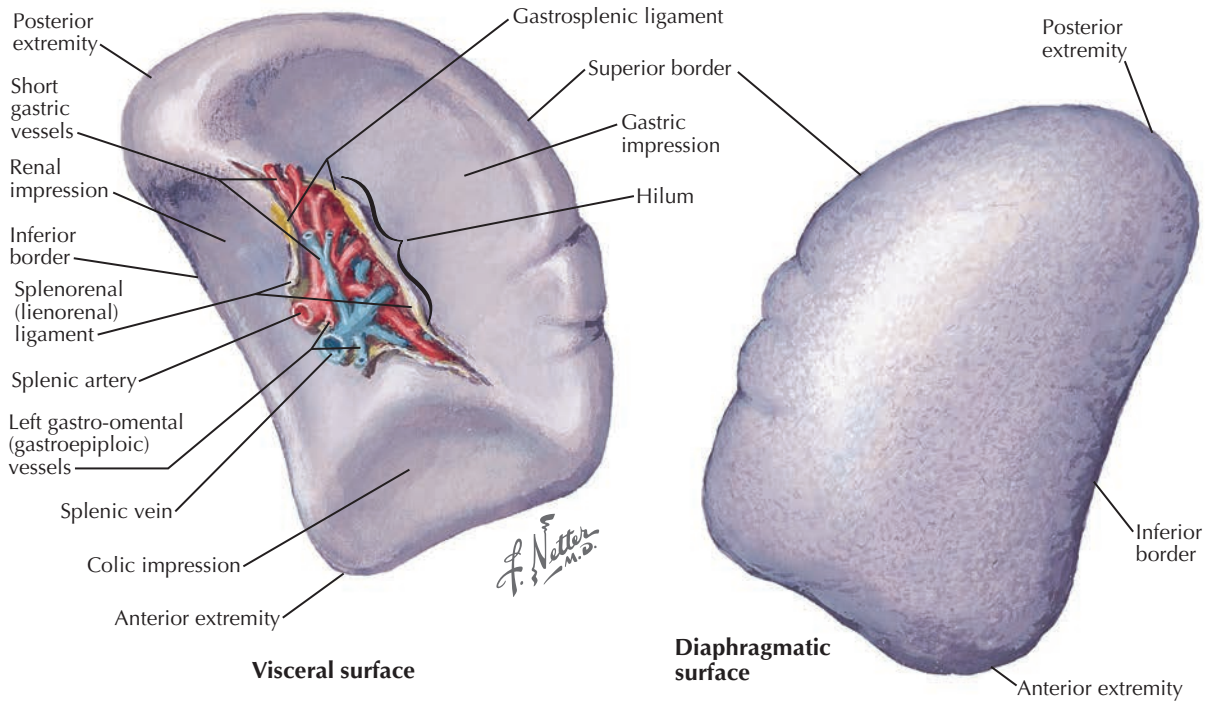


FIGURE 17-1 Spleen and surrounding structures.

LAPAROSCOPIC SURGICAL TECHNIQUE

The patient is placed in a right lateral position with the surgeon on the patient's right side and the patient flexed at the waist to open up the space between the costal margin and the iliac crest. Three or four ports are placed subcostally, with the camera port in the center to facilitate the triangulation for dissection. A 5-mm port is placed in the epigastric area, and a 12-mm port in the anterior axillary line will be used for the endoscopic staplers. These ports can be moved lower depending on the size of the spleen.

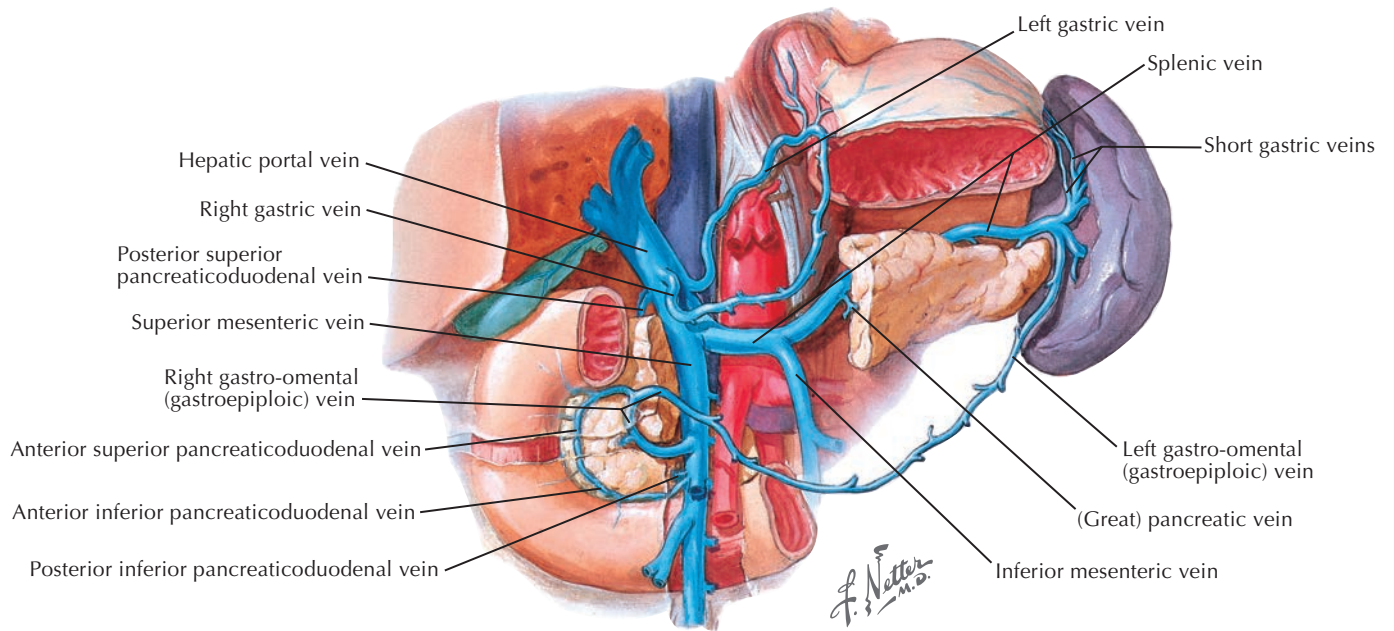
Initially and throughout each stage of the procedure, accessory spleens are searched for and removed if identified. Dissection is done with an ultrasonic energy source beginning at the lower pole of the spleen, mobilizing the splenic flexure by dividing the lienocolic ligament. The goal of the mobilization is to be able to place a vascular stapler safely across the hilum of the splenic structures, as shown in [Figure 17-1](#). The gastrosplenic ligament and the short gastric vessels are divided. The posterior and lateral splenophrenic attachments are also divided. These are usually avascular unless the patient has portal hypertension.

At this point, the splenic hilum can clearly be seen, and a vascular stapler can be placed perpendicular to the vessels before firing. At times, it may take several reapplications of the stapler to divide completely all the branches to the upper pole of the spleen. Once the splenic artery is divided, if there is significant thrombocytopenia and bleeding is a concern, platelets can now be given.

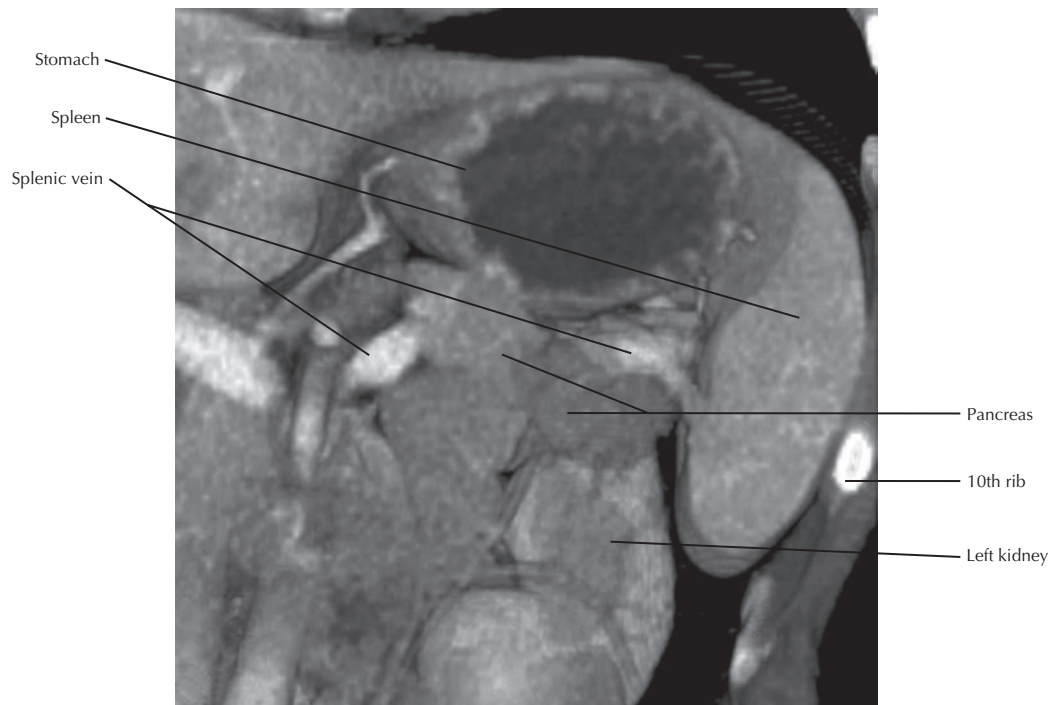Once the last retroperitoneal attachments have been divided, the spleen can be placed into a specimen bag and removed from the abdominal cavity by either extending the incision or morcellating the specimen with ring forceps. The abdominal cavity is evaluated again for evidence of accessory spleens and bleeding. Drains are not usually placed.

Hand-Assisted or Open Approach

If a hand-assisted approach is used, the patient is placed in a modified right lateral decubitus position with only 45- to 60-degree elevation. The hand port is placed in the upper midline position, with two other ports in the subcostal position. The dissection is similar to the laparoscopic approach, but the surgeon's nondominant hand is used to assist with the dissection. The spleen is then delivered through the hand port.



A. Venous drainage of spleen showing connection with the inferior mesenteric vein



B. Radiologic imaging can be used to estimate size of the spleen (spleen shown not enlarged)

FIGURE 17-2 Venous anatomy and the resection bed in splenectomy. (B from Weber EC, Vilensky JA, Carmichael JW. *Netter's radiologic anatomy*. Philadelphia: Elsevier; 2008.)

SUGGESTED READINGS

- Bulus H, Mahmoud H, Altun H, et al. Outcomes of laparoscopic versus open splenectomy. *J Korean Surg Soc* 2013;84(1):38-42.
- Fraser SA, Bergman S, Garzon J. Laparoscopic splenectomy: learning curve comparison between benign and malignant disease. *Surg Innov* 2012;19(1):27-32.
- Habermalz B, Sauerland S, Decker G, et al. Laparoscopic splenectomy: the clinical practice guidelines of the European Association for Endoscopic Surgery (EAES). *Surg Endosc* 2008;22(4):821-48.
- Katkhouda N, Manhas S, Umbach TW, Kaiser AM. Laparoscopic splenectomy. *J Laparoendosc Adv Surg Tech A* 2001;11(6):383-90.

Organ Transplantation

Kenneth J. Woodside, Edmund Q. Sanchez, and James A. Schulak

INTRODUCTION

Organ transplantation is a surgical treatment for end-stage organ disease. The optimal approach to treatment of the patient with end-stage kidney disease is a kidney transplant, with the allograft obtained from either a voluntary living donor or a deceased donor. Similarly, patients with type 1 diabetes mellitus can be treated with a pancreas transplant. Typically, these types of transplant are performed in *heterotopic* locations, with the original recipient organs remaining in situ. Cirrhosis, as well as certain metabolic conditions and certain primary liver tumors, can be treated with *orthotopic* liver transplant, although heterotopic and split-liver transplants are also performed. Most liver allografts are obtained from deceased donors.

Before initiating the transplant, the blood type of the recipient and donor should be confirmed. In addition, immunologic crossmatching is performed. If the patient is not sensitized, engraftment may occur before the crossmatch has returned. If there is a degree of sensitization, a negative crossmatch should be confirmed before engraftment. For liver transplantation, crossmatching is typically retrospective.

ABDOMINAL ORGAN DONATION

Deceased donors are a requisite to organ transplantation. The success of the donor surgery depends on the knowledge of the anatomy of the targeted organs for transplantation. Typically, no predonation anatomic imaging is performed, and successful recovery relies on the surgical familiarity and experience of the surgeon performing the operation. The most important structures to preserve are the hepatic arterial vasculature, which arises from the celiac axis in most cases, the portal venous trunk, and the extrahepatic bile ducts. There is significant anatomic variation in both the arterial and the biliary systems. In renal allograft retrieval, preservation of the renal arteries, veins, and ureters is important. Pancreas allografts require adequate length of portal vein, superior mesenteric artery, and splenic artery stumps.

The organs are procured through (1) standard deceased donor (DD) and (2) donation after cardiac death (DCD). The main difference is that the DD must have “brain death” declared, whereas DCD does not. Logistically, the DCD procedure cannot start until the patient has been declared dead by the primary team, which occurs after they have withdrawn support, cardiac arrest has occurred, and asystole has been documented for at least 5 minutes. Both procedures rely on retrograde or antegrade flushing of the organs with preservation solution through a cannula inserted in the distal aorta. After procurement, the cooled and flushed organs are transported to the appropriate transplant centers for engraftment.

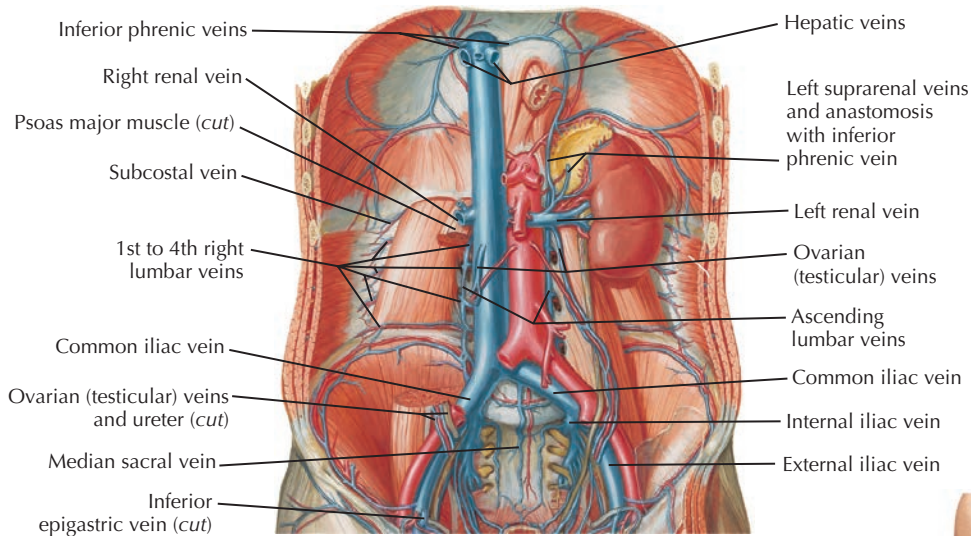
The goals of the donor operation are to isolate the necessary anatomic structures and to prevent any damage to the structures to allow successful transplantation. This procedure involves the preservation of arterial and venous supplies to the relatively solid organs. Also, the cannulas must be placed for organ flush and perfusion with preservative solution. Typically, retrograde flush of the organs is accomplished through the distal aorta, with proximal clamping above the celiac axis. The venous effluent is released through an incision in the right atrium or cannulation of the distal cava (Fig. 18-1, A).

Abdominal Surgical Approach

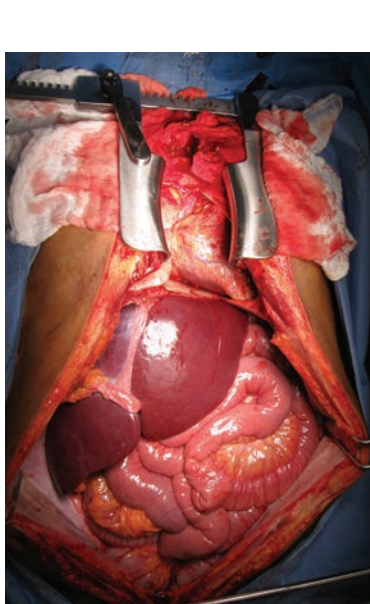
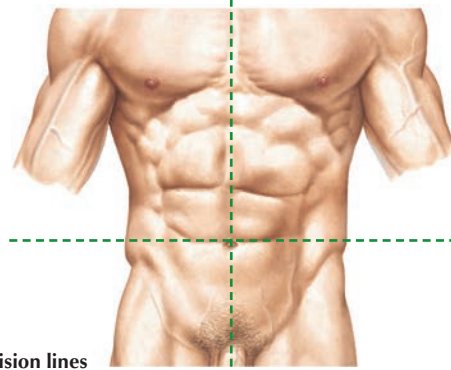
The incision for the donor surgery extends from the sternal notch to the pubis of the donor (Fig. 18-1, B and C). A sternotomy is performed, and most often, a sternal retractor and large Balfour retractor are used to provide exposure. When more abdominal exposure is needed, an abdominal cruciate incision can be utilized.

Mobilization of the right hemicolon with a right medial visceral rotation (Cattell-Braasch maneuver) is performed to expose the distal abdominal aorta and inferior vena cava (IVC) (Fig 18-1, D). The left renal vein can be exposed through this maneuver, and further dissection cephalad to the left renal vein will allow the surgeon to control the superior mesenteric artery (SMA). The distal aorta is encircled and cannulated, and the aorta is ligated just proximal to the iliac bifurcation after full heparinization before cross-clamping. Additionally, the inferior mesenteric vein (IMV) also can be isolated and encircled, which can provide access for portal system flush, if elected (Fig. 18-1, E).

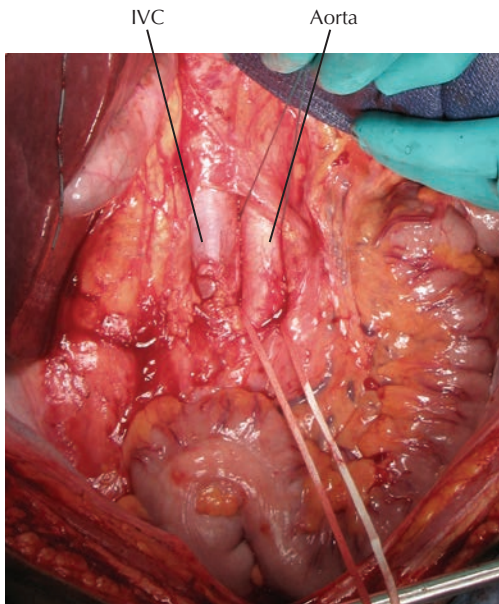
A. Inferior vena cava



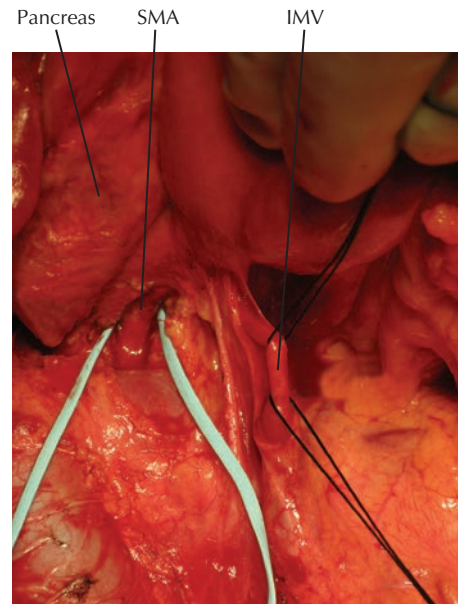
F. Netter M.D.
C. Machado M.D.



C. Organ donor exposure



D. Exposure of the distal aorta and IVC



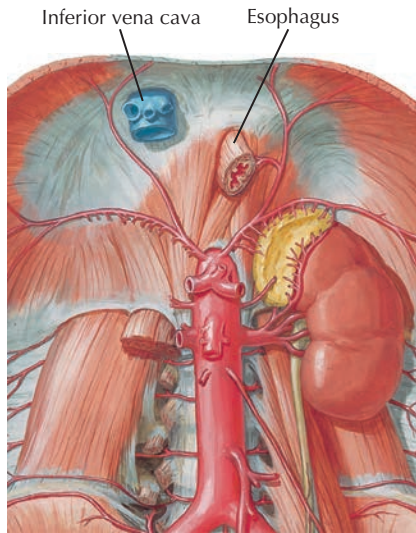
E. Exposure of the SMA and IMV caudal to the pancreas

FIGURE 18-1 Abdominal anatomy and organ procurement exposures. *IVC*, inferior vena cava; *SMA*, superior mesenteric artery; *IMV*, inferior mesenteric vein.

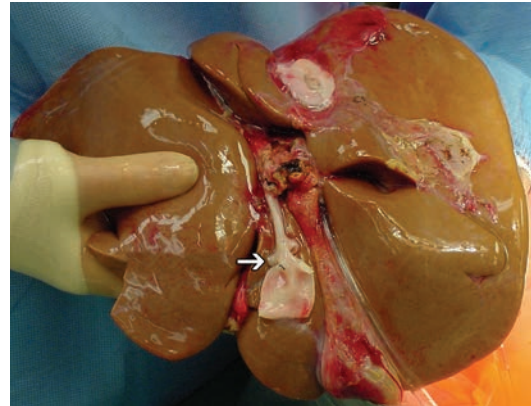
Abdominal Surgical Approach—Cont'd

To obtain proximal intraabdominal aortic control for retrograde flush, the surgeon exposes the supraceliac aorta by dividing the crus of the diaphragm while retracting the left lobe of the liver (Fig. 18-2, A). The supraceliac aorta is encircled at this time with a vessel loop or umbilical tape. The gastrohepatic ligament is inspected for accessory left hepatic artery, which arises from the left gastric artery (see Chapter 16, Fig. 16-3). If present, the accessory left hepatic artery is preserved by careful dissection along the lesser curvature of the stomach. Also, the lateral portion of the portal triad is palpated for the presence of a replaced right hepatic artery; if present, it is preserved down to its origin arising from the SMA.

The portal triad structures are dissected to expose more of the hepatic artery, portal vein, and common bile duct (CBD) (Fig. 18-2, B). The peritoneum is divided at the cephalad border of the duodenum to expose the CBD laterally, and the gastroduodenal artery and common hepatic artery (CHA) medially. A full Kocher maneuver can also be performed at this time to trace a replaced right hepatic artery to the SMA origin. This is not necessary if there is no replaced right hepatic artery, or if the pancreas will not be procured. The gastroduodenal artery is identified and followed up to the CHA, which is dissected out to determine whether there are any other anatomic variations. Further dissection to the origin of the splenic artery is often performed “in the warm” (before cross-clamp and perfusion), whereas the rest of the dissection down to the celiac trunk is usually performed “in the cold” (after cross-clamp and perfusion). The donor liver must have a celiac trunk in continuity with the CHA for the intended recipient (Fig. 18-2, C).



A. Anterior view. Openings from top to bottom are for inferior vena cava, esophagus, and aorta



C. Celiac trunk and hepatic artery on aortic patch (arrow)

B. Arteries of liver, pancreas, duodenum, and spleen

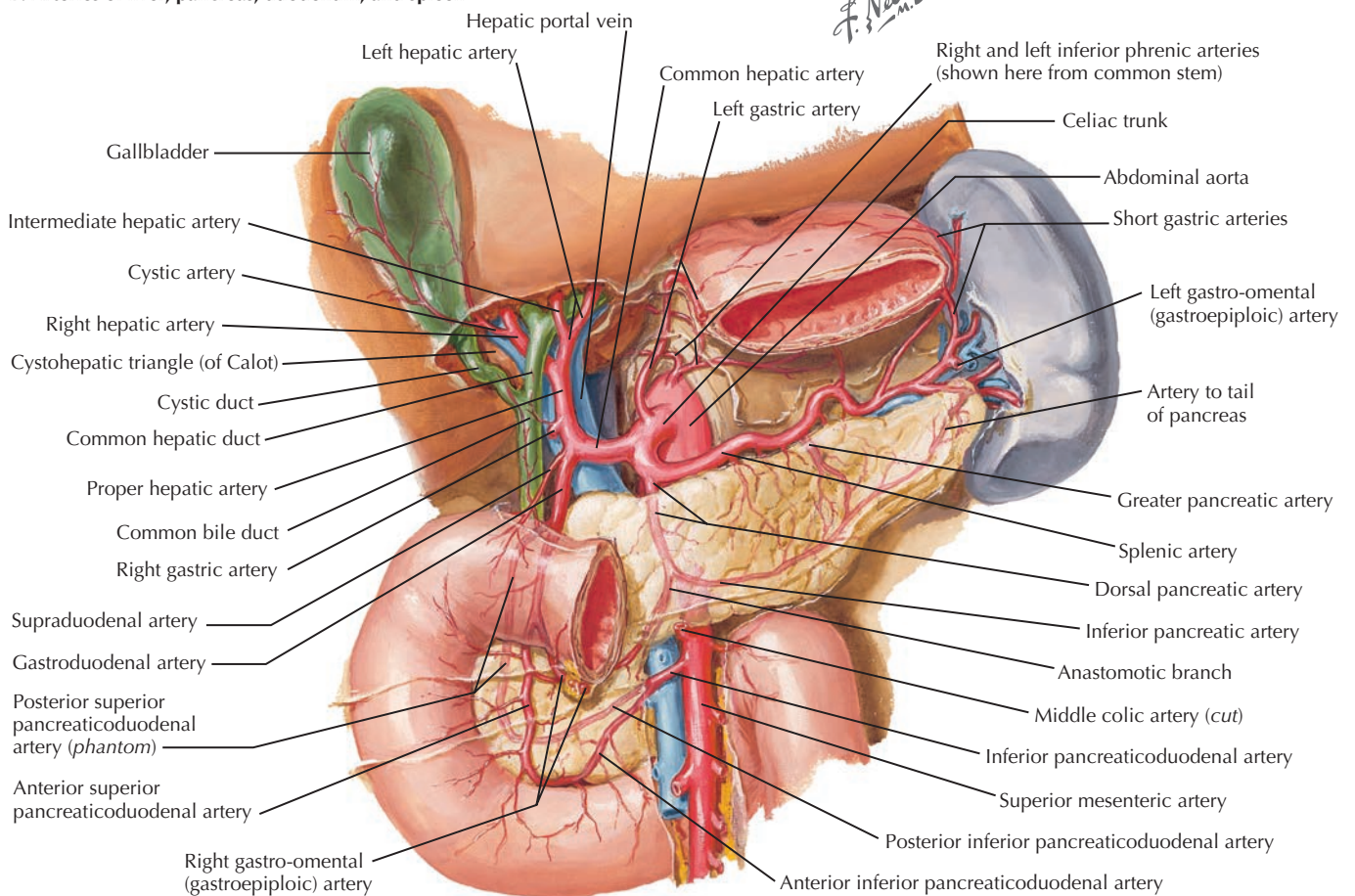


FIGURE 18-2 Suprahepatic aortic exposure during abdominal organ procurement.

Abdominal Surgical Approach—Cont'd

Once the arterial dissection is completed, the CBD is ligated proximally and transected. The gallbladder is opened and irrigated with saline irrigation, because bile remaining in the liver, ducts, or preservative solution during transportation can cause tissue damage.

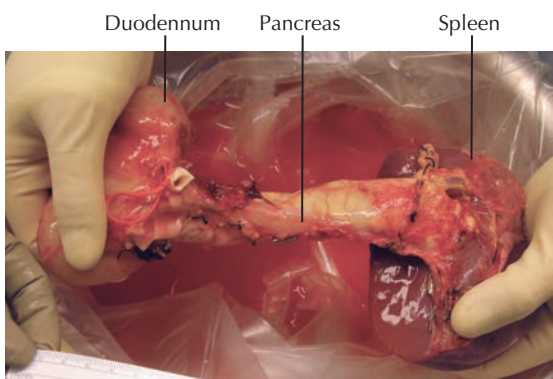
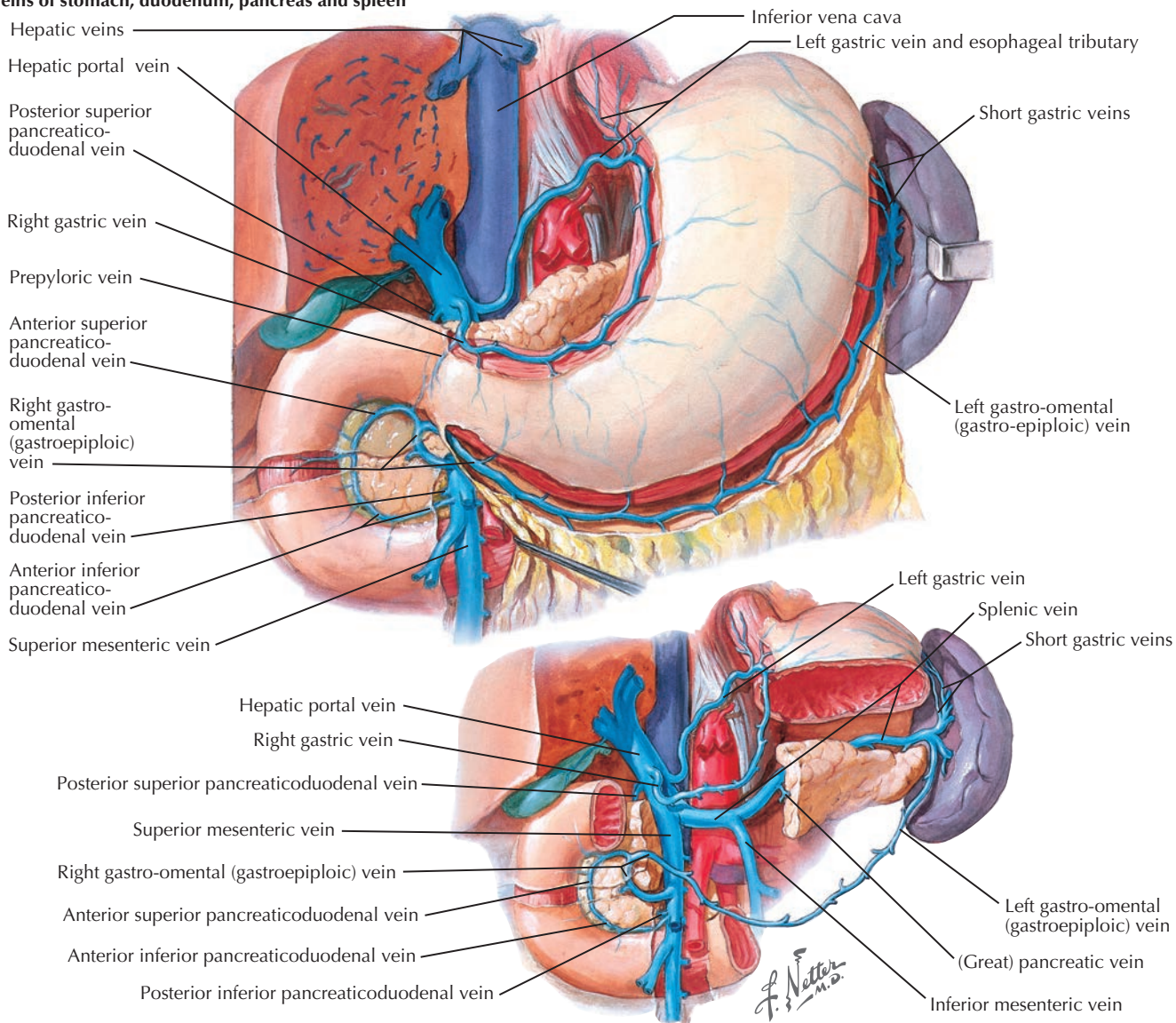
When the pancreas is also being recovered for transplant, the entire pancreaticoduodenal allograft is taken in continuity. The spleen is then mobilized in continuity with the tail of the pancreas. The maneuvers are identical to performing a distal pancreatectomy (see Chapter 15). Once completed, the jejunum just distal to the ligament of Treitz is divided. Some surgeons perform gut decontamination of the stomach and duodenum by flushing iodine solution down the nasogastric tube. The proximal duodenum is then divided distal to the pylorus. The vascular supply of the whole pancreaticoduodenal allograft consists of the portal vein, the SMA stump, and the splenic artery. These structures are left intact for engraftment (see [Pancreas Transplantation](#)). The reconstruction of the arterial system is performed at the backtable (backbench) by anastomosing the iliac artery conduit (from the same donor) limbs to the SMA and the splenic artery by the recipient surgeon.

After cross-clamping the aorta and retrograde flushing of the organs, the surgeon completes dissection of the vessels for all the allografts being retrieved. The IVC is mobilized from the intrapericardial IVC to the infrahepatic IVC proximal to the renal veins. The CHA is dissected to the celiac trunk with a Carrel patch from the aorta. A stump of splenic artery is left with the pancreas, and the gastroduodenal artery is divided. The portal vein can be mobilized to the confluence of the superior mesenteric vein (SMV) and IMV, and splenic vein if the pancreas is not being taken ([Fig. 18-3, A](#)). In cases of pancreas recovery, approximately 1 cm of portal vein is left with the pancreas allograft.

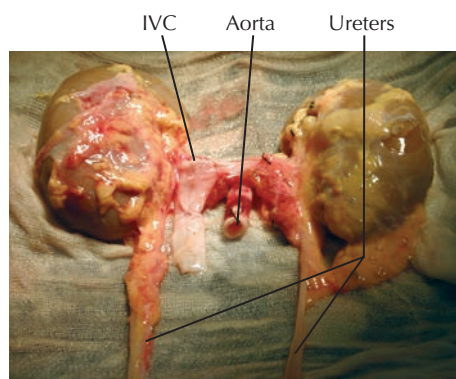
For pancreas recovery, the entire pancreaticoduodenal allograft containing the duodenal segment, the entire pancreas, and the spleen is removed, often en bloc with the liver ([Fig. 18-3, B](#)). The small bowel mesentery is divided and oversewn or stapled. The SMA is kept in continuity with the pancreas allograft, and the IMV is ligated.

The kidneys are removed after the other abdominal organs. Dissection of the ureters in the retroperitoneum is performed as distal as possible. The IVC is divided proximal to the bifurcation, and the aorta and IVC are dissected en bloc, protecting the renal arteries and veins. The kidneys are dissected and removed en bloc with the adrenal glands ([Fig. 18-3, C](#)).

A. Veins of stomach, duodenum, pancreas and spleen



B. El vivo pancreas allograft



C. El vivo kidney allograft

FIGURE 18-3 Pancreas and kidney procurement. IVC, Inferior vena cava; SMA, superior mesenteric artery; IMV, inferior mesenteric vein.

KIDNEY TRANSPLANTATION

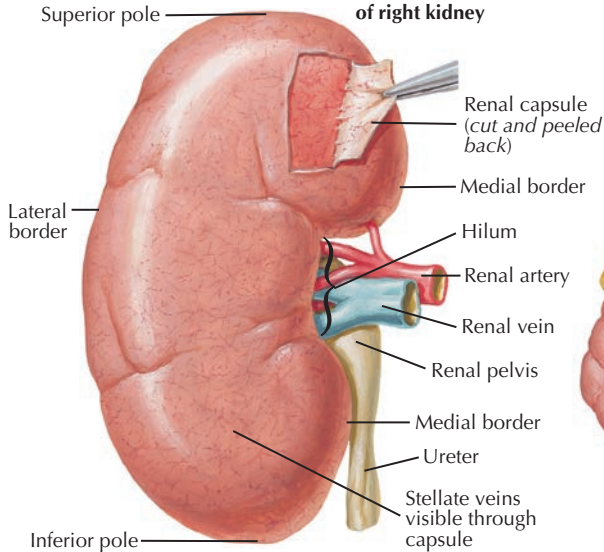
As the kidney transplant operation has evolved, different locations have been utilized. Although occasionally placed intraabdominally, especially if engrafted at the same time as a pancreas, kidneys are typically placed in the left or right retroperitoneal space at the iliac vessels. If these are unavailable or unusable, any appropriately sized inflow artery and outflow vein (e.g., aorta, IVC) may be used. Either the left or the right donor kidney may be placed on either side of the recipient. The donor ureter must be able to reach the bladder or urinary conduit. Because the donor ureter only obtains blood flow from the direction of the kidney, care must be taken to preserve that flow. High injuries to the donor ureter can be disastrous.

Kidney Surgical Approach

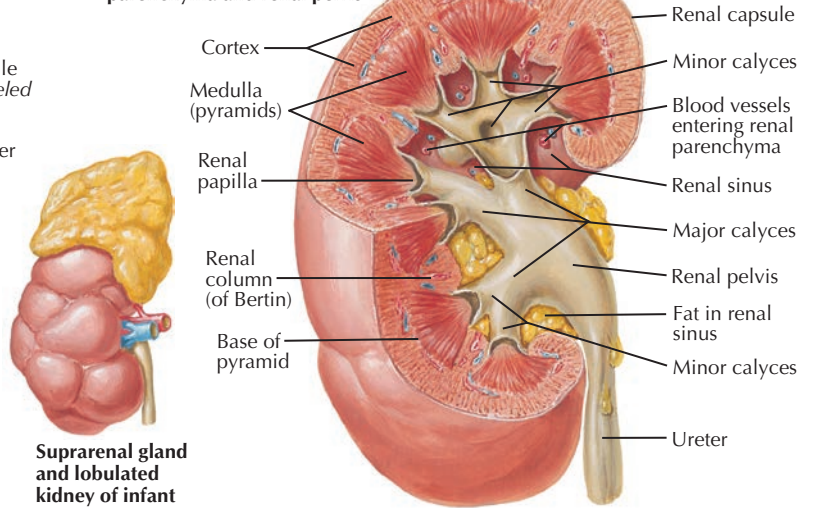
The kidney must be prepared for engraftment. *Backbenching* the kidney involves mobilizing the blood vessels and cutting away excess Gerota's fascia, the adrenal gland, and diaphragm. Living donor kidneys are often easier to backbench because most of these extra tissues are left in the recipient, although they will not have the aortic patch or IVC to use during anastomosis.

Classic renal anatomy includes single renal artery, renal vein, and ureter (Fig. 18-4, A), although multiple blood vessels can be present, and kidneys with duplicate ureters can still be used for transplant (18-4, B). If present, multiple arteries can be implanted on a common patch, joined together for a common anastomosis (Fig. 18-4, C), or implanted separately, depending on the distance between the vessels. Smaller accessory renal veins can be ligated because the venous system is collateralized within the kidney. For right kidneys, the donor IVC can be used as an extension, because the right renal vein can be very short. These reconstructions are often performed on the backbench.

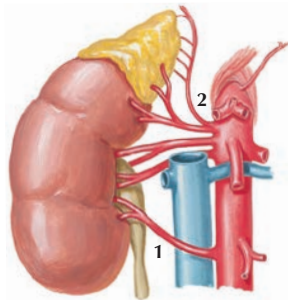
A. Gross structure of kidney



Right kidney sectioned in several planes, exposing parenchyma and renal pelvis

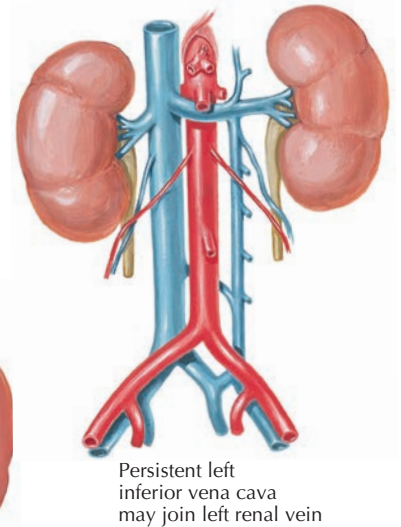
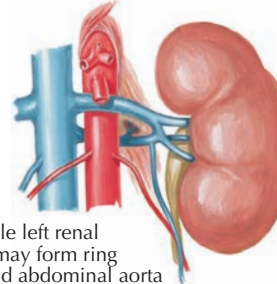
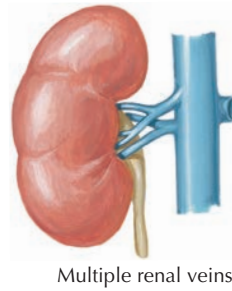
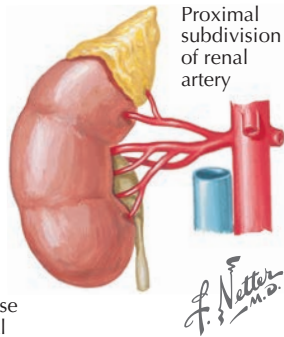


B. Renal vasculature: variations in renal artery and vein



1 Low accessory right renal artery may pass anterior to inferior vena cava instead of posterior to it

2 Inferior phrenic artery with superior suprarenal arteries may arise from renal artery (middle suprarenal artery absent)



C. Common anastomosis (arrow)

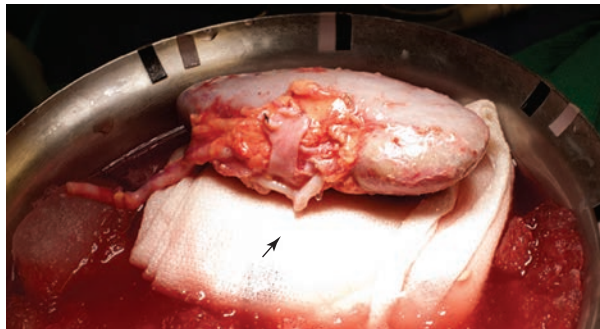


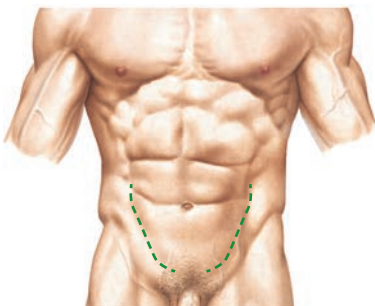FIGURE 18-4 Anatomic variations of kidney allograft.

Kidney Surgical Approach—Cont'd

The preperitoneal space is entered on the right or left side. Gibson's incision starts at the midline just over the pubis and is extended laterally to the edge of the rectus abdominis muscle sheath, at which point it follows the muscle's edge (Fig. 18-5, *A*). The fascial incision is made along the edge of the rectus abdominis muscle (18-5, *B*). Without entering the peritoneum, the surgeon develops plane between the peritoneum and the lateral abdominal wall, from the area above the bladder laterally and along the psoas muscle superiorly, exposing the external iliac artery and vein, as well as the spermatic cord in men (Fig. 18-5, *C*). The rectus abdominis muscle usually does not need to be divided and is retracted medially along with the spermatic cord. The vessels are exposed.

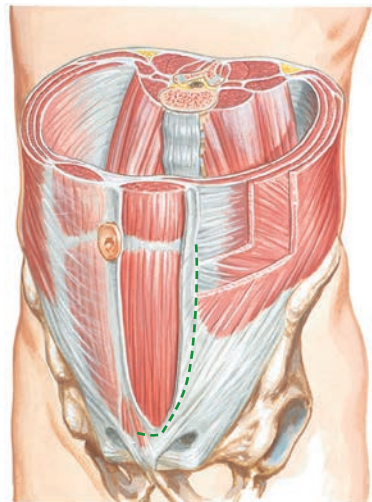
The venous anastomosis is usually performed first, followed by the arterial anastomosis (Fig. 18-5, *D*). Clamps are taken off the vein first. The renal artery is temporarily occluded, and the clamps are taken off the iliac artery. The renal artery occlusion is released, reperfusion of the kidney.

A. Gibson's incision

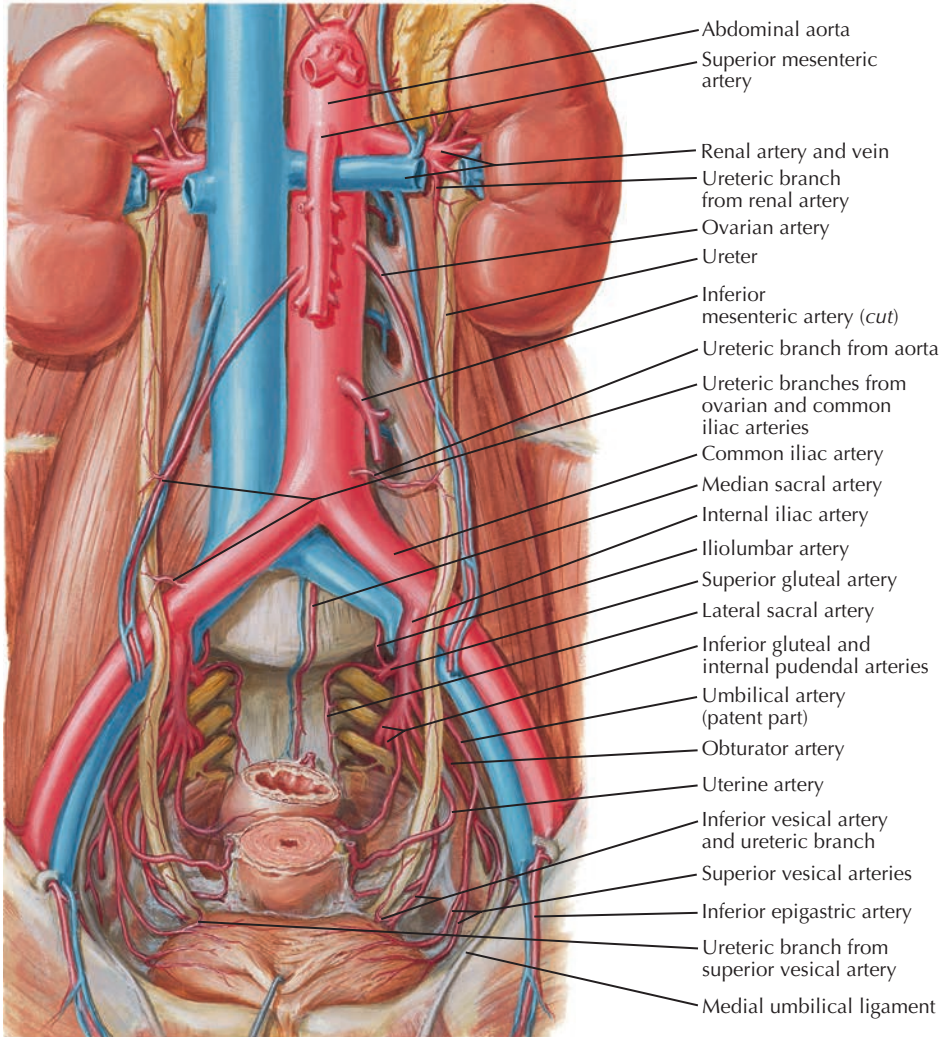


F. Netter M.D.
C. Machado M.D.

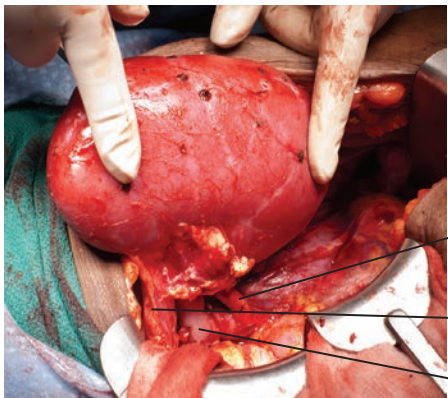
B. Fascial incision



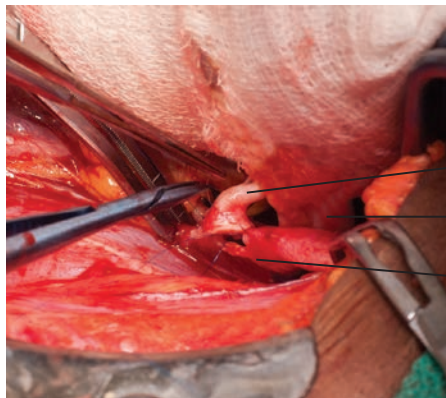
C. Arteries of ureters and urinary bladder



D. Arterial anastomosis



Renal artery
Ureter
Renal vein



Renal artery
Renal vein
External iliac artery

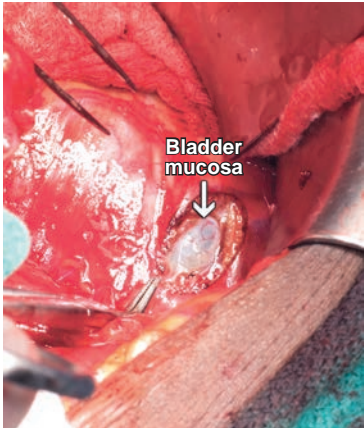
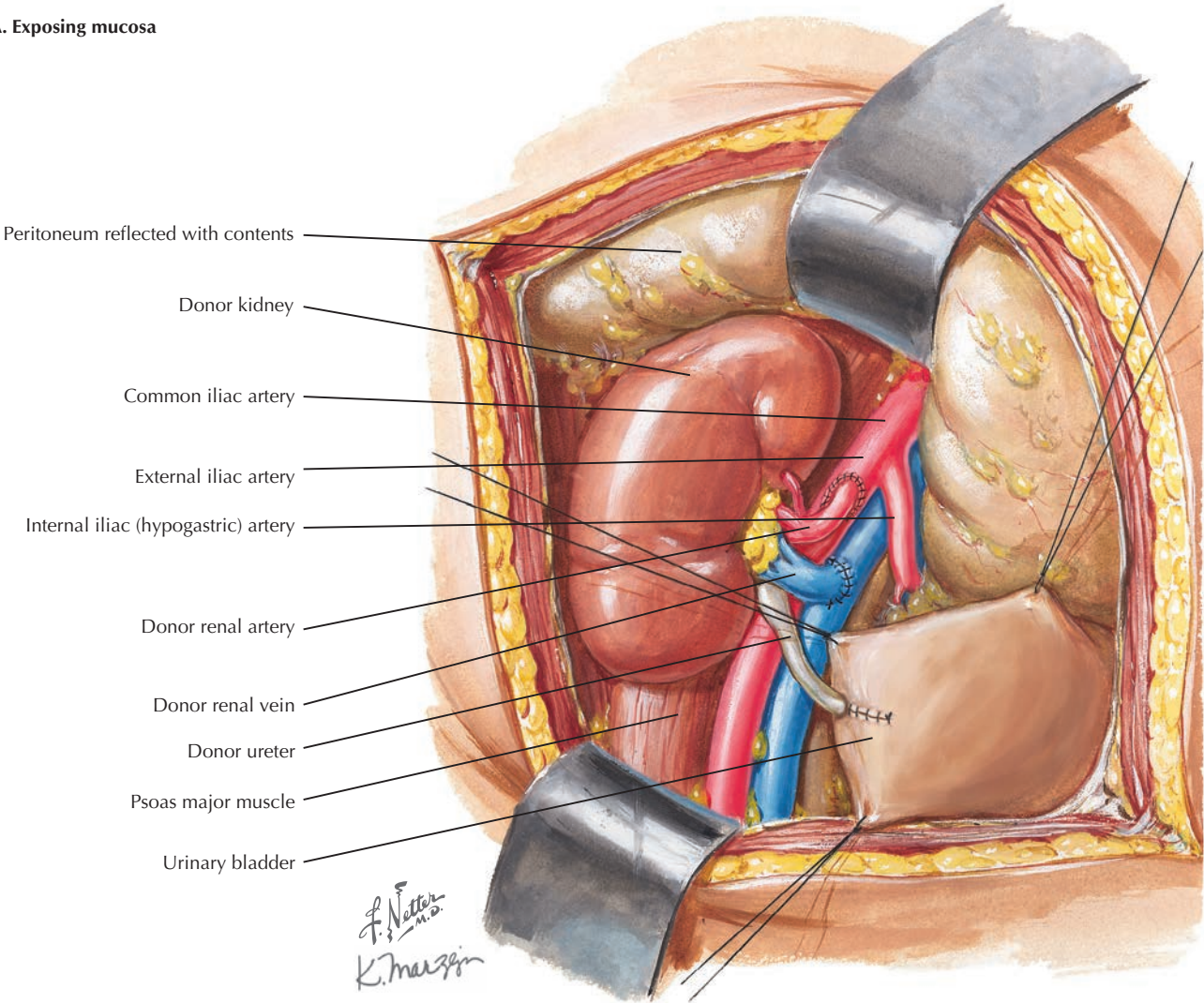
FIGURE 18-5 Vascular anastomoses of kidney allograft.

Kidney Surgical Approach—Cont'd

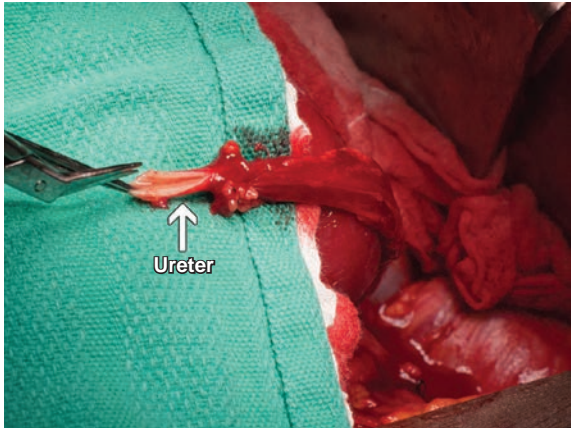
Once hemostasis is obtained, the bladder is distended in retrograde fashion and a 2-cm incision is made through the muscle layers of the bladder, exposing mucosa (Fig. 18-6, *A and B*). The ureter is cut to length and spatulated, and the surgeon performs a modified Lich-Gregoir ureteroneocystostomy with absorbable suture after creating a hole in the mucosa. A tunnel is then made over a portion of the anastomosis (Fig. 18-6, *C and D*).

Alternatively, primary uretero-ureterostomies (donor ureter to recipient ureter) can be performed instead. Often, the ureteroneocystostomy is performed over a double-J ureteral stent. Occasionally, a drain is placed. The kidney is placed laterally in the pocket created earlier, and the fascia is closed in one or two layers, depending on surgeon preference. Immunosuppression can impede healing, so Scarpa's fascia can also be closed with an absorbable suture, followed by skin.

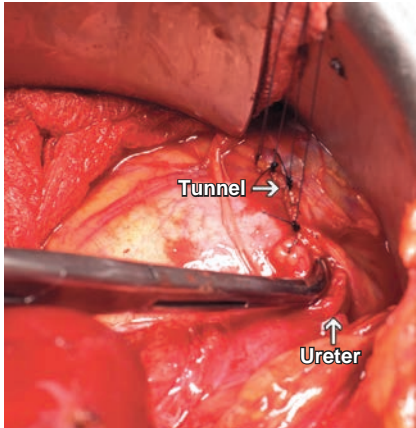
A. Exposing mucosa



B. Exposure of bladder mucosa



C. Distal transplanted ureter spatulation



D. Tunnel creation over ureteroneocystostomy

FIGURE 18-6 Ureteral anastomosis of kidney allograft.

PANCREAS TRANSPLANTATION

A pancreas transplant is done for patients with type 1 diabetes. Some centers have criteria to allow transplant for select patients with type 2 diabetes who have more of a type 1 physiology. Typically, a pancreas transplant is not done in isolation, but rather at the same time as a kidney transplant, or in a patient with an existing renal transplant.

The pancreas needs arterial inflow, venous outflow, and exocrine drainage. Several surgical approaches are available for placement and anastomosis. The pancreas can be placed in the retroperitoneum, similar to a kidney, although a transabdominal approach is most common. The arterial inflow typically comes from the iliac artery. Venous outflow can be systemic, via the iliac vein or IVC, or portal, via the SMV. Exocrine drainage is typically enteric—to the small bowel—although drainage of the donor duodenal remnant to the recipient duodenum or bladder can also be performed. If a kidney is already present, the pancreas is typically put on the other side. If not, it is typically put on the right, and the kidney can then be placed on the left. This section describes the systemic/enteric approach, which is the most straightforward.

Pancreas Surgical Approach

Proper backbench preparation of the pancreas is critical. During the procurement, the donor duodenum remains attached (see Fig. 18-2, B). The proximal end should be examined to ensure the pylorus is not present. The duodenum can be shortened to a reasonable length and the staple lines oversewn. The spleen is removed, with the splenic arteries and veins ligated at the tip of the tail of the pancreas. The bile duct should have been ligated during the donor procedure, which should be confirmed on the backbench. The blood vessels are mobilized. The portal vein should be long enough to allow visualization during anastomosis in the recipient. Infrequently, venous extension grafts may be needed to lengthen the vein. A Y graft, utilizing donor iliac artery bifurcation, is constructed, bringing the splenic artery and SMA onto the common trunk of the donor common iliac artery (Fig. 18-7).

If a kidney transplant will be performed at the same time, the kidney is prepared as well.

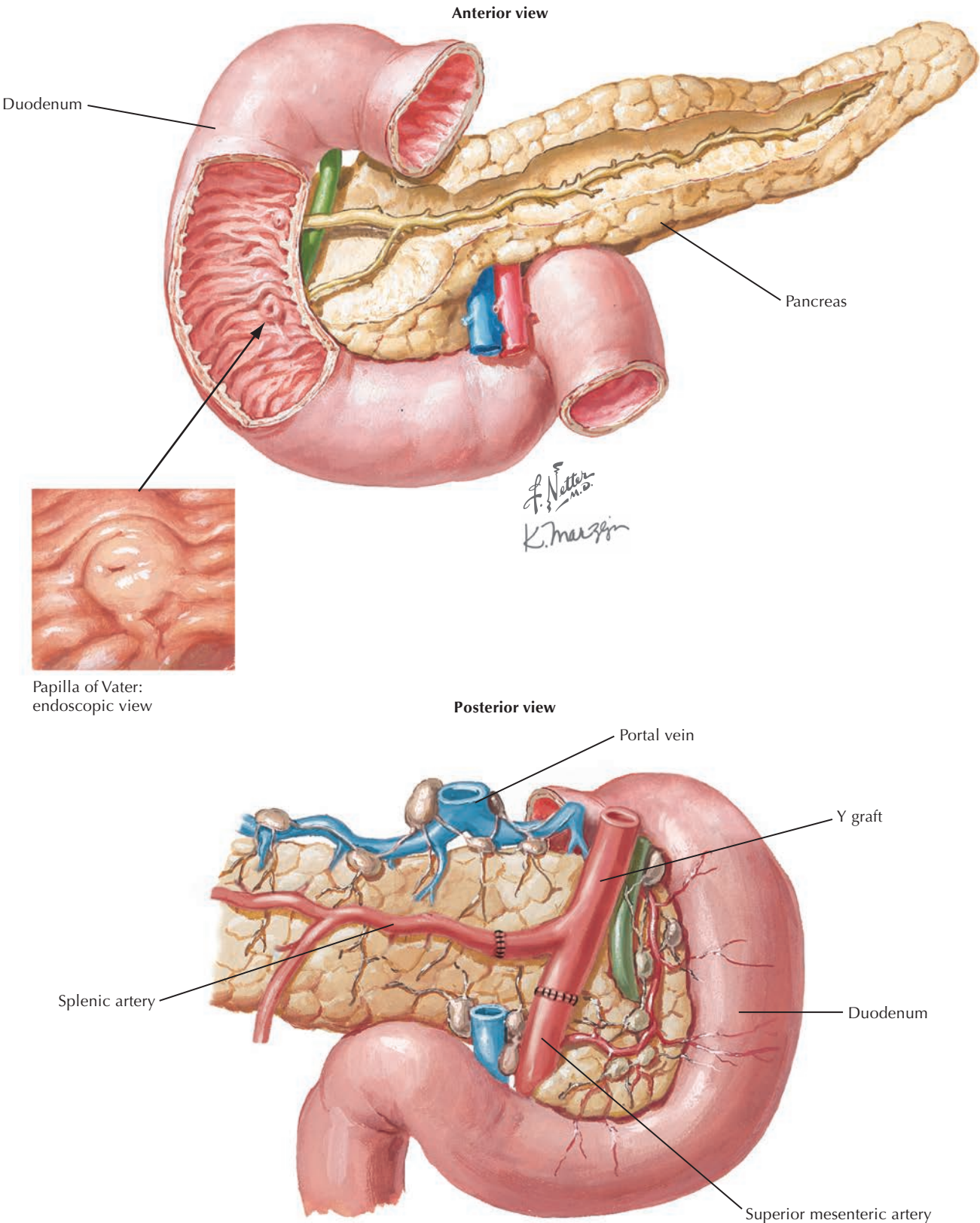


FIGURE 18-7 Arterial reconstruction for pancreas allograft.

Pancreas Surgical Approach—Cont'd

A midline incision is made and the retractors are placed. The surgeon mobilizes the cecum and right colon medially, taking care to avoid damaging the recipient ureter or duodenum. If needed, the pancreas can be placed on the left as well. The iliac vein and distal IVC are exposed, as well as the common iliac artery. If portal drainage is planned instead, the SMV is exposed at this time (Fig. 18-8).

For standard systemic and enterically drained pancreata, the tail of the pancreas is placed superiorly, with the duodenum facing the pelvis. Vascular anastomoses are performed in a similar manner to the kidney transplant, as previously described. Typically, the distal IVC or proximal common iliac vein is used, and the anastomosis to the donor portal vein is performed, followed by the anastomosis of the donor artery Y graft to the recipient common iliac artery. The venous clamp is removed first, followed by the arterial clamps, and reperfusion is complete.

Once hemostasis has been obtained, the donor duodenum needs to be connected to the bowel or bladder. Most often, a side-to-side duodenoenterostomy is performed, typically to a segment of small bowel away from the terminal ileum or to a Roux-en-Y ileal limb. Anastomosis of the donor duodenum to the bladder was performed frequently in the past but is rarely done at present, because of the metabolic and infectious complications of such exocrine drainage from the bicarbonate loss.

Once the pancreas is complete, the kidney is placed on the other side, if a simultaneous transplant is planned. Care must be taken to avoid excessive retraction on the pancreas transplant during kidney placement. Although the technique for kidney placement is modified somewhat (left and sigmoid colon segments are mobilized), because it is intraabdominal, the approach is essentially the same as described for kidney transplant. The midline incision is closed in the standard manner.

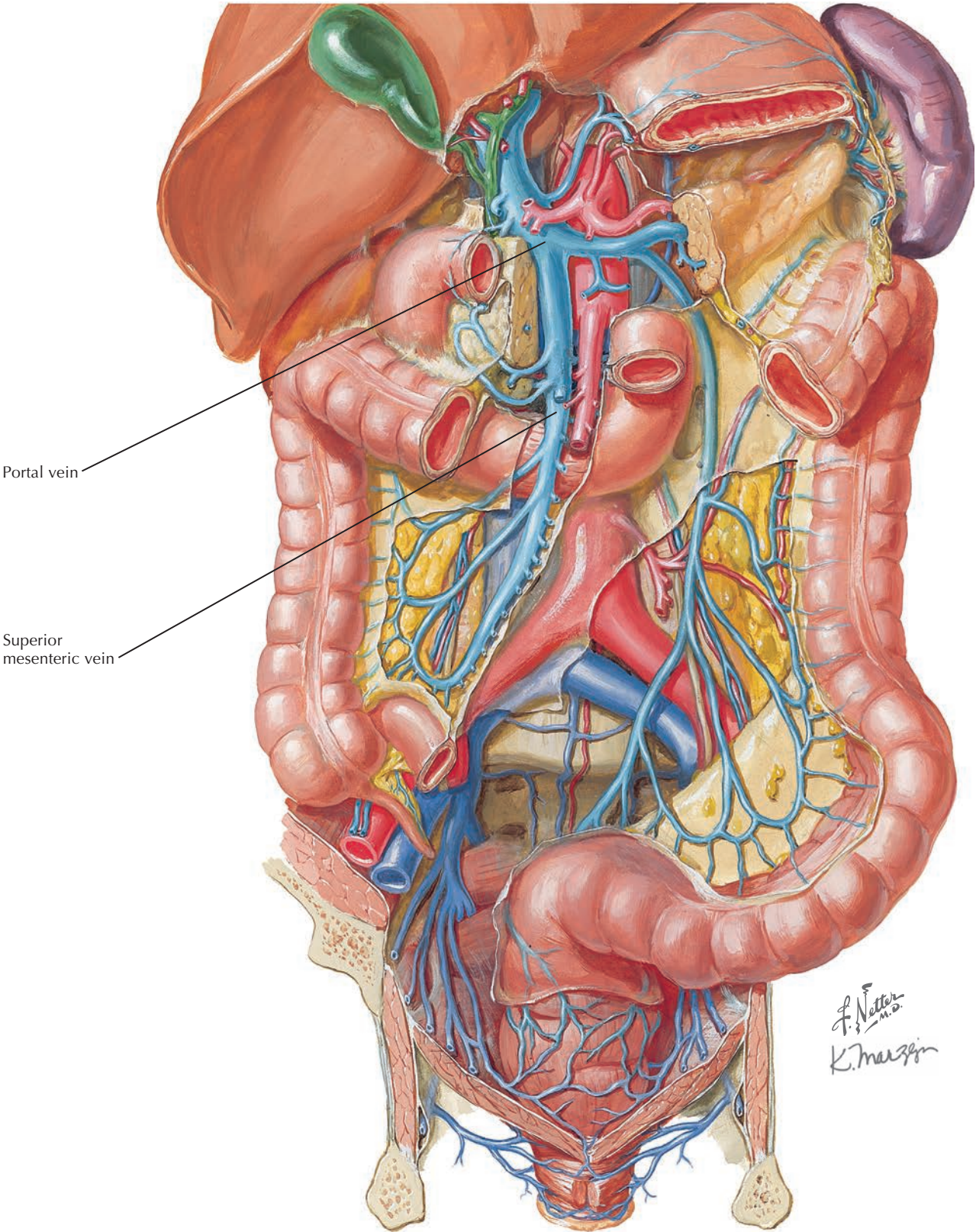


FIGURE 18-8 Superior mesenteric vein anatomy for portal drainage of pancreas allograft.

LIVER TRANSPLANTATION

One of the mainstays of treatment of end-stage liver disease and hepatocellular carcinoma is liver transplantation (Fig. 18-9). Other common indications for liver transplant include viral hepatitis, alcoholic cirrhosis, autoimmune liver diseases (primary biliary cirrhosis, primary sclerosing cholangitis), and nonalcoholic fatty liver disease. Adult and pediatric liver transplant is considered treatment for appropriate liver tumors and end-stage liver disease of varied etiology. Overall patient survival rate is greater than 85% at 1 year, with a 5-year survival rate of 60% to 70%.

Liver transplant surgery essentially restores or creates venous drainage for the liver allograft and reestablishes portal, arterial, and biliary continuity. Postoperative surveillance of vascular patency is easily done with Doppler ultrasound. More detailed imaging can be performed with computed tomographic or magnetic resonance angiography or conventional arteriography, as needed. The biliary anatomy can be imaged using magnetic resonance cholangiopancreatography, endoscopic retrograde cholangiopancreatography (ERCP), or percutaneous transhepatic cholangiography, depending on the reconstruction technique.

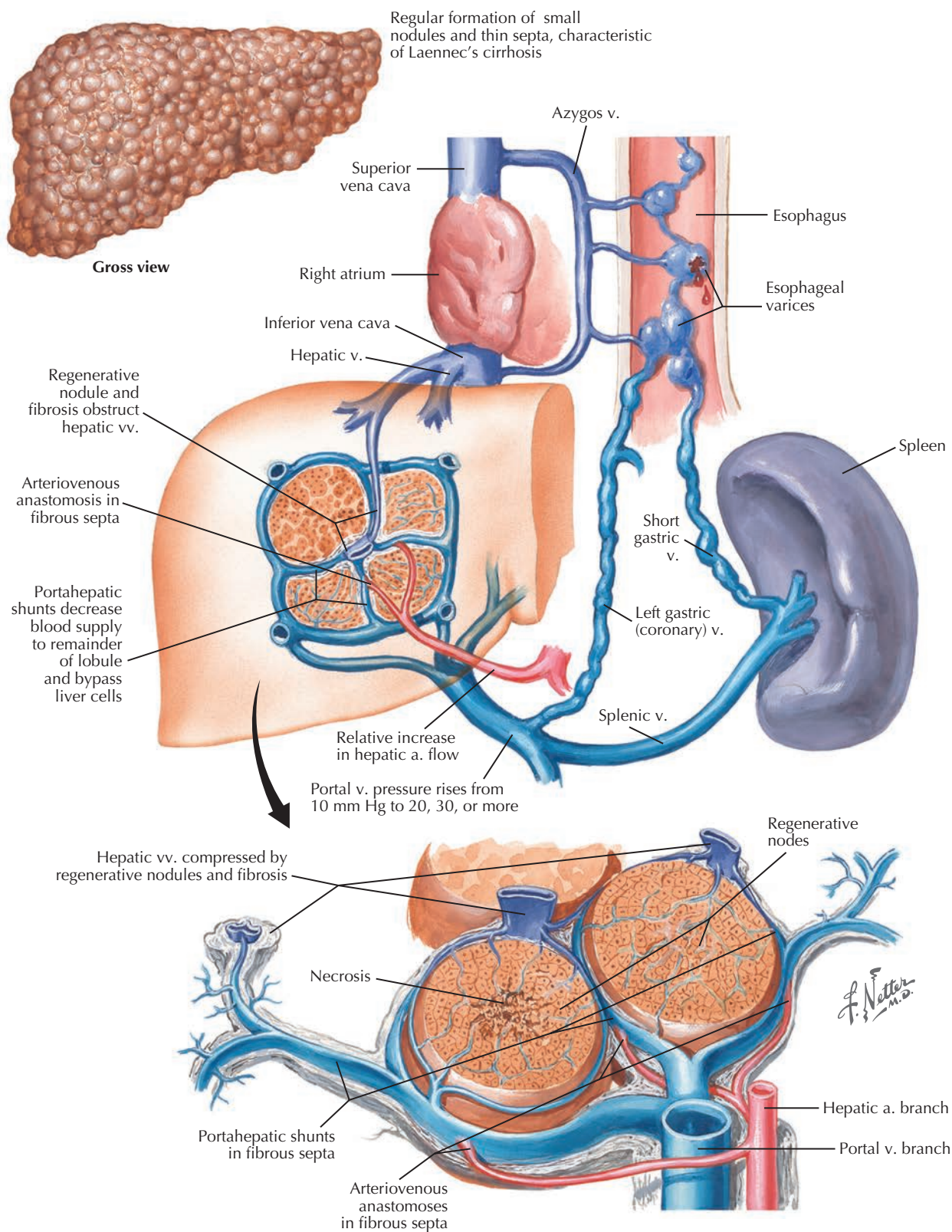


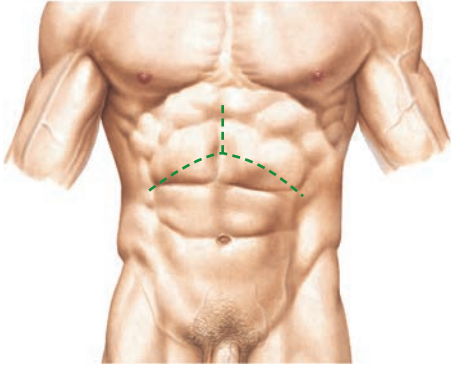
FIGURE 18-9 End-stage liver disease.

Liver Surgical Approach

Orthotopic liver transplant (OLT) dissection focuses on the IVC and portal triad. The liver transplant surgeon must be familiar with many anatomic variations. There are two exposure goals for the liver transplant incision (Fig. 18-10, A). First, the most cephalad extent of the incision must allow the surgeon to visualize and gain access to the suprahepatic IVC. Second, the right, most lateral extent of the incision must allow the surgeon to visualize and gain access to the infrahepatic IVC. The left subcostal extension can often be omitted, especially in patients with large ascites or in small donor liver allograft implantation.

Mobilization of the left and right lobes of the liver is performed (Fig. 18-10, B). The left and right triangular ligaments, ligamentum teres, and falciform ligaments are all divided. The falciform can contain significant collateral vessels (i.e., recanalized umbilical vein) and should be controlled before division. At this time, a retractor (Omni, Thompson, or Bookwalter) can be applied to maintain cephalad subcostal retraction.

A. Liver transplant incision



F. Netter M.D.
C. Machado M.D.

B. Surfaces and bed of liver

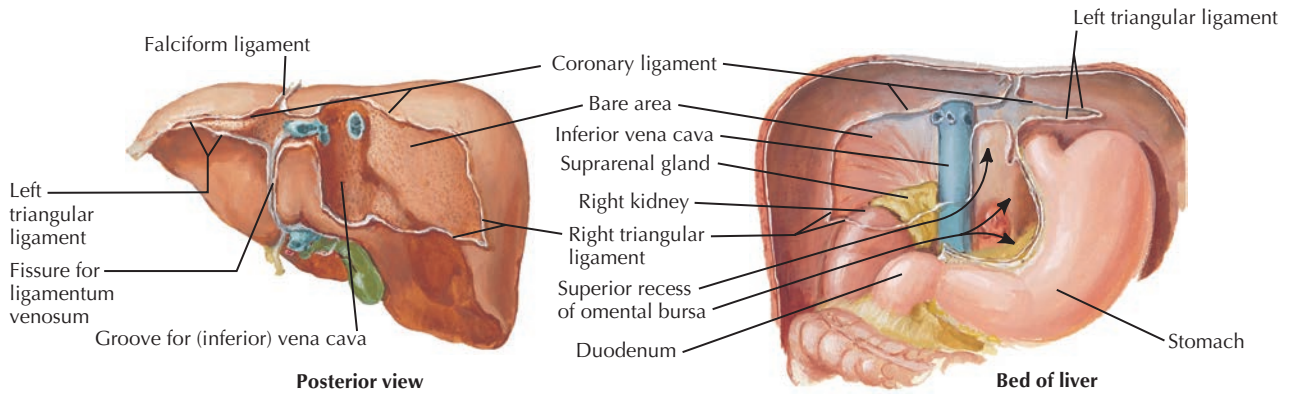
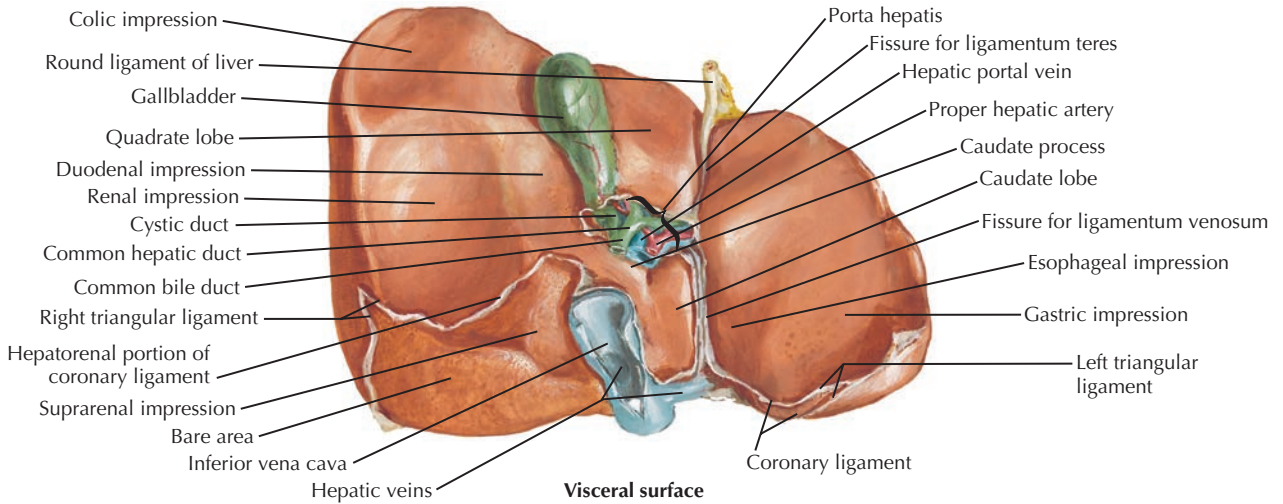
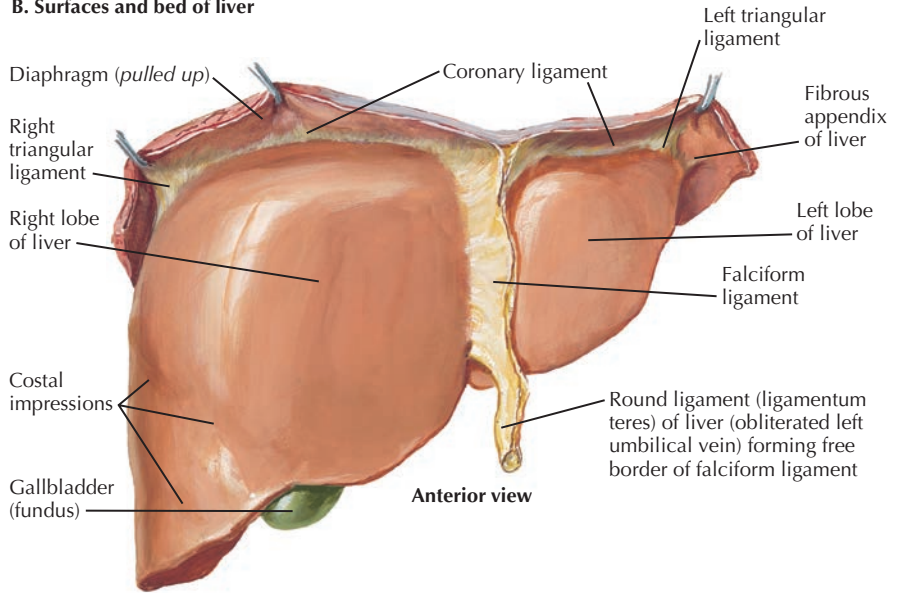


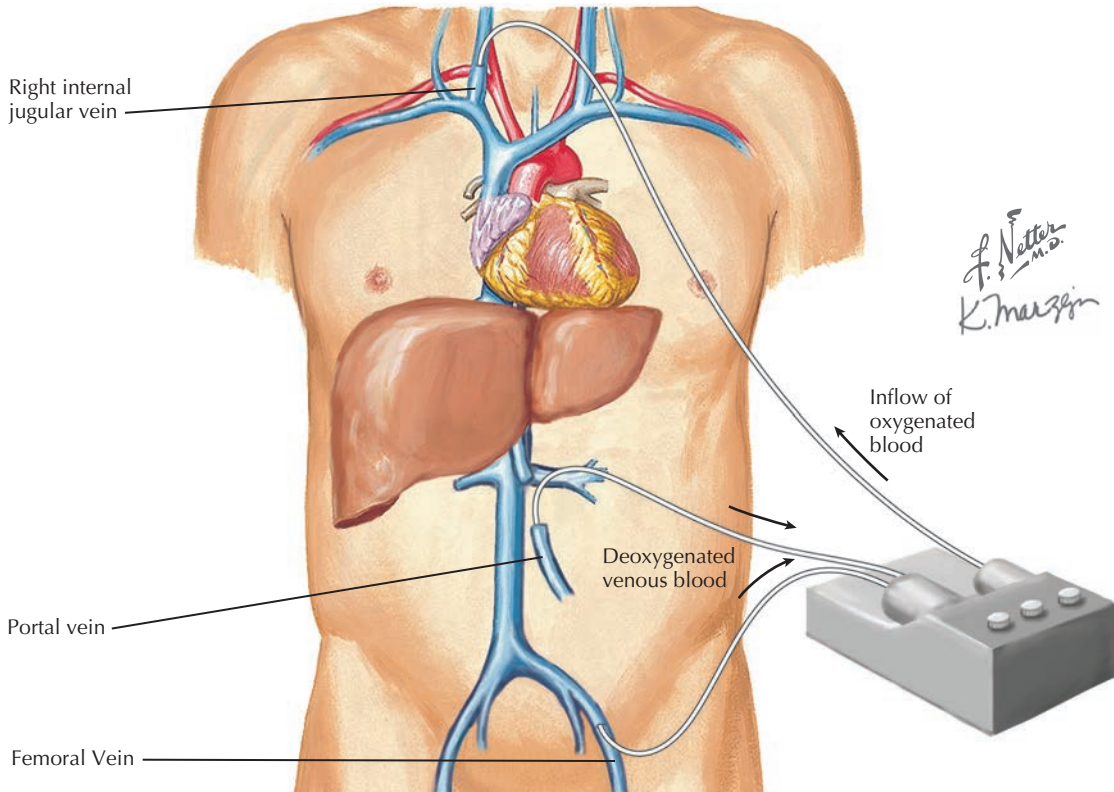
FIGURE 18-10 Liver anatomy.

Liver Surgical Approach—Cont'd

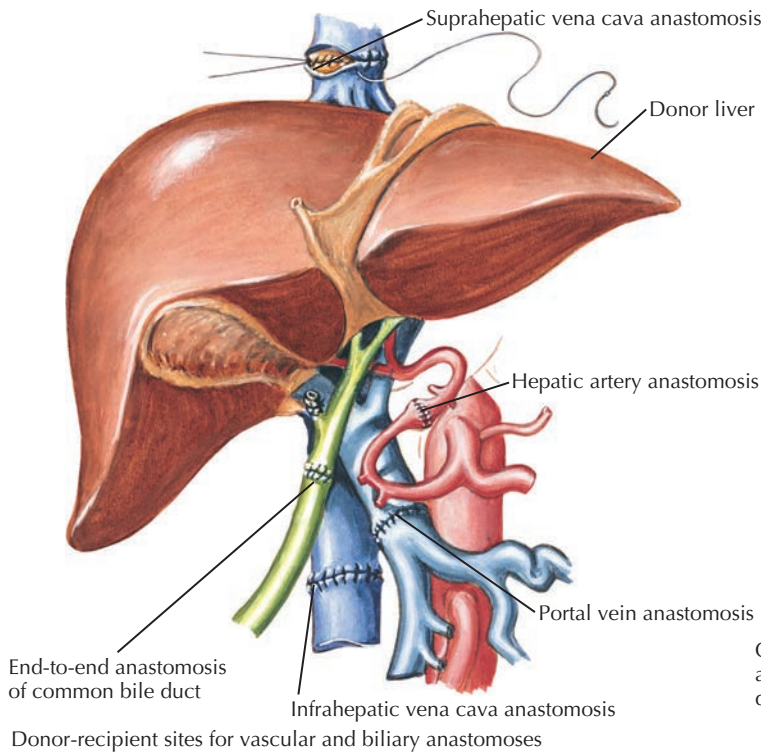
The portal triad is dissected out carefully (see Fig. 18-2, *B*). There are multiple small collateral vessels that form as a result of portal hypertension, especially with portal vein thrombosis. The main structures (hepatic arteries, common hepatic or common bile duct, portal vein) are dissected out and divided at the most cephalad position possible, to preserve length of these structures in the recipient. Similar to the donor surgery, a left accessory or right replaced hepatic artery must be identified (see Fig. 16-3). At this point, venovenous bypass is an option (Fig. 18-11, *A*).

Once the portal vein is divided, this allows the surgeon to mobilize fully the right and left lobes of the liver. The portal vein can be cannulated and drained into the venovenous bypass circuit, or a temporary end-to-side portocaval shunt can be performed to minimize portal congestion during the implantation of the liver allograft. The retrohepatic dissection is completed to allow placement of clamps for the caval interposition technique. Otherwise, the anterior surface of the retrohepatic IVC (see Fig. 18-1) is cleared by dividing the small vessels between the IVC and the posterior surface of the liver, completing mobilization of the liver up to the level of the hepatic veins.

A. Schematic of venovenous bypass



B. Completed liver transplant, with bicaval anastomosis and choledochocholedochotomy



C. Roux-en-Y choledochojejunostomy

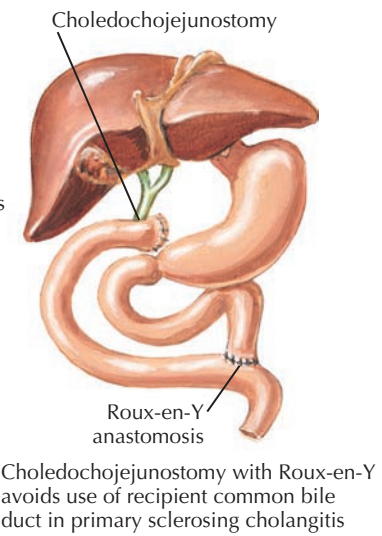


FIGURE 18-11 Liver surgical approaches and completed transplant.

Liver Surgical Approach—Cont'd

Once completed, the final anastomoses in a liver transplant restore continuity in the vena cava, hepatic artery, portal vein, and biliary drainage. The first vascular anastomosis in the liver transplant is performed to reestablish vena caval outflow. This anastomosis can be accomplished in one of three ways: caval interposition (Fig. 18-11, B), piggyback anastomosis (Fig. 18-12, A), or side-to-side cavocavostomy (Fig. 18-12, B). The portal vein is typically reconstructed after caval reconstruction. The portal vein anastomosis is done in an end-to-end fashion, using a growth knot.

The arterial management can be done in a number of ways, mostly by using the proper or common hepatic artery of the recipient as the inflow source (see Fig. 18-11, B). Because of the number of variations in the hepatic artery, the inflow can sometimes be created by using an alternate artery or even by using an arterial conduit originating from the supraceliac or infrarenal aorta (Fig. 18-12, C-E). The arterial anastomosis can be completed before or after reperfusion of the portal vein.

Once the portal or arterial anastomoses are completed, reperfusion can occur. The vena caval and hepatic vein clamps are removed first. The portal and arterial clamps are then removed to reperfuse liver completely. Portal reperfusion is done slowly, to allow for thermal accommodation and to maintain hemodynamic stability. Reperfusion can be associated with cardiac arrest and significant hypothermia if done too quickly.

The duct anastomosis in the liver transplant surgery is usually straightforward. Most cases require a primary end-to-end duct-to-duct anastomosis (choledochocholedochostomy). Primary sclerosing cholangitis patients almost always require a Roux-en-Y choledochojejunostomy (Fig. 18-11, C), because of potential disease in the remnant recipient ducts, which can cause biliary obstruction later. Once hemostasis is obtained, drains can be placed, and the incision is closed in the standard fashion.

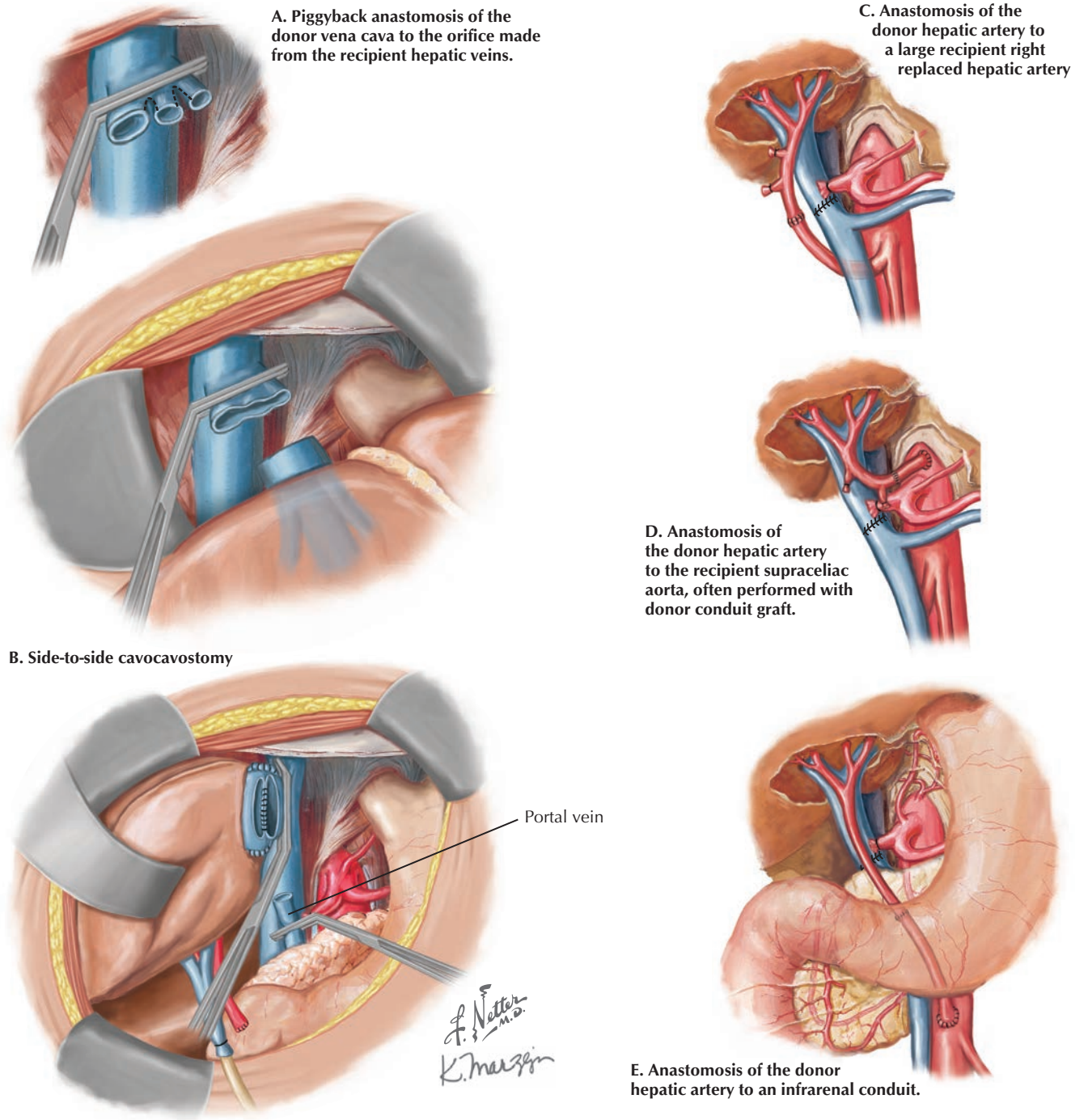


FIGURE 18-12 Anastomoses in liver transplant.

SUGGESTED READINGS

- Demartines N, Schiesser M, Clavien PA. An evidence-based analysis of simultaneous pancreas-kidney and pancreas transplantation alone. *Am J Transplant* 2005;5:2688-97.
- Kelly WD, Lillehei RC, Merkel FK, Idezuki Y, Goetz FC. Allograft transplantation of the pancreas and duodenum along with the kidney in diabetic nephropathy. *Surgery* 1967;61:827-37.
- Mazzaferro V, Regalia E, Doci R, et al. Liver transplantation for the treatment of small hepatocellular carcinomas in patients with cirrhosis. *N Engl J Med* 1996;334:693-699.
- Merion RM, Ashby VB, Wolfe RA, et al. Deceased-donor characteristics and the survival benefit of kidney transplantation. *JAMA* 2005;294:2726-33.
- Moers C, Smits JM, Maathuis MH, et al. Machine perfusion or cold storage in deceased-donor kidney transplantation. *N Engl J Med* 2009;360:7-19.
- Murray JE, Merrill JP, Harrison JH. Renal homotransplantation in identical twins. *Surg Forum* 1956;6:432-6.
- Starzl TE, Marchioro TL, von Kaulla KN, et al. Homotransplantation of the liver in humans. *Surgery* 1963;117:659-76.

Appendectomy



Mark L. Manwaring

INTRODUCTION

More than 280,000 appendectomies are performed annually in the United States. First described as a treatment for appendicitis by Reginald Fitz in 1886, appendectomy has become the standard of care because of its efficacy and low morbidity. Thorough knowledge of the diagnostic evaluation, preoperative considerations, operative decision making, anatomy, and technique for appendectomy is critical for every trainee and abdominal surgeon.

ANATOMIC PRINCIPLES OF DIAGNOSIS AND EVALUATION

There is considerable variation in the clinical presentation of appendicitis. The classic patient presents with several hours of periumbilical pain that “migrates” to the right lower abdomen, with associated anorexia. The migration of the pain is mediated by the separate innervation of visceral and parietal tissues. Appendiceal obstruction and inflammation, which occur early in the process, cause irritation of autonomic visceral afferent nerves of the superior mesenteric ganglion that result in a nonspecific, poorly localized epigastric or periumbilical pain, secondary to the location and lack of specificity of the autonomic ganglion (Fig. 19-1). Ileus, nausea, anorexia, and diarrhea may also be mediated in this manner. Once inflammation reaches parietal surfaces of the peritoneum (e.g., through perforation), somatic sensory fibers create localized pain in the right lower quadrant (RLQ) with findings of peritonitis, including rigidity, distention, and hyperesthesia.

Examination of the patient with appendicitis may further localize inflammation and determine the stage of the diagnosis. Tenderness in the RLQ at McBurney’s point is typical. Well-recognized signs include RLQ pain on palpation of the left abdomen (Rovsing’s sign) and internal rotation of the right hip resulting in motion of deep pelvic musculature, which can cause pain in the case of pelvic appendicitis (obturator sign). Pain with extension of the right hip is caused by motion of the psoas muscle posterior to the cecum (psoas sign) (Fig. 19-2, A).

Although the diagnosis of appendicitis may often be made with physical examination alone, computed tomography (CT) has been increasingly used for the evaluation of patients with appendiceal pathology because of its high sensitivity and specificity. Coronal and sagittal reconstructions provide excellent anatomic detail that is useful in surgical planning (Fig. 19-2, B and C).

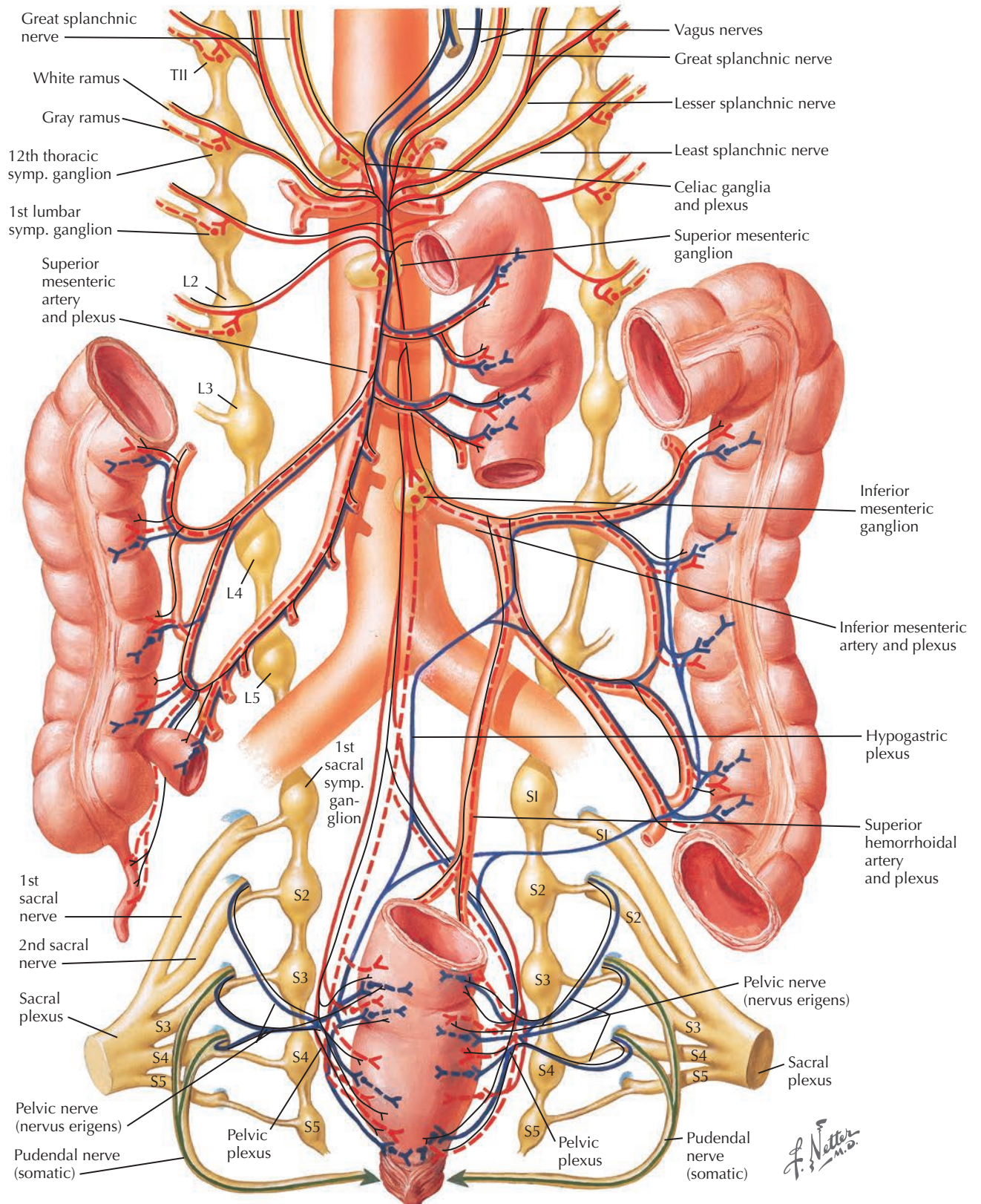


FIGURE 19-1 Autonomic innervation of the intestine. *Symp.*, Sympathetic; T11, 11th thoracic.

SURGICAL PRINCIPLES

Exposure

When the laparoscopic approach is used, placing the patient in a left-side down, Trendelenburg position aids laparoscopic visualization by employing gravity to retract intestinal structures away from the RLQ and cecum. The small intestine can be manipulated manually into the left upper quadrant to prevent injury and aid in visualization. The greater omentum often wraps the ileocecal area, localizing the infectious process to the right lower quadrant. Blunt dissection using an atraumatic laparoscopic instrument with gentle traction can mobilize the omentum away from the cecum, revealing the appendix. The challenges of dissection in appendectomy are typically related to inflammatory changes that make the appendix adherent to inflamed surrounding tissues. Again, blunt dissection in this setting is most effective for safely separating inflamed tissues. If a neoplastic process is suspected, however, an en bloc open resection is indicated.

In the open setting, incision length and type should allow adequate visualization of the critical anatomy. The choice of incision should be based on the patient's body habitus, previous surgical sites, physical examination findings, preoperative imaging, and surgeon preference. Use of small, handheld Richardson or appendiceal retractors is standard practice when an RLQ *Rocky-Davis* (transverse) or *McBurney* (oblique) incision is used. Retrocecal appendicitis may also be approached in this manner, although a somewhat longer incision is often required to mobilize the cecum adequately for appendectomy. When the surgeon uses an open approach, patients with perforated appendicitis, generalized peritonitis, or those with suspected neoplastic processes may best be approached with the use of a standard midline laparotomy.

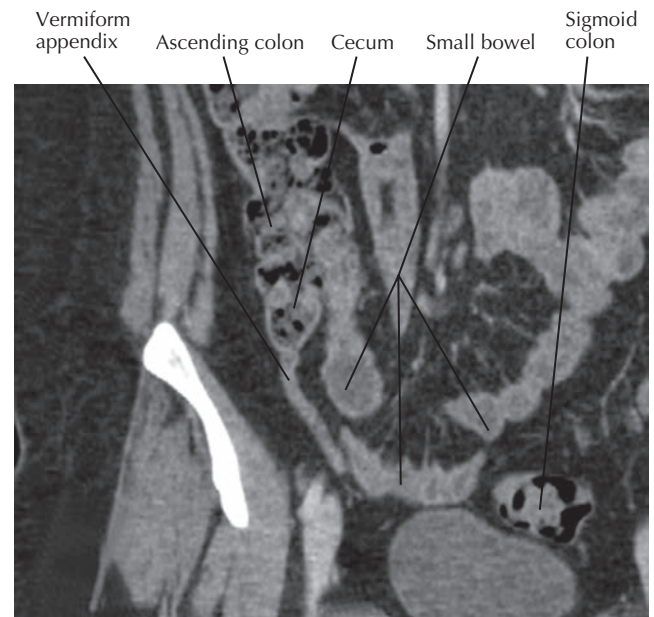
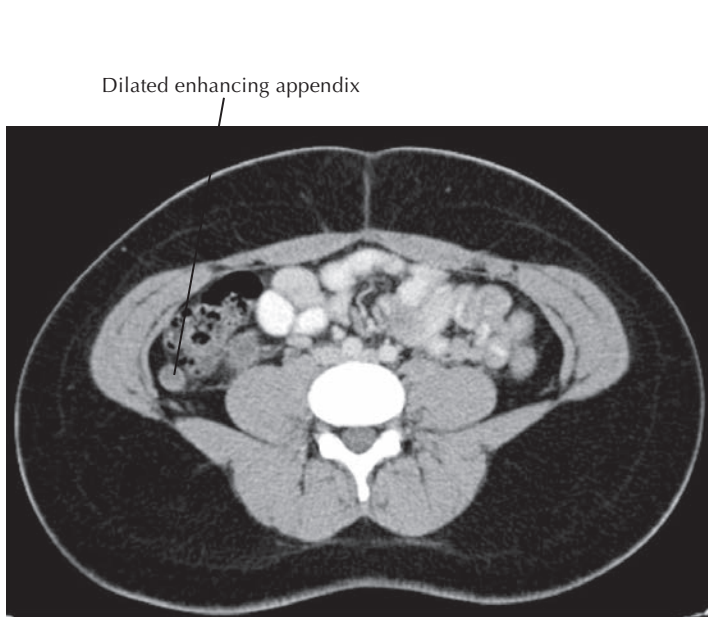
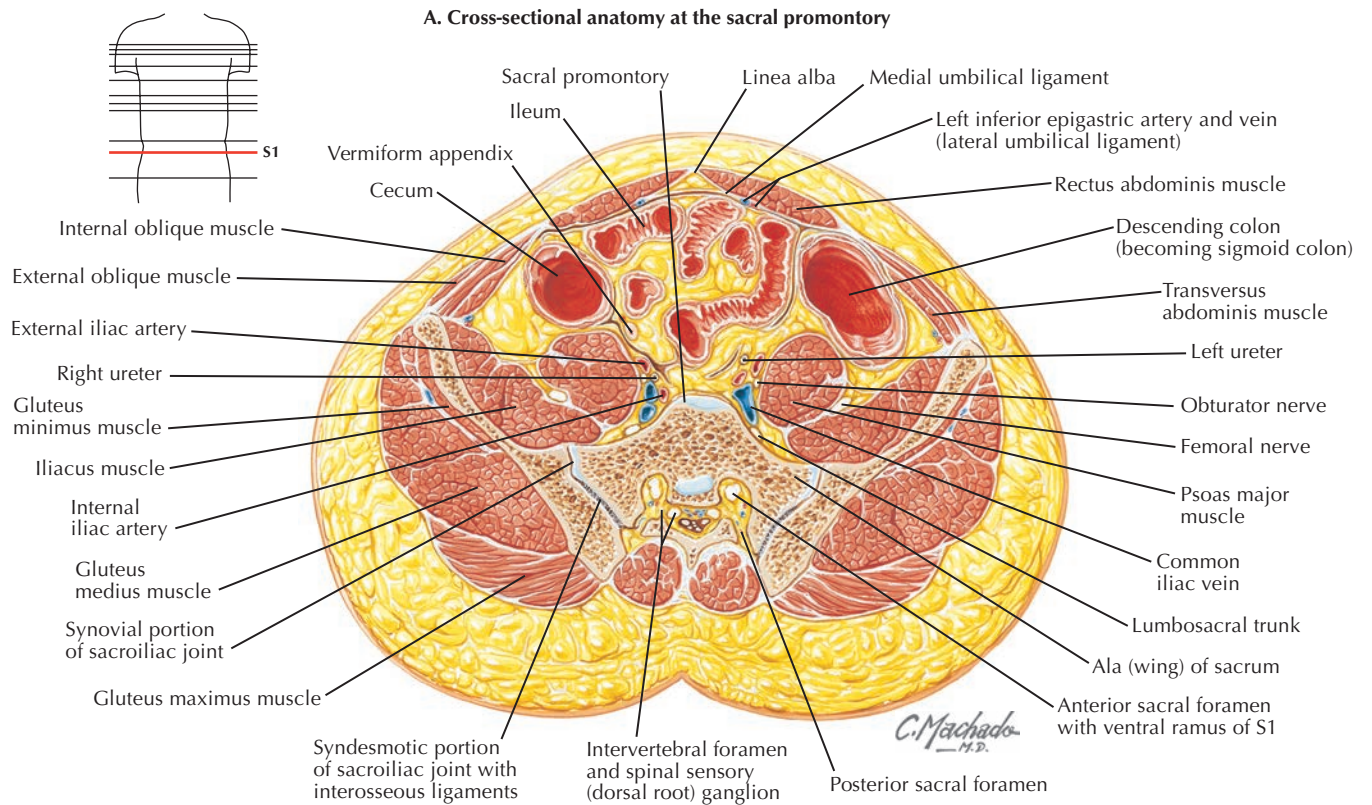


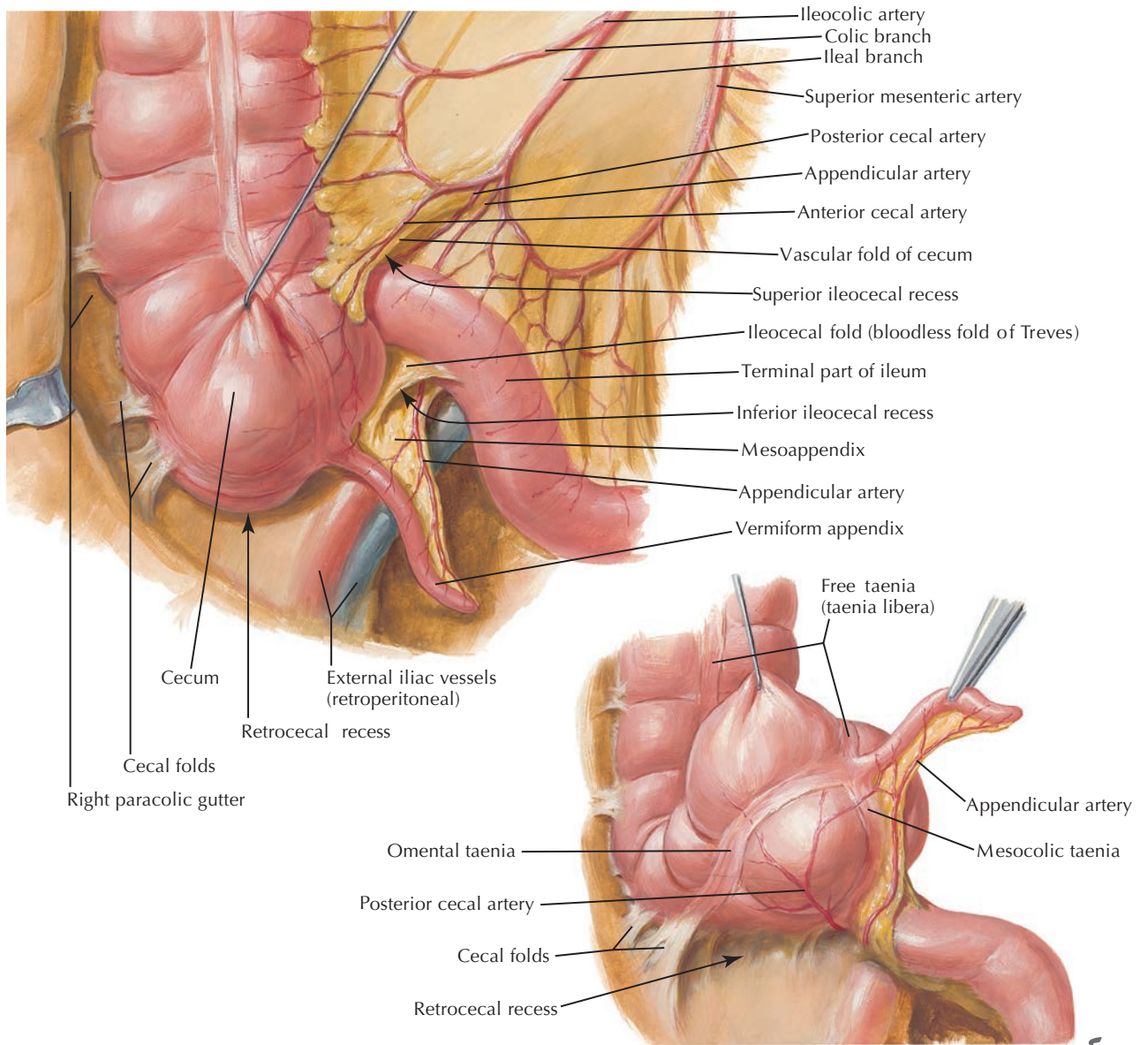
FIGURE 19-2 Cross-sectional periappendicular anatomy. CT, Computed tomography; S1, 1st sacral vertebra.

Operative Anatomy

The appendix is a tubular organ located at the base of the cecum; it begins invariably at the fused origin of the taenia coli. The appendix varies considerably in length and orientation relative to the cecum (Figs. 19-3 and 19-4). The appendix receives its blood supply from the appendiceal artery, a terminal branch of the ileocolic pedicle supplied by the superior mesenteric artery. The appendiceal artery travels posterior to the terminal ileum and into the meso-appendix (Fig. 19-5).

The terminal ileum joins the cecum at the ileocecal valve and generally lies medial to the appendiceal base (Fig. 19-6, *A*). The ureter lies within the retroperitoneum and is usually located medial to the appendix, although it must be considered when dissection in the region is performed. The appendix often courses over the right iliac vessels into the pelvis (Fig. 19-6, *B*). Laparoscopically, relational anatomy must be conceptualized because wide visualization can be limited; Figure 19-7 shows a laparoscopic depiction of the relevant anatomy.

Identification of the appendiceal base and full resection of length of the appendix are critical to avoid partial appendectomy. Complete appendectomy prevents recurrent infection of the appendiceal stump. In addition, ligation in an area of healthy tissue away from appendiceal inflammation is necessary to ensure safe closure of the cecum. Full dissection of the appendix along its course, followed by firm but atraumatic traction on the appendix, can aid in directing dissection to allow visualization of the base of the appendix. Before division, the terminal ileum, base of the cecum, and retroperitoneum should be identified and preserved.



Some variations in posterior peritoneal attachment of cecum

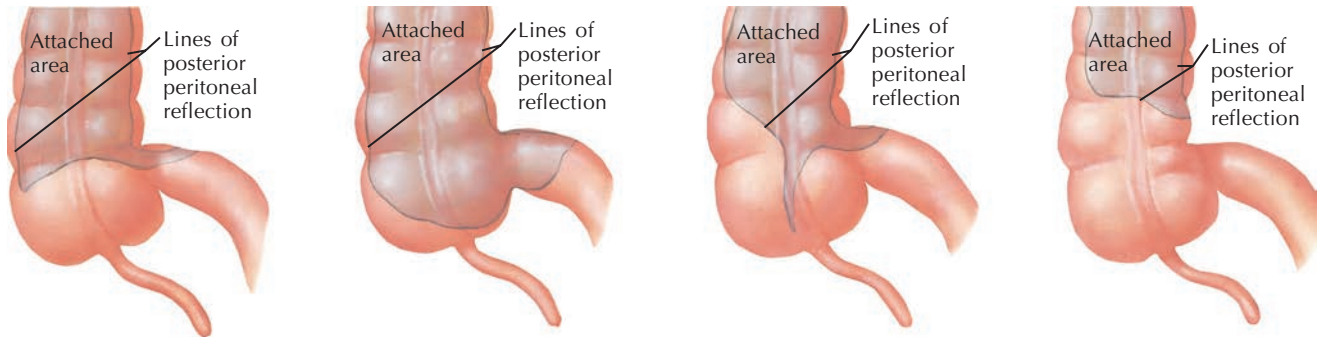


FIGURE 19-3 Ileocecal region.

F. Netter M.D.

SURGICAL TECHNIQUE

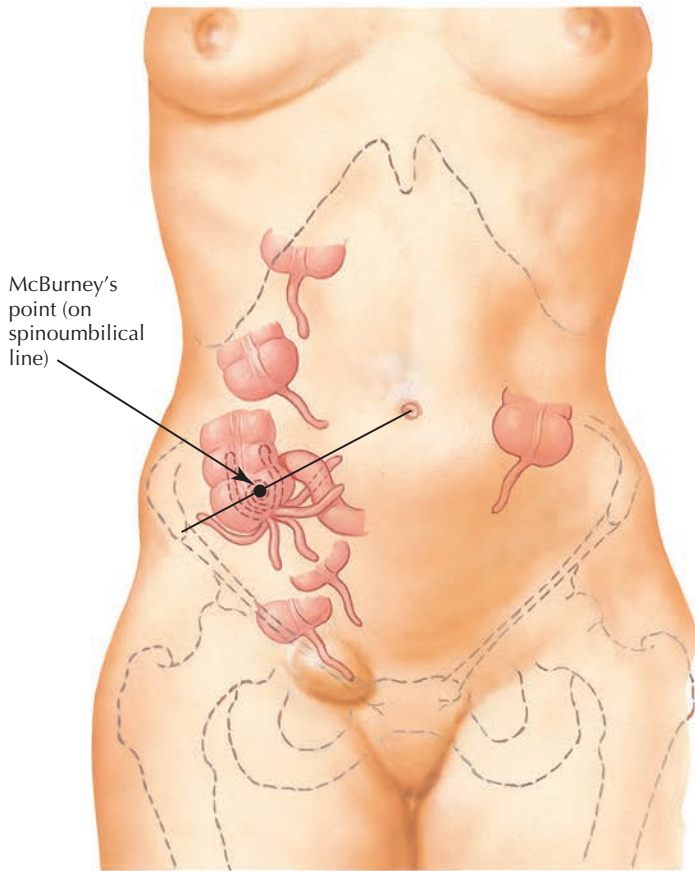
Laparoscopic Approach

Midline umbilical access is accomplished by using the open Hassan technique, and pneumoperitoneum is established. Next, using laparoscopic assistance and avoiding the inferior epigastric vessels, the surgeon places a 12-mm port in the left lower quadrant, which allows use of a stapling device and provides an aperture for specimen removal at the conclusion of the procedure. A third suprapubic port offers a good cosmetic option but is not always appropriate, depending on the patient's anatomy. Alternative approaches include use of a periumbilical port for stapling and specimen removal.

The patient is placed in the Trendelenburg position, and the operating table is "airplaned" to the left. This arrangement facilitates exposure of the right lower quadrant. Initial exploration includes retraction of the omentum, evaluation for abscesses or collections, and evaluation of the adnexa laparoscopically.

The tip of the appendix is identified and dissected, with care taken to preserve periappendiceal structures, which can include adnexa, gonadal vessels, and ureter. Once freed, the appendix is grasped and elevated by using an atraumatic grasper. An aperture in the mesoappendix is created bluntly at its base along the wall of the appendix using a Maryland dissector. This window is widened to admit a bowel grasper to identify the cecal-appendiceal junction clearly. The mesoappendix is then ligated with a vascular stapler load, or alternatively the appendiceal artery may be dissected and clipped. An endoloop or laparoscopic tissue stapler is then used to ligate or divide the appendiceal base. This procedure is performed at a site where tissue quality is adequate for the technique. If there is any doubt about tissue quality, the stapler may be applied slightly onto the base of the cecum.

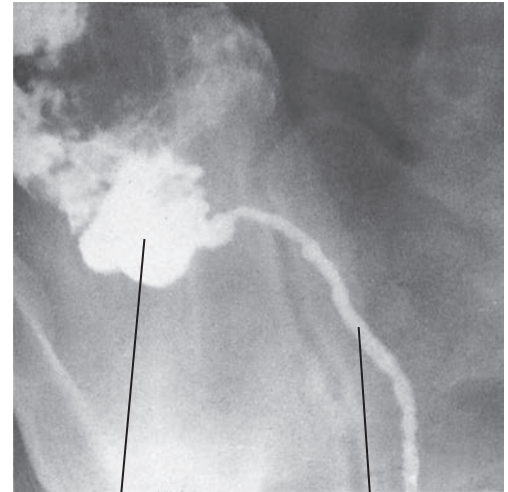The appendix is placed in a specimen bag and removed through the 12-mm port in the left lower quadrant. Any abscess or fluid collections can be irrigated before closure. If needed, a Jackson-Pratt drain can be left in place at the site of an abscess.



McBurney's point (on spinoumbilical line)

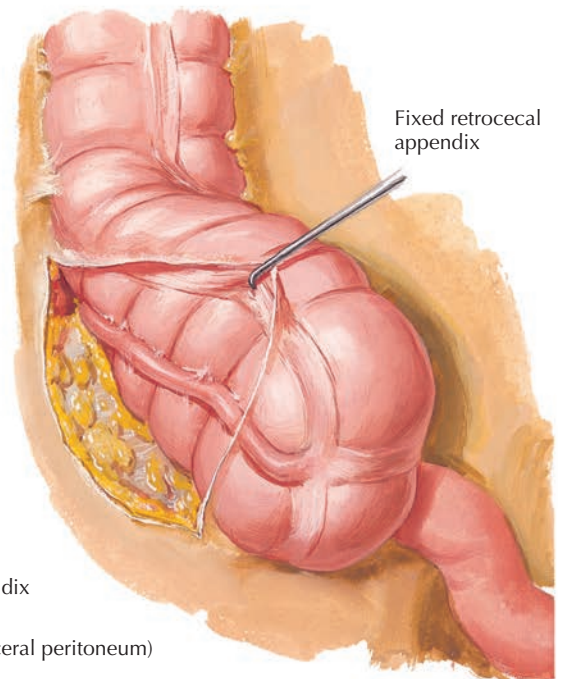
Variations in position of appendix

Barium radiograph of unusually long appendix

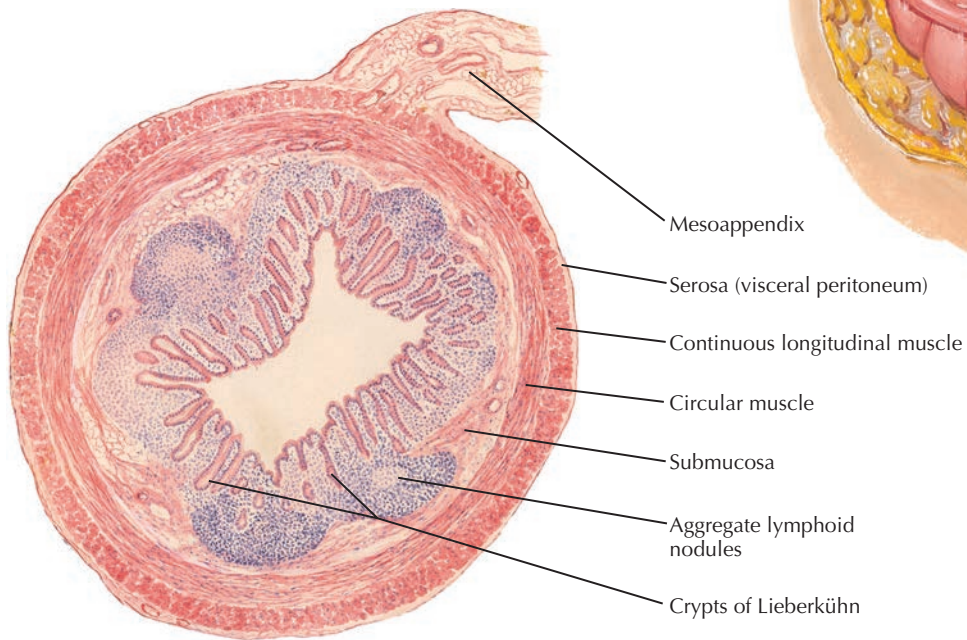


Cecum

Appendix



Fixed retrocecal appendix



F. Netter M.D.

FIGURE 19-4 Vermiform appendix.

Open Technique

An open incision is made at McBurney's point, located one-third the distance between the anterior superior iliac spine and the umbilicus (see Fig. 19-4). This area generally corresponds to the location of the base of the appendix. Subcutaneous tissues are opened to the level of the external oblique muscle by using electrocautery, and its fascia is incised parallel to its fibers. External oblique fibers run inferomedially and are separated along their length, exposing the internal oblique muscle and then the transversus abdominis muscle. These muscles also are preserved and separated through blunt retraction along their length. The peritoneum is opened sharply, with caution taken to avoid injury to underlying viscera.

The right lower quadrant is explored to identify the pathology. A finger sweep can be used to identify an inflamed appendix, which typically feels firm and indurated, revealing its location. Alternatively, identification of the decussation of the taenia coli can be used to identify the base of the appendix. The appendix should be followed to the tip to ensure complete resection. In the case of a retrocecal appendix, the cecum may need to be mobilized fully for adequate exposure (see Fig. 19-4).

After identification and mobilization, the base of the cecum and appendix can be flipped up into the wound. While holding traction on the appendiceal tip with the aid of a moist sponge or Babcock clamp, the surgeon sequentially divides the mesoappendix and appendiceal artery from distal to proximal to the base, freeing the appendix to be drawn out to length. Mesenteric attachments should be taken with fine clamps and ties to avoid hemorrhage when the mesentery retracts into the abdominal cavity.

Once the appendiceal base is visible, the appendix is clamped at its base; an absorbable tie is used to ligate the base. It is divided sharply distal to the tie, and the appendix is passed off the field and sent for pathologic review. Some surgeons invert the appendiceal stump by using a purse-string suture. Although its necessity has not been proved, this step may be used provided that tissue quality is appropriately pliant. The peritoneum may be closed with a running absorbable suture, and the fascia and skin are closed routinely.

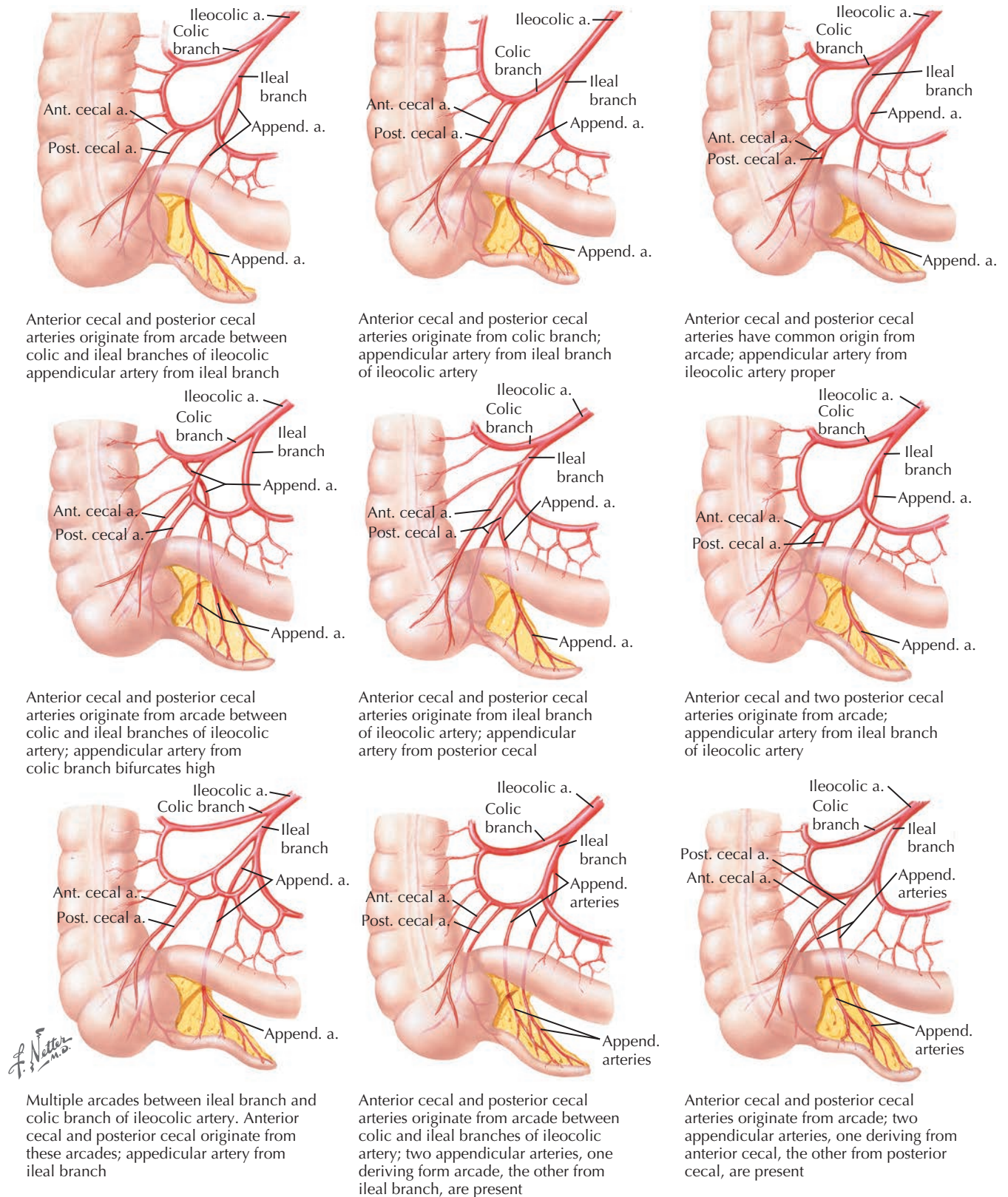
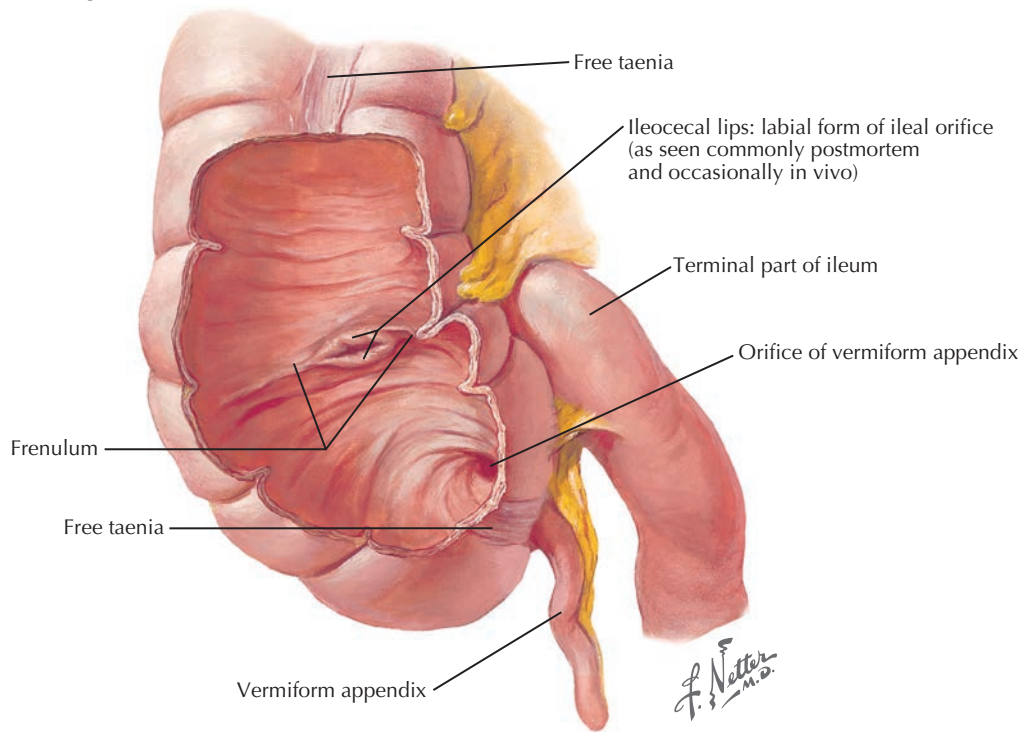


FIGURE 19-5 Variations in cecal and appendicular arteries.

A. Ileocecal region



B. Iliac vessels

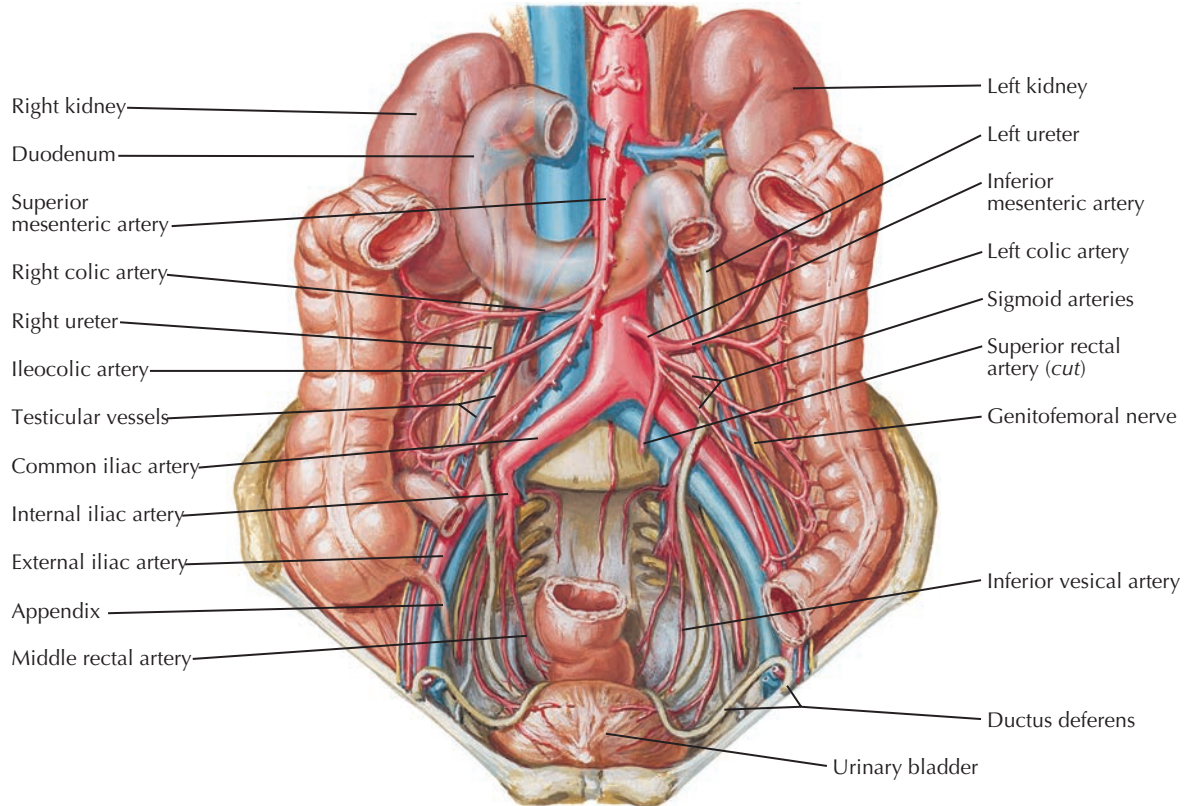


FIGURE 19-6 Ileocecal region and iliac vessels.

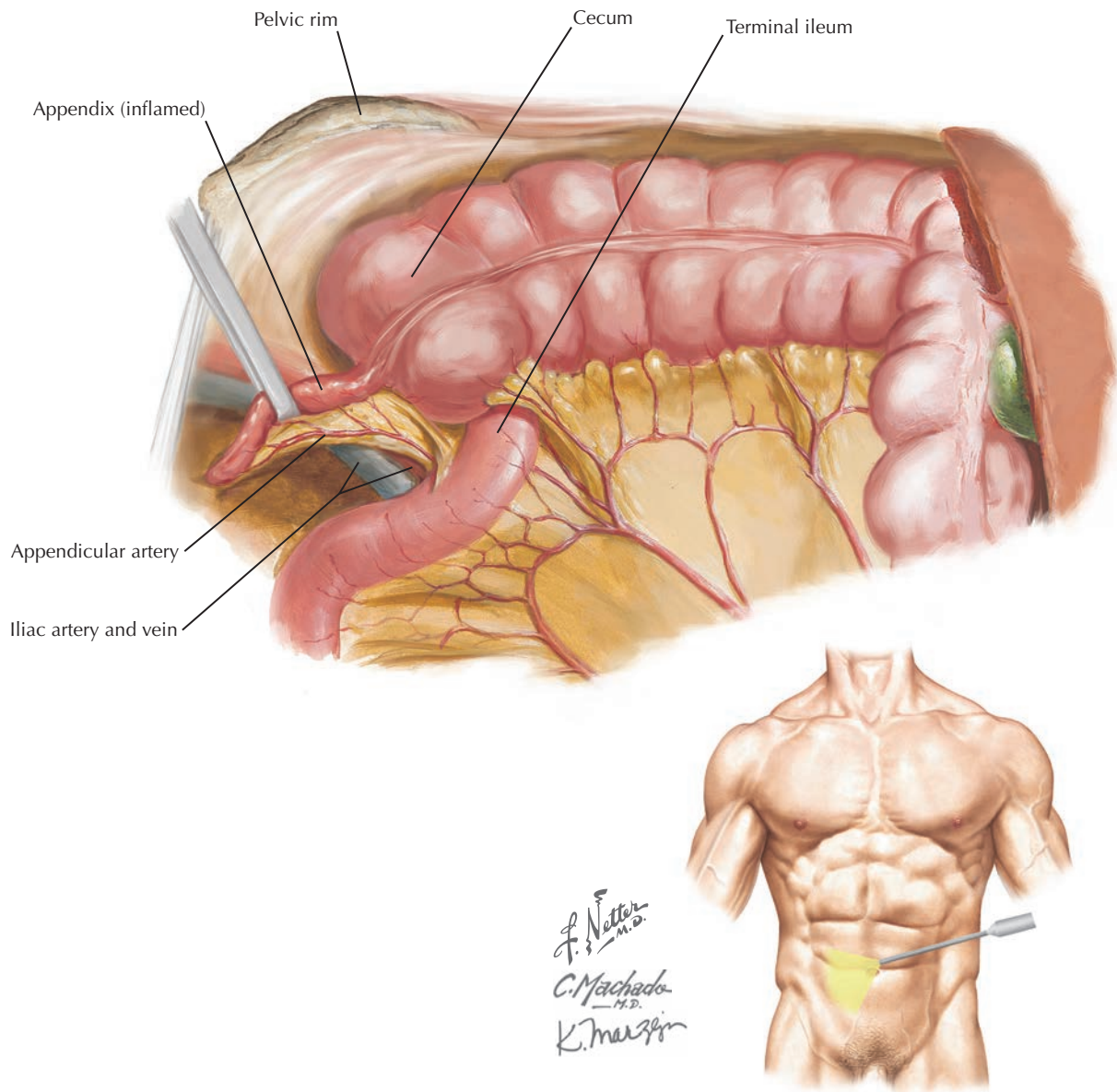


FIGURE 19-7 Right lower quadrant anatomy: laparoscopic view.

SUGGESTED READINGS

- Cameron JL. Current surgical therapy. 10th ed. St Louis: Mosby; 2011, pp 219-23.
- Morris KT, Kavanagh M, Hansen P, et al. The rational use of computed tomography scans in the diagnosis of appendicitis. *Am J Surg* 2002;183(5):547.
- Sauerland S, Lefering R, Neugebauer EA. Laparoscopic versus open surgery for suspected appendicitis. *Cochrane Database Syst Rev* 2004;CD001546.
- Wei HB, Huang JL, Zheng ZH, et al. Laparoscopic versus open appendectomy: a prospective randomized comparison. *Surg Endosc* 2010;24(2):266-9.

Abdominal Wall Anatomy and Ostomy Sites

Jeremy M. Lipman

INTRODUCTION

Proper ostomy creation can significantly minimize the potential for associated morbidity. Incidents of peristomal hernia, pouch leak, skin complications, and bowel prolapse can all be reduced with an appropriately created ostomy.

SURGICAL PRINCIPLES

The general location of the stoma will be determined by the type of ostomy required (proximal or distal bowel, small or large intestine) and by the reach of the mesentery associated with the bowel to be brought through the skin. Ideally, the patient should be examined preoperatively and potential ostomy sites marked by the surgeon or a trained enterostomal nurse. In cases in which the exact stoma location is unknown preoperatively, multiple acceptable locations may be marked to provide the surgeon with several options for placement. Markings are usually performed with permanent marker and may be scored with a needle intraoperatively to avoid removal during surgery.

The planned ostomy site should be placed over the rectus abdominis muscle whenever possible. Care should be taken to observe the patient standing, sitting, and reclining to identify and avoid skin creases and bony prominences that may cause pouching difficulties. Placement of the site should avoid the patient's belt line and ensure easy visualization and reach by the patient, accounting for any functional limitations. Ideally, stomas should be located far enough from incisions to allow for placement of a stoma appliance lateral to existing or new incisions. By locating the stoma in the upper abdomen in obese patients, the surgeon may avoid placing the stoma through the pannus, decrease the amount of subcutaneous tissue between fascia and skin, and provide better visualization of the stoma for the patient.

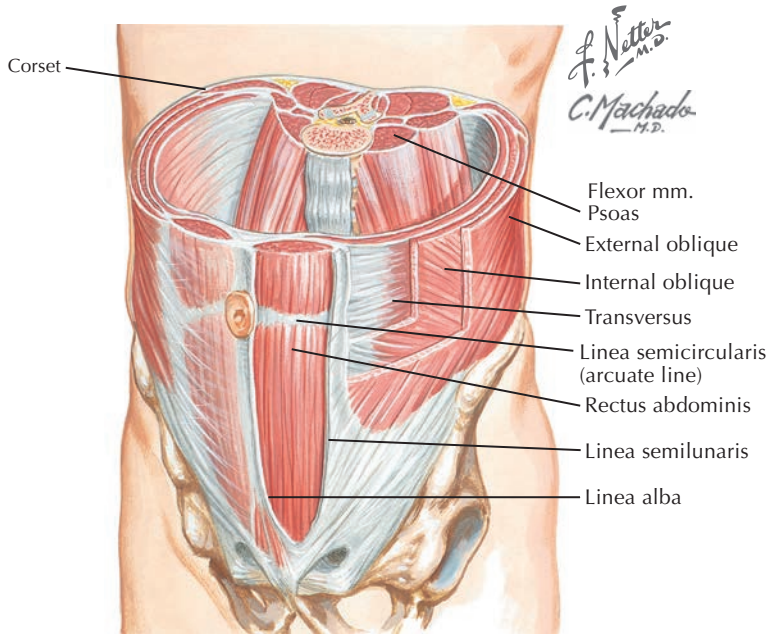
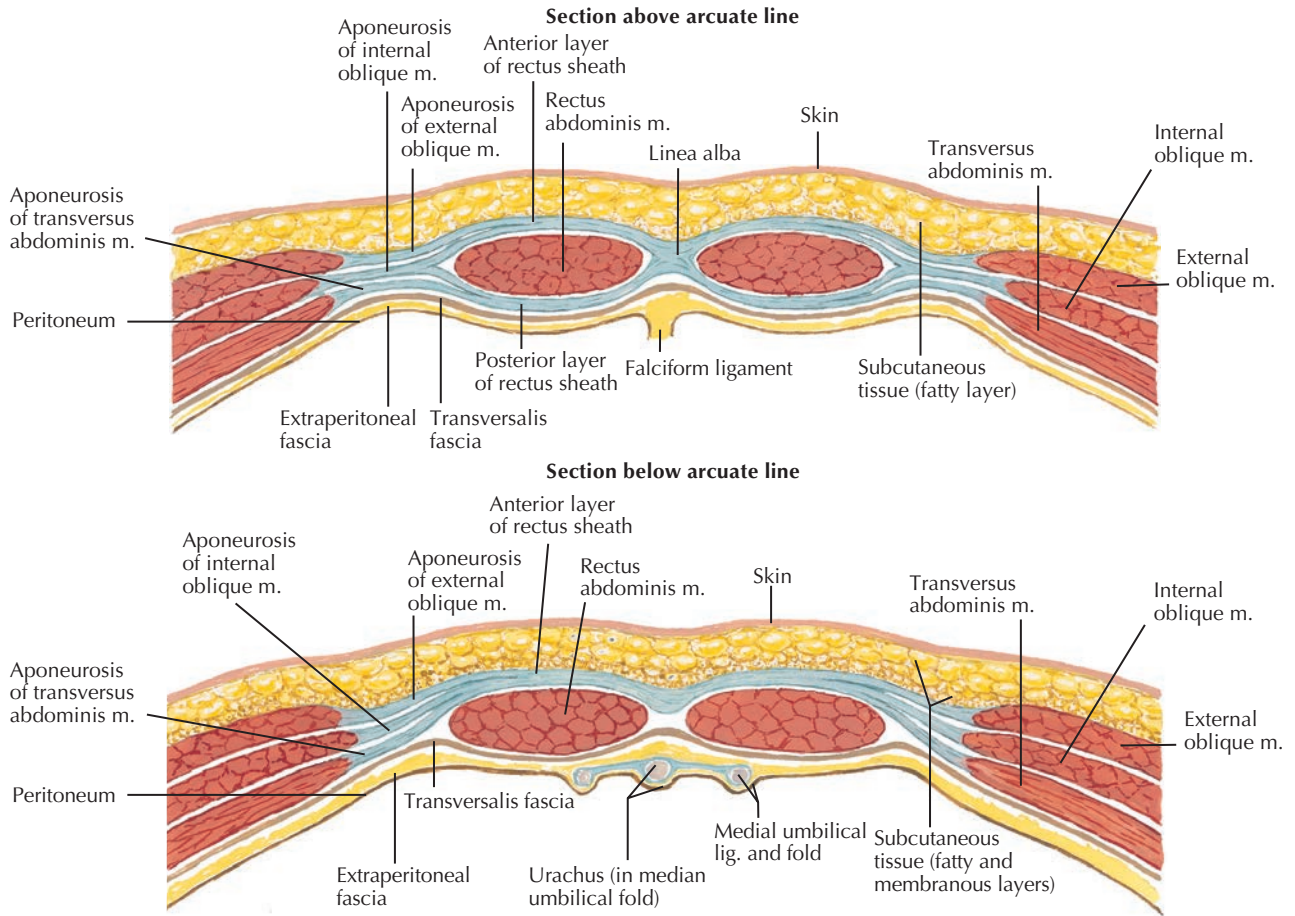
ABDOMINAL WALL ANATOMY

The fasciae of the external and internal oblique and transversus abdominis muscles converge at the linea semilunaris, lateral to the rectus muscles (Fig. 20-1). Medially, these fasciae converge again at the linea alba. Superior to the linea semicircularis (arcuate line), usually at the umbilicus, the fasciae divide to encircle the rectus muscles completely, forming an anterior and a posterior rectus sheath. Inferior to the linea semicircularis, all layers of the fasciae are anterior to the rectus muscles, with only the transversalis fascia posterior.

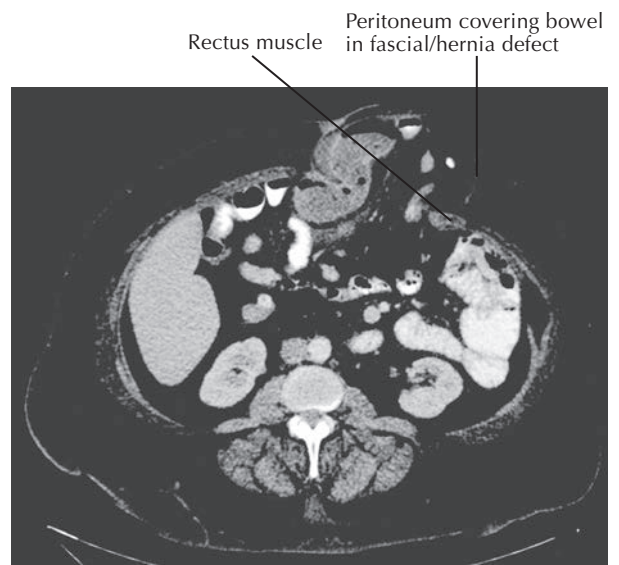
Preoperative Imaging

Although no imaging is specifically required for ostomy creation, available imaging should be reviewed to avoid existing fascial defects during operation (Fig. 20-1, C).

A. Cross-sectional anatomy of rectus sheath



B. Muscles of anterior abdominal wall



C. Preoperative imaging

FIGURE 20-1 Abdominal wall anatomy and rectus sheath.

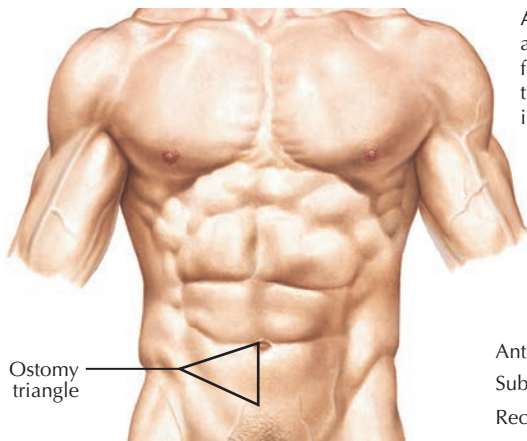
External Landmarks

The ideal ostomy location is on the summit of the infraumbilical fat pad, within the boundaries of the rectus abdominis muscle (Fig. 20-2, *A*).

CREATING THE TREPHINE

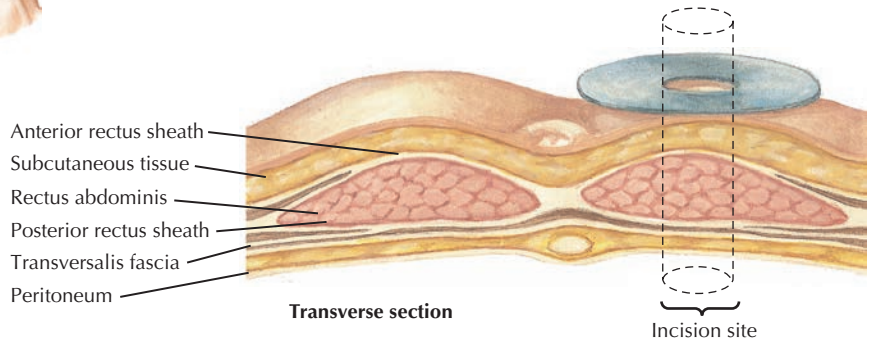
A circle of dermis is excised at the site of the planned ostomy; the subcutaneous tissues are not removed. When a midline incision has been made, the surgeon grasps the converged fasciae at the linea alba with a Kocher forceps through the skin incision. This forceps will be pulled medially to ensure the skin and muscular layers are aligned during creation of the trephine. Using a second Kocher forceps, the surgeon grasps the subcutaneous tissues at the planned ostomy site. A sponge is placed deep to the peritoneum through the incision and pushed anteriorly on the abdominal wall to protect the bowel and minimize the distance between abdominal wall layers (Fig. 20-2, *B*).

The subcutaneous fat is longitudinally divided with cautery through the fasciae of the anterior rectus sheath, exposing the rectus abdominis muscle. A clamp is placed between the fibers of the rectus muscle and is slowly spread transversely, separating the fibers without dividing them. The posterior sheath is then longitudinally divided with cautery onto the sponge pressing anteriorly against the peritoneum.

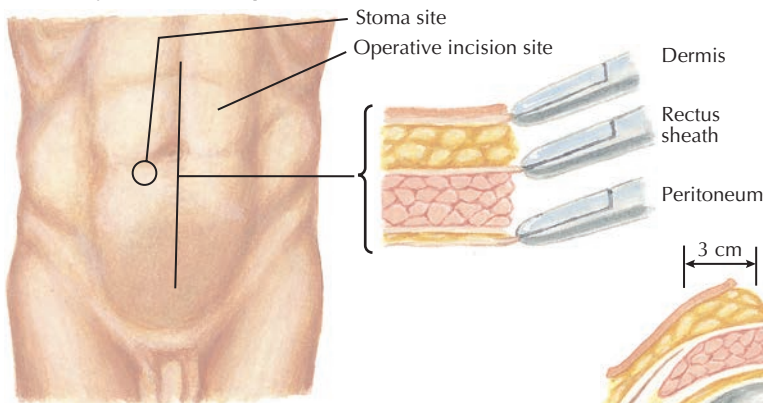


JOHN A. CRAIG AD
C. Machado M.D.

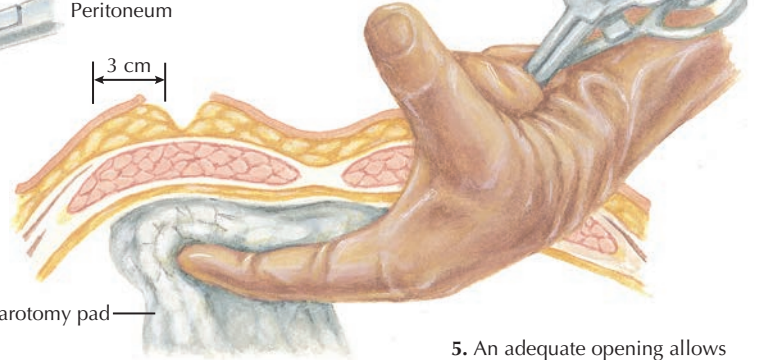
A. External landmarks. An estimate of the appropriate ostomy location can be derived by forming the stoma at the center of the “ostomy triangle”: a triangle connecting the anterior superior iliac spine, umbilicus, and pubic symphysis.



B. Ileostomy incision technique

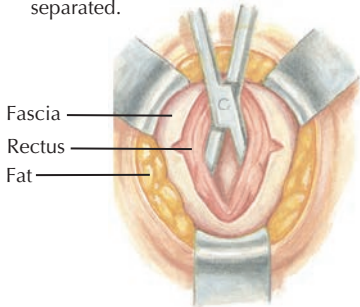


1. Abdominal wall aperture is prepared. Clamps are placed on dermis, rectus sheath, and peritoneum, and aligned to prevent “shutter” effect.

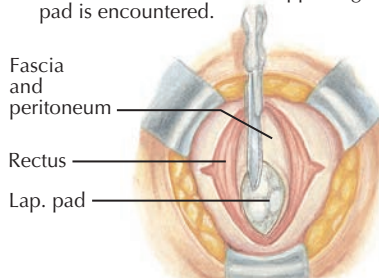


2. Traction is maintained on clamps and a 3-cm disk of skin is removed while upward pressure is exerted on wall.

3. Subcutaneous fat is sharply incised, then fascia, and the underlying rectus is bluntly separated.



4. The exposed posterior fascia and peritoneum are incised for 3 cm until supporting laparotomy pad is encountered.



5. An adequate opening allows two fingers to be inserted to the proximal interphalangeal joint.

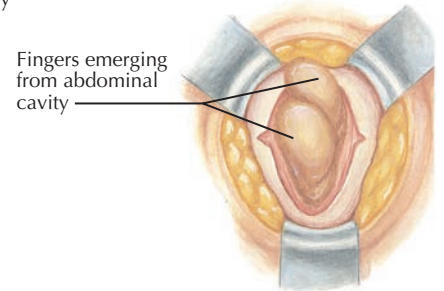
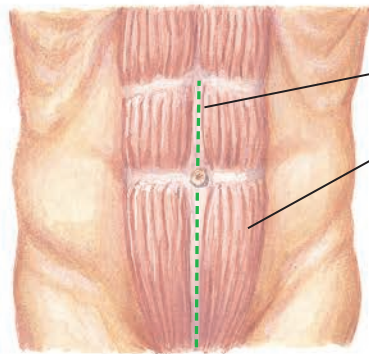


FIGURE 20-2 Ileostomy: anatomic landmarks and surgical technique.

END OSTOMY

Elevating the Bowel

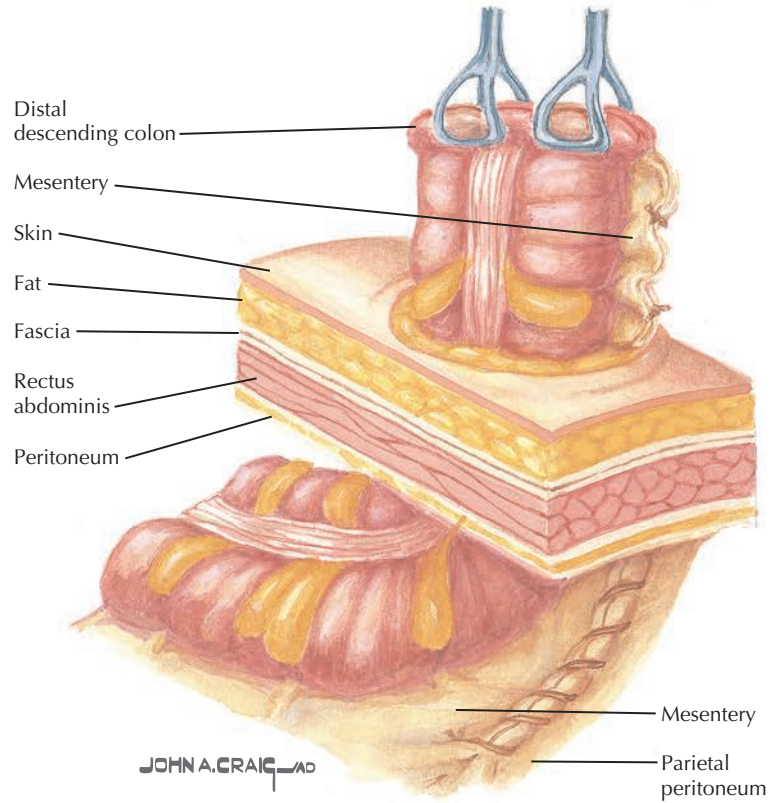
The distal aspect of the divided small or large intestine is then oriented to ensure the mesentery has no twists or turns. A Babcock clamp is passed through the trephine and the intestine is brought through to the skin. No tension is applied, to prevent inadvertent damage to the intestines or mesentery (Fig. 20-3).



Operative incision site

Stoma site

1. Distal descending colon is brought through stoma site with no tension, and with mesentery in place to provide adequate blood supply.



Distal descending colon

Mesentery

Skin

Fat

Fascia

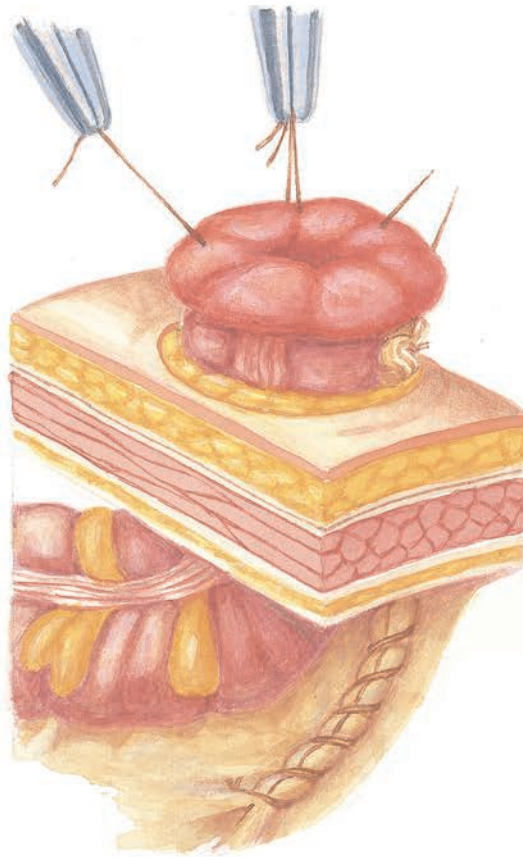Rectus abdominis

Peritoneum

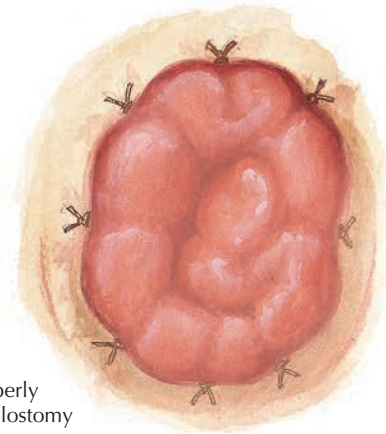
Mesentery

Parietal peritoneum

JOHN A. CRAIG, MD



2. Colostomy is "matured" by suturing full-thickness, freshened, viable colonic wall to dermis, avoiding epidermis.

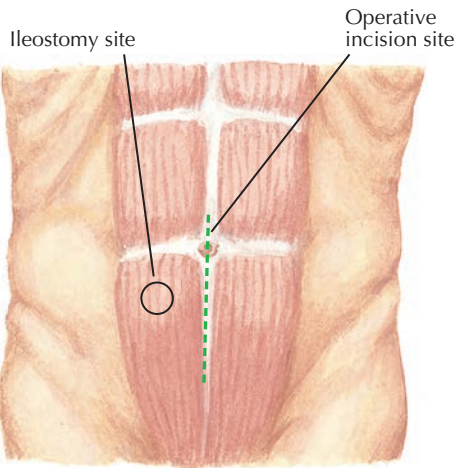


3. Appearance of properly constructed end colostomy

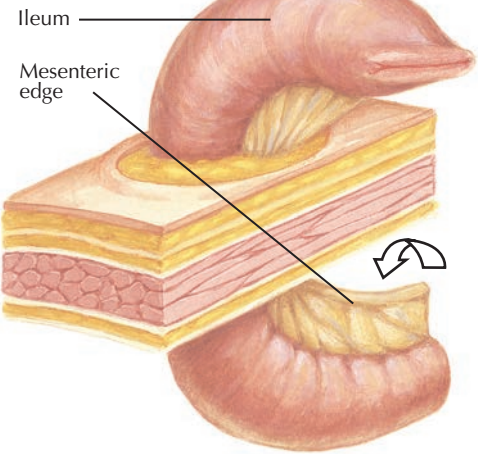
FIGURE 20-3 End colostomy.

Maturing the Ostomy

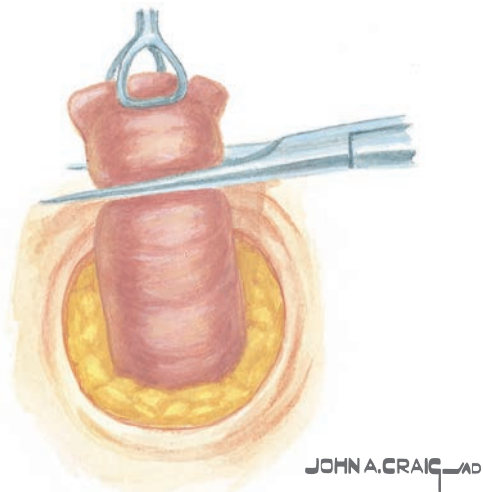
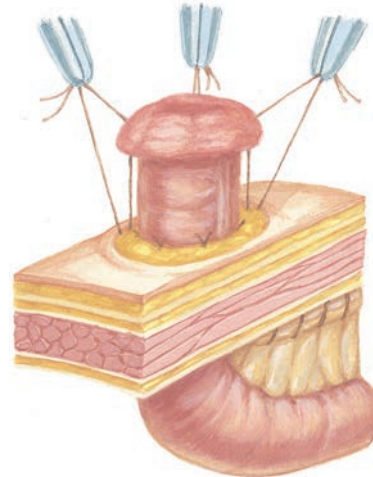
Several centimeters of bowel should be brought beyond the skin level. Sutures are placed full thickness from mucosa to serosa at the open end. The suture is then passed subcutaneously at the corresponding site on the trephine, taking care not to pass through the epidermis. Once sutures are placed in four quadrants, the bowel is everted while the sutures are tied ([Fig. 20-4](#)).



1. Ileum is divided. End of ileum with its mesentery is delivered through prepared stoma site.

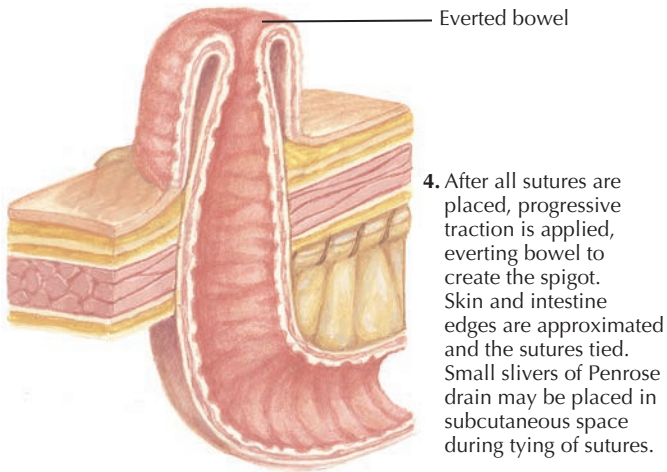
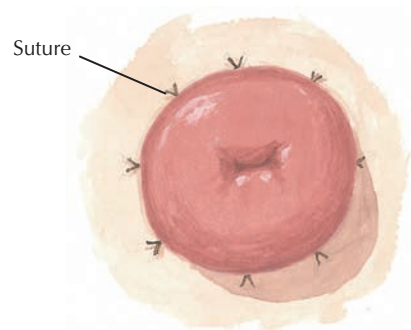


3. Final sutures (8 to 10) are placed through full-thickness bowel and dermis (avoiding epidermis) and are left untied.



2. Stump of intestine is resected.

5. Final spigot conformation protrudes above skin and is fitted with stoma appliance at end of procedure.



4. After all sutures are placed, progressive traction is applied, everting bowel to create the spigot. Skin and intestine edges are approximated and the sutures tied. Small slivers of Penrose drain may be placed in subcutaneous space during tying of sutures.

FIGURE 20-4 Brooke ileostomy technique.

LOOP OSTOMY

Elevating the Bowel

An appropriate segment of bowel is selected for the loop ostomy. Sutures of differing colors can be placed to mark the proximal and distal limbs to ensure correct orientation as the bowel is elevated. A window is created in the mesentery adjacent to the bowel, and umbilical tape is passed through the opening. The ends of the tape are then grasped through the trephine, elevating the ostomy above the skin. The umbilical tape is then exchanged for an ostomy rod (Fig. 20-5, step 1).

Maturing the Ostomy

The distal aspect of the loop is opened transversely across two-thirds its circumference, leaving the posterior wall intact. Distally, absorbable sutures are then placed (Fig. 20-5, step 2), with one in the center and one laterally just inferior to the rod on both sides. Sutures should be full thickness through the bowel and into the dermis, again taking care not to pass through the epidermis.

Sutures are placed proximally, in the same locations. While they are tied, the bowel is everted as a Brooke ileostomy. Brooke ileostomy allow for easier placement of the stoma appliance by elevating the stoma above the level of the epidermis (Fig. 20-5, steps 3 and 4).

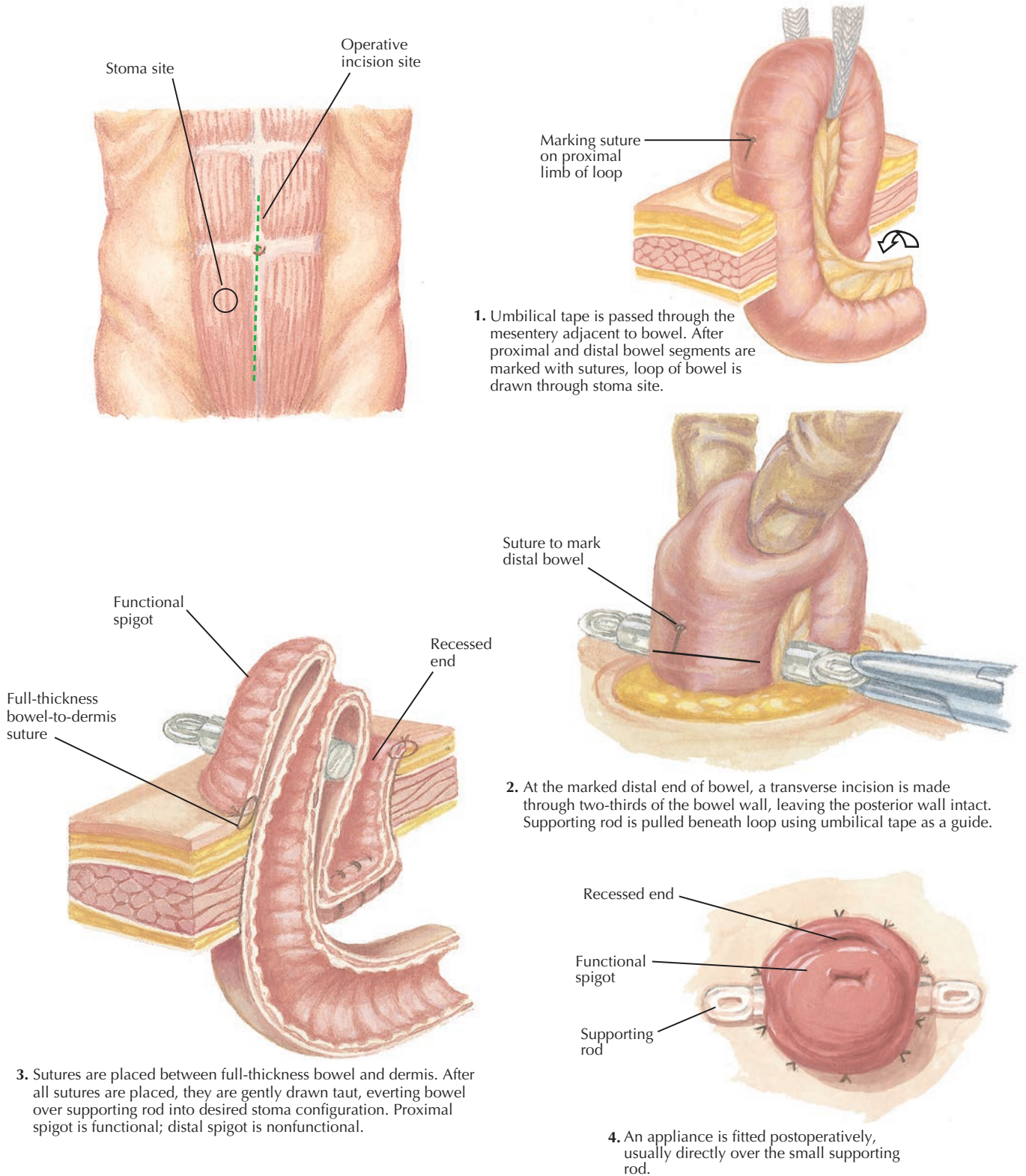


FIGURE 20-5 Loop-end ileostomy technique.

SUGGESTED READINGS

Beck DE. The ASCRS textbook of colon and rectal surgery. New York: Springer; 2011.

Corman ML. Colon and rectal surgery. New York: Lippincott; 2004.

Gordon PH. Principles and practice of surgery for the colon, rectum and anus. New York: Informa; 2007.

Right Colectomy



Sharon L. Stein

INTRODUCTION

A right colectomy is performed to treat a number of pathologies. Common indications include an unresectable polyp, colon cancer, Crohn disease of the terminal ileum, and right-sided diverticular disease. Ischemia and volvulus may also be indications. Resection of the terminal ileum and cecum is common to all these procedures. The distal extent of the right hemicolectomy will vary depending on the indication, oncologic principles, and adequacy of perfusion to the right or transverse colon.

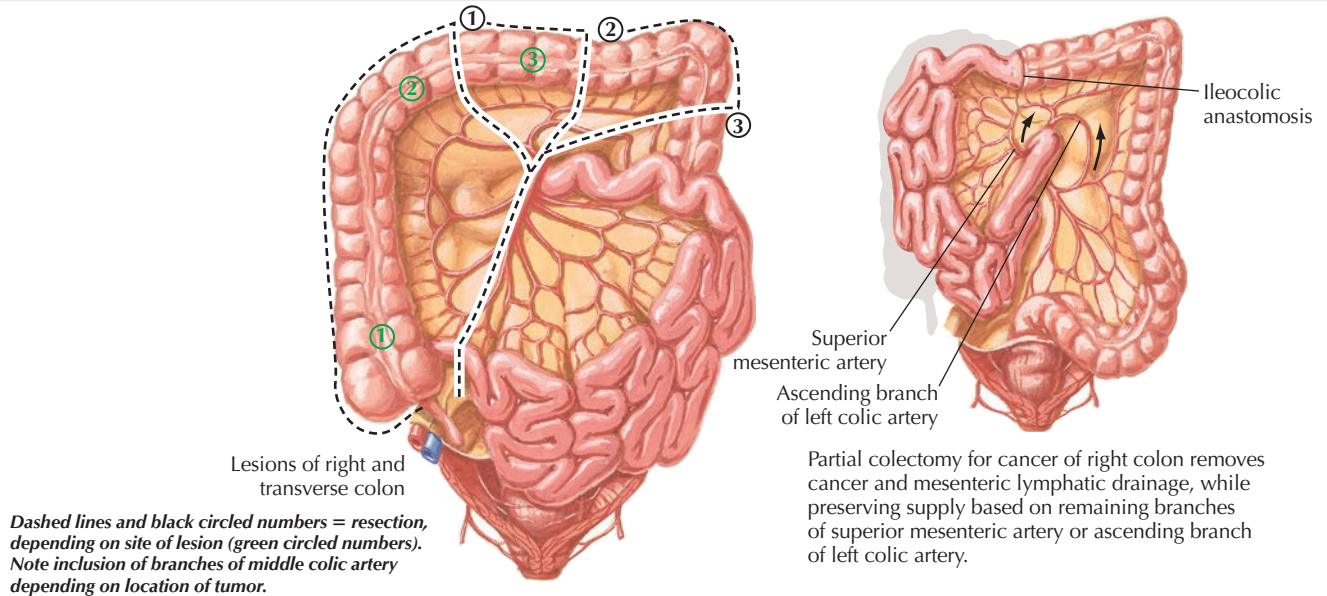
SUPERFICIAL ANATOMY AND TOPOGRAPHIC LANDMARKS

Before making an incision, either laparoscopic or open, it is important to understand the relationship between surface anatomy and the abdominal anatomy (Fig. 21-1, *A*). Understanding the location of the most difficult part of the anatomy or most tethered portion of the colon will assist in appropriately placing an incision. Also, in the morbidly obese patient, surface anatomy, such as the location of the umbilicus, may be greatly altered. The umbilicus may reach down to the pubis and overlie a large pannus, which may distort normal relationships with internal anatomy.

Although the right colon is typically tethered by the ileocolic artery, lateral attachments, and the middle colic artery, the inferior portion of the right colon and ileum will be very mobile after the surgery is performed. Attachments to the middle colic and lesser sac are typically the most tethered portion of the operation. In addition, appropriate isolation and evaluation of adequate blood flow of the middle colic vessels is often the most difficult part of the case (Fig. 21-1, *B*). For this reason, laparoscopic extraction incisions are usually made over the middle colic arteries.

The middle colic arteries typically lie approximately midway between the xiphoid process and the umbilicus in a nonobese patient. The inferior extent of the procedure (inferior dissection of terminal ileum and cecum) is typically only centimeters below the umbilicus and medial to the anterior superior iliac spine. Therefore, an open right colectomy can often be performed through a relatively small periumbilical midline or right-sided transverse incision in a thin patient.

A. Right colectomy



B. Arteries of the colon

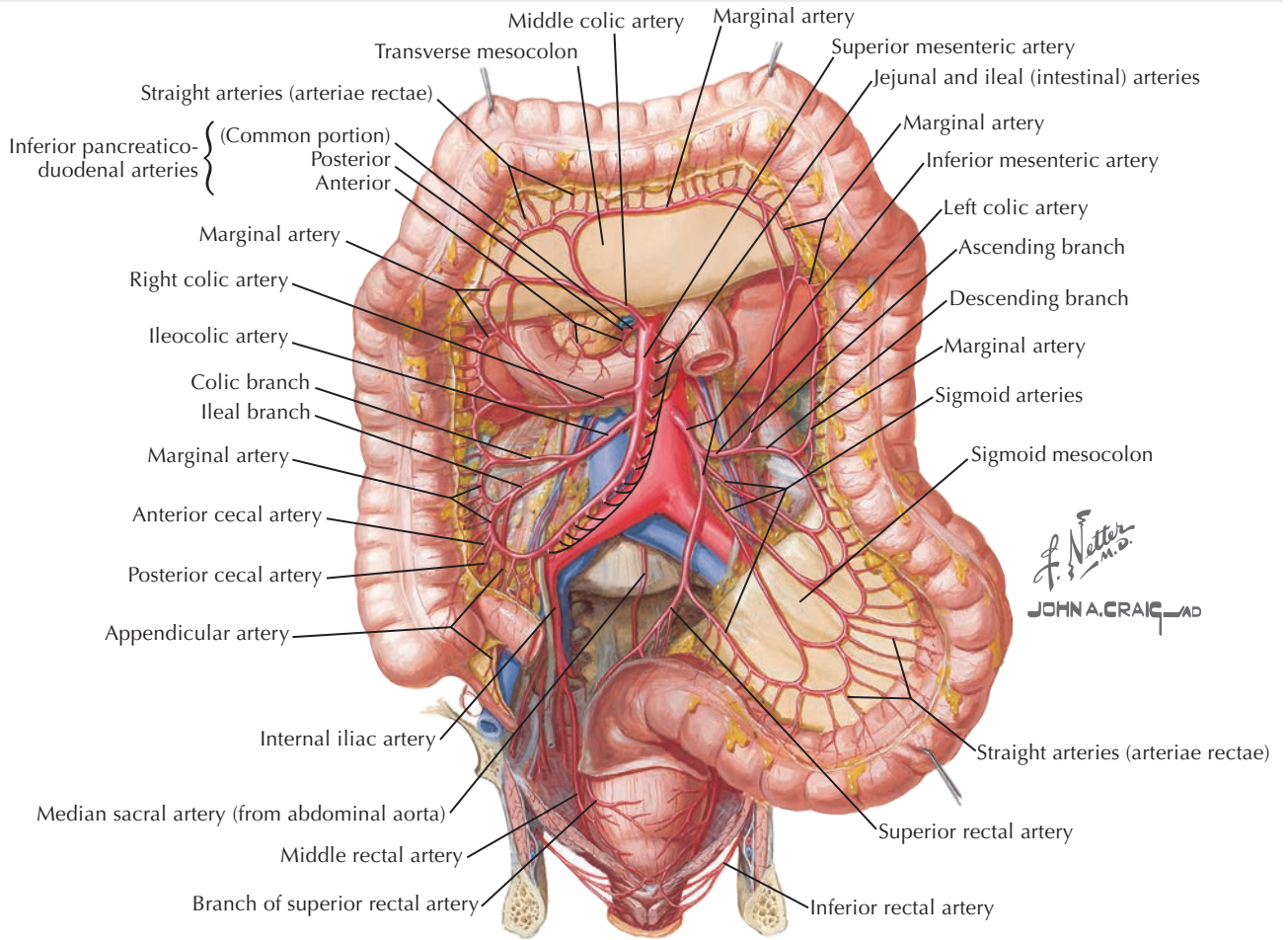


FIGURE 21-1 Right colectomy and arteries of the colon.

ANATOMIC APPROACH TO RIGHT COLECTOMY

Different surgical approaches to the right colon have been described and include medial to lateral, lateral to medial, inferior to superior, and superior to inferior. Varying the approach can allow for a safe, oncologically appropriate operation, depending on body habitus and pathology. Although anatomic relationships are constant, the surgeon's awareness of proximity of structures must change.

Medial to Lateral

Many surgeons prefer a medial-to-lateral approach for for laparoscopic and often open right colectomy. This provides several benefits: the vessels are taken early in the operation, decreasing stretch and torque and providing ligation before manipulation of the tumor in the patient with malignancy. In addition, this approach demonstrates the location of the duodenum, a crucial step early in the surgery.

The medial-to-lateral approach is more difficult in patients with thickened Crohn's mesentery; often the mesentery is extremely difficult to mobilize and resect and requires the use of Kelly clamps and suture ligation. In these patients the lateral dissection is performed early in the operation, and having obtained greater mobilization to the colon, ligation of the ileocolic vessels can safely be performed.

Identification of Ileocolic Vessels

To expose the ileocolic vessels, the small bowel must be swept to the left side or into the pelvis. Grasping and lifting the mesentery just proximal to the ileocolic valve tents the ileocolic artery (ICA), even in heavy patients. A single vessel is noted extending from the superior mesenteric artery (SMA) to the ileocolic junction. Scoring the peritoneum just below this fullness, usually with electrocautery or bipolar device, allows isolation of the pedicle. An avascular space exists below the vessel. In oncologic resections, this isolation should occur close to the SMA, including the lymphatic vessels. If performed too distally along the ICA, many branches to the ileum will be noted as the arcades are encountered, and dissection will be more tedious.

Once the avascular plane is identified, dissection can be carried posterior to the mesentery in a superior, medial, and lateral direction within this avascular space. Borders of the space will be the mesentery of the right colon superiorly, attachments of the colon to the liver superiorly and Toldt's fascia laterally. The retroperitoneum will form the floor of the space (Fig. 21-2).

Just lateral to the origin of the ileocolic vessels, care must be taken to prevent injury to the duodenum, which lies close to the SMA-ICA junction. Just above the duodenum, a subtle change in fat identifies the head of the pancreas, which should also be preserved. In fact, the plane anterior to the head of the pancreas mobilizes the transverse colon mesentery to complete the medial dissection for a right colectomy. Reaching the liver superiorly, the pancreas medially, and Toldt's fascia laterally facilitates later dissection (Fig. 21-2).

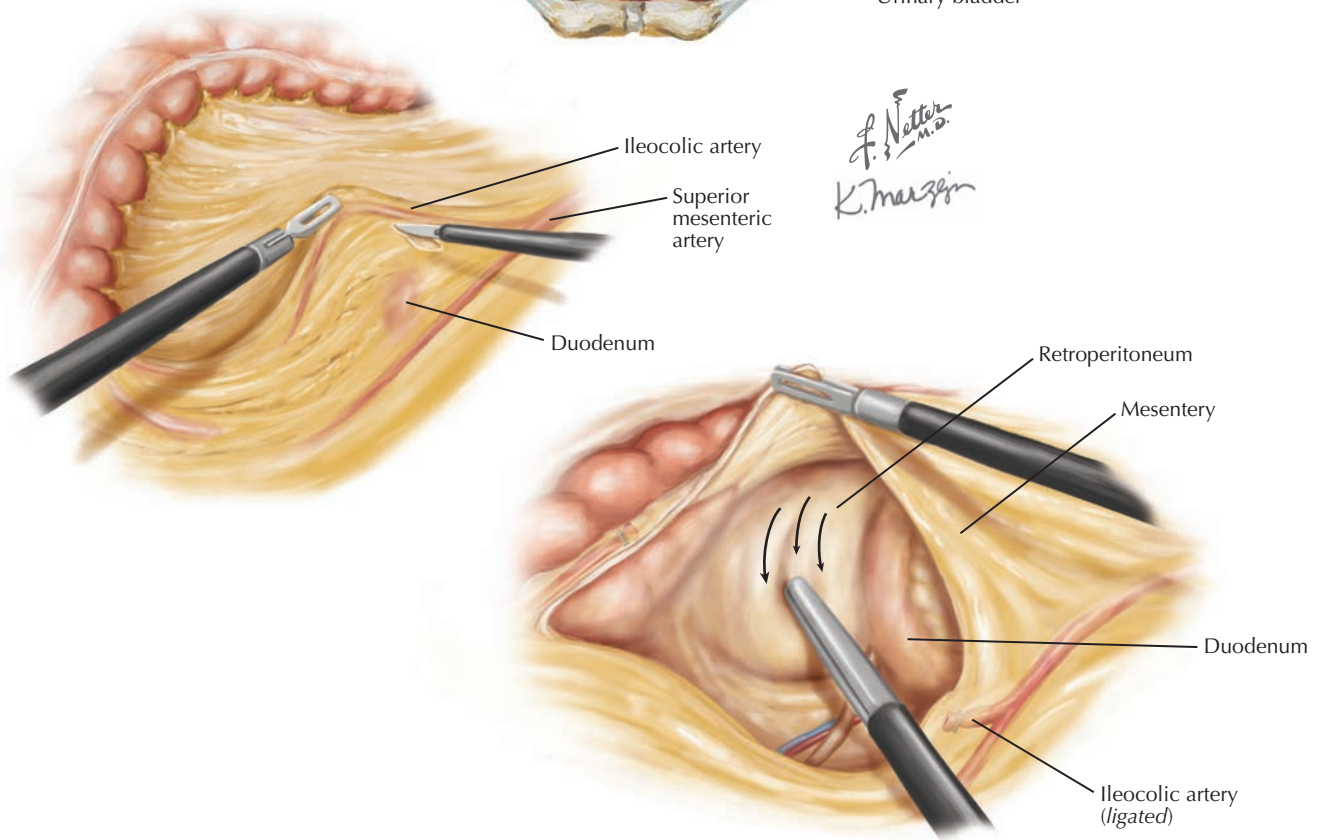
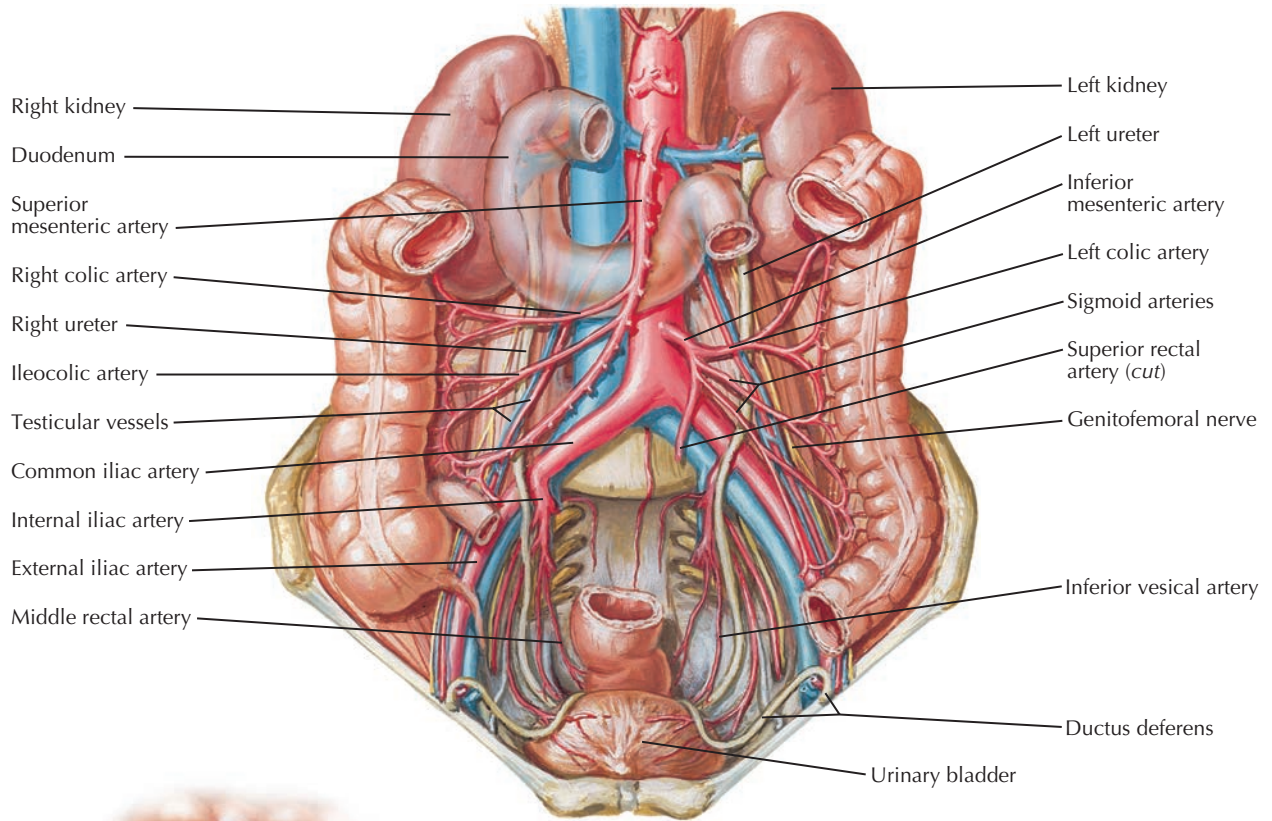


FIGURE 21-2 Retroperitoneal structures.

Transection of Ileocolic Vessels

Once the duodenum has been identified and the proximal ICA has been isolated, this can be transected just distal to the SMA. Means of transection include energy device, clips, staplers, and ties.

Variation in Arteries of Right Colon

Many textbooks demonstrate a distinct ICA and right and middle colic vessels, but arterial variation is common in this location. Often, the right colic artery (RCA) is either a branch from the ICA or not found at all. If a high ligation of the ICA is performed, the RCA may not need to be transected again. If it is a separate branch of the SMA, the RCA will also need to be transected, high if the operation is performed for oncologic reasons (Fig. 21-3).

Middle Colic Vessels

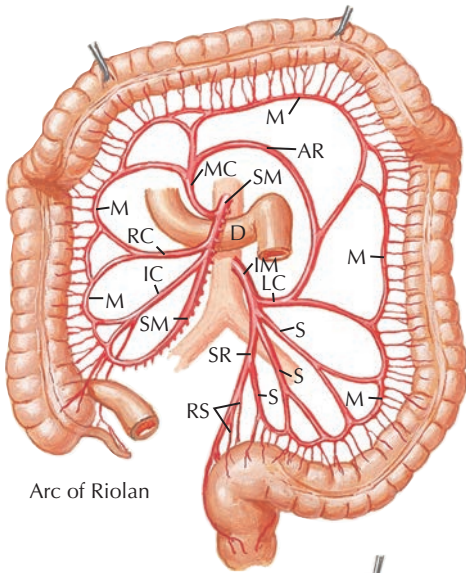
Middle colic anatomy is often varied. A single vessel to more than five branches may extend from the SMA in this location. Level of transection will depend on oncologic principles (see Fig. 21-1, A). If a tumor is located at the hepatic flexure or proximal transverse colon, it may be necessary to resect all the branches with a high ligation. However, for a typical right hemicolectomy, only the right branch is resected. This provides additional lymphatic information with the specimen as well as important mobility to the transverse colon.

In addition to isolating and transecting the vessels, it is important to free the mesentery extending to the bowel wall. If surgery is performed laparoscopically, torque and tension may be applied while exteriorizing the bowel. Cleaning the mesentery to the bowel margin minimizes the risk of tension and prevents unnecessary bleeding.

Omentum and Lesser Sac

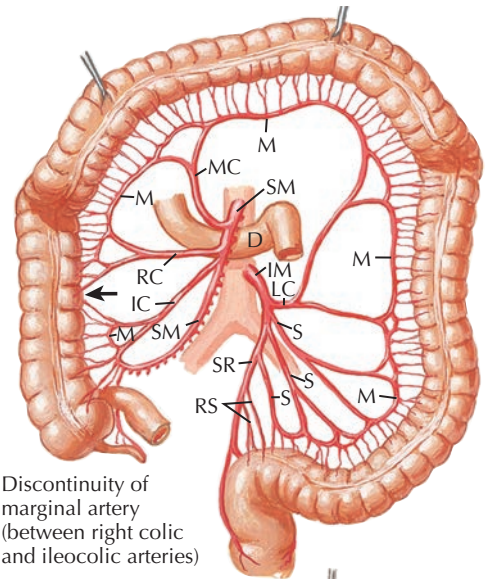
To mobilize the transverse colon for anastomosis and perform a *full hemicolectomy*, the lesser sac must be entered. Anatomically, the easiest place to enter the lesser sac is toward the midline, where layers of the omentum and lesser sac are fused. A subtle change in color or texture of fat differentiates extraneous epiploic and colonic adipose tissue from the omentum. Typically, an avascular plane close to the colon can be identified and entered.

Full dissection is ensured by visualization of the posterior aspect of the stomach, with gastroepiploic branches on the superior aspect of the stomach when elevated. In patients with hepatic flexure tumors, it may be necessary to transect and remove the omentum with the specimen for oncologic principles. The lesser sac should still be entered medially to the pathology, to ensure full mobilization. A branch of the venous drainage from the gastroepiploic vein to the colon mesentery is often noted toward the midline and may need to be transected to prevent injury.

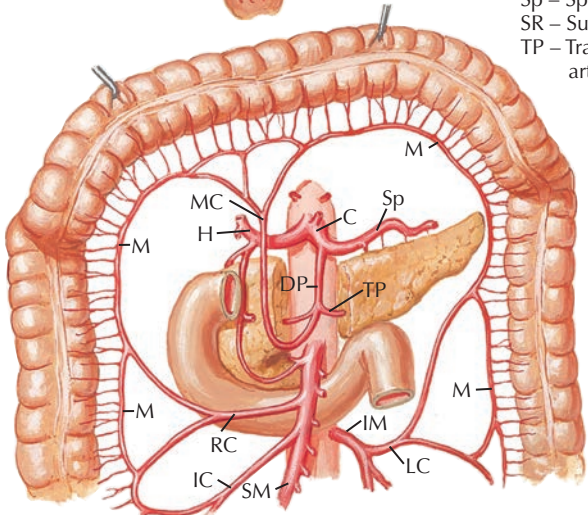


Arc of Riolan

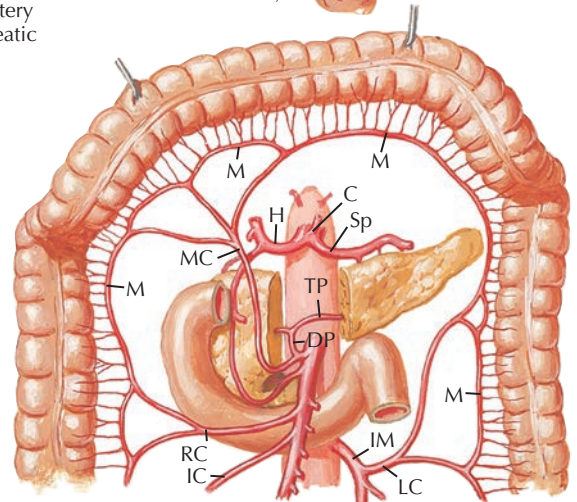
- Key
- AR – Arc of Riolan
 - C – Celiac trunk
 - D – Duodenum
 - DP – Dorsal pancreatic artery
 - H – Hepatic artery
 - IC – Ileocolic artery
 - IM – Inferior mesenteric artery
 - LC – Left colic artery
 - M – Marginal artery
 - MC – Middle colic artery
 - RC – Right colic artery
 - RGE – Right gastroepiploic artery
 - RRH – Replaced right hepatic artery
 - RS – Rectosigmoid arteries
 - S – Sigmoid arteries
 - SM – Superior mesenteric artery
 - Sp – Splenic artery
 - SR – Superior rectal artery
 - TP – Transverse pancreatic artery



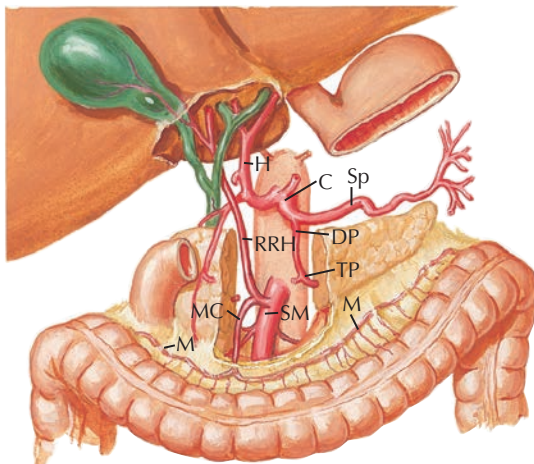
Discontinuity of marginal artery (between right colic and ileocolic arteries)



Middle colic artery originates from celiac trunk via dorsal pancreatic artery



Middle colic artery gives origin to dorsal pancreatic artery



Middle colic artery originates from or with replaced right hepatic artery (from sup. mesenteric a.)

Middle colic artery has common origin with right gastroepiploic from superior mesenteric artery

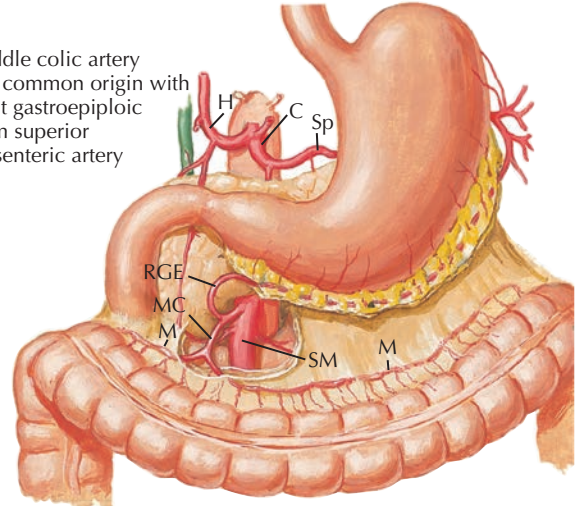


FIGURE 21-3 Variations in vascular anatomy of right colon.

Omentum and Lesser Sac—Cont'd

After the lesser sac has been entered, if a full mobilization of the retroperitoneum has occurred, a thin purple plane will be noted as the hepatic flexure is approached. This will be the only remaining layer between the previous medial dissection and the hepatic flexure. Opening this layer will facilitate the dissection and identification of planes.

When approaching the line of Toldt from a superior approach, it is important to stay close to the colon just inside the white line, unless necessary for oncologic margins. If lateral to the line of Toldt, it is easy to migrate into the retroperitoneum and behind the kidney. Staying immediately on the colon side of the line of Toldt will help prevent entering the incorrect plane. Dissection is typically continued inferiorly to the cecum, just inside the line of Toldt, but preserving the fascia propria of the mesocolon.

Inferior Dissection

The inferior approach to the cecum, appendix, and terminal ileum creates a potential risk to the gonadal vessels and ureter. A thin, filmy plane separates the natural attachments from the retroperitoneum and must be carefully dissected. The ureter crosses the iliac vessels medial to the gonadal vessels, just inferior to the cecum or ileum. Identification of the ureter within the pelvis and following it back to the dissection plane can prevent injury. Once this plane has been entered, dissection should continue to ensure adequate mobility of the ileum for the anastomosis. If necessary, dissection of the small bowel mesentery off the retroperitoneum can continue all the way to the duodenum, without transection of any vessels.

Anastomosis

The mesentery of both the ileum and the colon should be dissected to the bowel wall at the level of transection before anastomosis. This reduces mesenteric bleeding during creation of the anastomosis, which may be stapled or hand-sewn.

SUGGESTED READINGS

- Mancino AT. Laparoscopic colectomy. In Scott-Conner CEH, editor. *The SAGES manual: fundamentals of laparoscopy, thoracoscopy and GI endoscopy*, 2nd ed. New York: Springer; 2006.
- Okuda J, Tanigawa N. Right colectomy. In Milson JW, Bohm B, Nakajima K, editors. *Laparoscopic colorectal surgery*. New York: Springer; 2006.
- Scott-Conner CEH. Right colectomy for cancer. In Chaissin's operative strategy in general surgery: an expositive atlas, 3rd ed. New York: Springer; 2002.
- Sonoda T. Laparoscopic medial to lateral. In Wexner SD, Fleshman JW, editors. *Colon and rectal surgery: abdominal operations*. Philadelphia: Lippincott, Williams & Wilkins; 2012.

Left Colectomy



Bradley J. Champagne and Thomas J. Edwards

INTRODUCTION

Left colectomy is a resection of the colon within the territory supplied by the inferior mesenteric artery. The arterial supply of the colon is divided by the embryologic partitioning between midgut and hindgut, so a left colectomy is a resection of the hindgut, excluding the rectum. Terms such as left hemicolectomy, *sigmoid colectomy*, and *sigmoid wedge resection* also apply to left-sided colonic resection. Common indications include neoplasia, ischemia, and diverticulitis.

SURGICAL PRINCIPLES

The pattern of left colonic resection is defined by the indication for surgery, the need to facilitate a tension-free colo-colonic anastomosis, and the blood supply. The most common indication for isolated left colonic resection is *neoplasia*. In this case, a radical lymphadenectomy is necessary for staging and prognosis, and lymphatic drainage must be considered. Because the pattern of lymphatic drainage for the colon follows that of the arterial supply, the inclusion of the mesocolic envelope containing the inferior mesenteric artery (IMA) and its branches, with ligation of the IMA close to its origin, ensures that this is achieved. This is referred to as a *high* ligation of the IMA. This approach may devascularize the entire left colon, requiring its resection and the mobilization of the distal right colon for anastomosis to the upper rectum.

Other indications for left colonic resection include diverticular disease, ischemia, Crohn disease, sigmoid volvulus, rectal prolapse, and secondary involvement in noncolonic processes, such as ovarian carcinoma. None of these conditions requires high ligation of the IMA, and in these cases it may be acceptable to ligate only the relevant branches of the IMA, perform a less extensive mobilization of the left colon, and create a tension-free anastomosis.

ANATOMY FOR PREOPERATIVE IMAGING

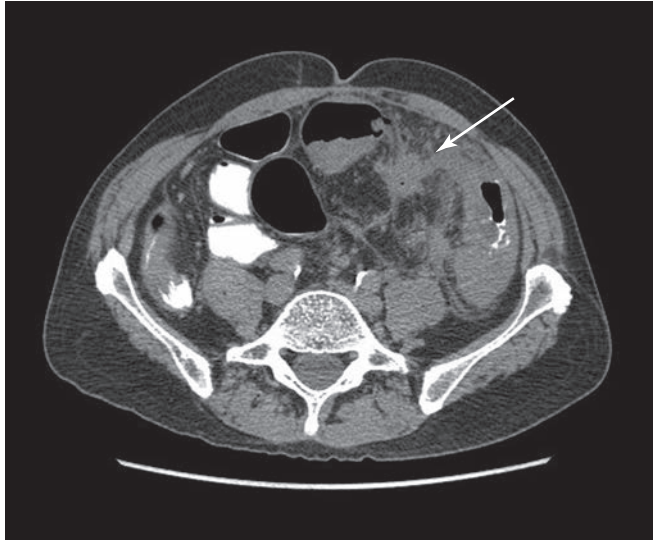
For colonic carcinoma, computed tomography (CT) of the chest, abdomen, and pelvis provides preoperative staging of the disease. CT includes identification of distant metastases, gross local lymph node involvement, and local invasion of the primary tumor (Fig. 22-1, A). Full colonoscopic evaluation determines the presence of synchronous lesions. For benign disease, CT and colonoscopy may help to identify pathologic features, such as the extent of Crohn disease or ischemia, that may affect approach and extent of dissection.

SURFACE ANATOMY, INCISION, AND PORT PLACEMENT

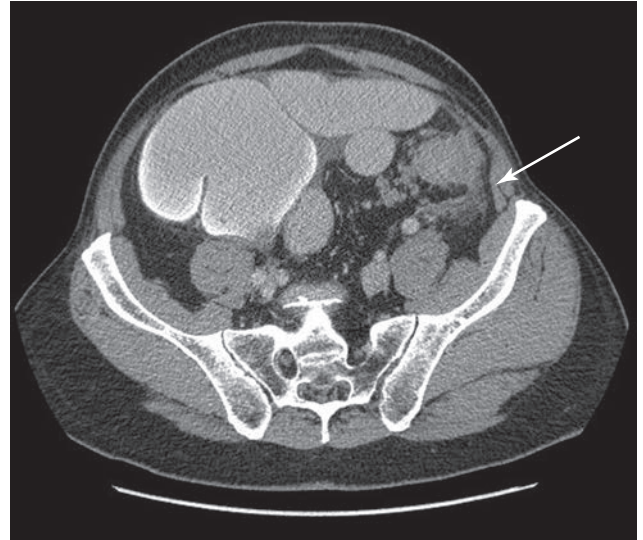
Left colectomy may be performed as either an open or a laparoscopic procedure. For either approach, the patient should be in the Lloyd-Davis position, supine, with the patient's buttocks at the foot of the table and legs slightly flexed in the horizontal position and held in leg supports. For a laparoscopic approach, the patient is secured with gel pad or bean bag in anticipation of an extreme head-down and right lateral tilt position.

A number of different port configurations have been described; the authors' preferred approach is shown in Figure 22-1, B. Open left hemicolectomy may be performed through either a midline or a left transverse incision.

A. Preoperative computed tomographic imaging

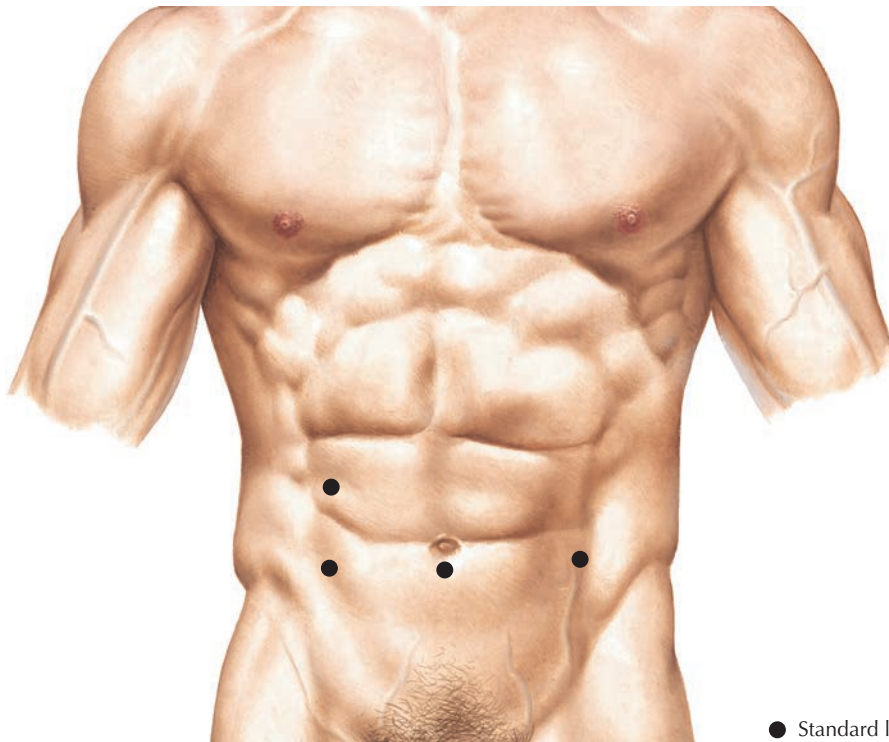

Thickened sigmoid secondary to diverticular disease with marked inflammatory fat stranding



Sigmoid descending junction obstructing carcinoma with dilated proximal large and small bowel

B. Key landmarks of the surface anatomy of the anteriolateral abdominal wall



● Standard laparoscopic port placement

C. Machado
—M.D.

FIGURE 22-1 Left colectomy: authors' preference for laparoscopic port placement.

VASCULAR ANATOMY

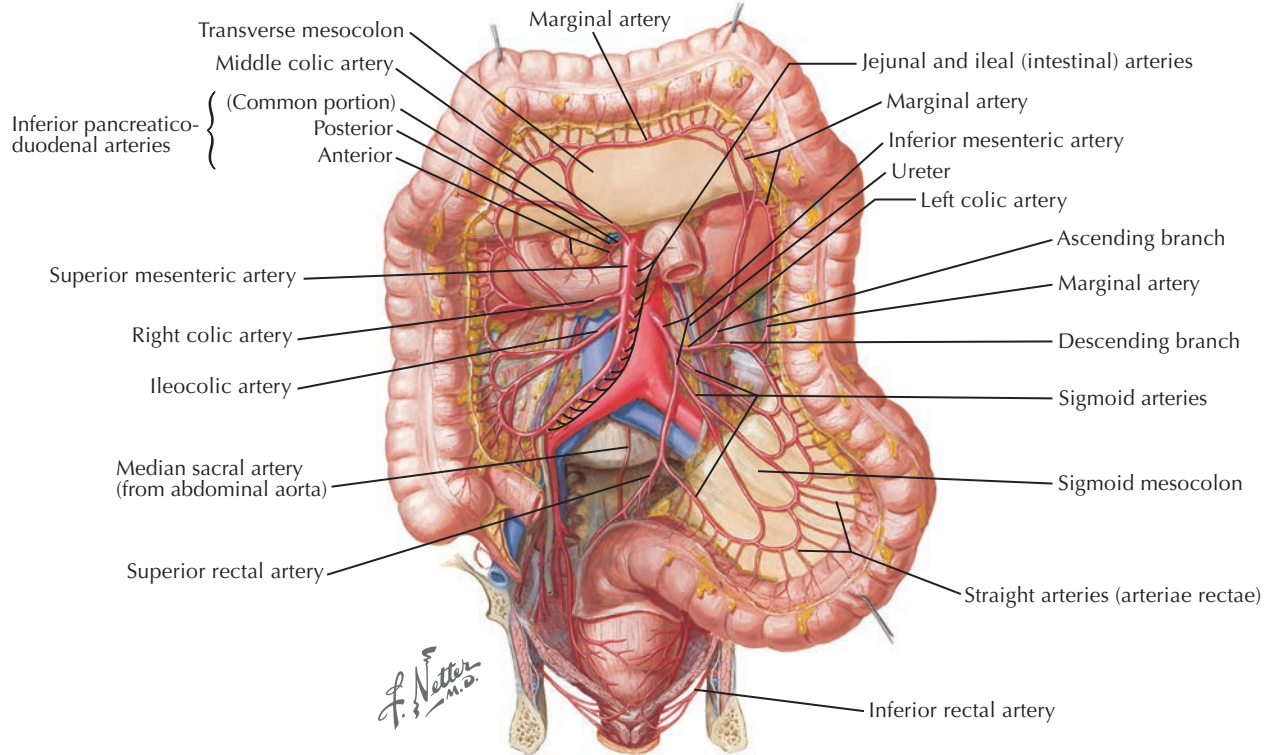
The anatomy of the vascular supply to the colon is demonstrated in [Figure 22-2](#). Knowledge of these vessels, the autonomic nerves, and the lymphatic drainage, as well as its relationship to the spleen, pancreas, kidney, and ureter, is required for successful completion of the left hemicolectomy ([Figs 22-3](#) and [22-4, A](#)).

The arterial blood supply to the left colon is derived from the IMA, which is the most distal of the three midline branches of the abdominal aorta. The ascending left colic or left colic artery is the first branch of the IMA. This supplies the descending colon and the splenic flexure, via the marginal artery of Drummond. The marginal artery joins the middle colic branch of the superior mesenteric artery in the midtransverse colon (see [Fig. 22-2, A](#)). The arterial supply to the splenic flexure is subject to a great degree of variability ([Fig. 22-4, A](#)). The marginal artery may be augmented by a second arcade, located more proximally in the mesocolon, known as the *arc of Riolan*. Also, both the marginal artery of Drummond and the arc of Riolan may be absent. Therefore, if the IMA and its branches have been ligated, it is essential to assess the vascularity of the colon at the proximal resection margin intraoperatively to ensure an adequate blood supply to the anastomosis.

Distally, branches of the IMA supply the sigmoid colon and vary greatly in number. The IMA itself proceeds to pass over the pelvic brim and thereby changes its name to the superior rectal artery, at which point it bifurcates and supplies the majority of the rectum.

Venous drainage of the left colon and hindgut is through tributaries of the inferior mesenteric vein (IMV) (see [Fig. 22-2, B](#)). The IMV lies in the base of the left mesocolon and passes posterior to the lower border of the pancreas, just lateral to the 4th portion of the duodenum. Under the pancreas, the IMV joins the splenic vein and superior mesenteric vein to form the portal vein. The IMV is significant in colorectal disease because it tethers the left colon, and high ligation is necessary for full left colon mobilization. Division of the IMV 1 inch (2.5 cm) below the inferior border of the pancreas provides several inches of extra mobility, often assisting the creation of a tension-free anastomosis ([Fig. 22-4, B and C](#)).

A. Arteries of large intestine. Note the proximity of the left ureter to the IMA trunk and branches at the pelvic brim.



B. Veins of large intestine. Note the proximity of the IMV to the lateral border of the fourth part of the duodenum and the inferior border of the body of the pancreas.

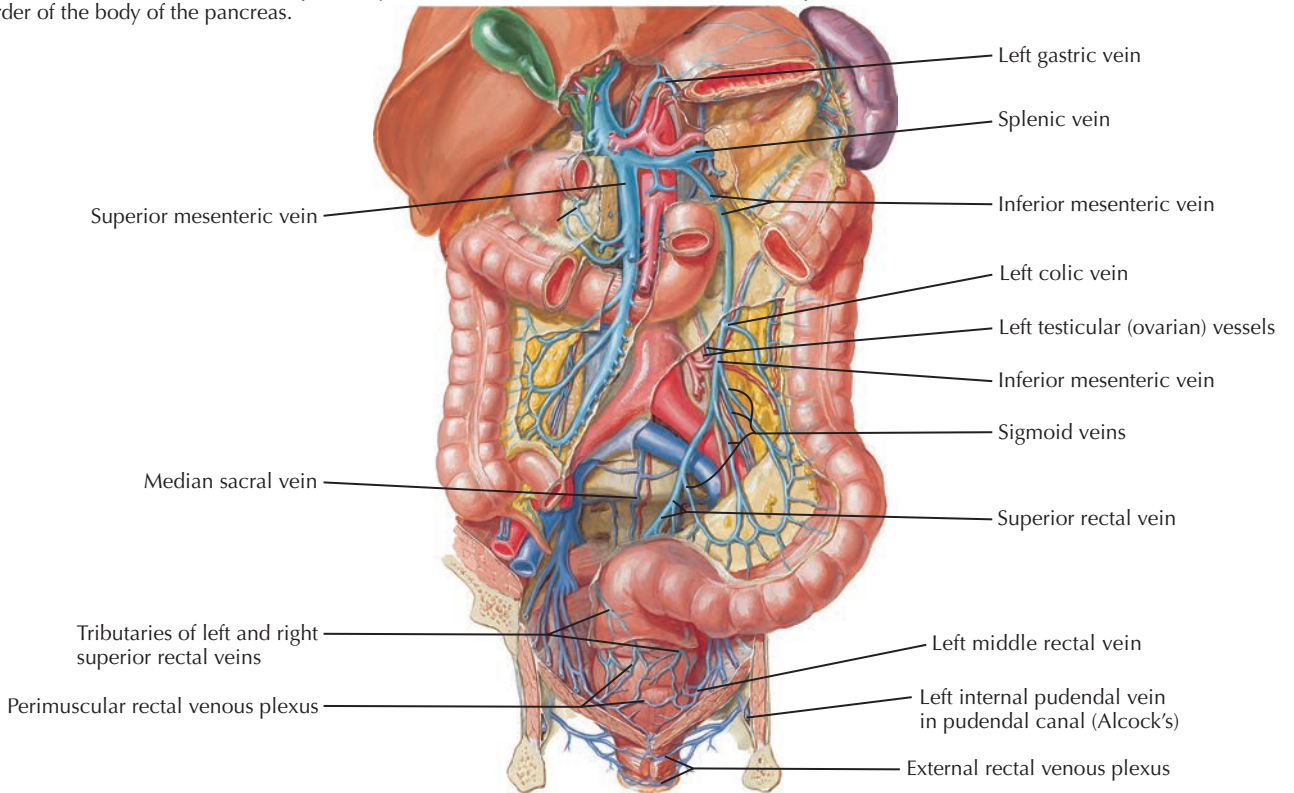
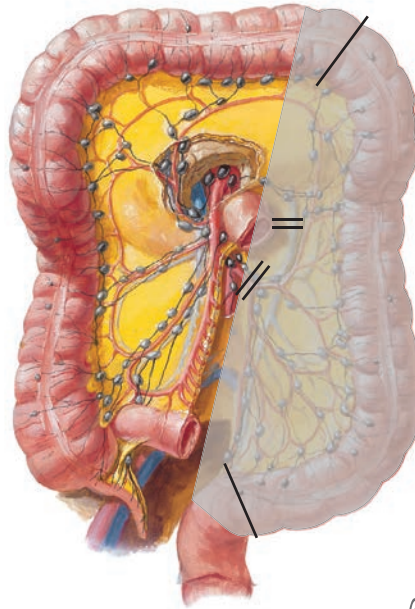


FIGURE 22-2 Vascular supply to colon. *IMA*, Inferior mesenteric artery; *IMV*, inferior mesenteric vein.

A. Left-sided resection pattern. Shaded area denotes extent of intended lymph node harvest.

==
Indicate point of ligation for the IMA and IMV
——
Indicate division of the colon



B. Innervation of small and large intestines. Note the right and left hypogastric nerves, the superior hypogastric plexus, and the inferior mesenteric ganglion, artery, and plexus.

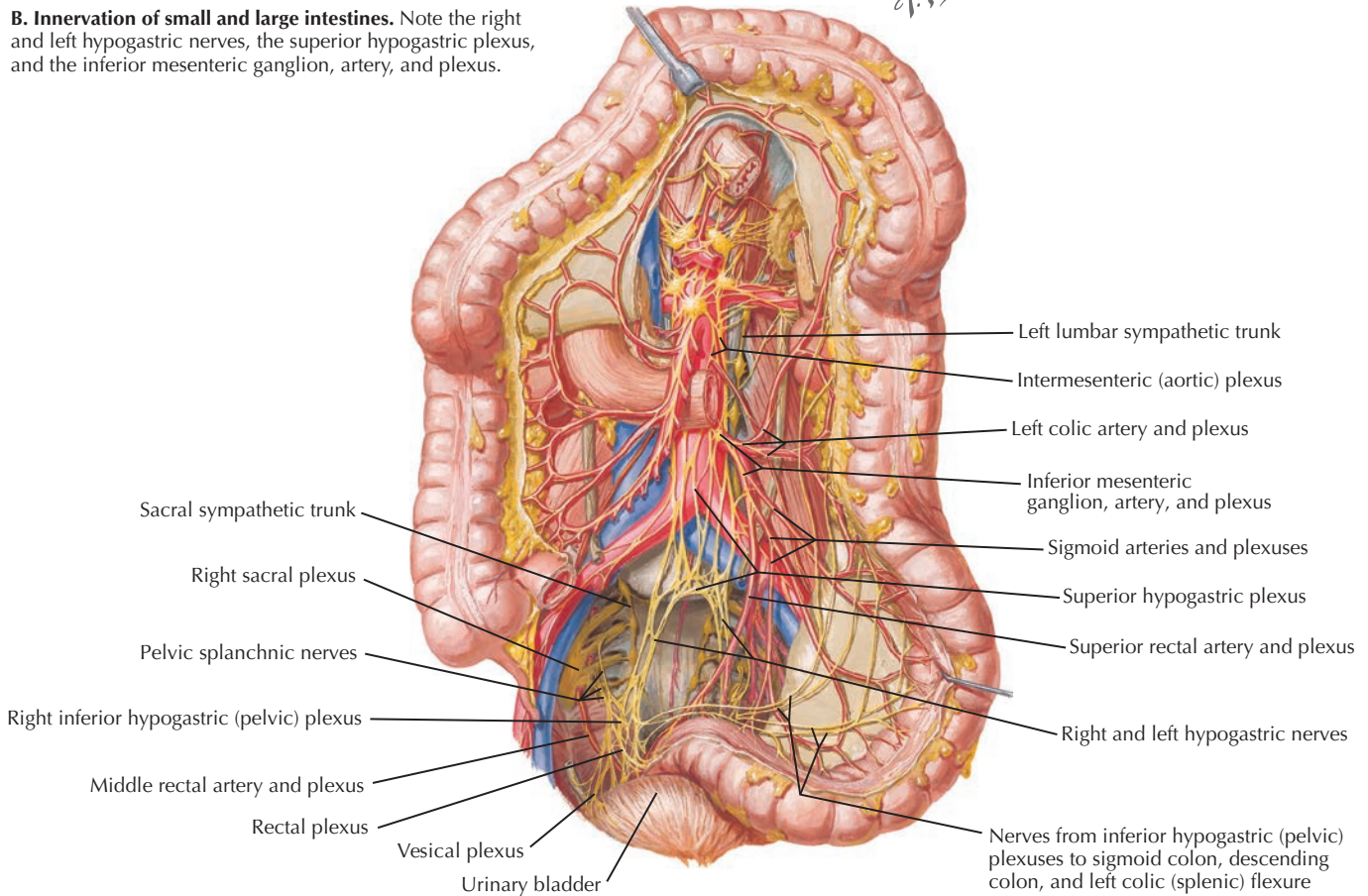
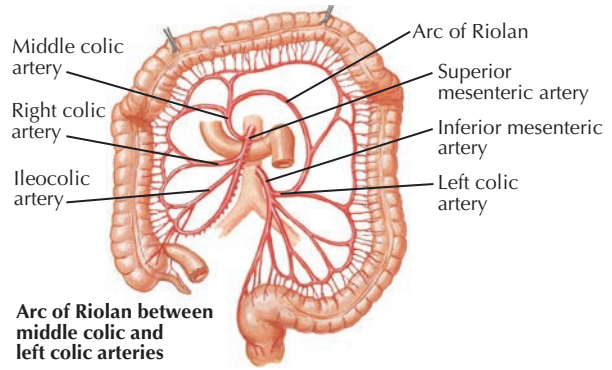
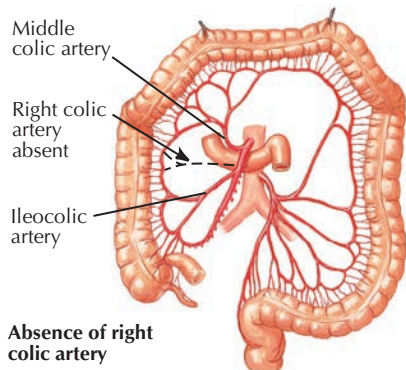
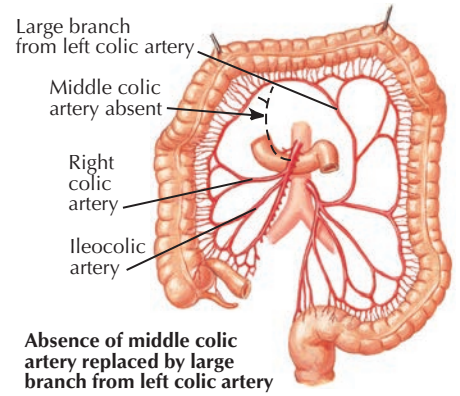
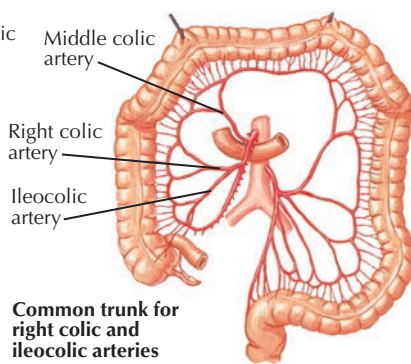
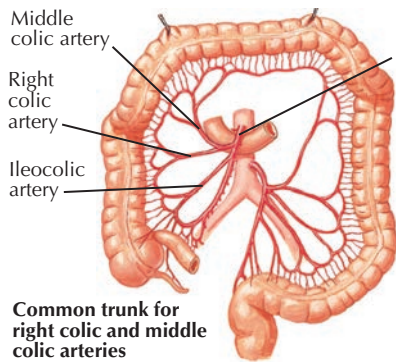
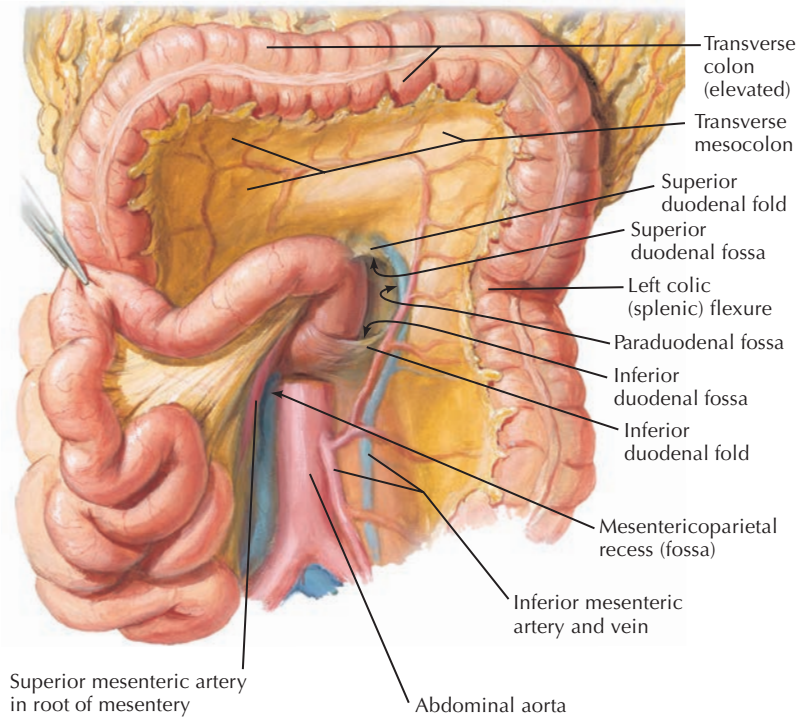


FIGURE 22-3 Left resection pattern; autonomic nerves and lymphatic drainage to colon. IMA, Inferior mesenteric artery; IMV, inferior mesenteric vein.

A. Vascular variations of the large intestine



B. Duodenal fossae and ligament of Treitz demonstrating proximity of IMV



F. Netter M.D.

C. Laparoscopic view of IMV and 4th part of duodenum

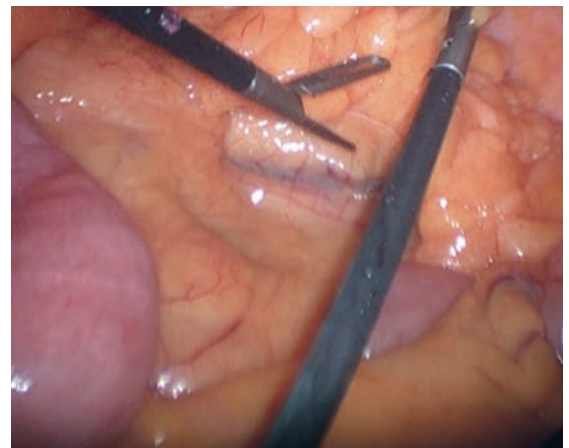


FIGURE 22-4 Vascular variations in colon; duodenal anatomy. IMV, Inferior mesenteric vein.

SPLenic FLEXURE

For left colonic resection, the sigmoid and descending colon, splenic flexure, proximal rectum, and distal transverse colon all require mobilization. Although there is no mandatory sequence in which this procedure should be undertaken, the authors usually prefer to commence at the splenic flexure.

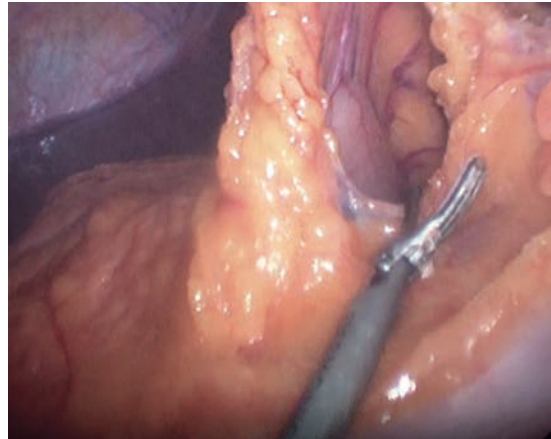
Although the splenic flexure is not mobilized routinely by all surgeons, this is an important skill to manage splenic flexure tumors and ischemic bowel and to allow sufficient mobility of the remaining proximal colon to fashion a safe, tension-free anastomosis. The flexure may be mobilized from a medial, lateral, or inferior approach, each of which may be used in laparoscopic or open surgery. Often, successful mobilization requires the use of a combination of approaches, allowing the surgeon to “cone in” to the most inaccessible section of the flexure.

Starting at the midtransverse colon, the greater omentum is elevated superiorly, demonstrating the avascular plane between omentum and transverse colon. At its left lateral extent, the omentum often exhibits adhesions to both the splenic flexure and the capsule of the spleen. Traction on the flexure may cause inadvertent trauma to the spleen. This complication may be mitigated by superior/cephalad retraction of the greater omentum in the midline and commencing dissection in the midtransverse colon. Opening this plane medially provides entry to the lesser sac, identified by visualization of the posterior wall of the stomach, and exposes the superior aspect of the transverse mesocolon (Fig. 22-5, A).

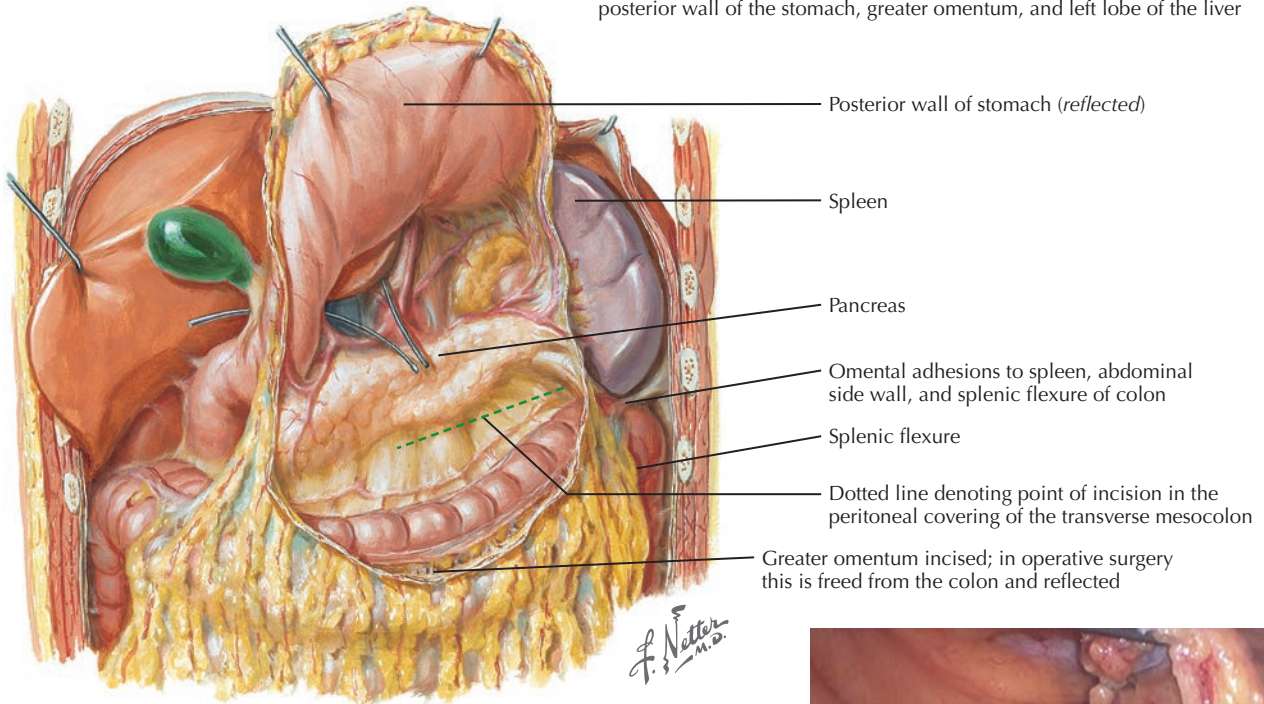
As with the lateral descending and sigmoid mobilization, there is a line of reflection between the parietal and visceral peritoneum. This line is less easy to see than the white line of Toldt but is present nevertheless (Fig. 22-5, B). The peritoneum must again be incised just above this line of reflection (closer to the colon). Mobilization too far from the retroperitoneum (too close to the colon) makes a defect through the mesentery of the colon. While mobilizing, attention must be paid to the jejunum, which is often only a layer of peritoneum away from the area of dissection. Superior mobilization is complete when the colon to the left of the midline is fully freed from its superior attachments.

Full mobilization of the splenic flexure requires division of the IMV. The inferior approach to the splenic flexure uses this as the starting point. With the transverse colon retracted superiorly and the small bowel retracted to the patient's right, the 4th part of the duodenum and ligament of Treitz are visualized (see Figs. 22-4, B and C, and 22-5, C). This approach exposes the IMV inferior to the vessel passing posterior to the pancreas. Once this has been divided, with Toldt's fascia identified, mobilization of the proximal descending colon continues from medial to lateral, through the mesocolon to the left lateral side wall. The retroperitoneum, gonadal vessels, and ureter are protected deep to the dissection, and the mesocolon and colon are preserved anteriorly.

Toldt's fascia continues superiorly, *posterior* to the body of the pancreas. Therefore, at the inferior border of the pancreas, the surgeon must cease to use this as the plane of dissection and instead release the transverse mesocolon from the anterior surface of the pancreas. This is most readily achieved toward the tail of the pancreas. In doing so, the lesser sac is entered. The lateral attachments are then divided, and the greater omentum is freed from the colon as previously described.

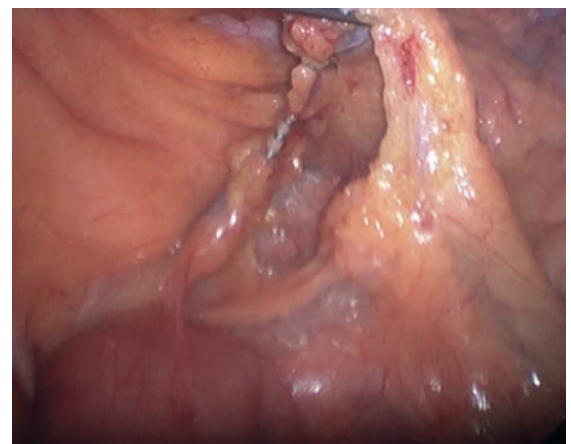


A. Laparoscopic view of the lesser sac displaying the transverse colon, posterior wall of the stomach, greater omentum, and left lobe of the liver



----- Transverse mesocolic reflection

B. Omental bursa (stomach reflected). Attachments of greater omentum and splenic flexure and spleen as well as pancreas. Note the dotted line indicates the line of incision in the visceral peritoneum of the transverse mesocolic reflection to allow full mobilization of the splenic flexure and distal transverse colon.



C. IMV skeletonized and clipped prior to division

FIGURE 22-5 Splenic flexure. IMV, Inferior mesenteric vein.

SIGMOID AND DESCENDING COLON

The left colon, as a part of the hindgut, originated as a midline structure. Through developmental rotation, however, the left colon has come to reside on the left side of the abdominal cavity, with the descending colon/mesocolon adherent to the parietal peritoneum overlying the retroperitoneum. The junction of parietal peritoneum and retroperitoneum is known as Toldt's fascia, or the white line of Toldt. Dissection at this junction mobilizes the mesocolon and restores the left colon to the midline.

The sigmoid colon may be mobilized by starting on the medial or lateral side. When the correct planes are defined, Toldt's fascia is carefully preserved. The left gonadal vessels, left ureter, and para-aortic autonomic nerves are posterior to this layer and should therefore be protected. In open surgery, this is best performed from the lateral aspect, where the "white line of Toldt" indicates the reflection of the parietal and visceral peritoneum. The peritoneum should be incised just above this line. The sigmoid mesocolon is then elevated from the retroperitoneum under slight tension and mobilization continued medially.

The peritoneum is scored proximal and distal to the inferior mesenteric artery. This approach allows the origin of the IMA to be encircled before division (Fig. 22-6), and it is the first step in a laparoscopic medial-to-lateral approach. Having confirmed the plane of dissection and preservation of the ureter in the retroperitoneum, the surgeon continues dissection laterally to the lateral peritoneal attachment.

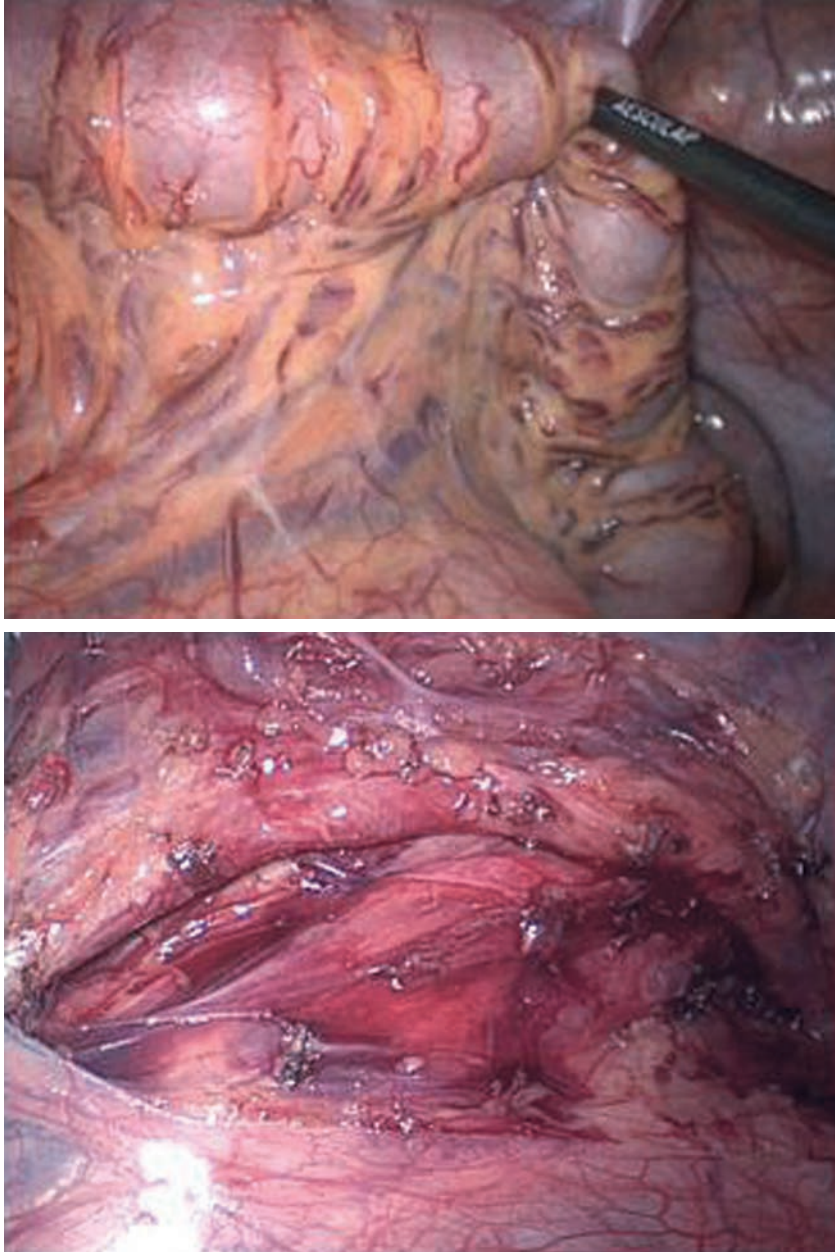
Rather than aiming for flush ligation at its origin, a 1- to 2-cm length of the IMA should be preserved, to ensure that the superior hypogastric plexus of the autonomic nervous system is not inadvertently damaged where it encircles the IMA (Fig. 22-6). For tumors of the left colon, the IMA should be divided proximal to the takeoff of the left colic artery to ensure a full lymphadenectomy.

UPPER MESORECTAL MOBILIZATION, TRANSECTION, AND ANASTOMOSIS

Although by definition, no rectum is resected in a left hemicolectomy, it is often necessary to mobilize the proximal rectum to allow the passage of the circular stapling devices for a stapled anastomosis, or to ensure a good blood supply to the distal component of the anastomosis. This approach is covered in detail in Chapter 24.

Once an adequate distal margin has been obtained, the rectum may be transected. The specimen is removed from the field.

If the IMA has been preserved and there is adequate length of distal sigmoid colon, a hand-sewn anastomosis may then be performed. If the distal transection line is at or below the pelvic brim, it is more straightforward to perform a stapled anastomosis.



IMA before (*top*) and after (*bottom*) skeletonization

FIGURE 22-6 Left hemicolectomy: skeletonization. *IMA*, Inferior mesenteric artery.

SUGGESTED READINGS

Farquharson M, Moran B. Farquharson's textbook of operative general surgery, 9th ed. Philadelphia; 2005.

Kirk RM, Winslet MC. Essential general surgical operations, 2nd ed. New York: Churchill Livingstone; 2007.

Sinnatamby CS. Last's anatomy: regional and applied, 12th ed. New York: Churchill Livingstone; 2011.

Transverse Colectomy

Eric L. Marderstein and Mujjahid Abbas

INTRODUCTION

Transverse colectomy is an uncommon procedure. Potential indications for transverse colectomy include transverse colon cancer, segmental inflammatory bowel disease, and segmental transverse colon ischemia. In most cases, however, an extended right hemicolectomy with anastomosis of terminal ileum to the distal transverse colon or the descending colon is preferred, secondary to the more robust vascular supply. If a surgeon is planning to perform an isolated transverse colectomy or as part of a subtotal colectomy, it is important that the anatomy of the transverse colon and the particular pitfalls of the surgery are well understood.

SURGICAL PRINCIPLES

Transverse colectomy requires detailed knowledge of the vascular supply of the colon, the anatomy of the hepatic and splenic flexures, and the relationship of the omentum to the colon and stomach. The goal of the operation is to resect the transverse colon and create a tension-free, well-vascularized bowel anastomosis. The procedure usually involves the following steps:

1. Mobilization of hepatic flexure
2. Mobilization of splenic flexure
3. Dissection of greater omentum off transverse colon, or resection of the omentum
4. Division of middle colic artery and vein
5. Proximal division of the colon
6. Distal division of the colon
7. Reanastomosis of the divided bowel

The procedure is somewhat unique in that steps 1 to 4 can be performed in any order desired by the surgeon. This is particularly important for the distal colonic segment, which will be perfused retrograde from the inferior mesenteric artery through the marginal artery of Drummond.

ANATOMY FOR TRANSVERSE COLECTOMY

Hepatic Flexure

The hepatic (or right) flexure is the anatomic name for the bend in the colon as it transitions from the ascending colon to the transverse colon. The hepatic flexure usually contains only small, unnamed vessels, although in some patients there are larger vessels that require ligation. Certain disease states, such as portal hypertension with retroperitoneal collateralization, can cause the hepatic flexure to become quite vascular.

The intraoperative photograph demonstrates the hepatic flexure in situ (Fig. 23-1, A). The liver is cephalad and the right kidney is posterior. The ascending colon is mobilized from its lateral attachments at the white line of Toldt. As the ascending colon is mobilized medially, the dissection is complete when the duodenum is identified and preserved posteriorly with the retroperitoneum. Aggressive traction near the end of the mobilization may cause avulsion injury to the middle colic vein, which results in difficult-to-control hemorrhage.

An alternative and more common strategy for mobilization of the hepatic flexure is to begin by dividing the lateral attachments of the ascending colon along the white line of Toldt. The dissection then proceeds distally around the hepatic flexure at the ascending-transverse junction and continues medially.

Splenic Flexure

The splenic (or left) flexure of the colon is the bend in the bowel where the distal transverse colon transitions to the descending colon. To mobilize the splenic flexure, the avascular lateral attachments of the descending colon to the retroperitoneum must be divided along the white line of Toldt. The splenocolic (lienocolic) ligament is the superior extension of this and forms connective bands connecting the apex of the splenic flexure to the inferior aspect of the splenic capsule. The anatomic relations of the splenic flexure in situ are shown in Figure 23-1, B and C.

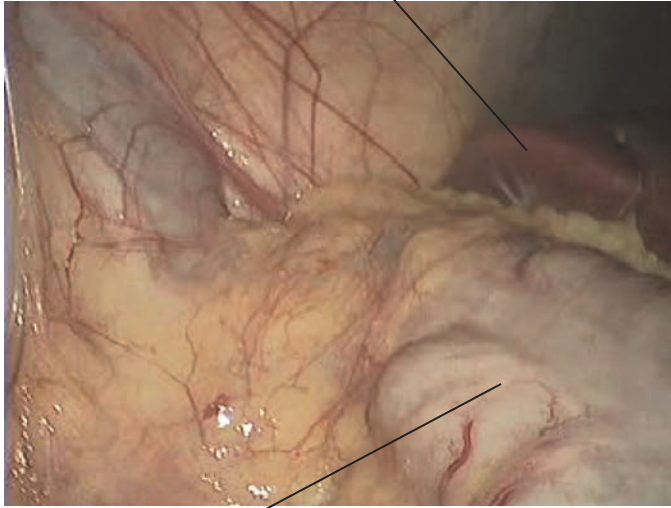
The dissection continues from distal to proximal on the descending colon in the proper plane along the white line of Toldt, as appropriate medial traction is applied. Aggressive downward traction on the flexure can cause avulsion injury to the splenic capsule, resulting in dangerous bleeding that may rarely require splenectomy. Variation in the splenic flexure redundancy, angle, and location can greatly affect the difficulty in mobilization. A low-lying, nonredundant flexure is much easier to mobilize than a high, redundant colon that is closely adherent to the spleen.

For difficult splenic flexures in open surgery, the incision must be of adequate size to provide optimal lighting and retraction. In laparoscopic surgery, extralong instruments, additional working ports, and changes in patient position may be necessary.

Dorsally, attachments to the kidney and filmy adhesions to the tail of the pancreas must be freed to supply adequate mobilization of the splenic flexure. The renocolic ligament is connective tissue posteriorly adherent from the colon to the kidney and must be divided to complete the dissection.

A. Hepatic flexure in situ

Right lobe of liver

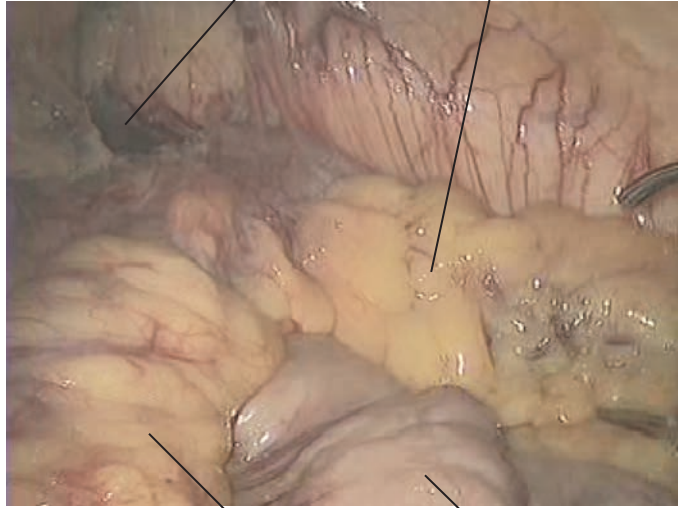


Transverse colon

C. Splenic flexure

Spleen

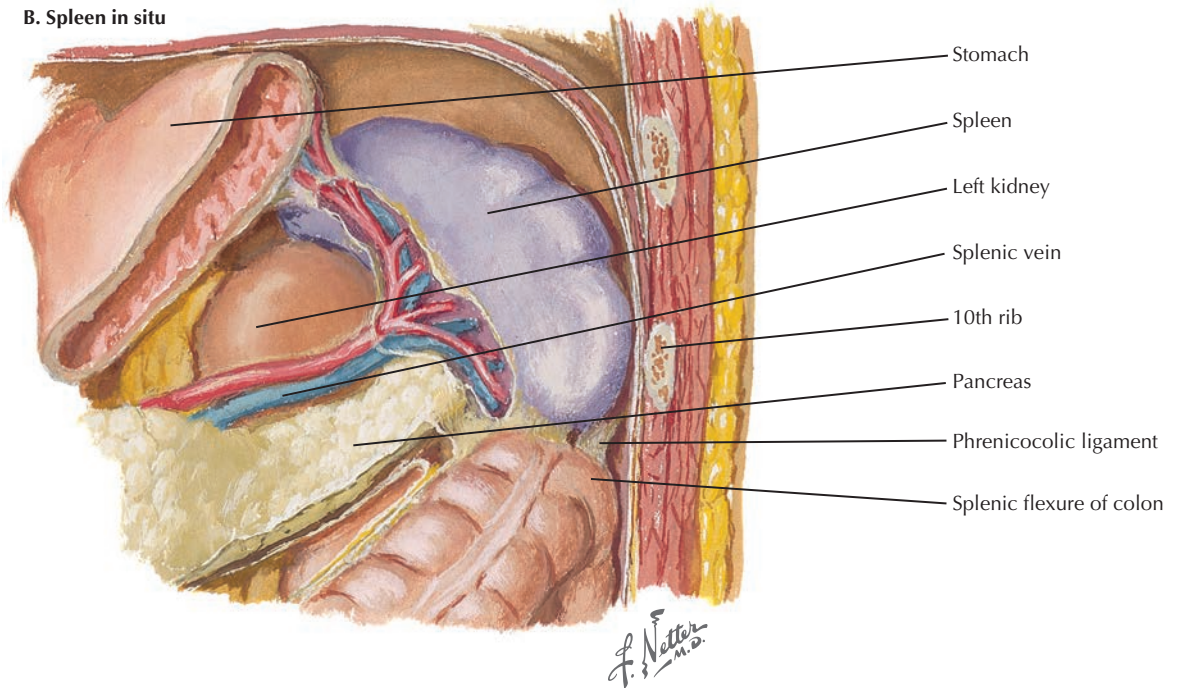
Descending colon



Transverse colon

Small bowel

B. Spleen in situ



Stomach

Spleen

Left kidney

Splenic vein

10th rib

Pancreas

Phrenicocolic ligament

Splenic flexure of colon

FIGURE 23-1 Hepatic and splenic flexures.

Relationships of Greater Omentum to Transverse Colon and Stomach

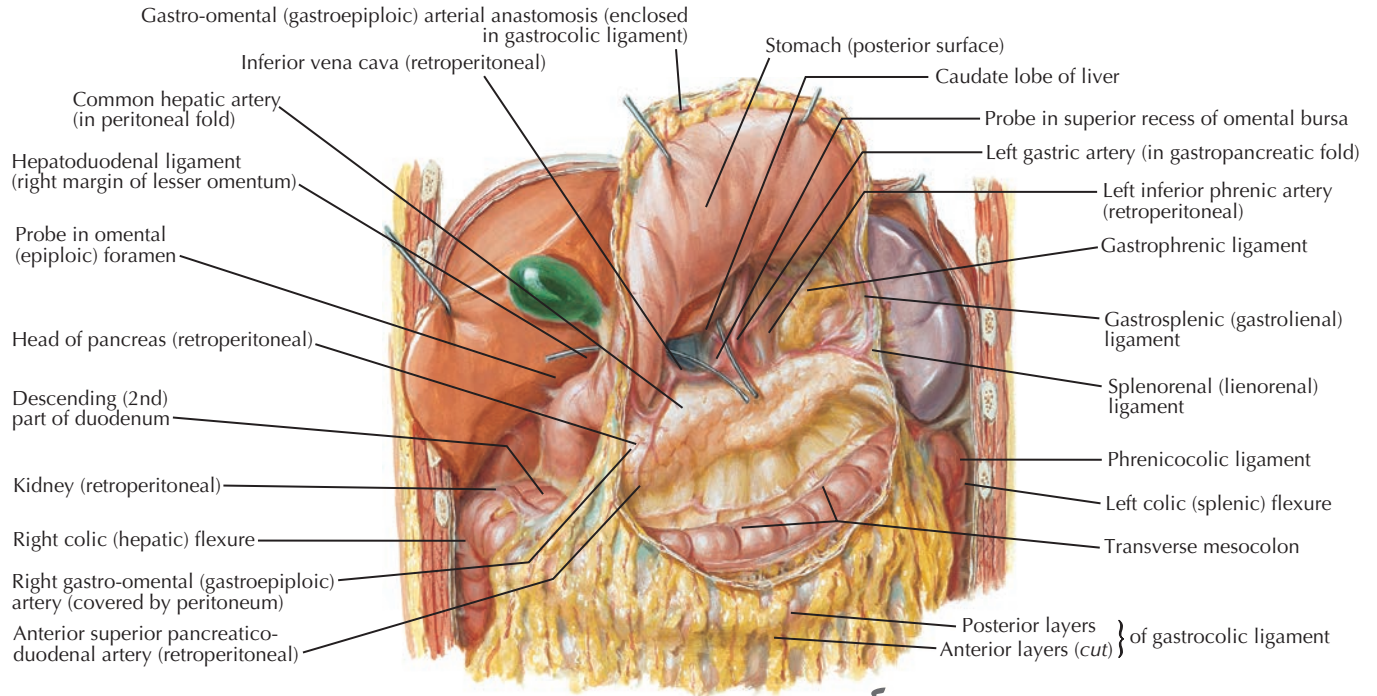
Before dissecting the mesentery of the transverse colon, the surgeon may prefer to dissect the omentum from the colon. Performing this step before mesenteric dissection provides better control of the mesenteric vessels.

The surgeon must decide whether to resect the greater omentum with the specimen or to preserve it; in general the decision depends on whether the procedure is being performed for malignancy. The omentum is a common site for intraabdominal cancer recurrence. The authors' practice is to resect the omentum in patients with transverse colon cancer. In colitis, separation of the omentum from the colon can be difficult because of inflammation. Preservation of the omentum can result in bleeding or inadvertent colon perforation; thus, resection of the omentum in severe colitis can be helpful. Some surgeons resect the greater omentum as a matter of routine.

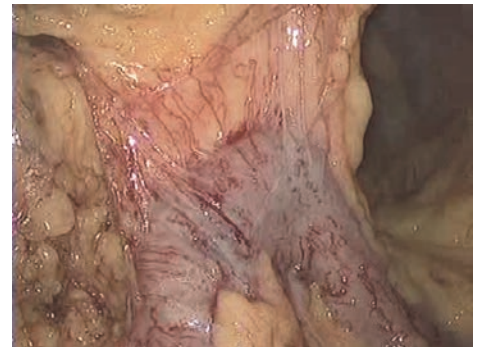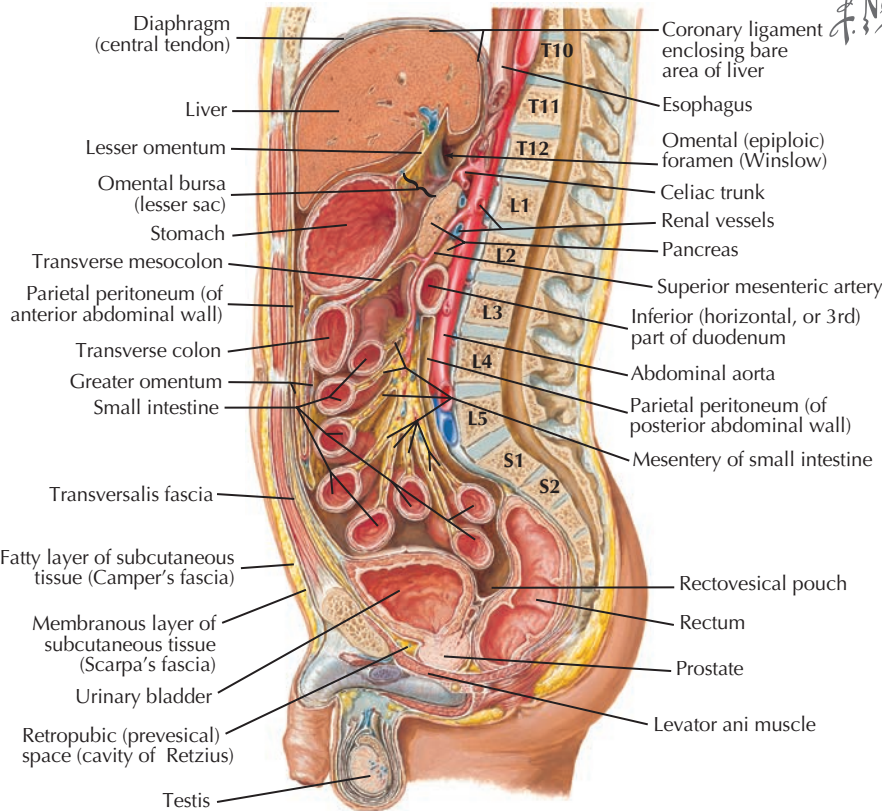
The omentum originates from the greater curvature of the stomach and continues anteriorly and caudad over the top of the transverse colon. If the omentum is to be resected, the gastroepiploic artery, which parallels the greater curve of the stomach, is preserved while the blood vessels of the omentum itself require ligation. The stomach is reflected cephalad to provide entry to the lesser sac (Fig. 23-2, A). If the omentum is to be preserved, the surgeon must dissect it off of the colon in the anatomic plane and reflected cephalad, making sure the colon is not injured in the process. A thin, filmy plane without vascular supply is noted between the transverse colon and the omentum and should be entered and can be followed into the lesser sac.

The plane of dissection in sagittal view is illustrated in Figure 23-2, B, which clearly shows the transverse colon mesentery originating off the anterior border of the pancreas. The dissection plane to separate the greater omentum off the transverse colon is shown in Figure 23-2, C. This mobilization is complete when the posterior wall of the stomach is clearly visualized and isolated from the mesentery of the transverse colon.

A. Omental bursa (stomach reflected)



B. Abdominal wall and viscera (parasagittal section)



C. Omentum and transverse colon

FIGURE 23-2 Greater omental and stomach in transverse colectomy. Vertebrae: L1, 1st lumbar; S1, 1st sacral; T10, 10th thoracic.

Middle Colic Artery and Vein

Division of the middle colic artery and vein are the most difficult aspect of a transverse colectomy because of the potential for rapid and difficult-to-control hemorrhage. The middle colic artery is the second branch of the superior mesenteric artery (SMA), after the inferior pancreaticoduodenal artery. The middle colic artery originates from the right lateral aspect of the SMA and classically bifurcates into right and left branches, although as many as five different branches are often noted. The classic arrangement of arteries to the large intestine is shown in [Figure 23-3](#). Although called the middle colic artery, it is generally oriented more to the patient's right than the middle ([Fig. 23-4, A](#)).

A number of anatomic variations of the middle colic arteries are possible, and a variation from normal is often seen. Several cadaver dissection studies have provided insight into the frequency of these anomalies. Some uncommon variations of the middle colic arteries within the SMA system are outlined in Chapter 21 (see [Fig. 21-3](#)). The middle colic is a short artery, with a mean length of 32 mm, sometimes presenting difficulties in transection. The view of the transverse colon with flexures and mesenteric vessels is best seen with a laparoscope ([Fig. 23-4, B](#)).

As previously stated, the middle colic artery and vein may be transected after the greater omentum has been dissected from the transverse colon or the omental arteries ligated and the lesser sac opened. A clear space to the patient's left of the middle colic artery is often used for retrocolic Roux limbs, such as those used for gastric bypass surgery (see Chapter 11). This space has been opened to facilitate subsequent division of the middle colic arteries ([Fig. 23-4, C](#)).

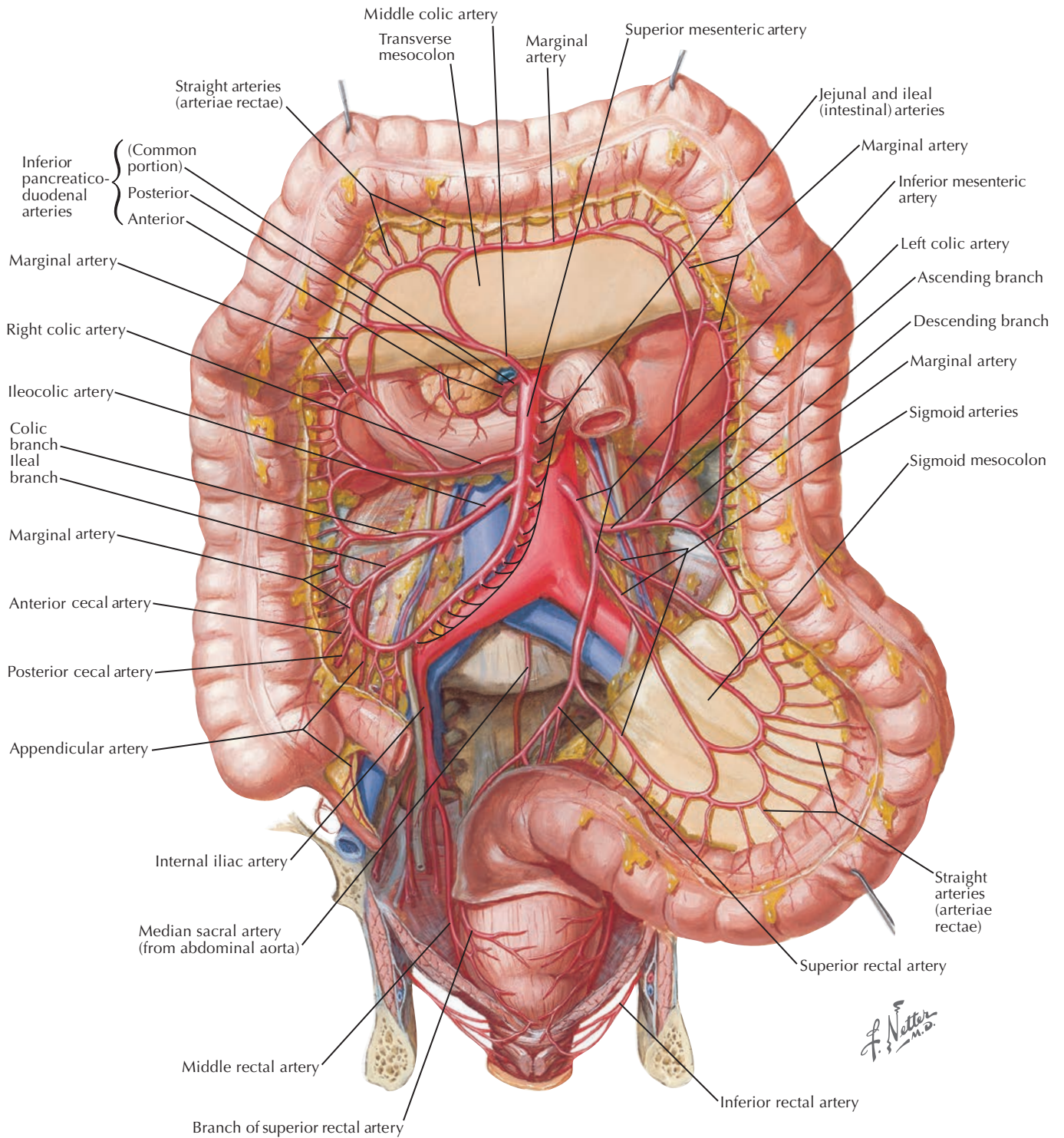
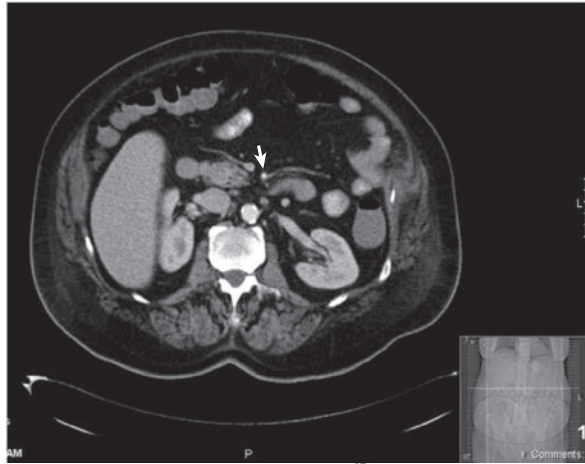


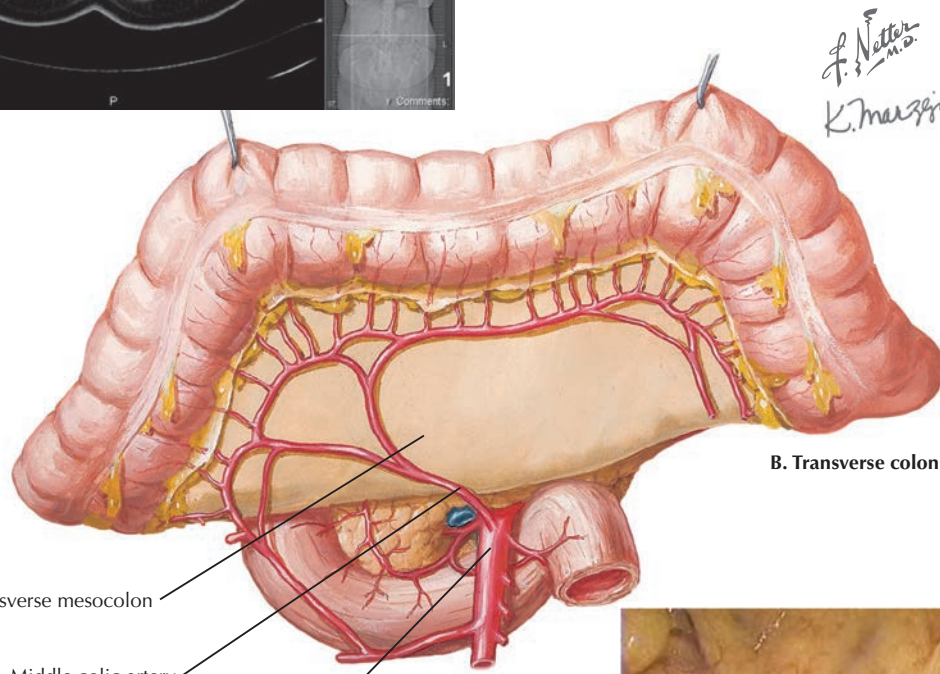
FIGURE 23-3 Arteries of large intestine.

COMPLETION OF TRANSVERSE COLECTOMY

Once both flexures are mobilized, the omentum dissected, and the middle colic artery and vein ligated, the bowel is divided to create a tension-free, well-vascularized anastomosis. The authors' preferred technique for bowel anastomosis in this situation is an end-to-end hand-sewn anastomosis. A stapled side-to-side, functional end-to-end anastomosis is possible but it can withstand greater tension, especially at the "crotch" of the anastomosis.



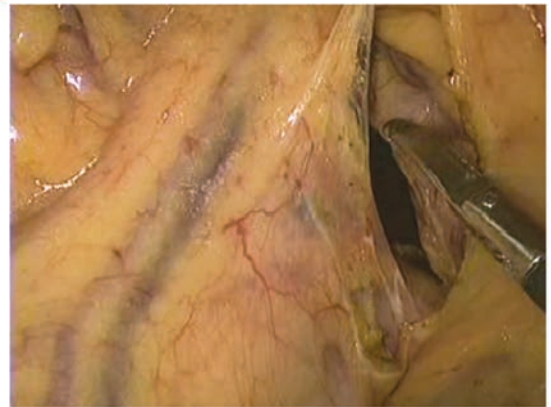
A. Origin of middle colic artery off of the superior mesenteric artery (arrow)



*F. Netter M.D.
K. Marzari*

B. Transverse colon

Transverse mesocolon
Middle colic artery
Superior mesenteric artery



C. Middle colic artery being prepared for division

FIGURE 23-4 Middle colic artery in transverse colectomy.

SUGGESTED READINGS

- Chitra R. Clinically relevant variations of the coeliac trunk. *Singapore Med J* 2010;51(3):216-9.
- Garcia-Ruiz A, Milsom JW, Ludwig KA, Marchesa P. Right colonic arterial anatomy: implications for laparoscopic surgery. *Dis Colon Rectum* 1996;39(8):906-11.
- Gerber SA, Rybalko VY, Bigelow CE, et al. Preferential attachment of peritoneal tumor metastases to omental immune aggregates and possible role of a unique vascular microenvironment in metastatic survival and growth. *Am J Pathol* 2006;169(5):1739-52.
- Lawrance RJ, Loizidou M, Cooper AJ, Alexander P, Taylor I. Importance of the omentum in the development of intraabdominal metastasis. *Br J Surg* 1991;78(1):117-9.
- McGory ML, Zingmond DS, Sekeris E, Ko CK. The significance of inadvertent splenectomy during colorectal cancer resection. *Arch Surgery* 2007;142(7):668-74.

Low Anterior Resection with Total Mesorectal Excision and Anastomosis



Conor P. Delaney

INTRODUCTION

Colon cancer is the second most common tumor in men and women in the Western world. Tumors occur most frequently in the rectum and sigmoid colon and are usually treated by resection and primary anastomosis. Surgery is the mainstay of therapy, and patients with positive nodal disease also require adjuvant chemotherapy.

Rectal cancer is a more challenging surgical problem than colon cancer, and its management is more complex. Since Miles' initial description of abdominoperineal resection in 1925, the main change in approach occurred when Dixon described the technique of anterior resection and reanastomosis for tumors of the upper rectum and distal sigmoid. The surgical principles involve wide resection of the rectum, including the entire investing fascia with the enclosed mesentery of the rectum. The results of total mesorectal excision (TME) indicate that complete excision with clear radial margins is important, and that local recurrence rates much lower than 10% can be achieved with good surgical technique.

SURGICAL PRINCIPLES

The current standards of care for patients with low rectal cancer include complete excision of the rectum and surrounding mesorectum, generally ensuring a minimal distal margin of 2 cm before a coloanal anastomosis is performed. In general, this procedure is performed in conjunction with a high ligation of the inferior mesenteric artery and vein and mobilization of the splenic flexure (see Chapter 22). The autonomic nerves are carefully protected. Patients with colon cancer require a minimum 5-cm proximal and distal margin, with at least 12 lymph nodes being harvested in the mesocolic excision. Patients with rectal cancer require a 1- to 2-cm margin depending on anatomy, tumor location, and tumor differentiation.

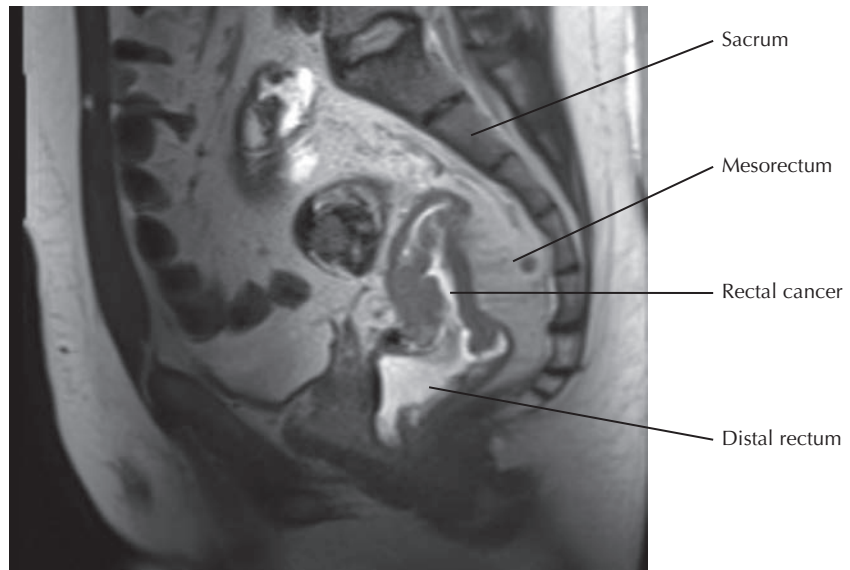
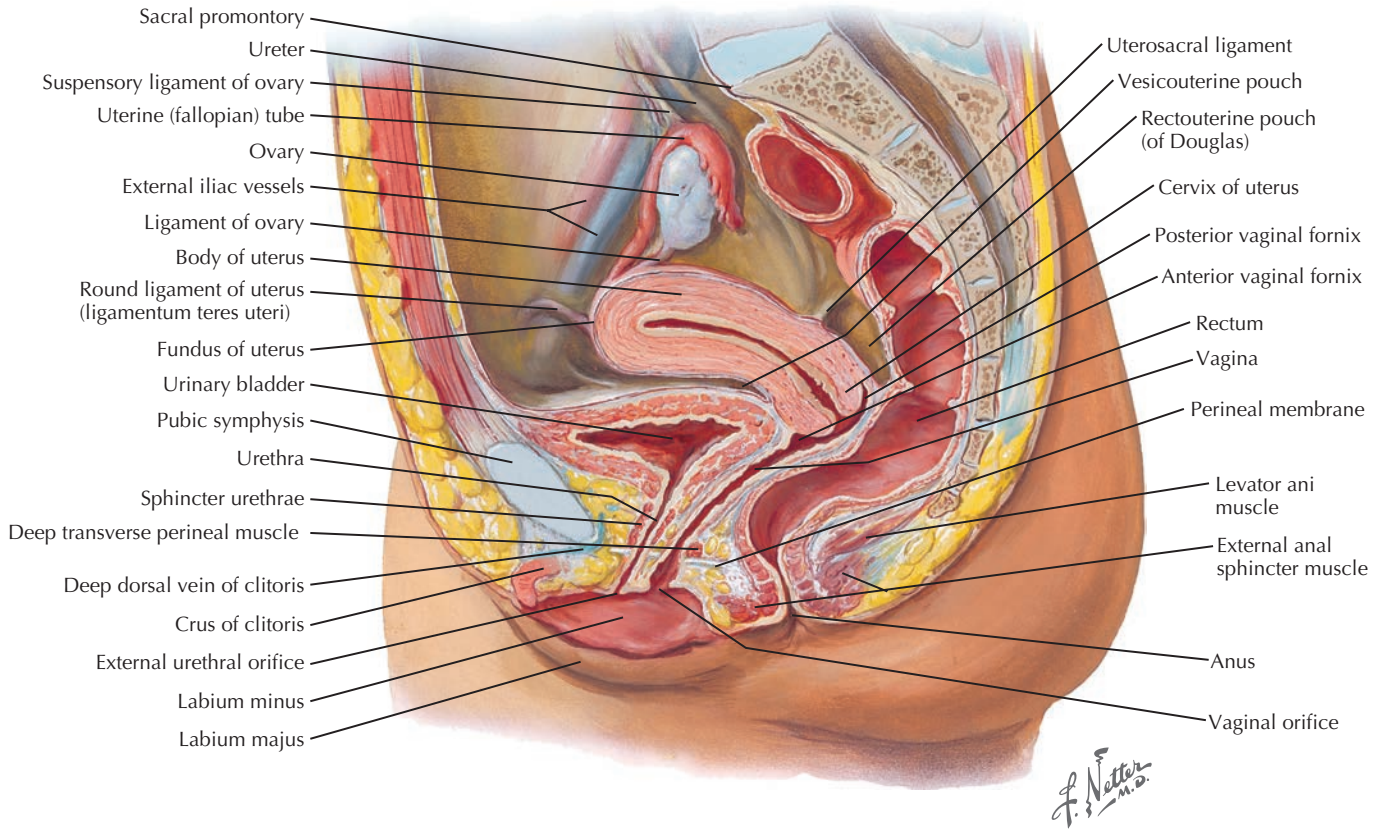
ANATOMY FOR PREOPERATIVE IMAGING

Preoperative imaging of rectal cancer is extremely important and helps define tumors that may threaten the circumferential resection margin, therefore requiring preoperative chemoradiation. Both sagittal and coronal views are obtained, and magnetic resonance imaging (MRI) is used more frequently because of the high-quality resolution obtained (Figs. 24-1 and 24-2). Ultrasound is also used in the assessment of rectal cancer and can provide excellent results for T staging (tumor infiltration), particularly of early T-stage lesions.

ANATOMY FOR COLONIC MOBILIZATION AND DISSECTION

The anatomy of the vascular supply to the colon is demonstrated in Figure 24-3. A knowledge of these vessels, the autonomic nerves, and the ureters is required before the surgeon begins the steps of the procedure (Figs. 24-4 and 24-5).

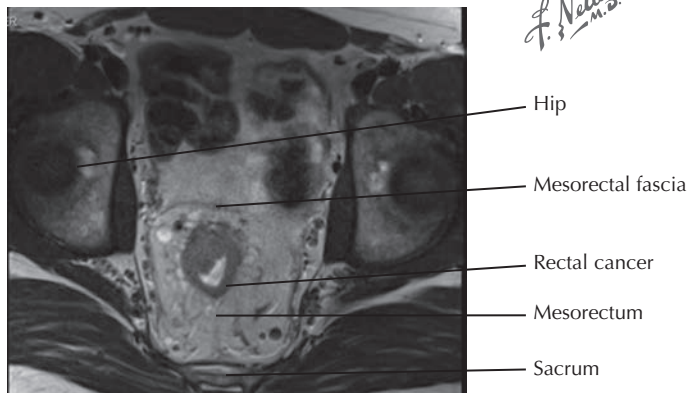
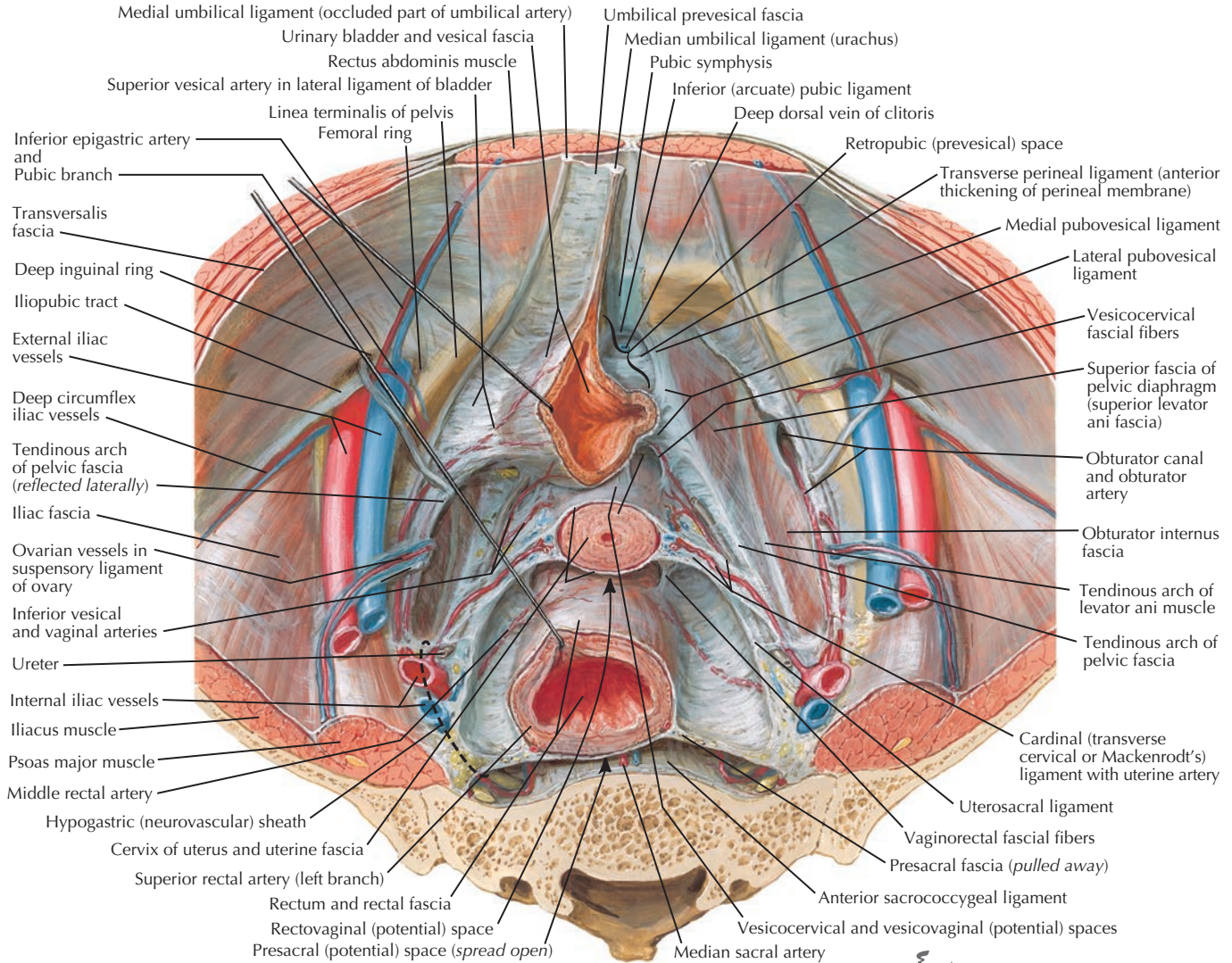
Median (sagittal) section



Sagittal section MRI showing a midrectal cancer

FIGURE 24-1 Pelvic viscera and perineum: female.

Female: superior view (peritoneum and loose areolar tissue removed)



Axial MRI showing rectal cancer, surrounding mesorectum, and mesorectal fascia

FIGURE 24-2 Endopelvic fascia and potential spaces: female.

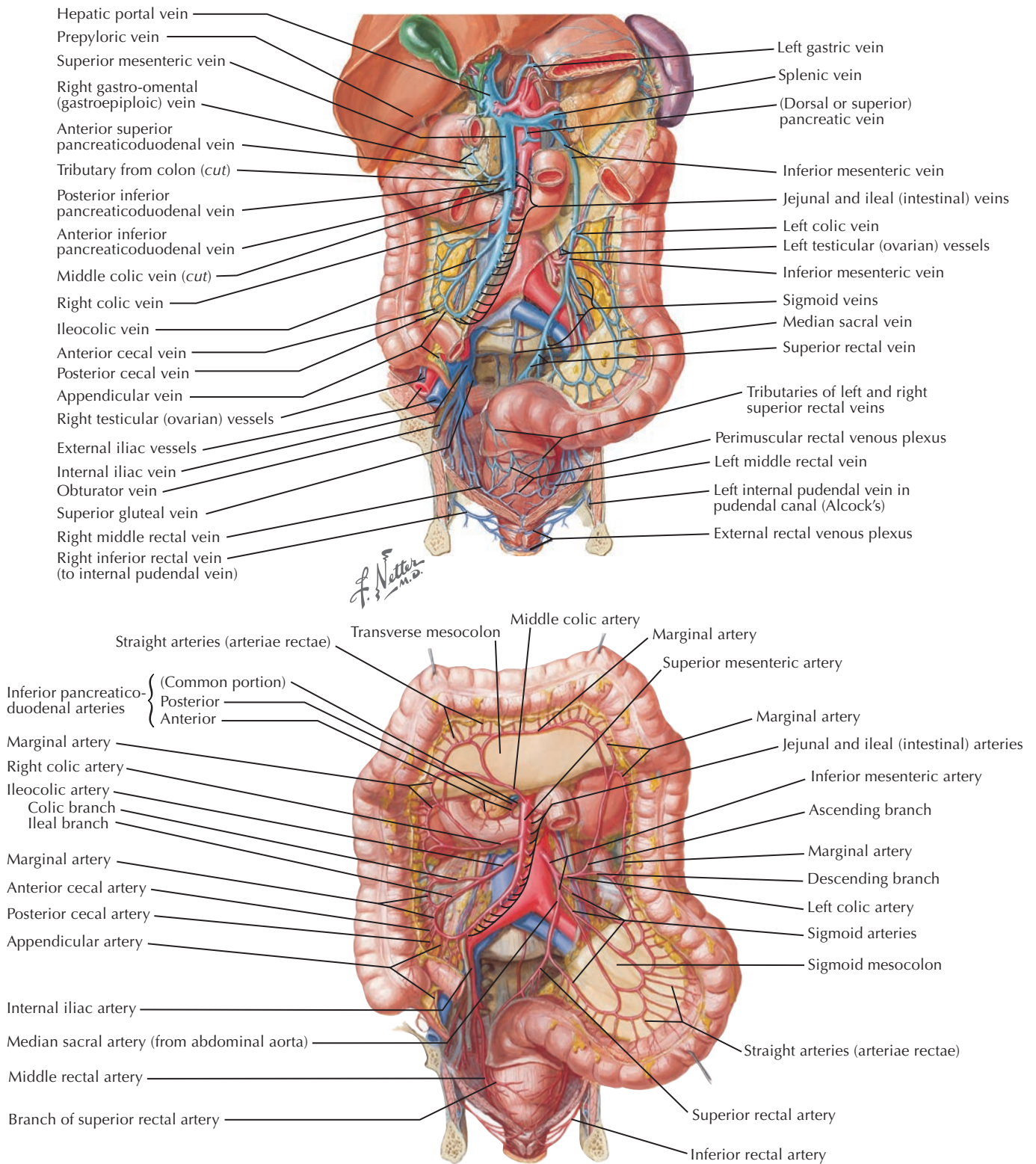


FIGURE 24-3 Arteries and veins of colon and rectum.

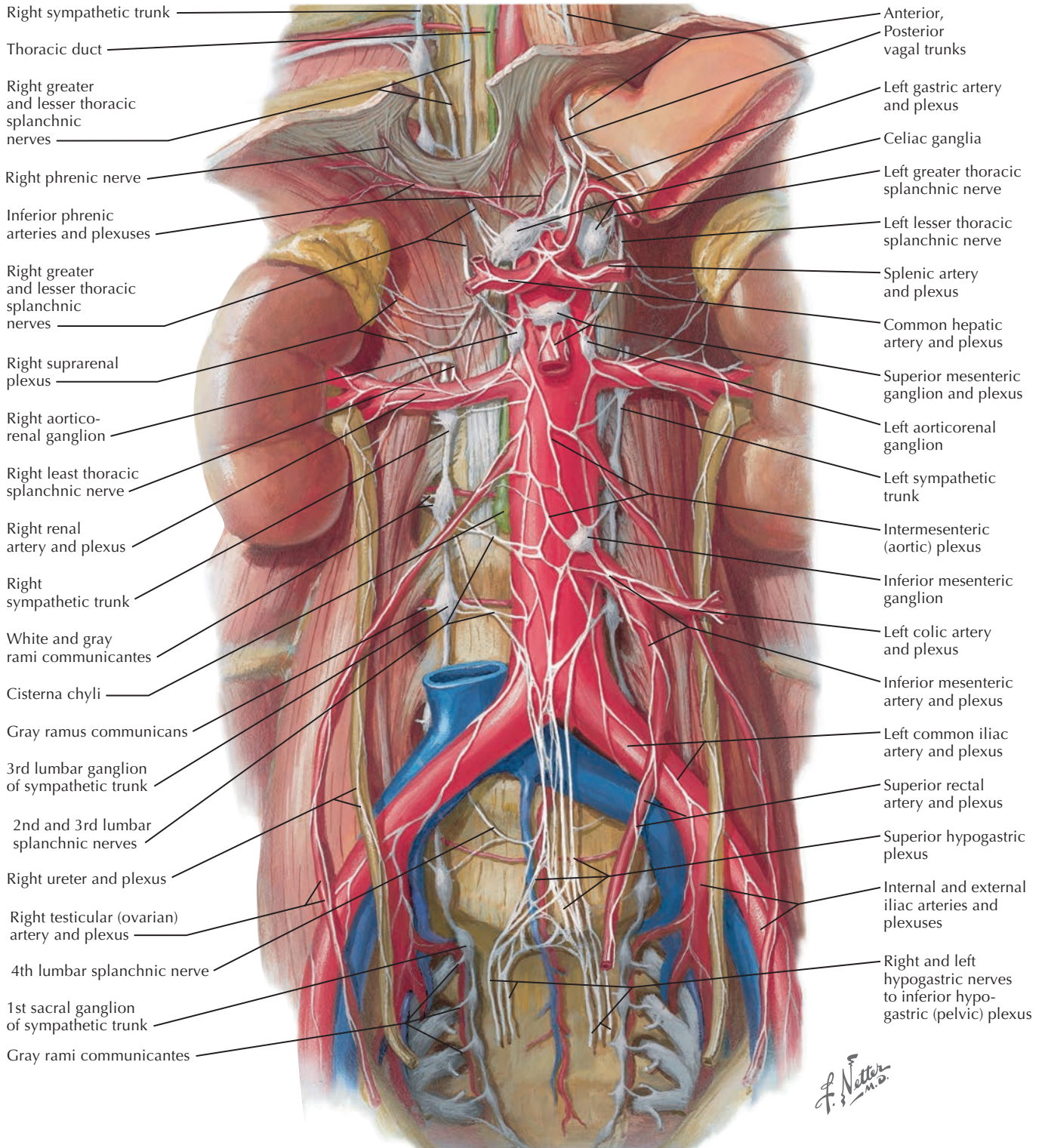


FIGURE 24-4 Autonomic nerves and ganglia of abdomen.

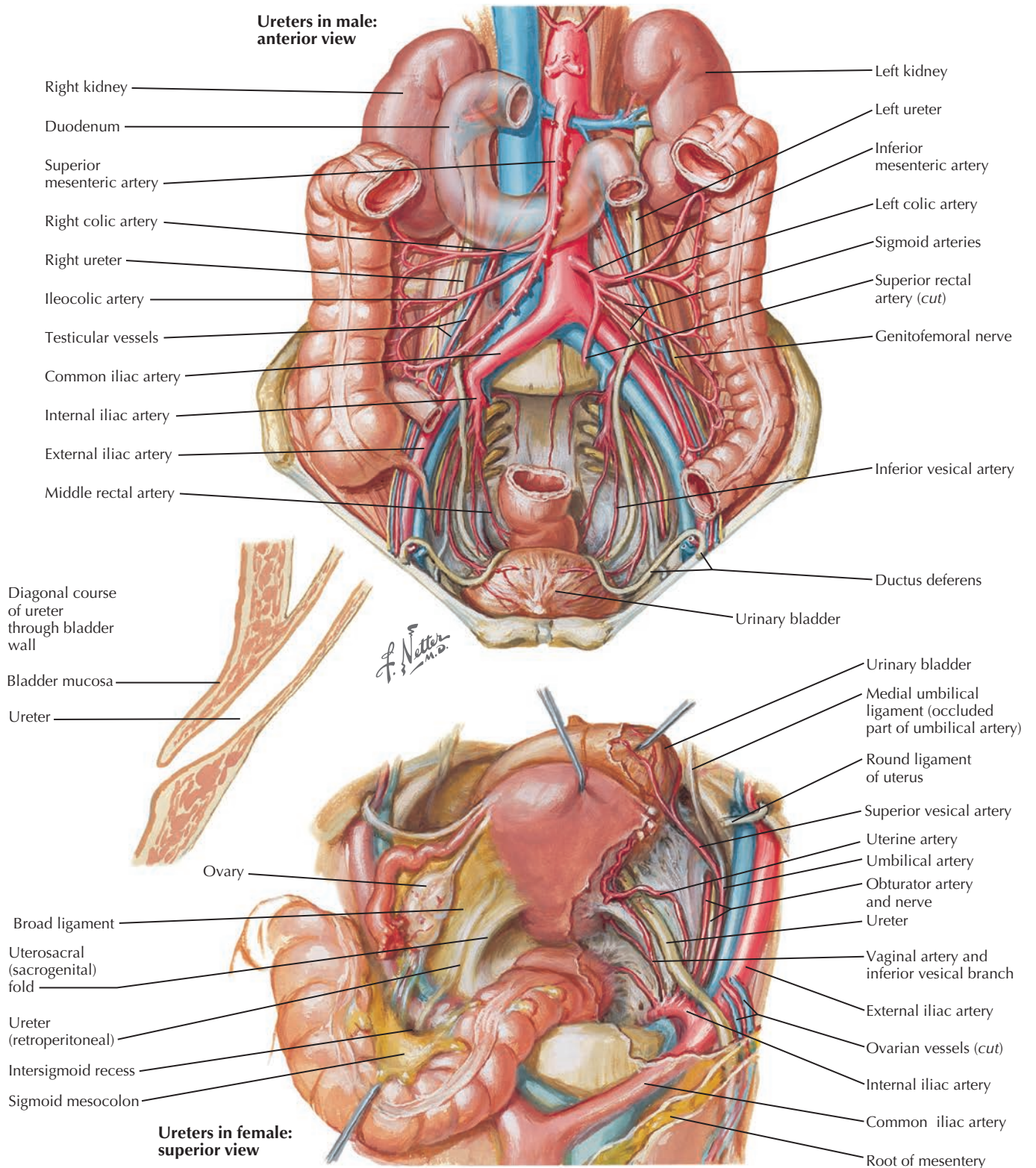
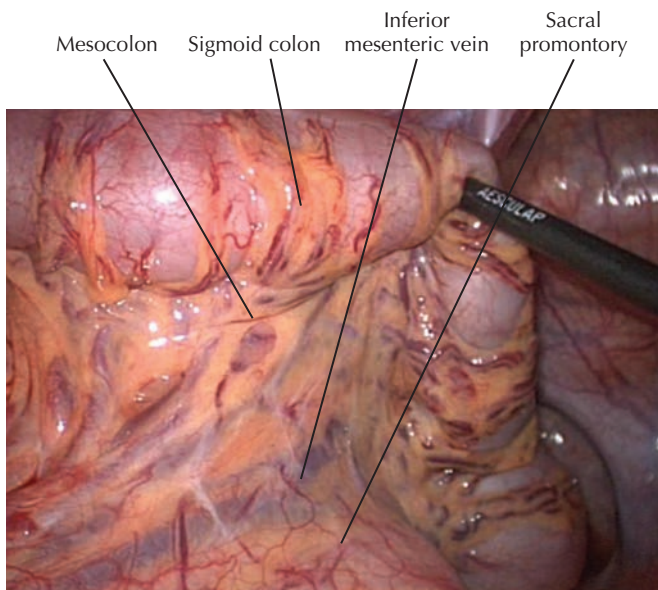
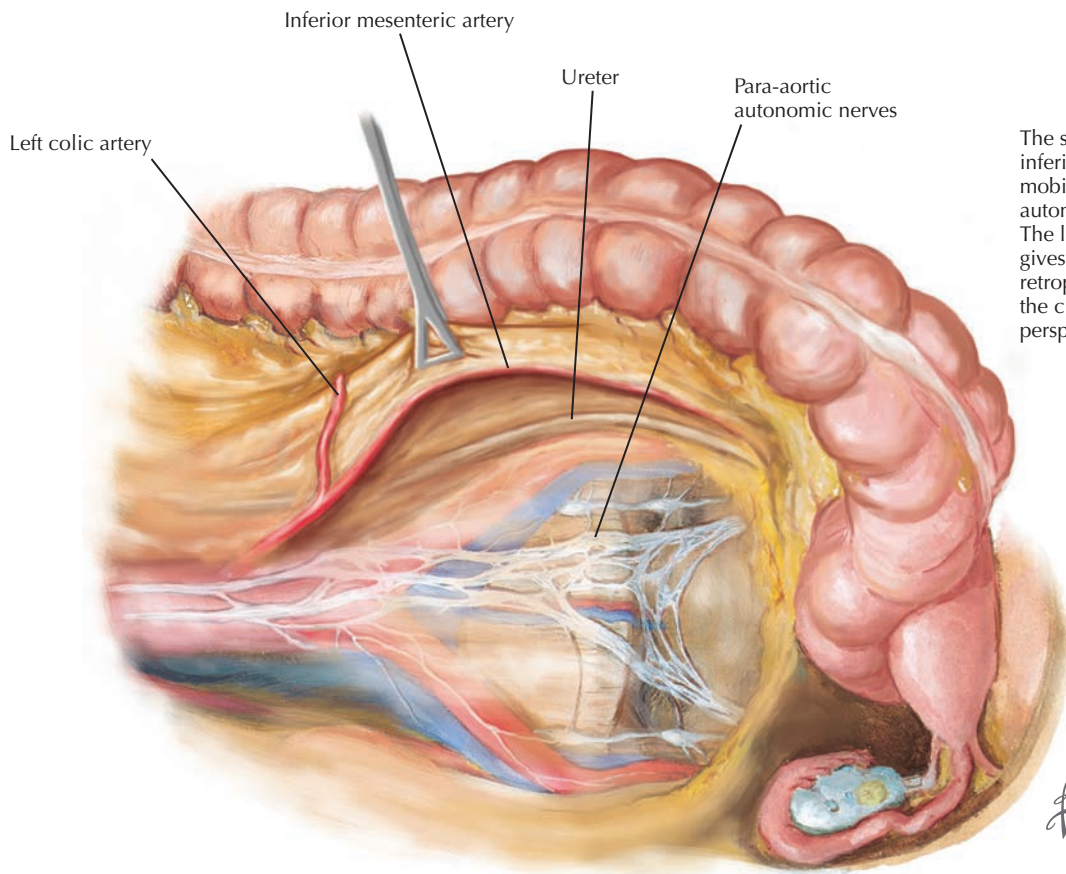


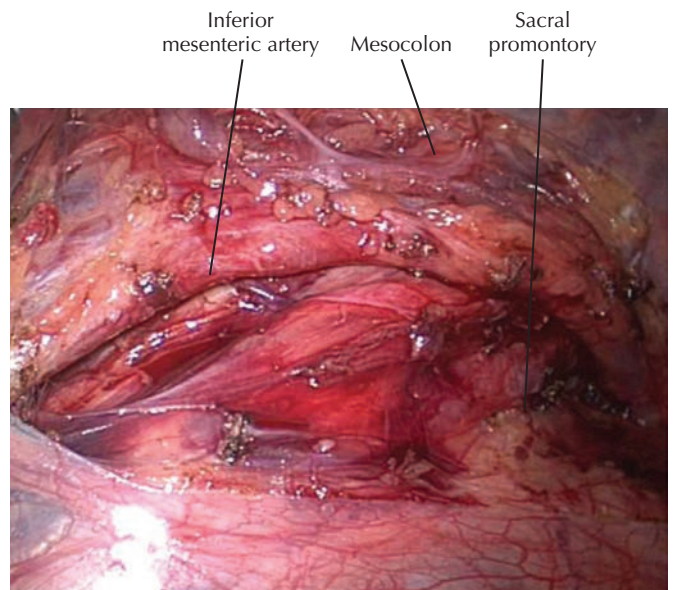
FIGURE 24-5 Anatomic relations of ureters: male and female.

Inferior Mesenteric Artery and Vein: Anterior View

The sigmoid colon may be mobilized starting on the medial or the lateral side. When the correct planes are defined, Toldt's fascia is carefully preserved and remains as a parietal layer over the retroperitoneum. The ureters and para-aortic autonomic nerves are by definition posterior to this layer. The mesentery of the distal sigmoid is then elevated from the retroperitoneum under slight tension. The peritoneum to the right of the inferior mesenteric artery (IMA) is opened parallel to the vessel, allowing the index finger of the left hand to encircle the origin of the IMA (Fig. 24-6).



Inferior mesenteric vein can be seen deep to the peritoneum, while the rectosigmoid junction is stretched anteriorly to place it under tension.



Once the peritoneum is opened, parallel and posterior to the inferior mesenteric artery, the autonomic nerves are swept posteriorly and protected. The left ureter can be seen behind and lateral to the artery.

FIGURE 24-6 Inferior mesenteric artery.

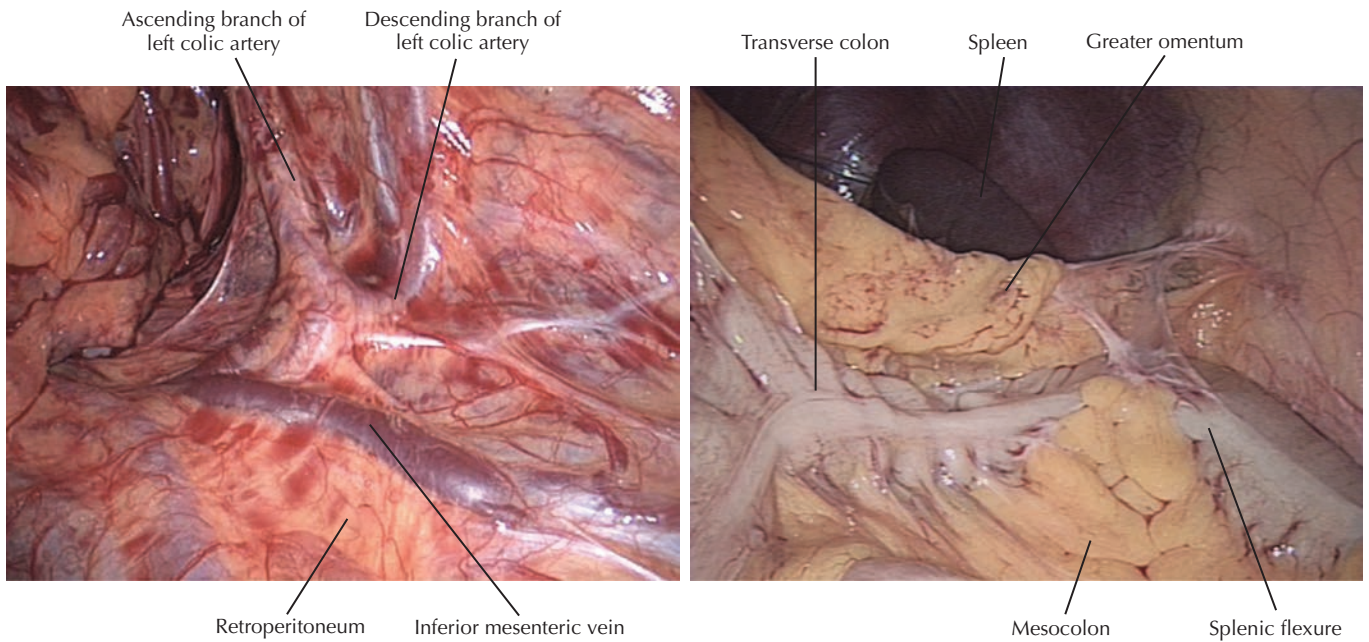
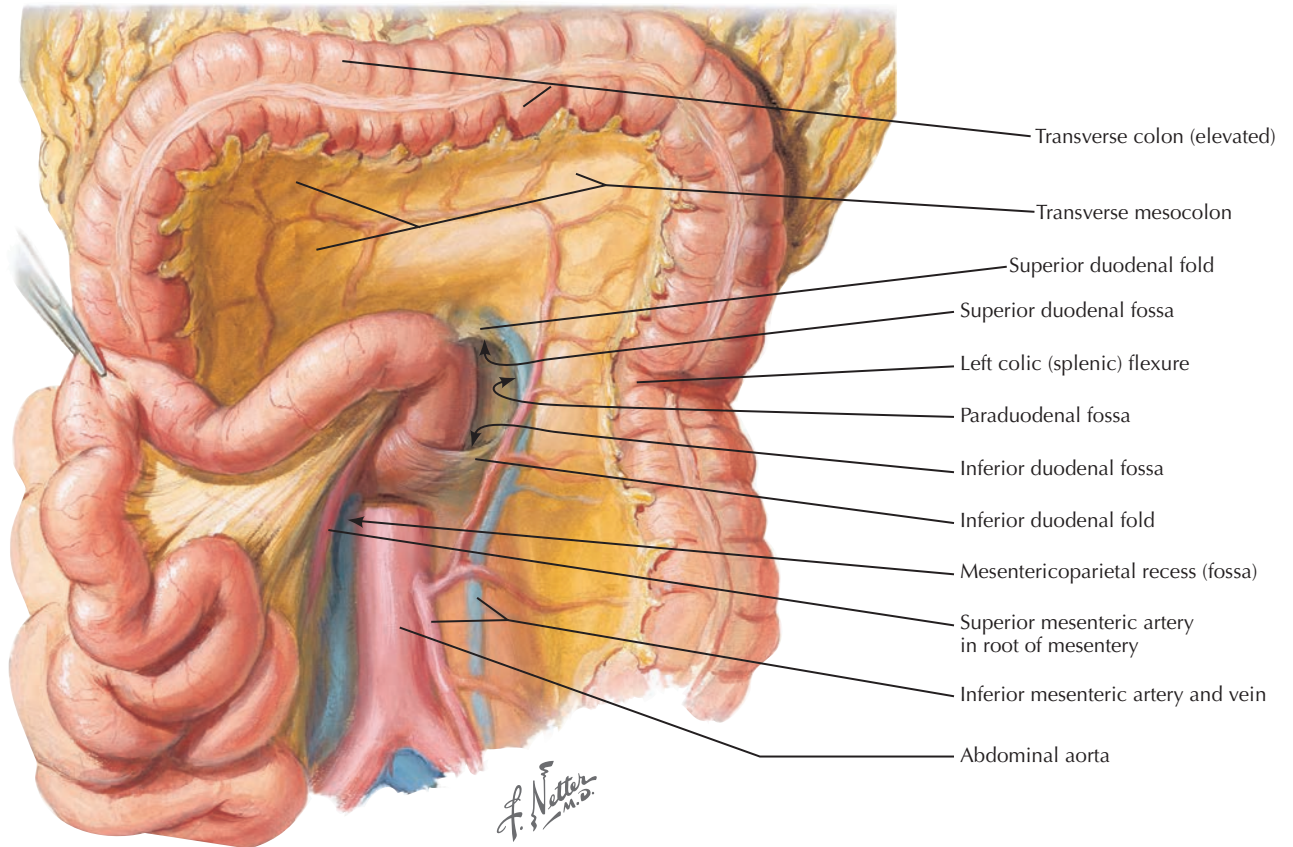
Inferior Mesenteric Artery and Vein: Medial Oblique View

The same anatomy is approached differently in laparoscopic surgery. The position of the camera means that the perspective of the vessels is from a much more oblique view. Nevertheless, the same structures can be observed. When the IMA is divided, this is performed 2 cm distal to its origin to protect the para-aortic autonomic nerves, but proximal to the left colic artery. The IMA is then divided again just below the takeoff of the left colic artery, thereby preserving the left colic's bifurcation to maximize blood flow to the segment of bowel that will be used as the neorectum (Fig. 24-7).

Splenic Flexure

Although the splenic flexure is not mobilized routinely by all surgeons, this is an important and frequently necessary skill. The flexure can be mobilized from a medial, lateral, or inferior approach. Entry to the lesser sac exposes the superior aspect of the transverse mesocolon, which inserts to the anterior border of the pancreas. Mobilization too far from the retroperitoneum (too close to the colon) creates a defect through the mesentery of the colon. While the surgeon is mobilizing the flexure, care must be paid to the jejunum, which is often only two cell layers away (through the mesentery) from the area of dissection.

The greater omentum is then elevated superiorly, demonstrating the avascular plane between this and the transverse colon. This plane is opened, mobilizing the splenic flexure so that the colon to the left of the midline is fully freed from its attachments. At this stage the colon is tethered by the inferior mesenteric vein (IMV) as it enters the splenic vein behind the pancreas. The IMV is divided just below the pancreas, giving several extra inches of reach to allow the descending colon to reach into the pelvis (Fig. 24-7).



The splenic flexure is mobilized to obtain adequate reach for a colorectal anastomosis. The operative photographs demonstrate the view of the splenic flexure lying in the retroperitoneum before mobilization.

FIGURE 24-7 Inferior mesenteric vein and splenic flexure.

ANATOMY FOR RECTAL MOBILIZATION AND DISSECTION

The anatomy of the dissection of the upper rectum is demonstrated in [Figure 24-6](#), along with the pelvic autonomic nerve anatomy. Knowledge of these vessels and the autonomic nerves is required before beginning the pelvic dissection.

Upper Mesorectum: Posterior Mesorectal Anatomy

Dissection commences behind the rectum, staying between the plane of the parietal peritoneum and the fascial layer investing the mesorectum. The initial dissection is in the midline posteriorly and continues down to the level of the levator muscles, demonstrating the bilobed appearance of the intact mesorectum. Adequate distraction of tissues assists in demonstration of the correct anatomic planes. Dissection continues laterally on both sides until the rectum becomes tethered by the anterior peritoneal attachments at the pouch of Douglas ([Fig. 24-8](#)).

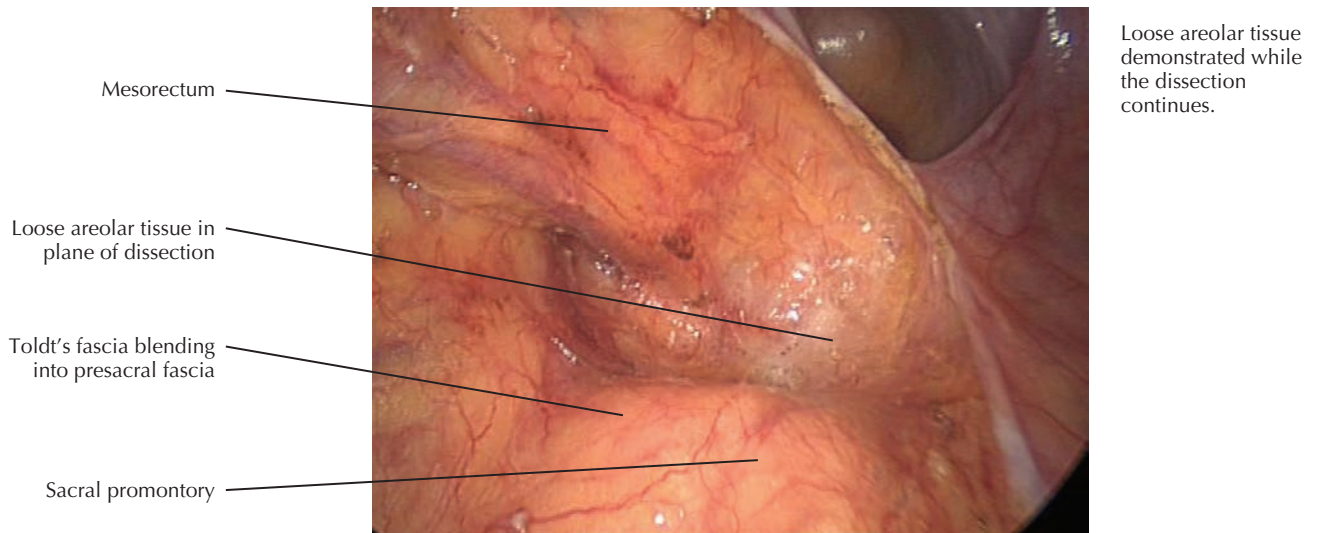
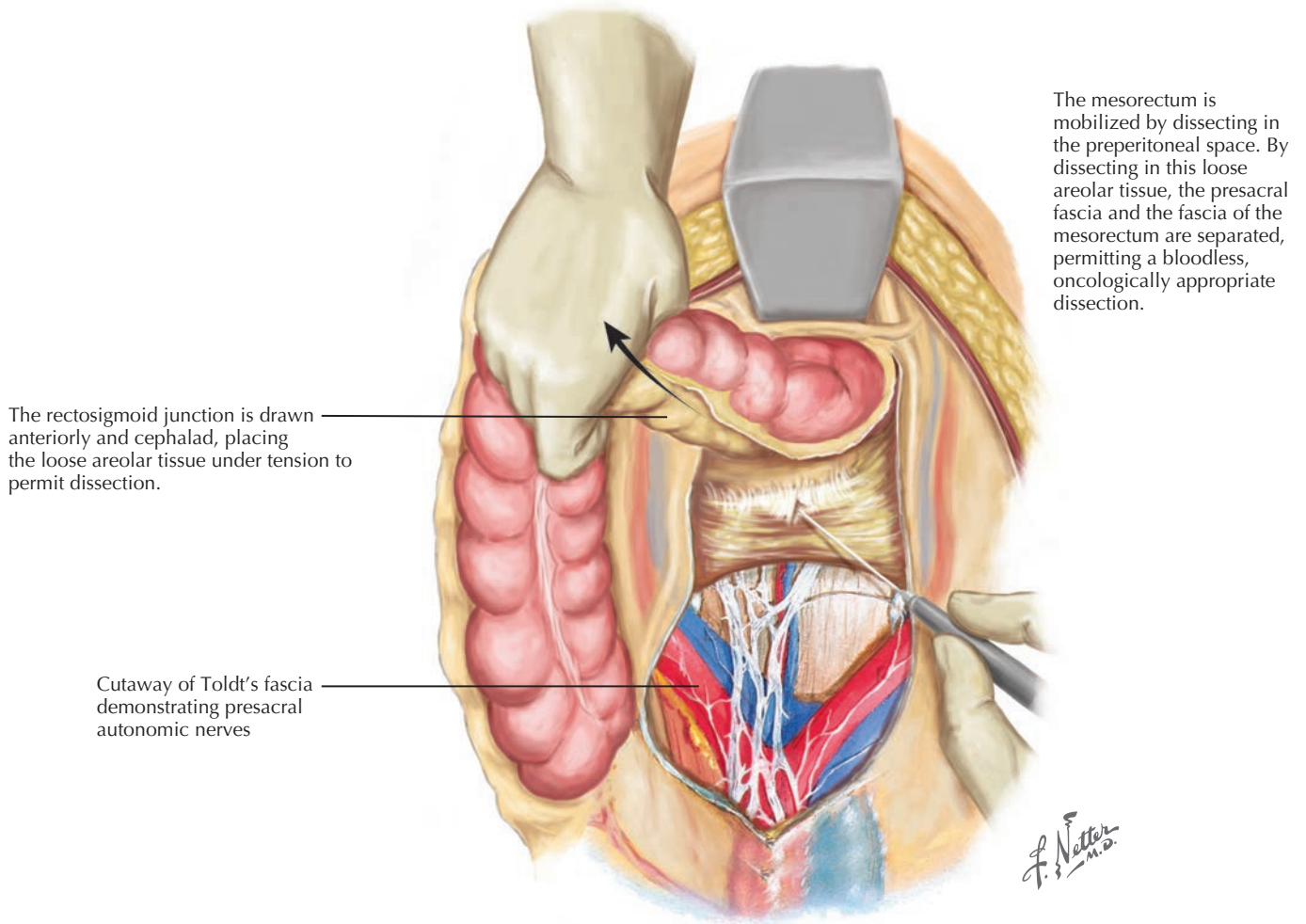
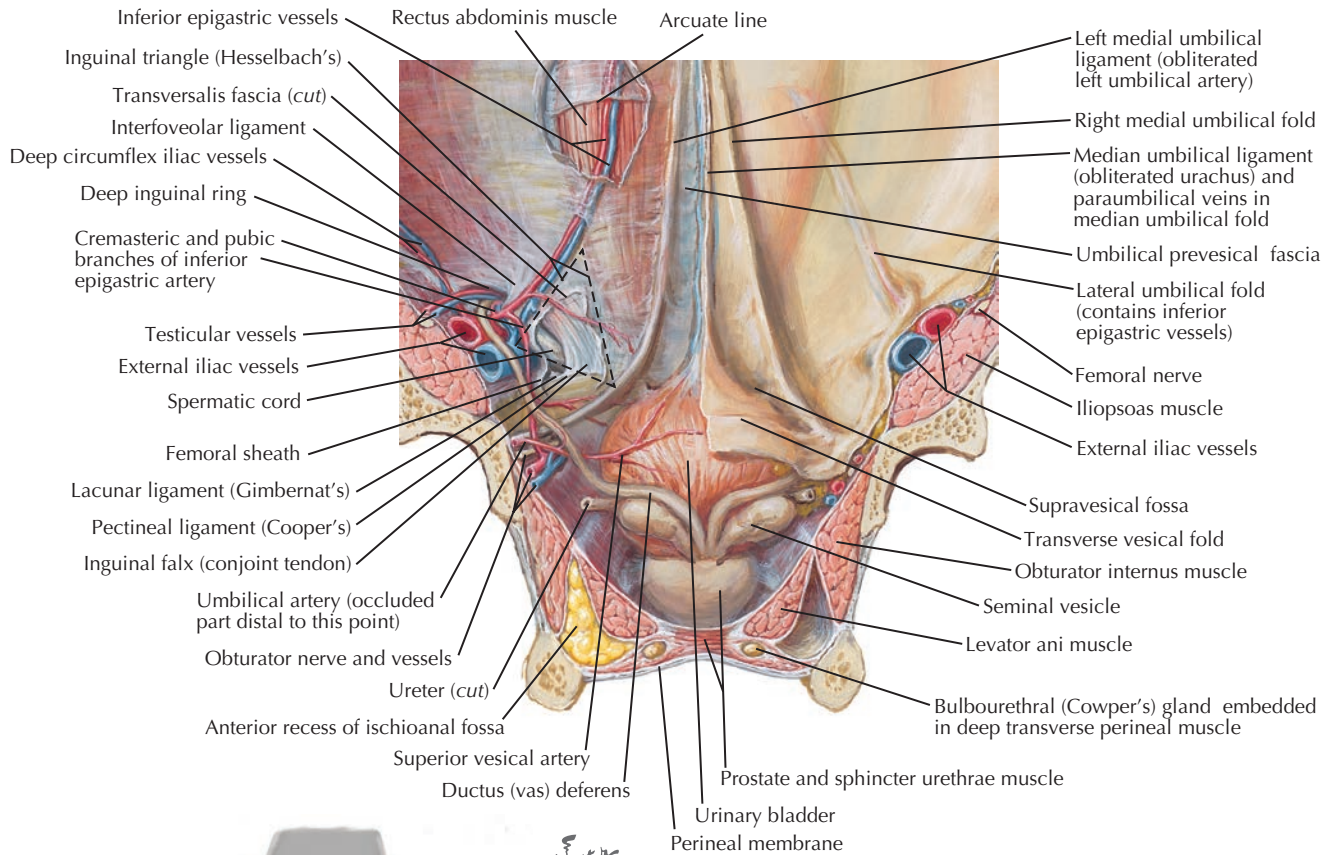


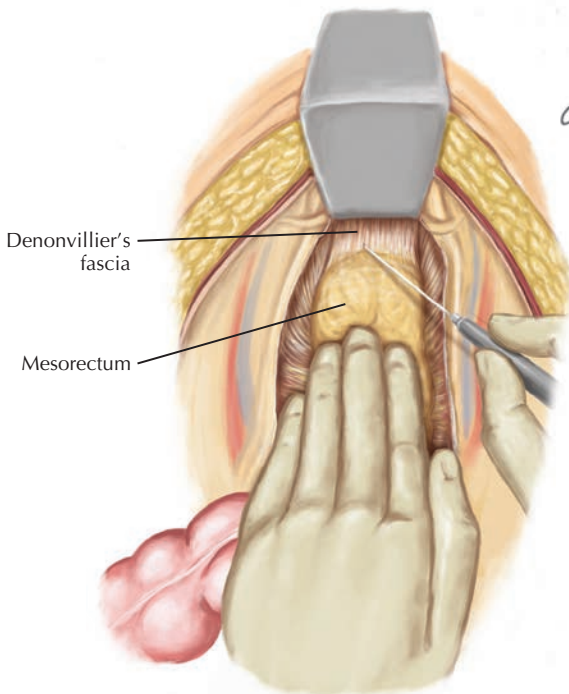
FIGURE 24-8 Upper posterior mesorectal dissection.

Lower Mesorectum: Anterior Mesorectal Anatomy

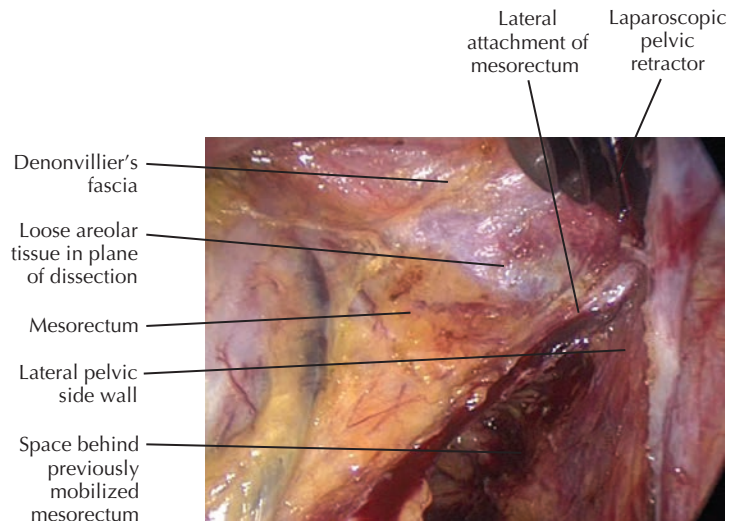
The bladder or uterus is then drawn anteriorly, and cautery is used to continue the lateral dissection anteriorly, opening the peritoneum immediately behind Denonvilliers' fascia. The dissection then continues distally until the levators are seen to curve distally into the anal canal, protecting the anterolateral neurovascular bundles (Fig. 24-9).



F. Netter M.D.
C. Machado M.D.



The upper rectum is drawn posteriorly, placing the anterior attachments under tension to permit dissection.



The upper rectum is drawn posteriorly, placing the anterior attachments under tension to permit dissection.

FIGURE 24-9 Lower anterior mesorectal dissection.

Rectal Transection from Above

Once an adequate distal margin has been obtained, the rectum may be transected below the level of the tumor, usually at the anorectal junction. At this level there is no mesorectum to divide, and a stapler fits easily around the rectum. The specimen is amputated and removed from the field. This approach leaves a transverse staple line that can be easily seen from above, sitting just into the upper anal canal within the sling of the levators, ready for a stapled colo-anal anastomosis (Fig. 24-10).

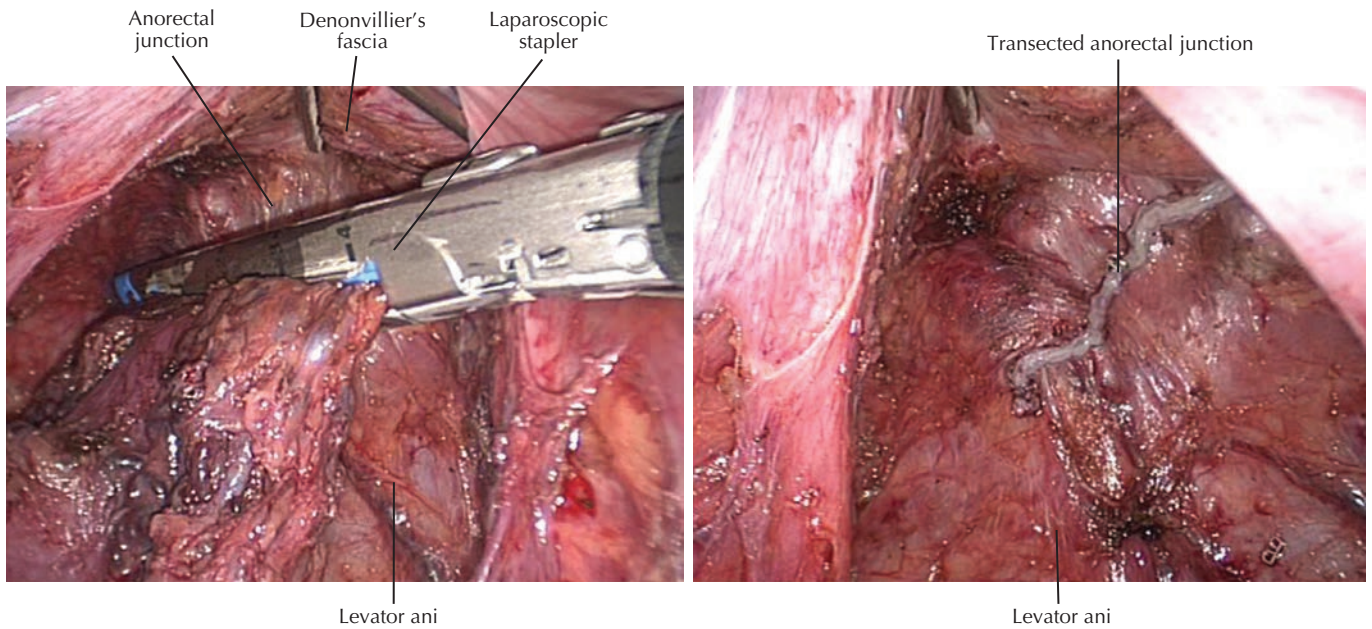
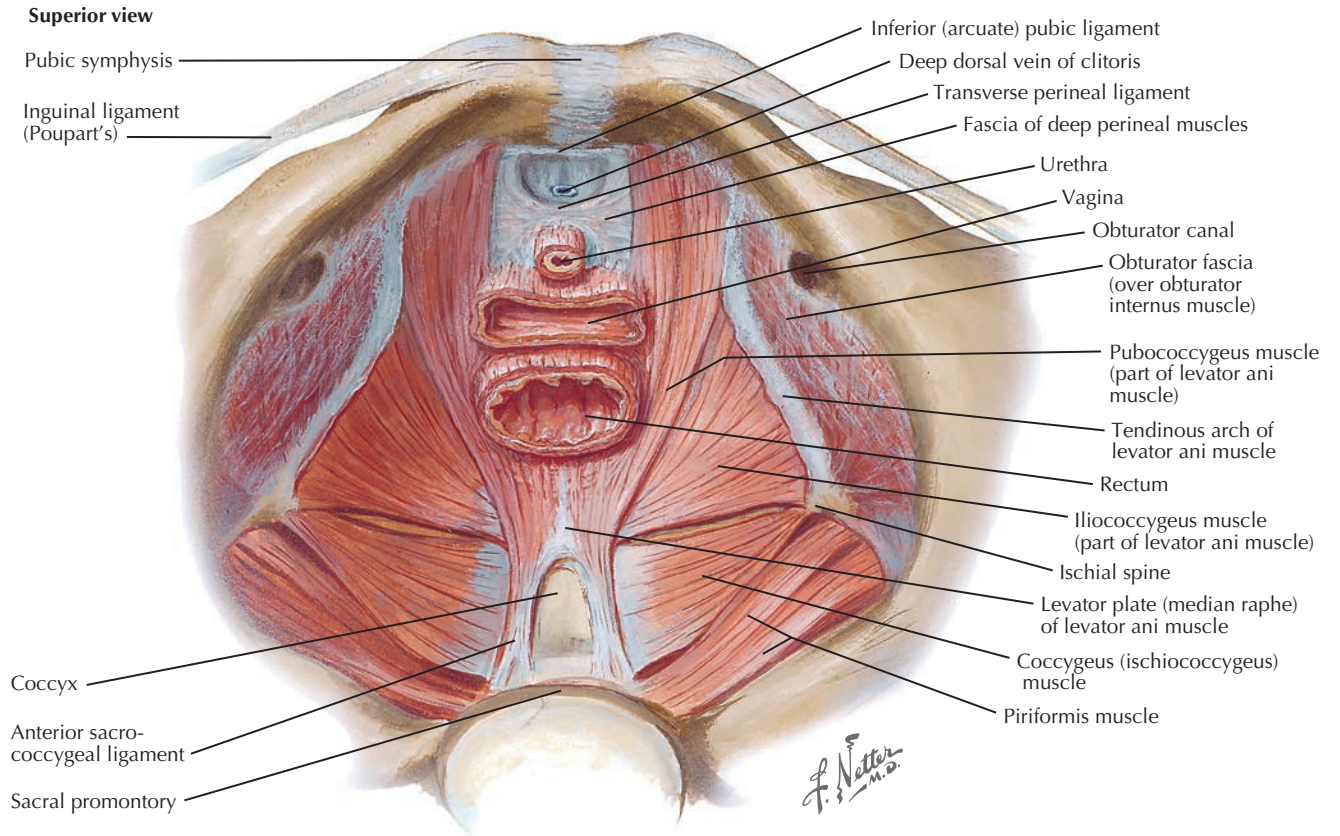


FIGURE 24-10 Stapled rectal transection.

Rectal Transection from Below

Some patients have insufficient distal margin for a stapled anastomosis, usually less than 1 or 2 cm from the dentate line. In these cases the intraabdominal dissection proceeds as previously described until the anal canal is reached. At this stage the surgeon moves to the perineum. An operating anoscope is used to visualize the dentate line, which is incised circumferentially with cautery. The dissection is continued to the internal sphincter, which is transected circumferentially. An intersphincteric dissection is then performed joining the prior plane of dissection from above (Fig. 24-11).

The anastomosis between the neorectum and the anal canal may then be sutured or stapled. A defunctioning proximal ostomy is usually created to mitigate complications of anastomotic leak.

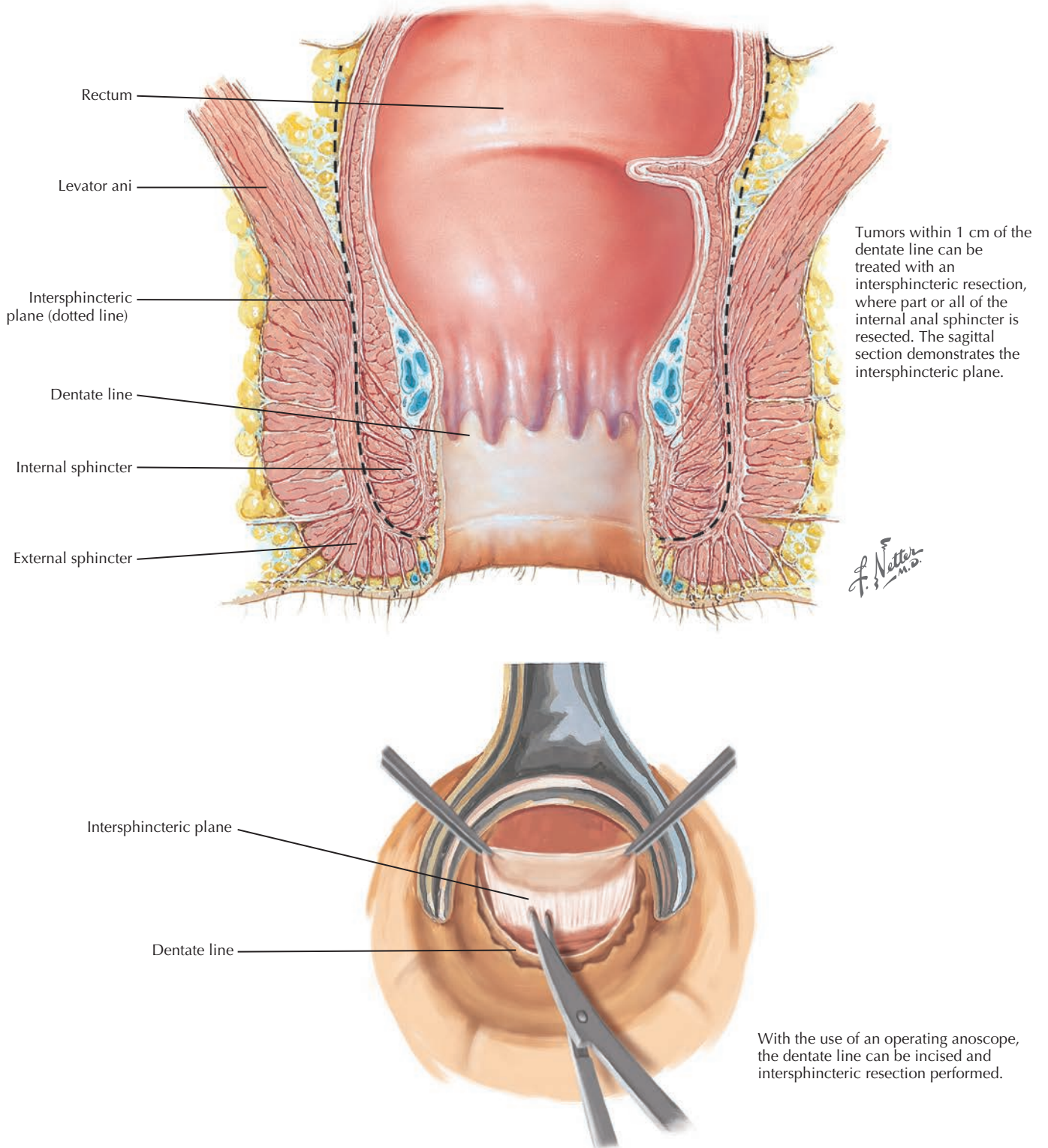


FIGURE 24-11 Intersphincteric transanal transection of rectum.

SUGGESTED READING

Delaney CP. Low anterior resection. In *Operative techniques in general surgery*. Philadelphia: Saunders; 2003, pp 214-23.

Abdominoperineal Resection

Harry L. Reynolds, Jr.

INTRODUCTION

Abdominoperineal resection (APR) is most often employed for lower-third rectal cancers with involvement of the sphincters. Tumors above the levator muscles can typically be treated with sphincter-sparing techniques. Patients with anal squamous cell carcinoma refractory to, or who are not eligible for, chemoradiation may also be treated with APR. Occasionally, patients with inflammatory bowel disease and severe perianal disease may require an APR. This chapter describes a standard, reproducible resection technique.

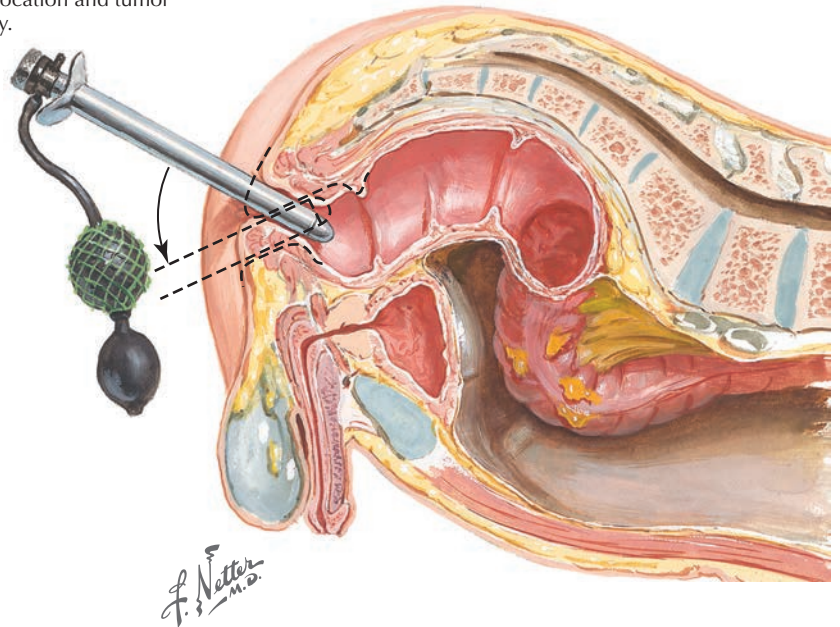
PRINCIPLES OF PREOPERATIVE EVALUATION

The patient is screened with a full colonoscopy. Digital rectal examination and proctoscopy are performed to confirm tumor location and to assess feasibility of a sphincter-sparing approach (Fig. 25-1, A). Digital vaginal examination and vaginoscopy are performed with the proctoscope to assess for local invasion. CT scanning of the chest, abdomen, and pelvis is done to survey for metastatic disease. Endorectal ultrasound is used for staging to assess the need for preoperative chemoradiation (Fig. 25-1, B).

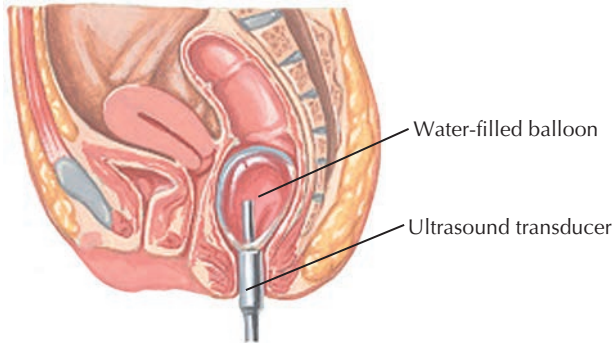
Pelvic magnetic resonance imaging (MRI) is increasingly used, providing a more complete and less operator-dependent picture of the extent of the tumor in the pelvis. MRI can provide extremely useful information on circumferential mesorectal margins or frank involvement of the pelvic side wall, sacrum, or anterior organs. MRI is particularly useful in men with anteriorly based tumors, because it can determine whether local involvement of the prostate, seminal vesicles, or bladder exists, indicating a need for exenteration.

Patients staged with clinical stage II or stage III tumors are usually treated with preoperative chemoradiation. Long-course therapy is routinely used, and surgery is typically performed 8 weeks after radiation therapy. The patient is reassessed with proctoscopy and the response to chemoradiation is noted. Some patients not thought to be candidates for a low anterior resection may be determined to be suitable for sphincter-sparing procedures when assessed after neoadjuvant therapy. Caution should be used in determining the extent of resection necessary. For patients with sphincter involvement or adjacent organ involvement before neoadjuvant therapy, the surgeon should excise the clinically involved tissue en bloc. Microscopic deposits are frequently seen in deep specimens despite clear mucosa.

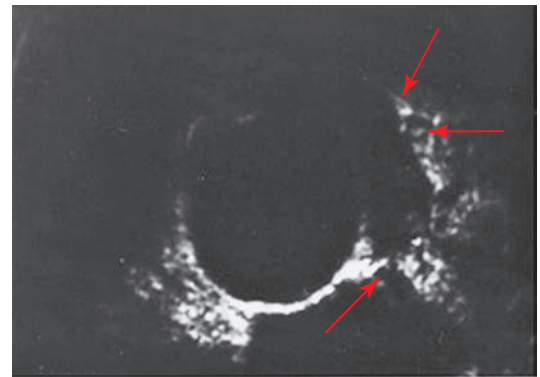
A. Rigid proctoscopy. Performed on all patients with rectal tumors. Location from anal verge should be noted as well as location and tumor characteristics prior to neoadjuvant or surgical therapy.



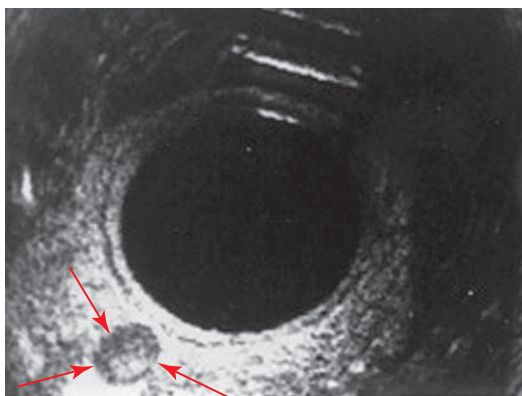
B. Endorectal ultrasonography. A digital exam can determine tumor characteristics, local invasion, and fixation of tumor. Anatomic location of the tumor can help to predict possible invasion into prostate or vagina anteriorly, side wall or coccyx posteriorly. It is very important to determine invasion of the levator muscles distally prior to therapy. Endorectal ultrasound can stage the tumor infiltration (T stage) as well as presence or absence of pathologic nodes. These findings will determine whether the patient is a candidate for surgical therapy or neoadjuvant chemoradiation.



Endorectal ultrasonography assesses depth of tumor penetration and degree of perirectal involvement



Ultrasonogram. Rectal tumor invades perirectal fat



Ultrasonogram. Rectal tumor and involvement of perirectal lymph nodes (arrows)

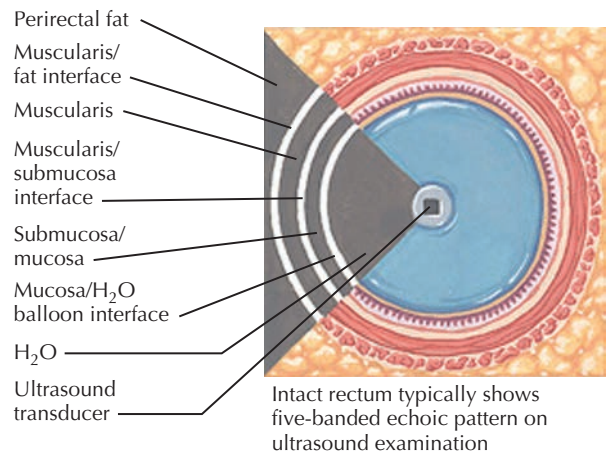


FIGURE 25-1 Proctoscopy and endorectal ultrasonography.

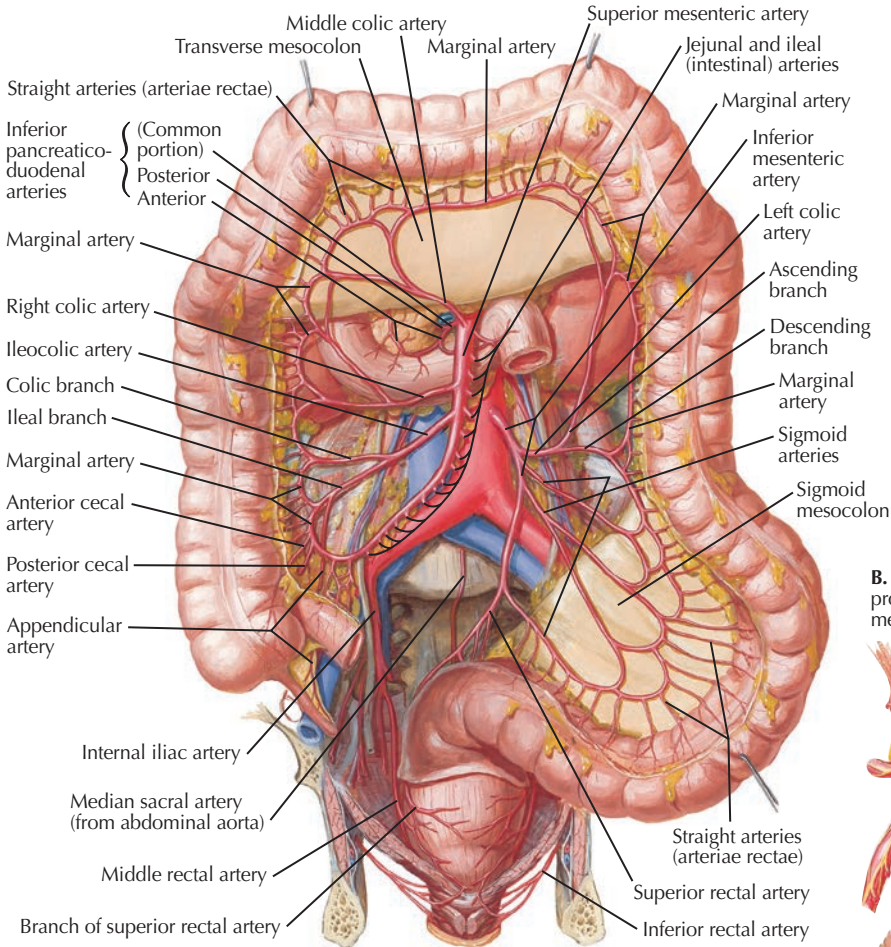
ANATOMIC APPROACH TO LEFT COLON MOBILIZATION

The left colon is mobilized just medial to the line of Toldt, preserving the fascia of the mesocolon. This approach allows a bloodless mobilization of the descending colon to the midline. The left gonadal and ureter are easily identified and protected throughout the dissection because they lie posterior to Toldt's fascia, which is kept intact over the retroperitoneum. If difficult to find, dissection either proximally toward the kidney or distally into the pelvis can assist in identifying the ureter.

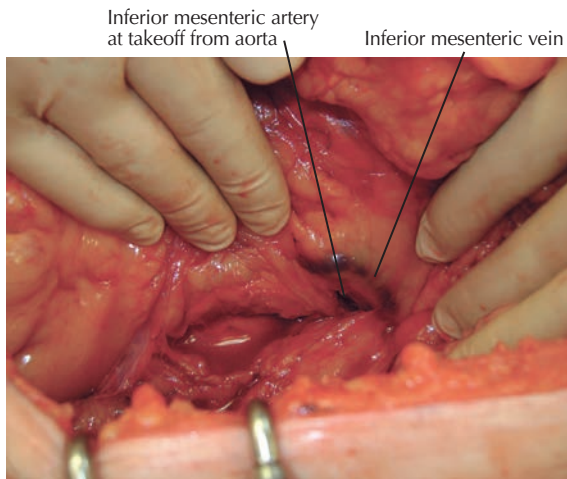
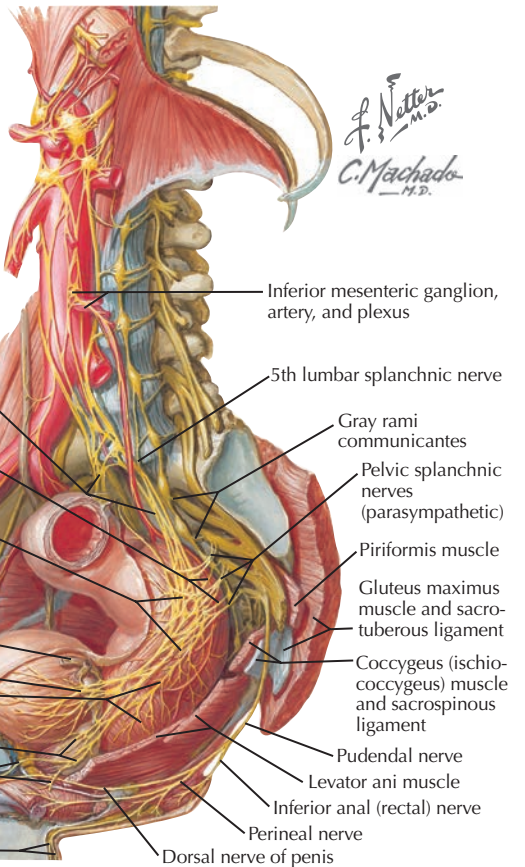
The mobilization is extended to the root of the mesentery, and the inferior mesenteric artery is identified at its takeoff from the aorta (Fig. 25-2, A). Branches of the sympathetic nerves, which lie deep to the IMA, are protected by keeping close to the fascia of the mesocolon as it wraps around the IMA, if necessary sweeping nerve branches dorsally and away from the vessel (Fig. 25-2, B). The IMA is isolated, clamped, and ligated. The left colic artery and the inferior mesenteric vein are divided and ligated at the level of the IMA (Fig. 25-2, C). The mesentery is divided perpendicularly to the level of the marginal artery, just proximal to the 1st sigmoidal branch. Unlike in low anterior resection, where extra length is needed for a tension-free colorectal anastomosis, mobilization of the splenic flexure is not required unless the patient is morbidly obese and extra length is needed for stoma construction.

The colon is divided proximal to the 1st sigmoid branch, and pulsatile arterial flow is confirmed in the marginal artery.

A. Arteries of the large intestine and rectum. For rectal tumors, a high ligation of the inferior mesenteric artery at its takeoff from the aorta is performed. The left colic artery may be preserved. The dissection is carried out to the marginal artery proximal to the first sigmoidal branch.



B. Nerves of the rectum and pelvis. Note the close proximity of the sympathetic plexus to the inferior mesenteric artery.



C. Arteries and veins of the left colon.

FIGURE 25-2 Arteries and nerves of pelvis and rectum.

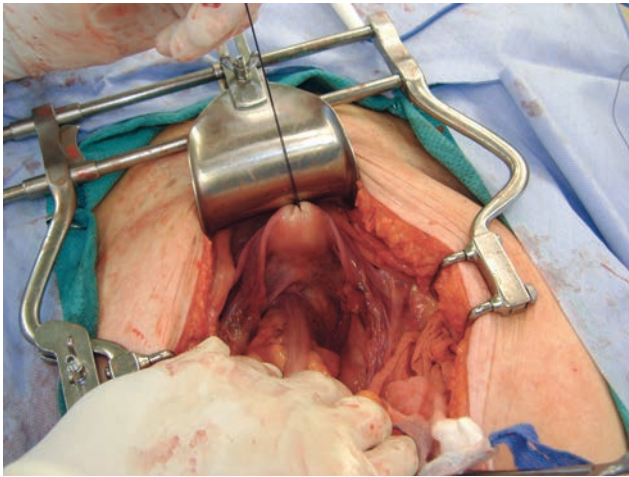
APPROACH FOR RECTAL DISSECTION

The patient is placed in the Trendelenburg position and a self-retaining retractor is inserted. It is helpful to place a figure-of-eight absorbable suture in the uterine fundus, retracting it anteriorly, and securing the suture to the self-retaining retractor (Fig. 25-3, *A*). In open surgical cases, the dissection is greatly facilitated by the use of lighted, deep pelvic retractors.

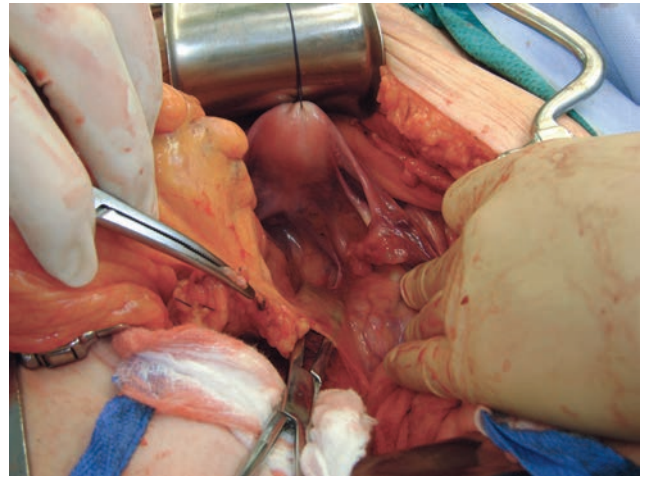
Mobilization of the rectum and its investing mesorectum and fascia begins behind the inferior mesenteric vessels, in the loose areolar tissue between the mesorectal fascia and the presacral fascia. The lateral peritoneum overlying the mesorectum is then scored (Fig. 25-3, *B*). Unless an extended resection is being performed, the ureters are generally easily protected because they lie deep to the fascia of the retroperitoneum. Nevertheless, the ureters' location is verified throughout the dissection (Fig. 25-3, *C*). The right and left hypogastric nerves are identified and swept posteriorly and are carefully avoided. The dissection continues posteriorly to the pelvic floor with the use of electrocautery (Fig. 25-3, *D*).

Dissection of the pelvis proceeds posteriorly, then laterally, and finally anteriorly. By lifting the rectosigmoid junction anterior and cephalad and indenting the mesentery, this avascular plane can be identified and entered, anterior to the nerves. If in the proper plane, cautery is adequate for hemostasis. Posteriorly, the dissection is continued through the filmy, avascular plane until the dissection reaches the rectosacral (Waldeyer's) fascia. While the dissection proceeds posteriorly, its direction will tilt more anteriorly, above the level of the coccyx (Fig. 25-3, *E*).

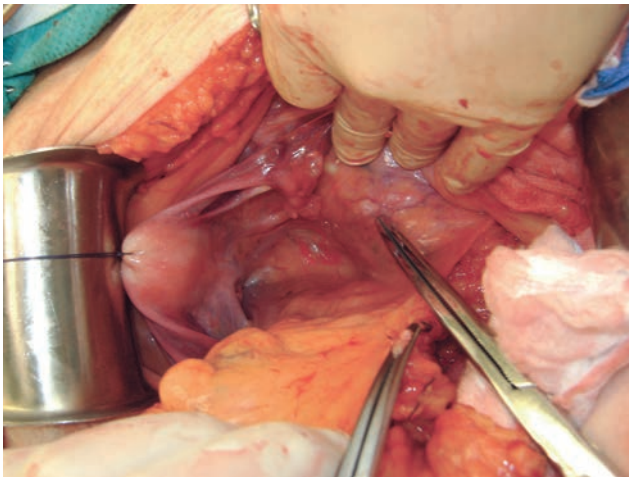
Laterally, the presacral parasympathetic nerves (nervi erigentes) can be seen along the pelvic side wall at approximately the level of the lateral stalks and middle rectal arteries (Fig. 25-3, *F*). The mesorectum is retracted medially and the dissection is continued on the right and left, and the nervi erigentes are allowed to fall laterally as the dissection ensues. This procedure is continued until the pelvic floor and levator muscles are reached.



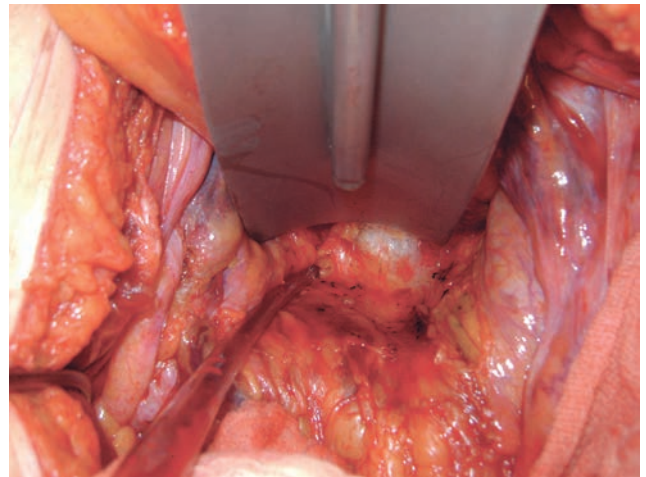
A. Uterus retracted anteriorly by suture attached to self-retaining retractor



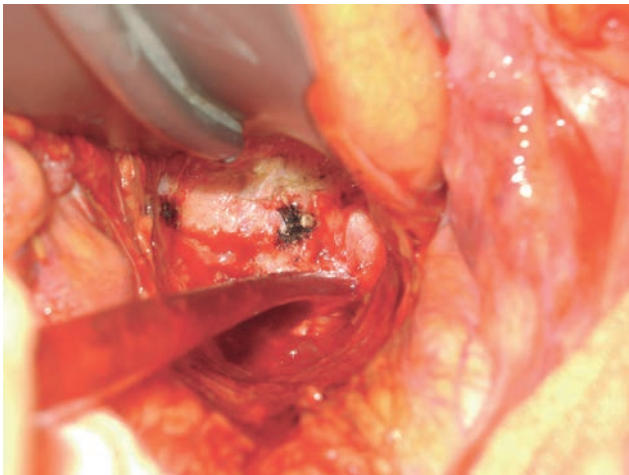
B. Mesorectal peritoneum scored bilaterally



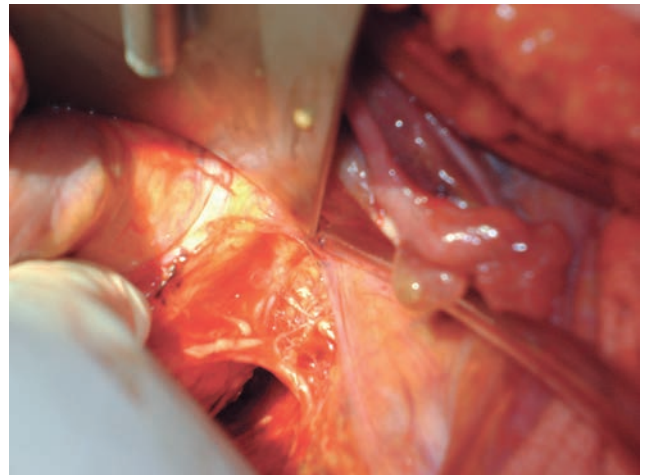
C. View into the pelvis, localization of the right ureter prior to dissection



D. IMA retraction anteriorly and starting dissection in the proper mesorectal plane identifying the hypogastric nerves. Lighted deep pelvic retractor facilitates dissection.



E. Completion of posterior dissection to the pelvic floor, showing pelvic floor/levators



F. Lateral attachments with the nervi erigentes at border of mesorectum

FIGURE 25-3 Approach for rectal dissection. *IMA*, Inferior mesenteric artery.

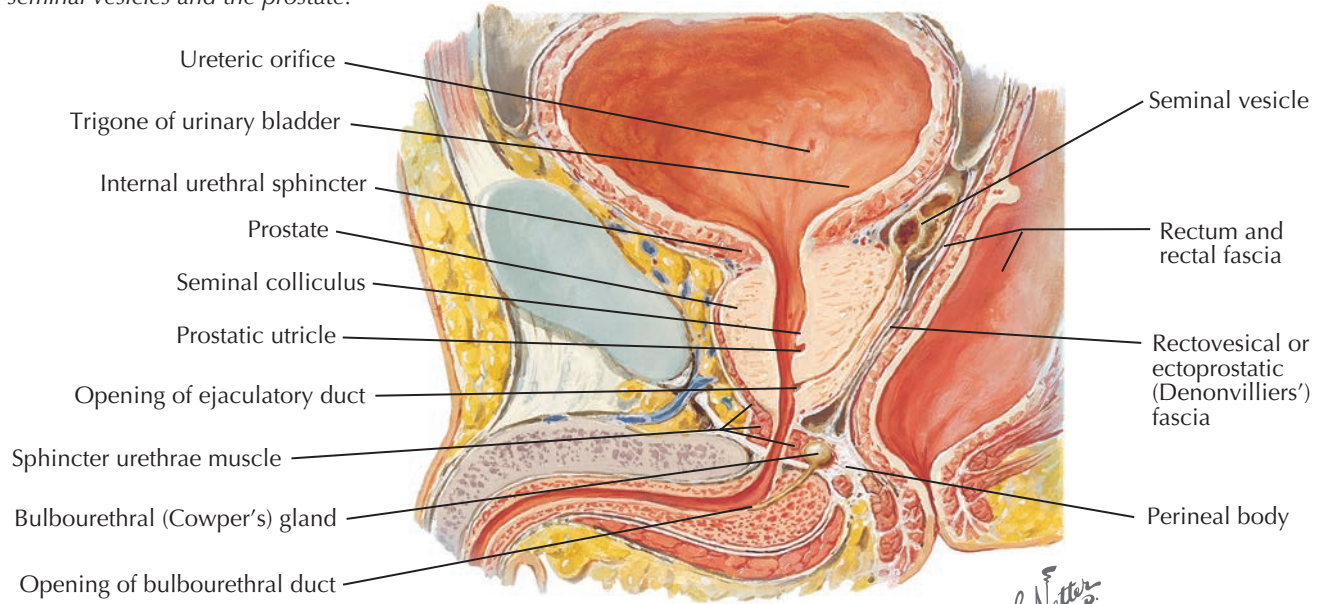
APPROACH FOR RECTAL DISSECTION—Cont'd

The anterior dissection is now begun. The peritoneum in the cul-de-sac is scored just anterior to the fold at the peritoneal reflection. Denonvilliers' fascia is reflected posteriorly to keep the mesorectum intact on the specimen. The surgeon must keep in mind the location of the pelvic plexus of nerves that overlies the seminal vesicles anteriorly in the male. It is important to avoid skeletonizing the vesicles to prevent nerve injury. Also to avoid injury, the proximity of the ureters to the apex of the seminal vesicles must be considered (Fig. 25-4). The anterior dissection is continued to the pelvic floor.

In women with a bulky, anteriorly based tumor, en bloc posterior vaginectomy is typically performed. The uterus and ovaries can be mobilized en bloc with the rectum if a hysterectomy has not been performed. The round ligaments are divided and ligated on the lateral side walls. The gonadal vessels are taken distal to the pelvic brim after identification and preservation of the ureters. The bladder is separated from the vagina anteriorly. The uterine vessels are serially clamped and suture-ligated directly adjacent to the cervix, to avoid the ureters. The anterior vagina is then opened, and the lateral borders of the vagina are divided with the cautery, leaving the posterior vagina en bloc with the rectum. Once at the pelvic floor, the abdominal dissection is complete.

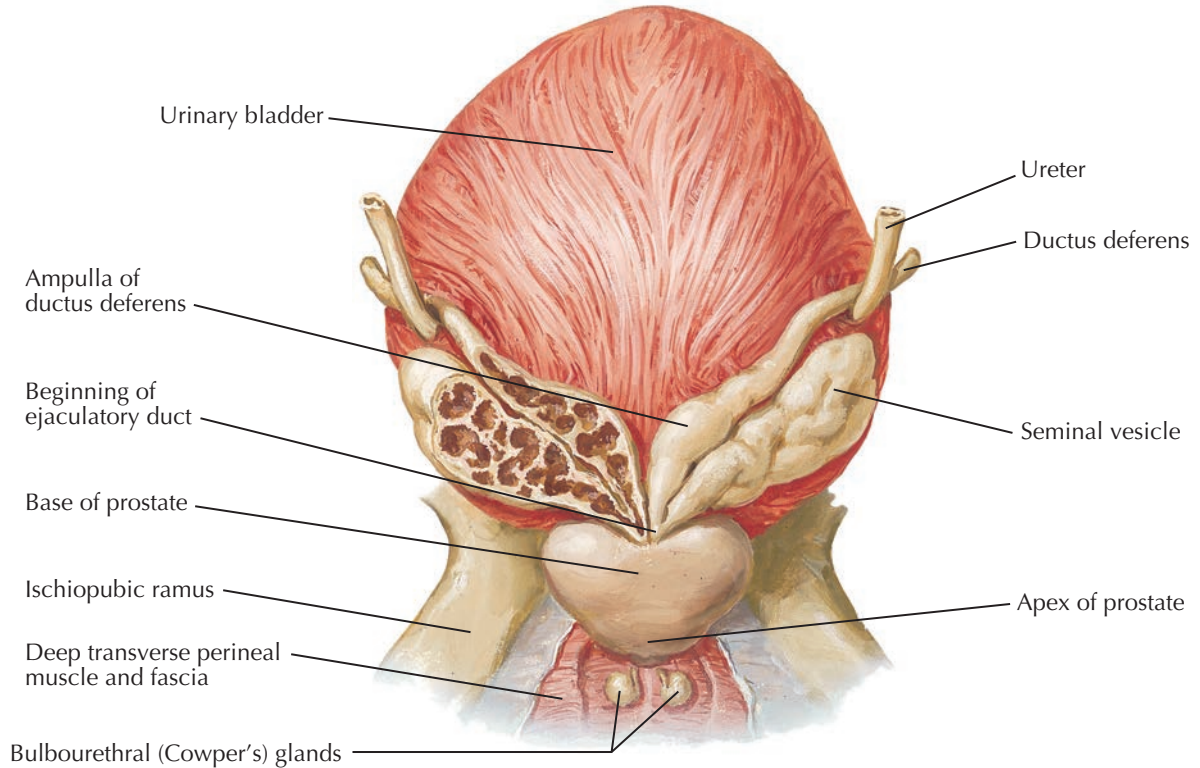
It should be emphasized that the common error of creating a narrow waist of tissue just proximal to the pelvic floor should be avoided. Because the mesorectum naturally tapers above the levator muscles, the surgeon must avoid "coning in" on the specimen and compromising the circumferential margin. This error must be consciously avoided throughout the distal pelvic dissection to complete an oncologic *extra-levator dissection*, more recently called a "cylindrical resection" by some authors.

Note the location of the tip of the seminal vesicle in relation to the ureter and its entrance in to the bladder. The pelvic plexus of nerves is immediately overlying the seminal vesicles and the prostate.



Sagittal section

F. Netter M.D.
C. Machado M.D.



Posterior view

FIGURE 25-4 Prostate and seminal vesicles.

APPROACH FOR RECTAL DISSECTION—Cont'd

After the abdominal dissection is completed, two options exist for the perineal dissection. The stoma can be created, the abdomen closed, and the stoma matured, followed by subsequent turning of the patient to the prone jackknife position. Some surgeons believe that this approach greatly facilitates the perineal dissection. Alternatively, the patient's legs can be moved to high lithotomy position and the perineal dissection completed with the surgeon seated between the legs.

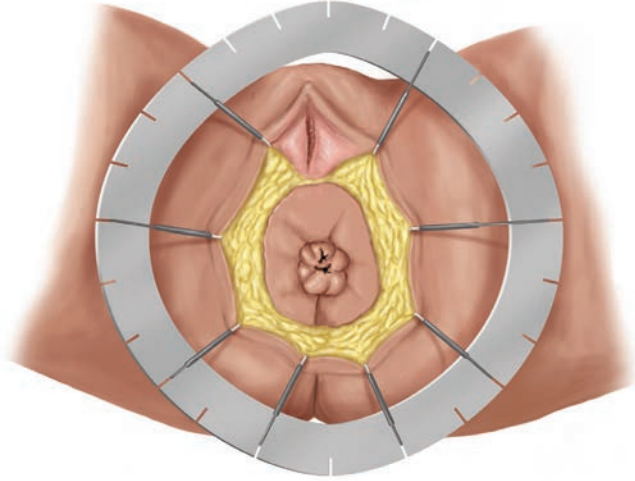
Regardless of positioning, the margins of dissection are determined by tumor location. In general, the posterior margin is determined by palpation of the coccyx, the lateral margins by palpation of the ischial tuberosities, and the anterior margin by the urethra in the male and the posterior vaginal wall in the female. As noted, posterior vaginectomy is typically performed for any bulky, anteriorly based lesion.

After outlining margins, the skin is scored. The amount of skin that needs to be taken is not great, and usually the anal verge suffices, except with a larger squamous lesion. The dissection is continued until the ischiorectal fossa is entered circumferentially (Fig. 25-5, A). Usually, the posterior dissection is performed first because it has the clearest landmarks. The dissection proceeds to join the abdominal dissection, just above the coccyx. The surgeon continues the lateral dissection up to the lateral origin of the levator muscles, staying in an extra-levator plane. A finger is placed in the patient's pelvis and hooked behind the levators, and cautery is used to divide the left and right muscles (Fig. 25-5, B).

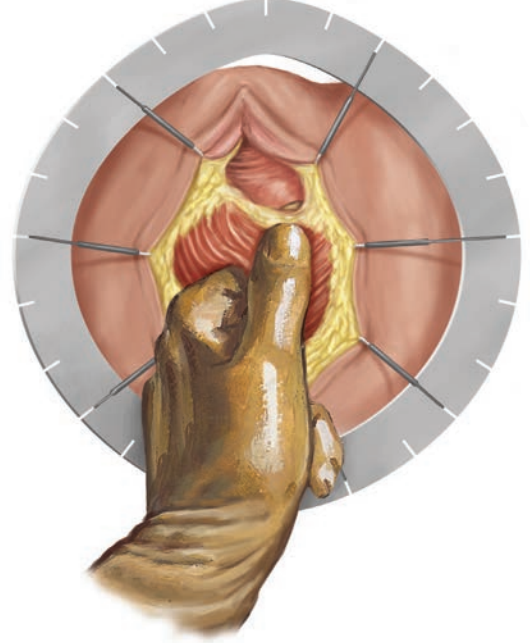
The anterior dissection is finally undertaken. In the male patient, the urethra is noted by palpation of the Foley catheter, and great care is taken to avoid injury. In the female patient, a finger in the vagina can help to define the anterior plane. After the dissection is completed circumferentially, the specimen is delivered through the perineum and carefully examined for adequacy of margins (Fig. 25-5, C).

Closure of the perineum is accomplished in layers with absorbable sutures. Generous bites are taken from the remaining ischiorectal fat. A deep layer is placed in the subcutaneous fat. The vagina, although somewhat narrowed, can usually be closed in a tubular fashion. The perineum is then closed with interrupted vertical mattress sutures, beginning at the introitus (Fig. 25-5, D).

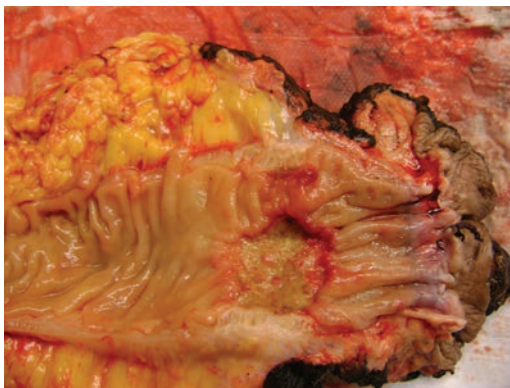
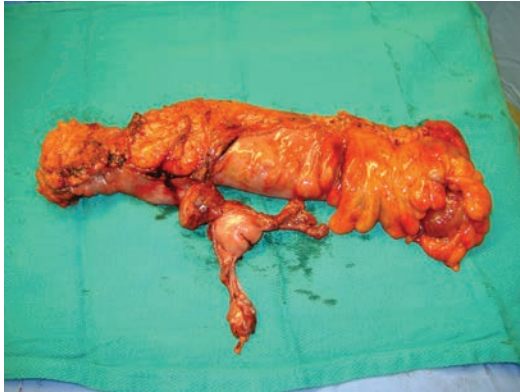
A. Perineal dissection and entrance into ischioanal fossa, taking posterior vagina en bloc



B. Abdomen is entered posteriorly anterior to coccyx; the levators are hooked with the index finger and divided.



C. Note the intact mesorectum, en bloc vagina, uterus, and ovaries and absence of narrowing just proximal to the levators in the specimen.



D. Closed vagina and perineum

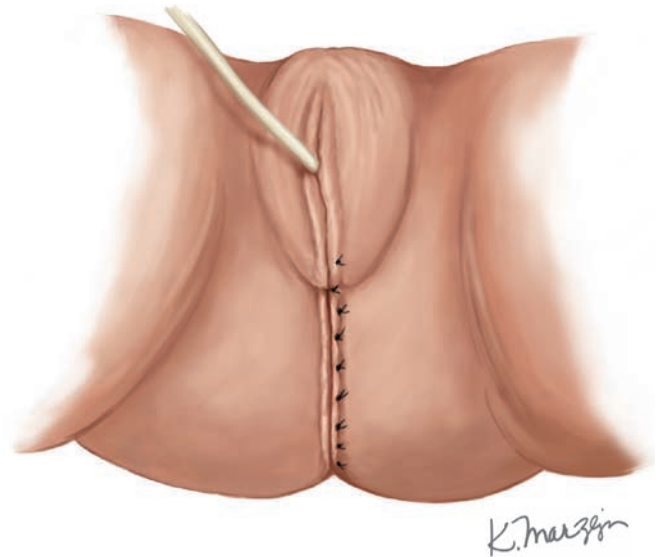


FIGURE 25-5 Perineal dissection.

SUGGESTED READINGS

Han JG, Want ZJ, Wei GH, et al. Randomized clinical trial of conventional versus cylindrical abdominoperineal resection for locally advanced lower rectal cancer. *Am J Surg* 2012;204:274-82.

Perry WB, Connaughton JC. Abdominoperineal resection: how is it done and what are the results? *Clin Colon Rectal Surg* 2007;20(3):213-20.

Stelzner S, Hellmich G, Schubert C, et al. Short-term outcome of extra-levator abdominoperineal excision for rectal cancer. *Int J Colorectal Dis* 2011;26:919-25.

Hemorrhoids and Hemorrhoidectomy

Jason F. Hall

INTRODUCTION

Complaints attributable to hemorrhoidal disease are common in both primary care and specialty settings. The vast majority of hemorrhoidal presentations can be managed with nonsurgical treatments, although procedural intervention is required in some circumstances. A firm grasp of anorectal anatomy is essential for choosing the appropriate method of treatment.

ANATOMY OF HEMORRHOIDS

Hemorrhoids are specialized, nonpathologic, vascular cushions found within the anal canal. They are typically organized into three anatomically distinct cushions located in the left lateral, right anterolateral, and right posterolateral anal canal (Fig. 26-1, A). Hemorrhoids are found in the submucosal layer and are considered *sinusoids* because they typically have no muscular wall. They are suspended in the anal canal by the muscle of Treitz, which is a submucosal extension of the conjoined longitudinal ligament.

Hemorrhoids are classified as internal or external. *Internal hemorrhoids* are located proximal to the dentate line and have visceral innervation; therefore the most common presentation is painless bleeding. Because they are close to the anal transitional zone (ATZ), internal hemorrhoids can be covered by columnar, squamous, or basaloid cells. *External hemorrhoids* are located in the distal third of the anal canal and are covered by anoderm (squamous epithelium). Because of the somatic innervation of external hemorrhoids, patients who have these are more likely to be seen with pain (Fig. 26-1, B).

Hemorrhoids are thought to enhance anal continence and may contribute 15% to 20% of resting anal canal pressure. They also provide complete closure of the anus, enhancing control of defecation. In addition to making important contributions to the maintenance of continence through pressure phenomena, hemorrhoids also relay important sensory data regarding the composition (gas, liquid, stool) of intrarectal contents.

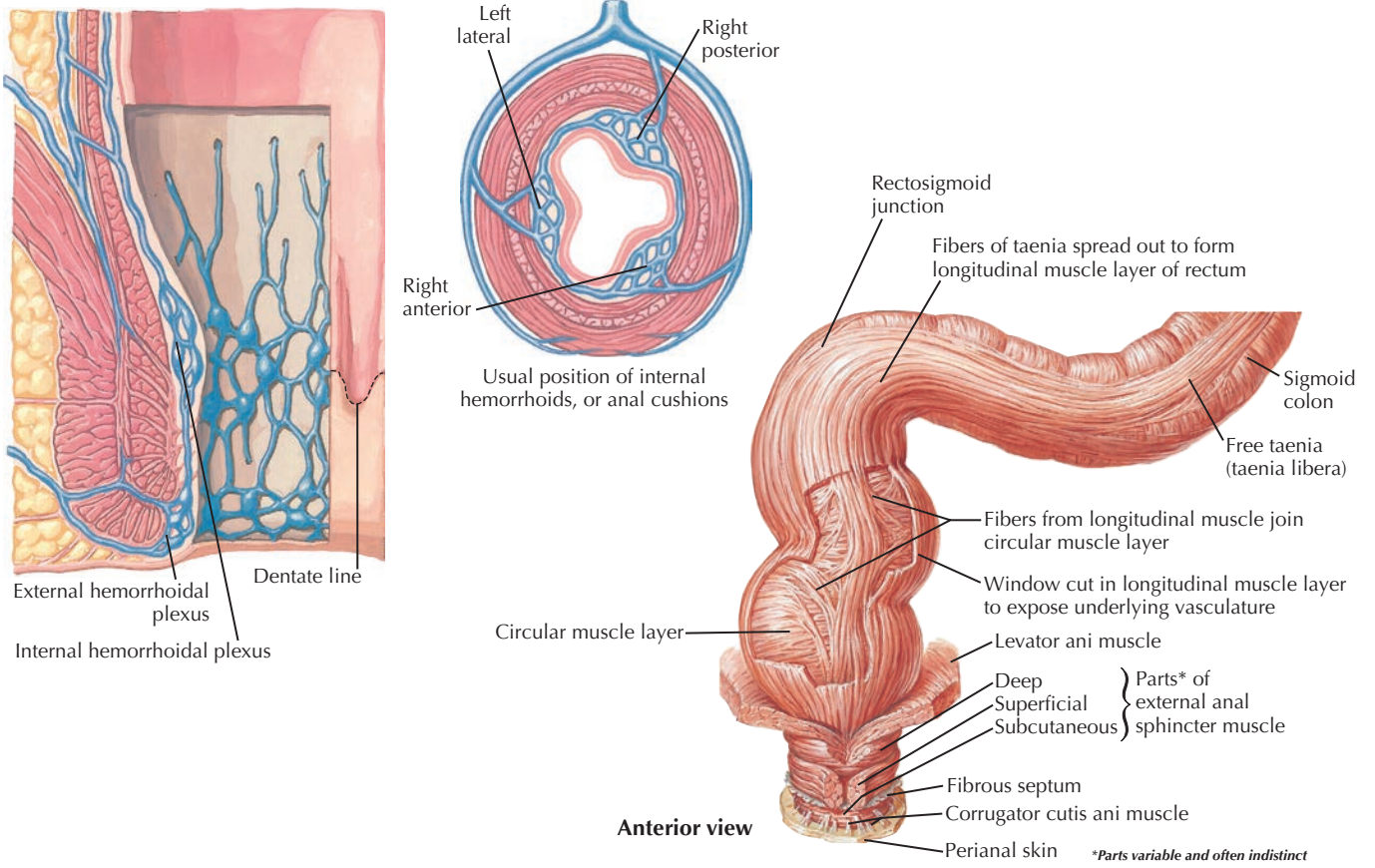
The central causative pathway for the development of hemorrhoidal pathology is an associated increase in intraabdominal pressure. This increase may be secondary to straining, constipation, or obesity. Other etiologic factors can include diarrhea, pregnancy, and ascites. Aging is also associated with dysfunction of the supporting smooth muscle tissue, resulting in prolapse of hemorrhoidal tissues.

Hemorrhoids are normal structures and thus are treated only if they become symptomatic. Common complaints include bleeding, pain, and swelling. After nonoperative measures have failed, treatment is largely applied on the basis of size and symptomatology. Hemorrhoids classically are categorized into grade 1, with enlargement, but no prolapse outside the anal canal; grade 2, with prolapse through the anal canal on straining, but with spontaneous reduction; grade 3, manual reduction required; and grade 4, hemorrhoids cannot be reduced into the anal canal.

First-degree hemorrhoidal disease can usually be treated with nonsurgical measures. The primary goal is to decrease straining with bowel movements and thus reduce the intraabdominal pressure transmitted to the hemorrhoidal vessels. The mainstay of nonoperative hemorrhoidal treatment is increased fiber and water consumption.

Patients with 2nd-degree hemorrhoids can be offered a trial of nonsurgical management, although a number of these measures will fail and require procedural intervention. The 3rd- and 4th-degree hemorrhoids generally require surgery.

A. Anatomy of hemorrhoids



B. Types of hemorrhoids

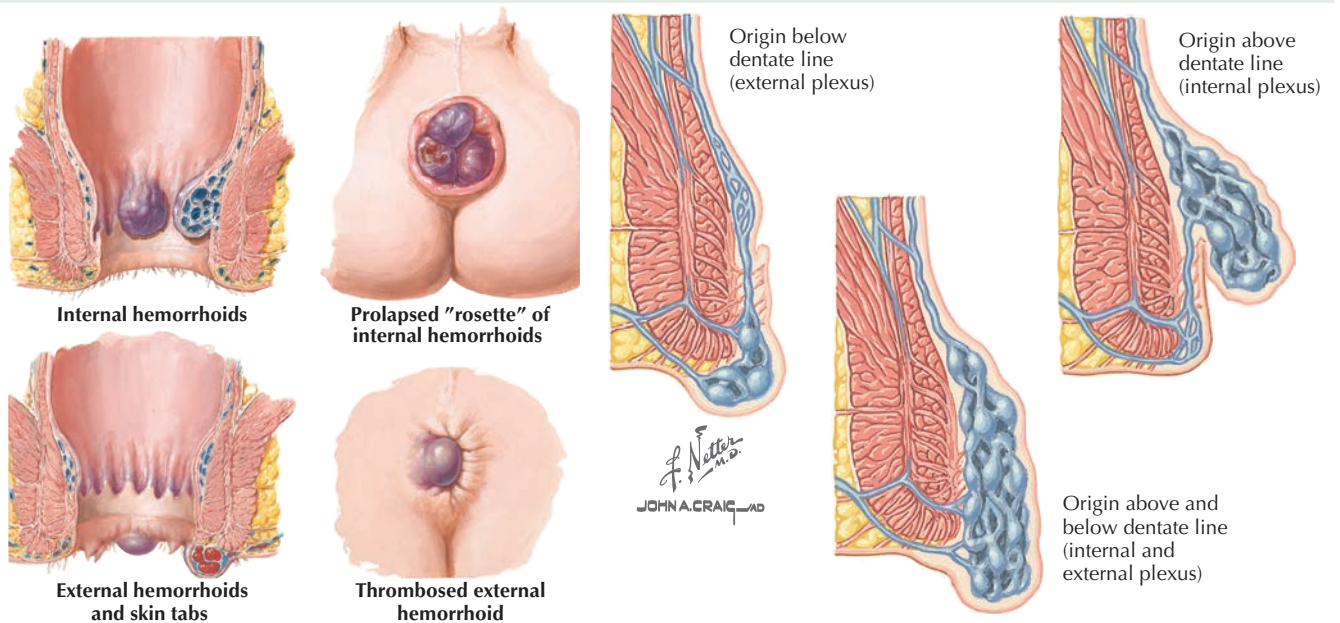


FIGURE 26-1 Anatomy and types of hemorrhoids.

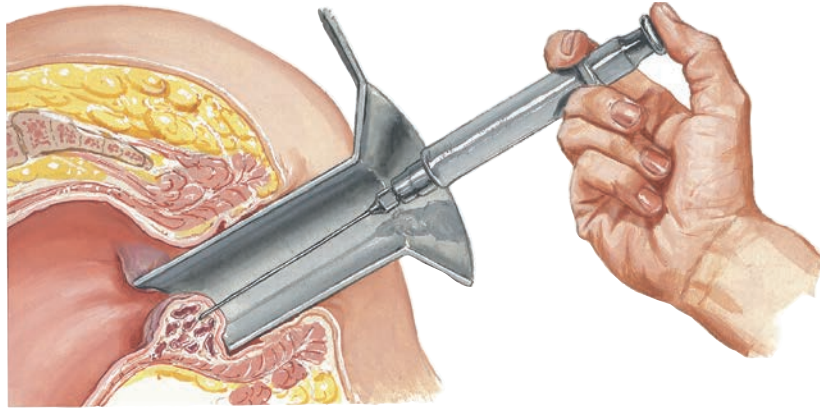
OFFICE PROCEDURES

Common office procedures in the management of patients with symptomatic hemorrhoids include rubber band ligation, infrared coagulation, bipolar diathermy, sclerotherapy, and cryotherapy. All these techniques rely on some form of tissue destruction, which then results in fixation of the remaining hemorrhoidal tissues.

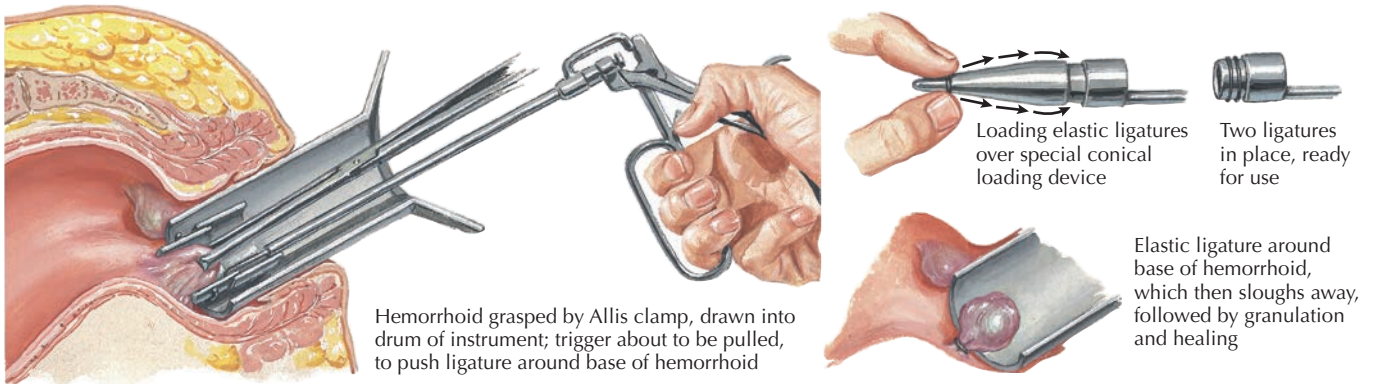
Rubber band ligation is the most frequently used procedure used in the United States. This technique is most often used to address 1st- and 2nd-degree hemorrhoids, although 3rd-degree hemorrhoids can occasionally be treated with this technique as well (Fig. 26-2, A). The rubber band necroses the intervening tissue over the course of 7 to 10 days and is passed in the patient's stool. The most common of the many implements available for application of the rubber bands is a *suction ligator*, which allows the surgeon to draw in the hemorrhoidal tissue and apply the rubber band with one hand. Other devices require that the operator grasp the hemorrhoidal pile with a long forceps and apply the rubber band with the other hand (Fig. 26-2, B).

Hemorrhoidal banding controls bleeding in more than 90% of cases. Complications are rare but include vasovagal response, pain, bleeding, and pelvic sepsis. Most complications can be avoided by ensuring that the rubber band is placed well above the dentate line, close to the base of the hemorrhoidal pile (Fig. 26-2, C). Pelvic sepsis may result from incorporation of the distal rectal wall into the band. The combination of pain, urinary retention, and fever after banding should raise suspicion of pelvic sepsis.

A. Injection of internal hemorrhoids



B. Ligation of internal hemorrhoids



C. Surgical management of internal hemorrhoids: Elastic ligation technique

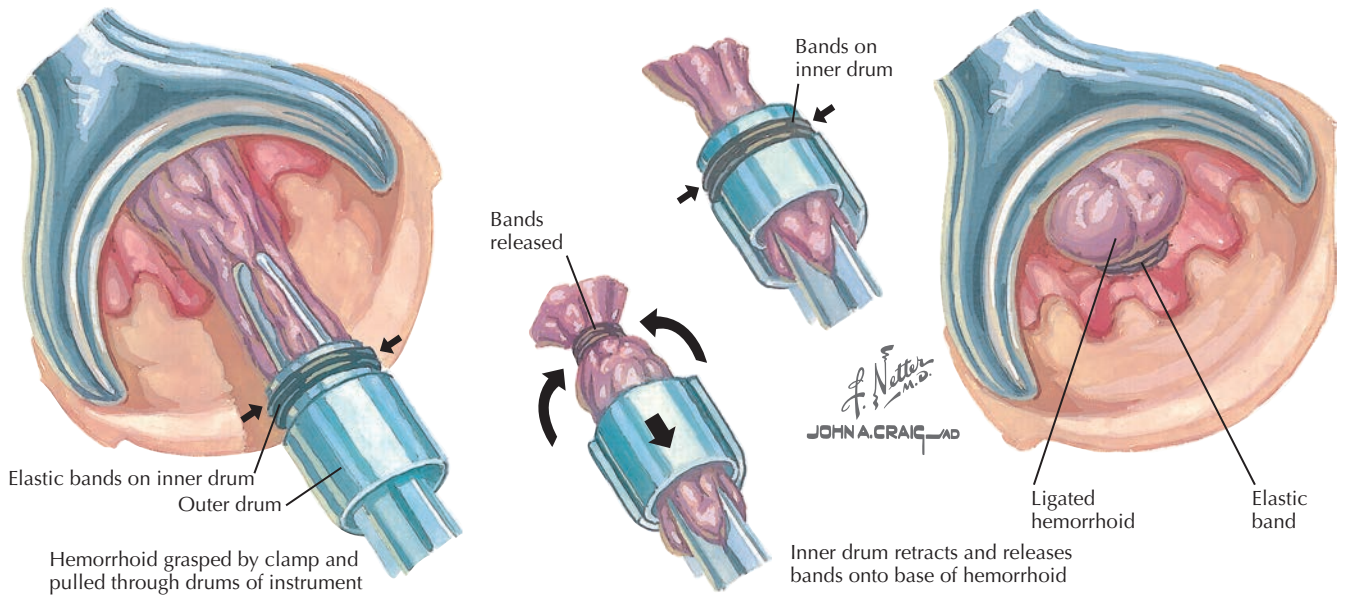


FIGURE 26-2 Office procedures for hemorrhoids.

OPERATIVE HEMORRHOIDECTOMY

Patients for whom medical or nonsurgical therapies are not successful are candidates for operative hemorrhoidectomy. Typically, these patients have 3rd- or 4th-degree hemorrhoids. Fortunately, postsurgical recurrence is rare. The most common procedures are the Ferguson and Milligan-Morgan hemorrhoidectomy. Both techniques involve elliptical excision of the internal and external hemorrhoidal complex (Fig. 26-3, A).

An operating anoscope is placed in the anal canal. An ellipse of anoderm is raised and dissected back toward the anal canal. The hemorrhoids are then raised off the anal sphincters. The layer of connective tissue that is present can be left on the sphincters, although some surgeons directly expose the sphincters. During this dissection it is important to separate the hemorrhoidal tissue from the internal sphincter without damaging the latter. After completion, the procedure is repeated on any further hemorrhoid columns that require removal.

The Ferguson technique is frequently used in the United States. After removal of the hemorrhoidal tissues, the base of the hemorrhoid is suture-ligated, and the anal mucosa/anoderm are reapproximated using a running absorbable stitch.

The Milligan-Morgan technique is used primarily in the United Kingdom. The defect is left open and allowed to granulate inward over 4 to 8 weeks.

STAPLED HEMORRHOIDOPEXY

Stapled hemorrhoidopexy was described as an alternative to traditional excisional hemorrhoidectomy because of the pain associated with the latter technique. The procedure involves placement of a mucosal purse-string suture 2 to 3 cm above the dentate line. A specially designed surgical hemorrhoidal stapler is used to resect the mucosa and submucosa associated with the hemorrhoid and to close the resultant defect.

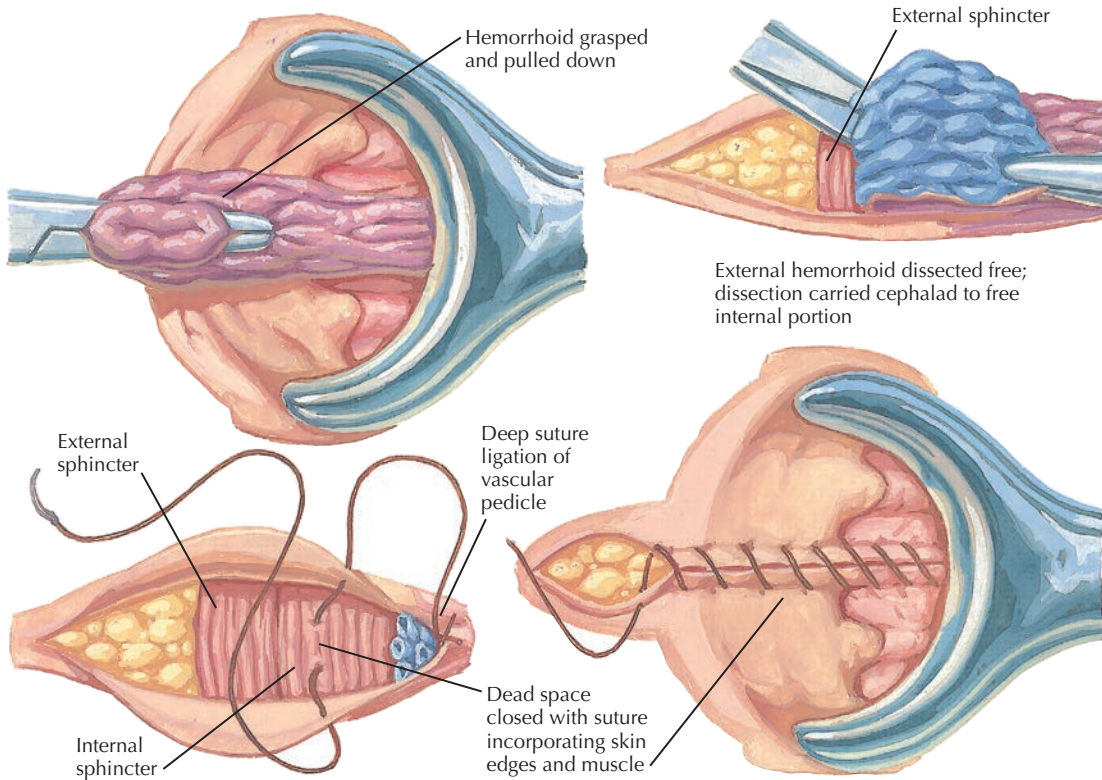
This technique is associated with less pain and analgesic use and higher rates of recurrence and residual prolapse. The most common complication of stapled hemorrhoidopexy is bleeding from the staple line. This is easily controlled with suture ligation or electrocautery. Other, rare complications include rectal perforation, pelvic sepsis, and chronic pain syndrome.

STRANGULATED HEMORRHOIDS

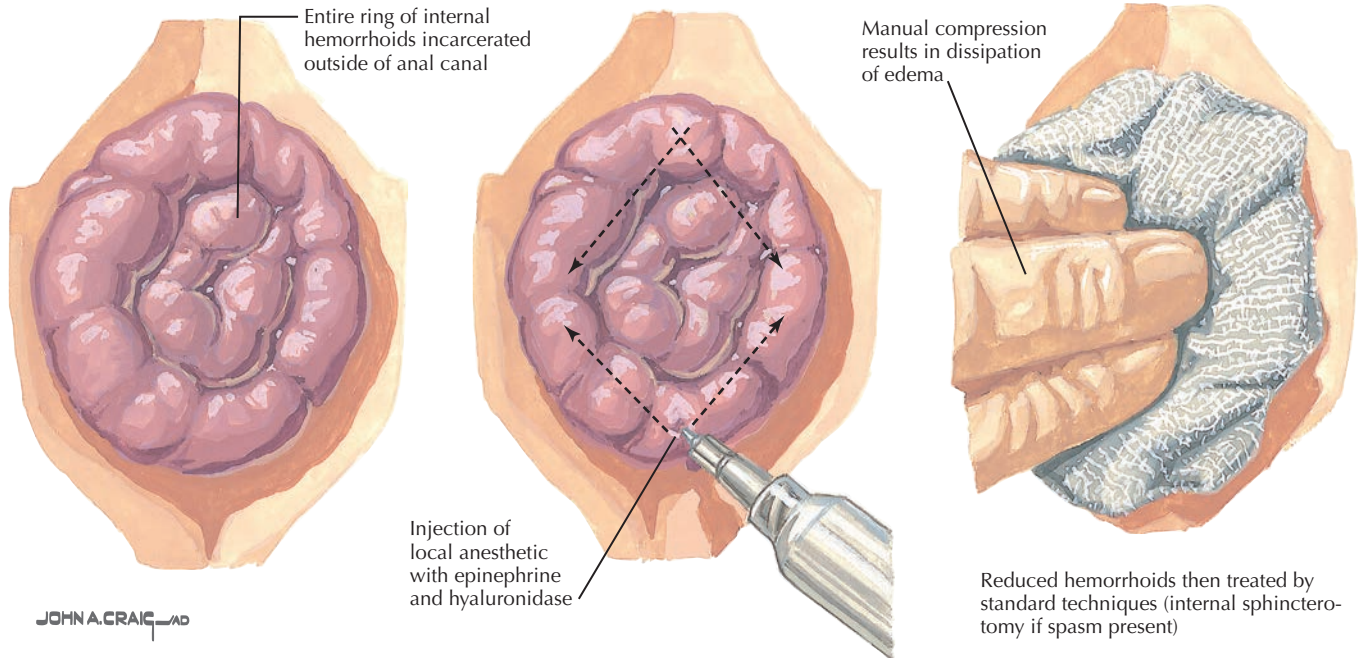
Strangulated (or incarcerated) hemorrhoids are 3rd- or 4th-degree hemorrhoids that become thrombosed because of chronic prolapse and resultant swelling. Patients typically have severe anal pain and sometimes urinary retention. Physical examination typically reveals thrombosis of the internal and external hemorrhoids, with or without evidence of necrosis (Fig. 26-3, B).

Patients can usually be managed with emergent excisional hemorrhoidectomy. If there is evidence of tissue necrosis, all nonviable tissue should be excised and the incision left open. In poor candidates for surgical intervention, the anoderm can be infiltrated with local anesthesia. The anesthesia causes the internal sphincter to relax, and the internal hemorrhoids can be reduced with gentle massage. External thrombectomies and multiple rubber band ligations of the internal hemorrhoids can be performed as an alternative to excisional hemorrhoidectomy.

A. Surgical management of internal hemorrhoids: Excision technique for mixed hemorrhoids



B. Incarcerated hemorrhoids



JOHN A. CRAIG, MD

FIGURE 26-3 Hemorrhoidectomy and incarcerated (strangulated) hemorrhoids.

SUGGESTED READINGS

Lestar B, Pennickx F, Kerremans R. The composition of anal basal pressure: an in vivo and in vitro study in man. *Int J Colorectal Dis* 1989;4:118-22.

Milligan ET, Morgan CN, Jones LE. Surgical anatomy of the anal canal and the operative treatment of hemorrhoids. *Lancet* 1937;2:119-24.

Schubert MC, Sridhar S, Schade RR, Wexner SD. What every gastroenterologist needs to know about common anorectal disorders. *World J Gastroenterol* 2009;15(26):3201-9.

Su MY, Chiu CT, Wu CS, et al. Endoscopic hemorrhoidal ligation of symptomatic internal hemorrhoids. *Gastrointestinal Endosc* 2003;58:871-4.

Thomson WH. The nature of haemorrhoids. *Br J Surg* 1975;62:542-52.

Perirectal Abscess and Fistula in Ano

Joshua I. S. Bleier and Husein Mooloo

INTRODUCTION

Cryptoglandular infection and abscess is a common problem encountered by general and colorectal surgeons. Development of abscesses is anatomically related to infection of the anal glands. Located in the intersphincteric space, the anal glands drain into the anal canal at the level of the anal crypts located at the dentate line; thus, strictly speaking, all these conditions start as intersphincteric abscesses.

PERIRECTAL ABSCESS

Anatomic Description

Anorectal abscess are defined by their anatomic relationship to the internal and external sphincter and levator musculature (Fig. 27-1). Abscesses that remain localized to the body of the gland in the potential intersphincteric space, between internal and external sphincters, are termed *intersphincteric* abscesses. Abscesses that perforate laterally through the external sphincter into the lower extrarectal space are called *ischiorectal* abscesses. The ischiorectal space is a pyramidal area bordered by the rectum and anus medially and pelvic side wall laterally. The apex of the ischiorectal space is formed by the levator ani muscle, and posteriorly the sacrotuberous ligament and gluteus maximus muscle form its borders. Importantly, the pudendal and internal pudendal vessels run through the superolateral wall of the ischiorectal space.

Most often, the infection will track through the intersphincteric space into the base of the ischiorectal space and into perianal soft tissue. This is termed a *simple perirectal* (perianal) *abscess* (PRA). This space contains both the external hemorrhoidal plexus and the subcutaneous part of the external anal sphincter.

Rarely, the infection will track cephalad and is termed *supralevator* abscess. More frequently, infections in the supralevator space originate in the pelvis, usually as a result of a diverticular abscess eroding through the pelvic floor. This space is bordered inferiorly by the muscles of the levator ani, laterally by the obturator fascia, and medially by the rectum.

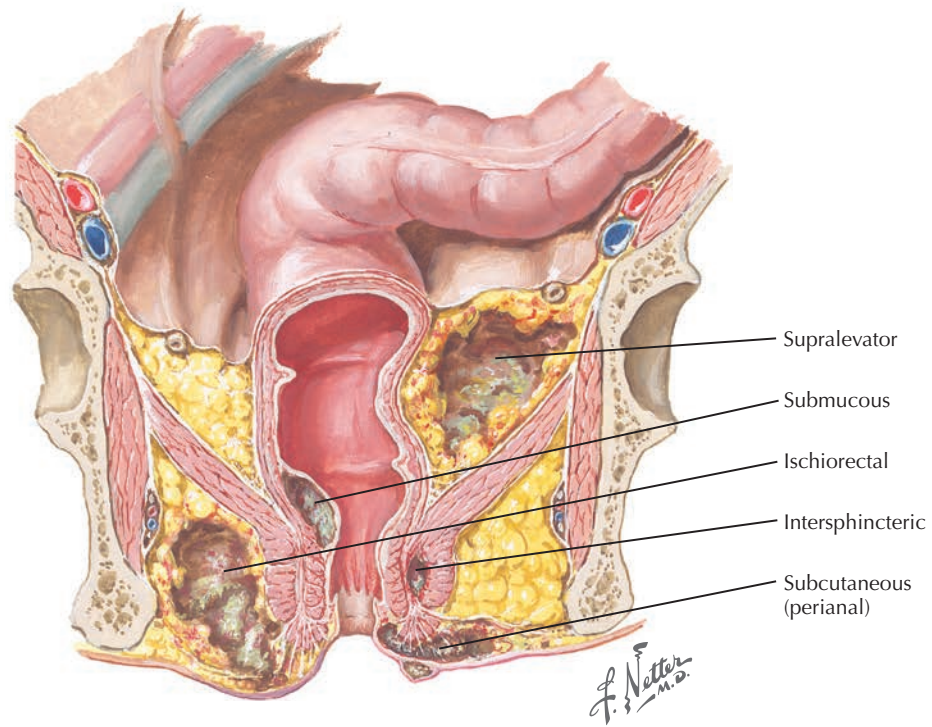


FIGURE 27-1 Sites of perirectal abscess.

Surgical Management of Anorectal Abscess

The main issue in the management of PRA is control of sepsis by draining the abscess. Surgical management requires not only adequate drainage but also effective anesthesia, for perioperative management as well as early postoperative pain control. An appropriate perianal block must be administered at surgery and relies on blocking nociceptive impulses from the pudendal nerve bilaterally. This approach allows for maximal relaxation and also sphincter relaxation, which augments exposure.

A perianal block is administered by injection of local anesthetic at the root of the pudendal nerve as it exits from Alcock's canal just medial to the pubic tubercle (Fig. 27-2, A). The tubercle is easily palpated through the skin, and the needle is introduced medial to this, as deeply as possible. Additional local anesthetic is fanned out in a diamond shape adjacent to the sphincters, to infiltrate the ramifying branches of the nerve. Another option is to perform a ring block, in which local anesthetic is introduced into the perianal skin and the underlying sphincter muscle.

Lastly, the skin immediately surrounding the abscess can be infiltrated. For all these methods, a small-bore needle (25 gauge) should be used because rapid infiltration through a large-bore needle can cause pain. Further, the acidic milieu that results from a purulent environment leads to less effective anesthesia if directly infiltrated; therefore the nonerythematous skin in the area should be targeted.

Specific Abscesses

Superficial anorectal abscesses are drained directly; the incision should be large enough to provide adequate drainage. Incisions should be made radially to avoid disruption of sensory and motor nerves.

Ischiorectal abscesses are deeper but they are approached in a manner similar to superficial abscesses. Whenever possible, these procedures should be done with the patient under anesthesia to allow for appropriate exposure and pain control. We routinely position the patient in the prone jackknife position, with buttock retraction using tape (Fig. 27-2, B). This position allows for optimal exposure for both surgeon and assistant. The incision should be large enough to allow for adequate drainage. Blunt dissection should be avoided to minimize damage to small nerves and blood vessels in the ischiorectal fossa. Packing of the abscess cavities is unnecessary and counterproductive to effective drainage and should be used only when needed to control hemorrhage.

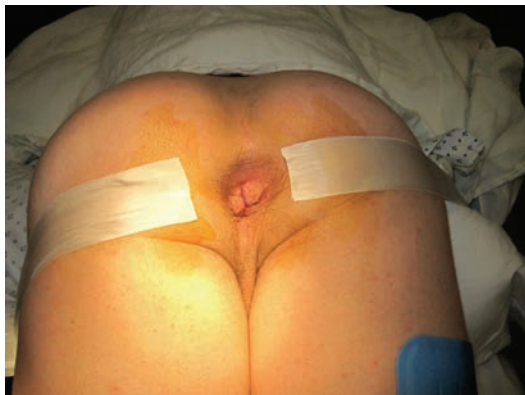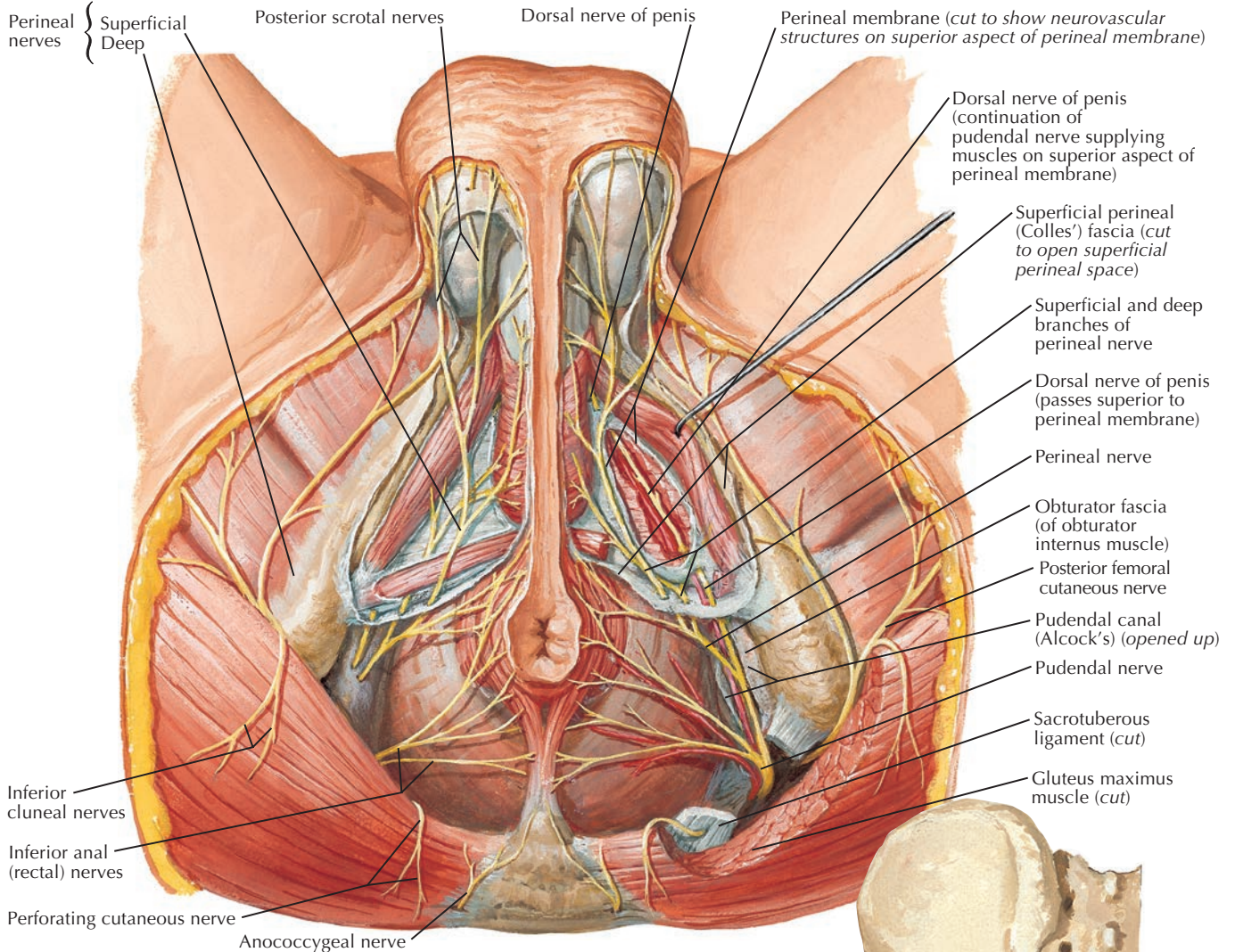
The patient with *intersphincteric* abscess often shows no external stigmata of abscess. The patient will complain of severe pain, especially during defecation, and bedside examination is often prohibitively painful. In these cases, once the abscess is localized by needle aspiration, drainage through the wall of the rectum is indicated, with adequate division of the overlying internal sphincter musculature to allow for adequate drainage.

Supralevator abscesses should not be drained by the transanal approach and may require percutaneous drainage using interventional radiology, or appropriate operative control through a transrectal approach.

Abscess with Fistula

Often, perianal infection is accompanied by perianal fistula, and a careful survey must be done at surgery for any fistula. Purulent drainage through an internal fistula opening can sometimes be seen perioperatively, and if not, injection of dilute hydrogen peroxide or methylene blue through the abscess cavity can be performed to help elucidate fistulous anatomy. If no fistula can be easily found, simple abscess drainage is performed. If a fistula is encountered, it should be managed appropriately (see later section).

A. Perineal innervation. Pudendal nerve exits from below the pubic tubercle and ramifies through the ischioanal fossa.



B. Patient positioning. The patient is in the prone jackknife position, with the buttocks distracted by tape, allowing for optimal visualization of the perianal area.

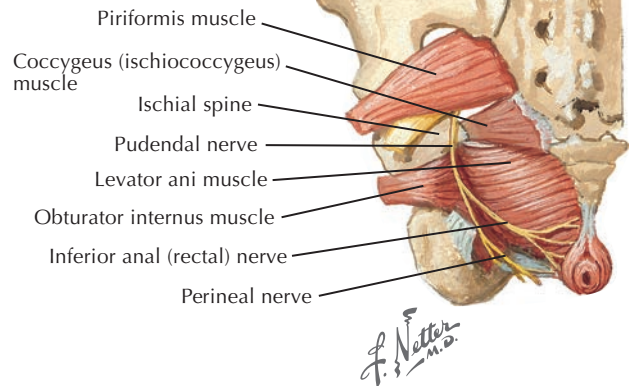


FIGURE 27-2 Perineal innervation and patient positioning.

Deep Postanal Space

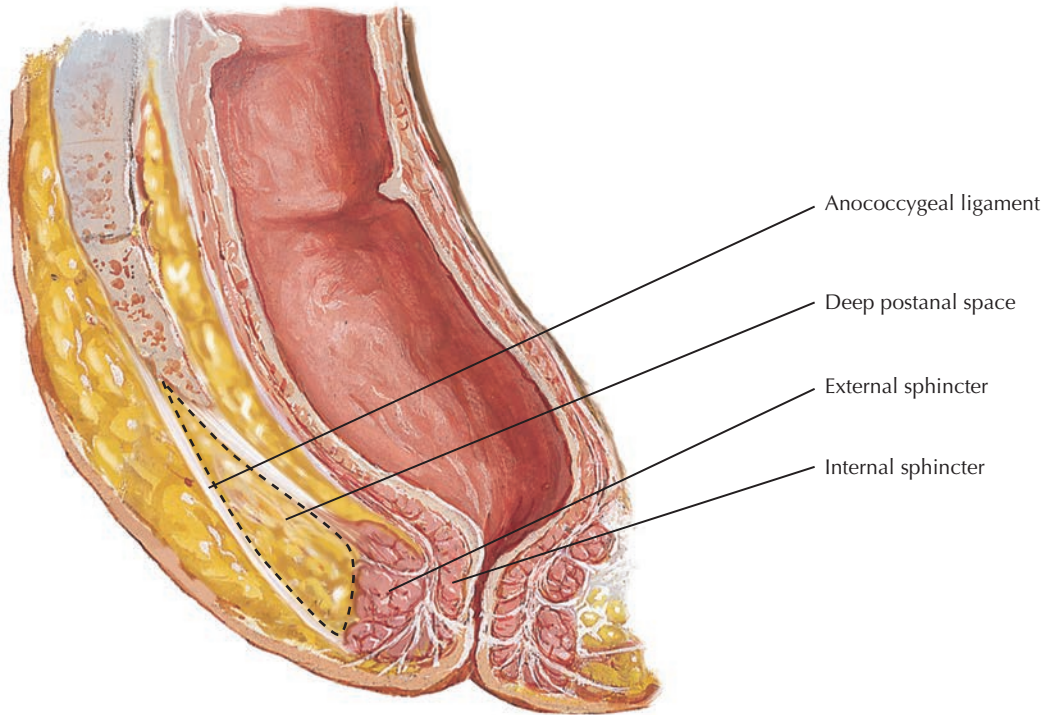
The deep postanal space abscess is a unique case that requires a high index of suspicion to identify. Chronic recurrent bilateral ischiorectal abscesses are called “horseshoe” abscesses and are pathognomonic for an abscess source in the deep postanal space. The deep postanal space is located cephalad to the anococcygeal ligament in the posterior midline and continues to bilateral ischiorectal spaces. Injection of either ischiorectal abscess cavity will usually result in drainage from an internal fistula in the posterior midline.

Effective management of these fistulas requires not only drainage through counterincisions over each ischiorectal space, but also unroofing of the deep postanal space. This approach requires division of the anococcygeal ligament and entry into this space (Fig. 27-3, A). The surgeon should work toward and just distal to the coccyx to guide the appropriate dissection. Division of the anococcygeal ligament and discharge of purulent fluid will confirm entry into this space.

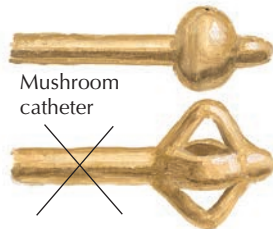
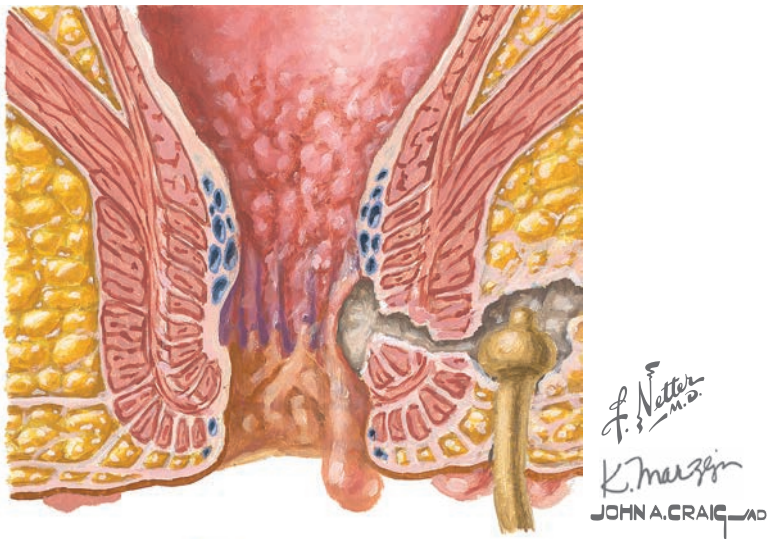
If a fistula is encountered in the posterior midline, division of the internal sphincter musculature distal to the fistula and into the deep postanal space is performed to allow adequate drainage. Counterincisions over the ischiorectal abscess are performed, and drainage catheters or Penrose drains are passed through to facilitate decompression. In patients with recurrent fistula, wide division of the residual external sphincter may be required, termed the *modified Hanley procedure*.

Occasionally, deep ischiorectal fossa abscesses cannot be easily drained by superficial incisions. In these cases, drainage may be facilitated by placement of catheter with a mushroom or flared tip. This approach allows for continued drainage and development of a persistent tract, which will remain open after the catheter is removed (Fig. 27-3, B).

A. Deep postanal space



B. Catheter drainage of perirectal abscesses



Mushroom catheter

Malecot catheter

(allows ingrowth of fibrous tissue, making removal difficult)

A mushroom or flared-tip catheter can be placed in deep ischioanal abscesses to maintain drainage

FIGURE 27-3 Deep postanal space abscess.

FISTULA IN ANO

Approximately 30% to 50% of anorectal abscesses will have associated fistulas. A *fistula* is defined as an epithelialized tract that connects two epithelially lined organs, in this case the rectum and the skin. This condition is usually heralded by chronic or recurrent drainage from a prior draining abscess site. Appropriate determination of the presence and anatomy of a fistula is imperative to guide treatment.

Anatomic Description

Types of Fistula

Fistulas are defined by their anatomic relationship to the pelvic floor musculature and sphincter complex (Fig. 27-4, A). The majority of fistulas track low through the subcutaneous soft tissue with minimal sphincteric involvement and are termed *simple*, or *superficial*. Simple lay-open fistulotomy is a time-honored and effective approach with a high success rate. *Complex* fistulas traverse a significant component of the sphincter or levator musculature and must be approached with caution. Performing a fistulotomy would require division of significant amount of sphincter muscle and may impair the continence mechanism.

Intersphincteric fistulas track through the intersphincteric space and exit on the perianal skin. *Transsphincteric* fistulas traverse both internal and external sphincter muscles. *Extrasphincteric* fistulas track above the sphincter complex from an internal opening and exit superficially, whereas *suprasphincteric* fistulas originate above the muscular pelvic diaphragm and exit externally.

The relationship of the external opening to the anal verge can offer clues as to the source of the internal opening using Goodsall's rule: An imaginary line is drawn transversely across the anal opening, and fistulas anterior to this line generally track radially to internal rectal openings (Fig. 27-4, B). Fistulas posterior to this line, as well as those located greater than 2 cm from the verge, tend to originate from a posterior midline opening.

Preoperative Imaging and Patient Positioning

If a complex tract is suspected, magnetic resonance imaging (MRI), ultrasound, or fistulography can be performed before initial examination in the operating room. This procedure can be especially helpful with Crohn fistulas, which tend to have multiple or complex tracts (see later section).

As mentioned earlier, patients are best examined placed in the prone jackknife position with the buttocks distracted with tape (Fig. 27-5, A). A headlight and Lockhart-Mummery fistula probes are important equipment that can facilitate identification of the tract.

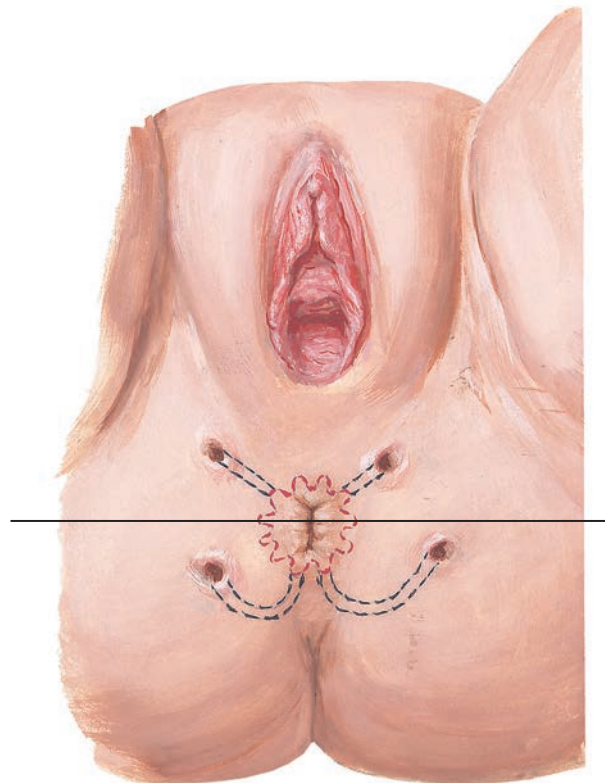
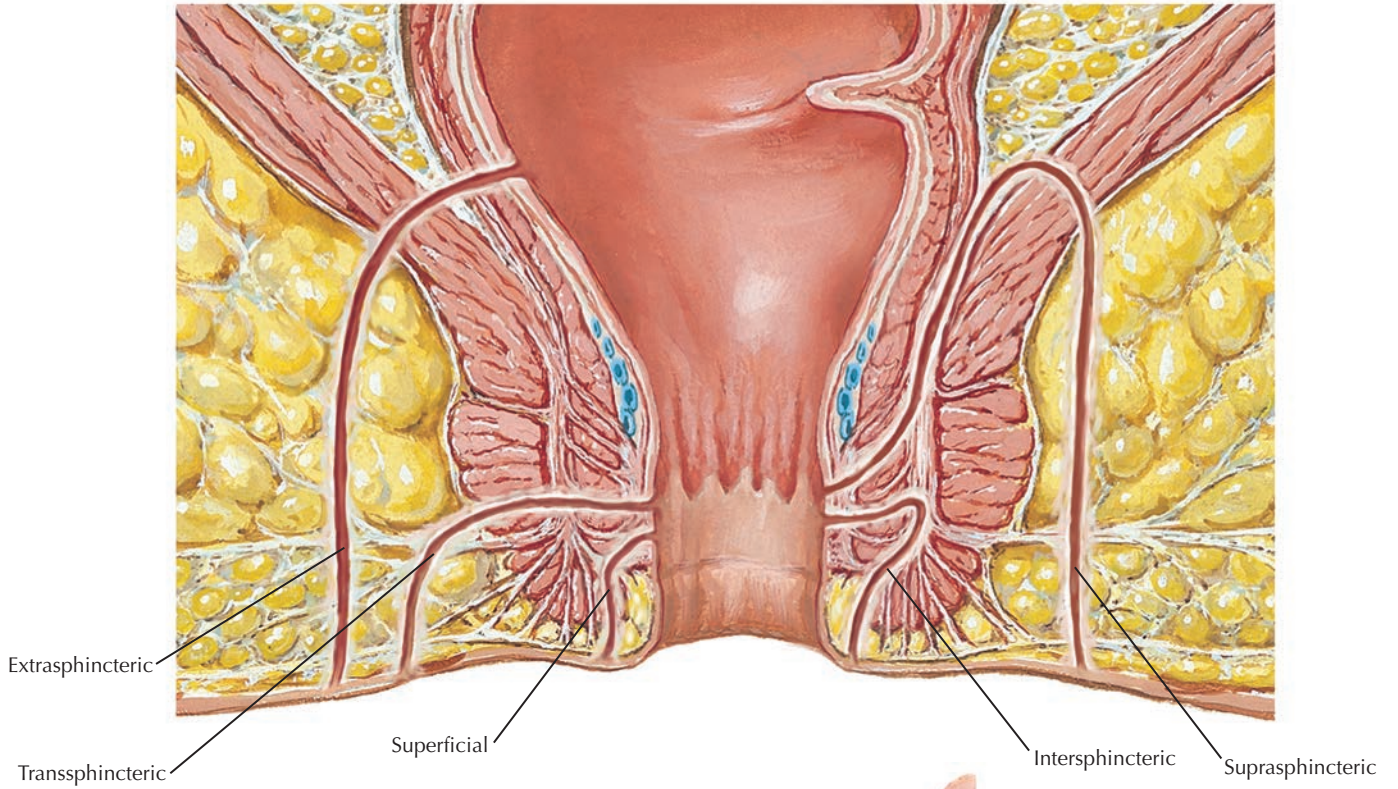
Surgical Management of Anorectal Fistula

Complex fistulas are treated initially by management of local sepsis through adequate abscess drainage. To spare sphincter musculature, a draining seton is usually the initial step in management. Draining *setons* are biologically inert drains through the fistula tract to provide ease of egress of infected material (Fig. 27-5, B).

Once sepsis and inflammation have resolved, the anatomy of the fistula and its relationship to the sphincter musculature can be better defined, either by careful clinical examination or adjunctive imaging studies such as ultrasound or pelvic MRI.

Intersphincteric fistulas can usually be safely approached with fistulotomy. Division of part or all of the internal sphincter muscle can usually be accomplished with little to no change in continence. This procedure is most easily done by placing a fistula probe through the fistula and dividing along it with electrocautery.

A. Types of anorectal fistula



B. Goodsall-Salmon's rule

J. Netter M.D.
JOHN A. CRAIG, MD
K. Marzani

FIGURE 27-4 Types of anorectal fistula and Goodsall's rule.

Surgical Management of Anorectal Fistula—Cont'd

Special consideration must be given to female patients, especially those of reproductive age and with anterior fistulas, because the sphincter complex is usually thinner and more tenuous anteriorly. In addition, the rate of occult sphincter injury after vaginal delivery is significant, approaching 30%, and further compromise of the sphincter musculature may result in changes of continence in a previously asymptomatic female.

It can be difficult at times to differentiate between the internal and external sphincter. One helpful surgical maneuver is to place the sphincter mechanism on gentle stretch with an operating anoscope and use the back of a dissecting forceps or finger to feel the groove between the internal and external sphincter. In doing this, surgeons can be reassured as to whether they are dealing with an intersphincteric or a transsphincteric fistula. Additionally, only fibers of the voluntary external sphincter will twitch when stimulated by electrocautery. The involuntary internal sphincter should not react to electrocautery.

Transsphincteric fistulas are best treated conservatively with sphincter-sparing approaches. Many techniques have been developed for their management. Initial approaches should include sphincter-sparing techniques, such as injection of fibrin glue along the fistula tract to seal the fistula and promote healthy tissue ingrowth. This approach is safe and has not been shown to affect continence; however, success rates are uniformly poor, often less than 20%, and require expensive materials.

The *fistula plug* is currently the most widely used approach and involves pulling a tapered plug of porcine submucosa or fibrous scaffolding through the fistula tract and anchoring it to the sphincter muscle. Initial reports of success with this approach were encouraging, with success rates as high as 80%. However, time and experience have shown durable results to be much lower in general, with success rates in the range of 30% to 40%. In addition, the plugs are expensive and often not covered by insurance.

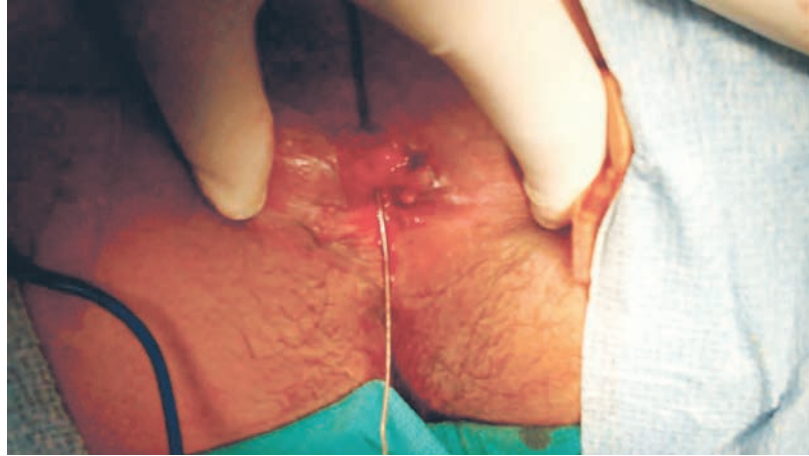More recently, the development of the LIFT—ligation of the intersphincteric fistula tract—procedure has been used with significant success. This technique involves isolating the fistula tract as it traverses the intersphincteric space, ligating it, and excising the intersphincteric component. Preliminary results show it to be comparable or even superior to the fistula plug, with a similar safety profile. This technique is easy to perform and becoming more widely used, with a randomized clinical trial of LIFT versus fistula plug underway.

Persistent failure or extrasphincteric fistulas may also be approached with the *advancement flap*. This technique is more difficult and involves mobilization of a full-thickness or partial-thickness flap of anoderm (endoanal) or rectal wall (endorectal). After excising the internal opening and scarred mucosa, the surgeon sutures a flap over the internal fistulous opening. This technique is more technically demanding, requires significant experience and training, puts large sections of otherwise healthy tissue at risk for ischemia and tissue loss, and can result in larger internal defects. Also, these dissections are associated with a not-insignificant risk of changes in continence because of the dissection of internal and external sphincters.

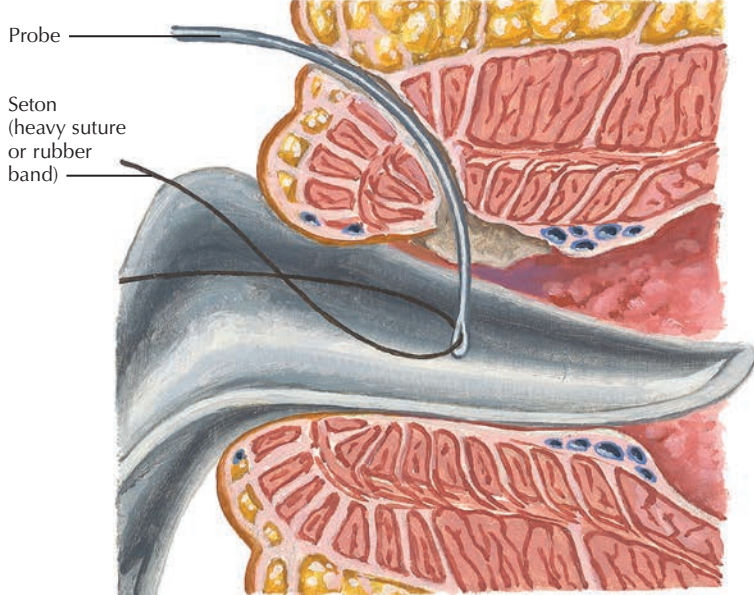
Suprasphincteric fistulas often arise from a pelvic source, usually a diverticular abscess. Appropriate source control and management of the source will usually result in closure of the fistula.

Occasionally, complex fistulas remain refractory to sphincter-sparing approaches. Strong consideration must be given to maintenance of a long-term indwelling seton to minimize the risk of recurrent sepsis and avoid the risk of significant impairment in continence.

A. Probe through fistula tract

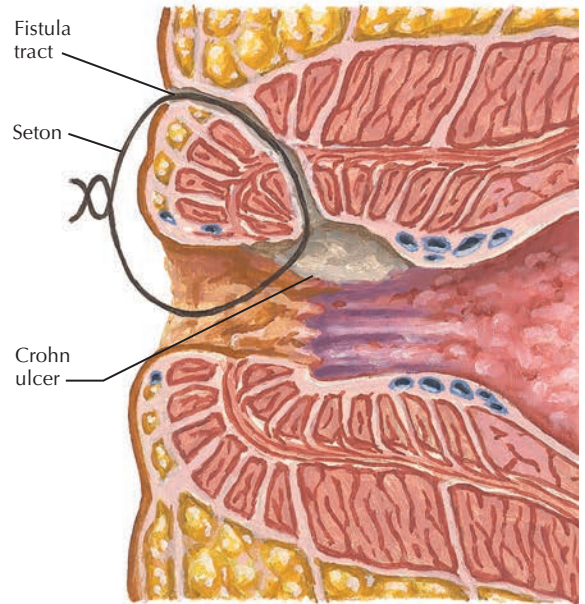


B. Seton placement



Sepsis of fistula tract controlled by placing seton (avoids fistulotomy wounds, which heal poorly and may lead to incontinence)

JOHN A. CRAIG MD



Seton left in place between internal and external openings to prevent abscess formation and further destruction of sphincter mechanism

FIGURE 27-5 Perirectal fistula examination and management.

CROHN-RELATED ABSCESS AND FISTULA

Complex perianal abscesses and fistulas are a hallmark of anorectal Crohn disease. As with benign anorectal abscesses, treatment requires initial management of local sepsis, with drainage and minimal dissection, because healing is impaired in patients with inflammatory bowel disease (IBD). Once local sepsis is managed, appropriate medical therapy can be initiated. The use of biologic modifiers (e.g., anti-tumor necrosis factor therapy) has been shown to have significant efficacy in healing anorectal fistulas, and thus surgery may not be necessary.

Unlike benign cryptoglandular fistulas, Crohn-related fistulas are often complex with multiple blind-end tracts. In general, they do not follow Goodsall's rule (see earlier). Because of the issues related to recurrence and difficulty with healing, typical surgical approaches are associated with high morbidity and chronic wounds that may not heal.

In the patient with quiescent disease and superficial fistulas, fistulotomy has been shown to be effective. With medically controlled disease and transsphincteric fistulas, sphincter-sparing approaches (e.g., fistula plug, fibrin glue) may have some success. Often, chronic use of indwelling setons is indicated to avoid significant morbidity and risk of sphincter injury associated with repair attempts. Patients with Crohn-related abscess and fistula should be referred to specialists who often see patients with Crohn disease.

SUGGESTED READINGS

- Abbas MA, Lemus-Rangel R, Hamadani A. Long-term outcome of endorectal advancement flap for complex anorectal fistulae. *Am Surg* 2008;74:921-4.
- Bleier JI, Moloo H, Goldberg SM. Ligation of the intersphincteric fistula tract: an effective new technique for complex fistulas. *Dis Colon Rectum* 2010;53:43-6.
- Champagne BJ, O'Connor LM, Ferguson M, et al. Efficacy of anal fistula plug in closure of cryptoglandular fistulas: long-term follow-up. *Dis Colon Rectum* 2006;49:1817-21.
- Christoforidis D, Pieh MC, Madoff RD, Mellgren AF. Treatment of transsphincteric anal fistulas by endorectal advancement flap or collagen fistula plug: a comparative study. *Dis Colon Rectum* 2009;52:18-22.
- Dudding TC, Vaizey CJ, Kamm MA. Obstetric anal sphincter injury: incidence, risk factors, and management. *Ann Surg* 2008;247:224-37.
- Garcia-Aguilar J, Belmonte C, Wong WD, Goldberg SM, Madoff RD. Anal fistula surgery: factors associated with recurrence and incontinence. *Dis Colon Rectum* 1996;39:723-9.
- Hanley PH. Conservative surgical correction of horseshoe abscess and fistula. *Dis Colon Rectum* 1965;8:364-8.
- Johnson JK, Lindow SW, Duthie GS. The prevalence of occult obstetric anal sphincter injury following childbirth: literature review. *J Matern Fetal Neonatal Med* 2007;20:547-54.
- Lewis RT, Maron DJ. Anorectal Crohn's disease. *Surg Clin North Am* 2010;90:83-97, table of contents.
- Lindsey I, Smilgin-Humphreys MM, Cunningham C, Mortensen NJ, George BD. A randomized, controlled trial of fibrin glue vs. conventional treatment for anal fistula. *Dis Colon Rectum* 2002;45:1608-15.
- Malik AI, Nelson RL. Surgical management of anal fistulae: a systematic review. *Colorectal Dis* 2008;10:420-30.
- Rojanasakul A, Pattanaarun J, Sahakitrungruang C, Tantiphlachiva K. Total anal sphincter saving technique for fistula-in-ano: the ligation of intersphincteric fistula tract. *J Med Assoc Thai* 2007;90:581-6.
- Swinscoe MT, Ventakasubramaniam AK, Jayne DG. Fibrin glue for fistula-in-ano: the evidence reviewed. *Tech Coloproctol* 2005;9:89-94.

Open Inguinal Hernia Repair

David M. Krpata and Michael J. Rosen

INTRODUCTION

Approximately 75% of hernias occur in the groin, which makes inguinal hernia repair one of the most common procedures performed by the general surgeon. The anatomy can be difficult to grasp, however, and before performing inguinal herniorrhaphy, the surgeon must understand inguinal anatomy to avoid complications such as chronic pain and recurrence.

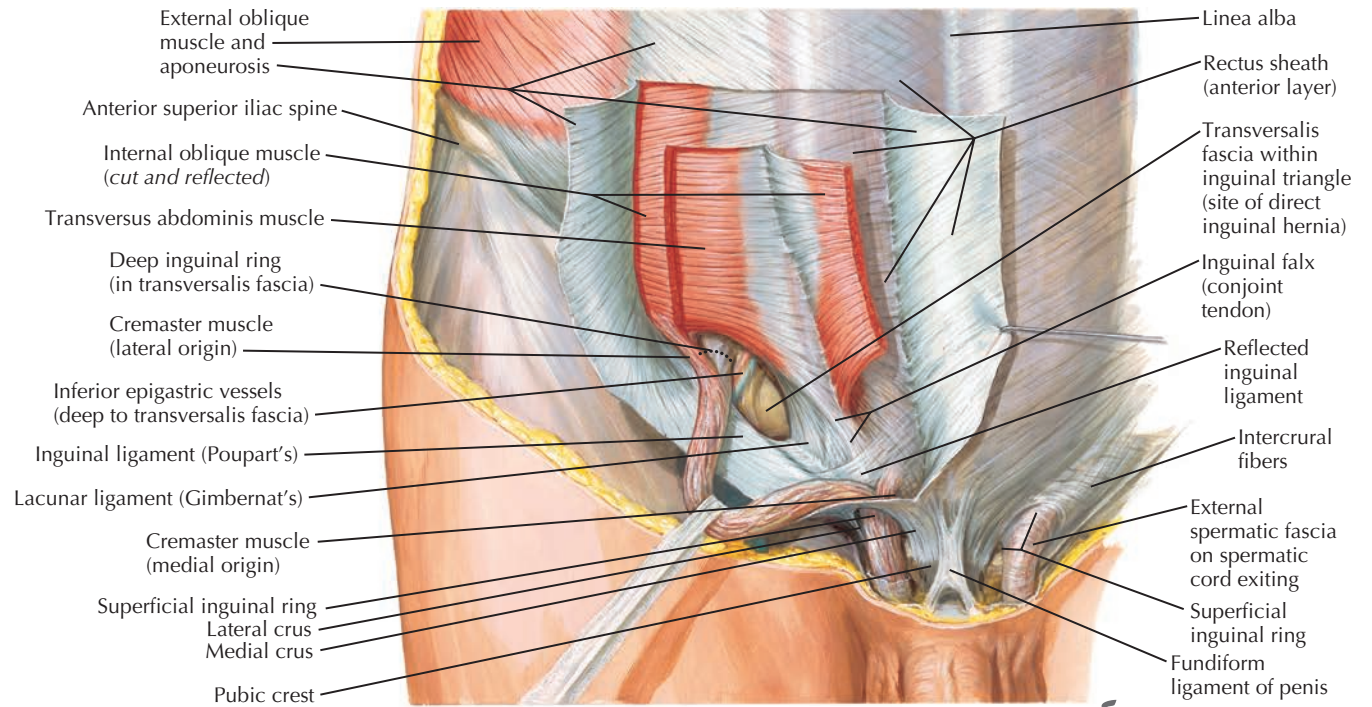
TERMINOLOGY

In referring to inguinal hernias, a major defining point is location of the defect—direct versus indirect. This distinction is strictly anatomic because the operative repair is the same for both types. Approximately two thirds of inguinal hernias are indirect. Men are 25 times more likely to have an inguinal hernia than women, and indirect hernias are more common regardless of gender. A *direct inguinal hernia* is defined as a weakness in the transversalis fascia within the area bordered by the inguinal ligament inferiorly, the lateral border of the rectus sheath medially, and the epigastric vessels laterally (Fig. 28-1). This area is referred to as *Hesselbach's triangle*.

Located lateral to the inferior epigastric vessels, an *indirect inguinal hernia* is characterized by the protrusion of the hernia sac through the internal inguinal ring toward the external inguinal ring and, at times, into the scrotum. Indirect inguinal hernias result from a failure of the processus vaginalis to close completely (Fig. 28-2). An inguinal hernia that has direct and indirect components is referred to as a *pantaloon hernia*.

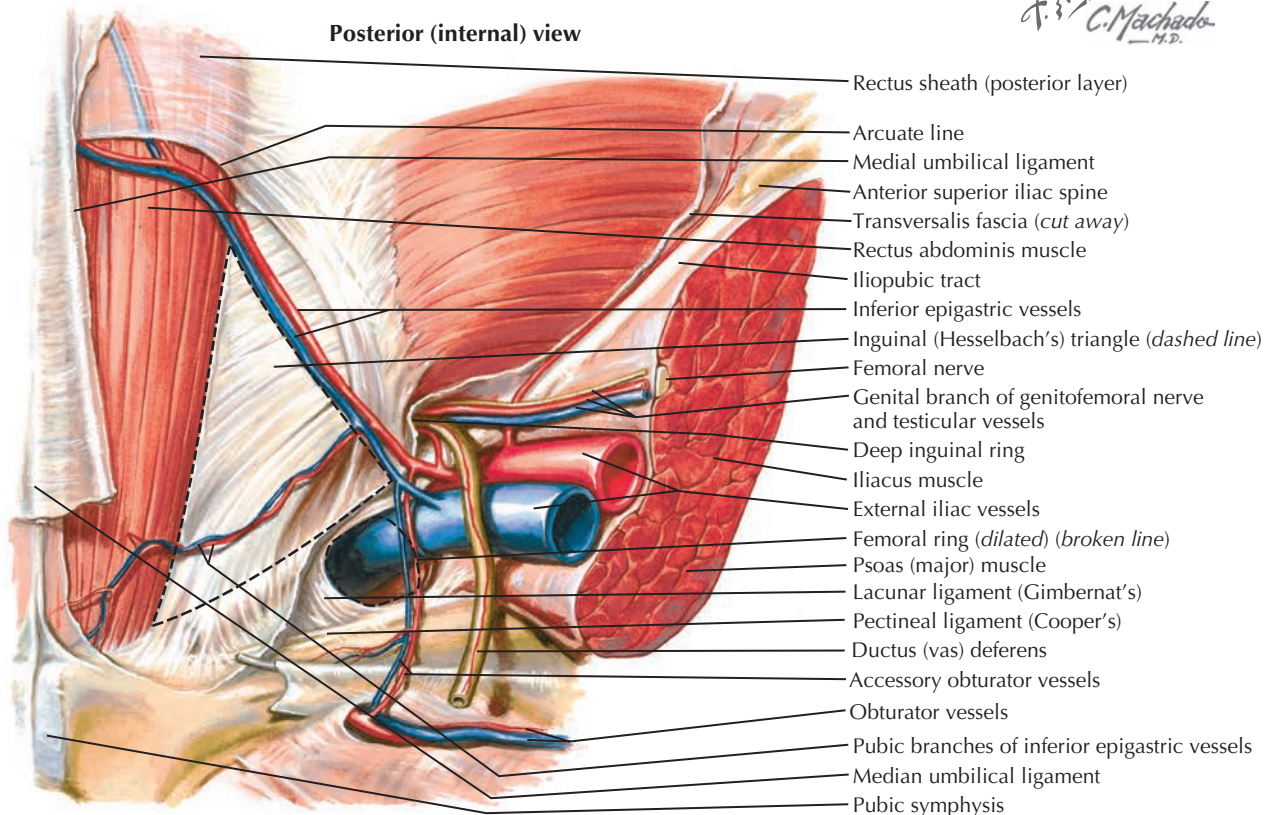
A hernia is defined as *reducible* if its contents can be placed back into the peritoneal cavity, alleviating their displacement through the musculature. In contrast, a hernia with contents that cannot be reduced is termed *incarcerated* (Fig. 28-3). If the blood supply to the contents of the hernia is compromised, the hernia is defined as *strangulated*. Strangulation is a potentially fatal complication of a hernia and should always be considered a surgical emergency. Less common inguinal hernias include *Amyand's hernia*, with the appendix (normal or acutely inflamed) contained in the hernia sac, and *Littre's hernia*, which contains a Meckel's diverticulum.

Anterior view



F. Netter M.D.
C. Machado M.D.

Posterior (internal) view



Hesselbach's triangle by Carlos Machado after Frank Netter

FIGURE 28-1 Inguinal region: dissections.

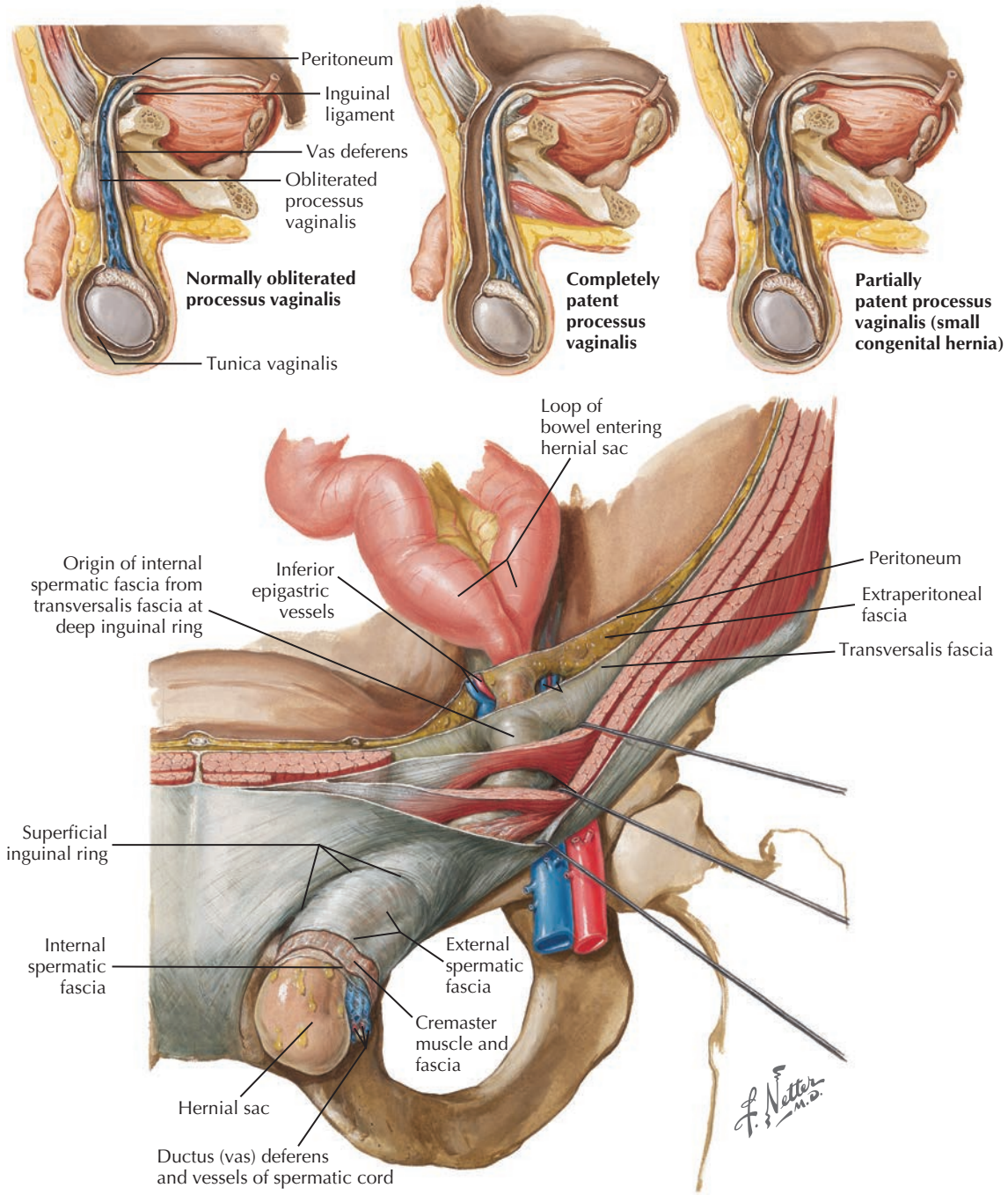


FIGURE 28-2 Patent processus vaginalis and indirect inguinal hernia.

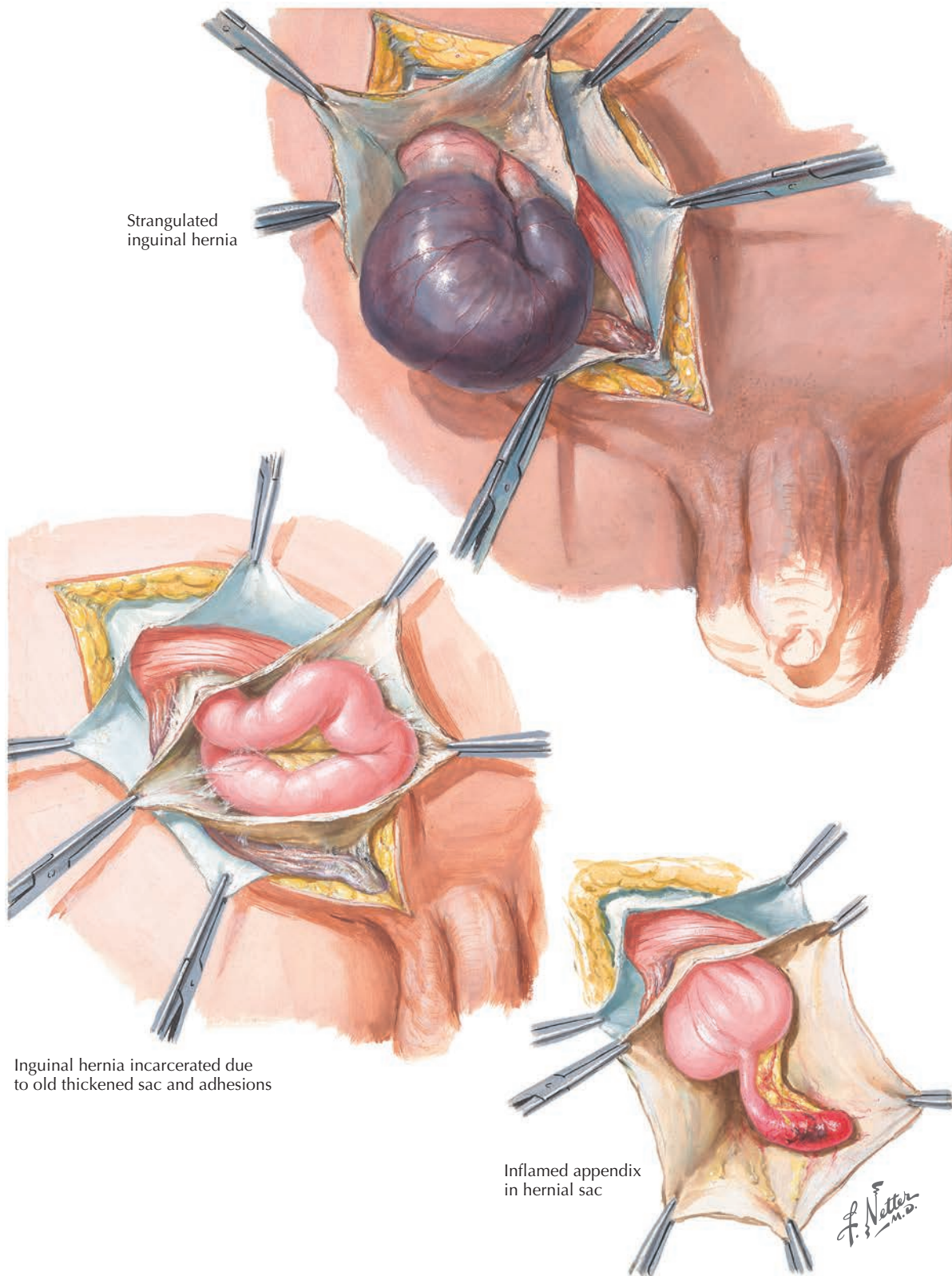


FIGURE 28-3 Types of hernias: incarcerated, strangulated, and Amyand's (appendix in sac).

SURGICAL APPROACH

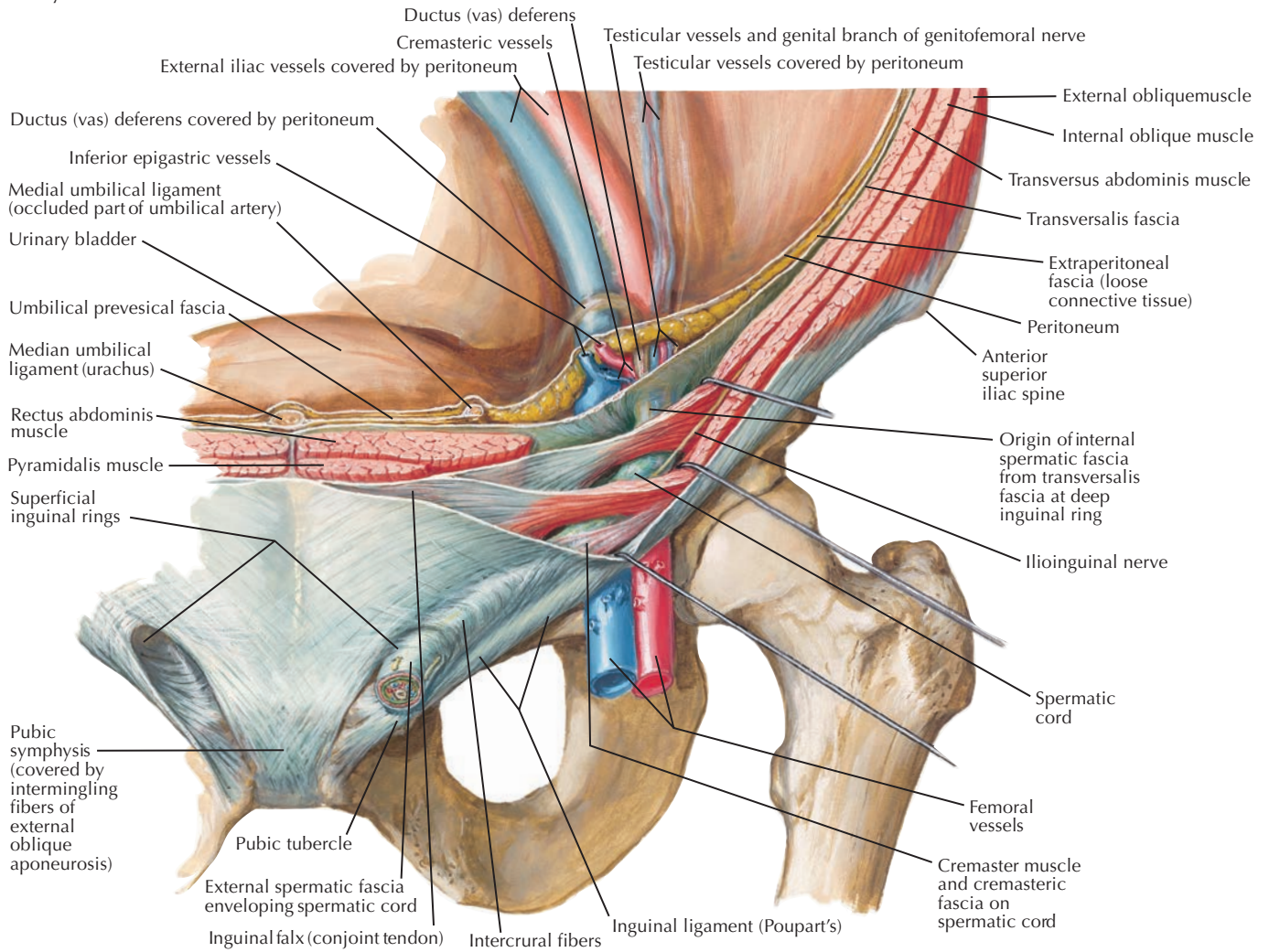
Open inguinal hernia repair has evolved from primary tissue repairs (tension repairs) to tension-free repair with mesh placement. However, an understanding of tissue-based repairs remains important, particularly for surgeons repairing inguinal hernias in the setting of contamination. *Tension-free repair* with mesh can be performed with many different techniques. Several unique mesh modifications enable the surgeon to patch the defect through an anterior approach (Lichtenstein), use a prosthetic plug (plug and patch), or place a bilayered mesh for anterior and posterior repair. Each of these approaches has unique advantages and disadvantages. This chapter focuses on the *Lichtenstein repair*, which remains one of the most common open inguinal hernia repairs.

To understand the anterior approach, the surgeon must appreciate the layers of the abdominal wall and their relation to the inguinal canal. The layers and the location of their neurovascular structures include skin, subcutaneous fat (e.g., Camper's and Scarpa's fasciae), muscles (external and internal oblique, transversus abdominis), transversalis fascia, preperitoneal fat, and peritoneum (Fig. 28-4, A).

The inguinal canal is approximately 4 cm in length and extends from the internal inguinal ring to the external inguinal ring. Within the inguinal canal lies the spermatic cord, which consists of the testicular artery, pampiniform venous plexus, the genital branch of the genitofemoral nerve, the vas deferens, cremasteric muscle fibers, cremasteric vessels, and the lymphatics. The superficial border of the inguinal canal is the external oblique aponeurosis. As the external oblique aponeurosis forms the inguinal (Poupart's) ligament, it rolls posteriorly, forming a "shelving edge," and defines the inferior border of the inguinal canal with the lacunar ligament. Posteriorly, the inguinal canal is bound by the transversalis fascia, often referred to as the "floor" of the inguinal canal. The inguinal canal is bound superiorly by the internal oblique and transversus abdominis musculoaponeurosis (see Fig. 28-1).

Before making an incision, it is essential for the surgeon to identify the landmarks defining the inguinal ligament. The anterior superior iliac spine (ASIS) and pubic tubercle are the insertion points for the inguinal ligament (Fig. 28-4, B). One of the challenging aspects of open inguinal hernia repair is securing the mesh to medial components. To help expose this area, the incision should begin over the pubis and extend 1 to 2 cm cephalad to the inguinal ligament, from the external ring to the internal ring.

A. Layers of the abdominal wall



B. Anatomic landmarks

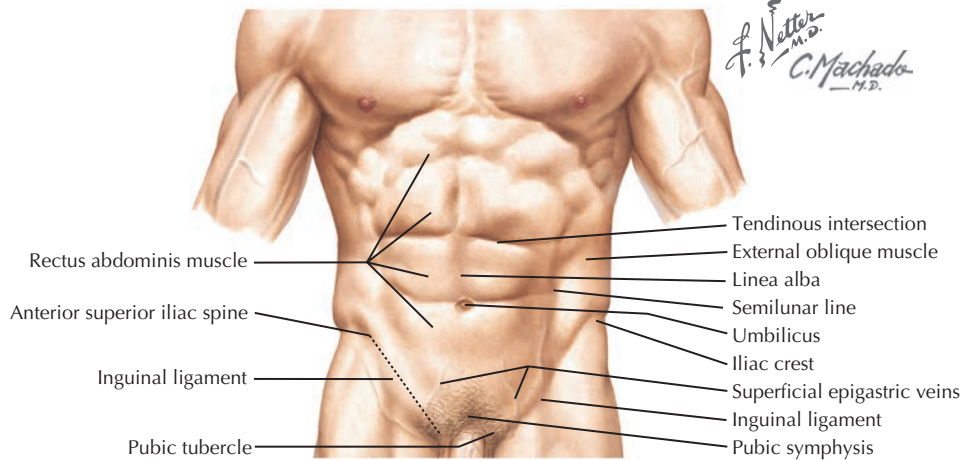


FIGURE 28-4 Abdominal wall and anatomic landmarks in hernia repair.

SURGICAL APPROACH—Cont'd

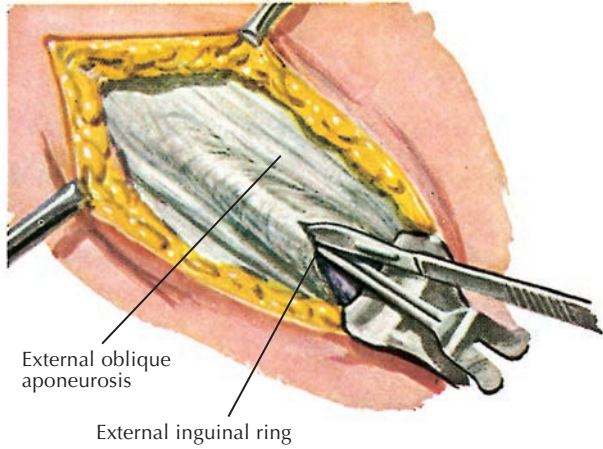
Dissection through the subcutaneous fat and Scarpa's fascia leads to the external oblique aponeurosis. Once encountered, the external oblique aponeurosis is completely exposed and the external inguinal ring is identified. The external oblique aponeurosis is incised sharply. The incision is extended along the fibers of the external oblique aponeurosis to the external inguinal ring, to expose the inguinal canal (Fig. 28-5, A).

At this time it is important to identify and isolate the iliohypogastric and ilioinguinal nerves to avoid injury. Failure to identify these nerves puts patients at greater risk of developing chronic pain through entrapment or transection. The iliohypogastric nerve is typically found lying on the internal oblique abdominal muscle after the edges of the external oblique aponeurosis are elevated. The ilioinguinal nerve runs along the spermatic cord through the internal inguinal ring and terminates at the skin of the upper and medial parts of the thigh (Fig. 28-5, B). Studies suggest a similar incidence of chronic pain whether the nerves are intentionally transected or preserved. Regardless of approach, identification of the nerves is critical to prevent inadvertent entrapment.

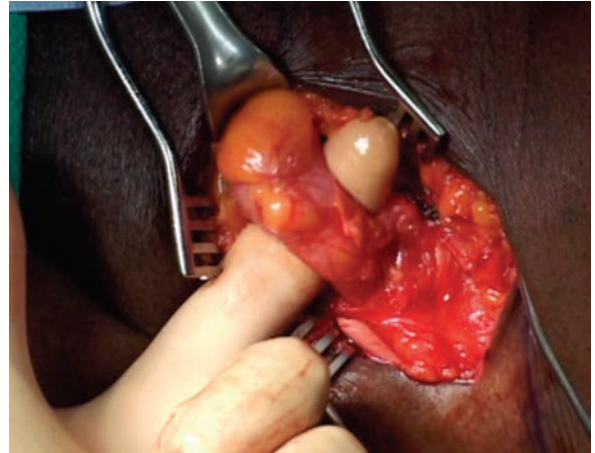
Through a combination of sharp and blunt dissection, the spermatic cord is mobilized at the pubic tubercle (Fig. 28-5, C). Staying close to the pubic tubercle avoids confusion of the tissue planes and disruption of the floor of the inguinal canal. Once mobilized, the spermatic cord is encircled with a Penrose drain to allow for easy retraction. Avoiding excessive traction is important to reduce testicular engorgement and early postoperative discomfort.

To facilitate identification of the hernia sac, the cremaster muscle is separated from the spermatic cord through blunt dissection. The hernia sac is usually found anterior and superior to the spermatic cord in an indirect hernia, whereas the sac protrudes directly through the floor of the inguinal canal in a direct hernia. During repair of an indirect hernia, the sac is cautiously separated from the spermatic cord down to the level of the internal inguinal ring. The hernia sac is examined for visceral contents. With a large hernia, the sac may be opened to ensure there are no contents before ligation and reduction. The hernia sac can be reduced into the preperitoneal space, or the neck of the sac is ligated at the internal inguinal ring and excess sac excised (Fig. 28-5, D). If present, a lipoma of the cord, with retroperitoneal fat herniating through the internal inguinal ring, should be ligated and excised before the surgeon begins repair of the inguinal canal.

A. Exposure of the external oblique aponeurosis



C. Spermatic cord mobilized at the pubic tubercle

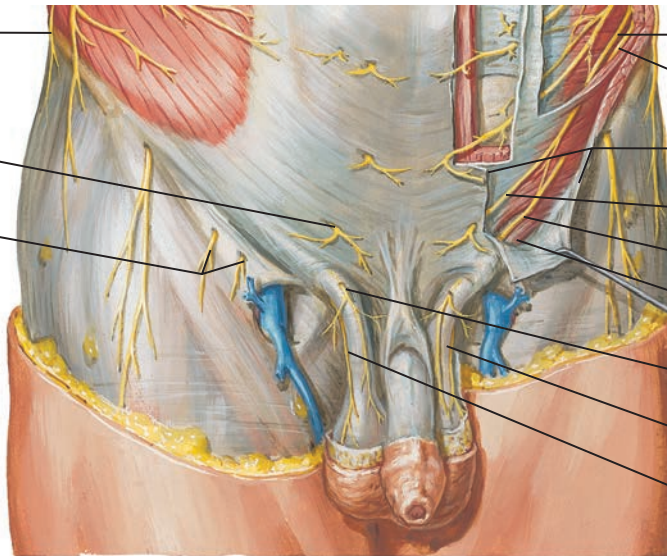


B. Inguinal nerves

Lateral cutaneous branch of iliohypogastric nerve (L1)

Anterior cutaneous branch of iliohypogastric nerve (L1)

Femoral branches of genitofemoral nerve (L1, 2)



Anterior branch of iliohypogastric nerve (L1)

Ilioinguinal nerve (L1)

External oblique aponeurosis (cut)

Anterior cutaneous branch of iliohypogastric nerve (L1)

Ilioinguinal nerve (L1)

Cremasteric muscle of spermatic cord

Anterior scrotal branch of ilioinguinal nerve (L1)

External spermatic fascia of spermatic cord

Genital branch of genitofemoral nerve (L1, 2)

D. Isolation and ligation of the hernia sac

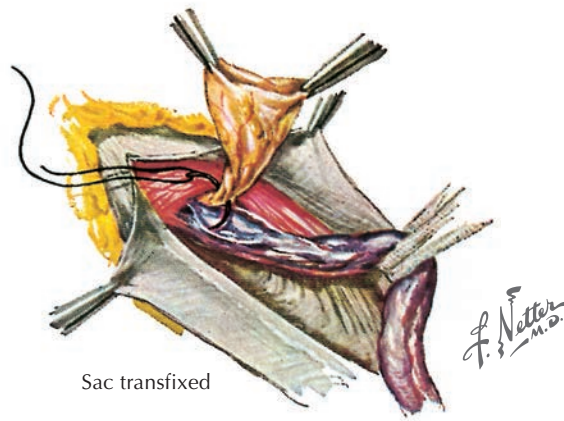
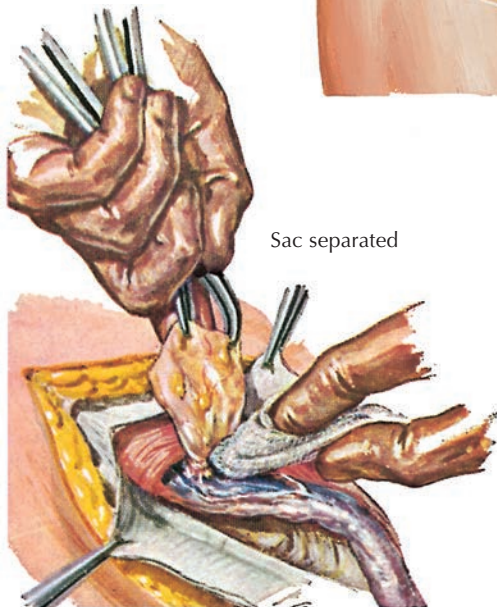


FIGURE 28-5 Exposed anatomy for hernia repair.

TENSION-FREE REPAIR

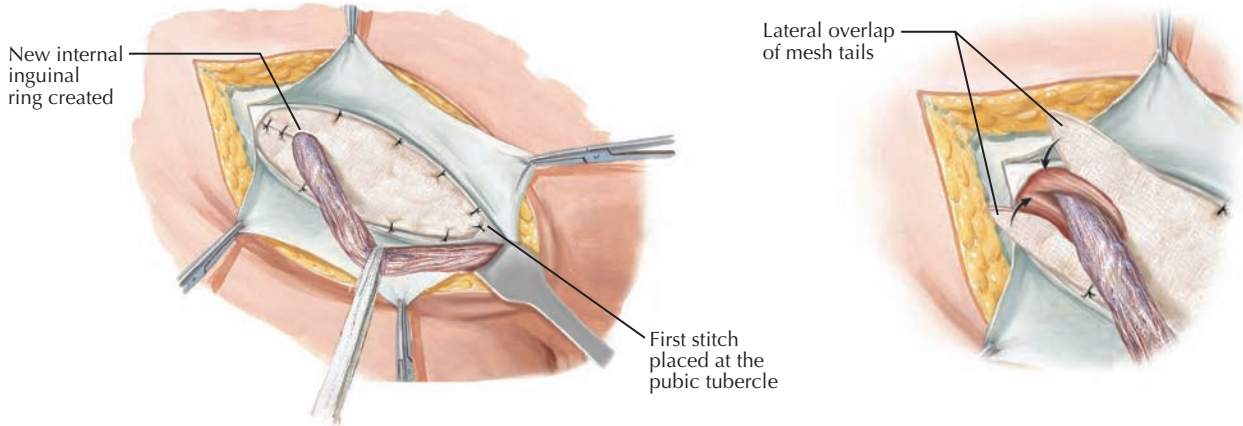
Guided by the principle that tension increases recurrence in hernia repair, placement of synthetic mesh to reinforce the floor of the inguinal canal and recreate the internal inguinal ring has become the primary method of anterior inguinal hernia repair. Using a nonabsorbable synthetic mesh, a slit is cut in the distal lateral edge to accommodate the spermatic cord. The mesh is first secured to the pubic tubercle with a nonabsorbable monofilament running suture (Fig. 28-6, A).

Three or four interrupted sutures are placed along the conjoined tendon or transversus abdominis muscle to the internal inguinal ring. Inferolaterally, the suture is run along the shelving edge of the inguinal ligament to a point lateral to the internal inguinal ring. The tails of the mesh are sutured together, creating a new internal inguinal ring through which the spermatic cord structures and ilioinguinal nerve are placed (Fig. 28-6, A).

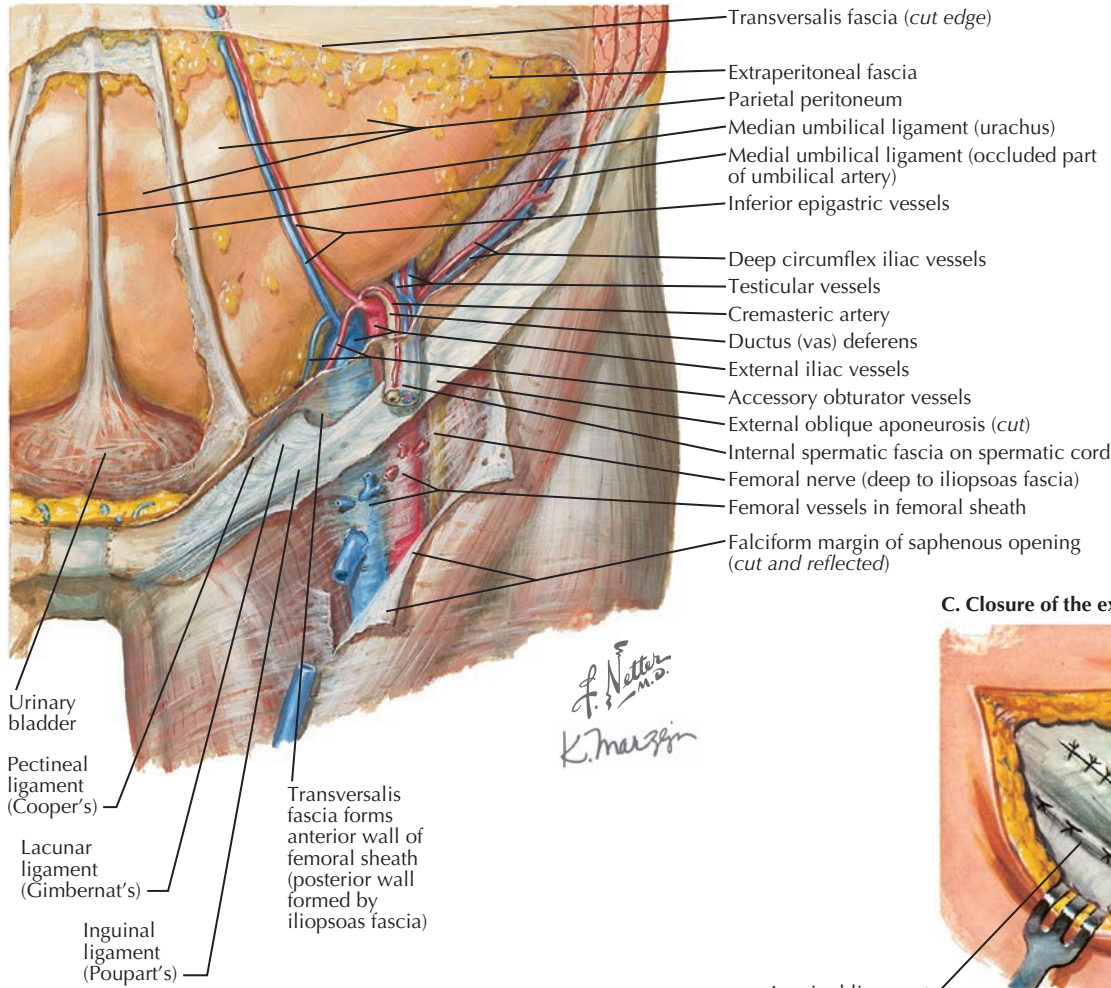
It is of critical importance when fixing the mesh in place at the inguinal ligament to respect the femoral vessels, which run directly below the inguinal ligament in the femoral sheath (Fig. 28-6, B).

After the mesh is secured, the external oblique aponeurosis is reapproximated with braided absorbable suture from lateral to medial. During closure of the external oblique aponeurosis, the external inguinal ring is recreated. Scarpa's fascia is reapproximated, and a continuous subcuticular stitch is used for skin closure (Fig. 28-6, C).

A. Mesh placement and recreation of the internal inguinal ring



B. Vascular anatomy of the groin



C. Closure of the external oblique aponeurosis

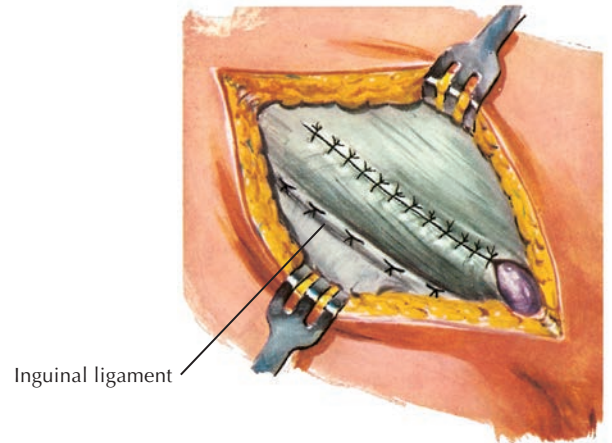


FIGURE 28-6 Tension-free hernia repair.

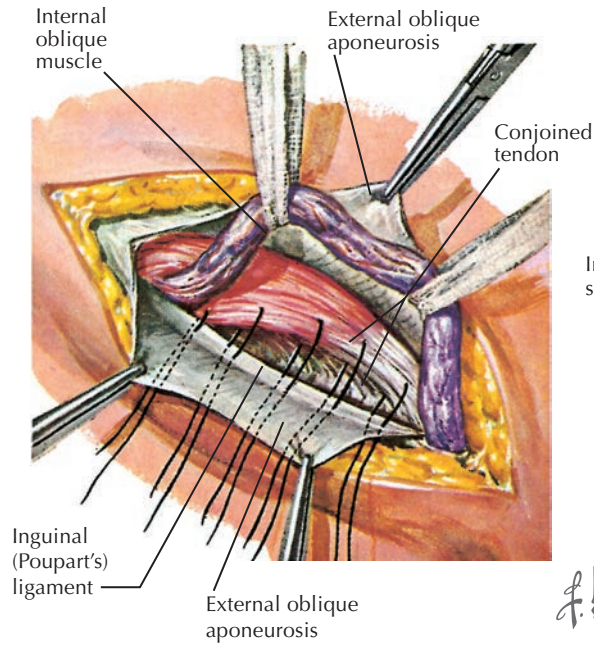
PRIMARY TISSUE REPAIR

Knowledge of primary tissue repair techniques will aid any surgeon who encounters an inguinal hernia in the setting of contamination, where mesh placement is contraindicated. Methods of primary tissue repair include the Bassini, McVay, and Shouldice repairs. The *Bassini repair* is performed by suturing the conjoined tendon (inguinal falx)—the distal ends of the transversus abdominis and internal oblique muscles—to the inguinal ligament (Fig. 28-7, A).

An alternative to suturing the musculoaponeurotic structures to the inguinal ligament is to suture them to Cooper's ligament. The *McVay repair*, or Cooper's ligament repair, uses a relaxing incision through the anterior rectus sheath to limit the tension on the suture line. To initiate this repair, interrupted nonabsorbable suture is used to approximate the transversus abdominis muscle to Cooper's ligament. This is continued down the pubic spine to the end of the ligament. A transition stitch is placed to approximate Cooper's ligament and the iliopubic tract. The McVay repair is completed by approximating the edge of transversus abdominis muscle to the iliopubic tract (Fig. 28-7, B).

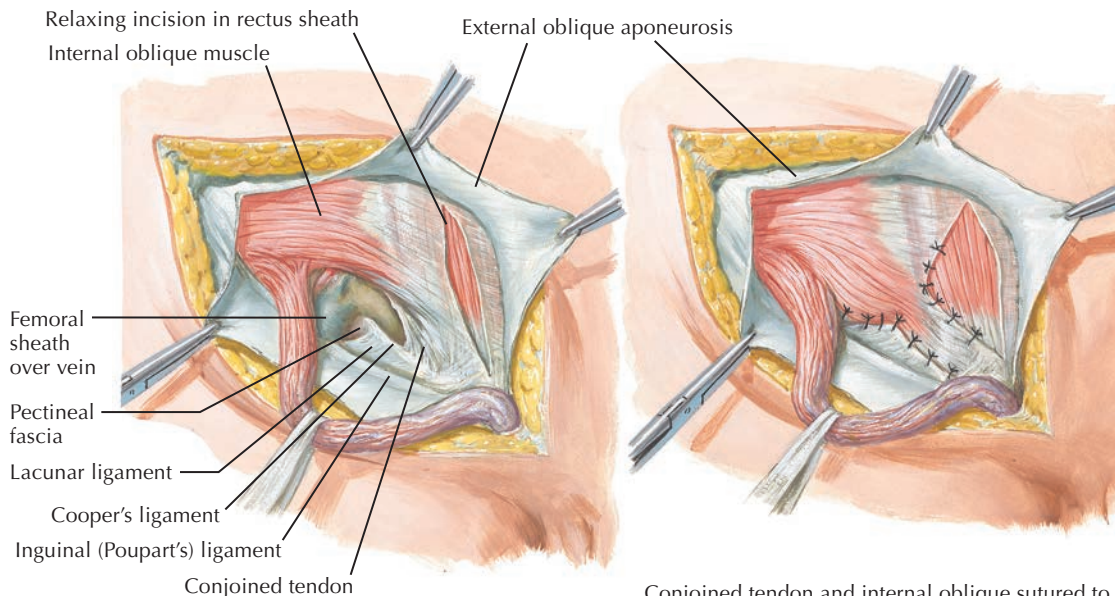
The *Shouldice repair* is a four-layer tissue repair that has the lowest recurrence rate of primary tissue repairs. The 1st layer involves securing the transversus abdominis aponeurosis to the iliopubic tract in continuous fashion from medial to lateral. For the 2nd layer, the same suture is then run from lateral to medial and approximates the transversalis fascia to the shelving edge of the inguinal ligament. The 3rd layer begins at the medial portion of the new internal inguinal ring, securing the conjoined tendon or internal oblique aponeurosis to the shelving edge of the inguinal ligament, and is taken to the pubic tubercle. The same suture is then run medial to lateral and again approximates the internal oblique muscle to the inguinal ligament as a more superficial 4th layer, ending at the internal inguinal ring.

A. Bassini repair



Internal oblique muscle and conjoined tendon sutured to inguinal ligament beneath cord

B. McVay repair



Exposure, attenuated fibers of posterior wall of inguinal canal (conjoined tendon and transversus abdominis trimmed away, Cooper's ligament cleaned)

Conjoined tendon and internal oblique sutured to Cooper's ligament, pectineal fascia, and anterior wall of femoral canal. Lateral margin of incision in rectus sheath sutured to rectus muscle and tendon

FIGURE 28-7 Bassini and McVay hernia repairs.

SUMMARY

A solid foundation of inguinal anatomy is essential to the successful performance of an inguinal hernia repair, regardless of the technique chosen. Defining an inguinal hernia as reducible, incarcerated, or strangulated aids acute decision making because strangulated hernias are surgical emergencies. Techniques include anterior and posterior approaches for fixing inguinal hernias. Although tension-free repair with mesh is the mainstay of anterior approaches for inguinal hernia repair, knowledge of primary tissue repairs gives surgeons the versatility needed for situations in which mesh is contraindicated.

SUGGESTED READINGS

- Fitzgibbons RJ Jr, Giobbie-Hurder A, Gibbs JO, et al. Watchful waiting vs repair of inguinal hernia in minimally symptomatic men: a randomized clinical trial. *JAMA* 2006;295:285-92.
- Neumayer L, Giobbie-Hurder A, Jonasson O, et al. Open mesh versus laparoscopic mesh repair of inguinal hernia. *N Engl J Med* 2004;350:1819-27.
- Sarosi GA, Wei Y, Gibbs JO, et al. A clinician's guide to patient selection for watchful waiting management of inguinal hernia. *Ann Surg* 2011;253:605-10.
- Woods B, Neumayer L. Open repair of inguinal hernia: an evidence-based review. *Surg Clin North Am* 2008;88:139-55, ix-x.

Laparoscopic Inguinal Hernia Repair

Heidi L. Elliott and Yuri W. Novitsky

INTRODUCTION

Inguinal hernias form because of a defect in the myopectineal orifice that allows intra-abdominal contents to protrude into the groin. Accounting for approximately 800,000 cases annually in the United States alone, inguinal hernia repair is one of the most common operations performed by general surgeons. Open anterior surgical repair with mesh prosthesis was the technique of choice until the early 1990s, when the introduction of laparoscopy revolutionized inguinal hernia repair. Benefits of the laparoscopic technique include lower incidence of chronic pain and faster return to work. The laparoscopic approach also affords significant advantages for patients with bilateral hernias, recurrent hernias previously repaired by an anterior approach, and femoral hernias. Regardless of the approach, an in-depth knowledge of groin anatomy is essential to achieve a durable repair.

LAPAROSCOPIC APPROACHES

The two most common laparoscopic hernia repair approaches are the transabdominal preperitoneal (TAPP) and the totally extraperitoneal (TEP). In the TAPP technique the abdominal cavity is entered and a transverse incision is made in the peritoneum, starting at the medial umbilical ligament and continuing out laterally just short of the anterior superior iliac spine (ASIS). The peritoneum is peeled down from the transversalis fascia to expose the entire myopectineal orifice and create a “pocket.” Mesh is then placed into this pocket in the preperitoneal position and secured with tacks and/or glue. The peritoneum is then reclosed with suture or tacks, thus excluding the mesh from the intraabdominal contents to prevent bowel adhesions and minimize the risk of intestines being “trapped” in the preperitoneal space.

The TEP approach differs by avoiding entry into the abdominal cavity. Instead, balloon dissection creates a pocket for the mesh between the rectus abdominis muscle and the transversalis fascia.

No significant difference has been found between TAPP and TEP with regard to length of surgery, return to normal activity, or rate of recurrence. Some studies suggest a higher incidence of port-site hernias and visceral injuries with TAPP, whereas more conversions may occur with TEP. Ultimately, surgeons should choose the technique they are most comfortable with to obtain the best outcomes.

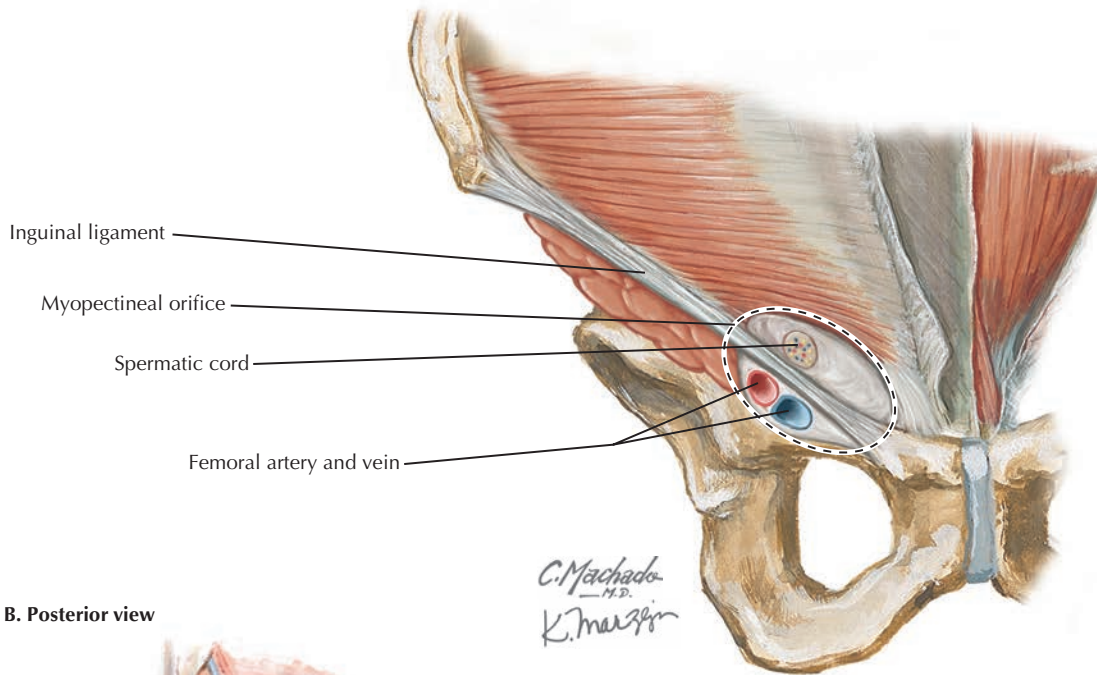
Regardless of the approach taken, the goal of laparoscopic herniorrhaphy remains a durable repair. In contrast to the open repair, the failures of the laparoscopic repair occur at the inferior border as the viscera “sneaks in” underneath the inferior edge of the mesh. As a result, sufficient dissection of the pocket along the inferior border is paramount to reduce recurrence. In addition, the authors often use fibrin glue to fixate the inferior edge of the mesh.

KEY ANATOMIC CONCEPTS FOR LAPAROSCOPIC REPAIR

Myopectineal Orifice

The myopectineal orifice is one of the most important anatomic features of the groin anatomy (Fig. 29-1, *dashed ovals*). All hernias of the groin originate from this single zone of weakness, which is covered only by transversalis fascia and peritoneum. Bisected by the inguinal ligament, the myopectineal orifice comprises the inguinal canal superiorly and the femoral canal inferiorly. The inferior border consists of the superior pubic ramus and the pectineal (Cooper's) ligament. Medially, the myopectineal orifice is bordered by the rectus abdominis muscle and the inguinal falx (conjoined tendon). The conjoined (conjoint) tendon (fusion of internal oblique muscle and transversalis fascia) is also the superior border of the orifice. Laterally, the boundaries consist of the iliopsoas muscle and lateral border of the femoral sheath.

A. Anterior view



B. Posterior view

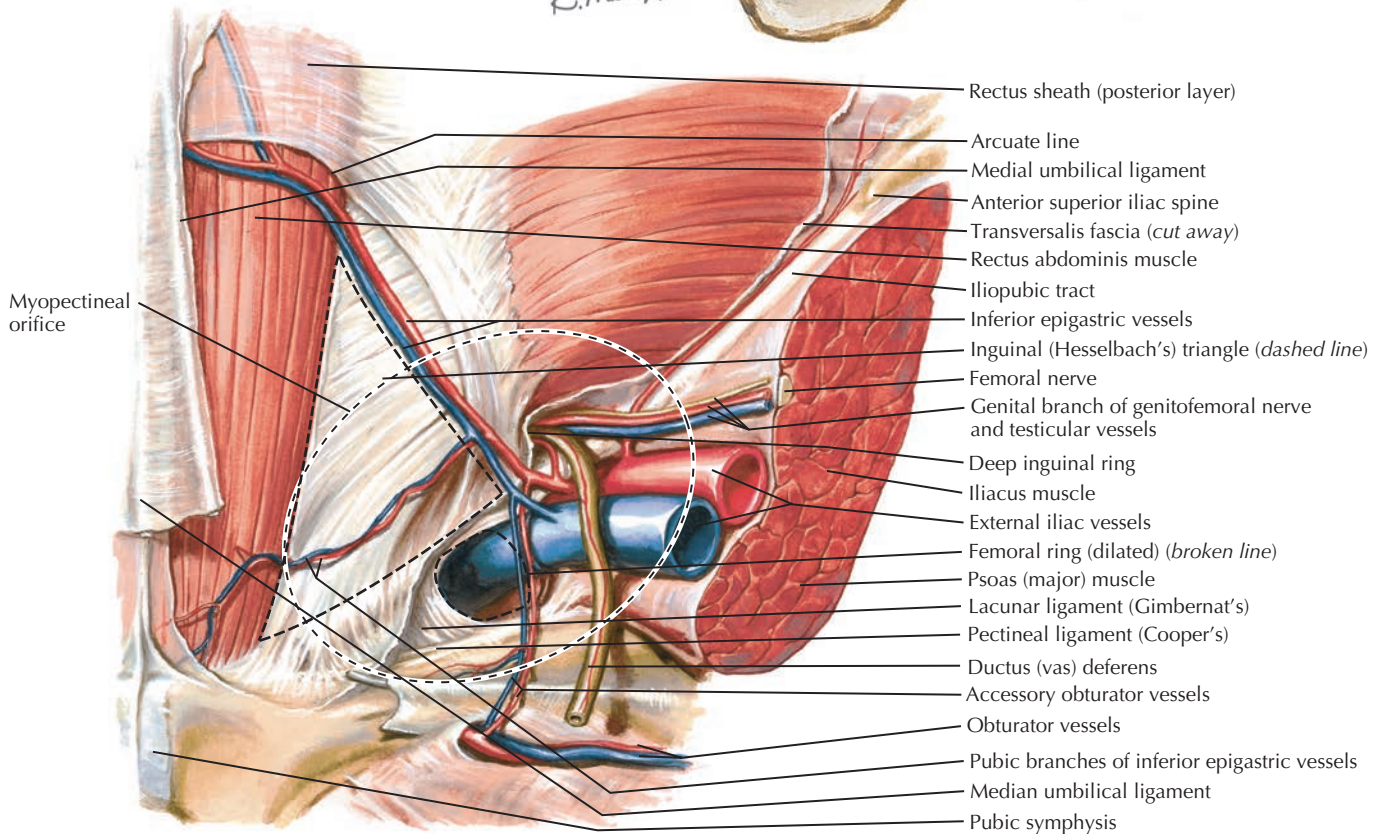


FIGURE 29-1 Anterior and posterior views of myopectineal orifice.

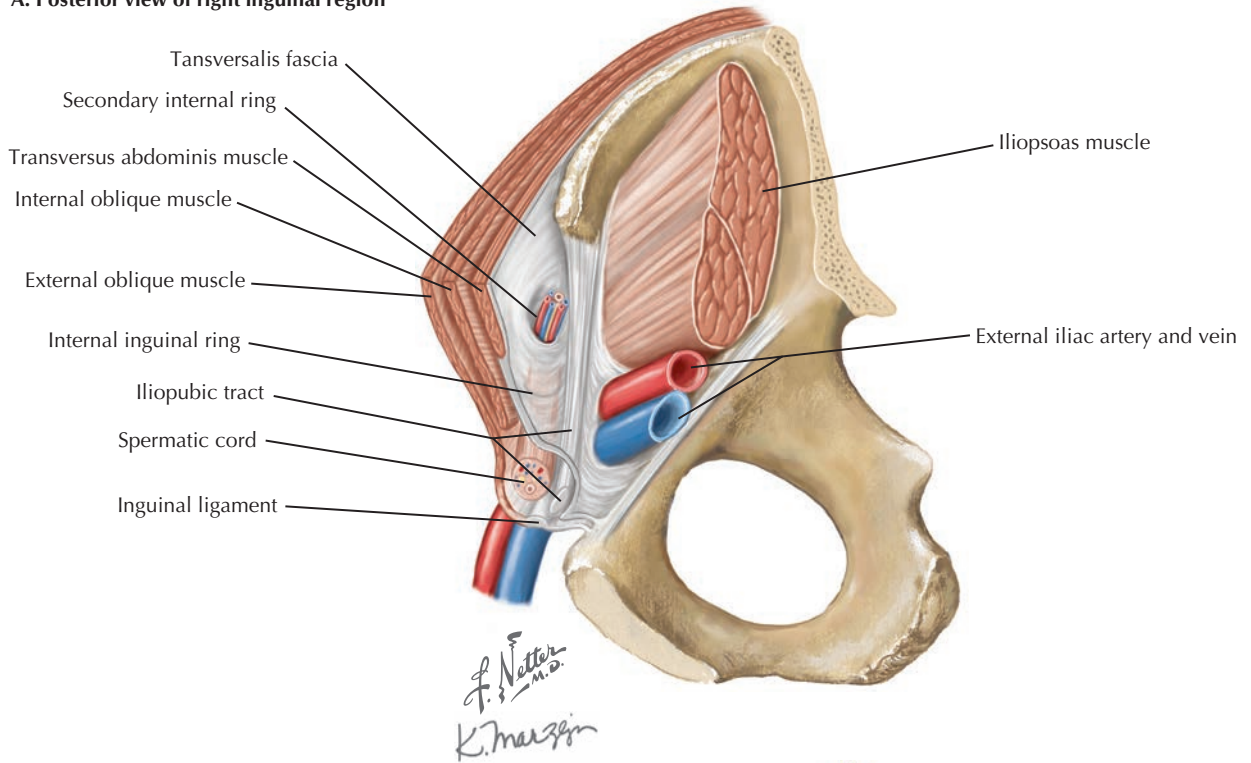
Inguinal Ligament versus Iliopubic Tract

Although a key anatomic landmark for open (anterior) inguinal hernia repair, the inguinal ligament is not seen in the laparoscopic (posterior) repair because it is an *anterior* lamina structure (Fig. 29-2, A). The inguinal (Poupart's) ligament is the inferior edge of the external oblique aponeurosis, extending from the ASIS to the pubic tubercle, turning posteriorly to form the "shelving edge." This shelving edge is used to secure the inferior border of the mesh in an open inguinal hernia repair (see Chapter 28). The iliopubic tract is the continuation of the transversus abdominis aponeurosis and fascia. It is located posterior to the inguinal ligament, extends from the pubic tubercle medially, and passes over the femoral vessels to insert on the ASIS laterally. This *posterior* lamina structure is an important landmark in laparoscopic inguinal hernia repair; lateral to the internal ring, no tacks should be placed below the iliopubic track because of the risk of injury to the lateral femoral cutaneous, genitofemoral, and femoral nerves.

Pectineal Ligament

The pectineal (Cooper's) ligament refers to the periosteum found along the superior ramus of the pubic bone, posterior to the iliopubic tract (Fig. 29-2, B). The pectineal ligament is an extension of the lacunar (Gimbernat's) ligament, which connects the inguinal ligament to Cooper's ligament near their insertion site at the pubic tubercle. Cooper's ligament is frequently used for medial fixation of the mesh in a laparoscopic hernia repair.

A. Posterior view of right inguinal region



B. Anterior view of left inguinal region

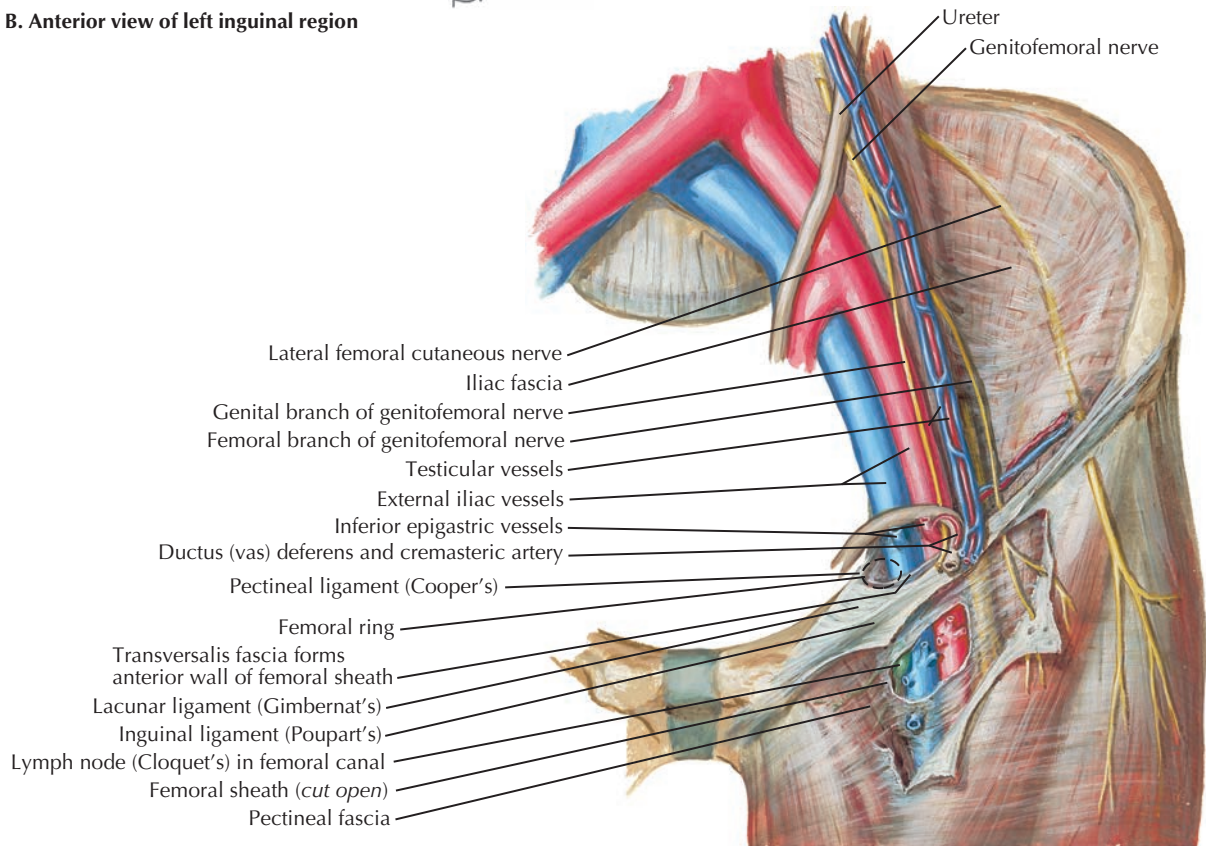


FIGURE 29-2 Posterior and anterior views of inguinal region.

Inguinal Geometry

Hesselbach's (inguinal) *triangle* is formed by the lateral border of the rectus sheath, inferior epigastric vessels, and inguinal ligament (see Fig. 29-1, B). Direct hernias occur through this space, medial to the inferior epigastric arteries. Indirect hernias are found lateral to Hesselbach's triangle and the lateral umbilical ligaments, which contain the epigastric arteries.

The "triangle of doom" contains the external iliac artery and vein (Fig. 29-3, A). It is formed medially by the vas deferens, laterally by the gonadal vessels, and inferiorly by the peritoneal edge. No tacks should be placed in this triangle to avoid injury to the iliac vessels.

The "triangle of pain" is defined by the gonadal vessels medially, iliopubic tract laterally, and peritoneal edge inferiorly (Fig. 29-3, A). It contains the lateral femoral cutaneous nerve, femoral branch of the genitofemoral nerve, and the femoral nerve. Tacks in this area risk nerve entrapment, causing pain on the anterolateral aspect of the thigh.

The "circle of death," also known as *corona mortis*, is a vascular ring formed by the anastomosis of an aberrant artery from the external iliac artery with the obturator artery, branching from the internal iliac artery (Fig. 29-3, B). Tacks should be avoided here because profuse bleeding can occur if the ring is injured.

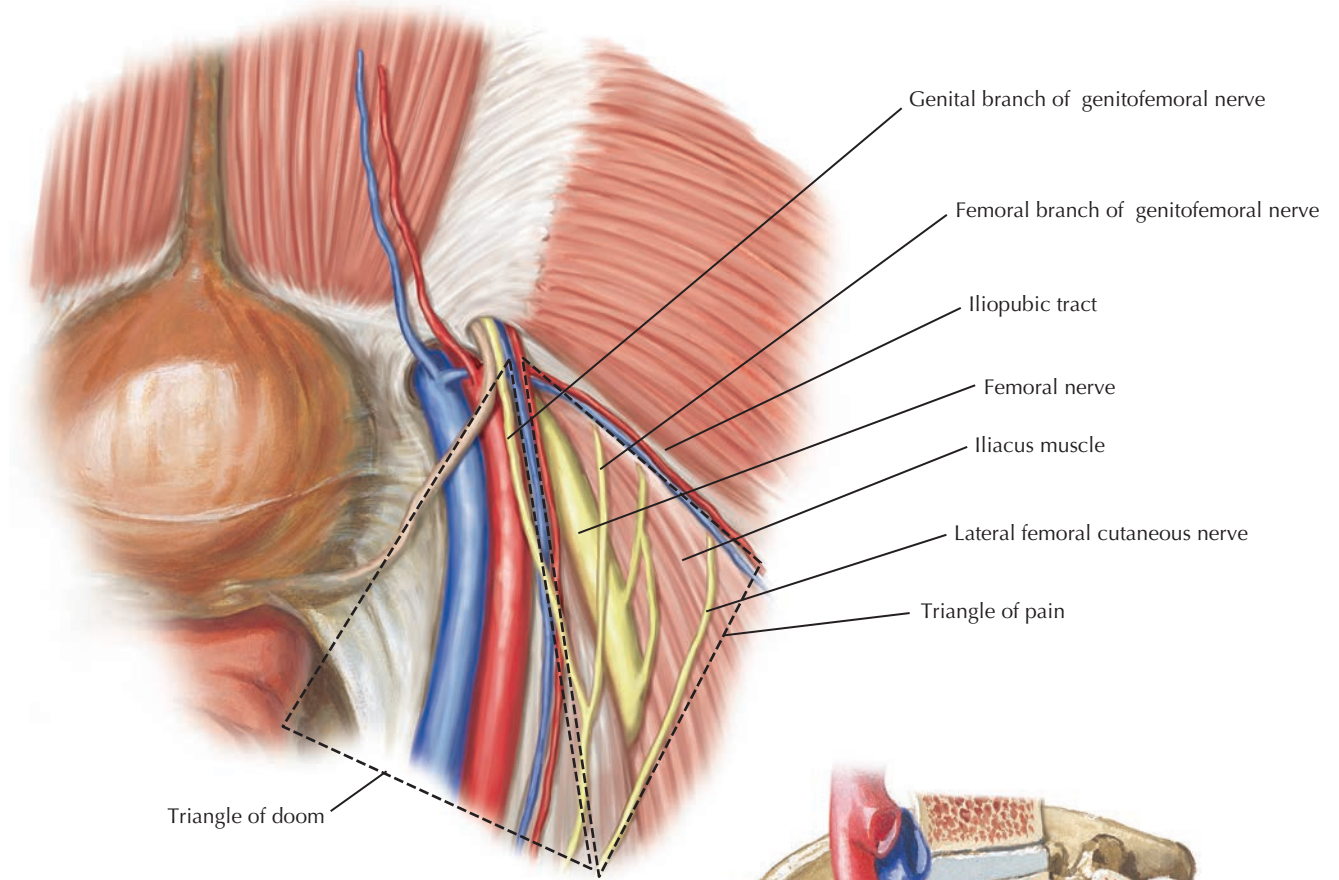
PRINCIPLES OF LAPAROSCOPIC REPAIR

General anesthesia is preferred in most TEP cases and is required for the TAPP approach. Patients are asked to void immediately before surgery, obviating the need for catheterization and helping prevent bladder injuries. Identification of the anatomic landmarks of Cooper's ligament medially, psoas muscle inferiorly, as well as the peritoneal sac, gonadal vessels, round ligament or vas deferens, iliac vessels, and the iliopubic tract, is key to operative safety and efficacy. Separation of the hernia sac from the cord structures before reduction of the sac helps avoid injury to the gonadal vessels and vas deferens.

Complete reduction of the hernia sac is critical to preventing recurrent hernias, as is dissection of a wide pocket for placement of the mesh and ample coverage of the direct, indirect, and femoral spaces. Minimal use of tacks, including avoidance of tacks below the iliopubic tract, is mandatory to avoid complications of chronic pain caused by nerve injury.

Importantly, a number of anatomic structures seen during the open anterior inguinal hernia approach are not visualized in the laparoscopic approach, including the inguinal and lacunar ligaments and the ilioinguinal and iliohypogastric nerves. Also, the spermatic cord, consisting of the cremasteric fibers from the internal oblique muscle, cremasteric vessels, testicular vessels, genital branch of genitofemoral nerve, vas deferens, and lymphatics, only becomes an entity within the inguinal canal, which is not seen in the laparoscopic view. The gonadal vessels, vas deferens, and genital branch of the genitofemoral nerve are seen entering the internal ring, at the entrance to the inguinal canal.

A. Triangle of doom and pain



B. Circle of death

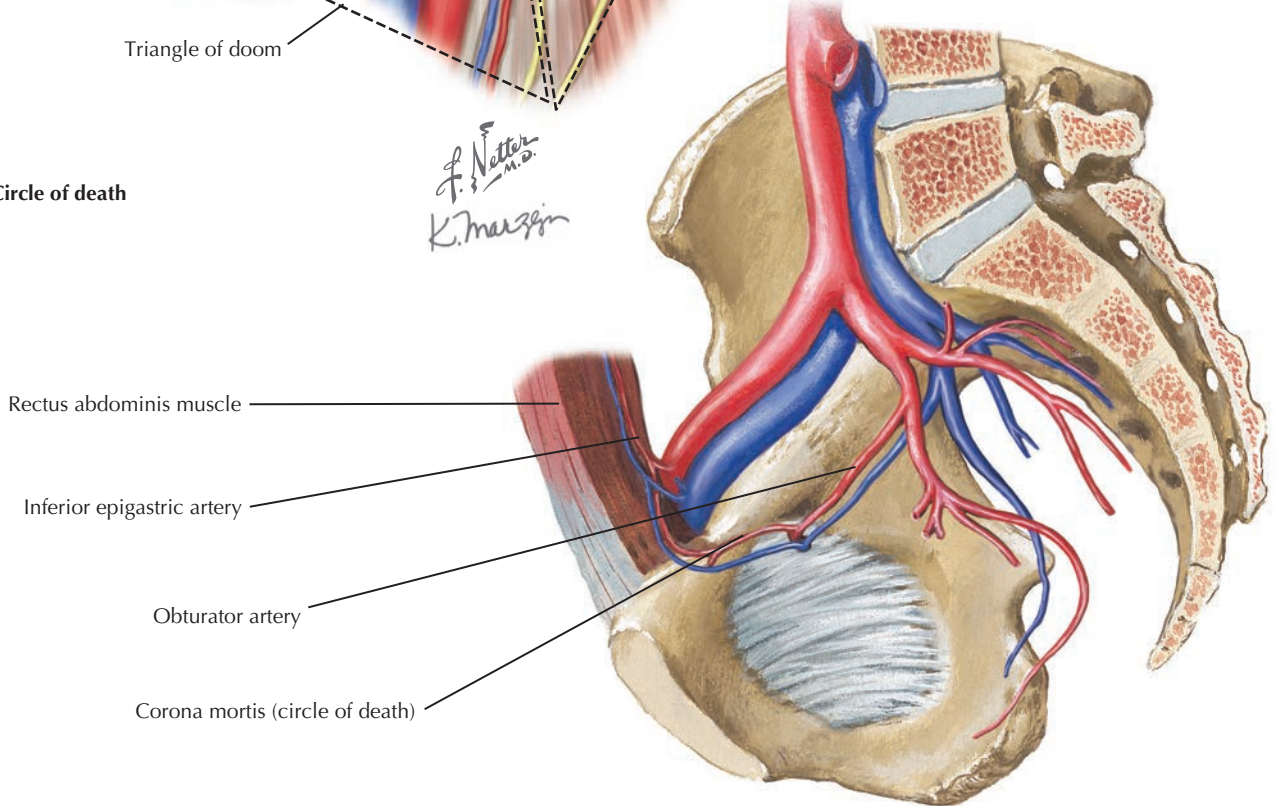


FIGURE 29-3 Inguinal landmarks in hernia repair: warning triangles and corona mortis.

TRANSABDOMINAL PREPERITONEAL APPROACH

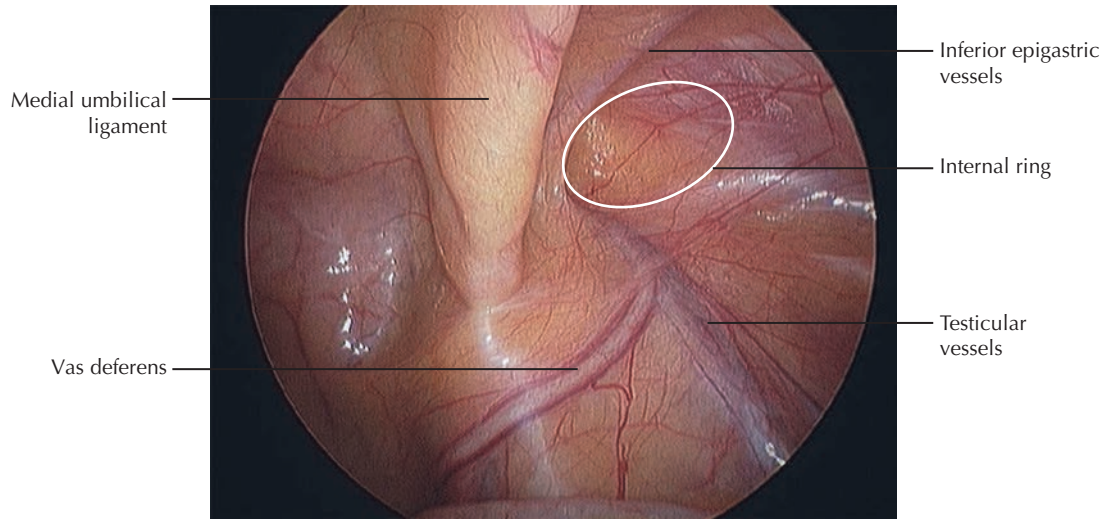
The patient is positioned supine, with both arms tucked at the sides. Port placement for the TAPP approach typically begins by placing a 12-mm port at the umbilicus. Once pneumoperitoneum is established to 15 mm Hg, an angled laparoscope is introduced into the abdomen. Two additional, 5-mm ports are then placed, one at the lateral border of each rectus muscle, taking care to avoid injury to the inferior epigastric artery.

Next, both inguinal areas are inspected for hernias. Identification of the following landmarks are critical to begin dissection: medial umbilical ligament (containing obliterated umbilical artery), testicular vessels, inferior epigastric vessels (lateral umbilical ligament), and external iliac vessels (Fig. 29-4, A).

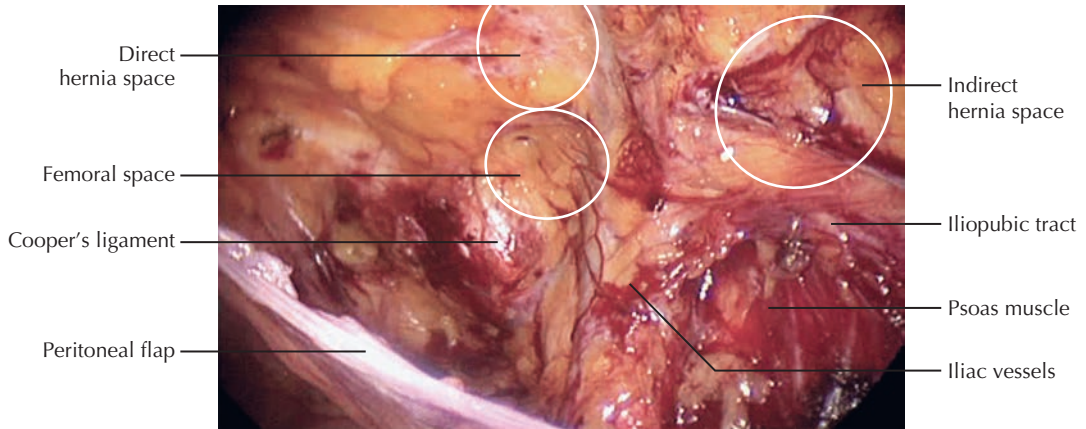
To begin the incision, the laparoscopic scissors are used to make a transverse incision in the peritoneum, starting at the medial umbilical ligament and continuing laterally along the anterior abdominal wall, ending just short of the ASIS. This incision line essentially parallels the arcuate line of Douglas. The peritoneum is then grasped along its edge and dissected away from the transversalis fascia, which remains on the anterior abdominal wall. When creating this peritoneal flap, great care must be taken to avoid injury to the epigastric vessels and to sweep all layers toward the anterior abdominal wall, except the thin peritoneal layer. This pocket is dissected out medially to expose the pubic symphysis and Cooper's ligament, a white glistening structure along the superior pubic ramus (Fig. 29-4, B). Lateral exposure continues 3 to 5 cm lateral to the opening of the internal inguinal ring and inferiorly until the edge of the psoas muscle is visible.

Dissection of the hernia sac, if present, is performed by placing inward traction on the peritoneum and carefully separating the sac from the cord structures. As the hernia sac is "reduced," the spermatic cord (running posterolaterally to sac) is identified and protected. If a direct hernia is present, the sac must be separated from the transversalis fascia within Hesselbach's triangle. It is important to separate the cord structures from the sac before reducing the sac, to avoid inadvertent injury to the vessels or vas deferens. Laterally, the gonadal vessels are also identified and dissected away from the lateral edge of the sac.

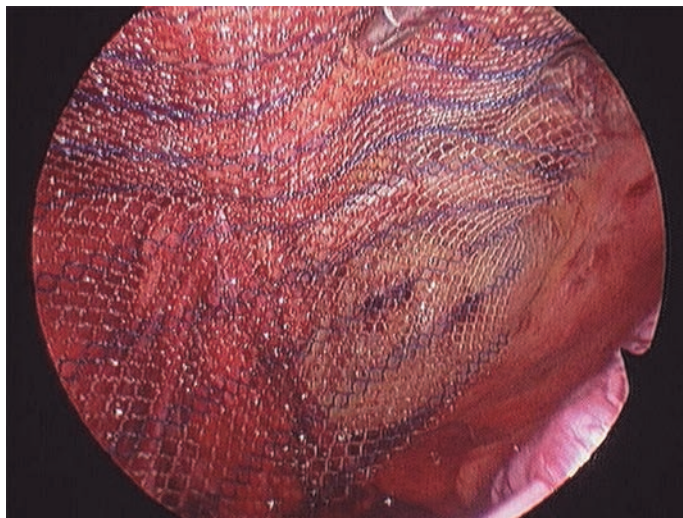
Once the peritoneal sac is completely reduced and the pocket enlarged to expose the entire myopectineal orifice, the pocket is ready for placement of the mesh. The surgeon must inspect the peritoneum for any defects made during dissection that could allow exposure of the mesh to the abdominal cavity. All defects must be repaired, or mesh with a barrier coating should be selected. The mesh is then introduced into the abdominal cavity through the umbilical port, then placed in the peritoneal pocket and unrolled to cover the entire myopectineal orifice with significant overlap. Essentially, the mesh is then positioned to cover the direct, indirect, and femoral openings. The authors typically use mesh that is 14 cm in medial-to-lateral dimension by 11 to 12 cm in craniocaudal direction (Fig. 29-4, C).



A. Laparoscopic view of right groin



B. Medial aspect of TAPP dissection



C. Mesh coverage prior to reperitonealizing

FIGURE 29-4 Laparoscopic dissection: transabdominal preperitoneal (TAPP) approach to inguinal hernia.

TOTALLY EXTRAPERITONEAL APPROACH—Cont'd

The authors use an endoscopic tacker to fixate the mesh medially to Cooper's ligament, anteromedially to the rectus abdominis muscle, and anterolaterally to the area above the internal ring. If tacks are used lateral to the internal inguinal ring, all tacks *must* be placed above the iliopubic tract, to avoid the triangle of pain and triangle of doom (see Fig. 29-3, A). The surgeon ensures this placement by manually palpating the tip of the tacker from the outside the abdominal cavity, above the inguinal ligament. If desired, fibrin glue is an excellent adjunct for mesh fixation inferiorly.

The peritoneal flap is then reapproximated over the mesh with the endoscopic tacker. Great care must be taken to avoid placing tacks into the epigastric vessels. No large gaps may be left in the closure, which would expose the mesh to the bowel and potentially allow for bowel to herniate inside the peritoneal flap. At the conclusion of the procedure, the surgeon should check to ensure both testicles are in their normal anatomic position within the scrotum.

TOTALLY EXTRAPERITONEAL APPROACH

The patient is positioned supine with both arms tucked at the sides and a single laparoscopic tower at the foot of the bed. Port placement differs from TAPP technique in that all ports for a TEP approach are placed vertically in the midline. To begin, a 10-mm infraumbilical incision (port) is made, and the anterior rectus sheath on the side of the hernia defect is opened longitudinally. The rectus abdominis muscle fibers are retracted laterally to expose the posterior rectus sheath. Finger dissection is performed to free the muscle fibers from their posterior attachments, to accommodate the dissection balloon. The key here is to avoid entering the peritoneal cavity, since the dissection plane is in the preperitoneal space. The dissecting-balloon trocar is slid into the space between the rectus muscles anteriorly and the transversalis fascia and peritoneum posteriorly until the tip reaches the pubic symphysis (Fig. 29-5). Great care must be taken in this step not to injure the epigastric vessels. Insufflation is done under direct laparoscopic visualization until an adequate space is developed. The dissecting balloon is deflated and replaced with a blunt-tipped trocar.

After placement of two additional, 5-mm ports in the lower midline, dissection is carried out similar to a TAPP repair. The landmarks of the pubic tubercle, Cooper's ligament, and inferior epigastric vessels aid in orienting the dissection. Often a direct hernia, if present, will reduce spontaneously with pneumopreperitoneum. Otherwise, clearing off the Cooper's ligament until the iliac vessels are reached, ensures exposure of the direct and femoral space.

Unlike TAPP technique, the indirect space must always be dissected out because a hernia here may not be readily apparent in a TEP approach. The peritoneum must be gently dissected from the anterior abdominal wall, from the level of the ASIS to below the iliopubic tract. If the peritoneal cavity is violated during dissection, insufflations of the abdomen may obscure the working space.

When all hernia sacs have been reduced, the mesh is ready for implantation, as in a TAPP approach. The choice of whether or not to use tacks depends on surgeon preference. Most will recommend one or two tacks in Cooper's ligament if a direct hernia component is present. Once positioned, the insufflation is released as graspers hold the lower edge of the mesh in place. All trocars are removed, and the anterior rectus fascia at the 10-mm port site is closed.

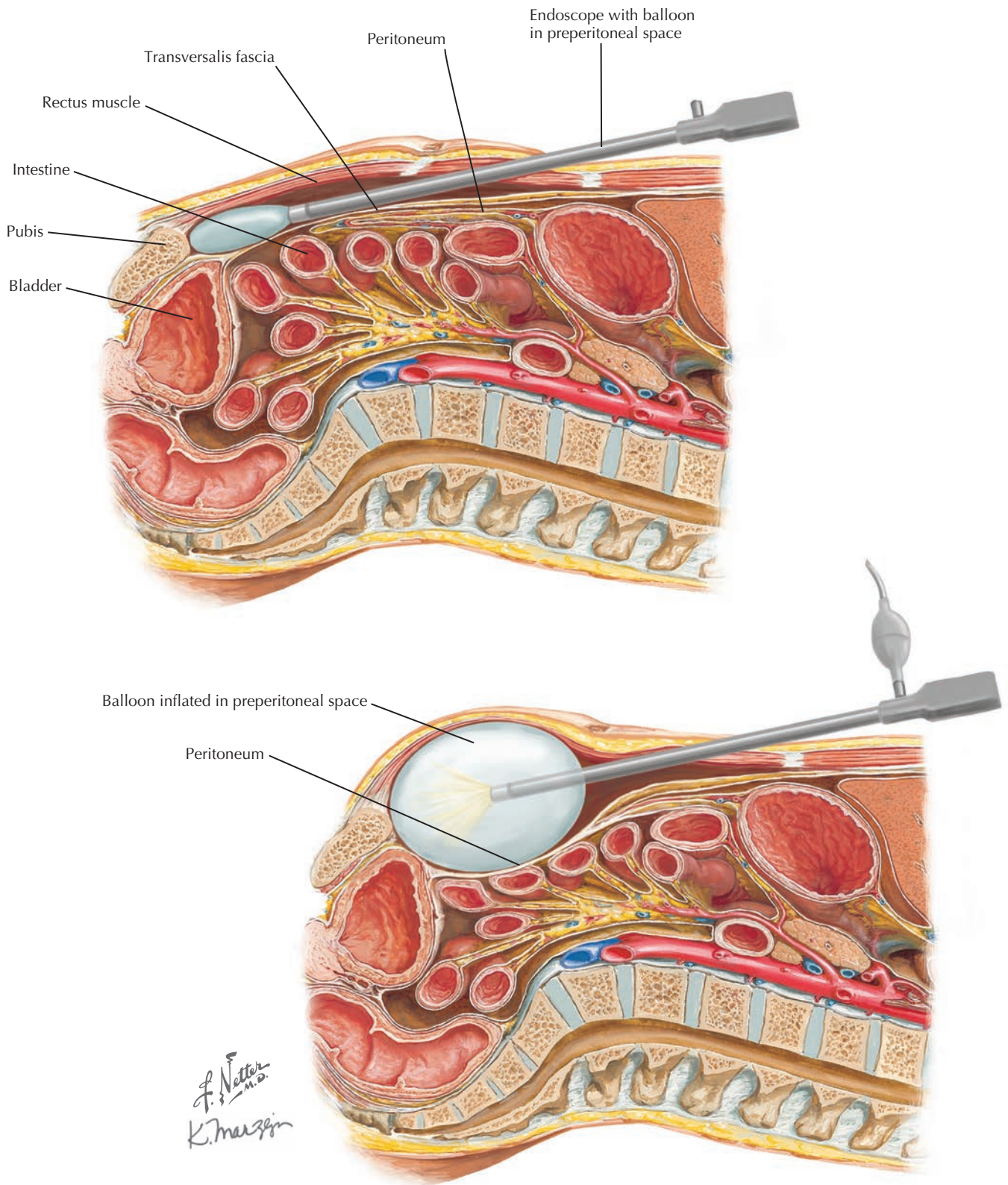


FIGURE 29-5 Laparoscopic balloon dissection: totally extraperitoneal (TEP) approach to inguinal hernia.

SUGGESTED READINGS

Cameron J. Hernia. In *Current surgical therapy*, 8th ed. Philadelphia: Elsevier; 2004, pp 545-52.

Scott-Conner CEH. *Operative anatomy*, 2nd ed. Philadelphia: Lippincott, Williams & Wilkins; 2003, pp 593-604.

Femoral Hernia Repair

Jeffrey A. Blatnik and Michael J. Rosen

INTRODUCTION

A femoral hernia is a type of groin hernia in which the hernia sac is located *below* the inguinal ligament. It can often be difficult to differentiate between femoral and inguinal hernias clinically, and thus the surgeon sometimes cannot distinguish between them preoperatively. Femoral hernias are much more common in women than in men (4:1) but are still less common than other types of inguinal hernias; they constitute only one third of all groin hernias in women and about 2% in men. Compared with inguinal hernias, femoral hernias are much more likely to become incarcerated or strangulated because of its anatomic location and rigid boundaries. For this reason, elective repair of femoral hernias is highly recommended to avoid the complications associated with incarceration or strangulation.

ANATOMY

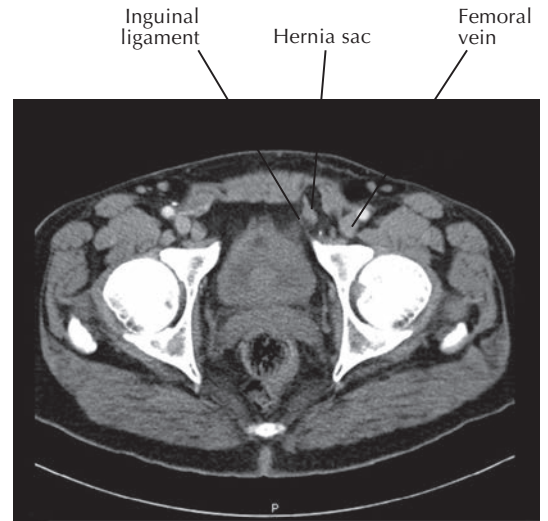
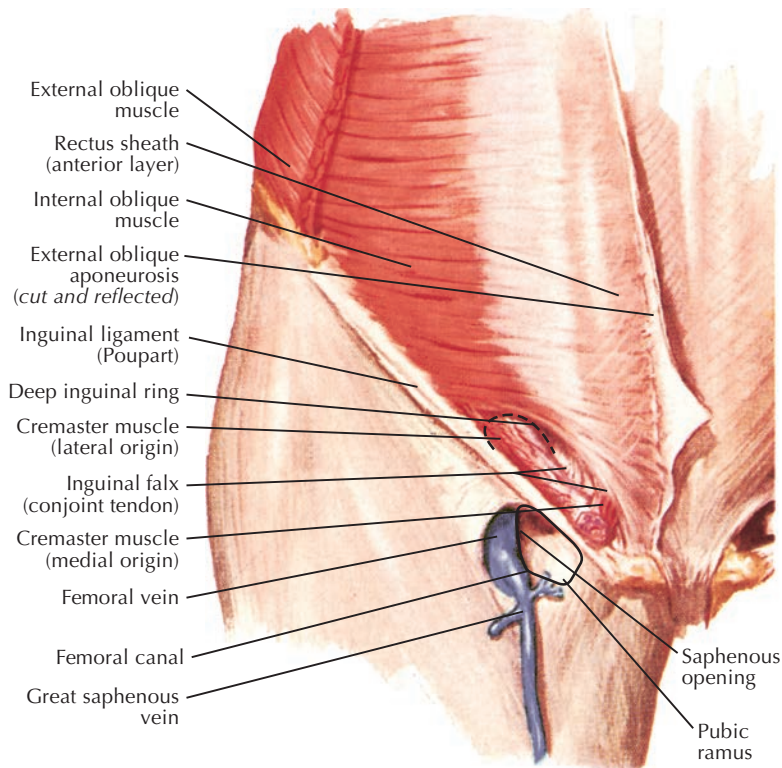
By definition, the femoral hernia protrudes through the femoral canal, bordered by the inguinal ligament superiorly, the femoral vein laterally, and the pubic ramus inferomedially (Fig. 30-1, *A*). This space is tight and cannot expand, which leads to the high risk of incarceration and strangulation.

CLINICAL PRESENTATION

The femoral hernia often is seen as an asymptomatic bulge inferior to the inguinal ligament, and as it enlarges, the sac can extend onto the thigh (Fig. 30-1, *B*). The hernia may or may not be reducible, and patients often report a sensation of fullness. Patients who have incarceration or strangulation often report significant pain, and they may also have evidence of a small bowel obstruction.

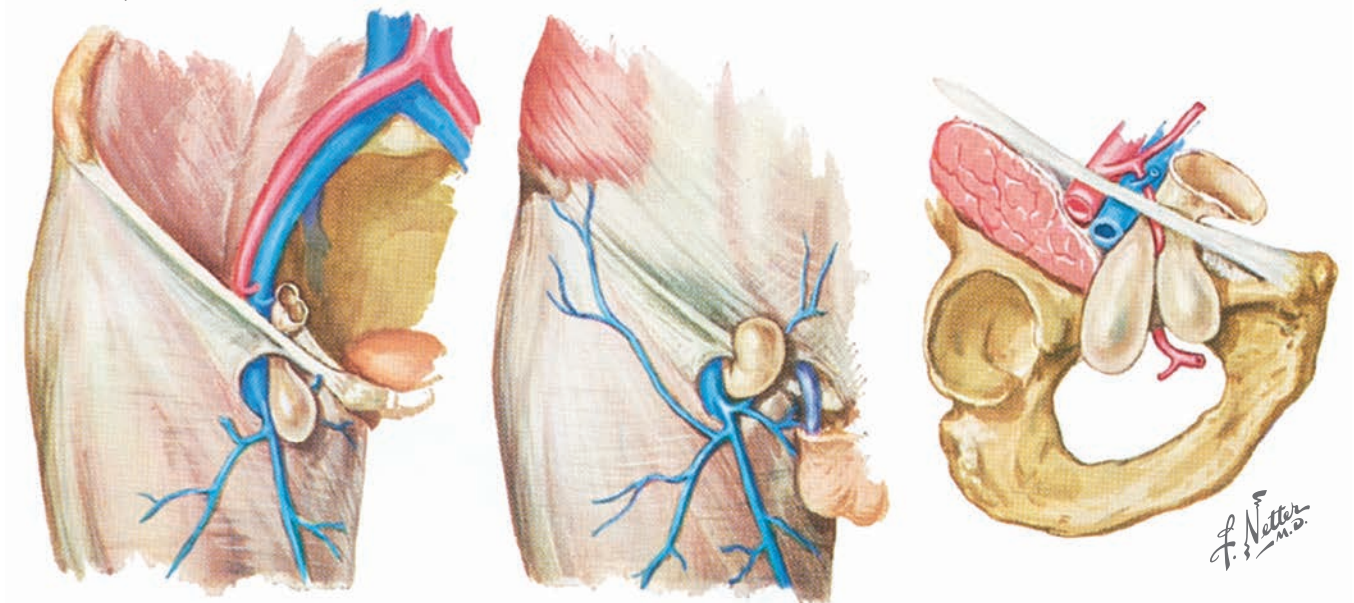
IMAGING

Additional imaging is not required but can provide useful information, especially when the diagnosis is unclear. Ultrasound or computed tomography (CT) scans can help differentiate between a femoral hernia, inguinal hernia, and inguinal lymphadenopathy (Fig. 30-1, *C*).



A. Femoral hernia protrudes through the medial femoral canal which is bordered by the inguinal ligament superiorly, the femoral vein laterally, and the pubic ramus medially.

C. CT scan showing a femoral hernia. In this cut the femoral vein and inguinal ligament which serve as boundaries for the femoral canal can be seen.



Course of hernial sac through femoral ring, femoral canal, and fossa ovalis

Sac turned upward over inguinal ligament along superficial epigastric vein

Bilocular sac resulting from aberrant obturator artery

B. Demonstrates different courses that the hernia sac can take after it protrudes through the femoral canal. If the sac is turned upwards as in the second picture, this can mimic an inguinal hernia on physical exam.

FIGURE 30-1 Anatomy of femoral hernia.

OPEN SURGICAL REPAIR

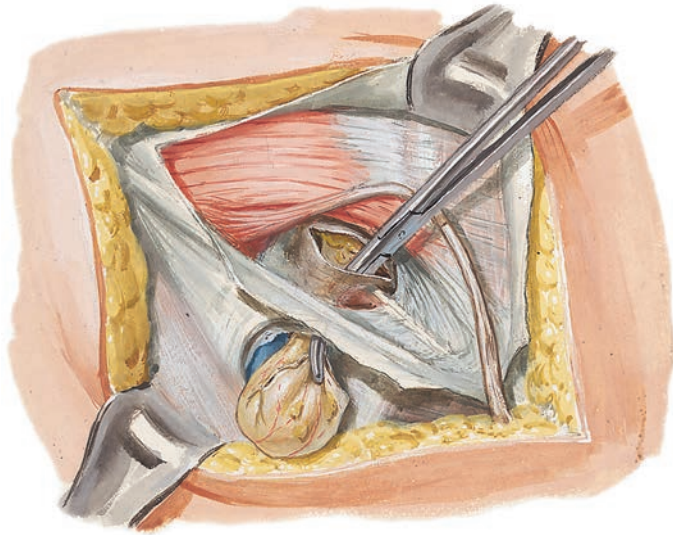
If a patient has signs of incarceration or strangulation, urgent repair is warranted. If the diagnosis of a femoral hernia is confirmed preoperatively, the incision can be placed below the inguinal ligament on the upper thigh. If the etiology of the hernia is uncertain, a standard inguinal hernia incision can be made, with plans to divide the transversalis fascia to expose the femoral space. The dissection can be completed from above the inguinal ligament or below (Fig. 30-2).

If the hernia sac cannot be reduced, the lacunar (Gimbernat's) ligament can be divided. In rare circumstances in which the contents still cannot be reduced, the inguinal ligament can be transected. The hernia sac can be reduced through the femoral defect to transition it into an inguinal defect. If the hernia sac is opened during reduction of the hernia contents, it can be ligated at this time.

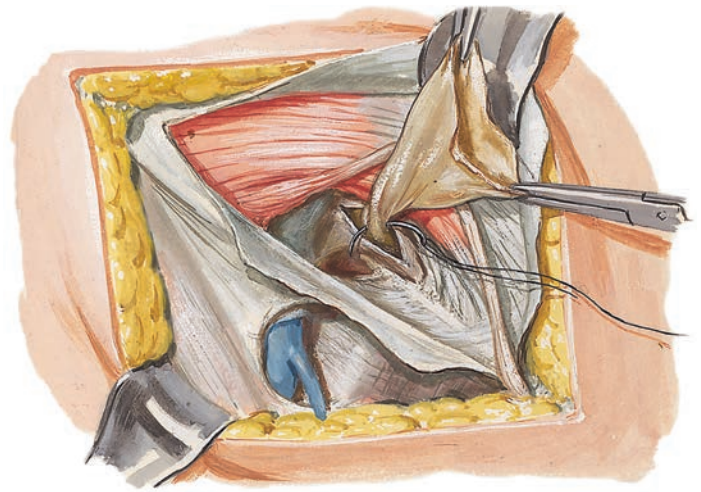
The defect can be repaired by a number of methods. The simplest repair involves suturing the inguinal ligament anteriorly to Cooper's (pectineal) ligament posteriorly, with a permanent monofilament suture to close the defect. Care should be taken to avoid injuring or narrowing the femoral vein because it is the lateral border of the repair.

As an alternative, the transversalis fascia can be affixed to Cooper's ligament medially and the iliopubic tract laterally.

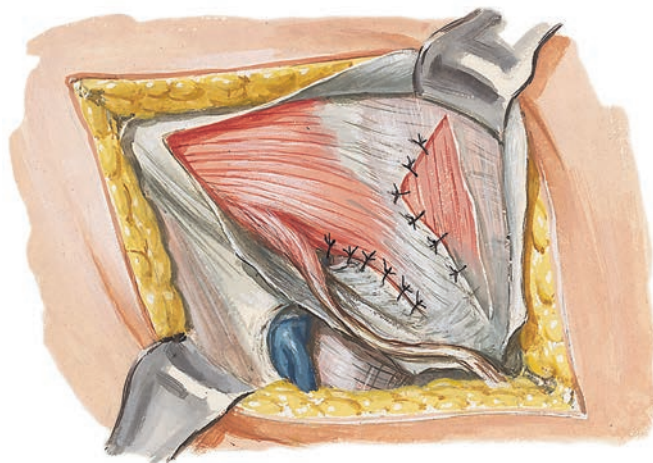
Another method of open repair involves the use of mesh reinforcement. Recent studies comparing open mesh repairs with open nonmesh repairs showed a similar rate of postoperative complications. However, fewer hernia recurrences were reported in patients who underwent mesh repair.



Demonstrates the exposure when the repair is performed from above the inguinal ligament.



After the hernia sac is dissected from the femoral defect, it can be opened, and the contents reduced into the abdominal cavity. The hernia sac can then be ligated.



Demonstrates a simple suture repair of a femoral hernia, which includes sewing Cooper's ligament to the inguinal ligament.

F. Netter M.D.

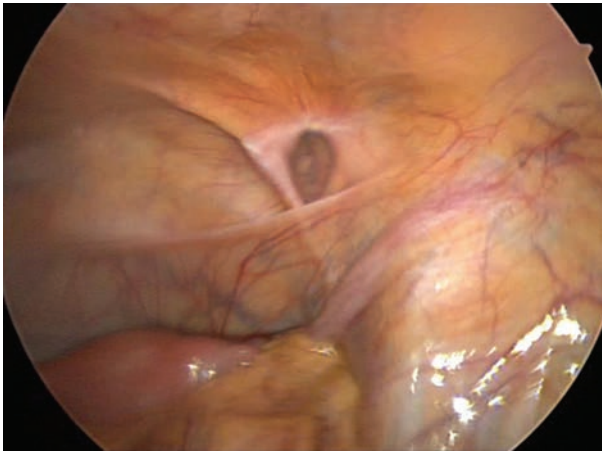
FIGURE 30-2 Open surgical repair of femoral hernia.

Laparoscopic Surgical Repair

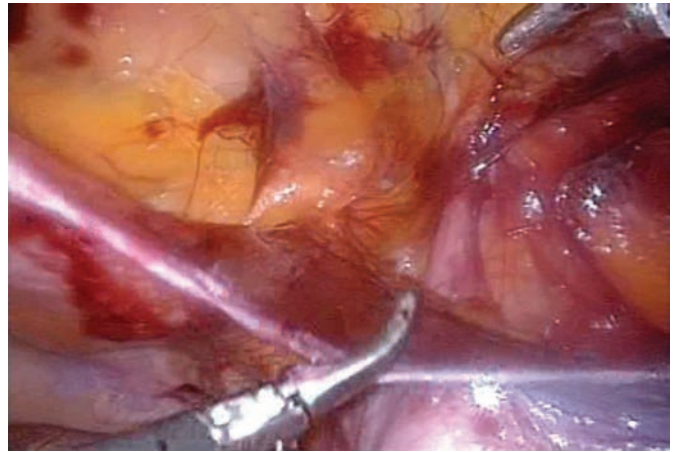
The laparoscopic repair of a femoral hernia is performed in the same manner as that of a standard inguinal hernia (see Chapter 28). Studies have reported both a transabdominal preperitoneal (TAPP) and a total extraperitoneal (TEP) approach for femoral hernia repair. For TAPP repair, traditionally three ports are used. Initial access is obtained at the umbilicus, and the additional working ports are placed to the right and left of midline at the level of the umbilicus. Initial examination reveals the defect near the femoral canal (Fig. 30-3).

The surgeon begins the procedure by taking down the peritoneum from the lateral abdominal wall to the midline. The femoral hernia can then be identified in the femoral triangle, and the hernia sac reduced into the abdominal cavity to expose the borders of the defect. For repair of the defect, a 12 × 15-cm piece of synthetic mesh is introduced into the abdomen through one of the laparoscopic ports. The mesh is laid in place overlying the defect, and is usually secured with tacks or fibrin glue. To complete the surgery, the created peritoneal defect is closed with titanium staples.

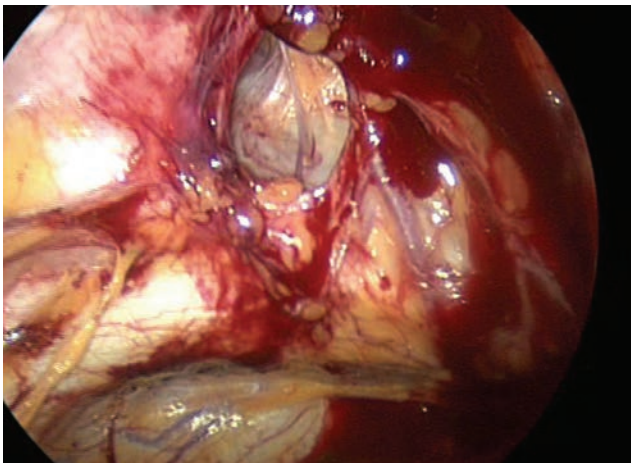
For TEP repair, the surgeon begins by making a 2-cm incision inferior and slightly lateral to the umbilicus. The rectus muscle is retracted laterally to allow visualization of the posterior rectus sheath. Using an S retractor or a finger, the surgeon develops the preperitoneal plane. A dissecting balloon is then passed into the space and insufflated under direct laparoscopic visualization. The dissecting balloon is then removed, and a port with a small stay balloon is inserted. Two 5-mm working ports are placed in the midline 2 cm and 5 cm superior to the pubic tubercle. The preperitoneal space can be developed with the assistance of a laparoscopic Kitner dissection. The repair technique is similar to that used for a TAPP repair, with the placement of mesh overlying the defect. However, because the surgery remains extraperitoneal, there is no need to close a peritoneal flap.



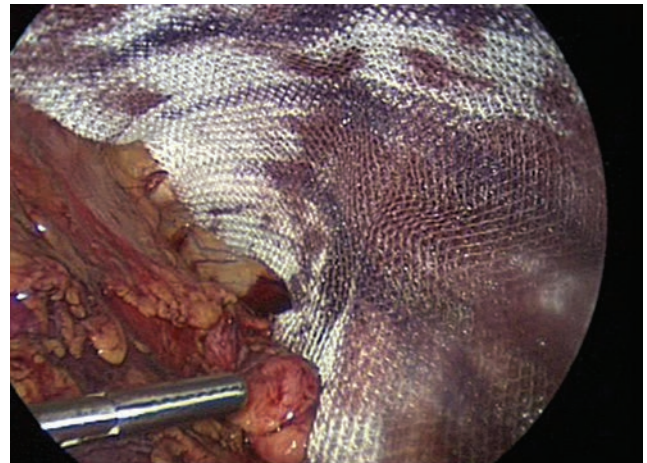
A. Initial laparoscopic view of a right femoral hernia. The defect is located superior to Cooper's ligament, inferior to the inguinal ligament, medial to the femoral vein, and lateral to the lacunar ligament.



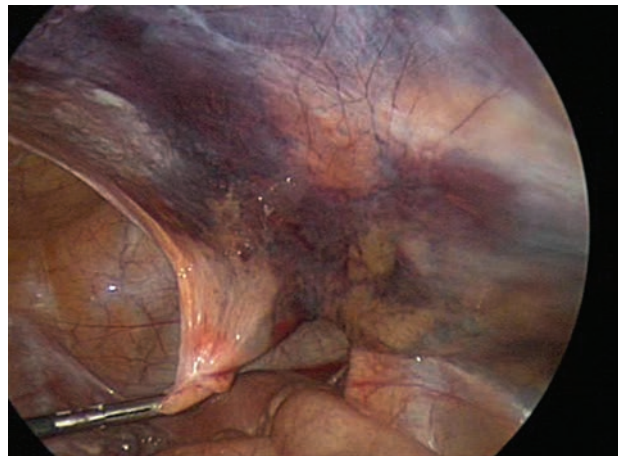
B. Peritoneal lining reflected inferiorly to allow access to the defect.



C. Border of the femoral defect after the hernia contents have been removed.



D. Placement of a macroporous synthetic mesh overlying the hernia defect.



E. To complete the TAPP repair, the peritoneal flap created earlier is secured with tacks or staples to exclude the mesh from the abdominal contents.

FIGURE 30-3 Laparoscopic surgical repair of femoral hernia.

SUGGESTED READINGS

- Chan G, Chan CK. Long-term results of a prospective study of 225 femoral hernia repairs: indications for tissue and mesh repair. *J Am Coll Surg* 2008;207(3):360-7.
- Dahlstrand U, Wollert S, Nordin P, Sandblom G, Gunnarsson U. Emergency femoral hernia repair: a study based on a national register. *Ann Surg* 2009;249(4):672-6.
- Hernandez-Richter T, Schardey HM, Rau HG, Schildberg FW, Meyer G. The femoral hernia: an ideal approach for the transabdominal preperitoneal technique (TAPP). *Surg Endosc* 2000;14(8):736-40.
- McCormack K, Scott NW, Go PM, Ross S, Grant AM. Laparoscopic techniques versus open techniques for inguinal hernia repair. *Cochrane Database Syst Rev* 2003;(1):CD001785.

Open Ventral Hernia Repair

Michael J. Rosen

INTRODUCTION

Ventral (abdominal) hernia repair is one of the most common procedures performed by general surgeons, with more than 200,000 done each year in the United States. Despite the prevalence of this procedure, there is little consensus as to the indications for repair, optimum technique, or appropriate position of the prosthetic mesh. Given the wide variety of patient and hernia factors, no single approach will likely suffice to repair all abdominal wall defects. Options include a laparoscopic or an open repair. The laparoscopic approach is typically reserved for obese patients with small to medium-sized defects, to avoid extensive subcutaneous dissection and potential mesh infections. The open repair can be performed with several methods.

Most surgeons agree that all incisional hernias should be repaired with prosthetic (synthetic or biologic) mesh, because recurrence rates are reduced by half. Prosthetic mesh can be placed as an *inlay* (sewn to the fascial edge), an *onlay* (sewn above the fascia), or a *sublay* (underneath the fascia). Sublay mesh can be placed in the intraperitoneal, preperitoneal, or retrorectus position. The inlay approach has been largely abandoned because of high recurrence rates, and the onlay approach is discouraged because the prosthetic mesh is placed in the subcutaneous position at highest risk for mesh sepsis. Most herniologists agree that the prosthetic mesh should be placed as a sublay. This chapter focuses on the sublay repair, with particular attention to the retrorectus placement of the mesh.

SURGICAL PRINCIPLES

General principles of incisional hernia repair include gaining access to the reoperative abdomen, complete adhesiolysis, preparation of the abdominal wall for prosthetic mesh placement, mesh deployment, and reconstruction of a dynamic abdominal wall with reapproximation of the linea alba. Safe access to the reoperative abdomen typically involves extending incisions in a cephalad direction to enter the undissected peritoneum. Complete adhesiolysis of the anterior abdominal wall is important to free the abdominal wall musculature and allow it to advance to the midline during eventual reconstruction of the midline.

Reestablishing the linea alba is an important concept in abdominal wall reconstruction. If the linea alba is seen as the tendinous insertion of the rectus abdominis muscle and oblique muscles, it is critical to achieve appropriate physiologic loading of the abdominal wall. In particular, reconstructing a completely tension-free repair in fact renders the oblique muscles nonfunctional, with constant lateral displacement of the abdominal wall leading to mesh displacement at the mesh-tissue interface. This chapter emphasizes surgical methods to reapproximate the rectus complex.

PREOPERATIVE IMAGING

Preoperative imaging of the abdominal wall is very helpful. The author typically performs abdominal pelvic computed tomography (CT) scans in all patients undergoing complex abdominal wall reconstruction. CT images can help delineate the location, size, and complexity of the hernia, particularly in obese patients. Attention to the relationship of the hernia to bone structures (e.g., xiphoid, costal margin, iliac crest, pelvis) is important for surgical planning. Recognizing the appropriate plane is paramount to gain sufficient overlap of the mesh and achieve the most durable repair. Likewise, the integrity of the rectus abdominis muscle is important. If the rectus muscle is narrow, the mesh cannot be placed in the retrorectus position and will need to be located in the preperitoneal position, as described later. If the rectus muscle is destroyed, absent, or atrophic, alternative methods are necessary.

Some surgeons have advocated abdominal wall ultrasound to detect hernias, but the author has found this to be very user dependent, with minimal experience.

ANATOMY OF ABDOMINAL WALL

Figures 31-1 and 31-2 show the anatomy of the vascular supply and innervation of the abdominal wall. Understanding the relationships of these nerves and vessels and their location in the abdominal wall is critical to preserve them during dissection, to maintain an innervated functional abdominal wall.

The blood supply of the anterior abdominal wall can be divided into three zones (Fig. 31-3). Zone 1 consists of the upper and midcentral abdominal wall and is supplied by the deep superior and deep inferior epigastric arteries. Zone 2 consists of the lower abdominal wall and is supplied by the epigastric arcade and the superficial inferior epigastric, superficial external pudendal, and superficial circumflex iliac arteries. Zone 3 consists of the lateral abdominal wall (flank) and is supplied by the musculophrenic and lower intercostal and lumbar arteries. Recognizing the location of prior transverse incisions that may have compromised abdominal wall blood supply is important to limit ischemic skin complications.

Sensory innervation of the abdominal wall is derived from the 7th thoracic (T7) to 1st lumbar (L1) intercostal and subcostal nerves. These nerves run alongside the intercostal and lumbar arteries in the plane between the internal oblique and transversus abdominis muscles. The rectus abdominis muscle is segmentally innervated by the lower six intercostal nerves. These nerves penetrate the linea semilunaris at the lateral border of the rectus muscle. It is important to preserve these nerves during dissection of the lateral abdominal wall, to avoid denervation of the rectus complex.

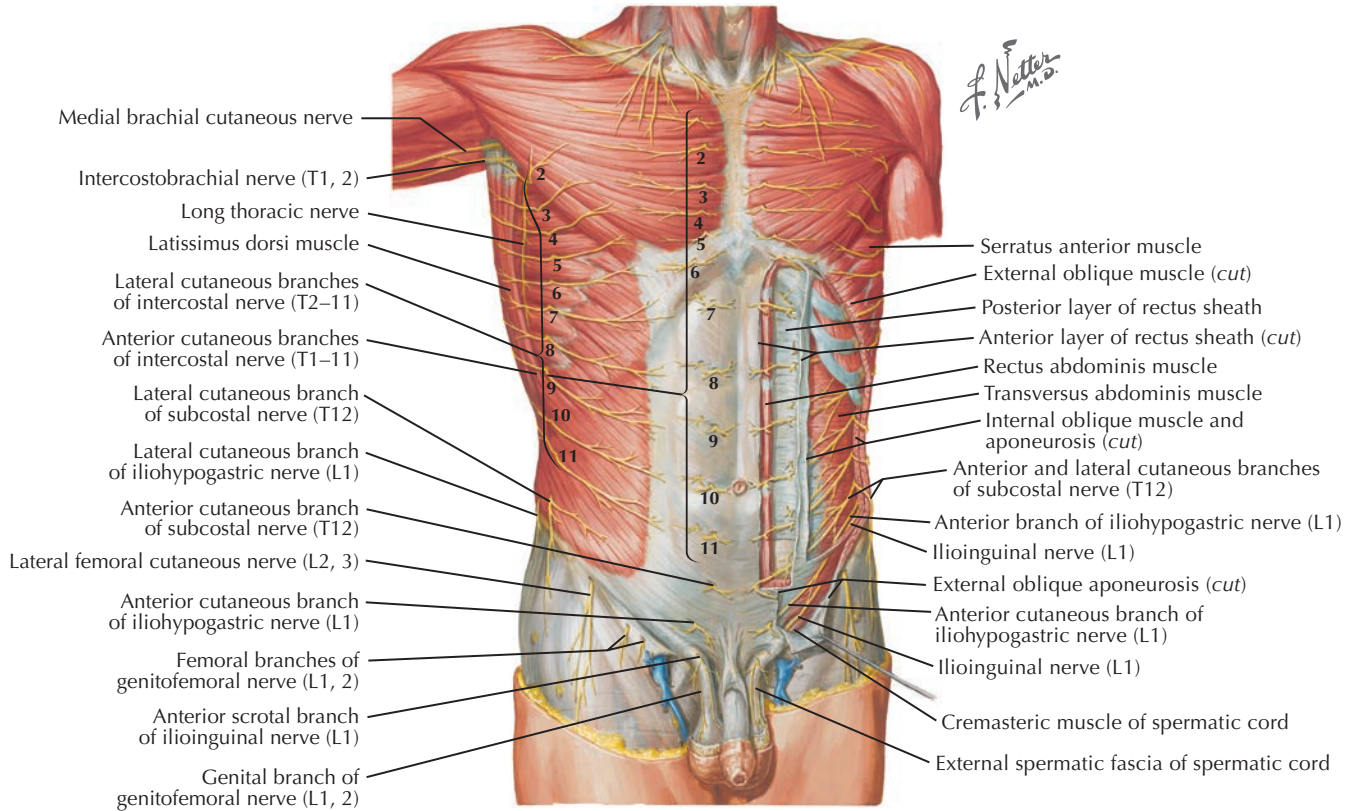
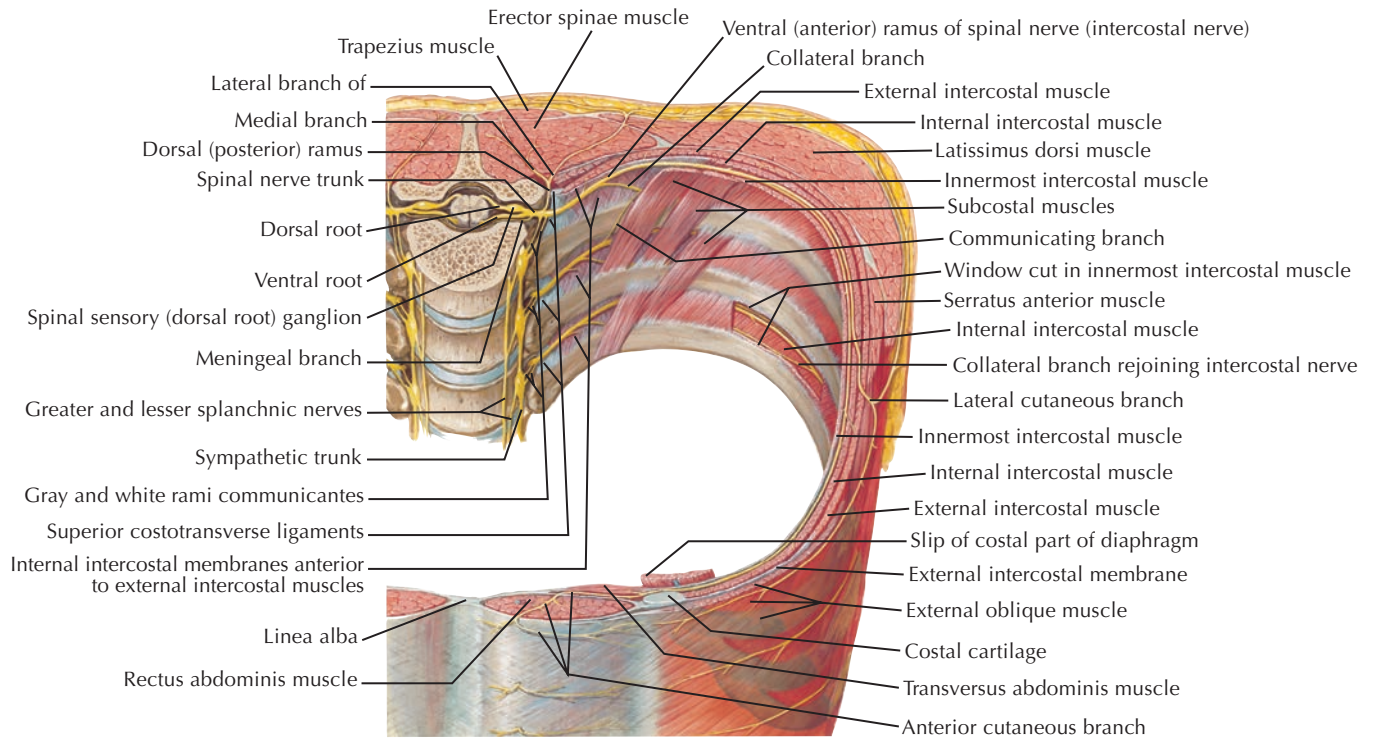


FIGURE 31-1 Innervation of abdomen and perineum.

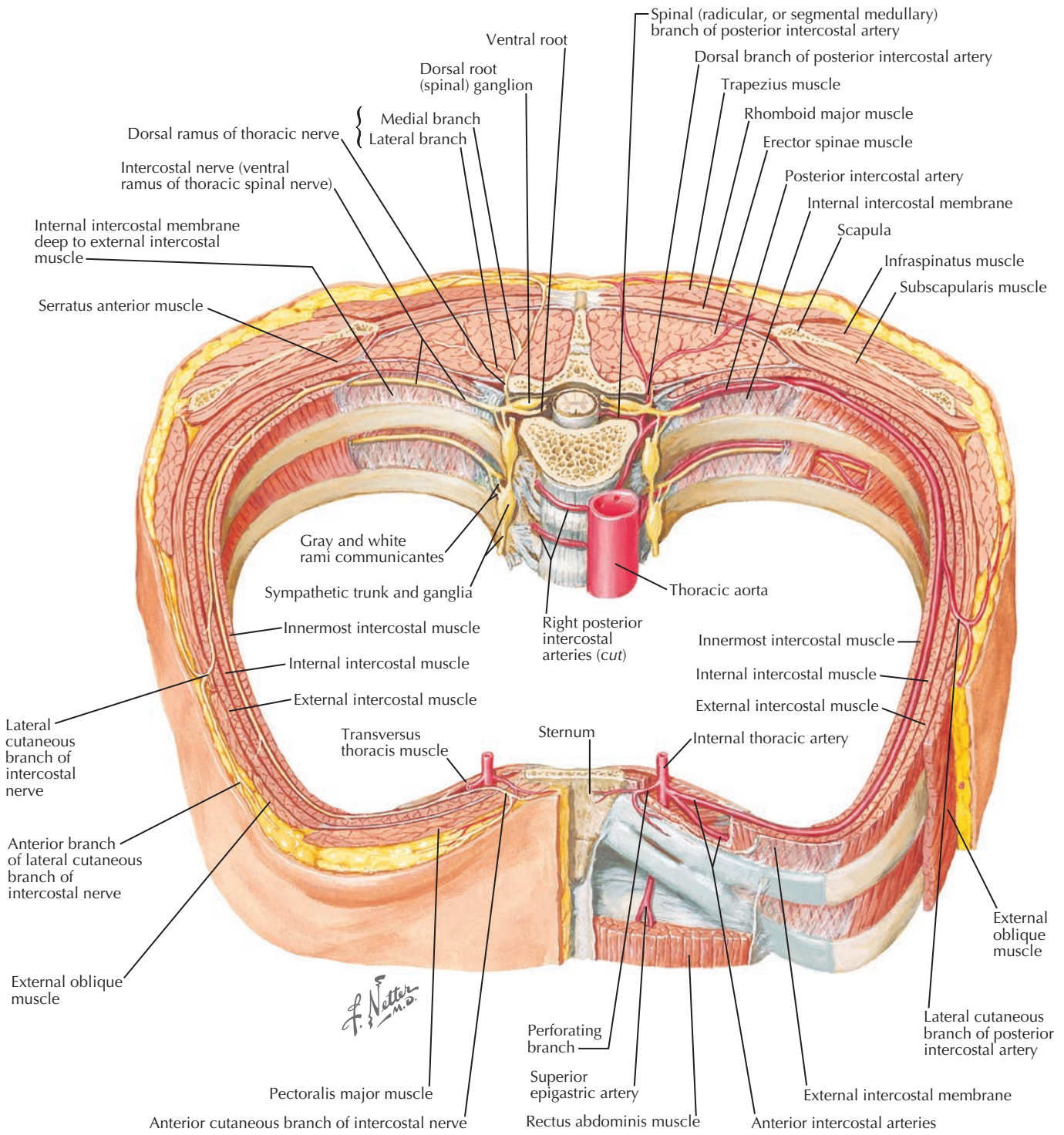


FIGURE 31-2 Course and relations of intercostal nerves and arteries.

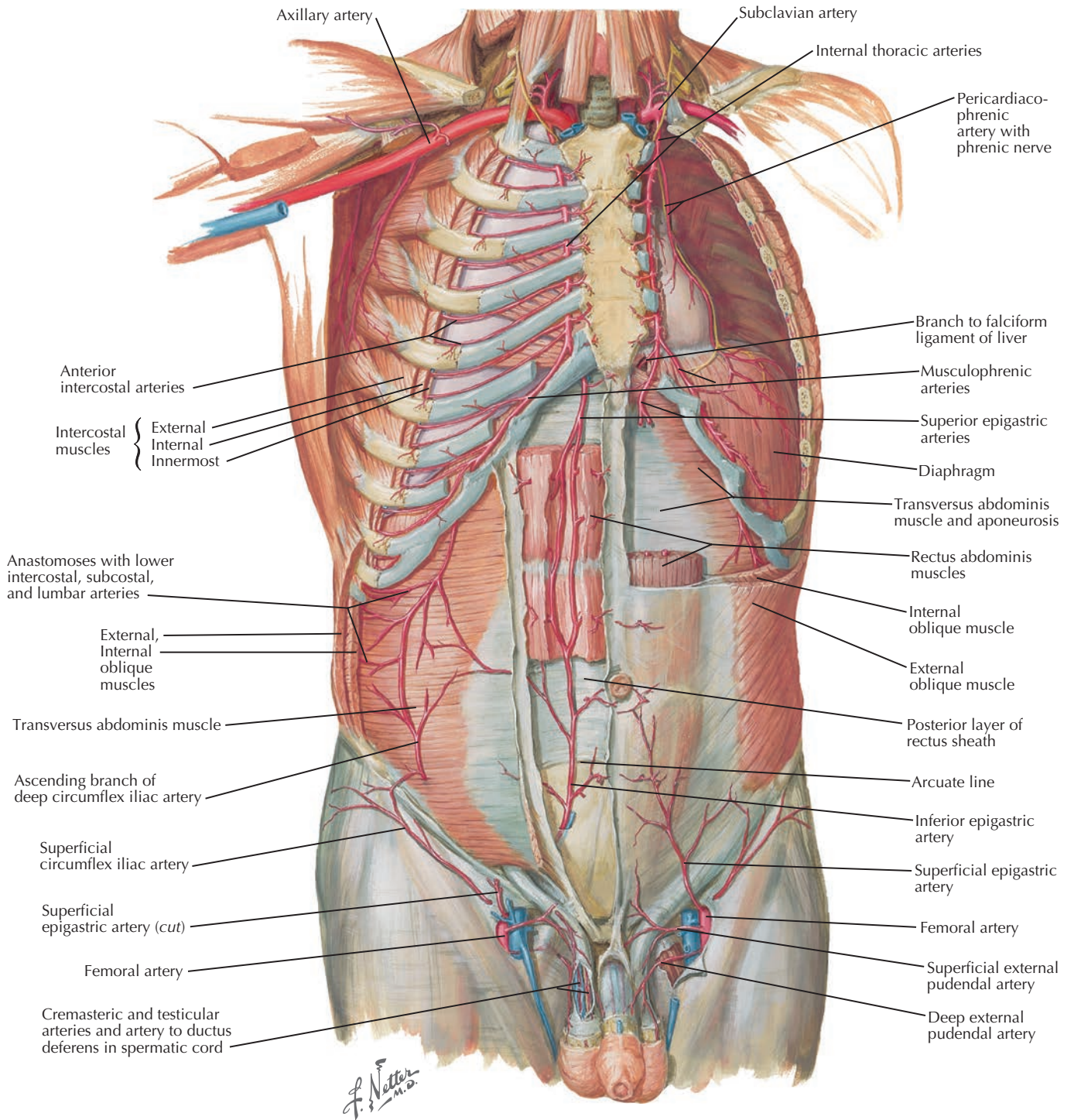


FIGURE 31-3 Arteries of anterior abdominal wall.

SURGICAL TECHNIQUE

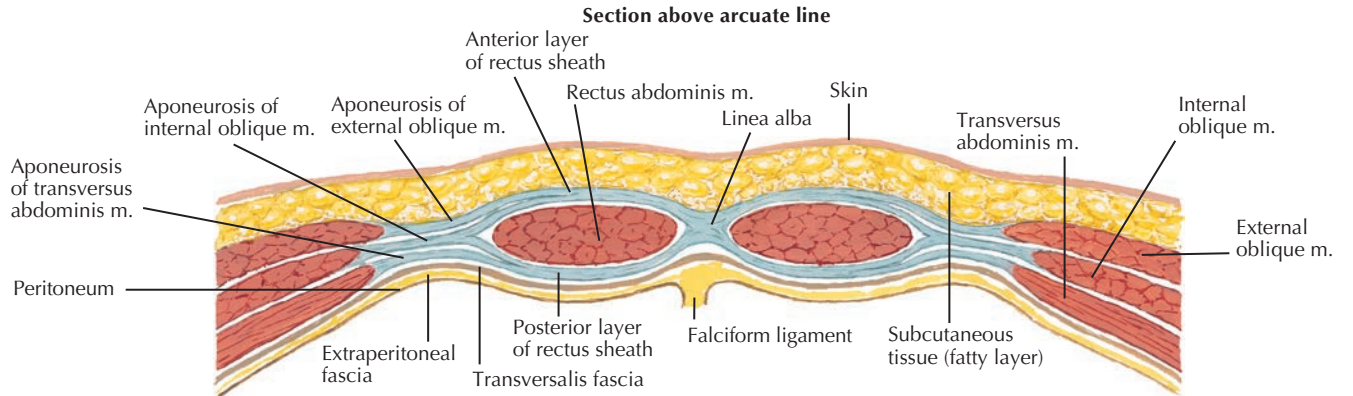
A standard midline incision is created to encompass all previous surgical incisions, if possible. The abdomen is entered sharply, and the anterior abdominal wall is completely freed of adhesions to the lateral gutters (adhesiolysis). It is important to separate all adhesions to avoid injuring visceral contents during dissection of the lateral abdominal planes, and to allow these structures to slide to the midline during eventual abdominal wall reconstruction. A surgical towel is placed over the viscera to protect them during dissection. All prior prosthetic materials are removed from the abdominal wall.

Creation of Retrorectus Space

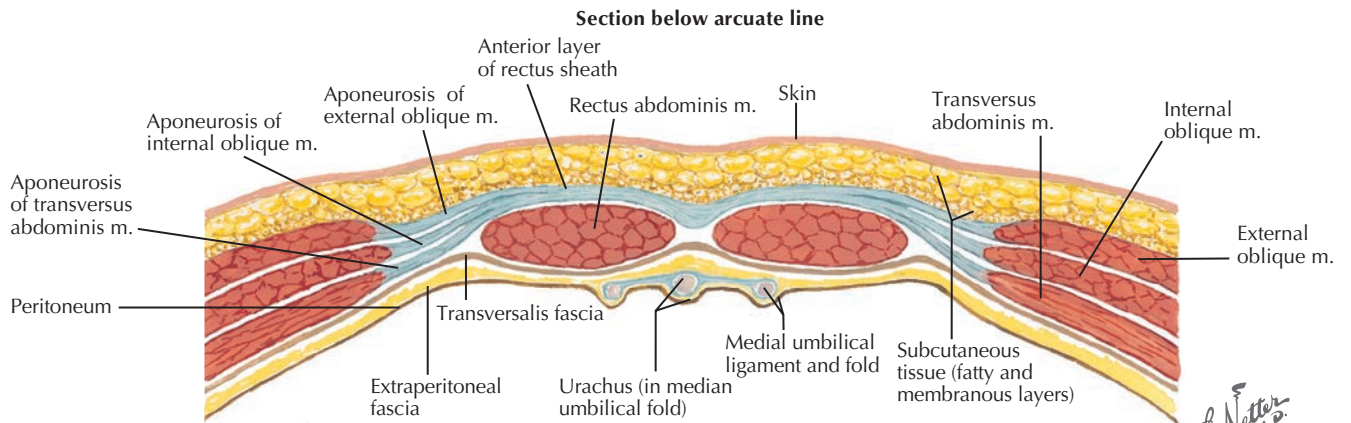
The linea alba is grasped with Kocher clamps, and the posterior rectus sheath is incised approximately 0.5 cm lateral from its edge (Fig. 31-4, A and B). This typically is begun just above the umbilicus. The plane is created using cautery, with care taken to avoid injuring the underlying rectus muscle. The retromuscular plane is then developed in a cephalad and caudal direction. The dissection is carried laterally to the linea semilunaris. This anatomic plane is localized by identifying the perforating intercostal nerves and vessels (Fig. 31-4, C). It is typically 1 cm lateral to the inferior epigastric vessels.

If the rectus muscle is relatively well preserved and sufficiently wide, the dissection is complete; the posterior components are closed and prosthetic mesh is placed. In larger hernias, requiring more overlap, or in atrophic narrowed rectus muscles, the dissection can be continued to the lateral abdominal wall (see [Lateral Dissection in Preperitoneal Plane](#)).

A. Cross-sectional anatomy of the anterior abdominal wall

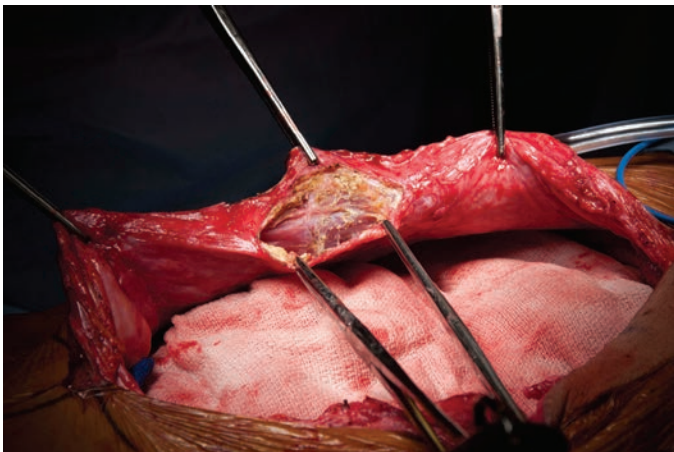


Aponeurosis of internal oblique muscle splits to form anterior and posterior layers of rectus sheath. Aponeurosis of external oblique muscle joins anterior layer of sheath; aponeurosis of transversus abdominis muscle joins posterior layer. Anterior and posterior layers of rectus sheath unite medially to form linea alba.

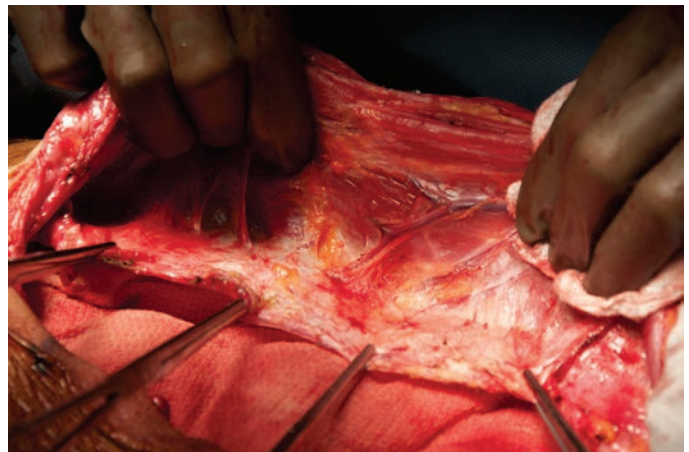

Aponeurosis of internal oblique muscle does not split at this level but passes completely anterior to rectus abdominis muscle and is fused there with both aponeurosis of external oblique muscle and that of transversus abdominis muscle. Thus, posterior wall of rectus sheath is absent below arcuate line, and rectus abdominis muscle lies on transversalis fascia.

F. Netter M.D.



B. Initial operative view of incising the posterior rectus sheath



C. Posterior rectus sheath has been separated from the rectus muscle with the intercostal nerves visible penetrating at the linea semilunaris, innervating the rectus muscle

FIGURE 31-4 Cross section of anterior abdominal wall and creation of retrorectus space.

Exposure of Cooper's Ligament and Pelvis

The dissection can be continued inferiorly to the pubis, if necessary (Figs. 31-5 and 31-6, A). The space of Retzius is entered bluntly to expose the pubic symphysis in the midline. If undissected, this plane is typically bloodless and can be easily developed. If the bladder has previously been mobilized, using a three-way Foley catheter with instillation of 300 mL of saline into the bladder can aid in identifying and avoiding a bladder injury. This plane is below the arcuate line and therefore consists of the peritoneum and transversalis fascia only. Fenestrations can occur and should be recognized and repaired accordingly. The pubis and bilateral Cooper's (pectineal) ligament are exposed. The inferior epigastric vessels, iliac vessels, and cord structures should be identified and carefully preserved in this dissection plane.

Lateral Dissection in Preperitoneal Plane

In patients with insufficient mobilization of the posterior sheath to reapproximate in the midline, narrow atrophied rectus muscles, and inability to place wide prosthetic mesh, the dissection is carried into the lateral abdominal plane. Ideally, this plane is entered while the innervation of the rectus complex is preserved. The preperitoneal space is entered approximately 1 cm medial to the perforating nerves at the linea semilunaris (Fig. 31-6, B and C). The posterior rectus sheath is divided throughout its length. With the use of blunt Kitner dissection, the preperitoneal space is developed to the psoas muscle, if necessary. This preperitoneal plane is particularly useful for subxiphoid hernias because the peritoneum can be swept off the costal margin several centimeters superiorly. As the dissection continues cephalad, the posterior sheath typically consists of the transversus abdominis muscle. This muscle must be divided to enter the preperitoneal space.

Posterior Layer Reconstruction

Once the release is completed on both sides, the posterior components are reapproximated in the midline, completely excluding the bowel from the mesh (Fig. 31-6, D). This procedure is performed with a running absorbable suture. Defects in the posterior layer are closed with interrupted figure-of-eight sutures or buttressed with native tissue (omentum, fat). Antibiotic irrigation is typically performed.

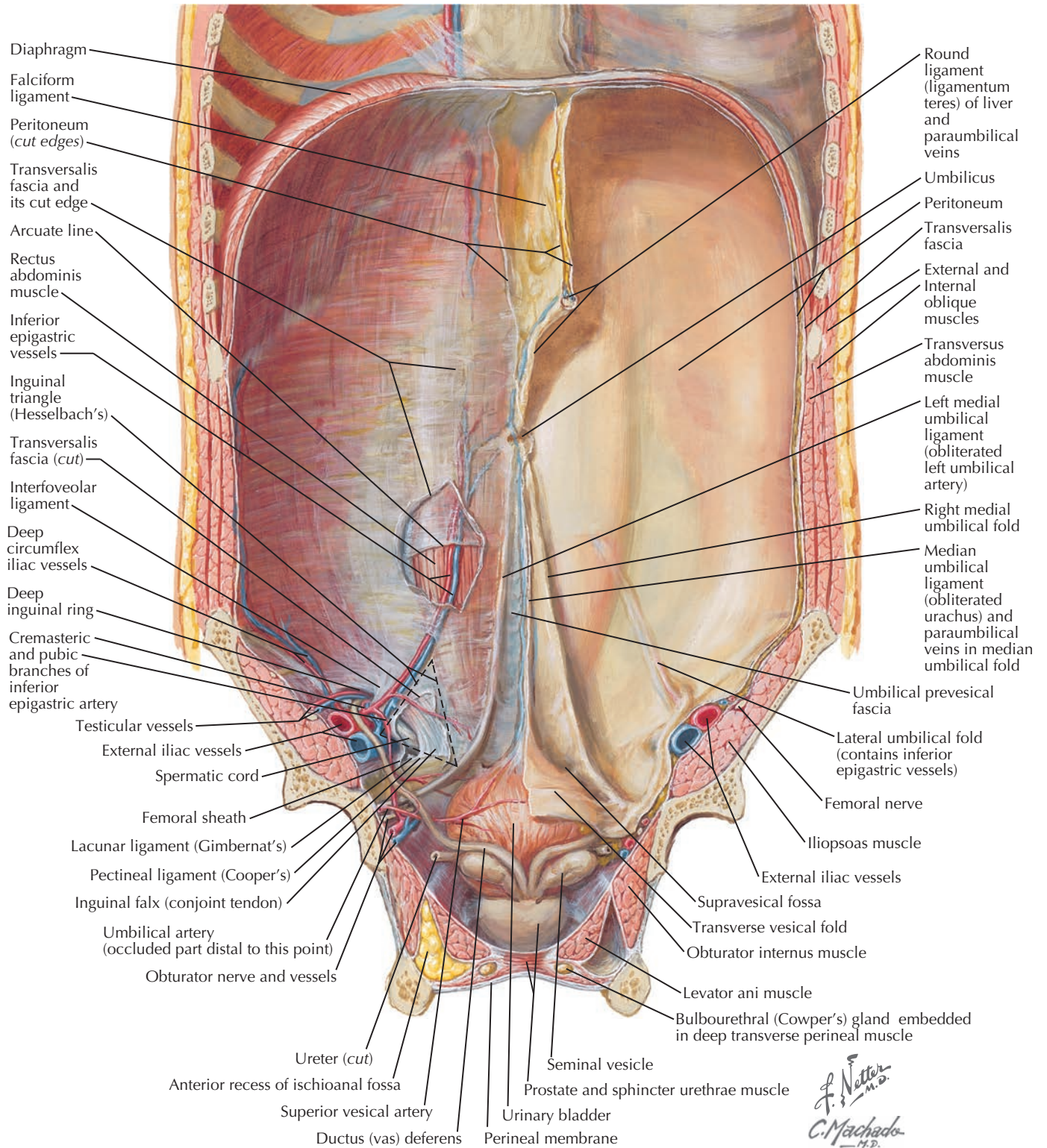


FIGURE 31-5 Posterior view of pelvis and lower abdominal wall.

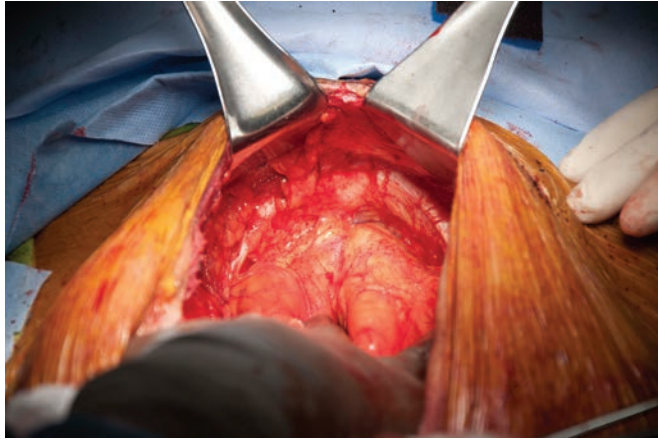
Mesh Deployment

The prosthetic mesh is placed in the sublay retromuscular position. Because the mesh is placed extraperitoneally, extensive sutures are not necessary because the bowel cannot herniate around the mesh. Likewise, a standard macroporous mesh is sufficient without an antiadhesive barrier. Full-thickness transfascial sutures are placed. These sutures serve two key purposes: providing stability to the mesh immediately after the repair to prevent displacement and helping medialize the rectus muscles and redistribute the tension of the repair to the lateral abdominal wall through the mesh. It is important to understand this concept, because this is not meant to be a true tension-free hernia repair. Instead, it restores appropriate physiologic tension to the abdominal wall. If the mesh is placed without tension, and the abdominal wall is then reapproximated, there is almost always some buckling of the mesh, which leads to seromas, infections, and lack of incorporation.

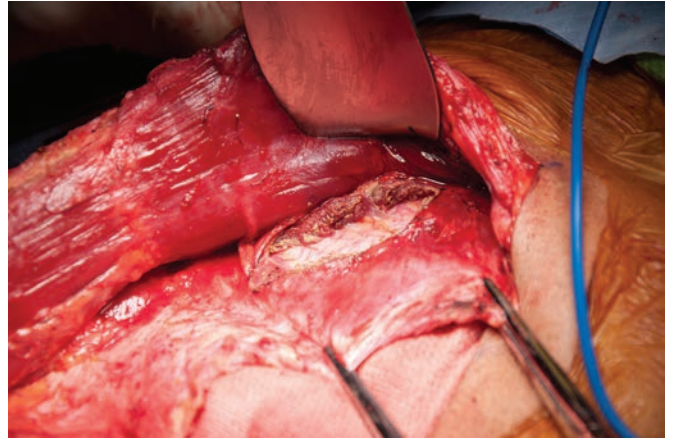
The inferior edge of the mesh can be secured directly to Cooper's ligament. If the defect is suprapubic, the sutures are backed off the edge of the mesh, to allow the prosthetic material to drape below the pelvis. Suction drains are placed in the retromuscular space, above the mesh. These drains are removed rapidly if synthetic mesh is chosen, or are left for several weeks if biologic mesh is used.

Reconstruction of Linea Alba

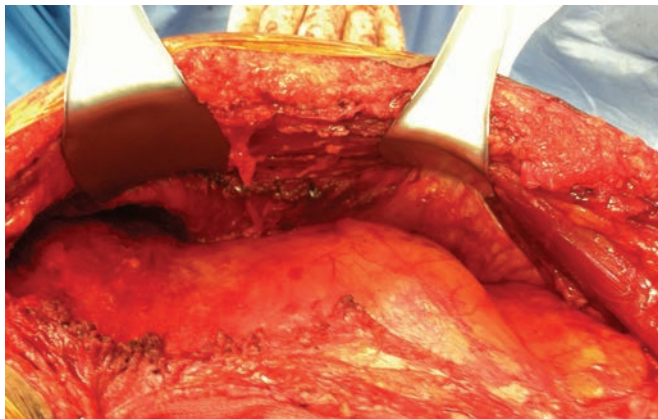
The anterior rectus sheath is then reapproximated in the midline using slowly absorbable figure-of-eight sutures. If plateau airway pressures increase more than 10 mm Hg, the fascia is not reapproximated and a bridged repair is planned. All excessive skin and hernia sac are excised, and the wound is closed in layers.



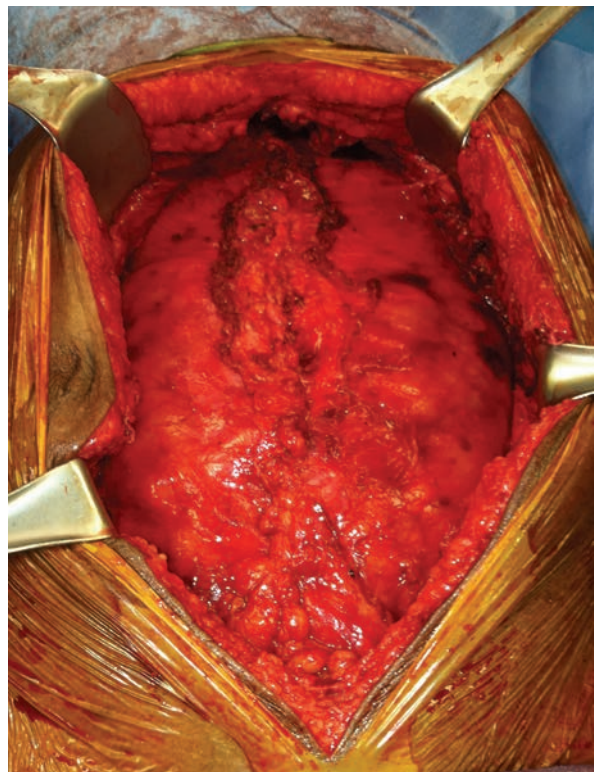
A. Intraoperative view of space of Retzius with bladder mobilized and pelvis exposed.



B. Initial transection of the transversus abdominis muscle just medial to the perforating intercostal nerves at the linea semilunaris



C. Complete mobilization of the lateral peritoneum and posterior complex.



D. Posterior components reapproximated in the midline, creating an entirely extraperitoneal plane for mesh deployment.

FIGURE 31-6 Open ventral (abdominal) hernia repair.

SUGGESTED READINGS

- Iqbal CW, Pham TH, Joseph A, et al. Long-term outcome of 254 complex incisional hernia repairs using the modified Rives-Stoppa technique. *World J Surg* 2007;31(12):2398-404.
- Luijendijk RW, Hop WC, van den Tol MP, et al. A comparison of suture repair with mesh repair for incisional hernia. *N Engl J Med* 2000;343(6):392-8.
- Novitsky YW, Porter JR, Rucho ZC, et al. Open preperitoneal retrofascial mesh repair for multiply recurrent ventral incisional hernias. *J Am Coll Surg* 2006;203(3):283-9.
- Ramirez OM. Inception and evolution of the components separation technique: personal recollections. *Clin Plast Surg* 2006;33(2):241-6, vi.
- Stoppa RE. The treatment of complicated groin and incisional hernias. *World J Surg* 1989;13(5):545-54.

Exposure of the Carotid Bifurcation



Jerry Goldstone

INTRODUCTION

Carotid endarterectomy is one of the most frequently performed vascular operations. The vast majority of these procedures are for atherosclerosis at the bifurcation of the common carotid artery, which lies within the anterior triangle of the neck, usually at the upper border of the thyroid cartilage (Fig. 32-1, *A*). The key anatomic boundaries are the sternocleidomastoid muscle, the midline, and the mandible (Fig. 32-1, *B*).

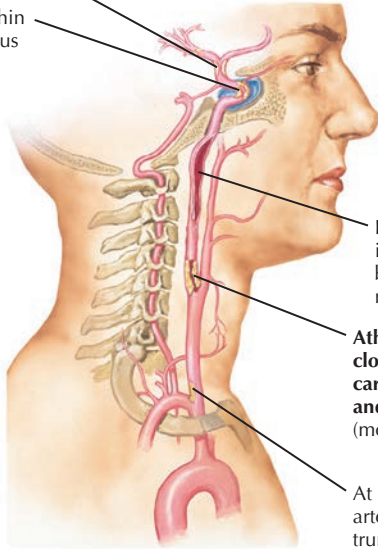
CAROTID ENDARTERECTOMY

The procedure begins with proper positioning of the patient, with the neck extended and turned toward the opposite side. The incision can be made along the anterior border of the sternocleidomastoid muscle (SCM) or transversely (obliquely) in a skin crease overlying the carotid bifurcation (Fig. 32-1, *B*). The bifurcation can easily be located with duplex ultrasound. The platysma muscle is then divided, exposing the deep cervical fascia (Fig. 32-1, *C*).

A. Stenosis or occlusion of carotid artery

Atheroma with or without clot at bifurcation of internal carotid artery into anterior and middle cerebral arteries

At siphon within cavernous sinus

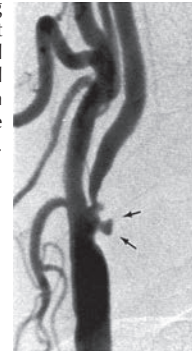

Dissecting aneurysm of internal carotid artery below base of skull (string sign radiographically)

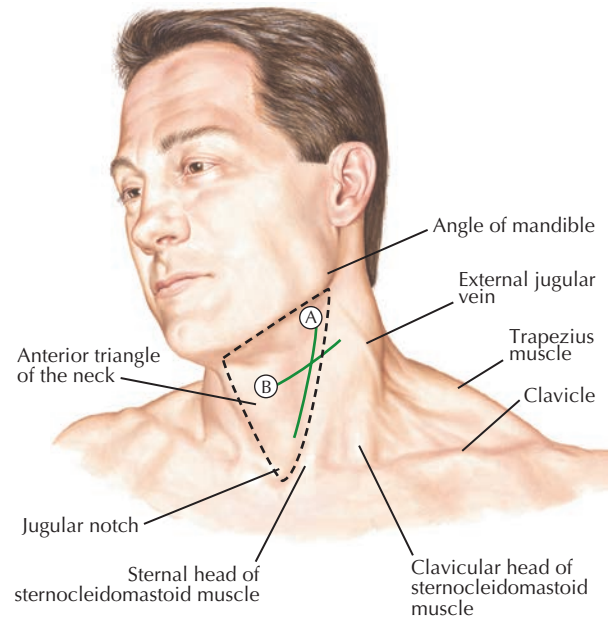
Atheroma with or without clot at bifurcation of common carotid artery into internal and external carotid arteries (most common)

At origin of common carotid artery from brachiocephalic trunk or aorta (uncommon)

Angiogram (lateral view) showing moderately severe stenosis at origin of left internal carotid artery, with ulceration indicated by protrusion of contrast medium (arrows). Such a case is suitable for endarterectomy.



B. Incision lines



- Ⓐ Incision along anterior border of the sternocleidomastoid
- Ⓑ Incision transverse/obliquely in a skin crease overlying the carotid bifurcation

C. Platysma

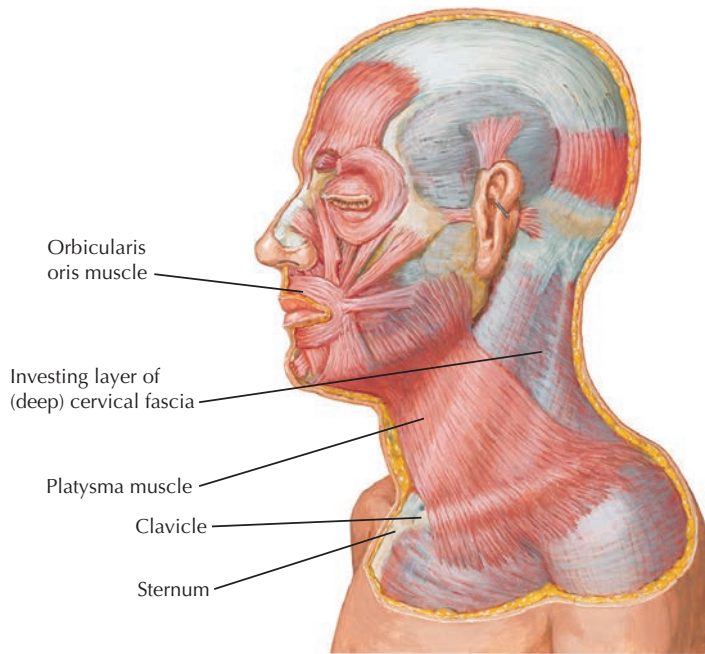


FIGURE 32-1 Carotid stenosis, incision lines for endarterectomy, and platysma.

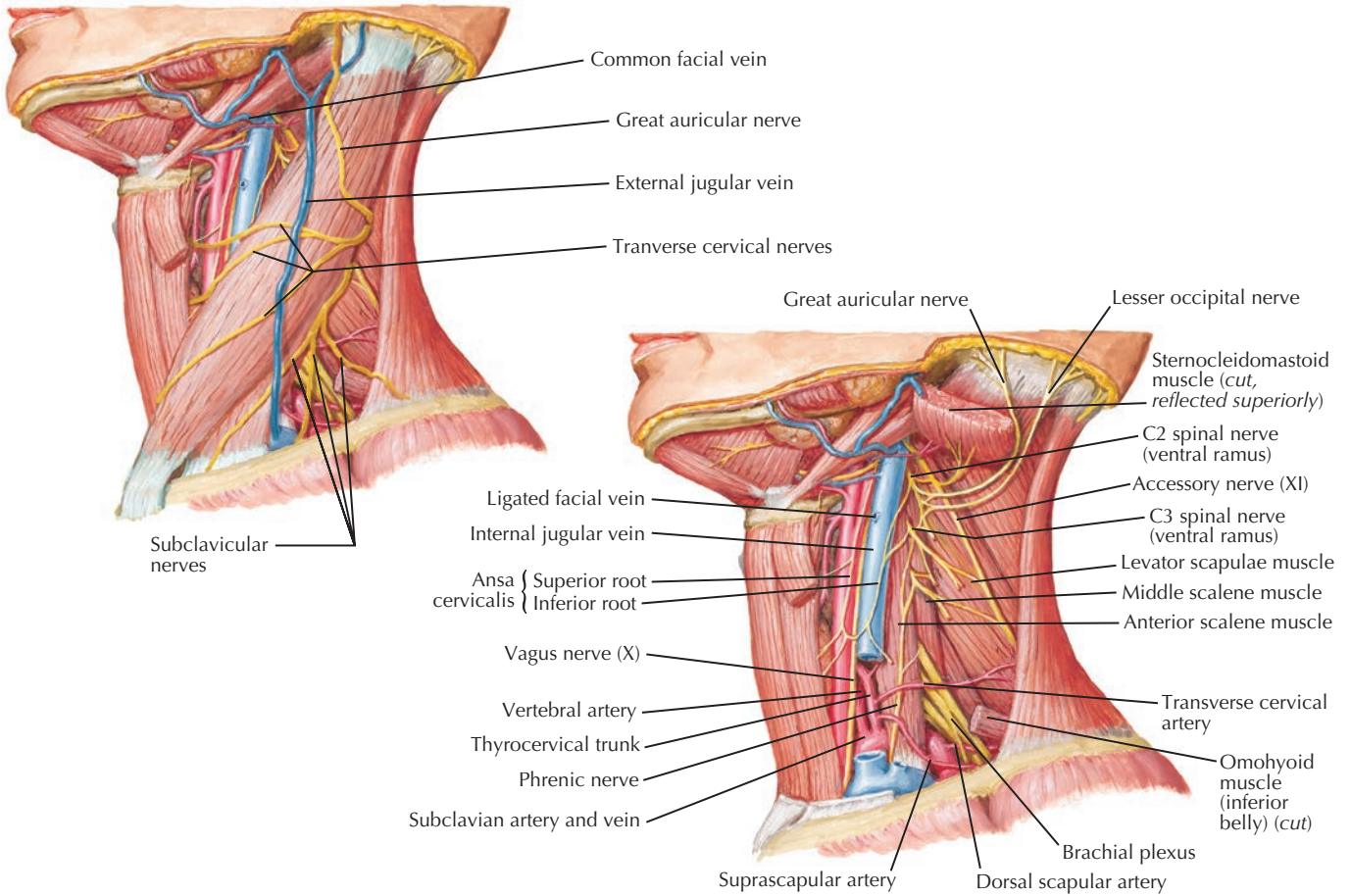
Surgical Principles

The external jugular vein and greater auricular nerve lie in this plane; the vein can be ligated, but the nerve must be preserved to avoid numbness of the ear lobe (Fig. 32-2, *A*).

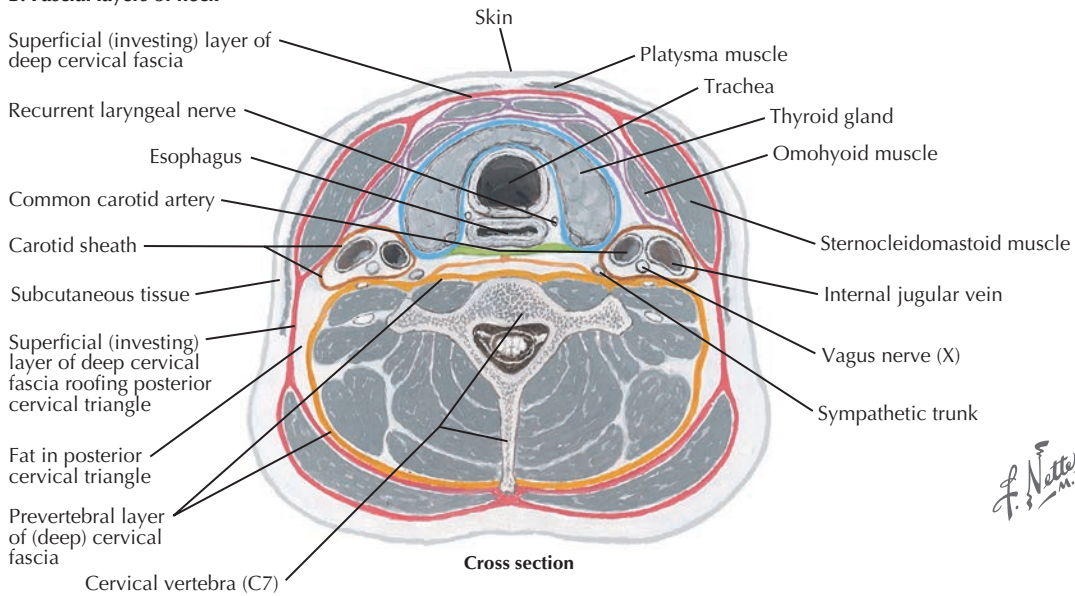
Next, two key steps are necessary to expose the carotid bifurcation. The first is mobilization of the anterior border of the SCM, which is invested within two layers of the deep cervical fascia (Fig. 32-2, *B*). If a transversely oriented incision is used, this requires creation of subplatysmal flaps, both cephalad and caudad, on the plane of the anterior SCM fascial layer.

The second step, after the SCM is retracted laterally, is mobilization of the internal jugular vein, which lies lateral and anterior to the common carotid artery within the carotid sheath. This sheath is loose, fibroareolar tissue rather than a single, well-defined layer. Mobilization of the internal jugular vein exposes the common carotid artery as well as the vagus nerve, which usually is posterior to the artery but may be anterior, where it is more susceptible to injury.

A. Nerves and vessels of neck



B. Fascial layers of neck



F. Netter M.D.

FIGURE 32-2 Nerves and fascial layers of neck.

Anatomic Landmarks

The *ansa cervicalis nerve* (also known as *ansa hypoglossi*) is often seen running along the anterior surface of the common carotid artery (Fig. 32-2, A). This nerve can be divided with impunity, and the cranial end followed to its junction with the hypoglossal nerve. The *hypoglossal nerve* runs between the internal jugular vein and internal carotid artery and is usually found about 2 cm above the carotid bifurcation. However, its position can vary. Often, small jugular venous tributaries drain the SCM at this level, along with accompanying arteries that must be divided. Extreme care must be taken to avoid bleeding in this location; attempts to control bleeding are a common cause of injury to the hypoglossal nerve.

The largest tributary of the internal jugular vein is the *common facial vein*, an important landmark that almost always overlays the location of the carotid bifurcation. The facial vein should be carefully mobilized, divided, and suture-ligated. The jugular vein can then be retracted laterally and its position maintained with a self-retaining retractor. Rarely, the hypoglossal nerve is low lying and closely attached to the underside of the facial vein, making it vulnerable to injury when the vein is divided.

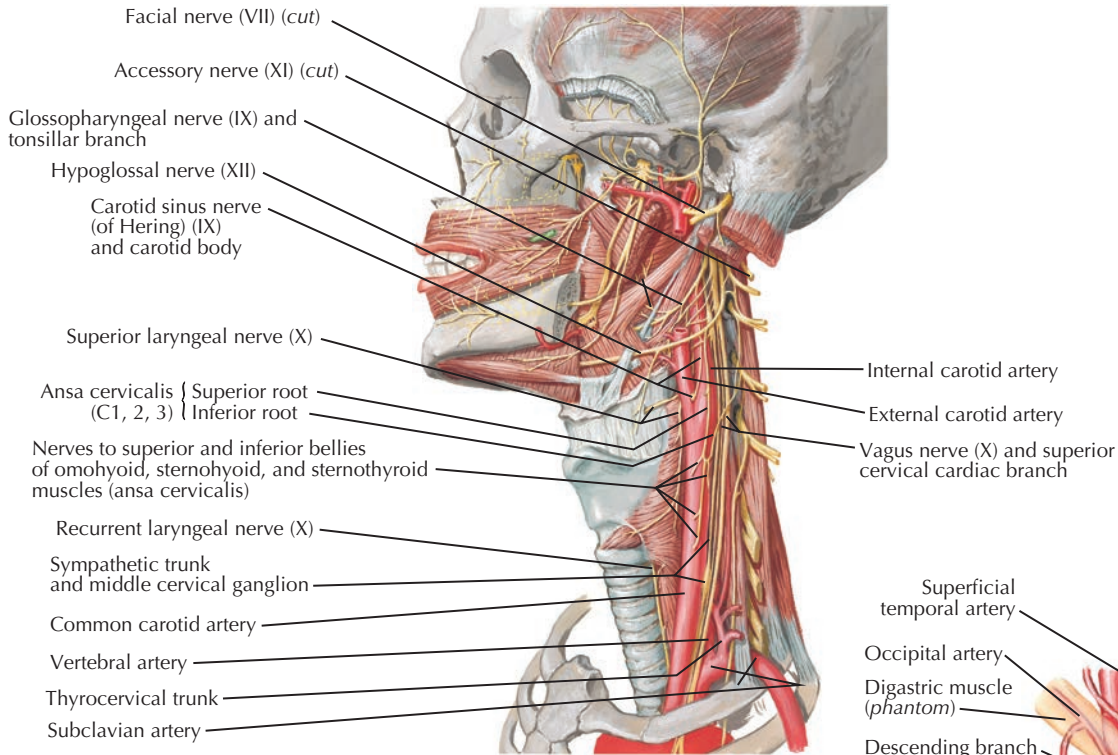
ARTERIAL DISSECTION

The arterial dissection begins with the common carotid artery, which should be mobilized as far proximally as the omohyoid muscle, which usually marks the proximal extent of the dissection. The internal and external carotid arteries should be mobilized before the carotid bifurcation. The external carotid artery is usually more anterior and lateral and should be mobilized before the internal carotid artery. The superior thyroid artery is encountered near the bifurcation of the common carotid and may be a branch of either the common or the external carotid. The superior thyroid is usually the only arterial branch at the level of bifurcation. Adequate mobilization of the external carotid artery should extend beyond its first bifurcation.

The internal carotid artery is mobilized next. This procedure often requires division and mobilization of an adipose and lymphatic mass that contains small venous tributaries of the internal jugular vein and their accompanying arteries. These vessels, especially the sternocleidomastoid branch of the occipital artery, tether the hypoglossal nerve and may need to be divided to mobilize it. Although tiny, these vessels can cause troublesome bleeding, and careful dissection is required to identify and ligate them. The internal carotid artery lies immediately deep to this layer, as does the hypoglossal nerve. Mobilization of the hypoglossal nerve anteriorly enables more distal exposure of the internal carotid artery to the level of the digastric muscle (Fig. 32-3).

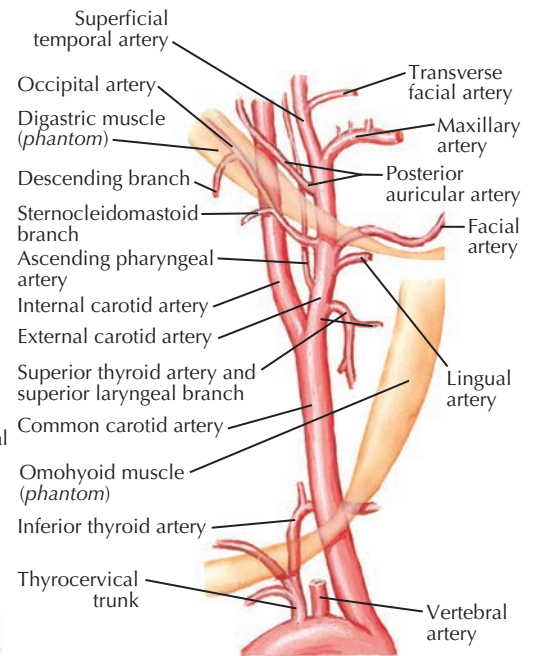
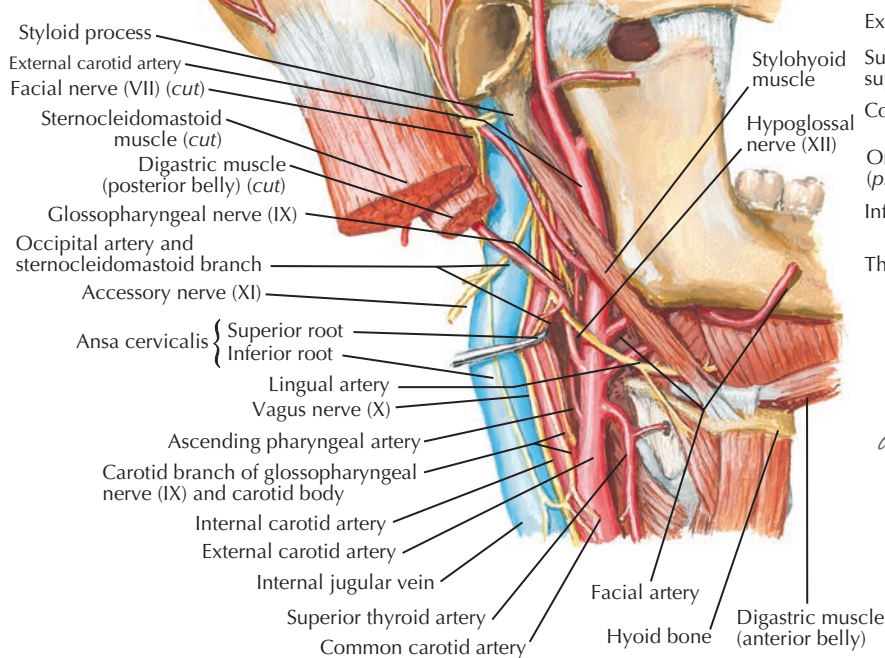
Division of the digastric muscle allows further exposure of the internal carotid artery to within 1 or 2 cm of the skull base. Cephalad retraction at this level must be gentle to avoid compression of the marginal mandibular branch of the facial nerve against the mandible, which can weaken the orbicularis oris muscle, resulting in asymmetric movement of the mouth. The occipital artery is usually found crossing the internal carotid artery at this level and can be ligated, if necessary, but the spinal accessory nerve also crosses the internal carotid at this level and must be protected from injury. The sympathetic chain is also vulnerable to injury where it lays just posterior to the internal carotid artery. Good lighting and gentle retraction are critical to safe dissection at this level.

A. Nerves of oral and pharyngeal regions



B. Carotid arteries

Parotid space (bed): right lateral dissection



Right external carotid artery branches: schema

F. Netter M.D.

FIGURE 32-3 Endarterectomy for extracranial carotid artery atherosclerosis.

Carotid Bifurcation

The carotid bifurcation should be mobilized last, after the internal and external carotid arteries. The carotid bulb is actually the first portion of the internal carotid artery. The tissue within the carotid bifurcation contains the ascending pharyngeal artery as well as baroreceptor nerves. It does not need to be divided in most cases, but when complete mobilization of the bifurcation is required, this tissue should be ligated rather than coagulated.

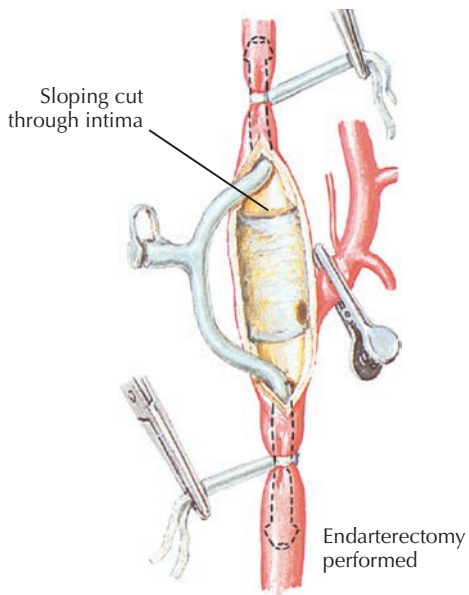
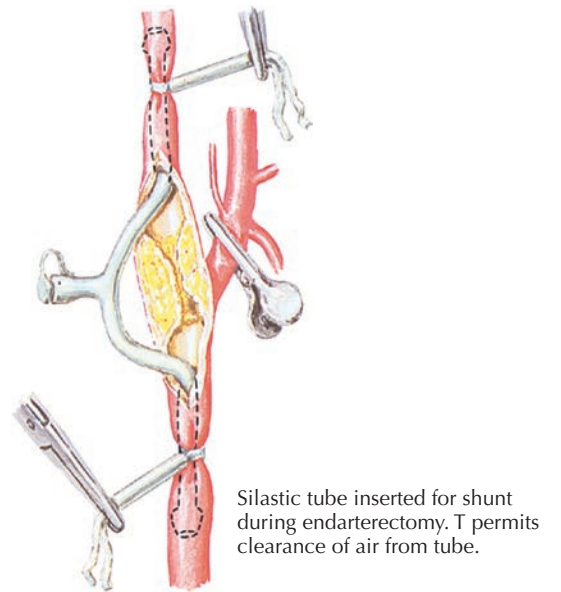
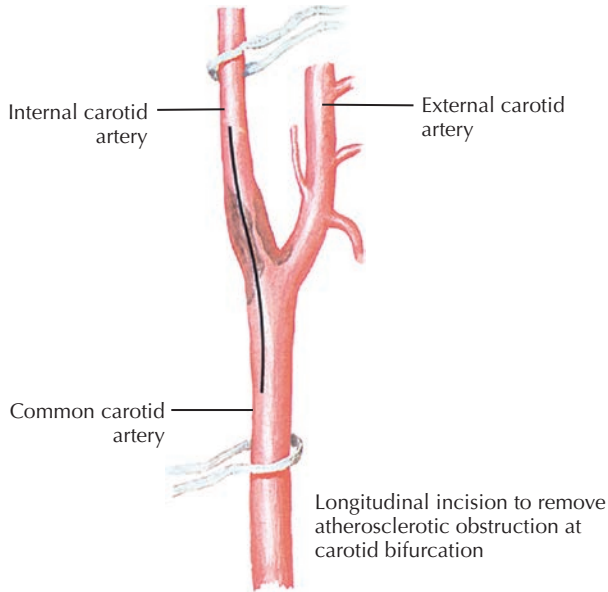
The superior laryngeal nerve runs posterior to the external carotid artery and is usually not seen, but the nerve can be injured during this portion of the exposure. Rarely and almost exclusively on the right side, the recurrent laryngeal nerve arises from the vagus nerve at the level of the bifurcation and runs directly to the larynx (nonrecurrent recurrent laryngeal nerve). Therefore, no nerves posterior to the carotid vessels should be divided.

Extremely gentle dissection of the bifurcation is important to prevent dislodgement and downstream embolization of material from underlying atherosclerotic plaque. When completed, this dissection should permit gentle lifting of the vessels toward the surface of the wound and greatly ease shunt insertion when necessary (Fig. 32-4).

ARTERIOTOMY AND CLOSURE

The arteriotomy should begin in the distal common carotid artery and extend through the carotid bulb, avoiding the flow divider, and extend far enough distally to allow visualization of the distal extent of the plaque. The arteriotomy should be closed with a patch, preferably vein or bovine pericardium.

After completion of the endarterectomy and achieving hemostasis, closure is straightforward. The deep cervical fascia does not need to be closed, although many surgeons choose to do so. The platysma layer should be reapproximated, followed by the skin. If necessary, drains should be placed within the carotid sheath and brought out through a separate site posterior and inferior to the incision (Fig. 32-4).



F. Netter M.D.

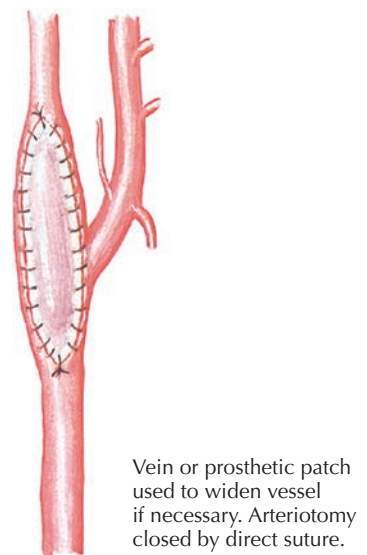


FIGURE 32-4 Nerves and carotid arteries.

SUGGESTED READINGS

- Lord RSA, Raj TB, Saryl DL, et al. Comparison of saphenous vein patch, polytetrafluoroethylene patch and direct arteriotomy closure after carotid endarterectomy: postoperative result. *J Vasc Surg* 1989;9:521-9.
- Roseborough GS, Perler BA. Carotid artery disease: endarterectomy. In Cronenwett J, Johnston KW, editors. *Rutherford's vascular surgery*, 7th ed. Philadelphia: Saunders; 2010, pp 1443-68.
- Zarins CK, Gewertz BL. Carotid artery surgery. In: *Atlas of vascular surgery*, 2nd ed. Philadelphia: Saunders; 2005, pp 3-38.

Aortic Exposure from the Midline Abdomen



Henry R. Baele

INTRODUCTION

Aortic pathology is a common problem, and even with endovascular therapy of *abdominal aortic aneurysm* (AAA) and aortoiliac occlusive disease, open surgical reconstruction of the abdominal aorta through a midline abdominal incision is still a mainstay in the vascular surgeon's toolbox. Complex neck, juxtarenal, or suprarenal AAA may be treated with a midline abdominal approach, although the author frequently uses a retroperitoneal or low thoracoabdominal approach through the left 10th interspace.

SURGICAL PLANNING

A midline incision is usually made from the xiphoid to pubic symphysis if a juxtarenal or infrarenal AAA is being repaired. A shorter, lower midline incision ending just below the umbilicus is used if an *aortobifemoral bypass* (AF2) is being performed.

Disease of the aortoiliac arteries can manifest as aneurysmal or occlusive disease. Aneurysmal disease is mainly of the juxtarenal or infrarenal aorta and may or may not involve the common iliac arteries. The external iliac arteries are usually spared, so an extensive midline abdominal incision gives all the exposure necessary. If the disease process is occlusive, it can take multiple forms or patterns. The external iliac arteries are frequently involved or become involved over time, so an AF2 is the best surgical option. This procedure requires a smaller abdominal incision, usually ending just below the umbilicus, and two groin incisions, transverse or longitudinal, depending on surgeon preference. If there is a combination of aortic aneurysm and aortoiliac disease, a full abdominal incision (xiphoid to pubis) with groin incisions is necessary.

Although angiography was once the mainstay of preoperative planning, it has a more limited role today. A computed tomographic angiogram (CTA) with 3-mm cuts and reconstructions provides the needed information. The CTA can be supplemented with sagittal and coronal cuts and three-dimensional (3D) reconstruction. This type of CTA is also used to plan endovascular aortic repair (EVAR).

INCISIONAL ANATOMY

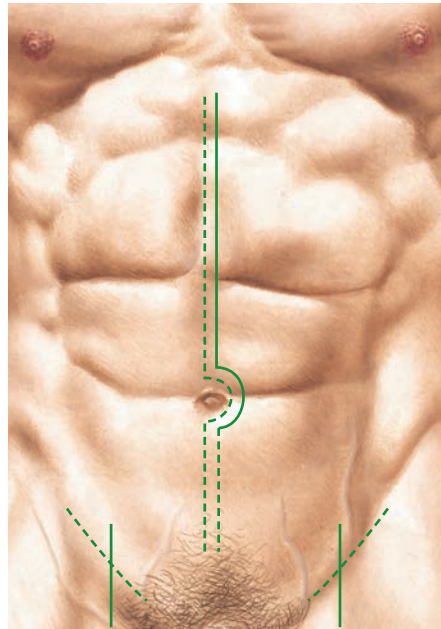
To begin the operation, the patient is placed on the operating room table in a supine position. A midline abdominal incision is made from the xiphoid process to below the umbilicus for an appropriate distance (Fig. 33-1, A). An AF2 or AAA not involving the common iliac arteries, and for which a predetermined tube graft will be performed, is sufficiently exposed with a shorter abdominal incision. If groin incisions will be used, the groin is opened first in the patient with no previous abdominal incision, with minimal difficulty predicted in exposing the abdominal aorta.

In patients with previous abdominal surgery, the author usually begins with the abdominal incision because of a higher likelihood of enterotomy during lysis of adhesions, and the groin would remain unscarred. In patients with extensive prior surgery, especially involving infection with peritonitis, a retroperitoneal or low thoracoabdominal approach may be warranted.

The choice of groin incision is also predetermined by looking at the patient and the CTA. A straightforward anastomosis to the common femoral artery or the anastomosis, including the first centimeter of superficial femoral artery or profunda femoris (deep femoral) artery, can be exposed with a transverse incision. Complexity in the groin necessitating more extensive or expansile exposure of the superficial femoral artery, or more often the profunda femoris artery, requires a longitudinal incision, the length of which can be modified to suit the situation.

A midline incision is made as illustrated in Figure 33-1. The small bowel is moved to the right and superiorly in the abdomen, and the sigmoid colon is gently retracted to the left. These maneuvers expose the midline retroperitoneum, and depending on the patient's body mass index (BMI), retroperitoneal structures can be easily identified or obscured by retroperitoneal fat (Fig. 33-1, B).

A. Incision lines



--- Transverse incision
 — Longitudinal incision

F. Netter M.D.
C. Machado M.D.

B. Exposure of the midline retroperitoneum

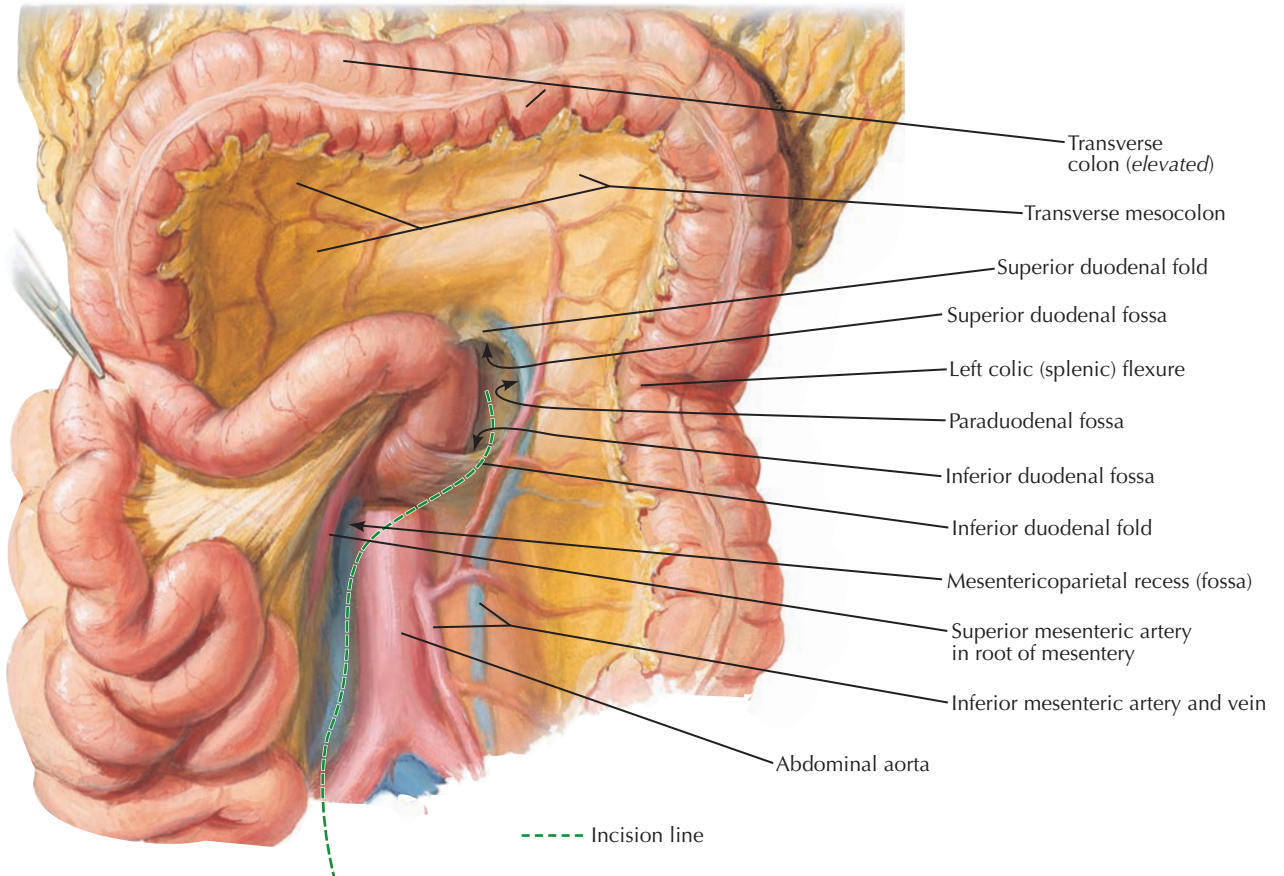


FIGURE 33-1 Abdominal incision lines and exposure of midline retroperitoneum.

ILIAC EXPOSURE

Palpation of the aortic bifurcation identifies the midline, and the author incises the pelvic retroperitoneum either in the midline or slightly to the right. This approach allows the surgeon to dissect the right common iliac bifurcation, retracting the peritoneum and its attached fat to the right. Remember that the ureter crosses the iliac vessels anteriorly and at the level of the common iliac bifurcation bilaterally (Fig. 33-2, A). Depending on the level of bypass, vessel loops can be placed around the right external and internal iliac arteries or around the distal common iliac artery, respecting the intimate relationship between the iliac arteries and veins. The most common atherosclerotic pattern demonstrates disease at the distal common iliac artery, so vessel loops around the external and internal iliac arteries are preferred. The vessels are usually soft at this location and will provide the most flexibility in constructing the anastomosis.

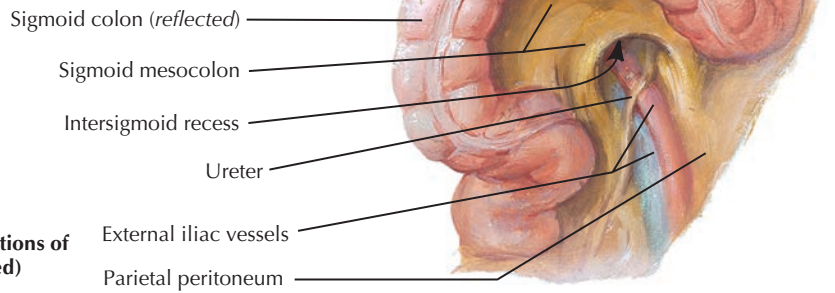
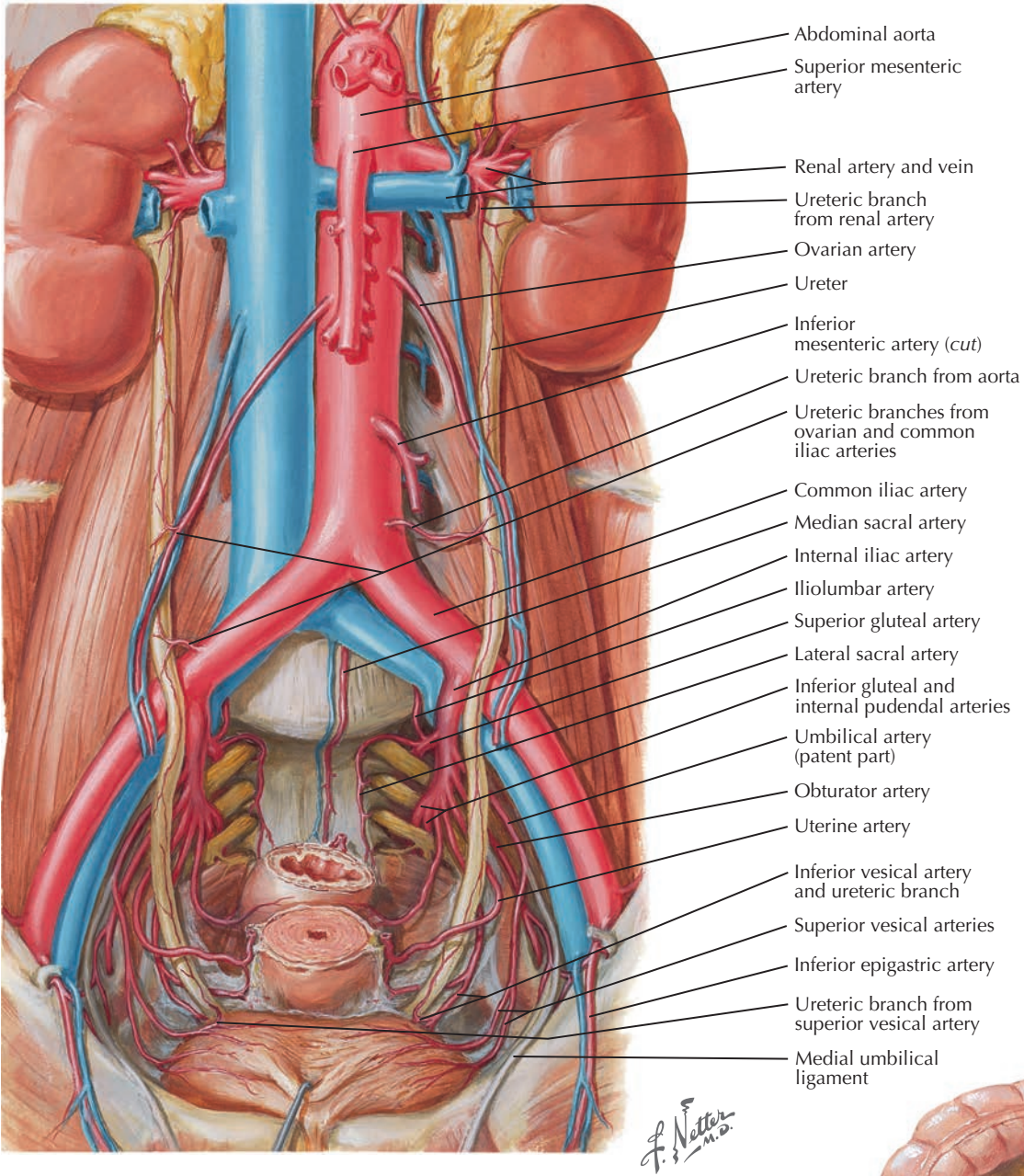
The left common iliac bifurcation reveals the same anatomic pattern of ureter anteriorly and a close relationship between the arteries and the fragile veins. Accessing the left common iliac bifurcation is more difficult because of the colonic mesentery. The author usually pulls on this mesentery to visualize the desired plane to go under. A layer of tissue that usually contains sympathetic nerves is left over the left common iliac artery, and the left iliac bifurcation is palpated. The ureter is then found, and the entire mass of tissue containing the ureter and sigmoid colon mesentery is gently retracted to dissect the bifurcation and carefully place vessel loops.

Lateral Approach

An alternate approach to the left iliac bifurcation is a lateral approach, reflecting the sigmoid colon's mesentery to the right and incising the peritoneum over the left external iliac artery (Fig. 33-2, B). This approach is helpful in patients with a large, left common iliac artery aneurysm, or if the retractors used to access the left iliac bifurcation from the medial side place too much tension on the ureter or sigmoid colon mesentery. With a larger common iliac artery aneurysm, if there is known internal iliac artery occlusion, the lateral approach could allow an end-to-end anastomosis to the left external iliac artery and thus exclude the entire aneurysm.

If there is severe calcific disease of the left common iliac artery, again the dissection could be simplified to the lateral approach, exposing the external iliac artery and developing a sub-ureteral tunnel. The common iliac artery can be ligated and an end-to-side anastomosis to the external iliac artery constructed, allowing backward flow to the left internal iliac artery and forward flow to the left leg. The anastomosis can be done in the more hospitable lateral exposure to the external iliac artery instead of the deeper area of the left iliac bifurcation. It can also be accomplished with much less traction on the sigmoid colon. This option should be considered to keep the entire operation to a single midline abdominal incision, thus avoiding a groin dissection.

A. Arteries of ureters and urinary bladder



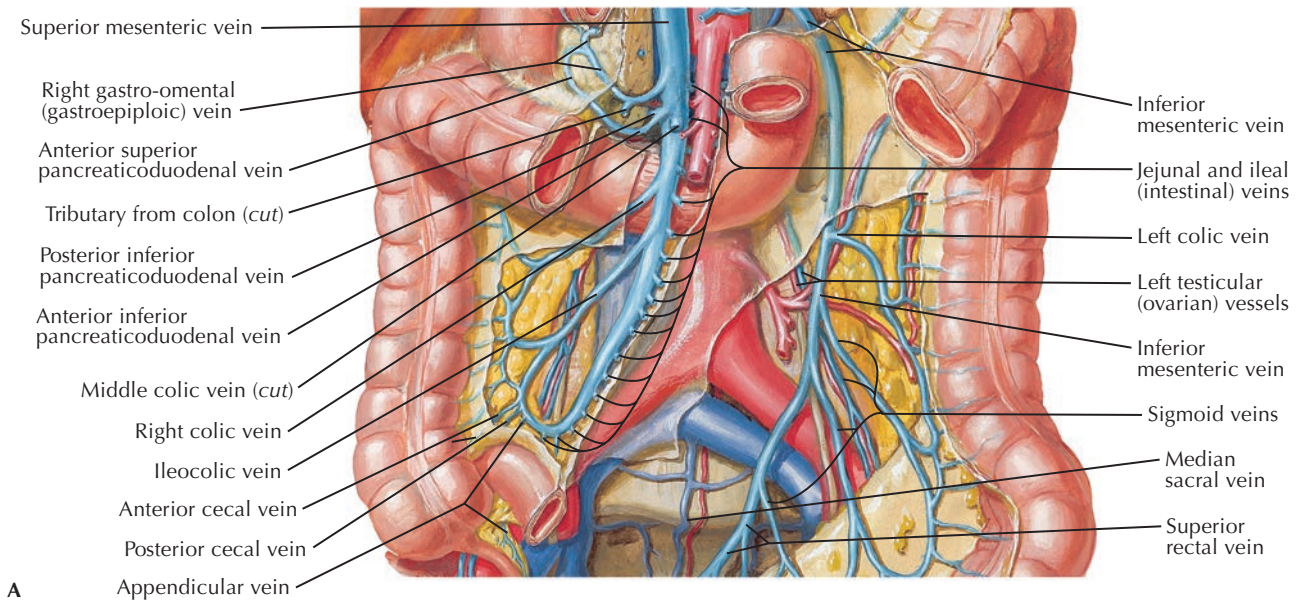
B. Mesenteric relations of intestines (reflected)

FIGURE 33-2 Aortic and iliac arterial relationships with retroperitoneal structures.

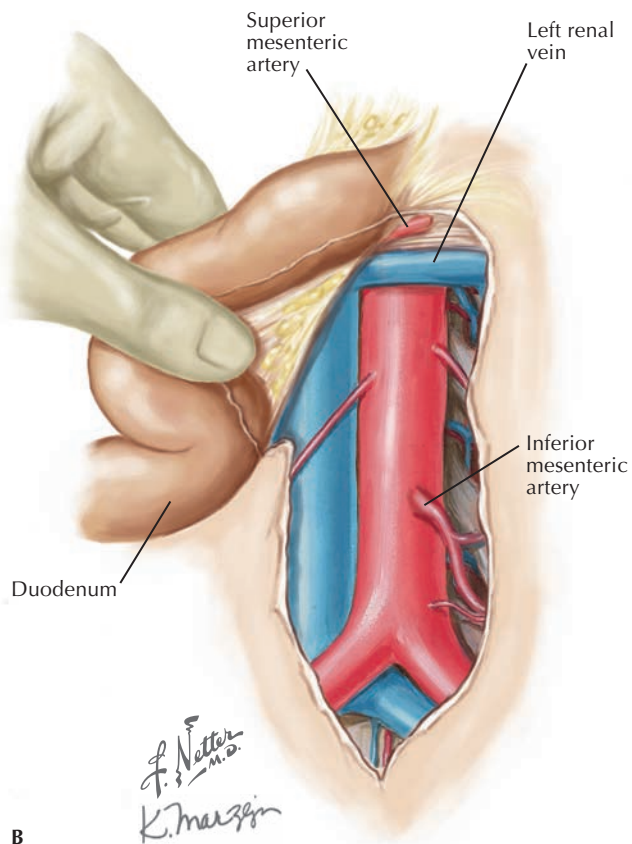
AORTIC DISSECTION

The main dissection of the aorta then proceeds (see Fig. 33-1, B). An incision is made along the right lateral border of the nonaneurysmal aorta and on the right side of an aneurysmal aorta. This approach is used to avoid injuring the inferior mesenteric artery or any collateral flow to the sigmoid colon. The duodenum comes into view, and the peritoneum is incised about 2 cm around the inferior edge of the duodenum, to access the plane under the duodenum and on the anterior surface of the aorta. The 2 cm of peritoneal cuff provides adequate tissue to close at the end of the aortic repair.

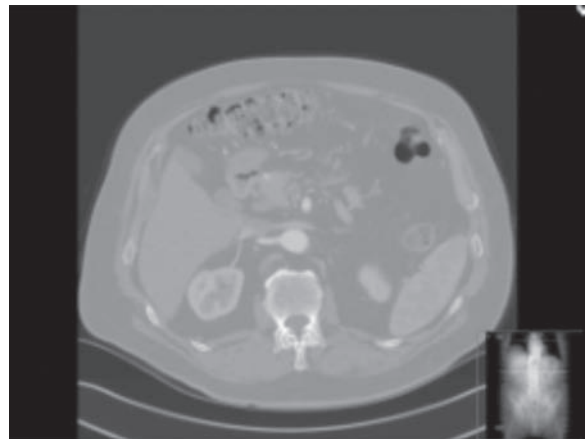
The plane on the anterior surface of the aorta is then developed, and the duodenum is retracted cephalad and slightly to the right. The inferior mesenteric vein usually can be ligated to facilitate this plan and exposure (Fig. 33-3, A). Be sure to palpate the bundle in which the inferior mesenteric vein travels; if an accompanying arch of Riolan is contributing to overall rectosigmoid blood supply, this bundle should be retracted. The goal of this dissection is to access the aorta just below the renal arteries, where a clamp should be applied for AF2 or AAA repair.



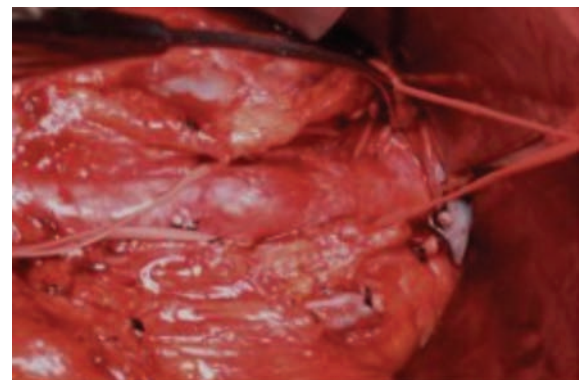
A



B



C. CT angiogram showing the usual relationship between the aorta, superior mesenteric artery, and left-to-right crossing left renal vein.



D. Infrarenal aorta in preparation for AF2. The left renal vein is seen to the right, the vena cava superiorly, and the suction device pointing to the right renal artery.

FIGURE 33-3 Aortic relationships: colon, duodenum, and left renal vein. AF2, Aortobifemoral bypass.

Renal Vasculature

The next structure seen is the left renal vein, with its left-to-right flow and its intimate relationship with the anterior surface of the aorta (Fig. 33-3, B-D). The left renal vein can be dissected free and retracted cephalad to achieve greater exposure of the aorta and renal arteries (Fig. 33-4). The left renal vein usually marks the neck of an infrarenal AAA and lies slightly caudal to the renal arteries. The aorta can be circumferentially dissected at the level of the cross-clamp.

Care should be taken not to damage lumbar vessels. These vessels originate from the posterior half of the aorta between lumbar vertebrae. Therefore, instrument or finger dissection posterior to the aorta has a clear space in the concavity of the lumbar vertebrae, between actual discs (Fig. 33-5, A). With a large AAA, there is anterior deviation or angulation of the neck, allowing less dissection and still sufficient purchase for safe, complete clamping of the aorta (Fig. 33-5, B).

If the AAA is juxtarenal, or if the aorta is occluded to the renal arteries and an AF2 is being performed, suprarenal control of the aorta is necessary. To accomplish this, the surgeon decides whether the renal vein should be retracted or divided and subsequently repaired. If the left renal vein must be cut, its adrenal, gonadal, and lumbar branches should remain intact (see Fig. 33-4). The left renal vein is then secured with large bulldog clamps 2 cm apart and cut between, leaving a cuff of 1 cm on either side to repair when the procedure is completed.

Usually the renal vein can be retracted; considerable retraction can be tolerated if the gonadal and lumbar branches are ligated and the renal vein is dissected circumferentially from the inferior vena cava (IVC) to the adrenal and suprarenal branches. Dissection of a small amount of IVC and its retraction with the left renal vein facilitate dissection of the right renal artery.

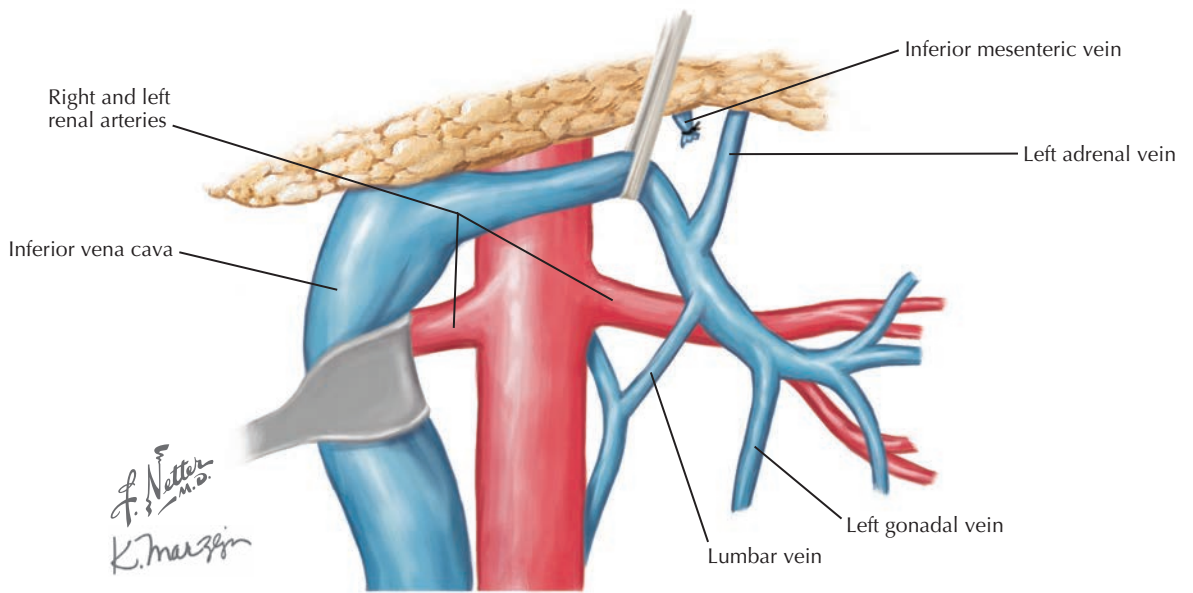
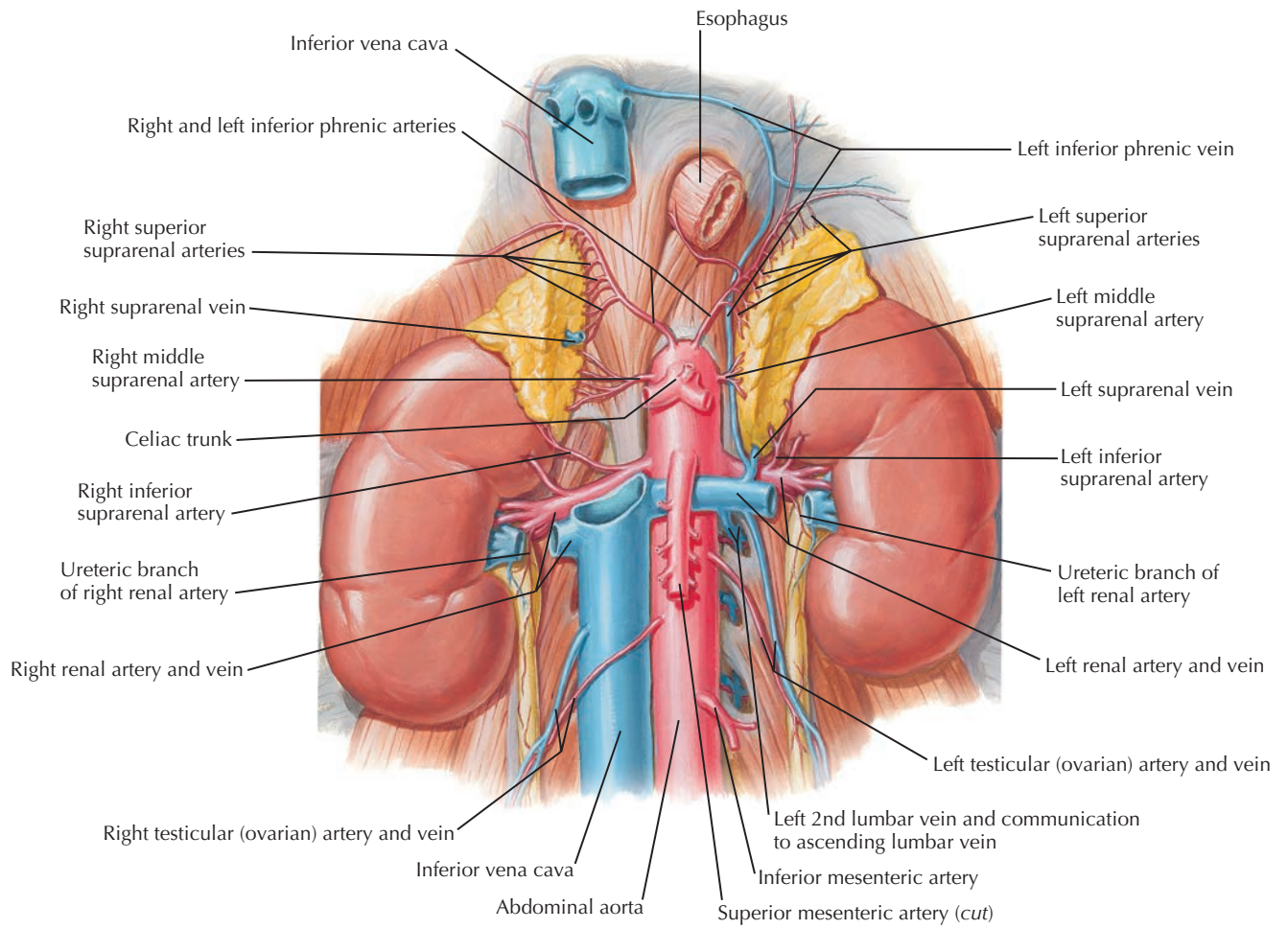


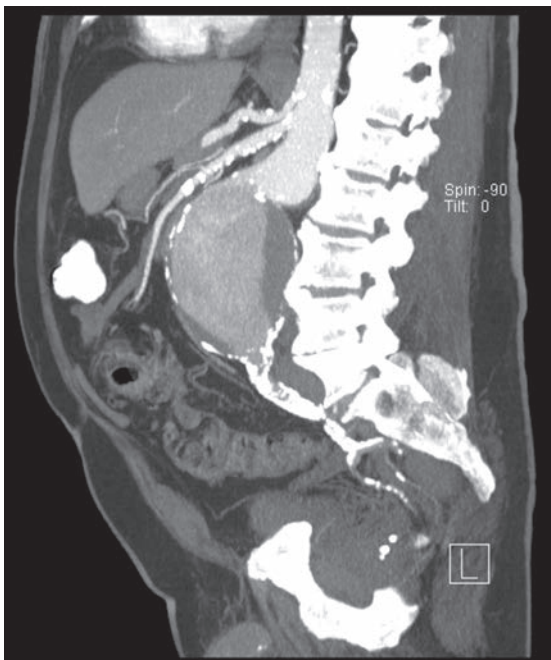
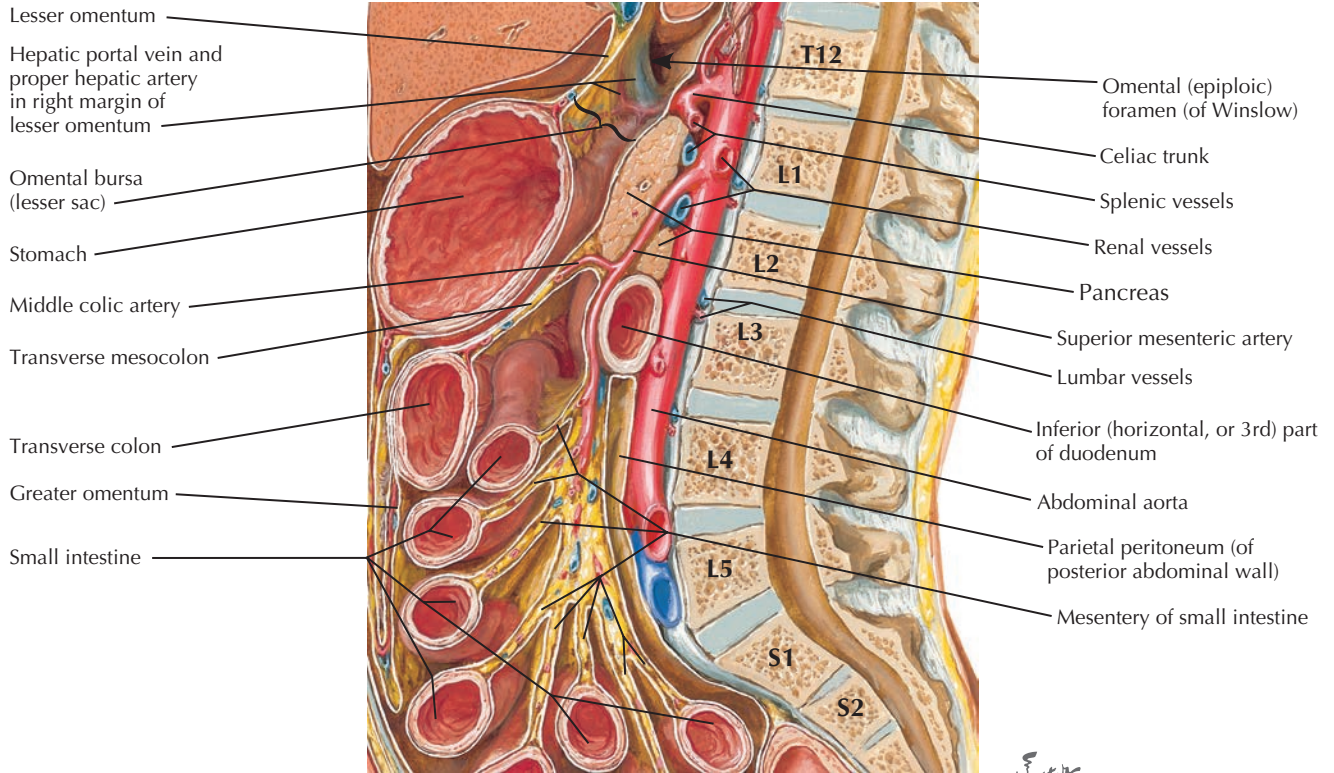
FIGURE 33-4 Aortic relationships with retroperitoneum and left renal vein.

SPECIAL CONCERNS

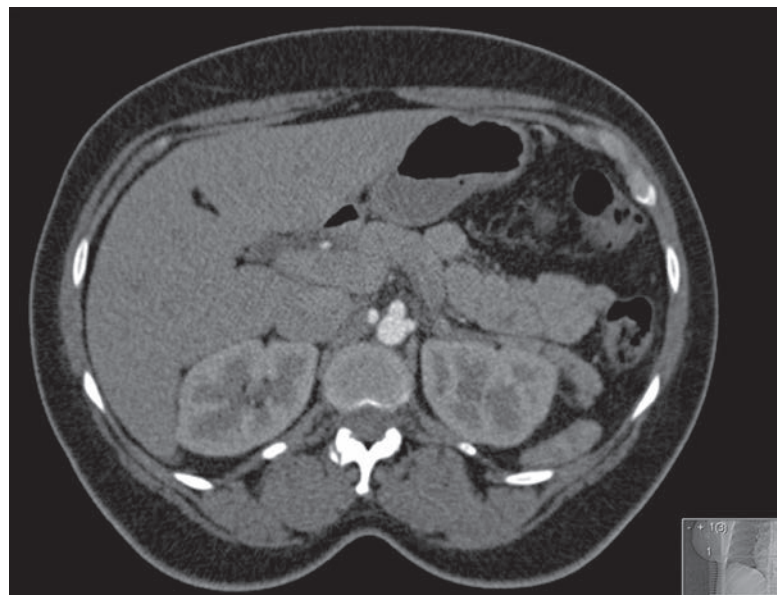
Dissection of the suprarenal aorta can then be done with finger and instrument dissection, but usually not circumferentially. The surgeon must always be cognizant of the superior mesenteric artery (SMA), and its retraction should be monitored. A space usually exists between the lateral takeoff of the renal arteries and the midline anterior origin of the SMA. The space for suprarenal clamping can vary but can be anticipated from careful inspection of the preoperative CT scan (Fig. 33-5, *B* and *C*).

Another potential area of concern or danger is variable venous anatomy. The main venous variations or anomalies are (1) left-sided or dual IVC and (2) the retroaortic left renal vein, which usually travels from lower left posterior to upper right, where it connects to the vena cava. The retroaortic left renal vein is usually not perpendicular to the aorta, as is the normal left renal vein. Again, the preoperative CT scan can demonstrate these variations.

A. Abdominal wall



B. Sagittal CT angiogram showing the angulation of the neck of a large 8-cm AAA. Also seen is an accentuated concavity in the lumbar vertebrae.



C. CT angiogram showing contrast in the aorta, renal arteries, and origin of the superior mesenteric artery. Note the proximity of these vessels. Note the unusually close proximity of these vessels in this patient.

FIGURE 33-5 Aortic relationships with lumbar spine and visceral vessels. AAA, Abdominal aortic aneurysm.

AORTOBIFEMORAL BYPASS

If an AF2 is indicated for aortoiliac occlusive disease, a shorter incision is usually made from the xiphoid to just below the umbilicus (see Fig. 33-1). The groin incisions are made transversely or horizontally depending on the complexity of the femoral reconstruction. The shorter abdominal incision is adequate because dissection of the aorta from its bifurcation to the renal arteries is the goal (see Fig. 33-3, *D*).

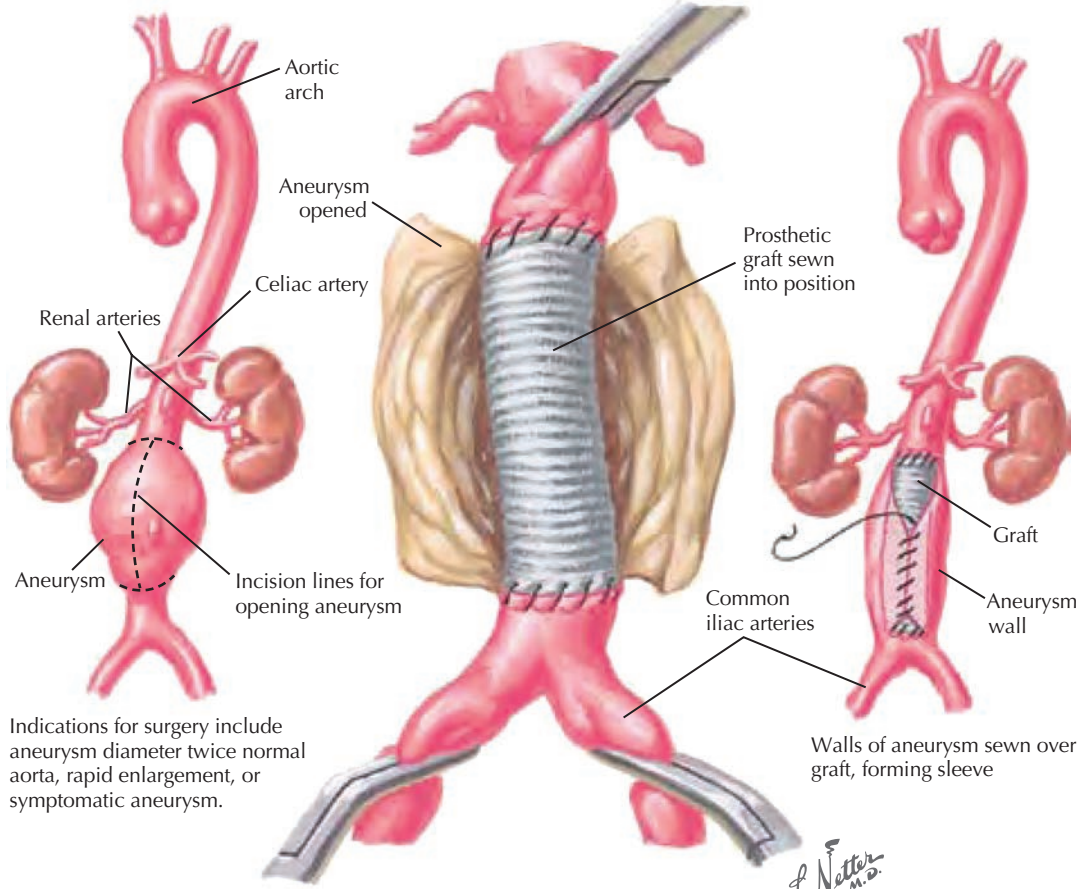
An end-to-side or end-to-end proximal anastomosis is done at the surgeon's preference. If both external iliac arteries are occluded and there is flow to at least one internal iliac artery, or if a large inferior mesenteric artery (IMA) is present, an end-to-side aortic anastomosis is preferred. A shorter abdominal incision also is preferable because the femoral limbs of the AF2 are tunneled to the groin incision. These tunnels are created on top of the iliac vessels with blind finger dissection from the groins to the aorta. An infraureteral tunnel is created to prevent stenosis or pressure on the ureter after scarring around the graft occurs. The tunnels are usually marked with an umbilical tape, and the limbs are pulled through the tunnels at the appropriate time (Fig. 33-6, *A*).

RUPTURED ABDOMINAL AORTIC ANEURYSM

The open approach to the ruptured AAA is usually the same as previously described, with a midline incision and dissection into the retroperitoneum to the right of midline, then along the duodenum, pushing it to the right. Care is maintained not to injure the duodenum or incise the retroperitoneum too far to the left, where collaterals to the sigmoid colon or the IMA may travel. The renal vein can be difficult to identify because of the hematoma and the tissue staining, making the entire retroperitoneum the same deep-maroon, purple color.

Occasionally, clamping the aorta at the diaphragmatic hiatus is necessary to gain proximal control. This technique can be an especially helpful maneuver in the trauma victim with a central hematoma (Fig. 33-6, *B*). This dissection is greatly enhanced by placing a nasogastric tube in the stomach. Usually, this maneuver is performed under less-than-ideal conditions. The left lobe of the liver is taken down, and the anterior portion of the crus of the diaphragm is incised. With the liver retracted to the right and the stomach retracted left, blunt finger dissection on both sides of the aorta allows pressure with a sponge stick or occlusion with a straight aortic clamp.

A. Abdominal aortic aneurysm (infrarenal)



Indications for surgery include aneurysm diameter twice normal aorta, rapid enlargement, or symptomatic aneurysm.

J. Netter M.D.
JOHN A. CRAIG AD

B. Esophagus and thoracic aorta

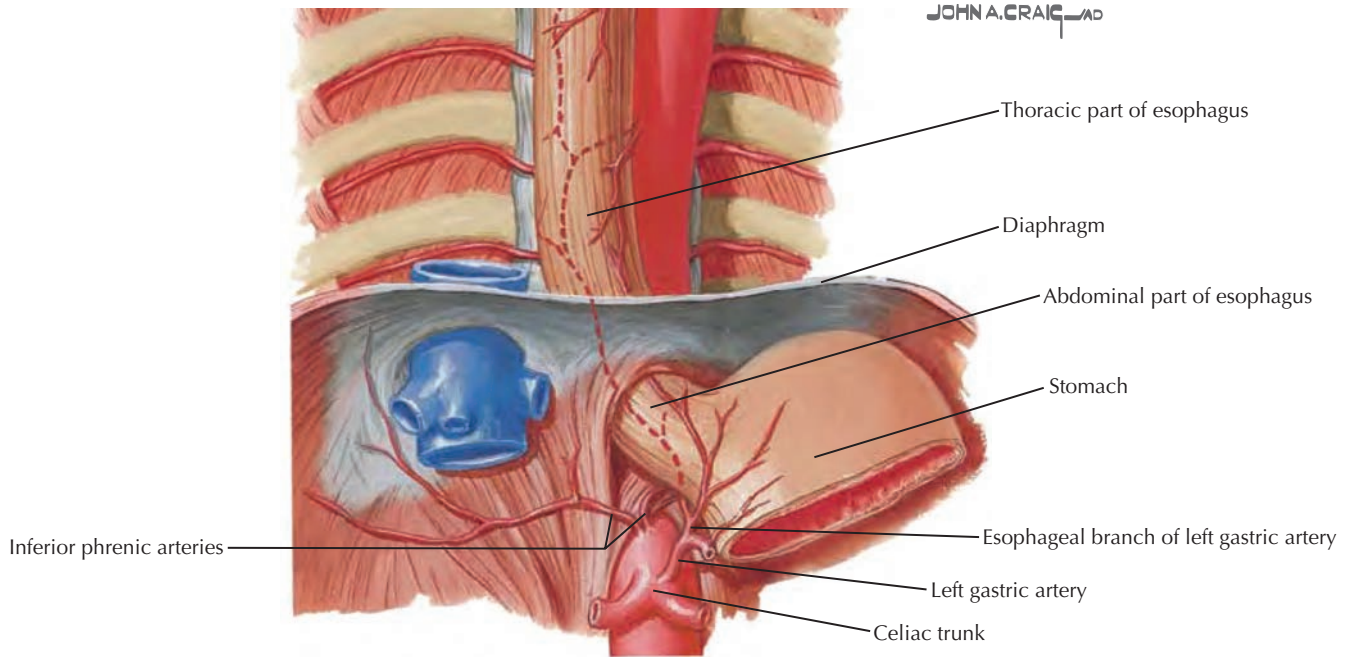


FIGURE 33-6 Abdominal aortic aneurysm and anatomy. Completion of aortic repair with tube graft and relationships of supraceliac aorta, stomach, and crus of stomach.

SUGGESTED READINGS

- Moore W, editor. *Vascular and endovascular surgery: a comprehensive review*. 7th ed. Philadelphia: Saunders-Elsevier; 2006.
- Turnipseed WD, Carr SC, Tefera G, et al. Minimal incision aortic surgery. *J Vasc Surg* 2001;34:47-53.
- Valentine RJ, Wind GG, editors. *Anatomic exposures in vascular surgery*; 2nd ed. Philadelphia: Lippincott, Williams & Wilkins; 2003.
- Wahlberg E, Olofsson P, Goldstone J; *Emergency vascular surgery: a practical guide*. Berlin: Springer; 2007. (See Chapter 7 on AAA for illustrations of supraceliac cross-clamp technique.)

Exposure of the Superior Mesenteric Artery and Celiac Axis

Matthew J. Kruse and Bruce L. Gewertz

INTRODUCTION

Unimpeded access to the aorta and its visceral branches is essential to successful surgical treatment of mesenteric ischemia. This chapter briefly addresses clinical presentations of acute and chronic mesenteric ischemia that most often require surgery and considers the various options to achieve optimal exposure.

CLINICAL PRESENTATION

Approximately half of the cases of *acute mesenteric ischemia* are caused by embolization of thrombus from cardiac pathology or arrhythmia. Patients present with the sudden, acute onset of epigastric pain not associated with rebound tenderness. The diagnosis is made by clinical correlation (e.g., history of cardiac arrhythmias) and angiographic findings of a focal arterial filling defect consistent with embolus. Radiographic findings of bowel ischemia (e.g., wall thickening, mesenteric edema) or bowel infarction (e.g., pneumatosis, portal venous gas) may be present.

The other primary cause of acute mesenteric ischemia is sudden thrombosis of one or more dominant mesenteric blood vessels. Although these patients frequently have symptoms similar to those with embolic events, prodromal symptoms such as postprandial abdominal pain (“intestinal angina”) and a history of atherosclerotic complications (peripheral vascular disease, myocardial infarction) are often elicited.

Chronic mesenteric ischemia is almost always caused by atherosclerosis of the mesenteric vessels; the classic symptoms are postprandial abdominal pain, weight loss, and food avoidance (“food fear”). The syndrome disproportionately affects women and heavy tobacco users. In most cases, two of the three major visceral vessels (celiac axis, superior and inferior mesenteric arteries) must be significantly narrowed or occluded for symptoms to occur. Arteriographic findings of multiple arterial plaques at the vessel origins confirm the diagnosis. Less common, nonatherosclerotic causes of chronic mesenteric ischemia include fibromuscular dysplasia, median arcuate ligament syndrome, and vasculitis.

The diagnosis of acute or chronic mesenteric ischemia requires both knowledge of the multiple clinical presentations and supporting findings from arterial imaging studies. Computed tomography angiography has an increasing role in diagnosis, with conventional angiography often reserved for potential therapeutic intervention such as fibrinolysis or angioplasty.

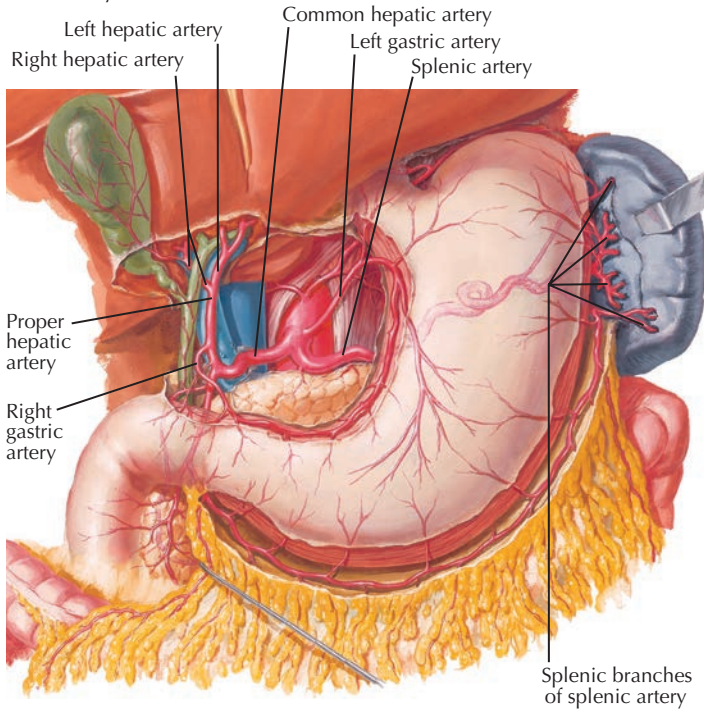
SURGICAL ANATOMY

The *celiac axis* refers to a short arterial trunk originating from the anterior surface of the proximal abdominal aorta as it passes between the diaphragmatic crura at the level of the 12th thoracic vertebra (T12). The artery divides most often into three major branches within 2 cm of its origin: the common hepatic, splenic, and left gastric arteries (Fig. 34-1, A and B). These arterial branches and their tributaries provide the blood supply for the stomach, liver, spleen, portions of the pancreas, and proximal duodenum. The common hepatic artery gives rise to the superior pancreaticoduodenal arteries, cystic artery, and right gastric artery in addition to its left and right hepatic arteries. In approximately 18% of cases, the right hepatic artery is “replaced” and originates from the superior mesenteric artery. The splenic artery gives off the dorsal pancreatic artery, left gastroepiploic artery, and short gastric arteries before completing its tortuous course toward the spleen. The left gastric artery supplies the gastric cardia and fundus before anastomosing with the right gastric artery. A “replaced” left hepatic artery originates from the left gastric artery in approximately 12% of cases.

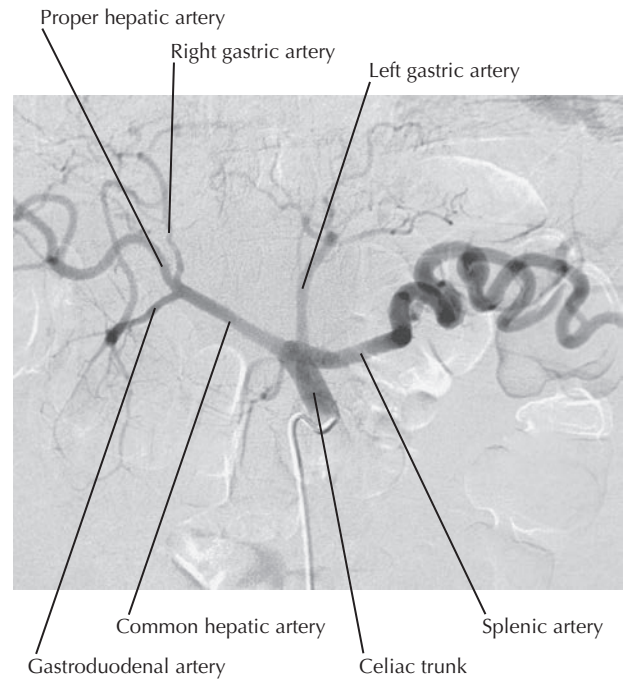
The next branch of the aorta, the superior mesenteric artery (SMA), provides the major arterial supply to the middle and distal small bowel as well as the ascending and transverse colon. The SMA is the major target artery for revascularization in patients with visceral ischemia caused by arterial insufficiency. The SMA typically arises about 1 cm distal to the celiac axis just inferior to the diaphragmatic hiatus at the level of the first lumbar vertebra (L1). It travels behind the neck of the pancreas, in front of the uncinate process and over the third portion of the duodenum. The SMA gives rise to the inferior pancreaticoduodenal artery, which anastomoses with the corresponding superior branch from the celiac circulation, and to the middle colic artery just before entering the base of mesentery of the small bowel.

Atherosclerotic pathology of the SMA most likely involves its origin, whereas emboli may lodge more distally in its course proximal or distal to the origin of the middle colic artery (Fig. 34-1, C and D).

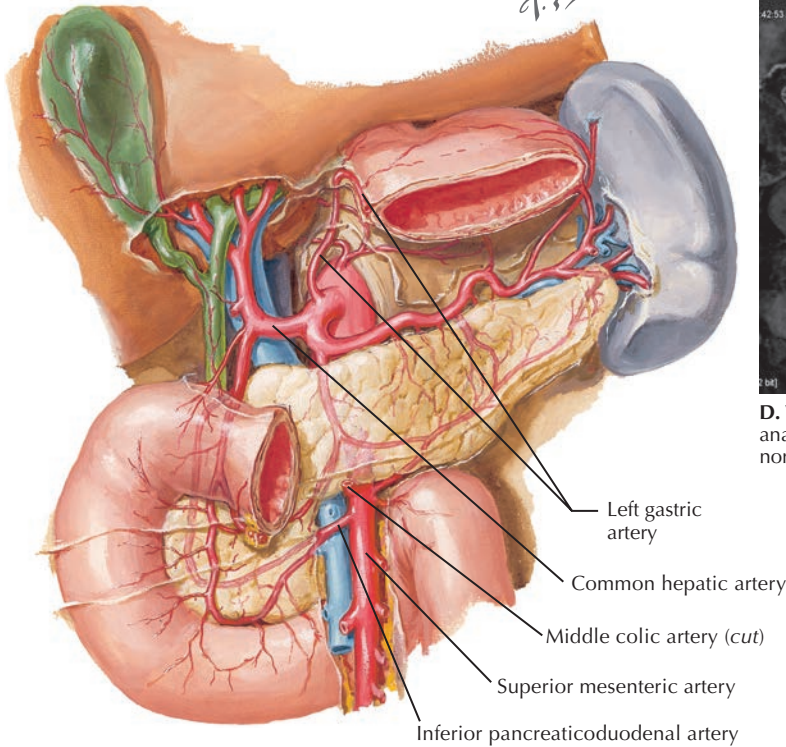
A. Anatomy of celiac axis



B. Normal celiac axis angiogram



C. Superior mesenteric artery as it courses below the inferior border of the pancreas



D. Volume rendered 3D CT angiogram demonstrating normal anatomy of the celiac axis and SMA in the sagittal view (left) and normal branching pattern of the SMA in the coronal view (right).

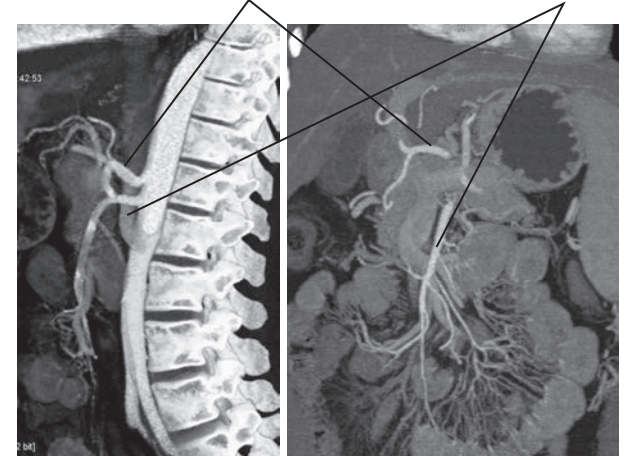


FIGURE 34-1 Celiac axis and superior mesenteric artery (SMA). (D from Horton KM, Fishman EK. Multidetector CT angiography in the diagnosis of mesenteric ischemia. *Radiol Clin North Am* 2007;45:275-88.)

SURGICAL PLANNING

The most common procedures for mesenteric ischemia are SMA embolectomy for acute embolic occlusion and antegrade and retrograde aorto-SMA bypass for atherosclerotic occlusive disease. When performing a surgical procedure for chronic mesenteric ischemia, it is generally wise to revascularize the celiac axis as well. The optimal procedure depends on the disease process, indication for operation, patient anatomy, comorbidities, and surgeon experience.

A technical goal common to all these procedures is accessing a portion of the SMA distal to the occlusion, to facilitate either the distal anastomosis of a bypass graft or the arteriotomy for introduction of balloon embolectomy catheters. Given anatomic constraints, the most accessible portions of the SMA are the origin of the vessel from the aorta and the more distal vessel within the mesentery at the inferior border of the pancreas.

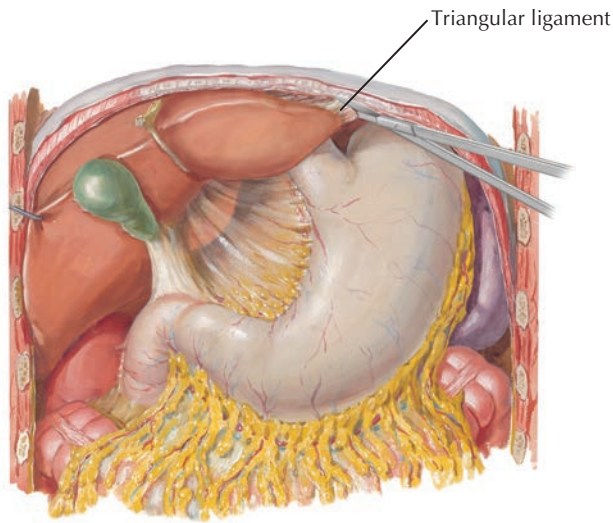
ANTERIOR TRANSPERITONEAL EXPOSURE

Anterior transperitoneal exposure is a simple and serviceable approach to the visceral vessels and aorta, although it does not afford continuous exposure of the abdominal and distal thoracic aorta unless combined with a medial visceral rotation. An upper midline incision provides adequate exposure in most patients, whereas bilateral subcostal incisions may be advantageous in patients with previous midline incisions or large abdominal girth.

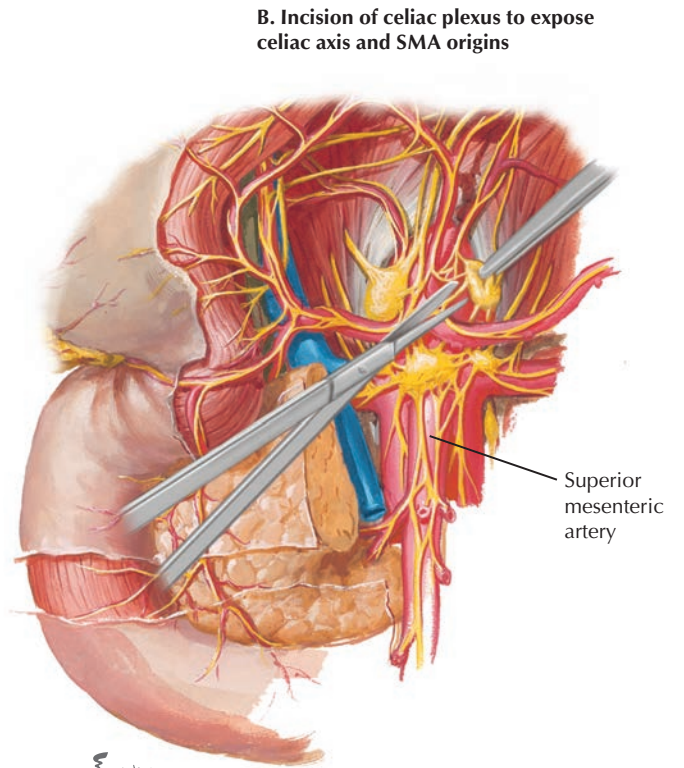
For antegrade bypass of the SMA, attention is first directed to exposing the supraceliac aorta. This portion of the aorta is often the last to be involved in patients with extensive atherosclerosis and is the preferred site of proximal anastomosis for a bypass graft. The esophagus and lesser curvature of the stomach are identified and retracted to the patient's left after division of the gastrohepatic ligament. The triangular ligament of the left lobe of the liver is divided (Fig. 34-2, A), and the left lateral segment of the liver is gently retracted to the right.

Care is taken to avoid excessive force when using self-retaining retraction systems, to prevent damage to liver parenchyma as the left lobe is folded toward the right. The right crus of the diaphragm is divided by electrocautery and the underlying median arcuate ligament incised, often through dense lymphatic and neural tissue. The posterior peritoneum may then be incised and the supraceliac aorta visualized and evaluated for its suitability for proximal anastomosis. Dissection in an inferior direction will expose the origin of the celiac axis and its primary branches. If the pancreas can be anteriorly retracted, the celiac origin and a limited portion of the SMA origin can be accessed (Fig. 34-2, B). If bypass to the celiac axis is planned, adequate exposure will be available for graft anastomosis to either the common hepatic artery or the cut end of the main celiac trunk.

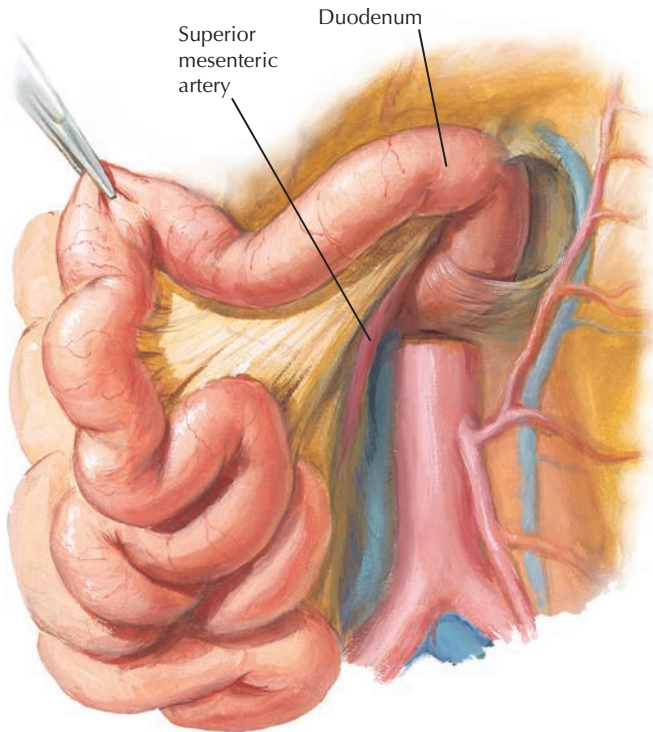
Most patients with atherosclerotic disease will require a bypass to a more distal portion of the SMA. Through the main peritoneal cavity, elevating and superiorly displacing the transverse colon allows palpation of its mesentery and identification of the middle colic artery and the SMA. The main vessel is exposed by incising the peritoneum directly above it at the root of the mesentery (Fig. 34-2, C). The vessel usually is easily identified, but care must be taken to avoid injury to parallel veins and often-sizable arterial branches. A retropancreatic tunnel is formed by blunt finger dissection to allow passage of a graft from the supraceliac aorta to the exposed portion of the SMA (Fig. 34-2, D).



A. Incision of the triangular ligament of the liver, which will be greatly retracted to the right in preparation for supraceliac aortic exposure

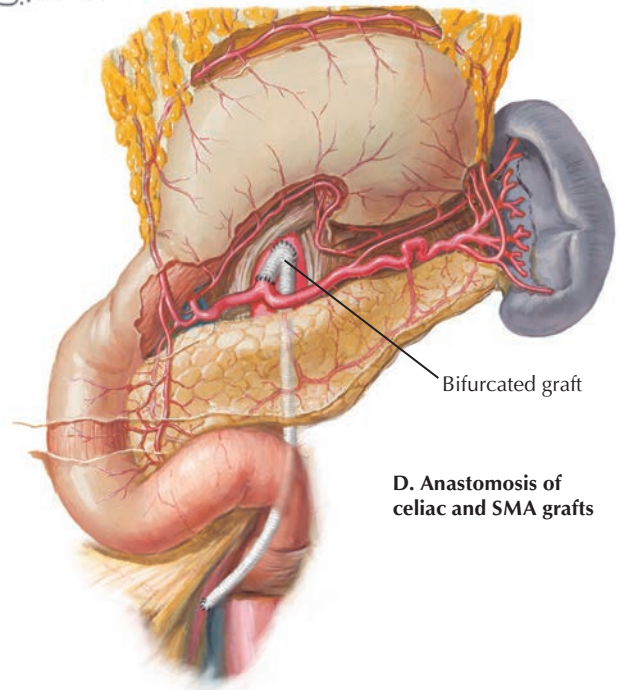


B. Incision of celiac plexus to expose celiac axis and SMA origins



C. Incision at base of small bowel mesentery to expose SMA distal to location of vascular compromise

*F. Netter M.D.
K. Marzari*



D. Anastomosis of celiac and SMA grafts

FIGURE 34-2 Anterior transperitoneal exposures and configuration of graft. SMA, Superior mesenteric artery.

ANTERIOR TRANSPERITONEAL EXPOSURE—Cont'd

The SMA may also be approached from a right lateral direction by mobilization of the 4th portion of the duodenum and incision of the ligament of Treitz. Alternatively, the SMA can be located in the lesser sac by incising the gastrocolic ligament, although the exposure is limited distally.

If a retrograde bypass is planned, the infrarenal aorta or left iliac arteries are exposed directly by either retracting the duodenum to the right and incising the retroperitoneum or medially reflecting the left colon. The vessel least involved with atherosclerosis is selected as the originating anastomotic site for a bypass graft, to be directed in a gradual curved path back to the SMA. Retrograde bypass is less favored because of extensive atherosclerotic involvement of the distal aortoiliac segment and potential kinking of grafts. Specific indications for retrograde bypass include a “hostile” upper abdomen or severe heart disease, which makes supraceliac aortic occlusion undesirable.

A most useful alternative to the transcrural approach to the SMA origin is medial visceral rotation. This approach is preferred for more extensive proximal revascularization, such as transaortic endarterectomy of the celiac artery, SMA, and renal vessels or repair of suprarenal aortic aneurysms. Incising the left lateral peritoneal reflection from the diaphragm to the pelvis allows mobilization of the descending colon (Fig. 34-3, A).

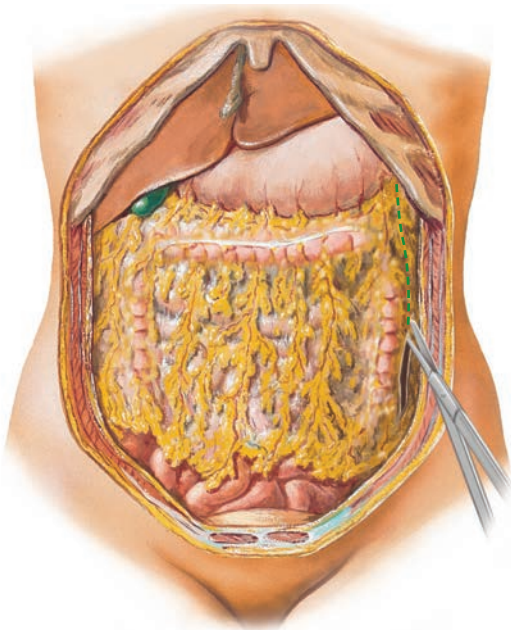
Next, the splenorenal and phrenocolic ligaments are carefully divided. With extension of the surgeon's hand under the descending colon, stomach, pancreas, and spleen, the visceral bundle is rotated anteriorly and medially. The plane of the dissection can be anterior or posterior to the left kidney (Fig. 34-3, B). The posterior approach provides continuous exposure of the visceral aorta as well as the proximal SMA and celiac axis (Fig. 34-3, C). As discussed next, rotating the patient to a lateral position with the right side down facilitates this exposure.

RETROPERITONEAL EXPOSURE

Retroperitoneal exposure to the abdominal aorta and its visceral branches is the favored approach for many vascular surgeons. In addition to affording excellent and continuous aortic exposure, the retroperitoneal route is particularly useful in patients with an ostomy or prior abdominal surgery and dense intraperitoneal adhesions. Further, retroperitoneal approaches have been associated with overall decreased perioperative morbidity and fewer respiratory complications, more rapid return of bowel function, and shorter ICU and hospital stays.

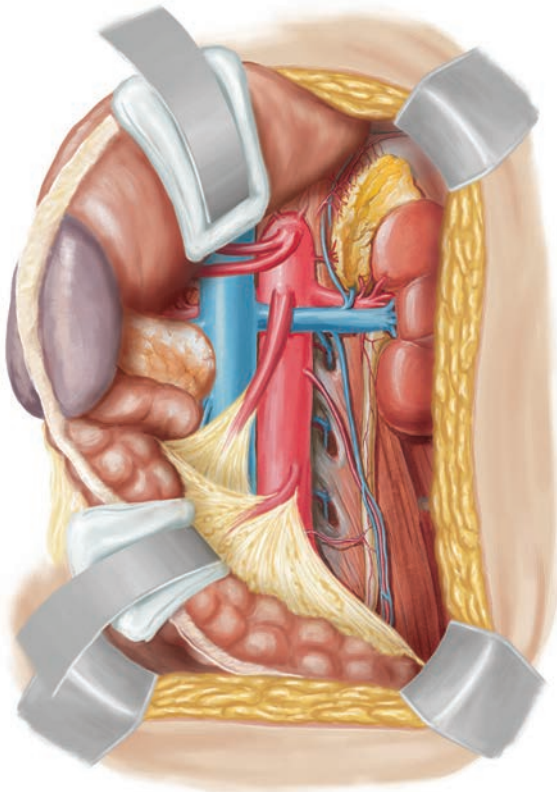
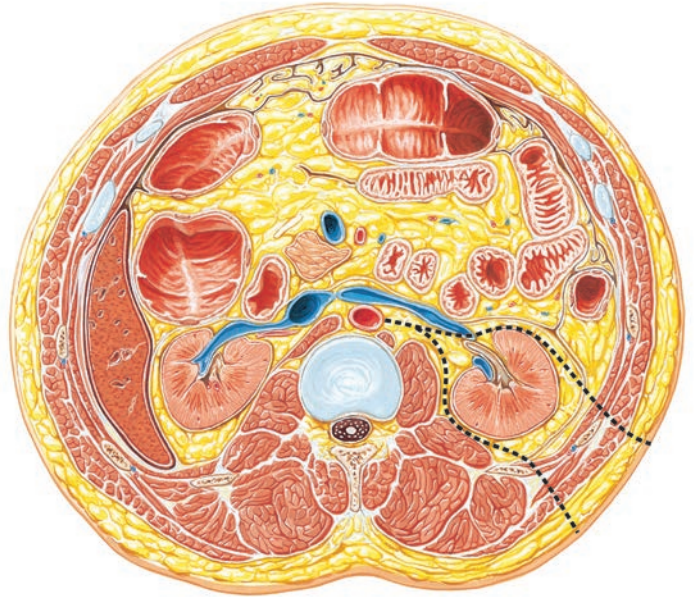
The patient is positioned with the left side up, rotated about 60 degrees from the supine position. Care is taken to position the “break” of the operating room table equidistant between the rib cage and pelvis and properly pad both the torso and the left arm, which is secured on a special arm holder and positioned crossing the chest (Fig. 34-3, D). Depending on how high an exposure is needed, the left flank incision is made along the 9th, 10th, or 11th rib. The selected rib is carefully dissected free from the intercostal neurovascular bundle on its underside. The OR table is flexed upward in its midpoint, enlarging the musculoskeletal portal. The peritoneal envelop is identified laterally and posteriorly and the dissection carried out as previously described for transperitoneal medial visceral rotation.

In patients with suspected acute ischemia, the surgeon may need to enter the peritoneal cavity at the conclusion of the procedure to assess bowel viability.

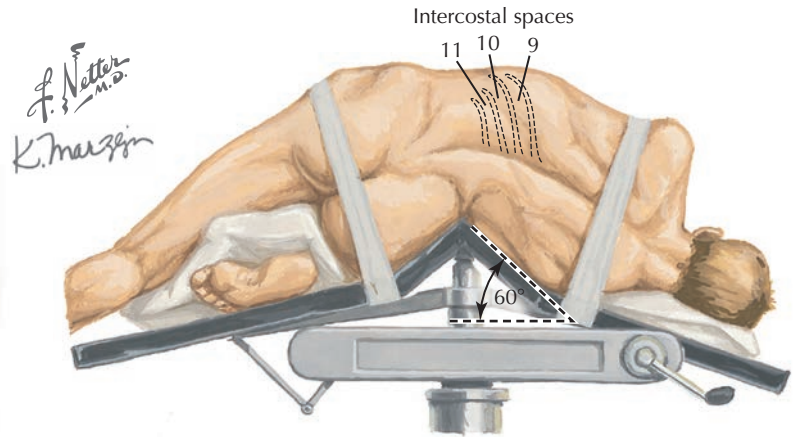


A. Incision of the left lateral peritoneal reflection

B. Planes of dissection from medial visceral rotation approach illustrating planes in front and behind left kidney



C. Transperitoneal medial visceral rotation leaving kidney in situ



D. Patient positioning for retroperitoneal approach

FIGURE 34-3 Retroperitoneal exposures through abdomen or flank.

SUGGESTED READINGS

- Klempnauer J, Grothues F, Bektas H, Pichlmayr R. Long-term results after surgery for acute mesenteric ischemia. *Surgery*. 1997 Mar;121(3):239-43.
- Moawad J, McKinsey J, Wyble CW. Current results of surgical therapy for chronic mesenteric ischemia. *Arch Surg* 1997;132:613-46.
- Schlidt SA, Desai TR, Gewertz BL. Anatomy and physiology of the mesenteric circulation. In Gewertz BL, editor. *Surgery of the aorta and its branches*. Philadelphia: Saunders; 2000, pp 329-34.

Upper Extremity Arteriovenous Access for Hemodialysis

Virginia Wong

INTRODUCTION

Establishment and maintenance of functional permanent arteriovenous (AV) access for hemodialysis remain a significant challenge for patients with chronic renal failure and their physicians. Early referral for surgical evaluation and access creation can reduce the need for temporary catheter access and improve patient outcomes. Attention to detail and commitment to principles of site preservation and long-term results are also important factors for success.

PREOPERATIVE EVALUATION

History, physical examination, vein mapping by duplex ultrasound, and in some cases venography play a role in establishing the surgical approach to AV access in a particular patient. In general, use of the nondominant upper extremity is preferred. Patients with advanced chronic kidney disease should be instructed to “save” an arm, avoiding venipuncture or peripheral intravenous (IV) placement, to preserve surface vein integrity for future creation of an *arteriovenous fistula* (AVF) or as outflow for an *arteriovenous graft* (AVG). AVF is preferred over AVG because of the lower risk of infection, lower rate of subsequent intervention for patency, and overall longevity.

However, AVFs require significantly more time to dilate and mature (weeks to months) before they are suitable for cannulation. Furthermore, a significant percentage of AVFs created may never mature sufficiently for use. This fact must be taken into account when selecting the best approach for an individual patient. Most algorithms direct surgeons to use more anatomically distal sites first (e.g., wrist fistula before arm fistula, forearm graft before brachioaxillary graft). This principle preserves proximal venous outflow for future AVF or AVG, if needed. In addition, establishment of distal AV flow can dilate the arm veins, preparing these for use as an AVF in the future.

Technical Considerations

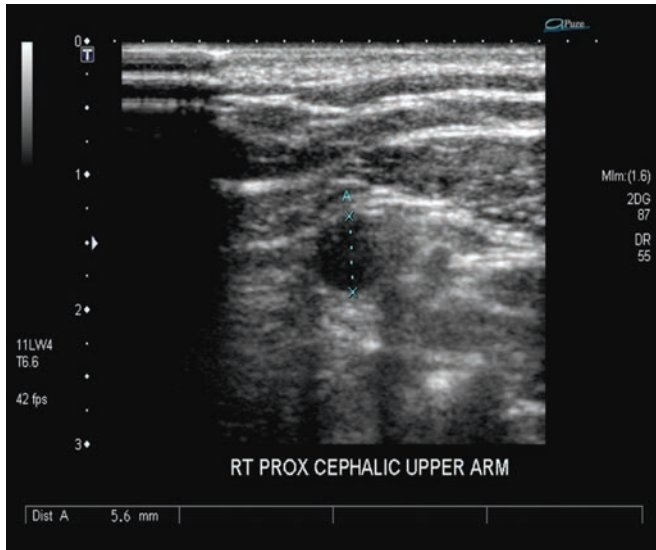
The hemodialysis patient population, often advanced in age, suffers from serious systemic disease and multiple comorbidities. Tissues are often fragile, arteries may be calcified or diseased, and surgical wounds may heal slowly or poorly. Therefore, meticulous technique, use of fine instruments, and gentle tissue handling are essential to avoid complications. Care must be taken to avoid cautery or retraction trauma to nearby sensorimotor nerves. Minimizing vessel manipulation can reduce vasospasm of artery or vein.

End-to-side or side-to-side AV anastomosis may be performed, depending on the ability to mobilize the vein in question and the need to preserve multiple (retrograde) venous outflow paths. Surface venous anatomy varies considerably, particularly near the antecubital fossa; adjustment in placement of the skin incision or use of draining venous side branches may be necessary. Anastomosis diameter, relative to size of inflow artery and outflow vein, may be a factor in achieving adequate arterial inflow for fistula dilation or in the development of “arterial steal” from the hand circulation. Subcutaneous tunneling of prosthetic graft material must be deep enough to allow puncture site sealing, but not so deep to be undetectable for cannulation. Attention to hemostasis and layered coverage of underlying vascular anastomosis or prosthetic graft material will protect against wound complications and graft infection.

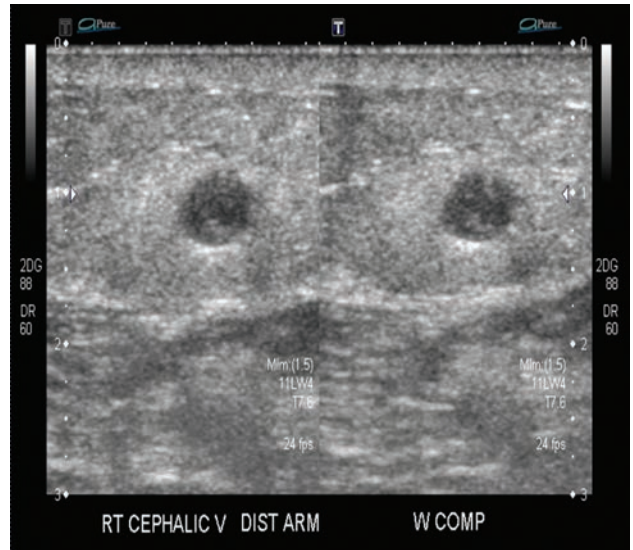
Preoperative Vessel Mapping by Duplex Ultrasound

Standard vessel-mapping protocols provide important information regarding approach to the best AVF or AVG location. Cephalic vein diameter is shown in [Figure 35-1, A](#). Venous fibrosis, identified by thickened vein walls or incomplete compressibility, may predict poor distensibility with arterial inflow. Thrombosis from venipuncture or IV placement is shown in gray-scale imaging ([Fig. 35-1, B](#)). The basilic vein often lies deep and medial in the arm and will need superficialization if used for AVF ([Fig. 35-1, C](#)). A small or heavily calcified radial artery at the wrist, a common finding in diabetic patients, may contraindicate use of this artery for inflow ([Fig. 35-1, D](#)).

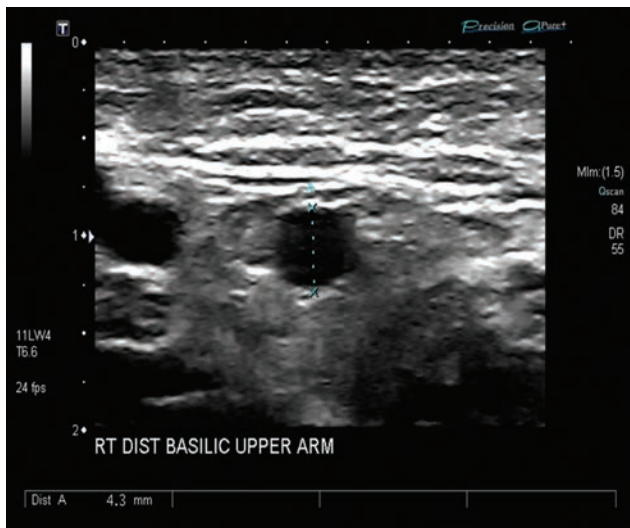
A. Calipers placed along a perpendicular line between opposite edges of the vessel generate a vessel diameter measurement, shown at lower right of the frame.



B. Cephalic vein thrombosis, identified by echogenic material filling the venous lumen on gray scale imaging (left panel). With compression, lack of venous wall apposition confirms the diagnosis (right panel).



C. Right basilic vein, lying medial to the brachial neurovascular bundle.



D. Small (< 2 mm diameter) radial artery at the distal forearm may provide unsuitable arterial inflow for AVF.

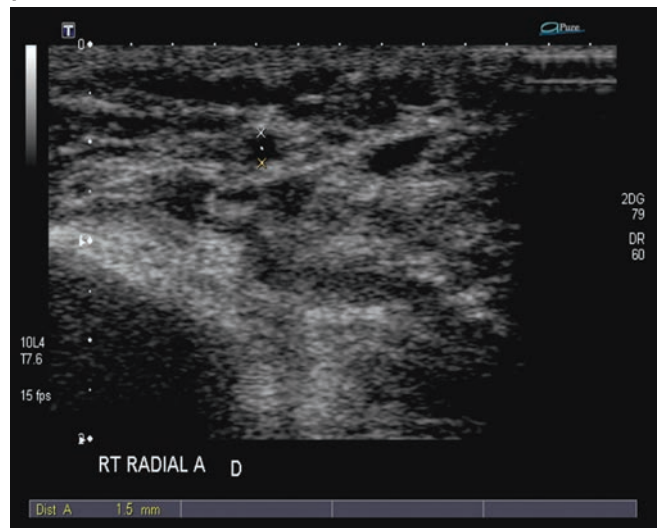


FIGURE 35-1 Preoperative duplex ultrasound vein mapping. AVF, Arteriovenous fistula.

ARTERIOVENOUS FISTULAS

Radiocephalic Fistula

The approach for radiocephalic AVF is through a longitudinal skin incision along the antero-lateral distal forearm that allows exposure of both the cephalic vein and the radial artery proximal to the flexor retinaculum. The superficial branch of the radial nerve, a small sensory branch, is often identified in the surgical field; excessive traction or transection may cause annoying numbness along the posterior thumb or lateral dorsum of the hand (Fig. 35-2, A; see also later Fig. 35-4).

After dilation and maturation, fistula cannulation takes place on the dorsolateral forearm.

Brachiocephalic Fistula

The approach for brachiocephalic AVF is through a transverse or curvilinear skin incision at or just distal to the antecubital crease, where cephalic vein is close to the distal brachial artery (Fig. 35-2, B). The cephalic vein must be mobilized sufficiently to deliver it medially and into the deeper plane, where the brachial artery resides. Radial artery takeoff is variable and may occur anywhere between axillary artery and brachial artery terminus. A smaller-caliber artery encountered in the more superficial incision may represent radial artery variation. In this case, clamping of brachial artery will not diminish radial artery pulsation at the wrist.

Toward the brachial artery terminus, the large median nerve diverges medially but may still be encountered close to the artery at this level. This important sensorimotor nerve should be preserved. Interruption of smaller sensory nerves, such as branches of lateral or medial antebrachial cutaneous nerves, may result in annoying numbness over lateral or medial forearm, respectively (see Fig. 35-4).

Once mature, cannulation of brachiocephalic AVF takes place on the anterior arm.

Brachiobasilic Fistula

For brachiobasilic AVF, transposition of the basilic vein to a more superficial and anterior location is generally required for comfortable arm position during cannulation and to prevent inadvertent puncture of the adjacent (and pulsatile) brachial artery in thin patients. The basilic vein, often inaccessible with venipuncture, is sometimes the obvious choice in patients without suitable cephalic or median cubital veins. Skin incision for anastomosis is sited medially at, above, or below the antecubital crease, depending on basilic and antecubital surface venous anatomy. Curved extension of the incision onto the medial arm may be helpful.

During same-stage transposition, the incision is extended cephalad on the medial arm, or skip incisions are used, to mobilize and harvest the basilic vein up to its entry into the axillary vein. Side branches are divided between ligatures. Branches of the medial antebrachial cutaneous nerve are often entwined around the basilic vein, making superficialization impossible without dividing one or the other. To avoid annoying numbness over the medial forearm, the vein must be divided and then anastomosed to itself after delivering it from under the nerve branch.

For two-stage transposition, AV anastomosis is performed at the first operation through a limited skin incision, followed several weeks later by harvest and superficialization of arterialized basilic vein. Cannulation of the mature and superficialized fistula takes place on the anteromedial arm.

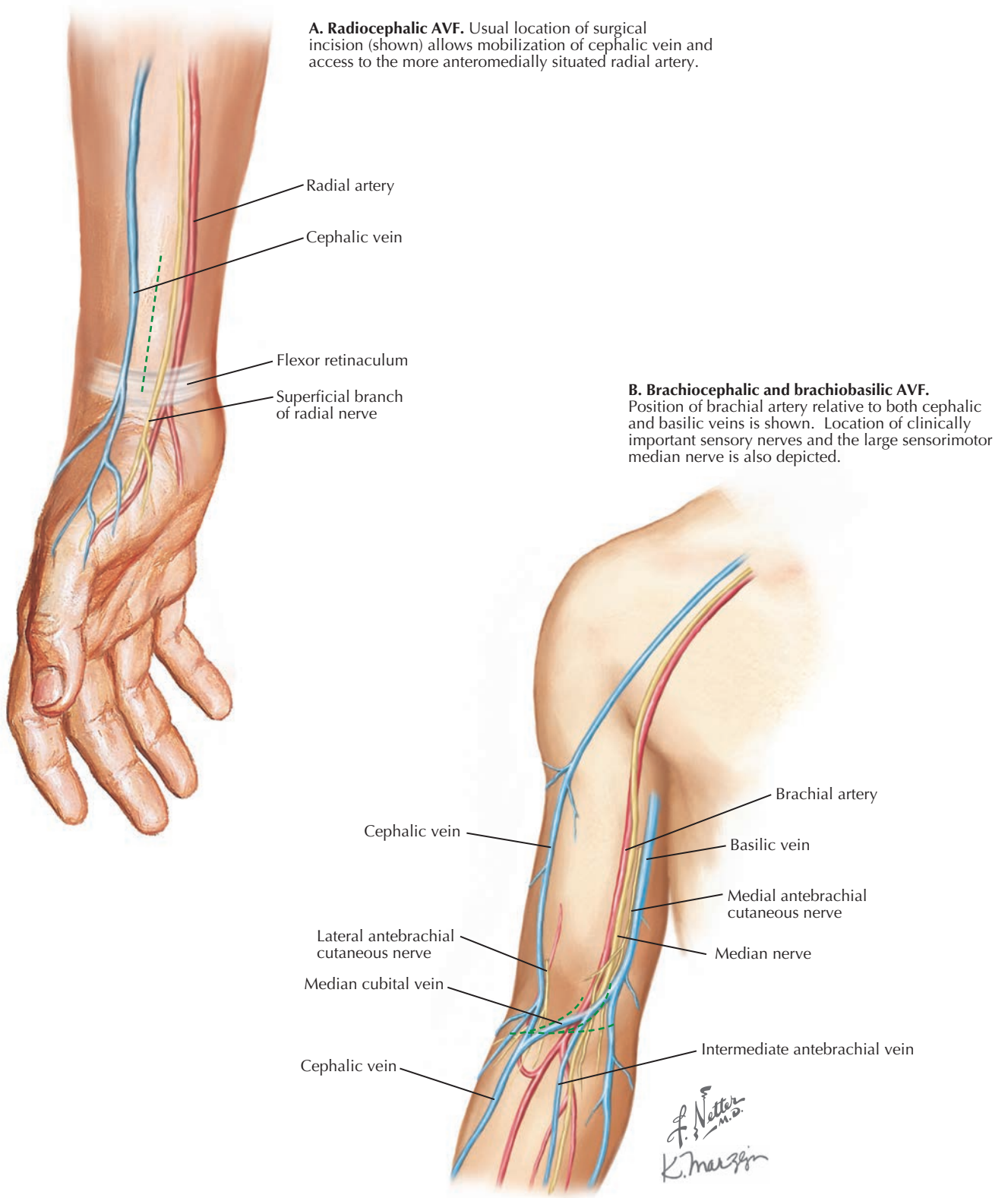


FIGURE 35-2 Radiocephalic, brachiocephalic, and brachio basilic arteriovenous fistulas.

PROSTHETIC ARTERIOVENOUS GRAFT

Forearm Looped Graft

This common configuration places a loop of prosthetic material between arterial and venous circulations. The forearm looped approach is by transverse or longitudinal skin incision in the proximal forearm, just below the antecubital crease (Fig. 35-3). This approach allows exposure of both the inflow artery, usually the brachial artery terminus or proximal radial artery, and an outflow vein, either median cubital or median cephalic/basilic, depending on anatomy. If no antecubital surface vein is suitable, a deep brachial vein may be accessible through the same exposure.

Prosthetic graft, usually expanded (porous) polytetrafluoroethylene (ePTFE), is passed through a shallow subdermal tunnel and looped over the anterior forearm. A small counterincision just distal to the apex aids graft placement. Leaving enough subcutaneous tissue for layered closure of this counterincision will minimize risk of prosthetic exposure, should the skin incision break down.

By convention, the venous (return) limb is sited laterally on the forearm. If a medial outflow vein is selected, graft limbs may be crossed over one another proximally. Maintaining the expected subcutaneous configuration will avoid misidentification of graft limbs during cannulation. Construction of the venous anastomosis over venous side branches and bifurcations helps maximize outflow and may develop arm veins for use as a future AVF.

Attention to hemostasis and careful layered closure over prosthetic material may reduce risk of graft exposure and infection. Prosthetic AVG do not require time to dilate and may be cannulated as soon as tissue incorporation occurs. Any perigraft edema or ecchymosis should be allowed to resolve. Most AVGs are usable 7 to 14 days after implantation.

Brachioaxillary Graft

The brachioaxillary approach is used when more distal options have been exhausted, or when distal arterial or venous anatomy is not adequate to support AV flow. Arterial inflow is from the distal brachial artery, exposed through a longitudinal skin incision in the medial arm, above antecubital crease.

The *median nerve* is closely associated with the brachial artery at this level, usually encountered first on opening the neurovascular sheath. Great care must be taken with use of cautery and retraction. Mobilization of the large, motor median nerve will allow gentle vessel loop retraction posteriorly, to expose the brachial artery fully. The axillary vein is exposed through a second skin incision, placed at the base of the hair-bearing area. A longitudinal incision allows extension if significant venous branching dictates additional exposure in either direction. The axillary vein is fairly superficial and will be encountered before reaching the axillary artery.

Prosthetic graft, usually ePTFE, is passed through a shallow subdermal tunnel created between the two incisions, arching laterally onto the anterior arm, in a C configuration. Although most of the graft must be shallow enough for cannulation, tunneling the anastomotic ends more subcutaneously allows layered closure of the incisions and reduces the risk of prosthetic exposure, should the skin incision break down. Time to AVG cannulation is as described earlier.

Prosthetic arteriovenous graft (AVG).
Common configurations for both forearm looped
AVG and brachioaxillary AVG are shown.

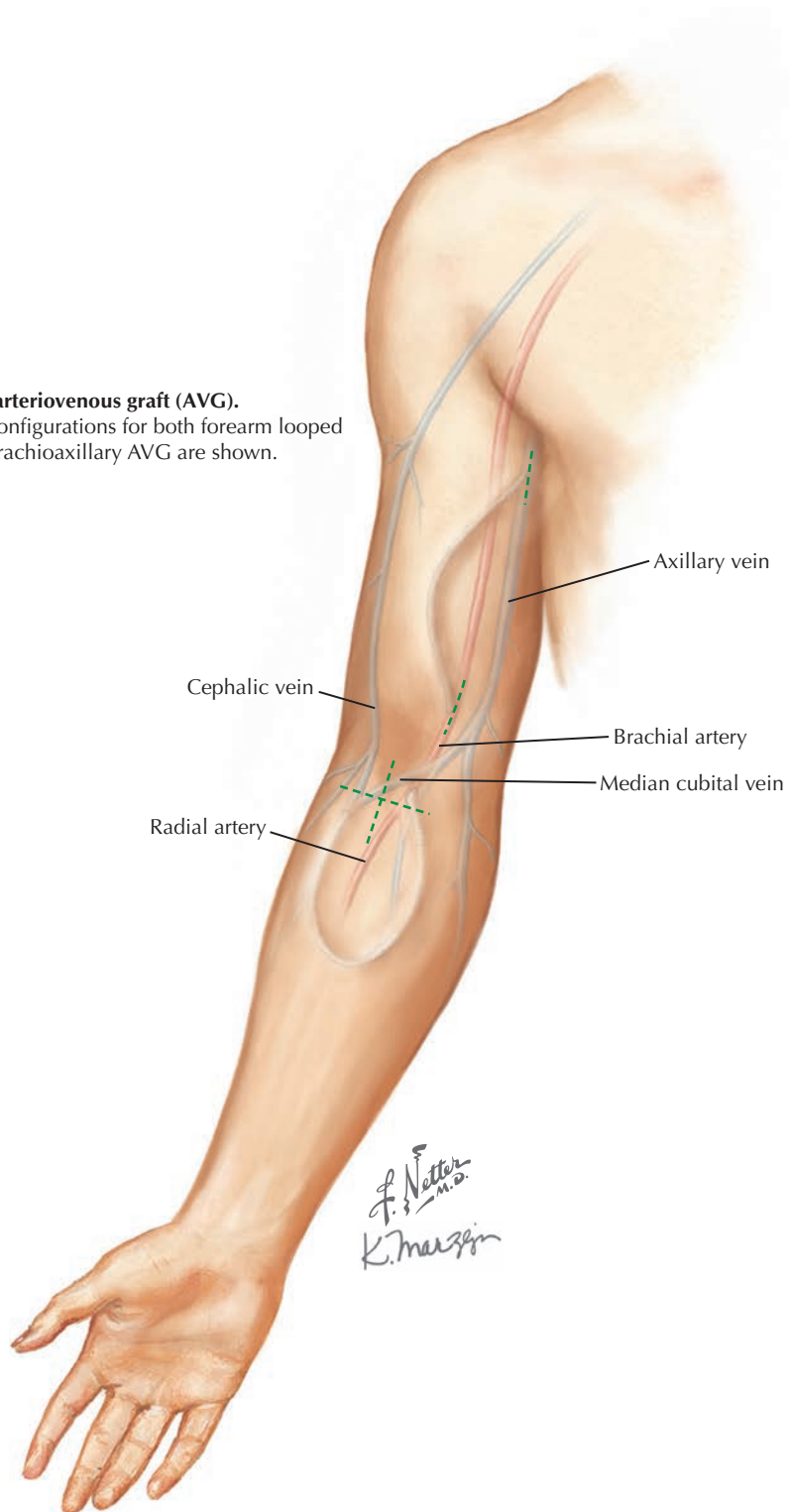


FIGURE 35-3 Prosthetic arteriovenous graft.

CUTANEOUS INNERVATION OF UPPER LIMB

Annoying sensory deficits can be caused by cautery or retraction trauma or by division of smaller nerve branches. The superficial branch of the radial nerve, encountered during radiocephalic AVF exposure, affects the area over the dorsal hand and thumb. Lateral and medial antebrachial cutaneous nerves, encountered during distal brachial exposure, affect forearm areas colored green and purple, respectively, in [Figure 35-4](#).

Again, the median nerve, likely the only major motor nerve encountered during these procedures, is closely associated with the brachial artery and must be protected from injury to avoid motor and sensory loss at the wrist, lateral hand, and fingers.

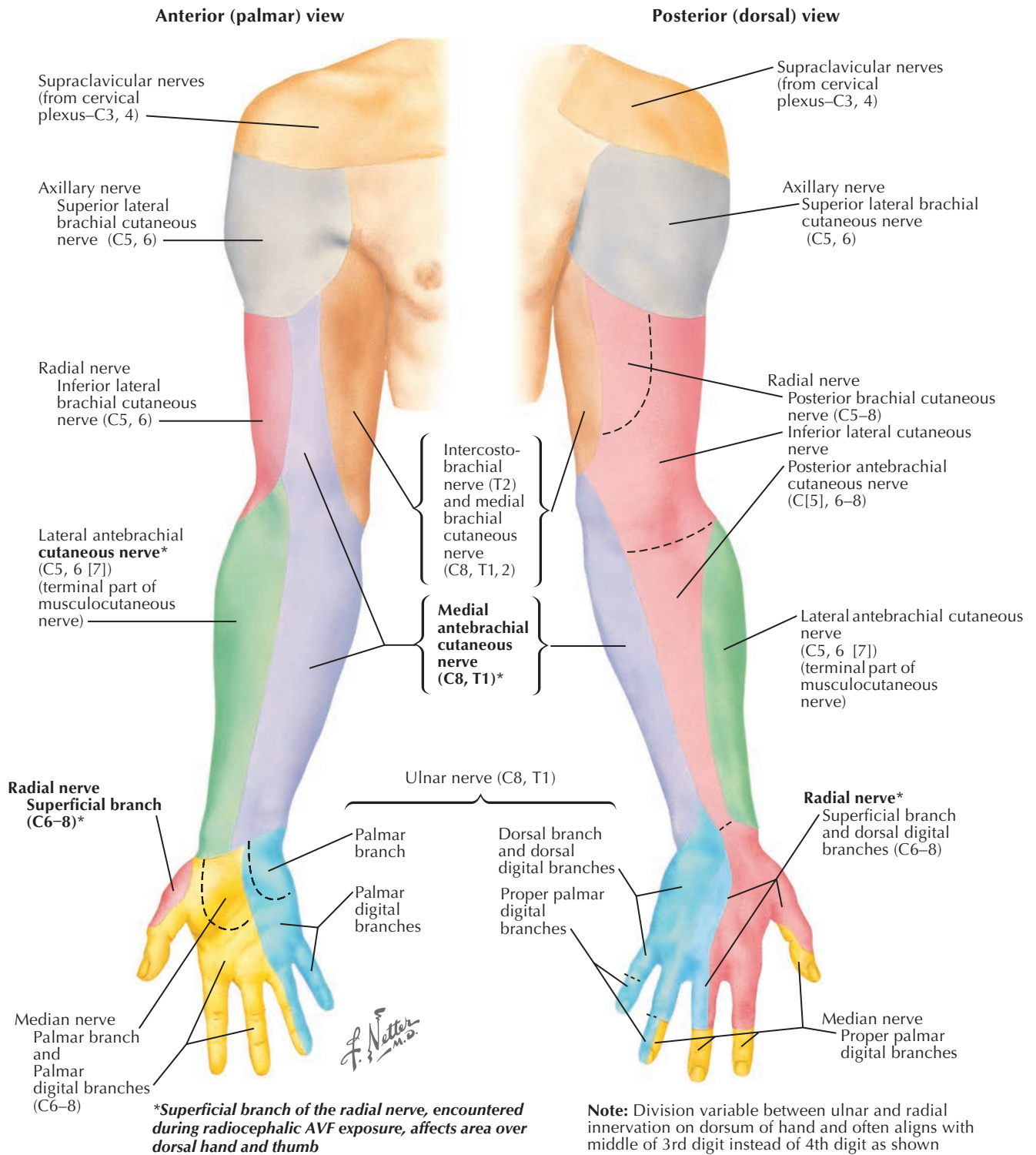


FIGURE 35-4 Cutaneous innervation of upper limb. AVF, Arteriovenous fistula.

SUGGESTED READINGS

National Kidney Foundation. KDOQI clinical practice guidelines and clinical practice recommendations for 2006 update: vascular access. *Am J Kidney Dis* 2006;48(Suppl 1): S176-276.

Scher LA, Vesely TM. Hemodialysis access: perspectives for current clinical practice. *Semin Vasc Surg* 2007;20(3).

Davidson I. On call in . . . vascular access: surgical and radiologic procedures. Austin, Texas: Landes Bioscience; 1996.

Saphenofemoral Exposure



Victor M. Sandoval, Matthew T. Allemang, and Vikram S. Kashyap

INTRODUCTION

This chapter discusses the significance of groin anatomy for both open surgical exposure and percutaneous vascular access. Within the groin area are the femoral artery, femoral vein, and femoral nerve. The two main branches of the common femoral artery are the superficial femoral and profunda femoris arteries. The venous tributary of significance is the great saphenous vein, which joins the femoral vein in the fossa ovalis; this area is also called the *saphenofemoral venous junction*. Multiple venous branches are also present in this area. Vascular exposure is necessary for multiple procedures, including endarterectomy, embolectomy, bypass, and endovascular repair of aneurysms.

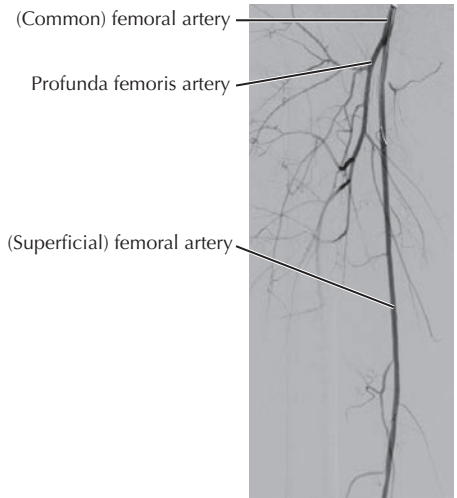
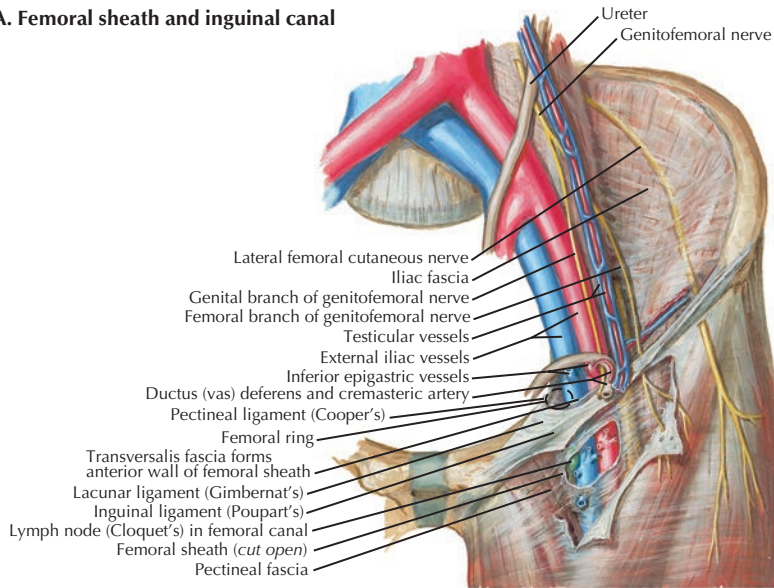
FEMORAL ANATOMY

The femoral artery is an extension of the external iliac artery and by convention begins at the inguinal ligament. The first segment of the femoral artery and the femoral vein are enclosed within the femoral sheath and separated by a fiber septum (Fig. 36-1, A). The *femoral sheath* is a dense, fibrous band primarily consisting of two layers of fascia; the posterior aspect is a continuation of the fascia covering the pectineus muscle, and the anterior aspect is an extension of the transversalis fascia.

The iliac artery travels along the medial portion of the psoas muscle, then traverses the femoral triangle as the femoral artery. Moving laterally to medially within the femoral triangle are the femoral nerve, femoral artery, femoral vein, and the lymphatic tissue (NAVEL). The boundaries of the triangle are made up of the inguinal ligament superiorly, the sartorius muscle laterally, and the adductor longus medially. The roof of the triangle is composed of skin, Camper's fascia, the inguinal lymph nodes, and the fascia lata.

As the femoral artery moves obliquely over the pectineus muscle, it divides into two branches, the profunda femoris and superficial femoral (Fig. 36-1, B). The superficial femoral artery exits the femoral triangle into the subsartorial (Hunter's) canal, crosses above the adductor longus muscle, and runs beneath the sartorius muscle (Fig. 36-1, C). As it moves distally, the superficial femoral artery decreases in caliber, eventually forming the popliteal artery.

A. Femoral sheath and inguinal canal



B. Digital subtraction angiogram of the (common) femoral, profunda femoris, and (superficial) femoral arteries of the thigh

C. Muscles of thigh: anterior view

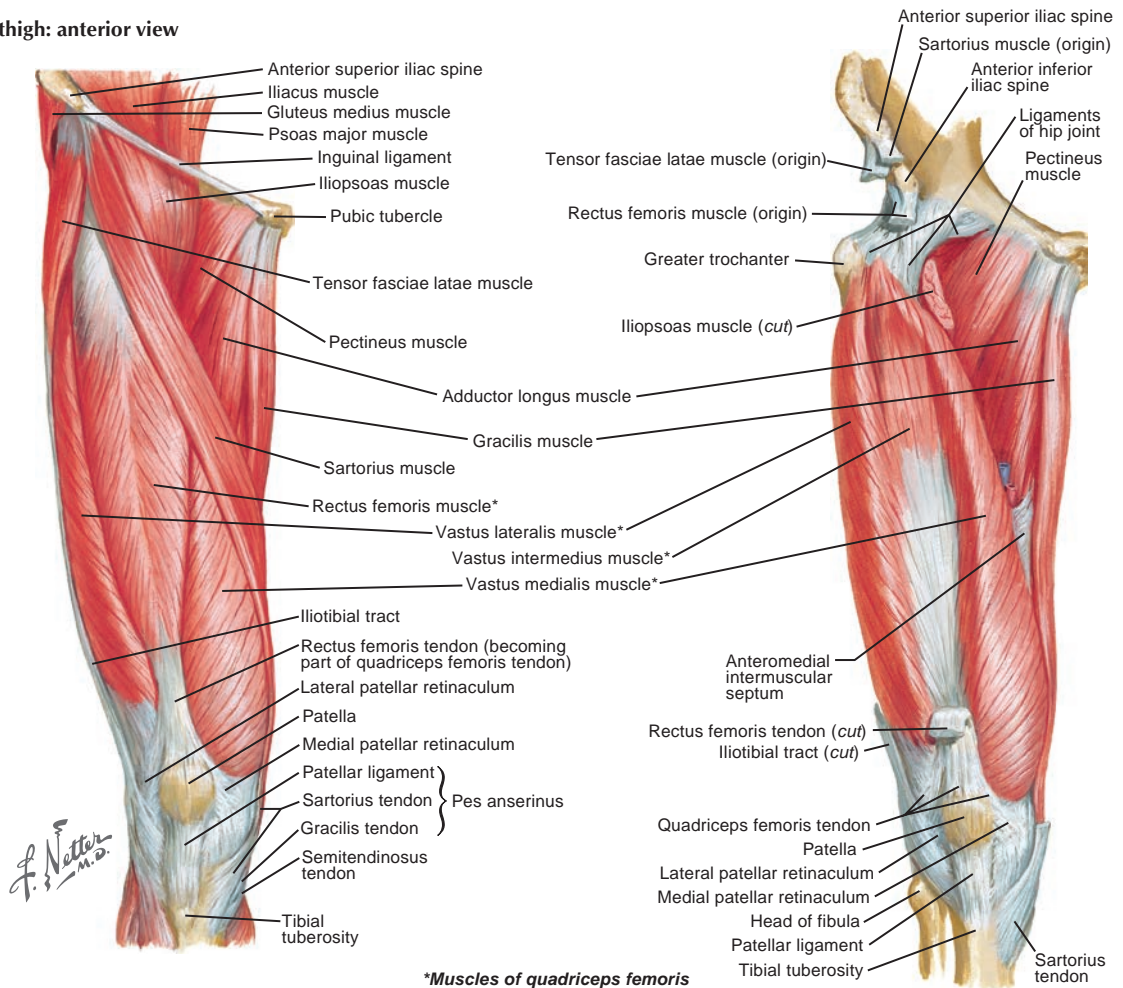


FIGURE 36-1 Femoral canal and inguinal anatomy with digital subtraction angiogram.

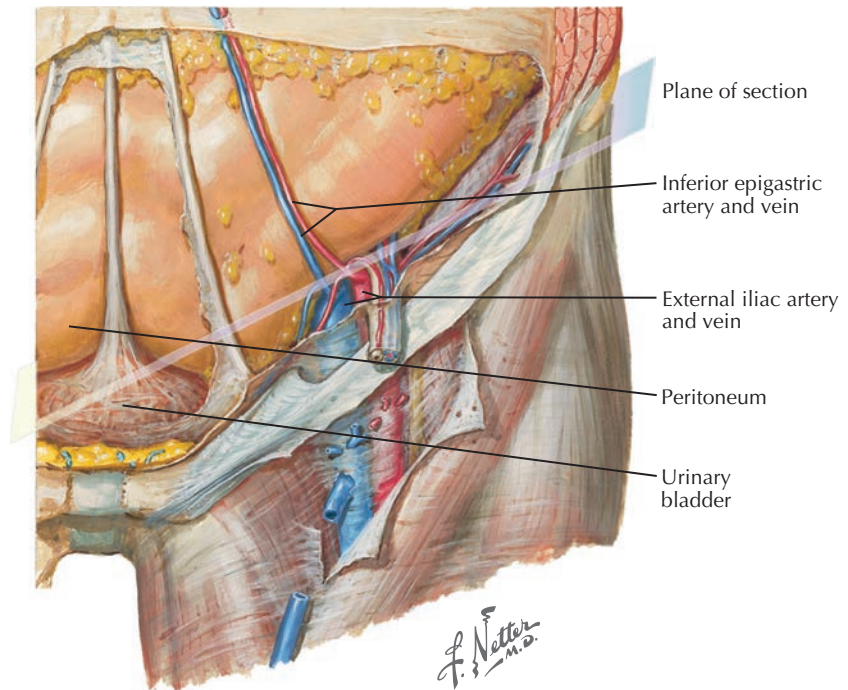
EXPOSURE OF FEMORAL ARTERY

The most common approach allowing complete exposure of the common femoral artery and its branches is the *vertical incision*. The incision starts approximately at the midpoint of the inguinal ligament (Fig. 36-2, A). The patient is placed in the supine position. Location of the femoral pulse will guide the incision. Starting the incision directly over the pulse, 2 to 3 cm above the inguinal ligament, the surgeon continues the incision 4 to 8 cm distally toward the tip of the femoral triangle. In some cases, the patient's pulse may not be palpable because of extensive calcification. If no pulse can be palpated, anatomic landmarks are identified: the pubic tubercle and anterior iliac spine (Fig. 36-2, B). The incision should be made at the midpoint between these two structures.

As the dissection deepens into the subcutaneous tissue, several small arteries (e.g., superficial epigastric, circumflex iliac) are encountered; these can be retracted or occasionally ligated and divided. Multiple lymph nodes and lymphatic channels lie within the path of dissection and should also be ligated and divided to avoid postoperative leak or lymphocele. Dissection is then continued through the fascia lata, exposing the medial margin of the sartorius muscle. With lateral retraction of the sartorius, the anterior lamella of the femoral sheath can be opened longitudinally with scissors or forceps to expose the femoral artery (Fig. 36-2, A). The lateral circumflex vein crosses over the origin of the profunda femoris and can be divided for adequate exposure of this artery.

An *oblique incision* is used where limited exposure of the femoral vessels is needed, as with endovascular device placement. The oblique approach is associated with lower wound morbidity than the standard vertical approach, including risk of infection and lymph leak. The patient is placed in the supine position and the inguinal ligament identified. Making an oblique incision approximately 2 to 2.5 fingerbreadths above the groin crease, the surgeon should make a cut in line with the inguinal ligament that runs over the palpated femoral pulse (Fig. 36-2, A). The incision is carried through the subcutaneous tissues to the fascia lata. Often, this is an avascular plane. All lymphatic tissue should be carefully ligated and divided to avoid a postoperative lymphocele. With the femoral sheath in view, it is then opened longitudinally, exposing the femoral artery.

A. Inguinal region



B. Bones and ligaments of pelvis

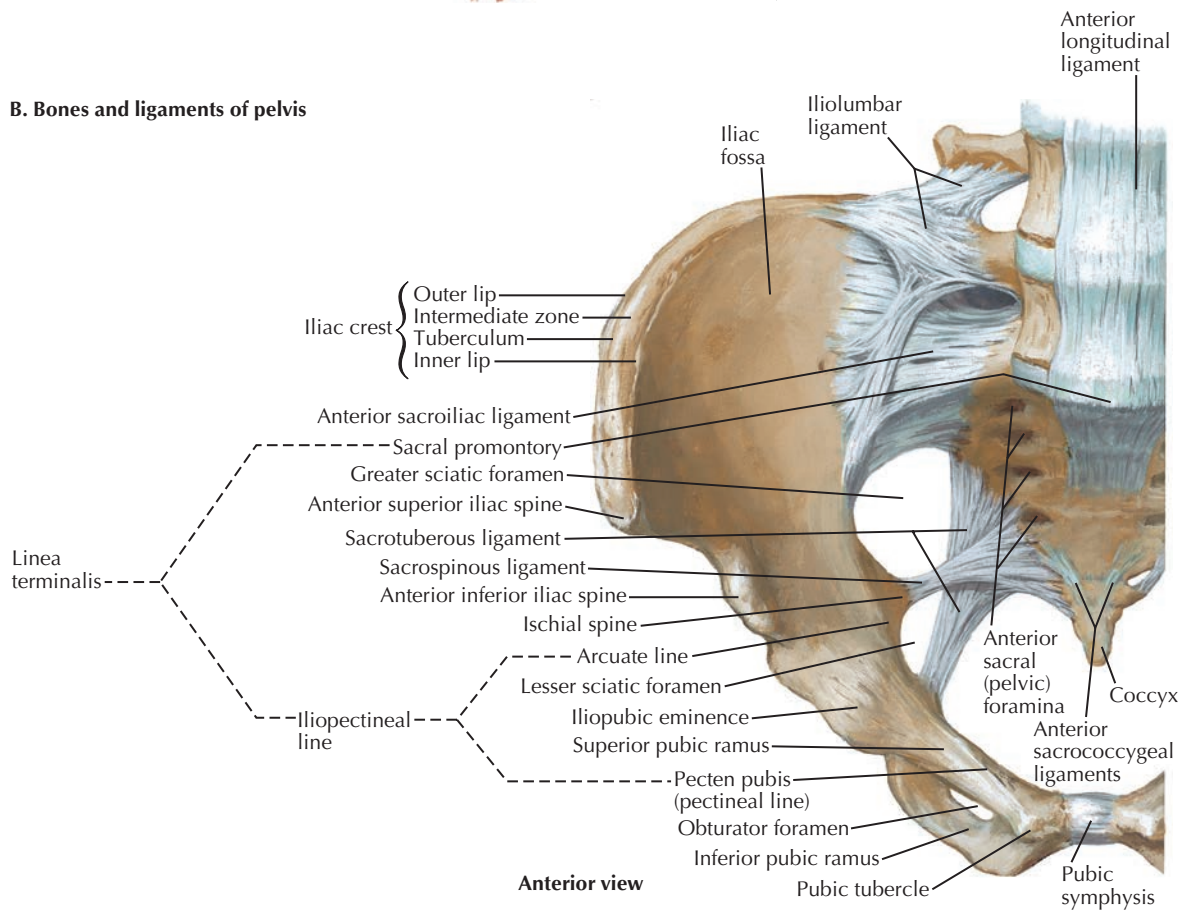


FIGURE 36-2 Anatomic landmarks for femoral incisions.

SAPHENOFEMORAL ANATOMY

The saphenofemoral junction is another important structure within the groin, located at the saphenous orifice (fossa ovalis) (Fig. 36-3, B). The saphenous opening is a small aperture in the fascia lata, inferior and lateral to the pubic tubercle and superior to the femoral vein. The fascia forms a curved edge lateral to the great saphenous vein. Its roof is composed of the cribriform fascia, the saphenous vein, and the venous tributaries that enter here.

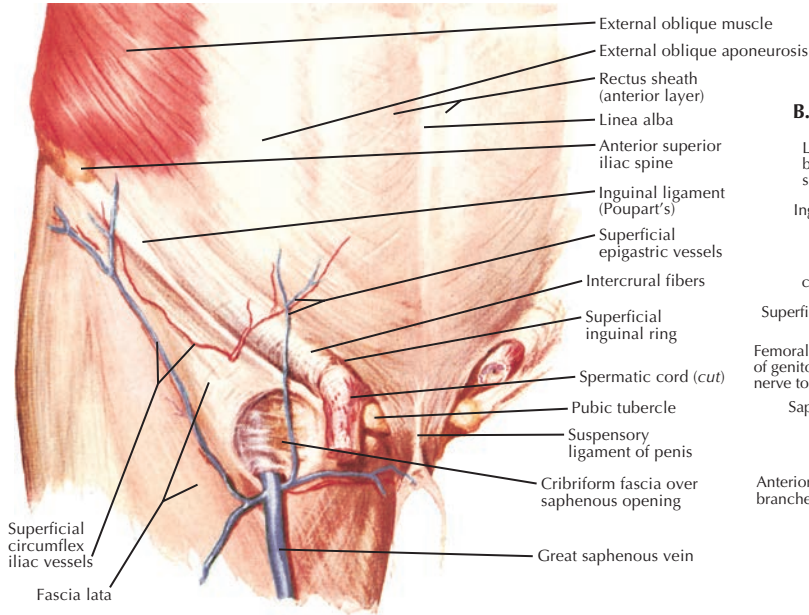
The great saphenous vein, common femoral vein, and the superficial inguinal veins join to form the saphenofemoral junction. Just before the fossa ovalis, multiple venous tributaries enter the great saphenous vein (e.g., superficial circumflex, superficial epigastric, lateral and medial accessory saphenous, external pudendal). Beginning at the superficial arch of the foot, the saphenous vein travels cephalad through the medial portion of the leg, above the deep fascia of the thigh, and then pierces the fascia of the femoral triangle, entering the fossa ovalis (Fig. 36-3, B).

EXPOSURE OF SAPHENOFEMORAL JUNCTION

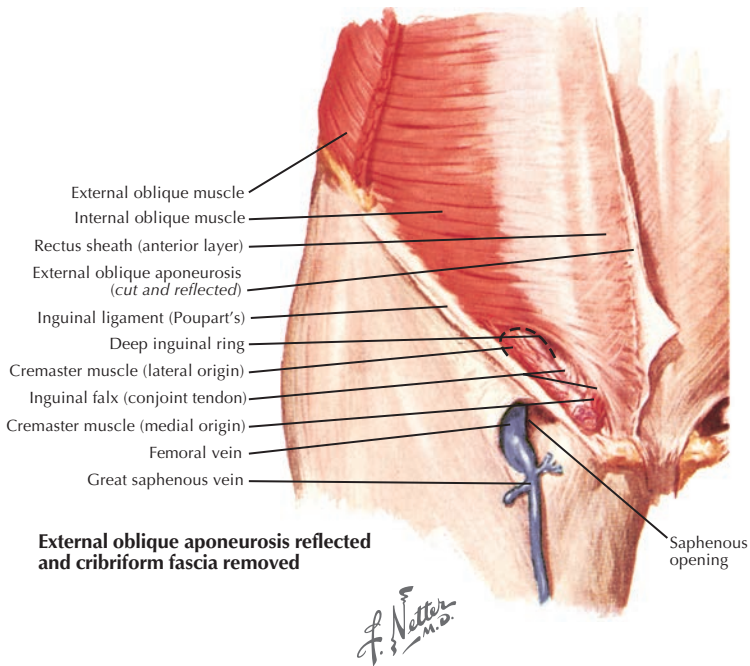
For exposure of the saphenofemoral junction, palpation of the femoral pulse can guide the incision. After locating the pulse, an angled incision should be made approximately 1 to 1.5 cm medial to the pulse. The incision should be extended distally for 4 to 6 cm. If the pulse is weak or not palpable, the femoral crease can be used as an anatomic landmark for the incision. Sharp dissection is carried through the superficial fascia into the subcutaneous space. Use of rake retractors or a self-retaining retractor provides adequate exposure and traction.

The great saphenous vein is found in the subcutaneous layer, coursing anteromedially along the thigh (Fig. 36-3, B). With the saphenous vein in view, the incision should be extended to the saphenofemoral junction (Fig. 36-3, A). The fascial covering of the trunk is dissected off the vein. Multiple tributaries enter the great saphenous vein, which then enters the fossa ovalis and joins the femoral vein. These venous tributaries can be ligated and divided. Identification of the external pudendal artery defines the lower border of the saphenofemoral opening.

A. Inguinal and femoral regions



Skin and subcutaneous tissue removed



External oblique aponeurosis reflected and cribriform fascia removed

B. Superficial nerves and veins of lower limb: anterior view

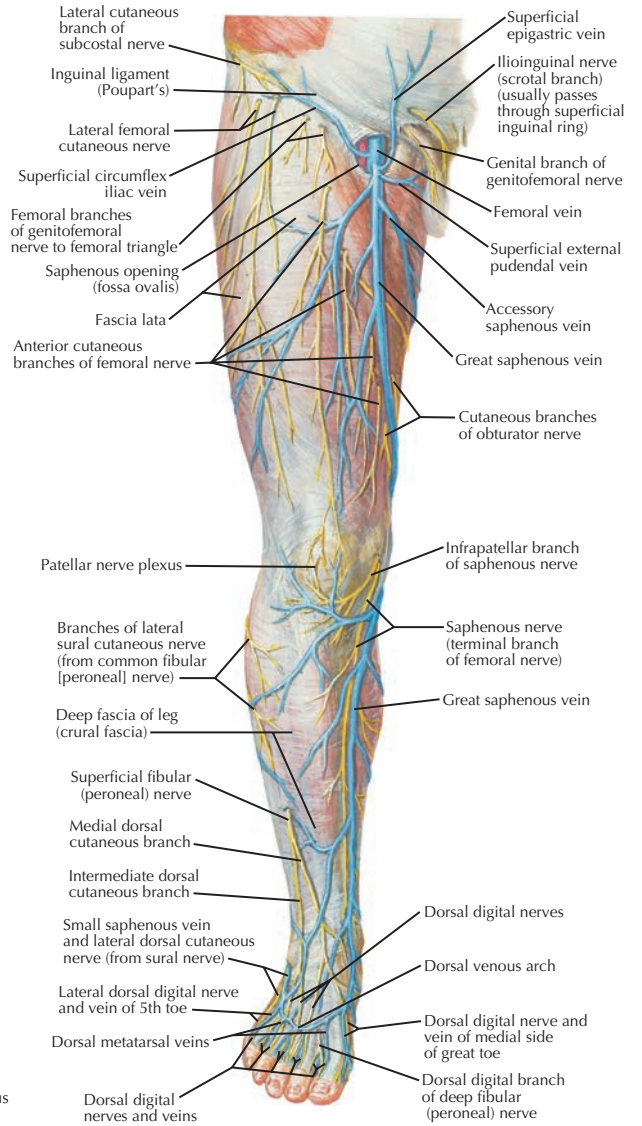


FIGURE 36-3 Saphenofemoral junction exposure and lower limb veins/nerves.

SUGGESTED READINGS

- Beirne C, Martin F, Hynes N, Sultan S. Five years' experience of transverse groin incision for femoral artery access in arterial reconstructive surgery: parallel observational longitudinal group comparison study. *Vascular* 2008;16(4):207-12.
- Caiati JM, Kaplan D, Gitlitz D, Hollier LH, Marin ML. The value of the oblique groin incision for femoral artery access during endovascular procedures. *Ann Vasc Surg* 2000;14(3):248-53.
- Schneider DB, Sarkar R, Messina LM, Stoney RJ. Extended iliac exposure from the groin. *Vasc Surg* 2001;35(2):131-6.
- Swinnen J, Chao A, Tiwari A, et al. Vertical or transverse incisions for access to the femoral artery: a randomized control study. *Ann Vasc Surg* 2010;24(3):336-41.

Exposure of the Common Femoral Artery and Vein

John C. Wang

INTRODUCTION

Anatomic knowledge of the common femoral artery (CFA) and its surrounding structures is important for safe and successful access during percutaneous or open vascular procedures. These procedures can be diagnostic or therapeutic and include arterial monitoring lines, intraaortic balloon pump placement, cardiac catheterization, and peripheral angiography, with or without endovascular intervention. More invasive access to the CFA includes femoral control for bleeding in traumatic injuries, cannulation during cardiopulmonary bypass, femoral cutdown for delivery of aortic endografts, and arterial revascularization procedures such as femoral endarterectomy and bypass (aortobifemoral, axillobifemoral, femorofemoral, infrainguinal).

FEMORAL ANATOMY

The CFA measures approximately 5 cm and is the direct continuation of the external iliac artery, distal to the inguinal ligament. The femoral neurovascular bundle emerges from the retroperitoneum of the pelvis at the inguinal level on its way into the thigh. Just as the umbilicus is located toward the midline, the mnemonic NAVEL refers to these structures deep to the inguinal ligament, from lateral to medial: femoral *N*erve, common femoral *A*rtery (CFA), common femoral *V*ein (CFV), *E*mpy space in femoral canal containing lymph vessels and lymph nodes, and lacunar *L*igament (Fig. 37-1, *A*).

The inguinal (Poupart's) ligament, which spans from the anterior superior iliac spine (ASIS) to the pubic tubercle, also forms the superior border of the femoral triangle (Fig. 37-1, *B*). The lateral and medial borders are the sartorius and adductor longus muscles, respectively. The femoral triangle appears as a depressed plane on thigh flexion and external rotation and contains the femoral neurovascular bundle, including the two major CFA branches, the femoral and profunda femoris (deep femoral) arteries and their corresponding veins. Proximally, deep to the NAVEL structures, the floor of the triangle comprises, from lateral to medial, the iliopsoas and pectineus muscles and pectineal ligament condensation on the superior pubic ramus (Fig. 37-1, *C*). The roof of the triangle is formed by fascia lata of the thigh, which has an oval opening at the superomedial aspect (fossa ovalis) through which the greater saphenous vein and lymphatic vessels join the deeper structures. Lymphatic vessels and lymph nodes are oriented parallel to the CFA and CFV, as well as along the inguinal ligament (Fig. 37-1, *D*).

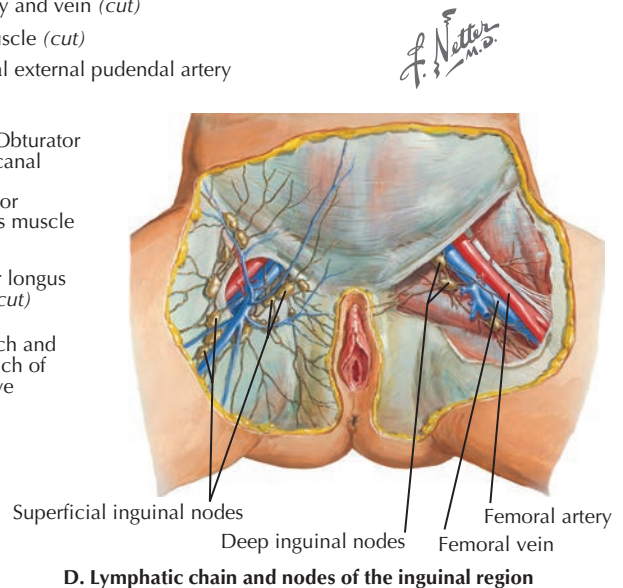
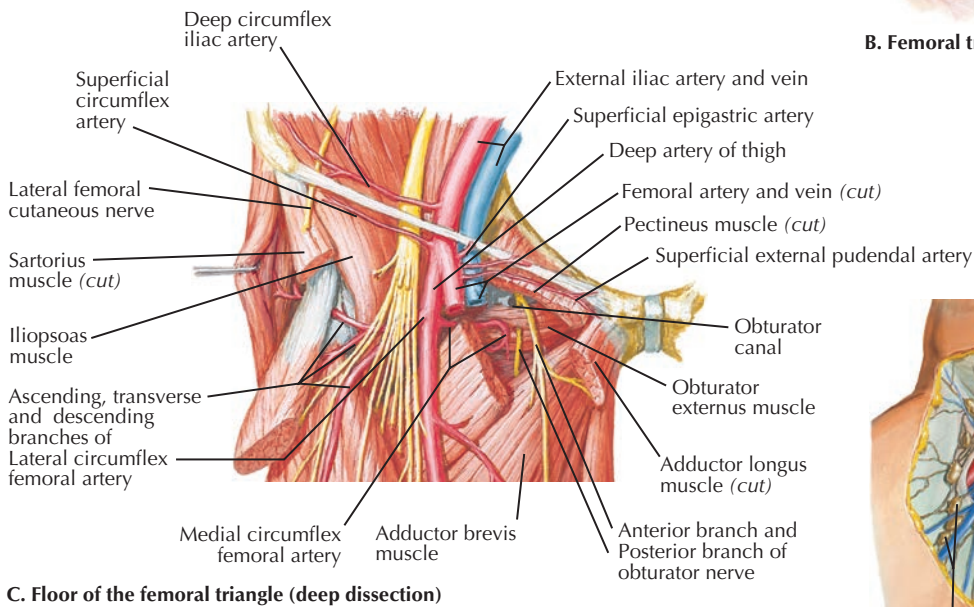
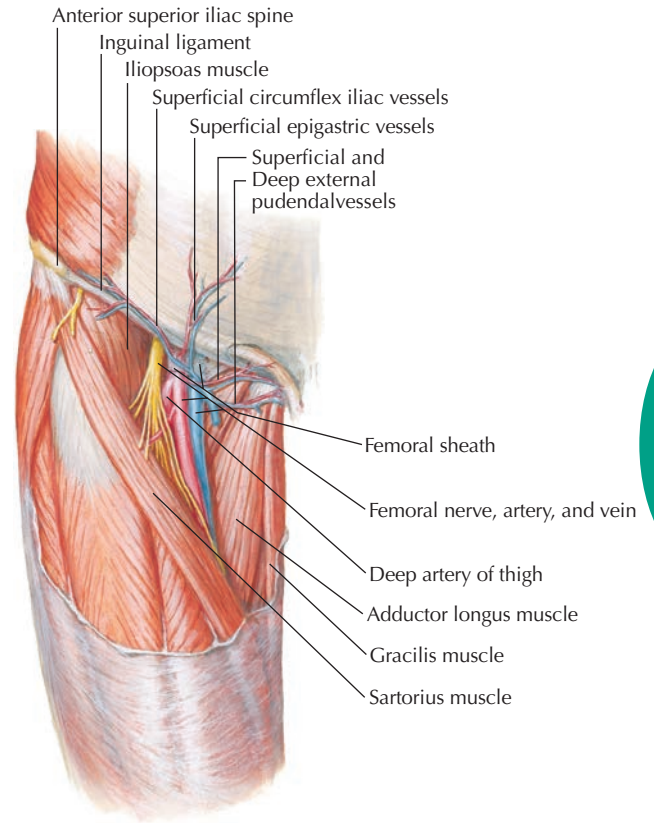
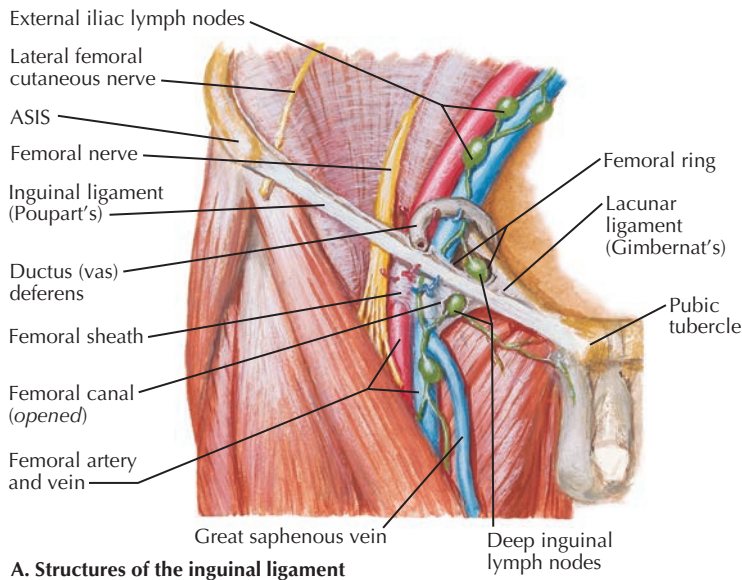


FIGURE 37-1 Anatomy of inguinal region and femoral triangle. ASIS, Anterior superior iliac spine.

SURGICAL PRINCIPLES

The location of CFA for percutaneous access is usually guided by palpation of its pulse, typically located just medial and inferior to the midpoint of the inguinal ligament. A common misconception that leads to low arterial sticks and possible injury to the femoral or profunda artery is that the groin crease directly corresponds to the inguinal ligament (Fig. 37-2, A). The inguinal ligament is two to three fingerbreadths cephalad to the crease and is most reliably identified by bony landmarks (ASIS, pubic tubercle) on palpation or fluoroscopy. The CFA usually overlies the medial two thirds of the femoral head (Fig. 37-2, B). These guidelines are helpful when the CFA is pulseless (heavy calcification, severe stenosis) or indiscernible (body habitus, obesity).

Inadvertent high sticks into the external iliac artery, especially if through the anterior and posterior walls, may cause significant retroperitoneal bleeding and exsanguination because no posterior wall buttress exists for tamponade, even with application of direct pressure. Unlike the CFA, which has the femoral triangle floor for effective tamponade, the external iliac artery lies within the retroperitoneum, which is a massive potential space.

Incisions and Closure

Operative exposure of the CFA can be achieved through vertical or oblique incisions. A vertical incision is favored if access to the CFA, femoral artery, and profunda femoris artery (PFA) is required. The PFA takeoff is usually 3 to 5 cm below the inguinal ligament in a posterolateral direction. The vertical extent of skin incision can therefore be adjusted to the required level of dissection (Fig. 37-2, C). Dissection in a vertical plane lessens inadvertent transection of lymphatic vessels that travel parallel to the CFA. Along with meticulous ligation of lymphatic tissue before transection, complications (lymphatic leak, lymphocele) and subsequent wound infection can be minimized.

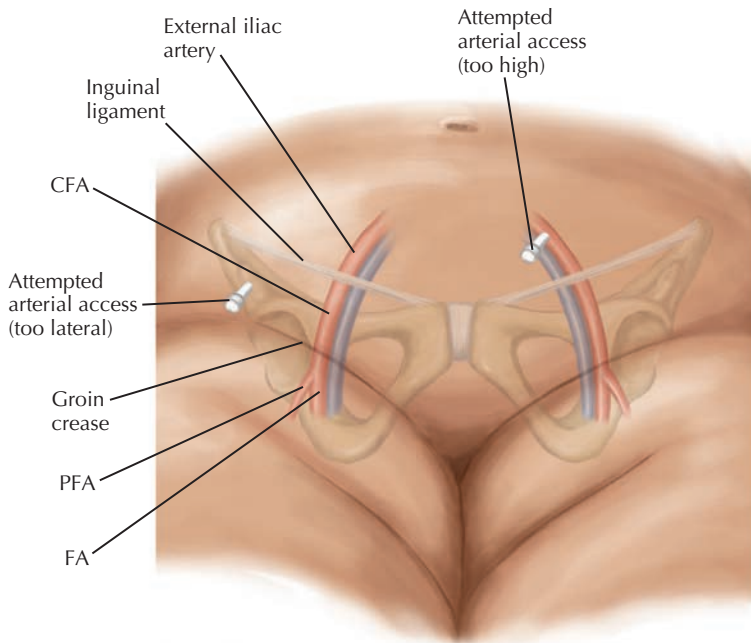
Oblique incisions should be made at a level between the groin crease and inguinal ligament, overlying the CFA. This technique is favored if only a segment of CFA is required, such as for delivery of aortic endografts. A separate skin incision inferiorly can be made to allow tunneling of the endograft delivery device (vascular sheath) through subcutaneous fat to reach the CFA at a suitable entry angle (Fig. 37-2, D).

Closure of groin wounds should be meticulous and achieved in layers to avoid exposure of bypass conduits or angioplasty patch material. The deep and superficial fascia should be closed separately by using running continuous sutures to ensure effective closure and binding of any residual cut lymphatic vessels. Skin can be approximated with subcuticular sutures or skin staples.

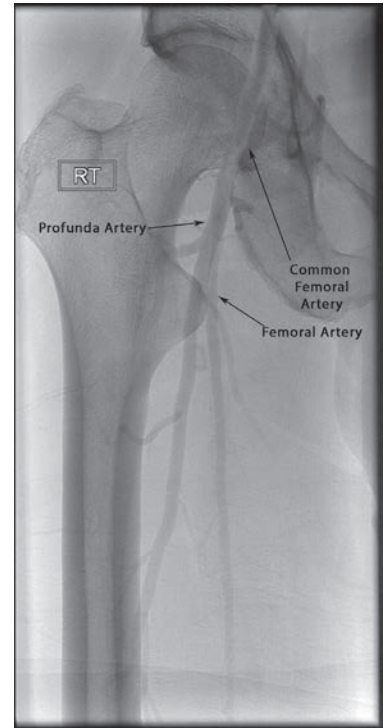
Nerve and Venous Injury

Care should be observed during dissection of the femoral vessels so as not to injure the femoral vein or nerve. Venous injury contributes to unnecessary blood loss, and venous repairs (venorrhaphy) may be associated with the increased morbidity of deep vein thrombosis (DVT). Femoral nerve injury may cause weakness of the quadriceps muscle and pain or paresthesia at the groin or along the medial thigh and leg.

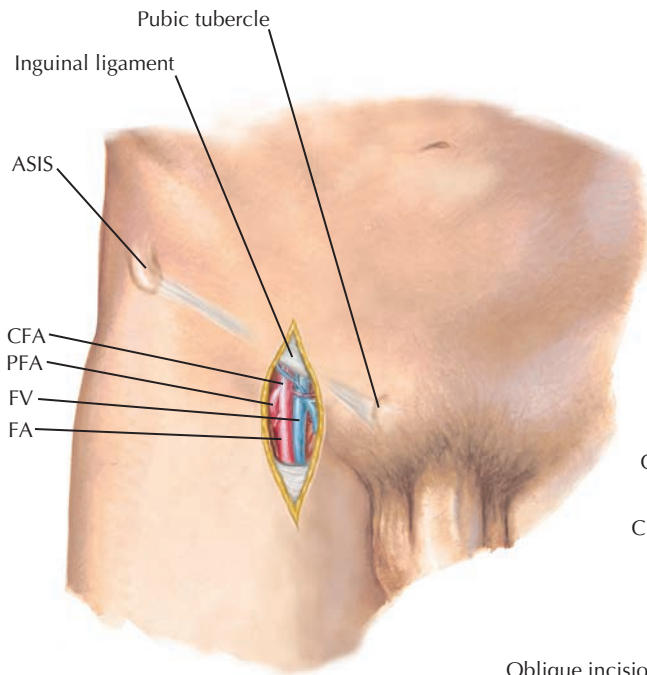
A. Location of inguinal ligament in relation to groin crease



B. Relation of CFA overlying the femoral head on angiogram



C. Access to the CFA and branches by vertical incision



D. Access to the CFA by oblique incision and counterincision for delivery of vascular sheath

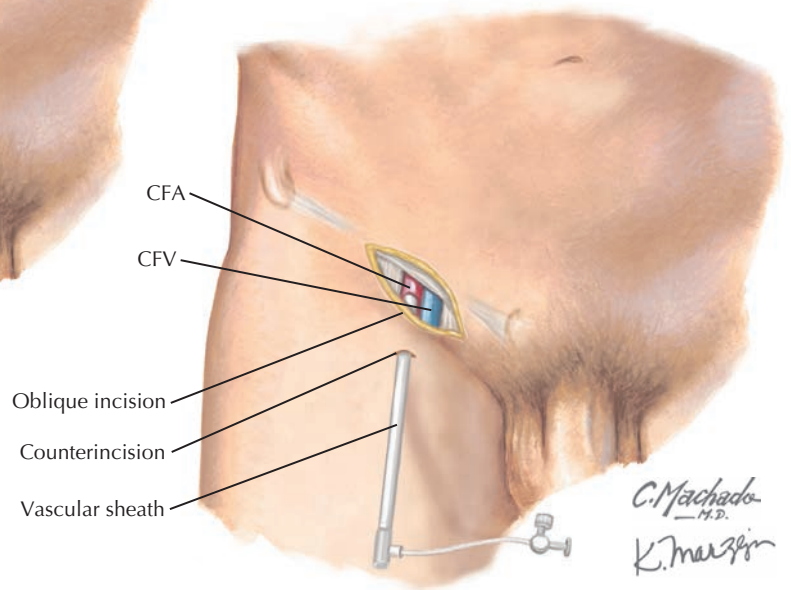


FIGURE 37-2 Accessing the femoral artery. ASIS, Anterior superior iliac spine; CFA, common femoral artery; CFV, common femoral vein; FA, femoral artery; FV, femoral vein; PFA, profunda femoris artery.

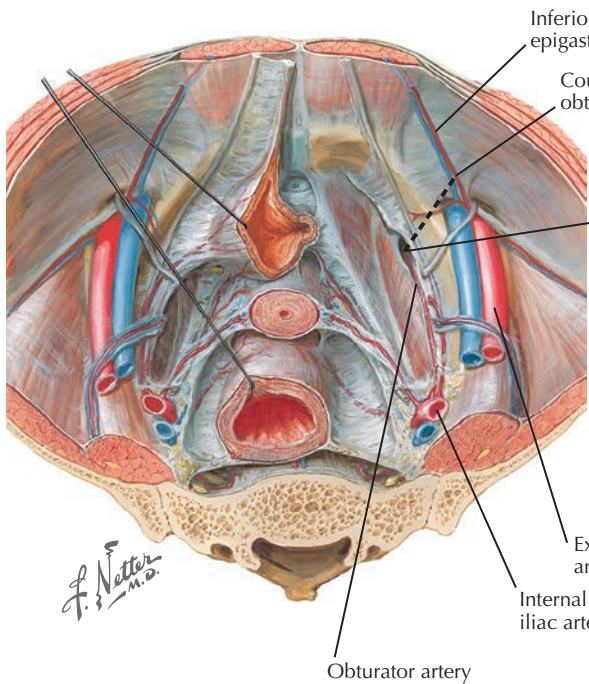
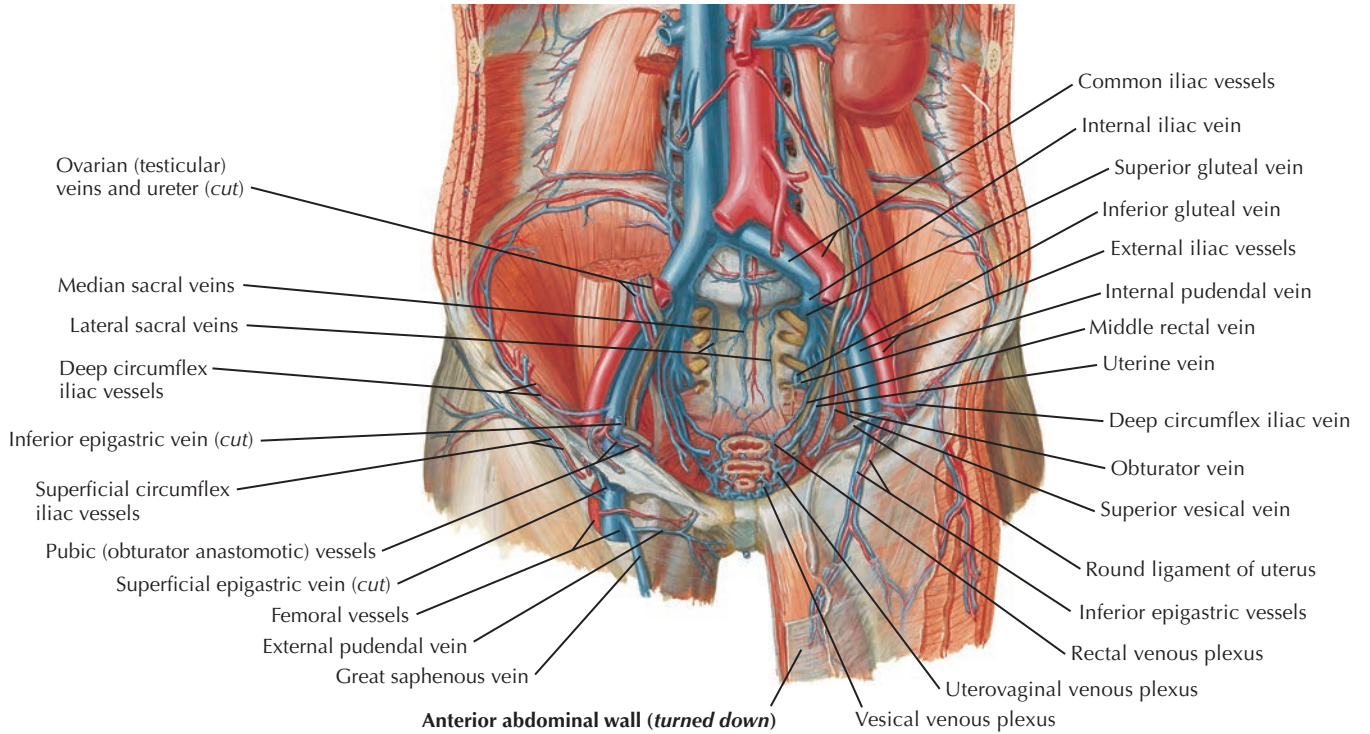
MAJOR ARTERIAL BRANCHES

The distal external iliac artery gives off two small branches, the inferior epigastric artery and the deep circumflex iliac artery, which runs between the peritoneum and transversalis fascia just cephalad to the inguinal ligament (Fig. 37-3, A). The inferior epigastric artery supplies the lowest part of the rectus abdominis muscle, entering at the level of the arcuate line. An aberrant obturator artery may be present in 20% of cases, originating from the inferior epigastric artery instead of the internal iliac artery. This aberrant obturator artery is prone to injury during bypass graft tunneling (aortofemoral or iliofemoral) or femoral hernia repairs, because it lies across the femoral canal and pectinate line, coursing to exit at the obturator foramen (Fig. 37-3, B). The deep circumflex iliac vessels, especially the vein, are also prone to injury because they course along the lateral portion of the inguinal ligament. Control of the vein by division between silk ties is recommended before blunt tunneling of the retroperitoneum from the femoral triangle into the abdomen, to accommodate a bypass graft.

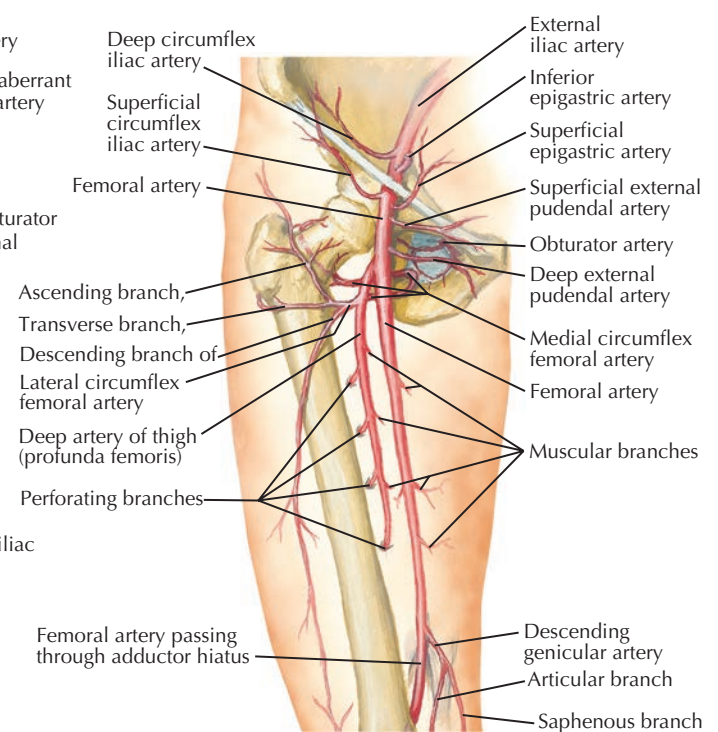
The CFA gives rise to three superficial branches that emerge through the deep fascia of the femoral sheath and thigh (fascia lata), to supply the subcutaneous tissue and skin of the lower abdomen and upper thigh: superficial epigastric, superficial external pudendal, and superficial circumflex iliac arteries (Fig. 37-3, C). These arteries may develop to become prominent collateral branches in peripheral vascular occlusive disease and therefore should be preserved as much as possible. Their corresponding veins converge at the greater saphenous vein (GSV) close to the saphenofemoral junction. Dissection along any of these tributaries in a central direction can help identify the GSV if needed as a vein conduit for bypass surgery.

The deep branches of the CFA include the deep external pudendal artery and two large terminal branches, the femoral artery and PFA. The femoral artery traverses the femoral triangle and passes through the adductor (Hunter's) canal between the adductor and quadriceps muscles. The highest geniculate artery (descending geniculate artery) usually takes off before entry into Hunter's canal and may become an important collateral in femoropopliteal occlusive disease. The PFA (deep femoral artery) usually arises on the posterolateral side of the CFA and runs posteromedial to the femur shaft. It gives off the medial and lateral circumflex femoral branches near its origin and continues posterior to the adductor longus muscle as it gives rise to four perforating branches. The lateral circumflex femoral vein crosses the PFA origin and should be controlled by division between silk ties if access and adequate control to the PFA is required. Along with branches from the internal iliac artery (obturator artery, superior and inferior gluteal arteries), the PFA and its branches supply the musculature of the thigh.

A. Branches of the distal external iliac artery



B. Aberrant obturator artery



C. Branches of common femoral artery

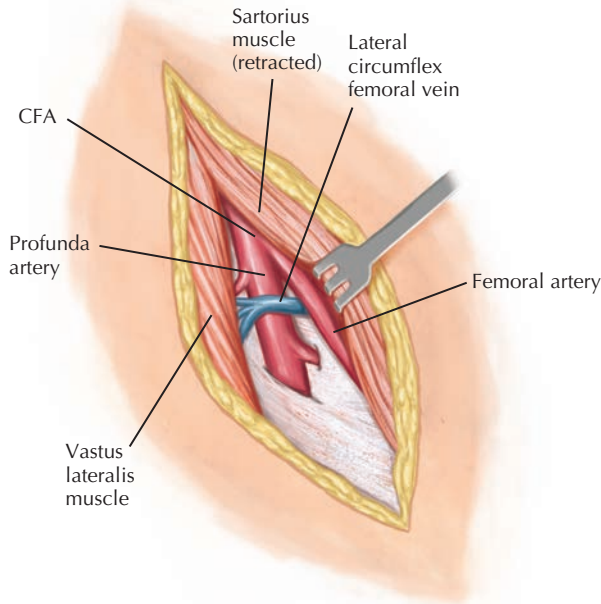
FIGURE 37-3 Branches of external iliac and common femoral arteries; aberrant obturator artery.

AVOIDING THE COMMON FEMORAL ARTERY

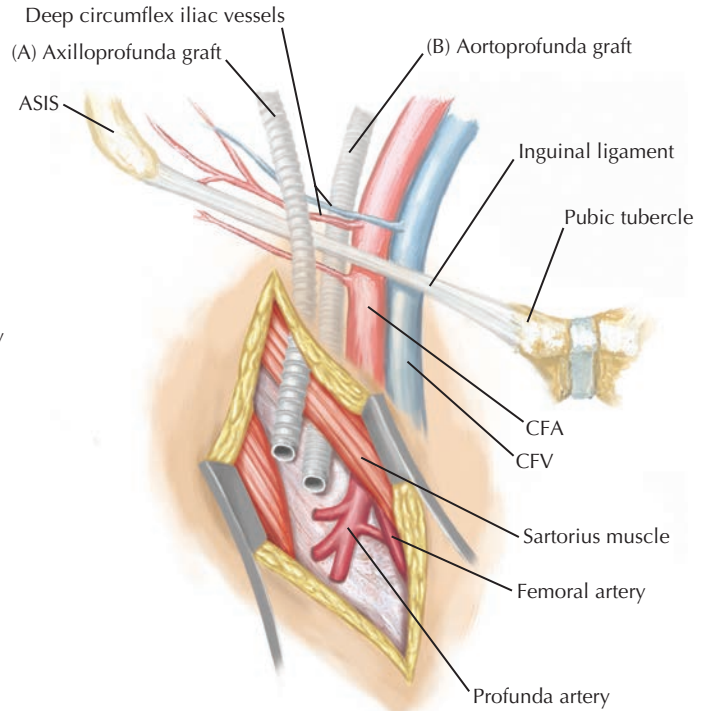
When avoiding the CFA is indicated, as in redo surgery and extensive scarring, the PFA may be an adequate recipient vessel for bypass with a slanted incision along the lateral border of the sartorius muscle. Dissection of the CFA bifurcation and proximal PFA can be achieved deep to the sartorius (Fig. 37-4, A). The bypass graft can be tunneled more laterally toward the ASIS, superficial to the inguinal ligament in an axillo-PFA bypass, or deep to the ligament in an aorto-PFA bypass (Fig. 37-4, B).

In the more morbid situation of graft infection involving the groin area, after complete excision of infected graft material and debridement of infected tissue, revascularization can also be achieved with an obturator bypass. The obturator artery is best approached with a lower-quadrant incision along the direction of the external oblique muscle fibers. The internal oblique and transversalis muscles are divided and the peritoneum and its contents are retracted superomedially to expose the retroperitoneum and iliac vessels (Fig. 37-4, C). The surgeon passes the bypass conduit through the central portion of the obturator fascia, taking care not to injure the obturator artery and vein passing into the obturator canal. Using a curved tunneler, the surgeon can bring the graft behind the pectineus and adductor muscles to the midhigh for anastomosis with the femoral artery, or to the adductor canal for anastomosis with the supra-genicular popliteal artery (Fig. 37-4, D).

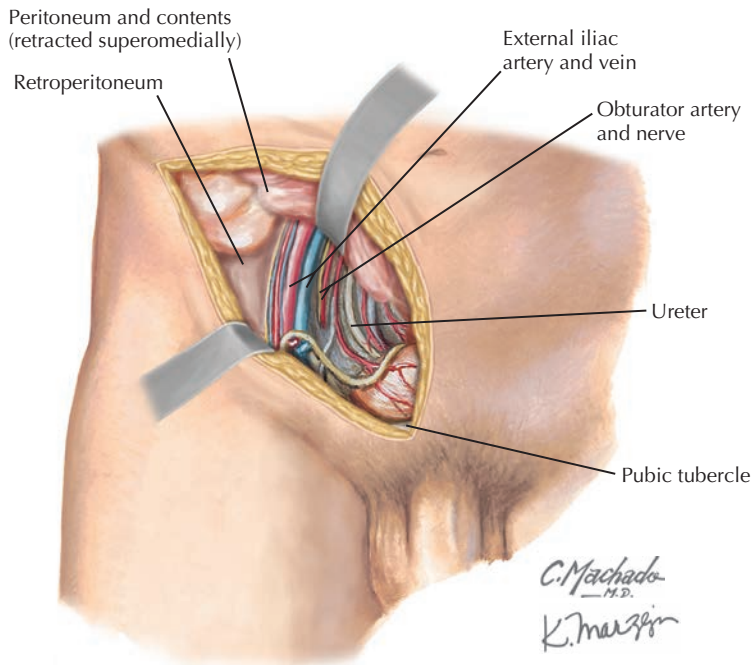
A. Lateral exposure of right CFA bifurcation and profunda artery



B. Schematic for tunneling in axilloprofunda bypass graft (A) superficial to inguinal ligament, and aortoprofunda bypass graft (B) deep to inguinal ligament



C. Retroperitoneal exposure of the iliac arteries for obturator bypass



D. Path of obturator bypass. Sartorius and quadriceps muscles removed.

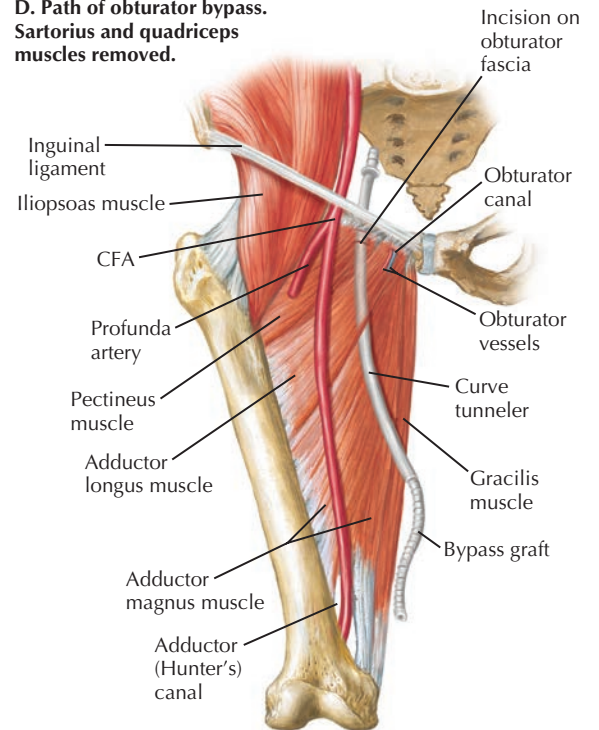


FIGURE 37-4 Avoiding the femoral artery. ASIS, Anterior superior iliac spine; CFA, common femoral artery; CFV, common femoral vein.

SUGGESTED READINGS

- Lawrence RF. Arterial bypass through the obturator foramen. In Baker RJ, Fisher JE, editors: *Mastery of surgery*, 4th ed. Philadelphia: Lippincott, Williams & Wilkins; 2001, pp 2109-14.
- McMinn RMH. Lower limbs. In *Last's anatomy: regional and applied*, 9th ed. London: Churchill Livingstone; 1994, pp 145-70.
- Valentine RJ, Wind GC. Common femoral artery. In *Anatomic exposures in vascular surgery*, 2nd ed. Philadelphia: Lippincott, Williams & Wilkins; 2003, pp 375-411.

Exposure of the Popliteal Artery and Vein



Matthew T. Allemang and Vikram S. Kashyap

INTRODUCTION

Exposure of the popliteal artery and vein is relevant to many surgical specialties, including general, vascular, and trauma. The approach to the popliteal anatomy can be dictated by the pathology, with specific conditions unique to this mobile area. Thus, this chapter encompasses both medial and posterior approaches to the popliteal artery and vein. Causes of popliteal artery disease include atherosclerosis, aneurysm, trauma (pseudoaneurysm, dissection, rupture), popliteal entrapment syndrome, and cystic adventitial disease. Although less common, venous pathology usually encompasses trauma, aneurysm, and entrapment as well. Treatment of each is largely determined by the anatomic location, and therefore knowledge of basic anatomy and relevant landmarks is critical.

SURGICAL PRINCIPLES

The popliteal artery begins at the adductor canal within the adductor magnus muscle (Hunter's canal) as it enters the popliteal space behind the knee joint. The popliteal artery ends when it splits in the lower leg to become the anterior tibial artery and tibioperoneal trunk. Several important geniculate collaterals increase in caliber in cases of progressive atherosclerotic occlusion of the distal superficial femoral and popliteal arteries (Fig. 38-1, A). If an acute occlusion is present in this area, however, the collateral vessels are not sufficient and the leg is usually threatened, requiring immediate revascularization. Venous anatomy, on the other hand, is more variable.

MEDIAL SUPRAGENICULATE APPROACH

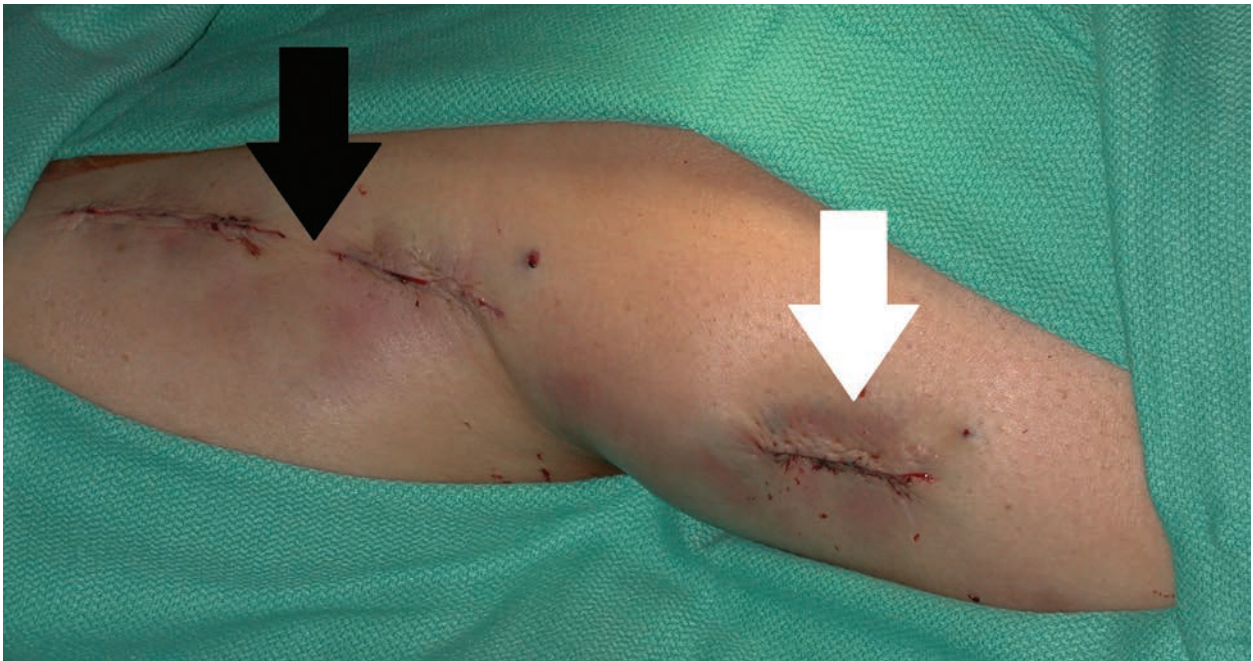
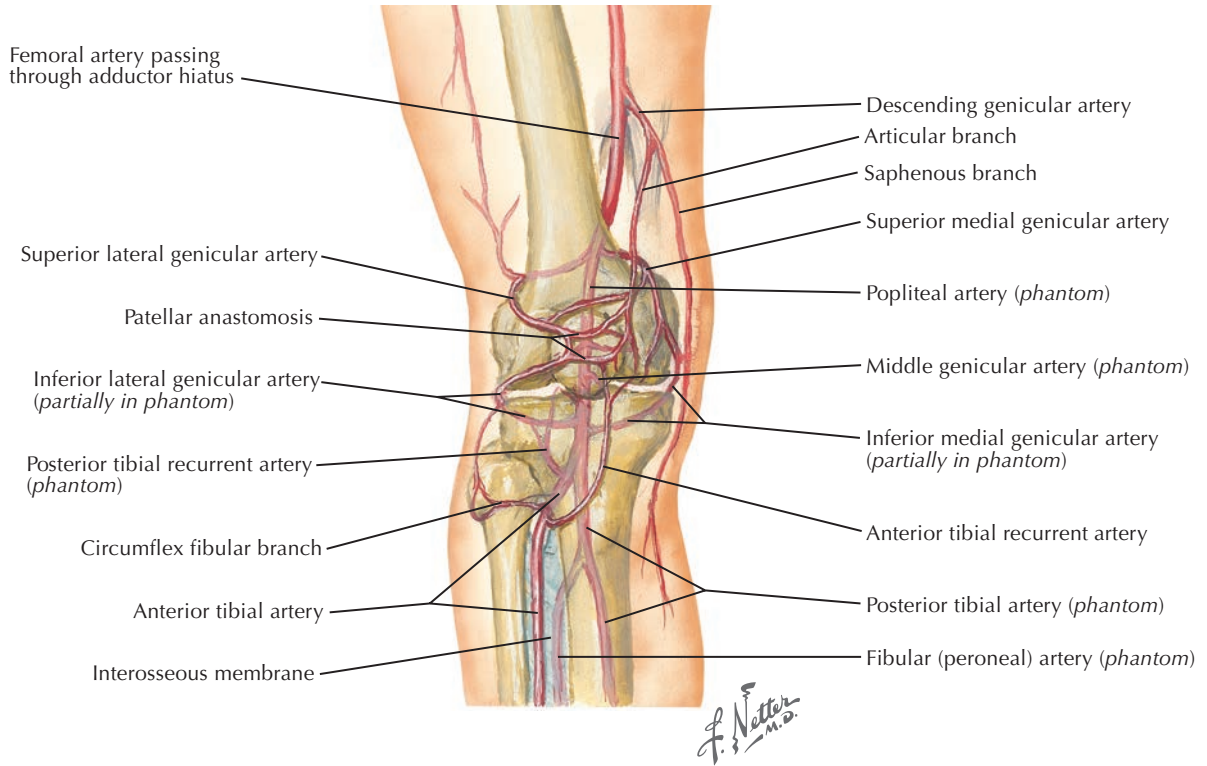
The medial suprageniculate approach is most often used in femoral-to-popliteal artery (femoropopliteal) bypass above the knee. The patient is placed in the supine position with the knee slightly flexed. An incision is made on the distal portion of the medial thigh over the estimated location of the sartorius muscle (Fig. 38-1, B).

After locating the junction between the sartorius (posterior) and vastus medialis (anterior), the surgeon places a self-retaining retractor there (Fig. 38-2).

The popliteal artery should be easily palpable below the fascia tissue between the adductor magnus and semimembranosus muscles (Fig. 38-3, A). It is important to avoid injury to any collateral arteries and veins.

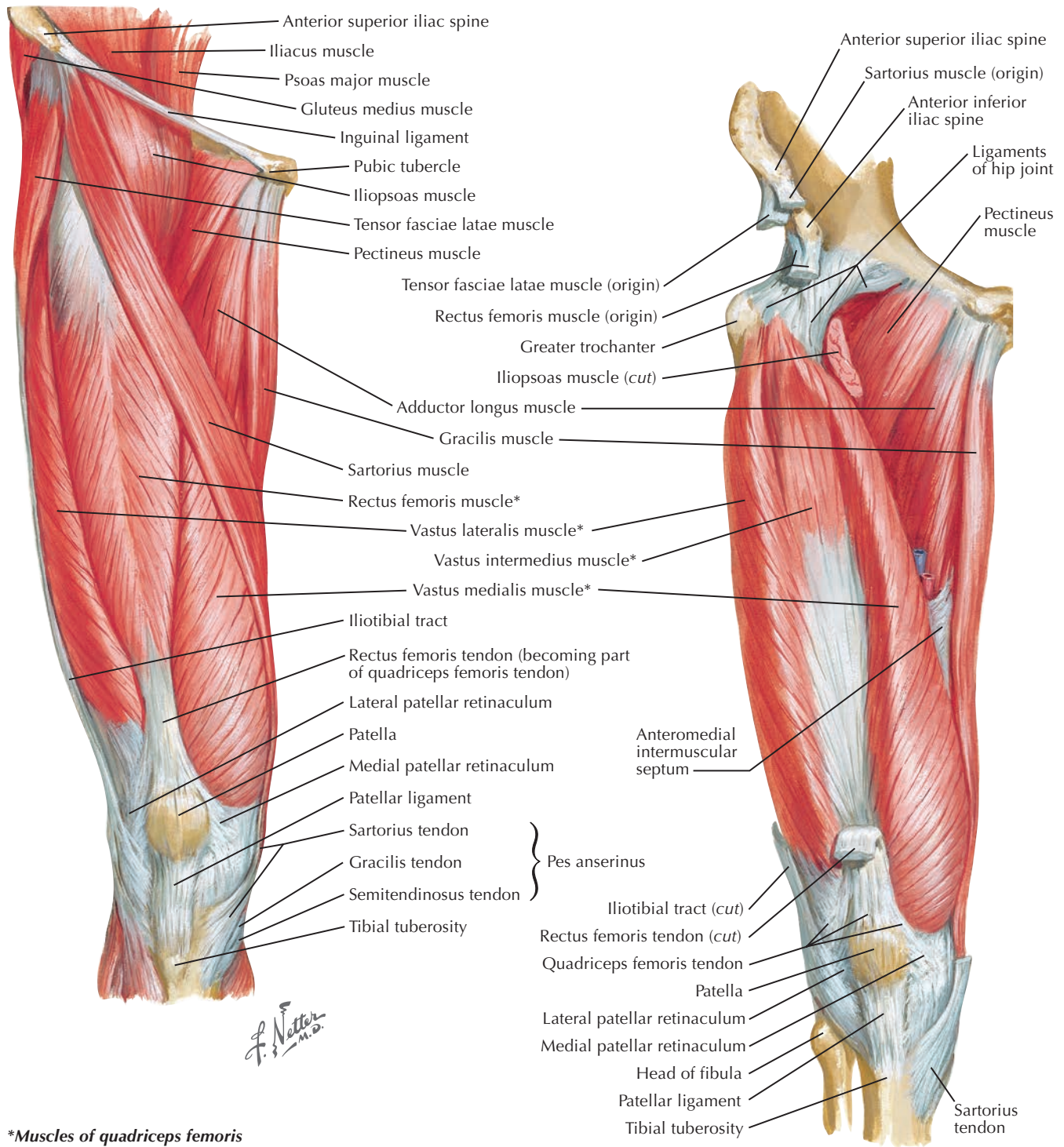
Once this next fascia layer is opened, the vascular sheath containing the proximal popliteal artery and vein is seen as these vessels emerge through the canal. The adjacent popliteal vein is usually encountered first in the authors' experience, but venous anatomy can be variable (Fig. 38-3, B). Sharp dissection is used to isolate the artery or vein proximally up to the adductor canal. Vessel loops are used to encircle the artery. The surgeon must be careful and look for a bifid popliteal vein with a second vein behind the artery; injury to the vein can lead to significant blood loss.

A. Arteries of knee



B. Medial view of a left leg depicting supragenicular (*black arrow*) and infragenicular (*white arrow*) incisions.

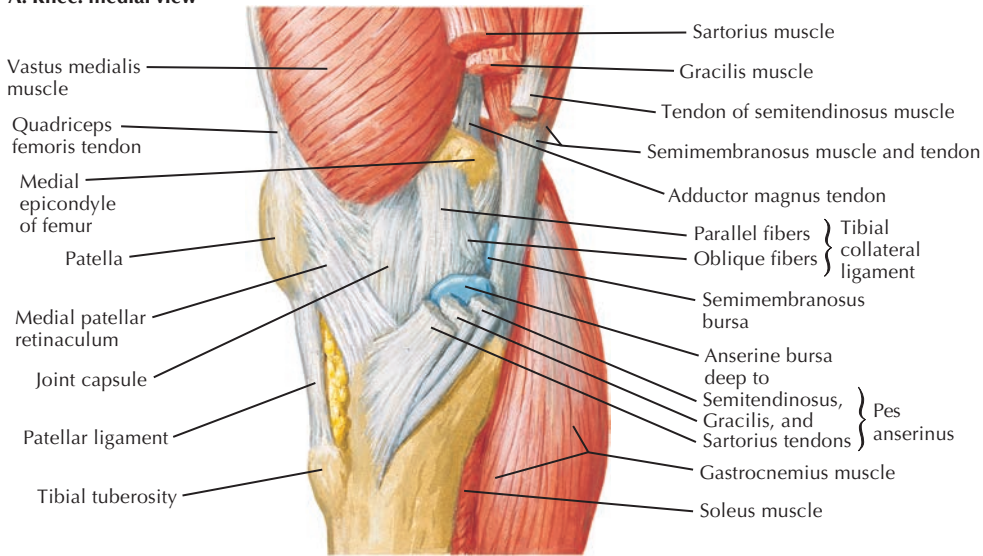
FIGURE 38-1 Arteries of knee and thigh incisions.



*Muscles of quadriceps femoris

FIGURE 38-2 Muscles of thigh: anterior view.

A. Knee: medial view



B. Muscles of thigh: anterior view

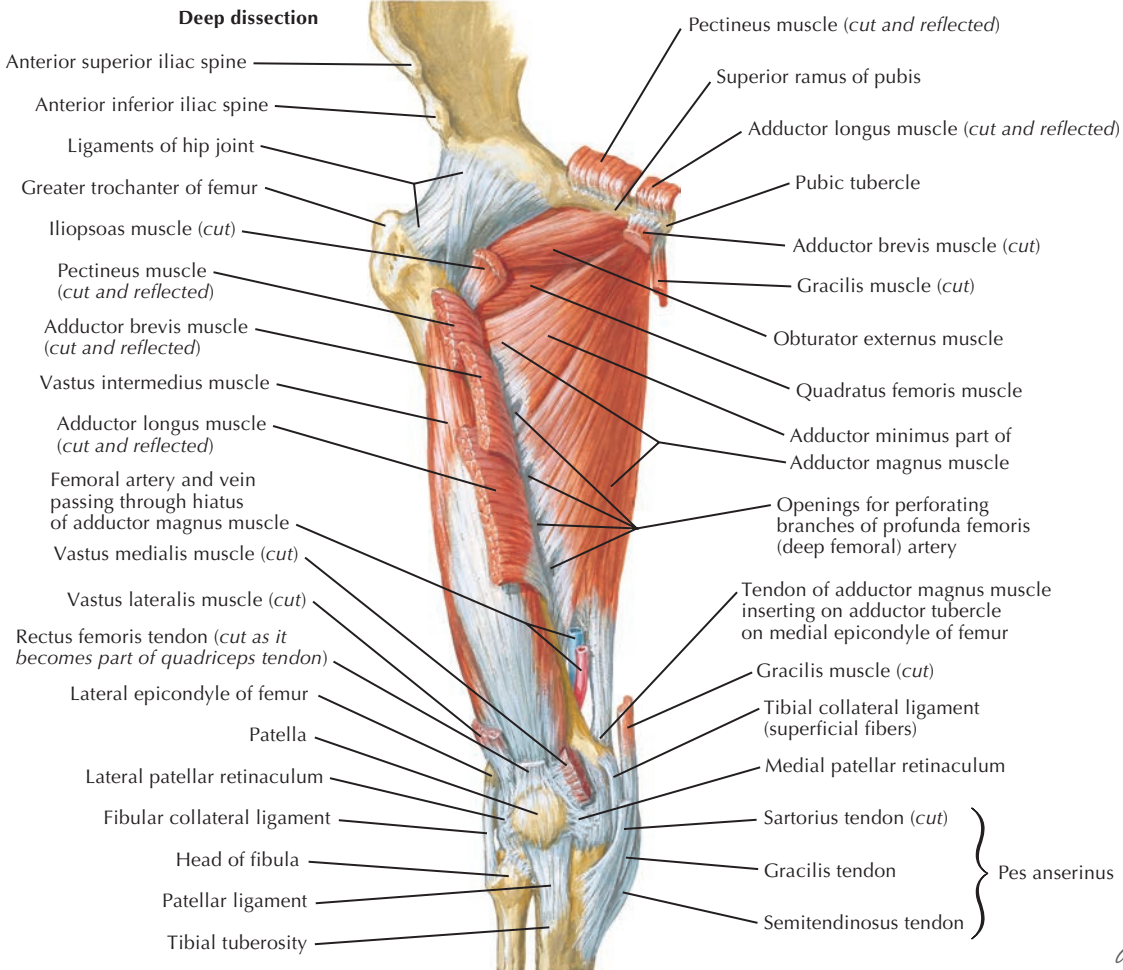


FIGURE 38-3 Muscles of knee and thigh (deep dissection): medial and anterior views.

F. Netter M.D.

MEDIAL INFRAGENICULATE APPROACH

The medial infrageniculate technique is most often used in cases of femoropopliteal bypass below the knee. As for the suprageniculate approach, the patient is placed in the supine position with the knee slightly bent and the hip externally rotated. The incision is started just distal to the medial tibial plateau and runs longitudinally along the posterior border of the tibia approximately 1 fingerbreadth (see Fig. 38-1, B). This incision can be extended distally down the lower leg as needed for adequate exposure. It is important to avoid injury to the greater saphenous vein (GSV) or branches during the initial incision as it lies in the same approximate position. The GSV is often used as the bypass conduit and should be sought out first and protected during the dissection.

Next in the medial infrageniculate approach, the fascia overlying the medial head of the gastrocnemius muscle is incised and the muscle retracted posteriorly using a self-retaining retractor (see Fig. 38-3, A). Again, the vascular bundle is encountered, usually with the popliteal vein first medially. Through sharp dissection, the popliteal artery or vein is isolated, and vascular loops are placed for control. If additional length is needed, the soleus muscle can be divided from its tibial attachments distally. Alternately, the tendons of the pes anserinus (semitendinosus, gracilis, and sartorius muscles) can be temporarily divided proximally, but care must be taken to reattach these tendons after completion of the procedure for knee stability.

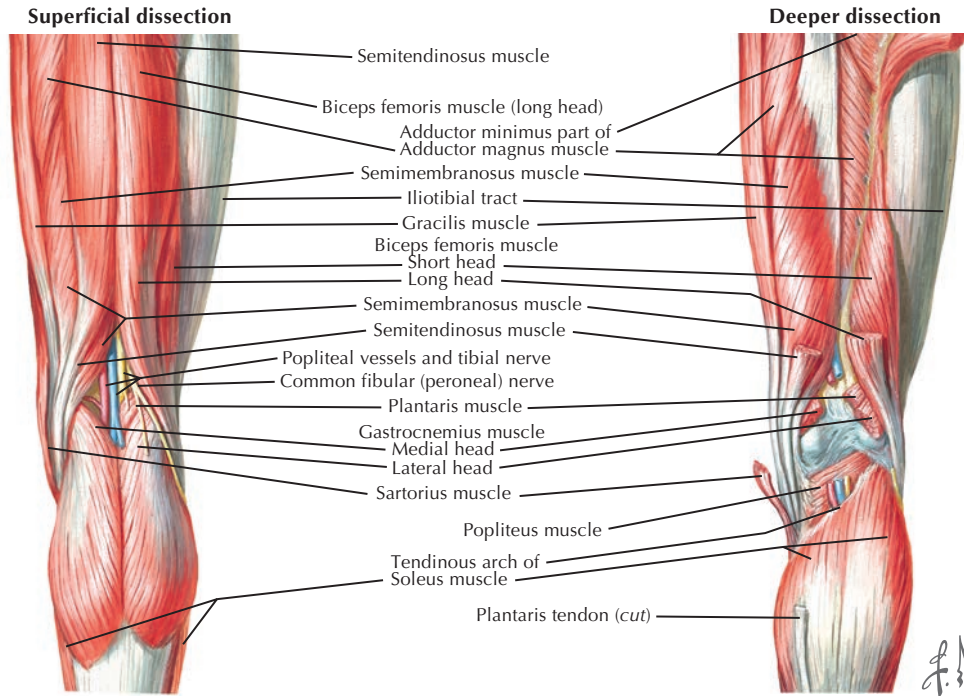
POSTERIOR APPROACH

Best used for treatment of trauma, aneurysms, cystic adventitial disease, and popliteal entrapment syndrome, the posterior approach begins with the patient in the prone position. A lazy S-shaped incision is made to prevent debilitating wound-healing contracture across a mobile joint. Starting at the proximal medial aspect of the lower thigh along the muscle bodies of the semimembranosus and semitendinosus, the surgeon carries the incision down to the popliteal crease and crosses it horizontally from medial to lateral, then down distally along the lateral calf (Fig. 38-4, A). At this point, the small (short) saphenous vein is encountered and ligated or harvested for bypass, if it is of adequate size (Fig. 38-4, B).

The surgeon then incises the fascia overlying the popliteal fossa with a vertical incision, being vigilant to avoid injury to the numerous nerve branches. At this point, the popliteal artery should be palpable (medial) between the two heads of the gastrocnemius muscle. A self-retaining retractor is placed. The tibial and common peroneal nerves traverse the popliteal space and should only be gently retracted to prevent traction injury. The vascular sheath can be incised and popliteal artery or vein sharply dissected with vessel loops placed for control. If necessary, the two heads of the gastrocnemius can be dissected distally to allow more exposure.

Figure 38-5 provides an example of a popliteal artery aneurysm and subsequent bypass with polytetrafluoroethylene (PTFE) using the posterior approach.

A. Muscles of thigh: posterior view



B. Muscles of leg (superficial dissection): posterior view

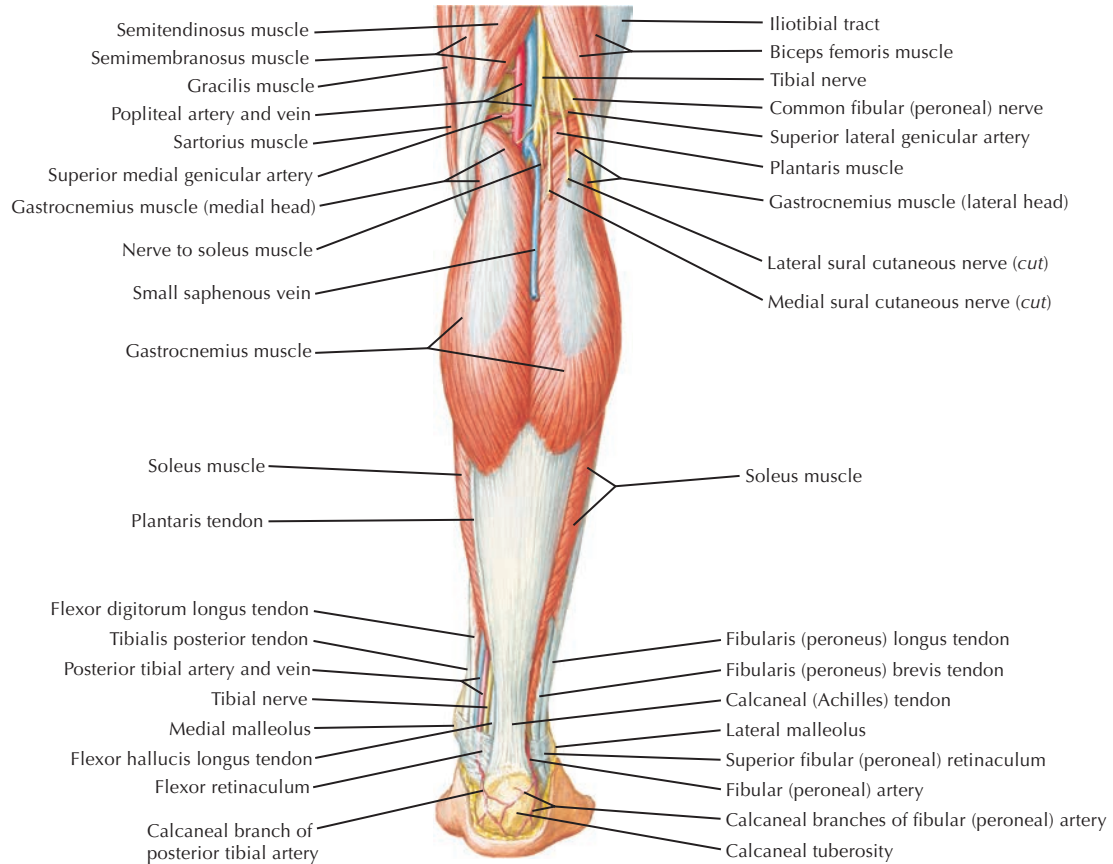
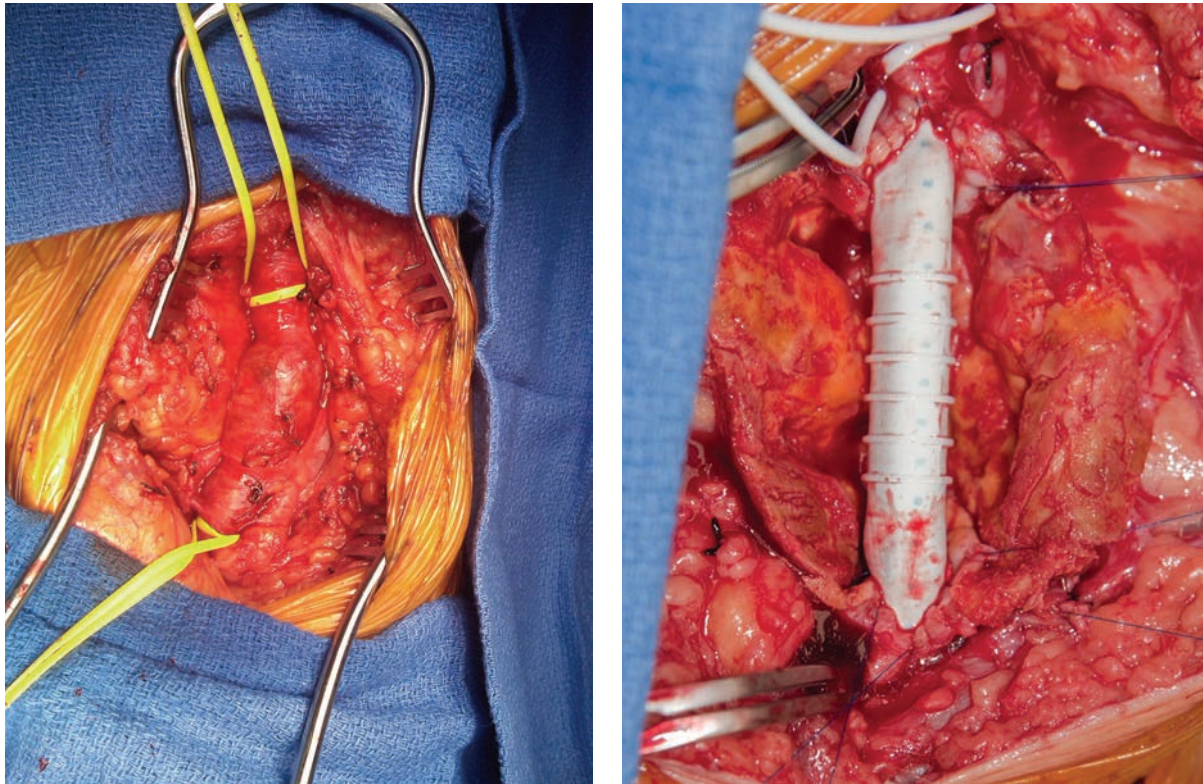


FIGURE 38-4 Muscles of thigh (superficial/deeper dissections) and leg (superficial dissection).



Popliteal artery aneurysm before (*left*) and after (*right*) PTFE bypass graft.

FIGURE 38-5 Popliteal artery aneurysm repair.

SUGGESTED READINGS

- Gelabert HA, Colburn MD, Machleder HI. Posterior exposure of the popliteal artery in reoperative vascular surgery. *Ann Vasc Surg* 1996;10(1):53-8.
- Kropman RH, van Santvoort HC, Teijink J, et al. The medial versus the posterior approach in the repair of popliteal artery aneurysms: a multicenter case-matched study. *J Vasc Surg* 2007;46(1):24-30.
- Norgren L, Hiatt WR, Dormandy JA, et al. Inter-society consensus for the management of peripheral arterial disease (TASC II). *J Vasc Surg* 2007;45(Suppl):S5-7.
- Ziegler KR, Muto A, Eghbalieh SD, Dardik A. Basic data related to surgical infrainguinal revascularization procedures: a twenty year update. *Ann Vasc Surg* 2011;25(3):413-22.

Above-Knee and Below-Knee Amputation

Gilles Pinault

INTRODUCTION

Amputations above and below the knee are common surgical procedures performed by vascular, orthopedic, and general surgeons. The indications for these procedures include infection, acute ischemia, chronic progressive ischemia, trauma, intractable pain, neuropathy, and nonhealing wounds. In developed countries, the primary indications for lower-extremity amputation are complications of peripheral vascular disease and diabetes mellitus.

PREOPERATIVE EVALUATION

The level of amputation is predicated on skin healing and the patient's functional status. In patients who are ambulatory before surgery, the goal is to perform amputation at the most distal level that returns the patient to maximum function. Typically, the below-knee amputation (BKA) requires much less energy postoperatively to walk and allows patients to remain fully ambulatory. Patient can be ambulatory after above-knee amputation (AKA), but walking is more difficult and requires a significant increase in energy expenditure, which may not be available to older patient with significant comorbidities. If a patient is nonambulatory, AKA improves the chance of healing and limits complications from contractures. Preoperative non-invasive testing is helpful in determining lower-extremity blood flow and appropriate level of amputation for successful healing.

Preoperative evaluation and optimization prepare the patient for surgery and minimize perioperative complications. Glucose control and underlying nutritional status should be evaluated and optimized. Occasionally, initial guillotine amputation is indicated to provide drainage and control of deep space infection, with a secondary procedure for definitive closure. Recognition of the importance of amputation as the first step of the patient's rehabilitation to recovery of functional status should be emphasized to the patient and health care team. Successful rehabilitation depends on aggressive postoperative physical and occupational therapy. Group amputee therapy is helpful in patients with psychological issues surrounding the actual amputation.

SURGICAL PRINCIPLES

Surgical technique should emphasize gentle handling of the tissues, strict hemostasis, use of viable tissue for closure, and ligation of nerves under tension to allow retraction out of the area of surgical incision. Retraction and atrophy of tissues associated with normal healing and scarring should be considered when transection of bone is performed, to avoid the complication of wound breakdown from tension on the healed scar.

Use of immediate postoperative prosthesis (IPOP) typically is surgeon and institution specific. IPOP allows for early weight bearing and ambulation and is well suited for younger, motivated patients. The goal of operation is to provide a healed wound with a stump that can fit into a prosthetic limb. For BKA, the long posterior myocutaneous flap is typically used, although circular and fish-mouth incisions may be necessary with wounds in or on the calf. Newer prosthetic techniques allow for mediolateral or anteroposterior flaps with good functional outcome. The importance of identifying the fascial layers for closure and meticulous handling of the tissues should be emphasized (Fig. 39-1).

The length of the stump depends on preoperative functional status with expected postoperative potential for prosthetic fitting, but usually the tibial transection is made about 10 cm beyond the tibial tuberosity. For AKA, it is preferable to leave the residual femur as long as possible, except in nonambulatory patients with severe peripheral vascular disease who undergo AKA for palliation of pain or nonhealing ulcers and may benefit from a shorter stump to maximize healing potential. Understanding the bony landmarks, arterial supply, nerves, and compartments of the lower extremity is essential to perform an appropriate procedure (Figs. 39-2 and 39-3).

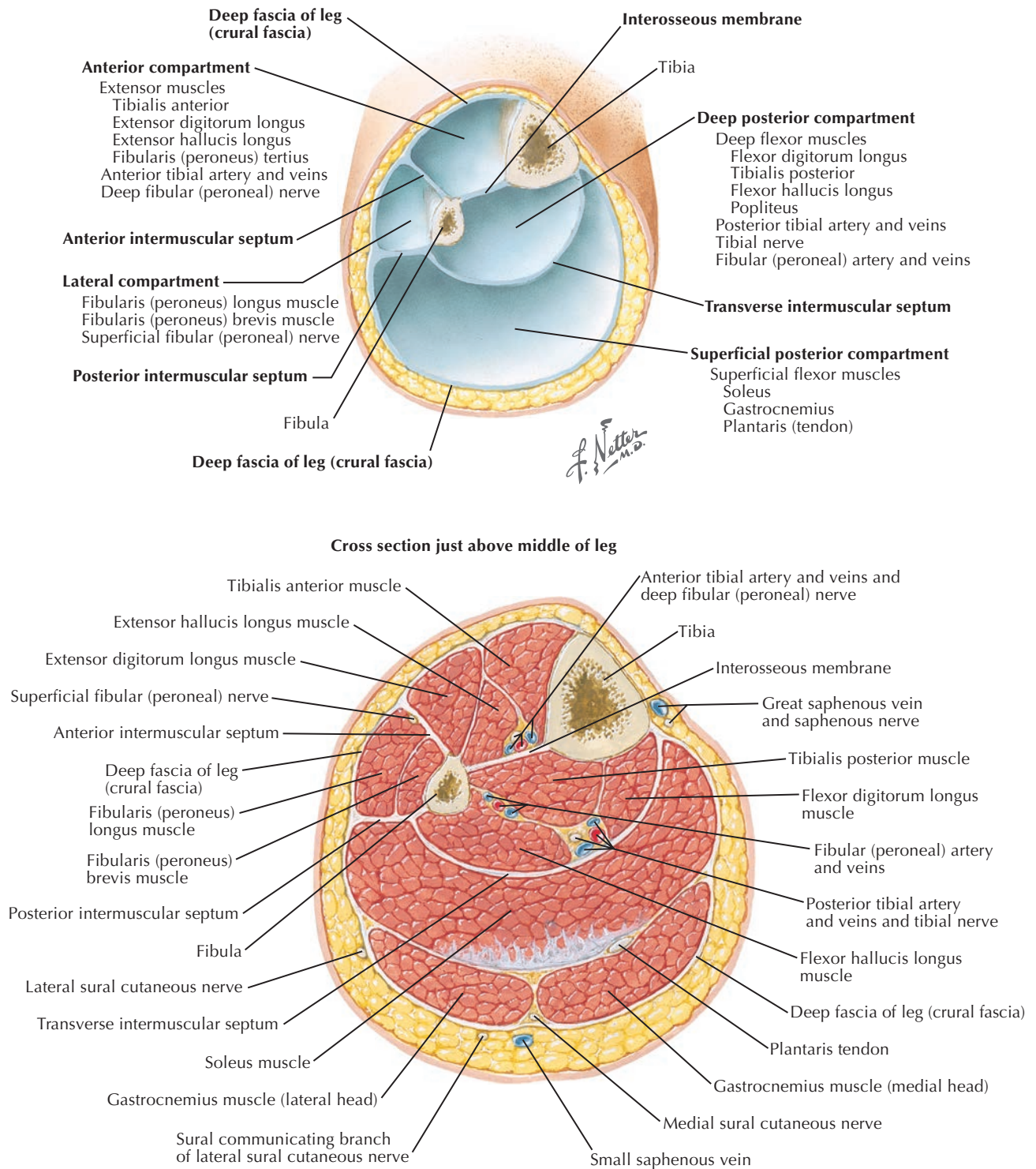


FIGURE 39-1 Fascial compartments of leg.

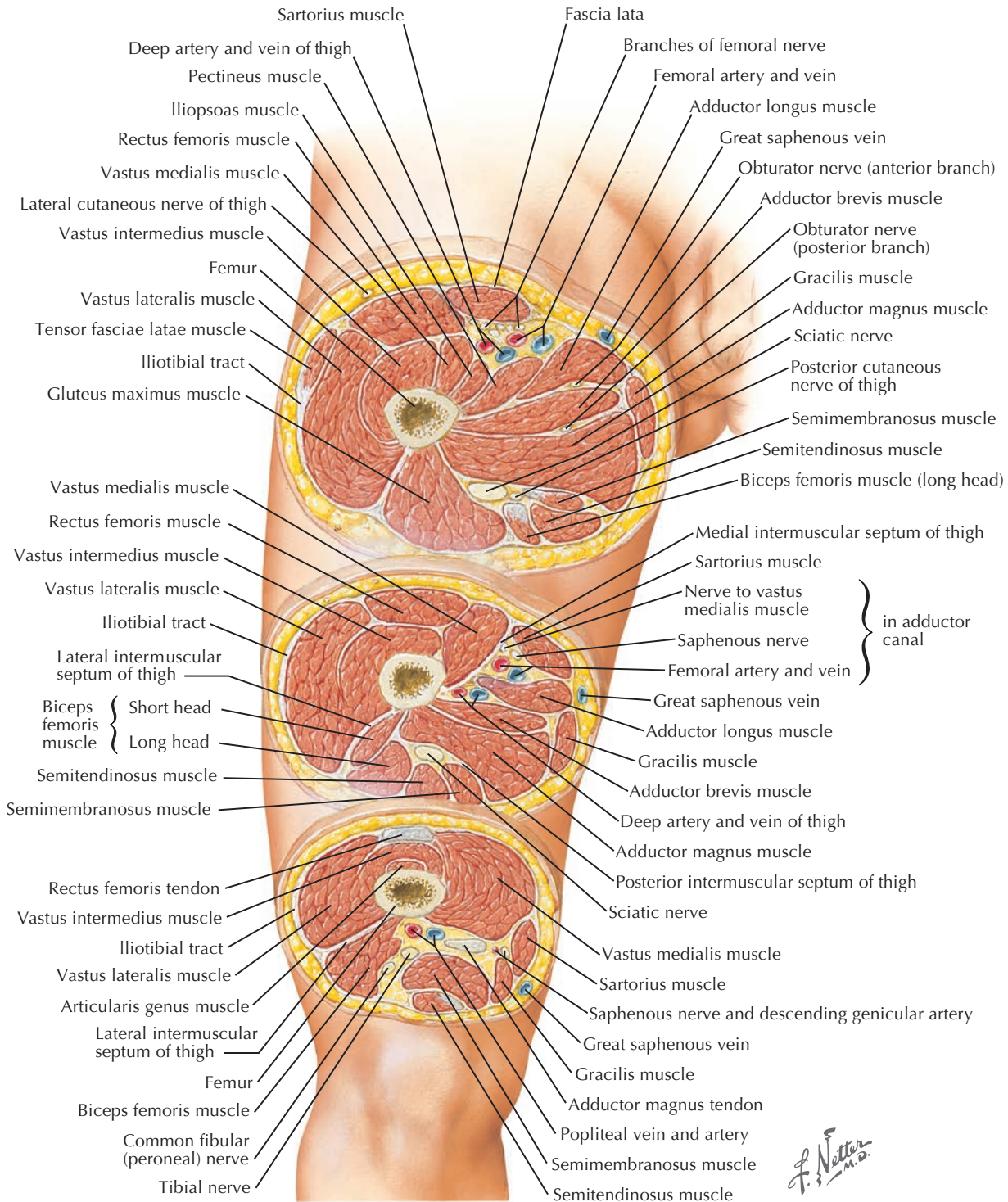
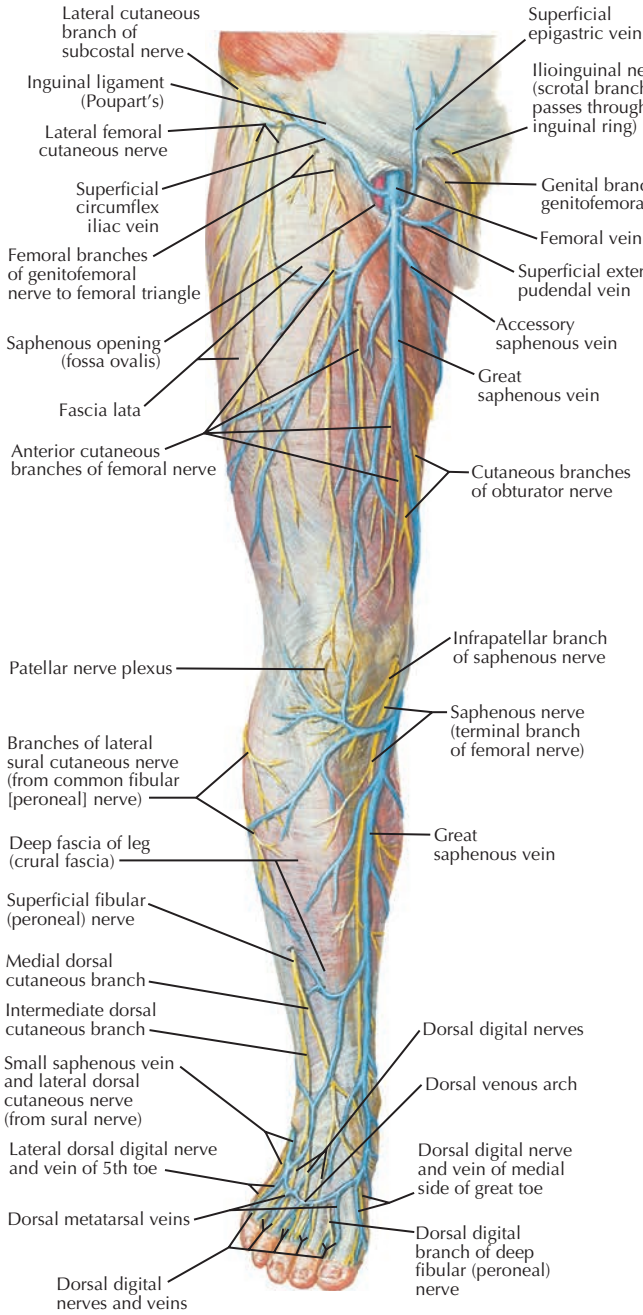


FIGURE 39-2 Cross-sectional anatomy of thigh.

Superficial nerves and veins (anterior view)



Arteries of leg

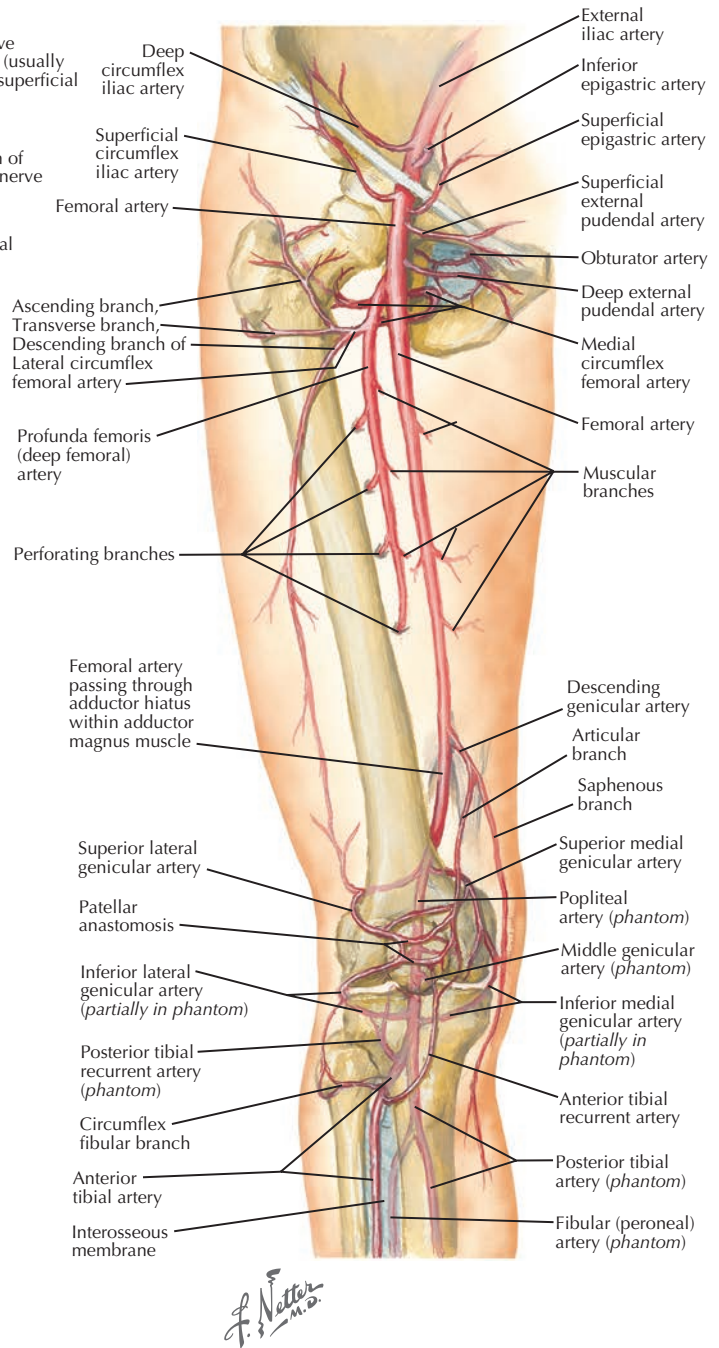


FIGURE 39-3 Arteries and veins of leg.

BELOW-KNEE AMPUTATION

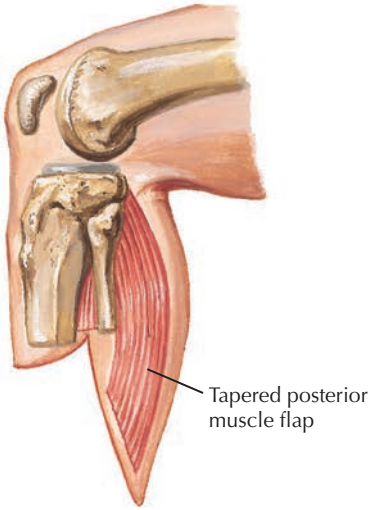
The myocutaneous skin flap can be measured or created freehand. For a typical posterior flap in below-knee amputation (BKA), the anterior skin incision is made approximately 10 cm below the tibial tuberosity to the level of the fascia (Fig. 39-4, *A*).

The skin and fascia are transected with care in the same vertical plane. The anterior compartment musculature is transected with cautery. The anterior tibial artery and vein are identified beneath these muscles, lying on the interosseous membrane with the peroneal nerve, and should be individually ligated. Medially, the musculature is transected. The tibia is dissected clear of surrounding tissues and the interosseous membrane transected. The fibula is also dissected circumferentially. The posterior skin and muscle flap are transected to fascia before bone transection, to maintain length.

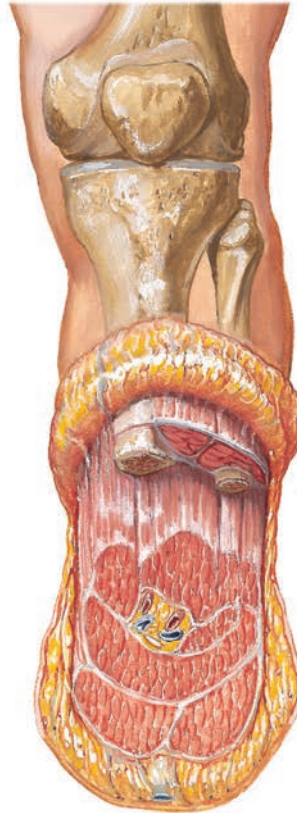The tibia is then transected at approximately the level of the skin incision by using a power saw (Fig. 39-4, *B*). The anterior tibia is beveled 60 degrees. The fibula is then transected 1 to 2 cm proximal to the tibia. This technique permits exposure of the posterior tibial and peroneal neurovascular bundles, which are individually ligated.

The posterior flap in BKA is fashioned with an amputation knife or cautery. Strict hemostasis is achieved; placement of a drain is optional. Closure is performed with absorbable fascial sutures. Special care is taken with the skin closure, using staples or nonabsorbable vertical mattress sutures (Fig. 39-4, *C and D*). A well-padded sterile dressing is applied. IPOP is an option in younger, highly motivated patients. Other BKA patients may benefit from a rapidly removable cast or knee immobilizer to minimize contracture.

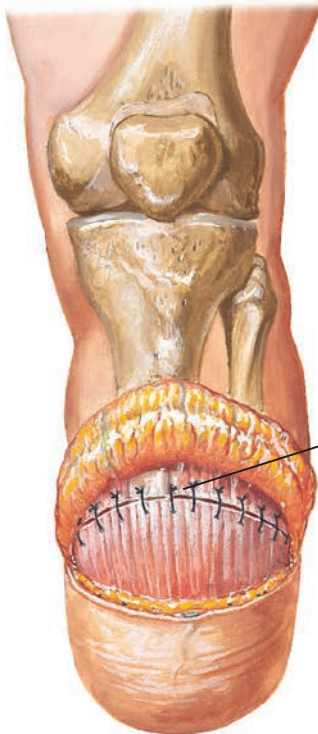
A. Below-knee amputation



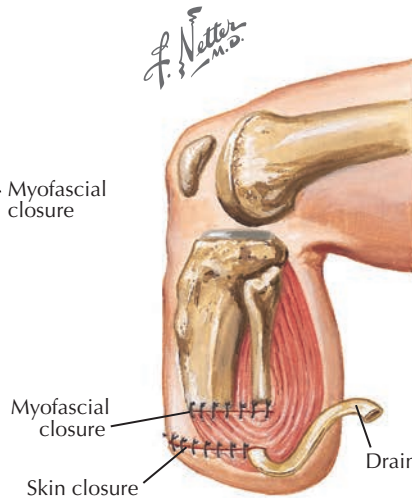
1. Short anterior and long posterior skin flaps created. Tibia and fibula resected



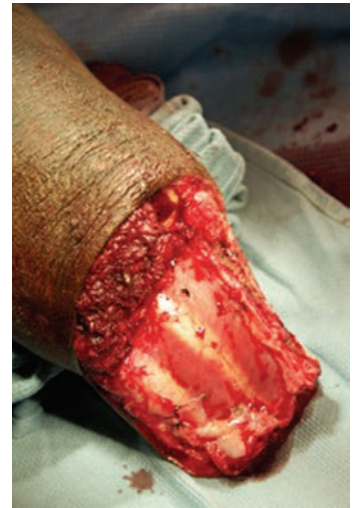2. Completed posterior muscle flap



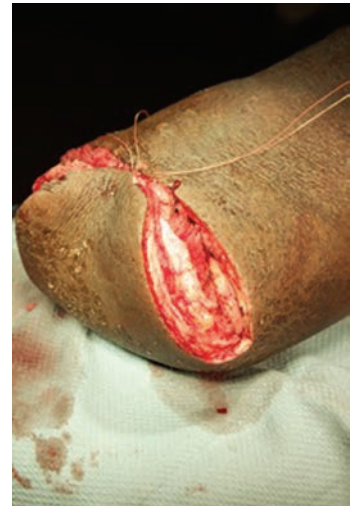3. Posterior muscle flap sutured to anterior fascia and periosteum



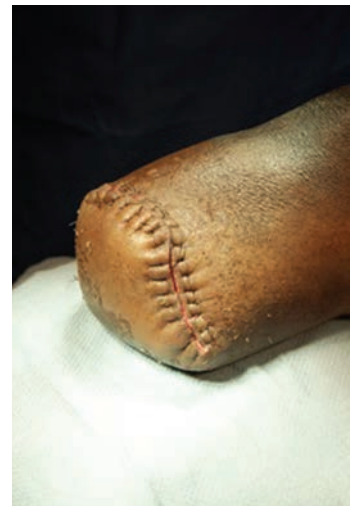4. Completed closure



B. Posterior flap



C. Fascial closure



D. Completed amputation

FIGURE 39-4 Below-knee amputation and closure.

ABOVE-KNEE AMPUTATION

The most common closure in above-knee amputation (AKA) is an anteroposterior fish-mouth incision, but as in BKA, this can be modified to obtain adequate tissue coverage (Fig. 39-5, A). A short fish-mouth incision minimizes the length of incision in AKA. The incision is carried down to the level of the fascia, which is transected. The quadriceps muscles are transected with Bovie cautery. Medial division of the sartorius muscle allows entry into the popliteal fossa, where the superficial femoral artery and vein are ligated and transected. The sciatic nerve is deep to these vessels and should be ligated and divided separately. Laterally, the iliotibial band and intermuscular septum are divided, along with the large lateral muscles.

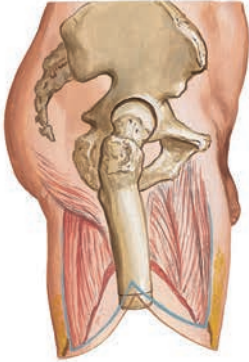The femur is dissected clear of surrounding tissues. The periosteum is raised to the appropriate level (Fig. 39-5, B). The femur is transected with a power saw. The bone should be transected generously proximal to the skin incision, allowing for skin retraction during healing and avoiding tension on the distal incision by the remaining femur. The posterior flap is then fashioned with an amputation knife or cautery. The sciatic nerve is ligated as far proximal as possible, then allowed to retract with transection.

Strict hemostasis is achieved with cautery and silk ligatures in the AKA patient. The fascia is approximated with absorbable sutures; the skin is closed with staples or nonabsorbable suture (Fig. 39-5, C and D). A padded sterile dressing is applied with a final application of an impervious dressing.

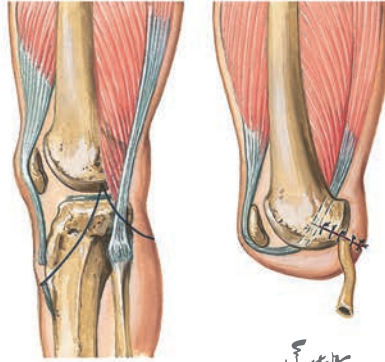
POSTOPERATIVE CARE

The use of barrier occlusive dressing is recommended to avoid postoperative soiling. Early indications to evaluate the amputation site include significant pain, hematoma, and unexplained fever; otherwise the initial operative dressing is maintained for 5 days. Proper positioning of the stump and use of knee immobilizers or IPOP to prevent contracture are imperative. Early transfer to rehabilitation minimizes deconditioning and optimizes functional outcome in the patient with lower-extremity amputation.

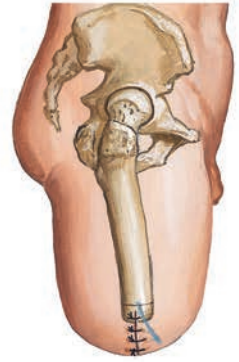A. Above-knee amputation



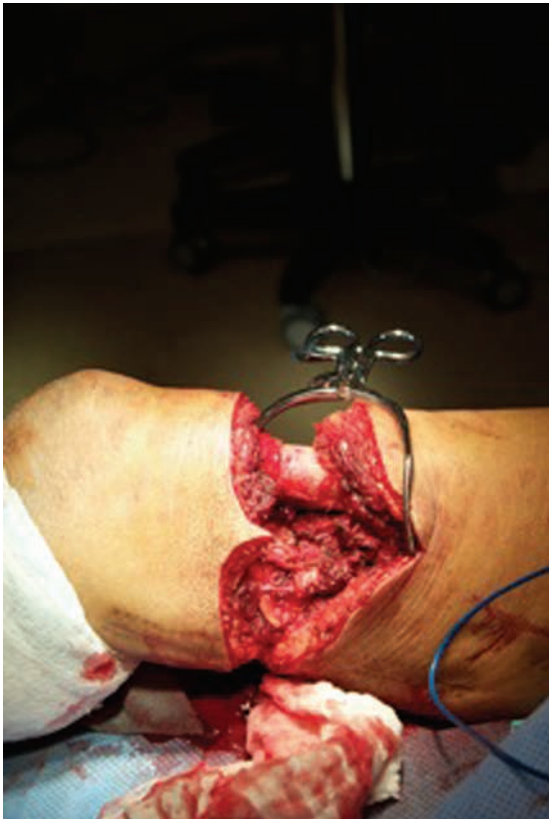Skin and myofascial flaps tailored for closure



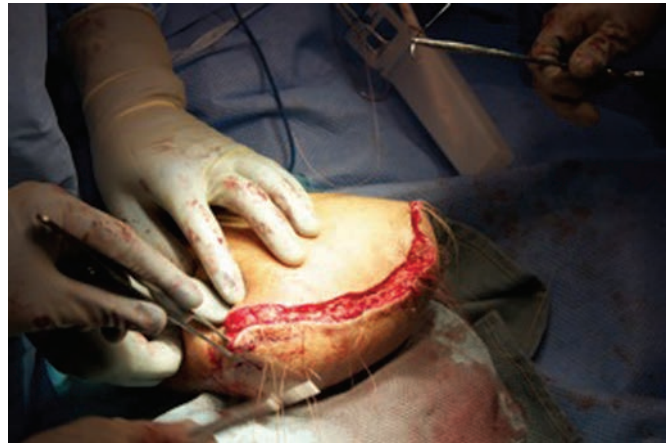F. Netter M.D.



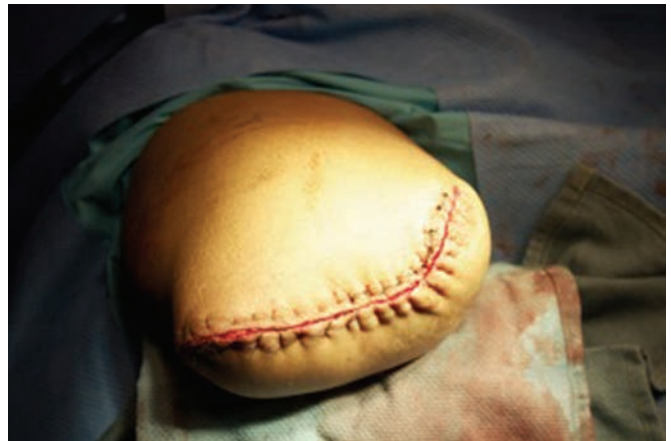Myofascial and skin flaps closed over drain



B. Anterior posterior fish-mouth incision



C. Fascial closure



D. Completed amputation

FIGURE 39-5 Above-knee amputation and closure.

SUGGESTED READINGS

- Eidt JF, Kalapatapu VR. Lower extremity amputation: techniques and results. In: Cronenwett J, Johnston KW, editors. Rutherford's vascular surgery, 7th ed. Philadelphia: Saunders; 2010.
- Goodney PP, Holman K, Henke PK, et al. Regional intensity of vascular care and lower extremity amputation rates. *J Vasc Surg.* 2013 Feb 1. [Epub ahead of print]
- Robinson KP. Amputations in vascular patients. In: Bell PRF, editor. Surgical management of vascular disease, Philadelphia: Saunders; 1992.

Central Line Anatomy

Mark A. Malangoni

INTRODUCTION

Understanding the anatomic relationships of the large veins used for placement of central catheters is key to successful cannulation and avoidance of complications. The internal jugular, subclavian, and femoral veins can be accessed for fluid infusion, blood sampling, hemodialysis, cardiac pacemaker placement, and measurement of central venous pressures. Ultrasonography is a safe and noninvasive imaging method that can help identify the target vessels and their relationship to surrounding structures. Ultrasound allows for assessment of the patency of the target vessel and reduces complications when using the internal jugular approach. Infection or injury in the local area, distortion at the entry site, occlusion of the target vein, and an uncooperative patient are relative contraindications to line placement in these vessels.

COMMON DETAILS FOR VENOUS CATHETERIZATION

When internal jugular or subclavian vein catheterization is selected, the patient is placed in the Trendelenburg position with a roll put lengthwise between the shoulders. This position helps distend the veins, improve the line of access, and reduce the incidence of air embolism. The head is rotated slightly away from the proposed insertion site.

After the skin is prepared with a chlorhexidine-based solution, the area for insertion is draped; a cap, mask, eye protection, and sterile gowns and gloves are donned; and aseptic technique is maintained. Local anesthetic, usually 1% lidocaine, is injected into the patient's skin and surrounding tissues. The ultrasound probe should be covered with a sterile transparent sheath and sterile acoustic gel applied.

Although a variety of methods are used for central venous cannulation, this chapter describes the most common approaches.

INTERNAL JUGULAR VEIN CATHETERIZATION

The internal jugular vein is located in the triangle formed by the two heads of the sternocleidomastoid muscle and clavicle in the anterior neck (Fig. 40-1). Cannulation of the right internal jugular vein is preferred to the left vein because the right provides more direct access to the right atrium, avoids the thoracic duct, and is associated with fewer complications. The ultrasound probe is placed to position the vein in the center of the image. The surgeon differentiates the internal jugular vein from the carotid artery by noting that the vein compresses with gentle pressure.

The needle is inserted 2 to 3 cm (1 inch) above the clavicle, pointed toward the ipsilateral nipple, and maintained at a 30- to 45-degree angle during advancement. The needle can be identified parallel to the vein when the probe is placed in a longitudinal orientation, but it appears only as a dot when the probe is oriented in cross section. Gentle aspiration is applied to the connected syringe as the needle is advanced. Once nonpulsatile blood return is established, the Seldinger technique is used to pass a guidewire into the vein and then a catheter over the wire.

Ultrasound can verify that the catheter is within the lumen of the vessel. The wire is removed and the catheter is secured to the skin with sutures. The catheter tip should rest about 12 to 15 cm (5 to 6 inches) from the skin insertion site. Each port is flushed with saline solution and the presence of blood return demonstrated. A sterile dressing is applied. A chest radiograph is obtained to confirm proper placement of the catheter, which should not go beyond the junction of the superior vena cava and right atrium.

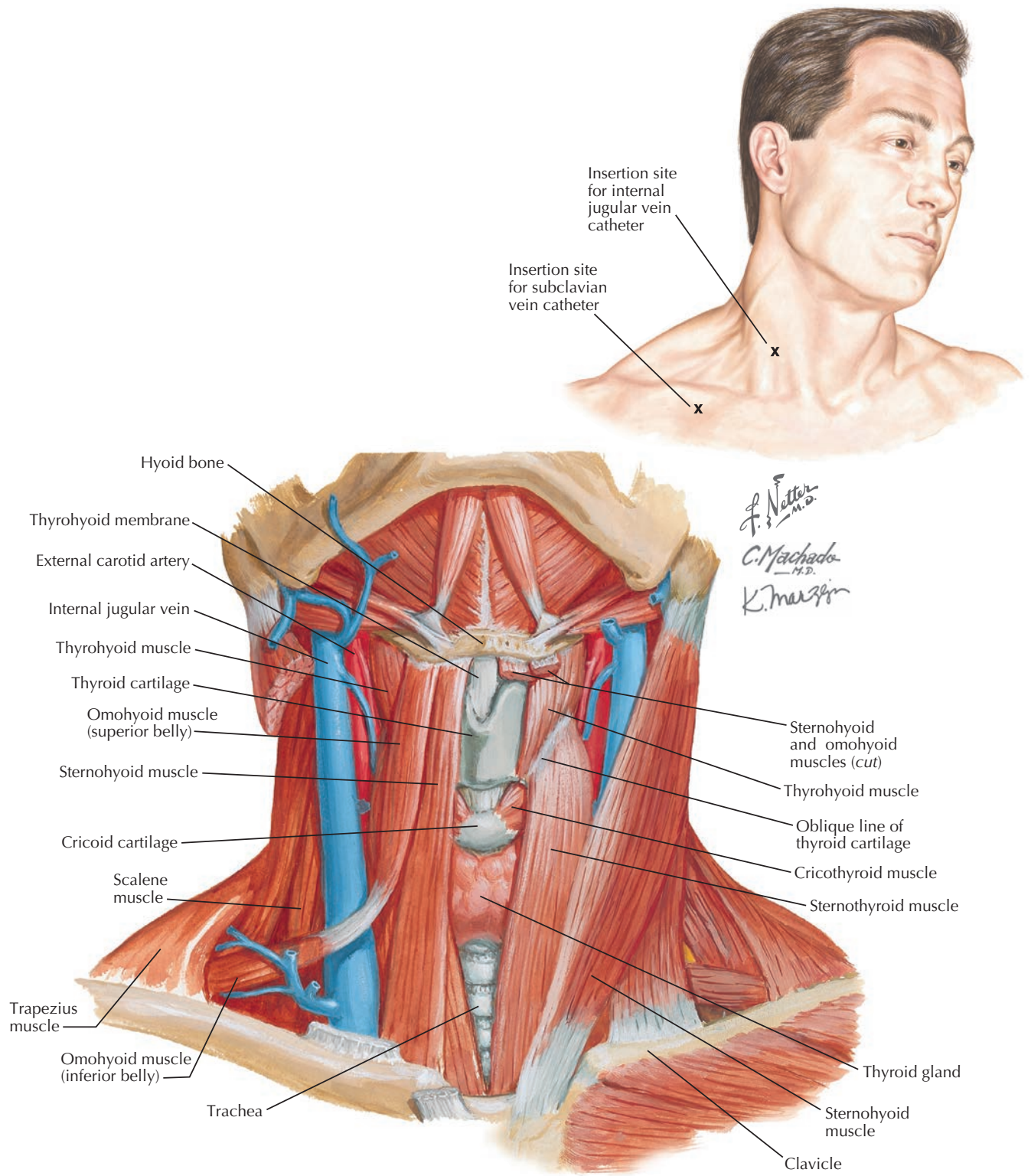


FIGURE 40-1 Internal jugular vein anatomy and insertion sites for catheterization.

SUBCLAVIAN VEIN CATHETERIZATION

The subclavian vein passes just below the point where the clavicle deviates from the 1st and 2nd ribs (Fig. 40-2). Here the vein is anterior and inferior to the subclavian artery. The needle is inserted at a point 2 cm lateral and 2 cm inferior to the junction of the middle and lateral thirds of the clavicle. The needle penetrates the skin at a 15- to 30-degree angle and can be directed toward a point 1 to 2 cm above the sternal notch.

Although not as useful as for internal jugular cannulation, an ultrasound probe can facilitate cannulation by detailing the relationship between the vein and subclavian artery. If ultrasound is used, Doppler flow may be needed to differentiate the subclavian vein from the artery. After the needle is inserted and blood return demonstrated, insertion is completed as previously described.

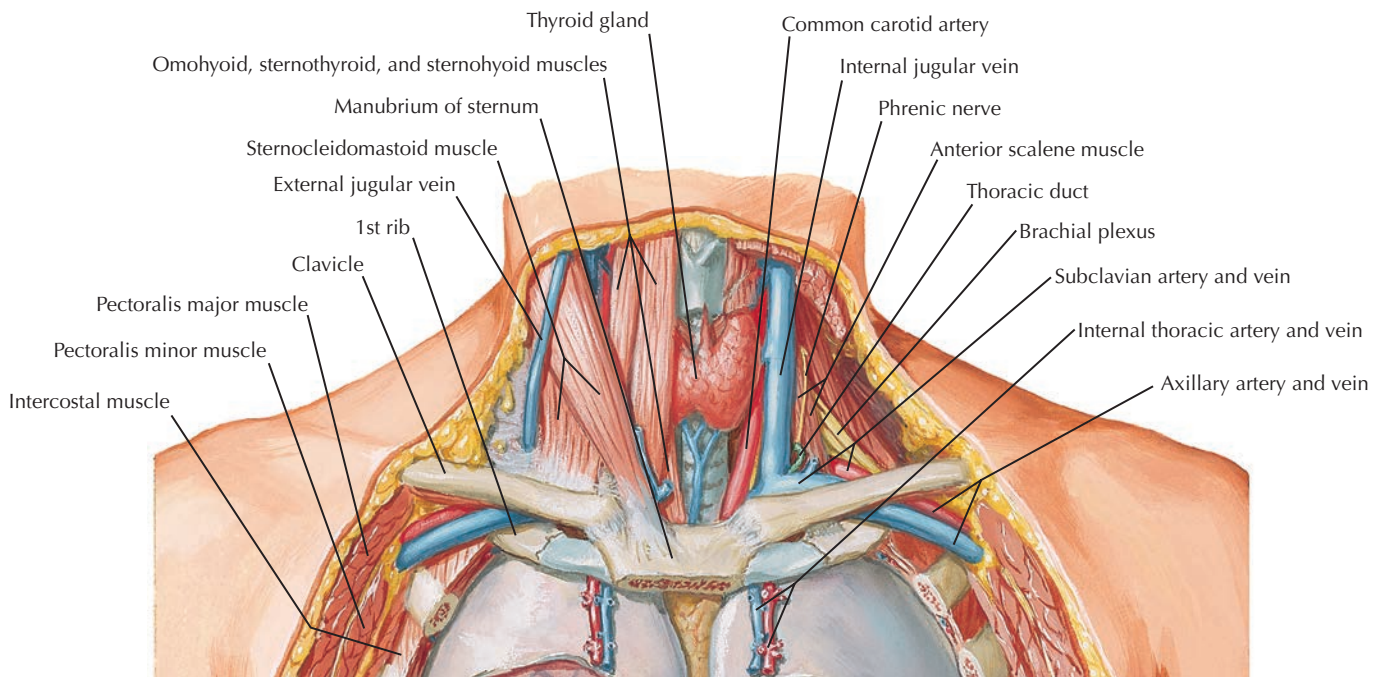
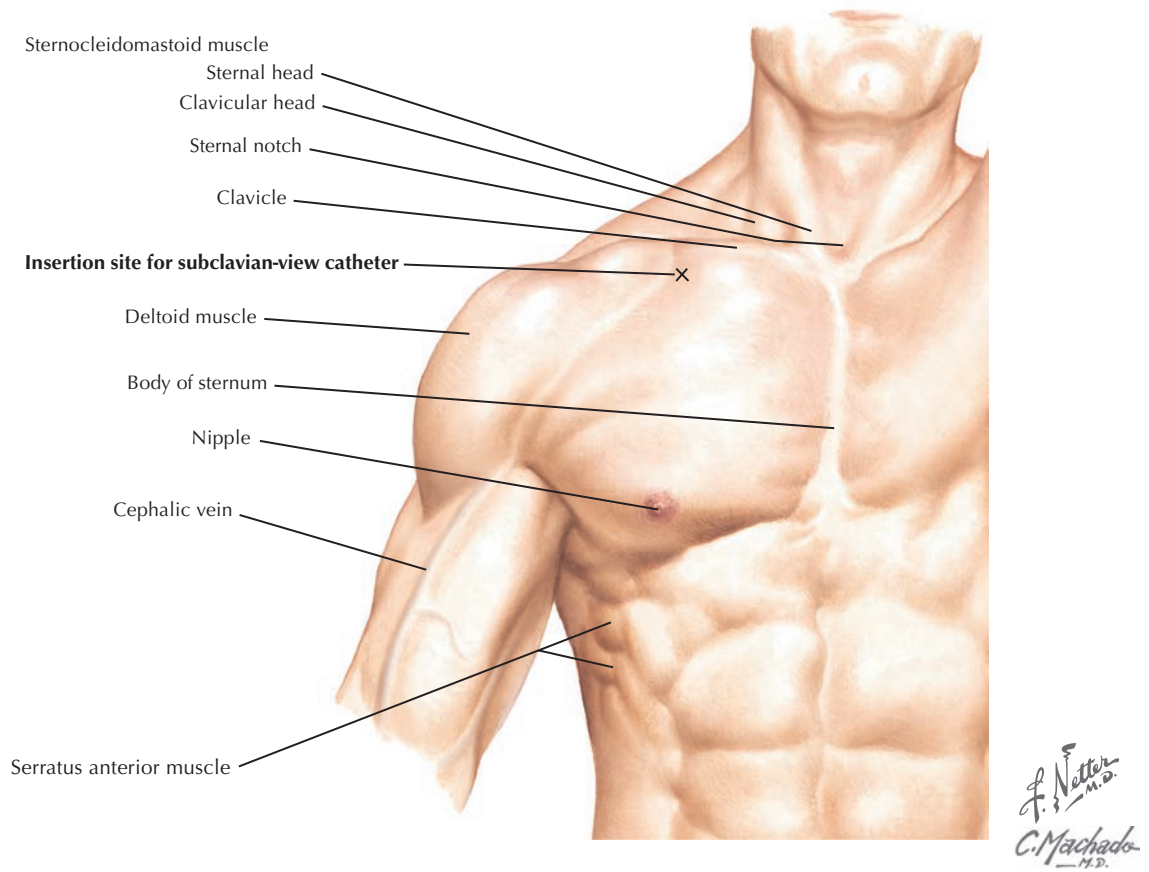


FIGURE 40-2 Subclavian vein anatomy and insertion sites for catheterization.

FEMORAL VEIN CATHETERIZATION

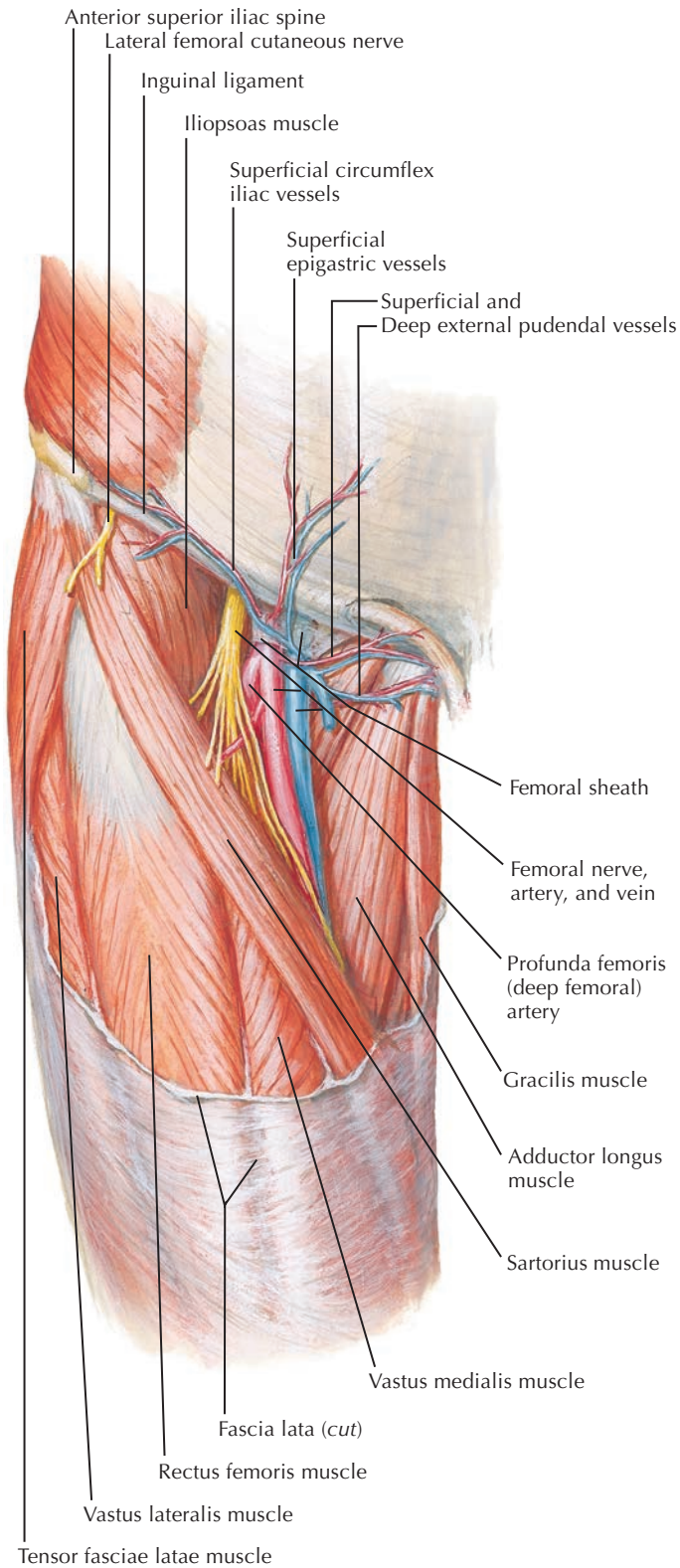
The femoral vein lies within the femoral triangle in the inguinal-femoral area (Fig. 40-3). The triangle is formed by the inguinal ligament, adductor longus muscle, and sartorius muscle. When the inguinal ligament is not easily seen, its position can be determined as it courses between the pubic tubercle and anterior superior iliac spine. The femoral artery lies at the midpoint along the course of the inguinal ligament, and the femoral vein lies medial to the artery below the inguinal ligament.

Ultrasound is useful to determine the location of the femoral vein, which can be differentiated from the artery by its more medial position and by its easy compression with the ultrasound probe. The needle is inserted at a 30-degree angle 2 to 3 cm below the inguinal ligament and directed toward the left shoulder. When blood return is established, insertion is completed as described previously.

COMPLICATIONS

The use of ultrasound guidance has reduced the incidence of catheter-related complications for internal jugular vein insertion. The common complications of central vein catheterization include misplacement of the catheter, cannulation of the artery, pneumothorax, hemothorax, localized bleeding or hematoma at the insertion site, or air embolism. Late complications include infection and thrombosis of the cannulated vein.

Femoral vein catheters should not be used in ambulatory patients because of the increased risk of catheter dislodgement and fracture. Femoral vein catheterization avoids hemothorax and pneumothorax, but the risk of infection is also increased because of the proximity of the perineum and groin, both of which harbor increased levels of bacteria.



Anterior view

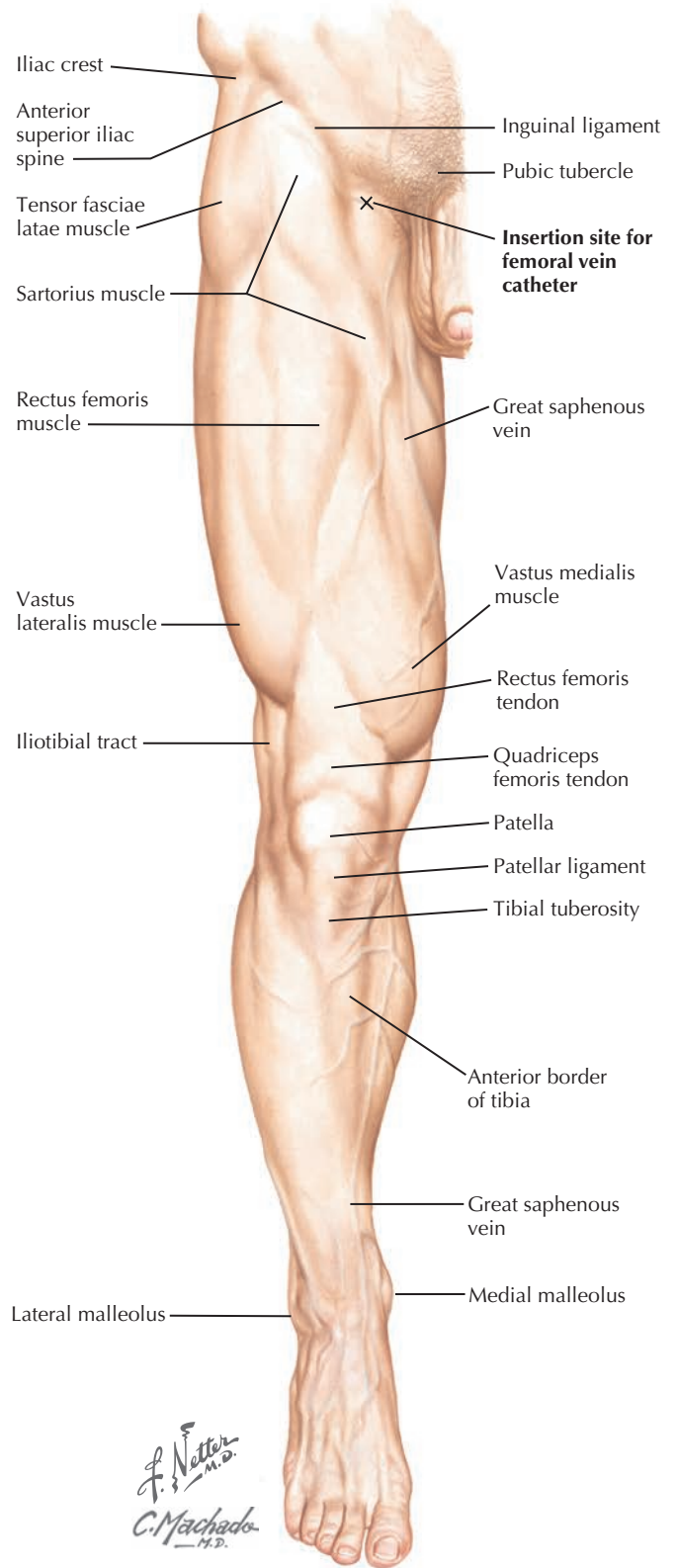


FIGURE 40-3 Femoral vein and inguinal anatomy and site for catheter insertion.

F. Netter M.D.
C. Machado M.D.

SUGGESTED READINGS

- Braner D, Lai S, Eman S, Tegtmeyer K. Central venous catheterization: subclavian vein. *N Engl J Med* 2007;357:e26.
- Kron IL, Ailawadi G. Cardiovascular monitoring and support. In Fischer JE, editor. *Fischer's mastery of surgery*, 6th ed. Philadelphia: Wolters Kluwer/Lippincott, Williams & Wilkins; 2012, pp 65-82.
- Ortega R, Song M, Hansen CJ, Barash P. Ultrasound-guided internal jugular vein cannulation. *N Engl J Med* 2010;362:e57.

Arterial Line Anatomy

John J. Como

INTRODUCTION

Arterial lines are used in the intensive care unit setting when continuous invasive blood pressure monitoring is deemed essential, or if frequent arterial blood gas levels or other laboratory determinations are needed. Arterial lines are most often placed in the radial artery, although the axillary, brachial, femoral, and dorsalis pedis arteries are also frequently accessed.

RADIAL ARTERY

The radial artery is chosen most frequently for arterial cannulation because it is readily accessible, relatively easy to cannulate, easily tested for collateral circulation, and associated with few long-term complications (Fig. 41-1). The radial artery is palpated between the distal radius and the flexor carpi radialis tendon. In this area the radial artery is covered by skin, subcutaneous tissue, and fascia only.

Ultrasound can be used to locate the radial artery when it is not palpable. Either a 20-gauge angiocatheter or an arterial line kit may be used, depending on the preference of the practitioner. The catheter is inserted at a 30- to 45-degree angle to the skin until there is pulsatile flow from the artery, at which point the catheter is advanced.

The Allen test is often used to test for collateral circulation using the ulnar artery, although its utility is questionable. To perform this test, the radial and ulnar arteries are manually occluded, preferably after a fist is made by the patient. The ulnar artery is then released, and if collateral circulation is sufficient, perfusion should return to the hand in several seconds.

On occasion, the radial artery is not available for cannulation. In these situations the practitioner must be aware of alternative sites for arterial cannulation, such as the axillary, brachial, femoral, and dorsalis pedis arteries. The technique for cannulation of these sites is similar to that of the radial artery, except that a longer catheter (12 cm) should be used for the axillary, brachial, and femoral sites. Ultrasound may also be helpful in locating these arteries.

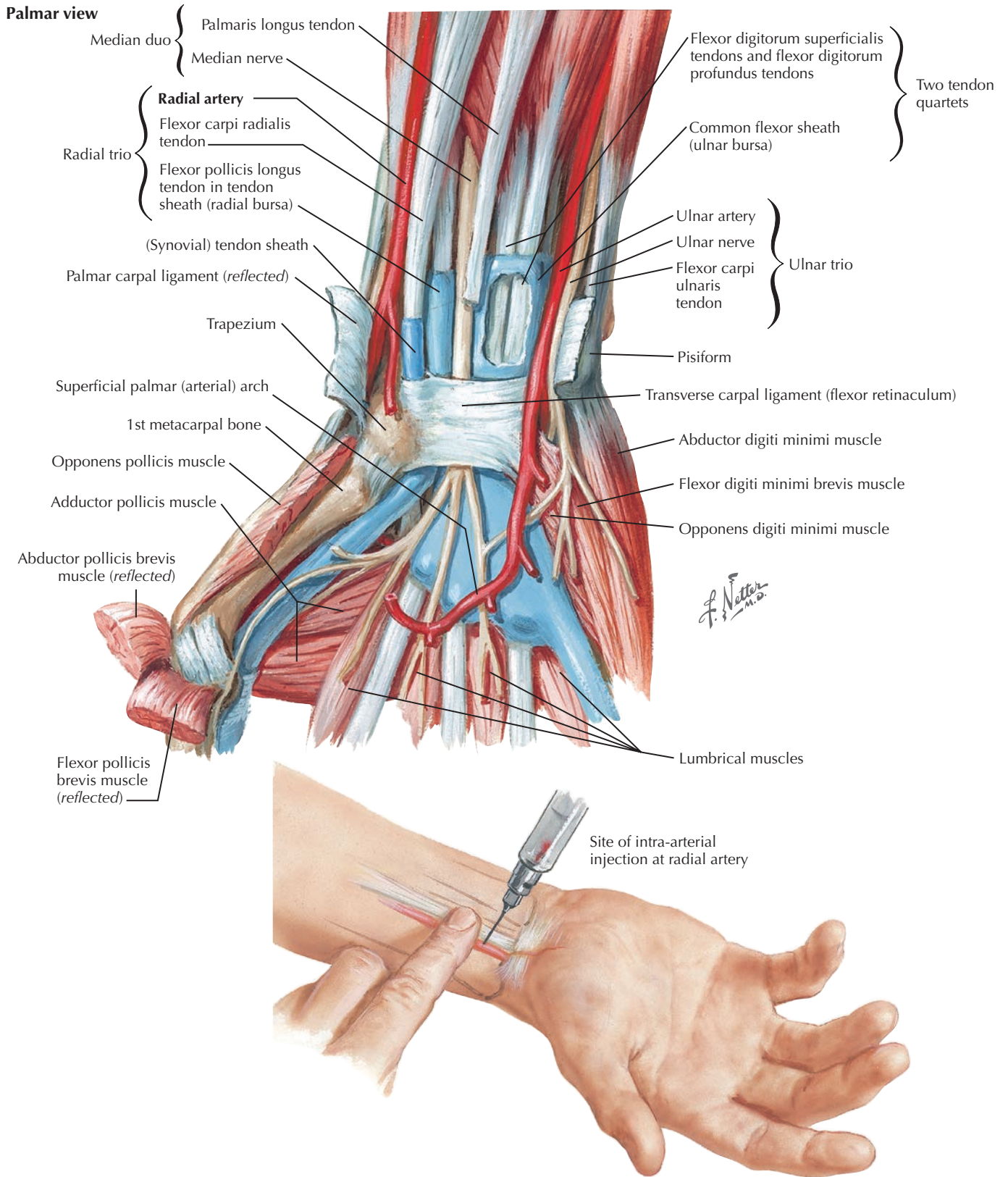


FIGURE 41-1 Arrangement of tendons, vessels, and nerves at the wrist.

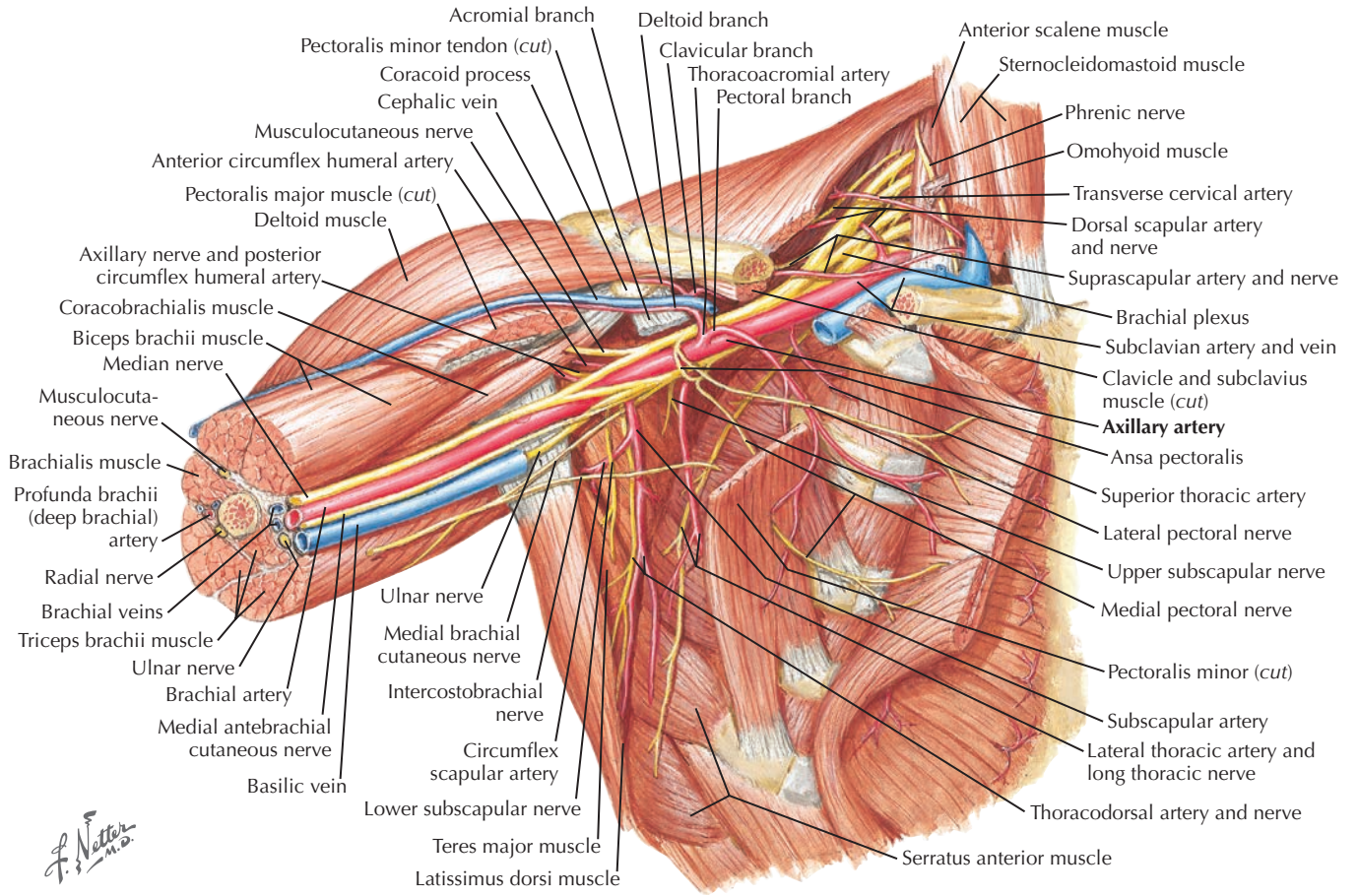
AXILLARY ARTERY

The axillary artery can be palpated in the axilla with the patient's arm elevated over the head (Fig. 41-2, A). The axillary artery lies lateral to the axillary vein throughout its course, and it is divided into three parts on the basis of its relationship to the pectoralis minor muscle. The third or most distal segment is located lateral to the pectoralis minor muscle and is available for cannulation. The close relationship between the brachial plexus and the axillary artery should be recognized because of the risk of nerve injury with axillary artery cannulation.

BRACHIAL ARTERY

At the lower border of the teres major muscle, the axillary artery becomes the brachial artery (Fig. 41-2, B). It then traverses the flexor compartment of the arm, eventually bifurcating into the radial and ulnar arteries. The brachial artery is superficial throughout its course, covered only by skin, subcutaneous tissue, and fascia, and is palpable between the biceps and triceps muscles proximal to the antecubital fossa. The brachial artery gives off numerous muscular branches and a nutrient artery to the humerus. Some of these vessels take part in the arterial anastomosis at the elbow joint. The largest branch is the profunda brachii artery. The brachial artery is accompanied by a pair of brachial veins. Although limb ischemia is a feared complication of brachial arterial lines, little evidence supports this concern.

A. Axillary artery



B. Brachial artery

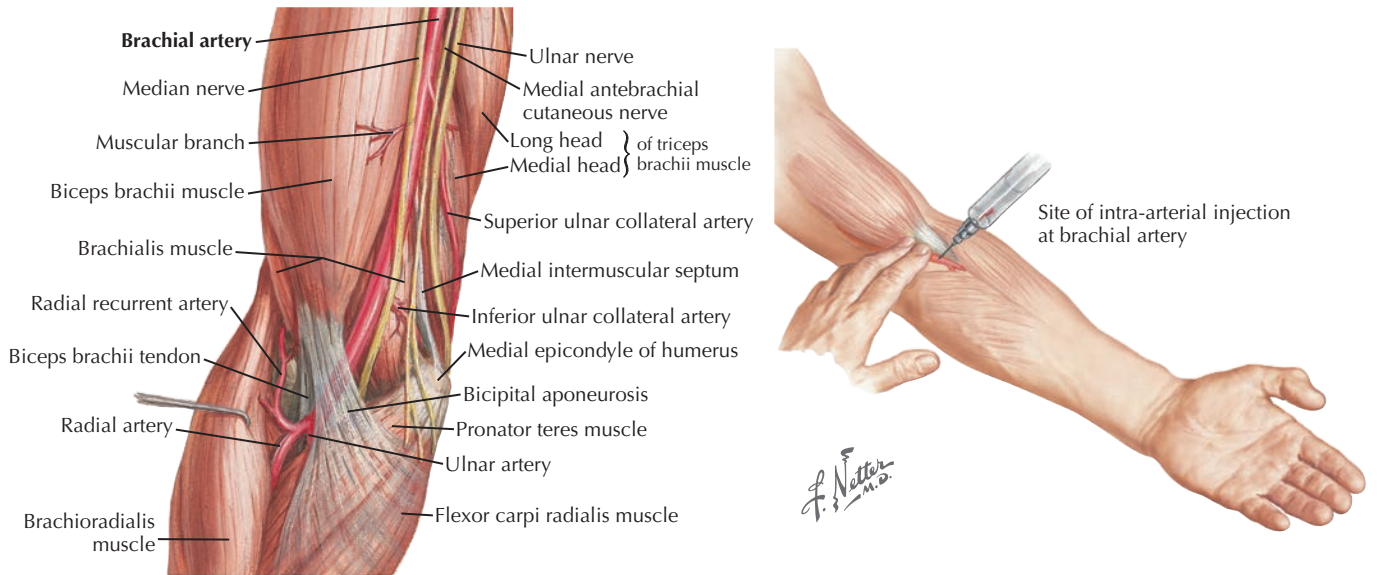


FIGURE 41-2 Axilla (dissection: anterior view) and brachial artery in situ.

FEMORAL AND DORSALIS PEDIS ARTERIES

The femoral artery is a continuation of the external iliac artery below the inguinal ligament (Fig. 41-3). It is palpable at this level at the midinguinal point, that is, halfway between the anterior superior iliac spine and the pubic symphysis. The artery courses lateral to the femoral vein and medial to the femoral nerve.

As it enters the foot, the anterior tibial artery becomes the dorsalis pedis artery (Fig. 41-4). It runs superficial to other structures over the dorsum of the foot until it passes through the first intermetatarsal space to anastomose with the plantar arch on the sole of the foot. The dorsalis pedis artery is palpable over the dorsum of the foot between the first and second metatarsal bones.

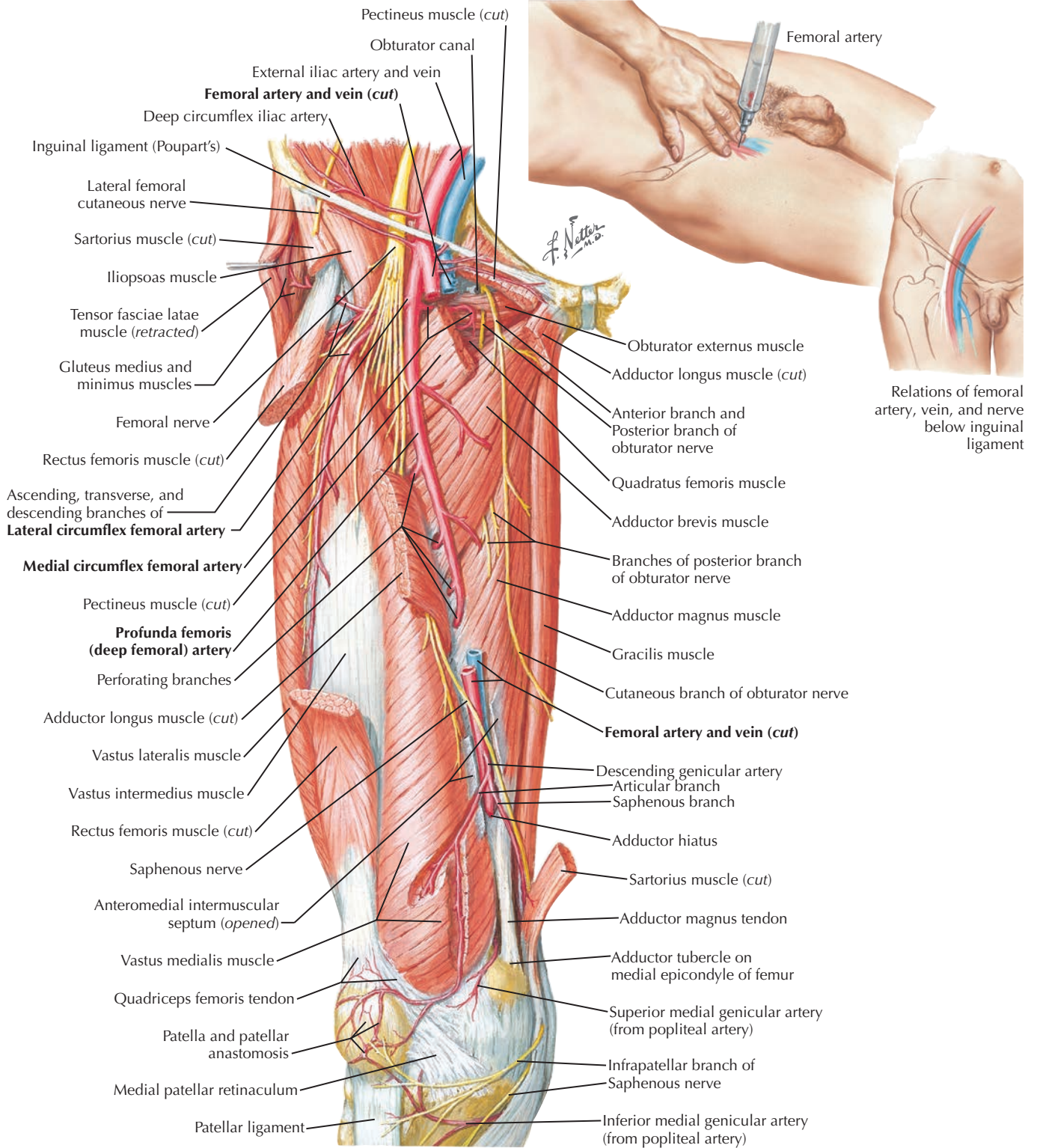


FIGURE 41-3 Arteries and nerves of thigh: deep dissection (anterior view).

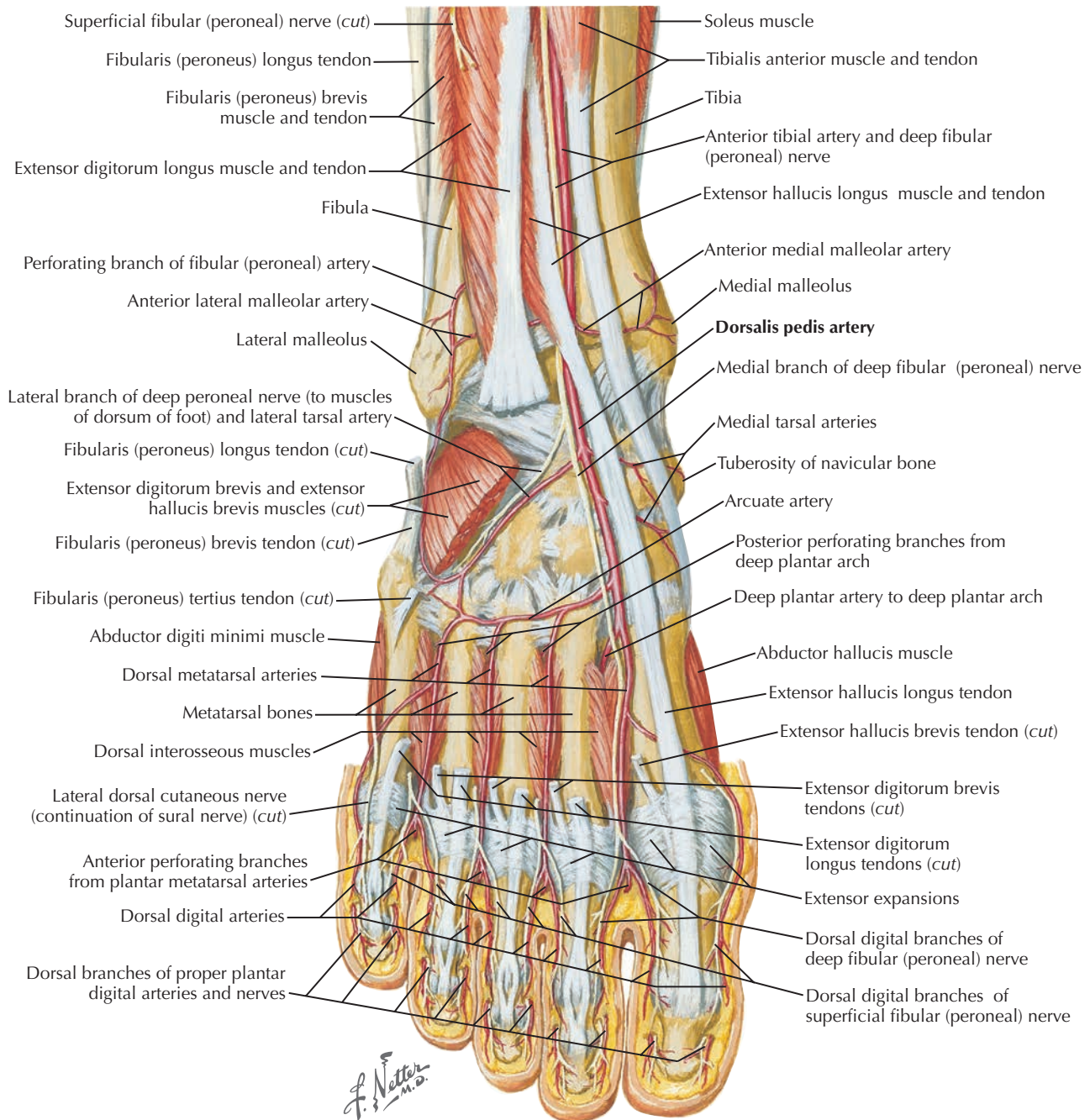


FIGURE 41-4 Muscles, arteries, and nerves of front of ankle and dorsum of foot: deeper dissection.

SUGGESTED READINGS

- Gordon LH, Brown M, Brown OW, Brown EM. Alternative sites for continuous arterial monitoring. *South Med J* 1984;77:1498-1500.
- Hall-Craggs ECB. *Anatomy as a basis for clinical medicine*, 2nd ed. New York: Urban & Schwarzenberg; 1990.
- Okeson GC, Wulbrecht PH. The safety of brachial artery puncture for arterial blood sampling. *Chest* 1998;114:748-51.
- Slogoff S, Keats AS, Arlund C. On the safety of radial artery cannulation. *Anesthesiology* 1983;59:42-7.
- Tegtmeyer K, Brady G, Lai S, Hodo R, Braner D. Videos in clinical medicine: placement of an arterial line. *N Engl J Med* 2006;354: e13. <http://www.nejm.org/doi/full/10.1056/NEJMvcm071974#figure=preview.gif>. Accessed January 23, 2011.

Leg and Forearm Fasciotomy

Christopher J. Smith and Harry A. Hoyen

INTRODUCTION

Compartment syndrome of the lower extremity is a morbid condition that can lead to limb loss, functional impairment, renal failure, and death. Fasciotomy is required to treat the syndrome and prevent or minimize complications. Compartment syndrome can develop in any anatomic compartment, but the most common site is the lower extremity, in particular the leg. The lower-extremity compartments include those of the buttocks, thigh, leg, and foot.

Compartment syndrome of the forearm and hand is usually seen after blunt trauma. Other conditions that contribute to the development of upper-extremity compartment syndromes include blood dyscrasias, clotting abnormalities, metabolic fluid shifts, longstanding compression, direct fluid injection, and infection. Increased pressure in the forearm compartments results from direct muscle injury, hematoma from soft tissue and osseous injuries, or secondary swelling. The condition can occur in the rapid acute manner or after fluid resuscitation in a seriously injured patient.

LEG FASCIOTOMY

The lower leg is divided into four compartments: anterior, lateral, superficial posterior, and deep posterior (Fig. 42-1). The anterior compartment is especially prone to ischemic injury because of its relative paucity of collateral arterial supply. Compared with the other compartments, especially the posterior compartments, the anterior compartment is also more firmly constrained. The spatial relationships among the nerve, vascular, muscular, and bony structures change from proximal to distal in the leg, an especially relevant consideration in performing complete lysis of the posterior compartments (Figs. 42-2 and 42-3).

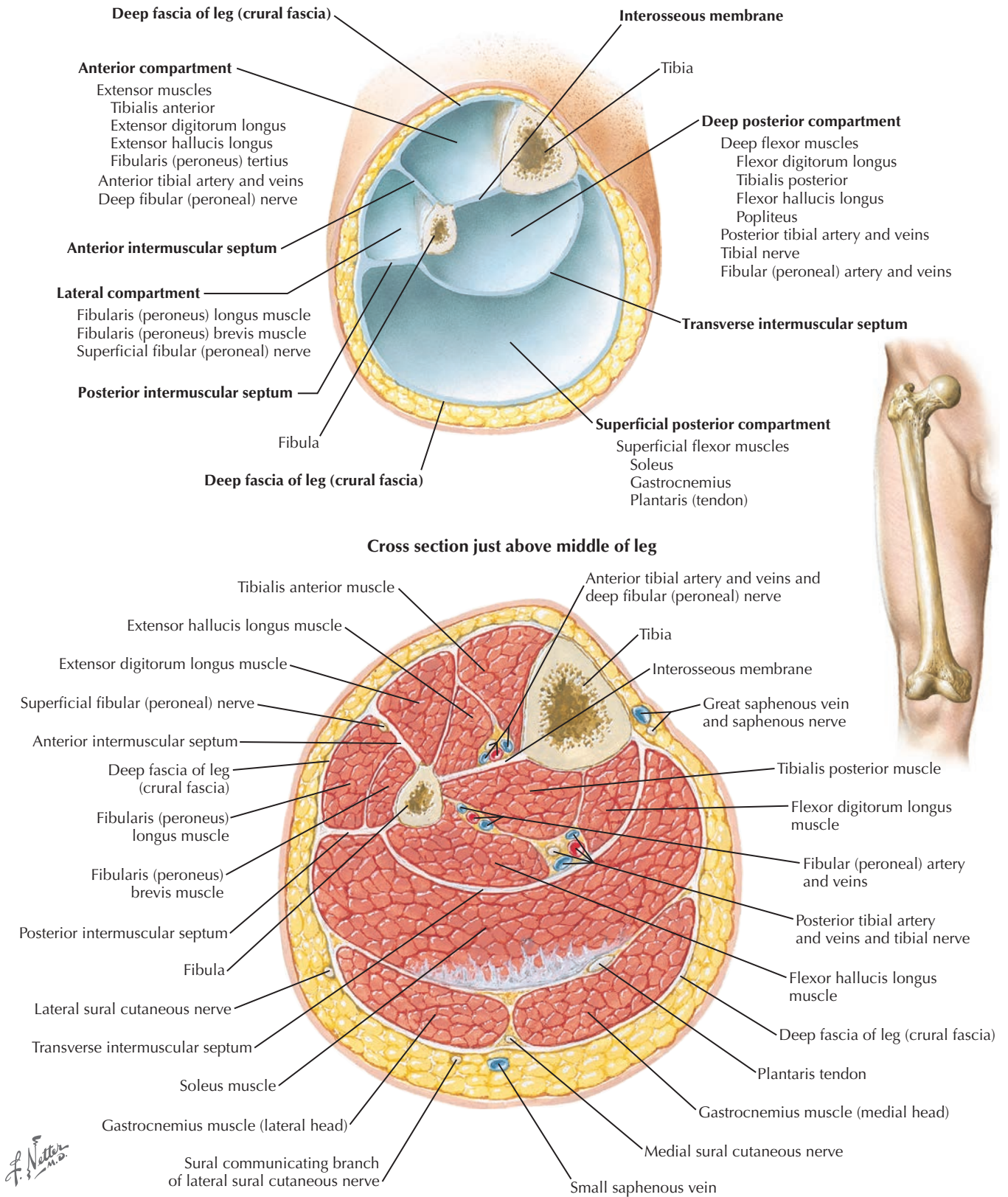


FIGURE 42-1 Cross-sectional anatomy of leg and fascial compartments.

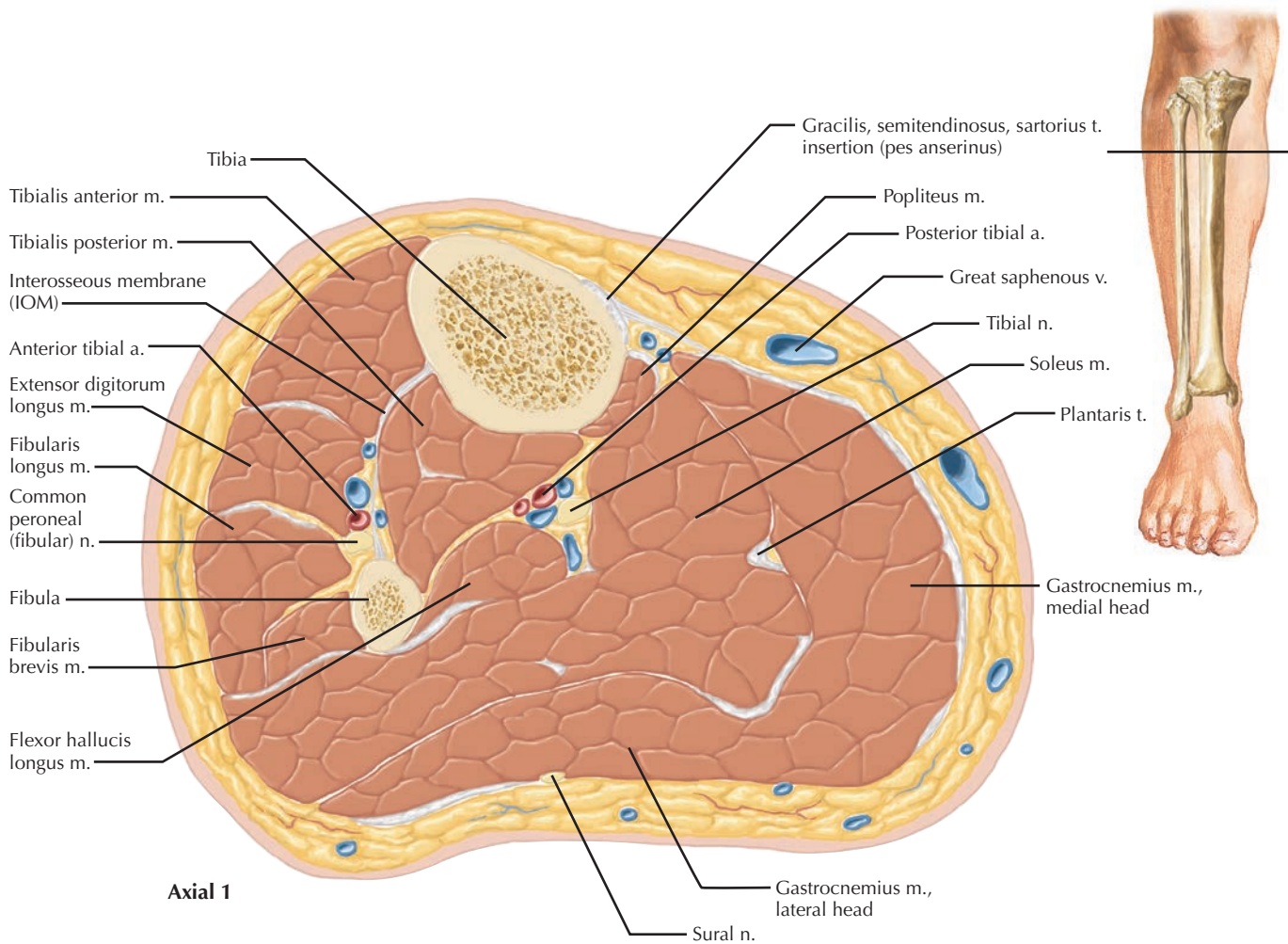


FIGURE 42-2 Cross-sectional leg anatomy, below knee.

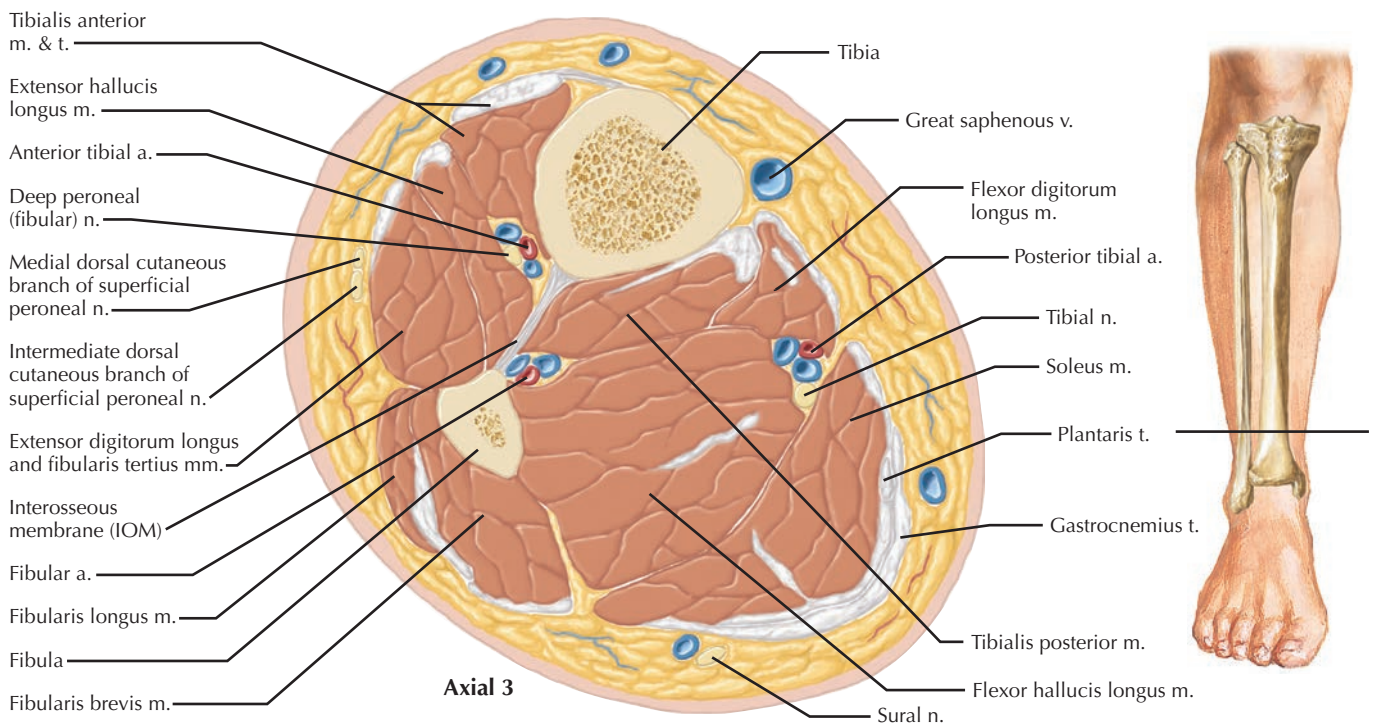
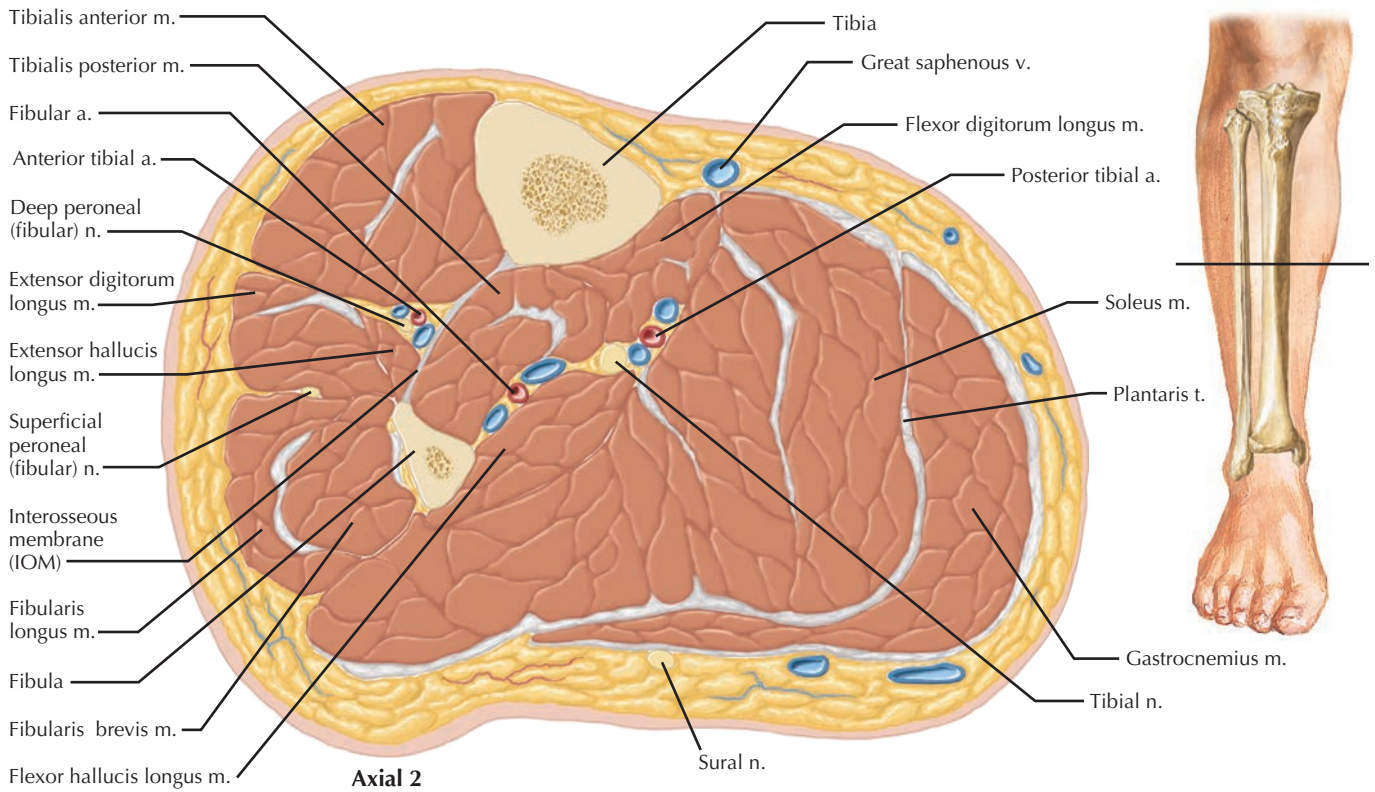


FIGURE 42-3 Cross-sectional leg anatomy, middle and lower tibia.

Etiology of Compartment Syndrome

Compartment syndrome occurs when the compartmental pressure rises sufficiently to prevent adequate tissue perfusion. This condition can result from increased volume in the compartment caused by bleeding, infiltration of exogenous fluid, or reperfusion edema (Fig. 42-4). Increased compartment pressures can also result from external constraint on the compartment, such as with casts, braces, or bandages. A compartment pressure greater than 30 mm Hg is accepted as sufficiently elevated to cause compartment syndrome. This pressure is usually sufficient to restrict venous outflow from the compartment, thereby leading to further increases in compartment pressure.

Compartment syndrome can occur at lower compartment pressures, especially in the patient with hypotension. In clinical practice, compartment syndrome more often occurs in the setting of reperfusion after arterial revascularization for acute, limb-threatening ischemia, as well as in the trauma patient. Reperfusion injury after arterial revascularization is more common after a longer period of ischemia, and prophylactic fasciotomy should be considered when acute ischemia lasts longer than 4 to 6 hours. In the injured extremity, contributing factors to development of compartment syndrome include intracompartmental bleeding, crush or blast injury, and arterial insufficiency from direct vascular injury or shock. In the trauma patient, concomitant venous injury may also lead to venous hypertension, further increasing the risk of compartment syndrome.

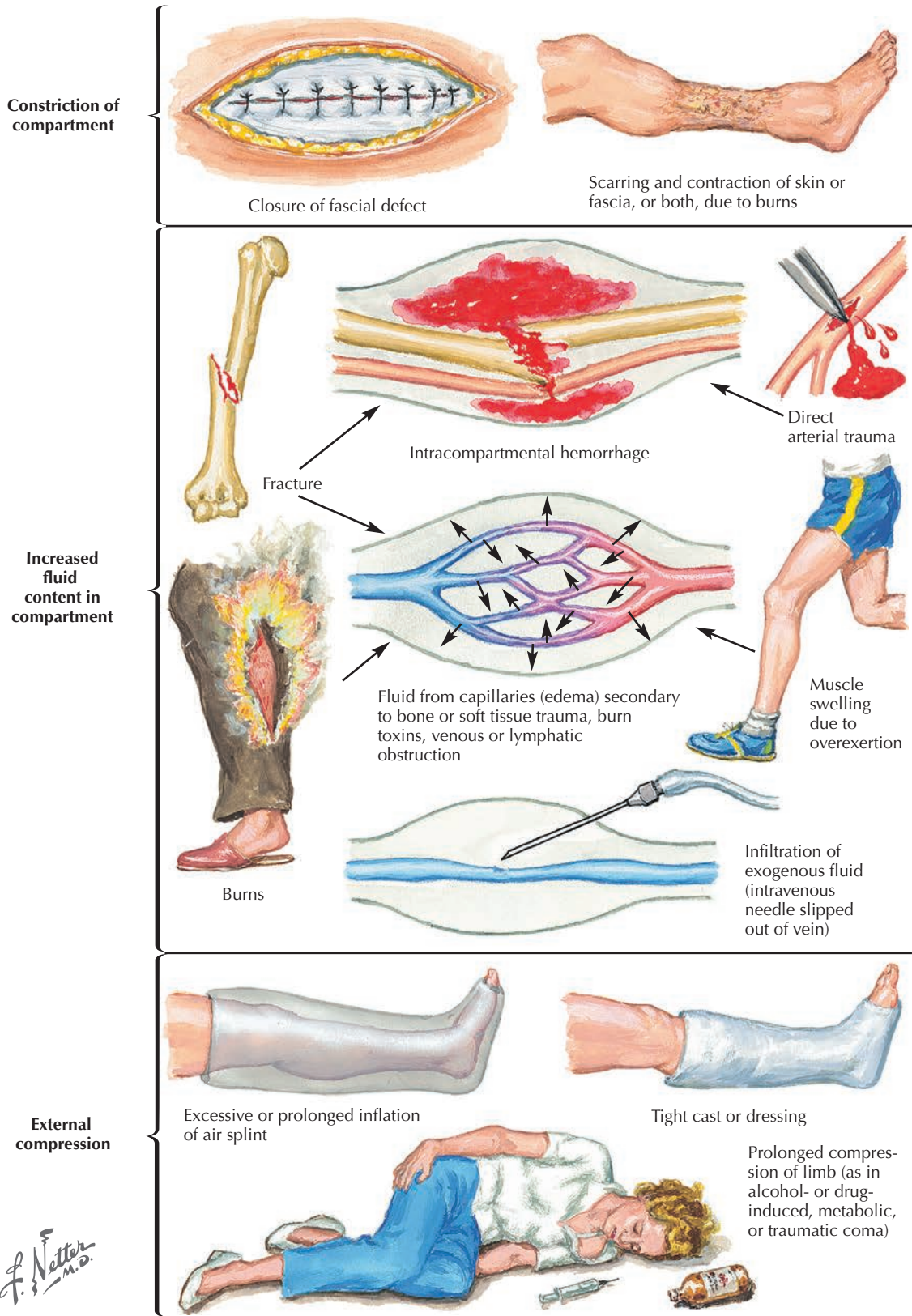


FIGURE 42-4 Etiology of compartment syndrome.

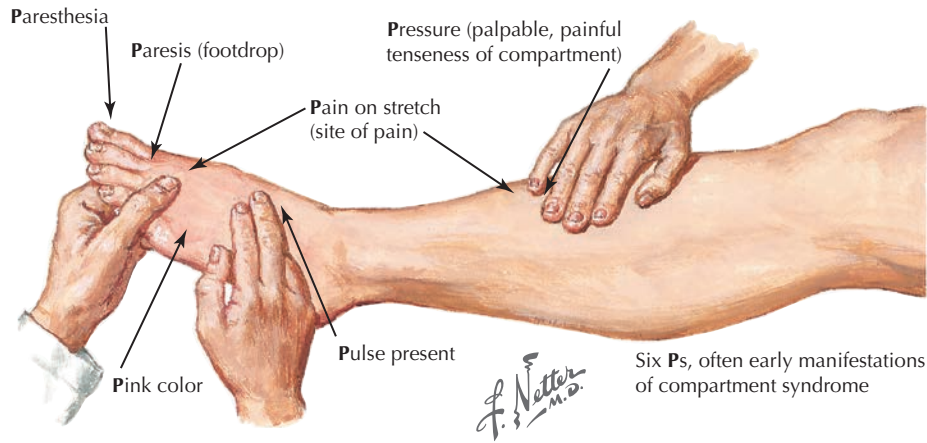
Clinical Diagnosis and Decision Making

In the appropriate clinical setting, compartment syndrome should always be considered. Pain is the most prevalent symptom, but the patient may report diminished motor strength and altered or reduced sensation (Fig. 42-5). Pain with passive movement and palpation is extremely common, although the absence of pain in the extremity with compromised neurologic function can be misleading.

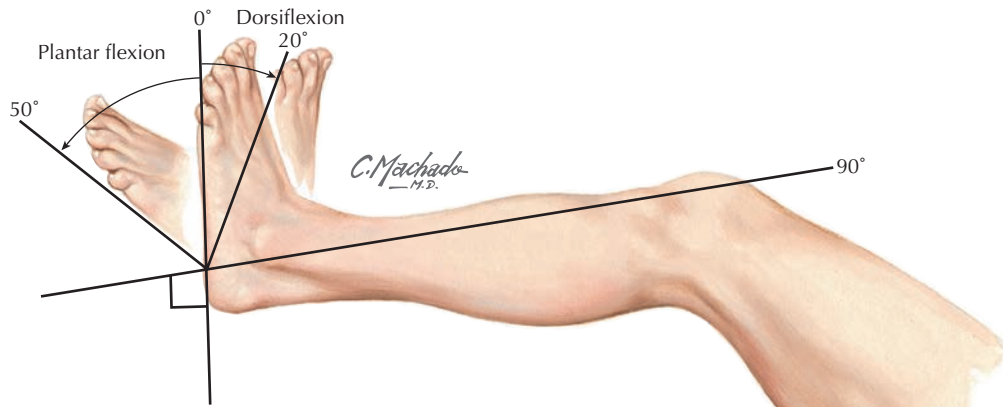
Findings consistent with arterial insufficiency are not always present, so their absence does not exclude the presence of compartment syndrome. Therefore the presence of palpable pedal pulses (dorsalis pedis artery, posterior tibial artery) does not rule out the diagnosis of compartment syndrome. Because neuronal tissue is sensitive to ischemia, peripheral nerve dysfunction is common in the patient with compartment syndrome and is caused by neuronal ischemia. Diminished motor strength can be tested by assessing dorsiflexion and plantar flexion of the great toe and the ankle, which reflect function of the major muscle groups the leg.

Light touch sensation is often diminished before the development of motor weakness and can best be tested in the web space between the first and second toes. Touch sensation reflects the function of the deep peroneal nerve (Fig. 42-6).

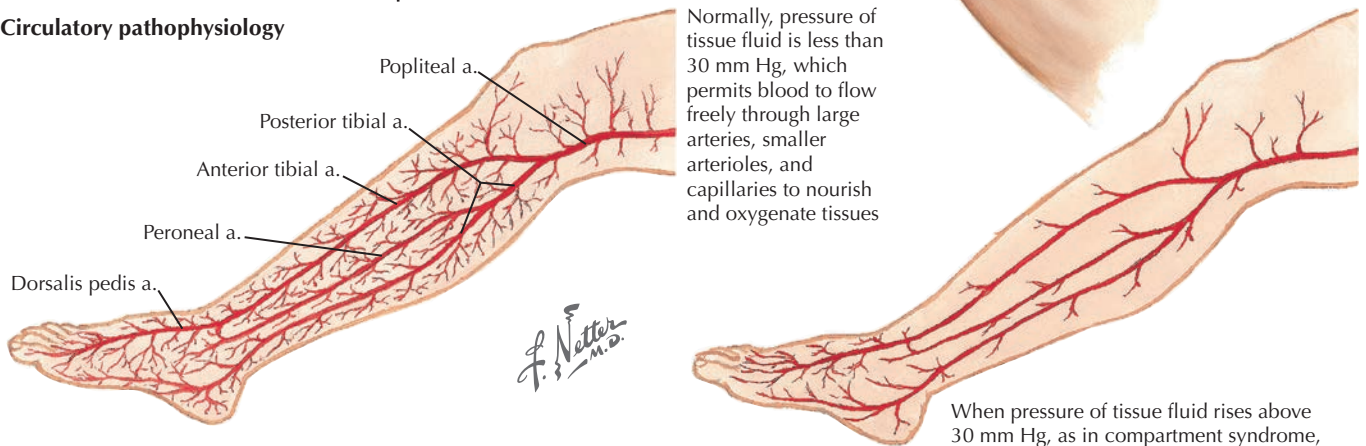
When findings are equivocal, compartment pressure can be measured by introducing a needle or intravenous catheter into the compartment(s) and directly measuring the pressure (Fig. 42-7). The decision to perform fasciotomy is made on the basis of the index of suspicion, clinical findings, and presence of increased compartment pressure. In the appropriate clinical setting with positive physical findings, compartment pressure measurements are not required to justify fasciotomy.



Six Ps, often early manifestations of compartment syndrome



Circulatory pathophysiology



Normally, pressure of tissue fluid is less than 30 mm Hg, which permits blood to flow freely through large arteries, smaller arterioles, and capillaries to nourish and oxygenate tissues

When pressure of tissue fluid rises above 30 mm Hg, as in compartment syndrome, small nutrient arterioles and capillaries compressed. Flow in larger, more resistant arteries persists. Pulse may therefore be palpable despite tissue ischemia, giving false impression of adequate circulation.

Differential diagnosis			
	Compartment syndrome	Arterial occlusion	Neurapraxia
Pressure increased in compartment	+	-	-
Pain on stretch	+	+	-
Paresthesia or anesthesia	+	+	+
Paresis or paralysis	+	+	+
Pulses intact	+	-	+

FIGURE 42-5 Clinical diagnosis of compartment syndrome.

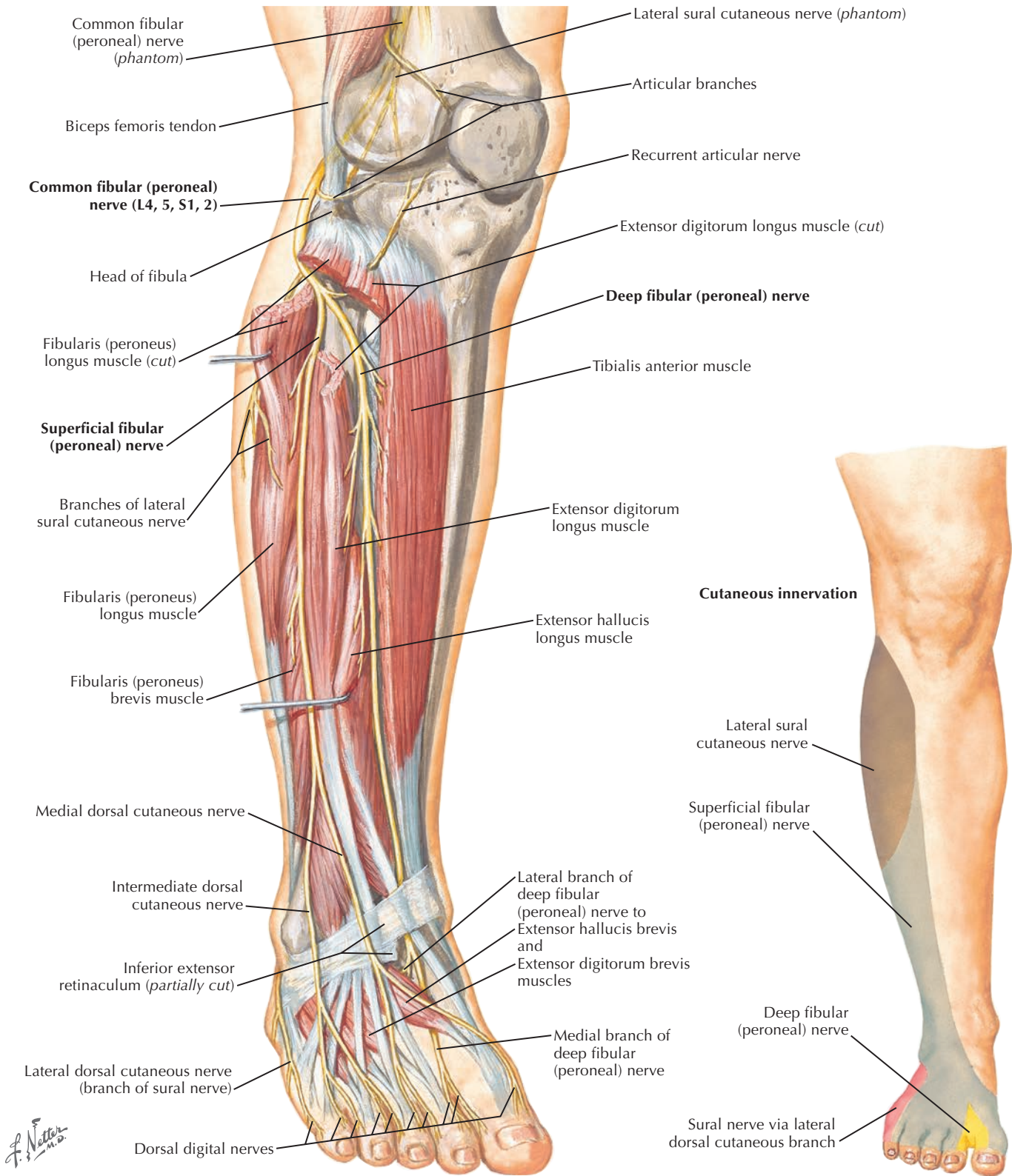
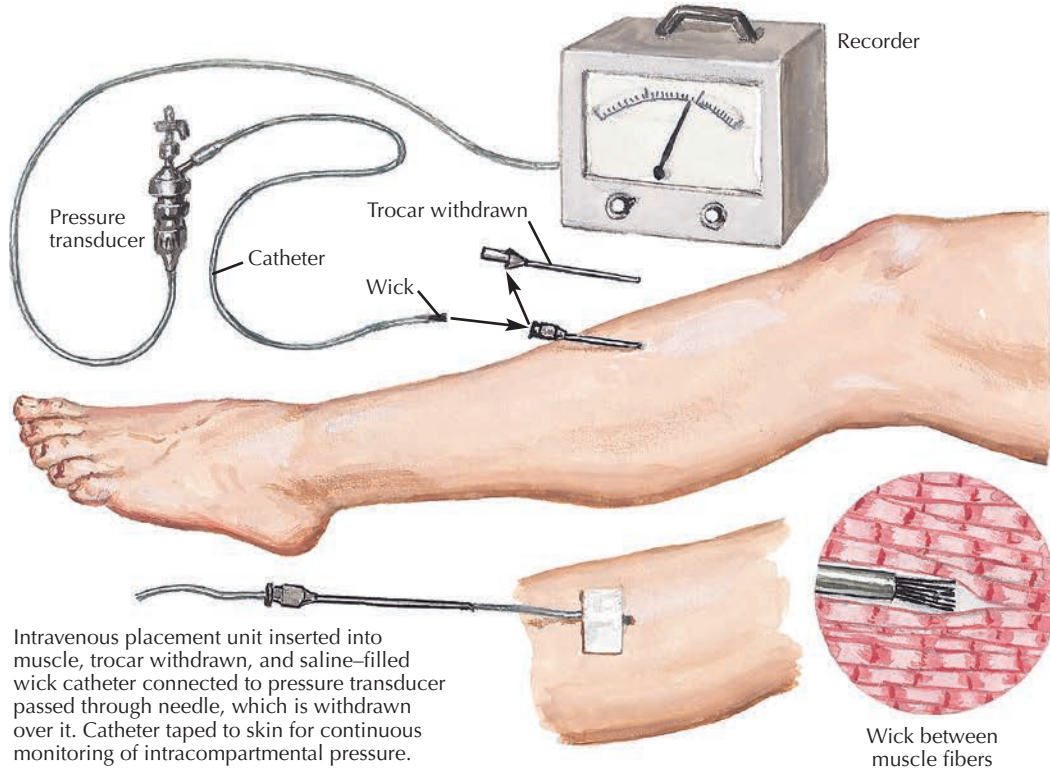


FIGURE 42-6 Common fibular (peroneal) nerve: mixed motor/sensory function.

Wick catheter technique



Slit catheter technique

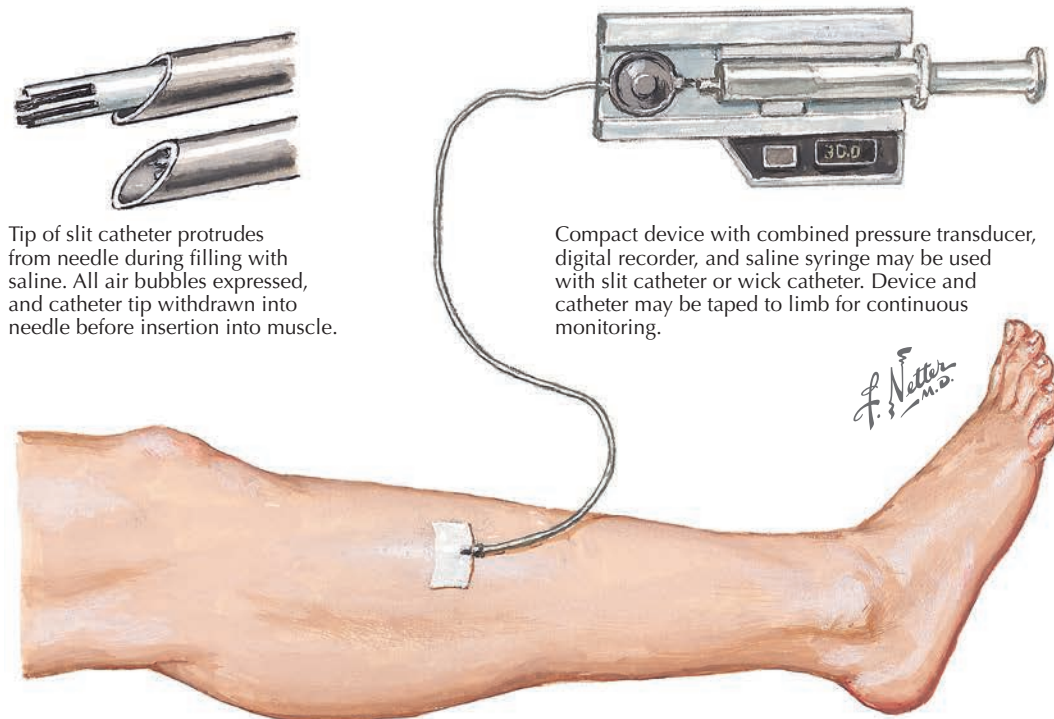


FIGURE 42-7 Measurement of intracompartmental pressure.

Surgical Principles

The fundamental objective of fasciotomy is to decompress the involved compartment(s) completely. Complete lysis of the containing compartmental fascia is mandatory to allow for adequate expansion of the involved soft tissues. Direct visualization of the fascial envelope is required, and the fasciotomy must extend the entire length of the compartment. Partial lysis of the compartment may provide incomplete decompression and contribute to further morbidity. Inadvertent injury to peripheral nerves can also occur as a result of fasciotomy.

Surgical Anatomy and Technique

Fasciotomy in the leg can be achieved with a single lateral incision. More frequently, both medial and lateral incisions are used (Fig. 42-8). The medial incision is used to decompress the posterior compartments, and the lateral incision addresses the anterior and lateral compartments. The medial incision is made approximately 1 to 2 cm posterior to the medial margin of the tibia.

The posterior deep and superficial compartments are incised along the length of the leg, essentially from the proximal tibia to the medial malleolus. The long saphenous vein and its tributary branches may be encountered in the surgical field, and care should be taken to avoid injury to these vessels. The venous tributaries can be ligated and divided as needed, allowing the saphenous vein to be reflected either anteriorly or posteriorly to facilitate adequate fascial lysis.

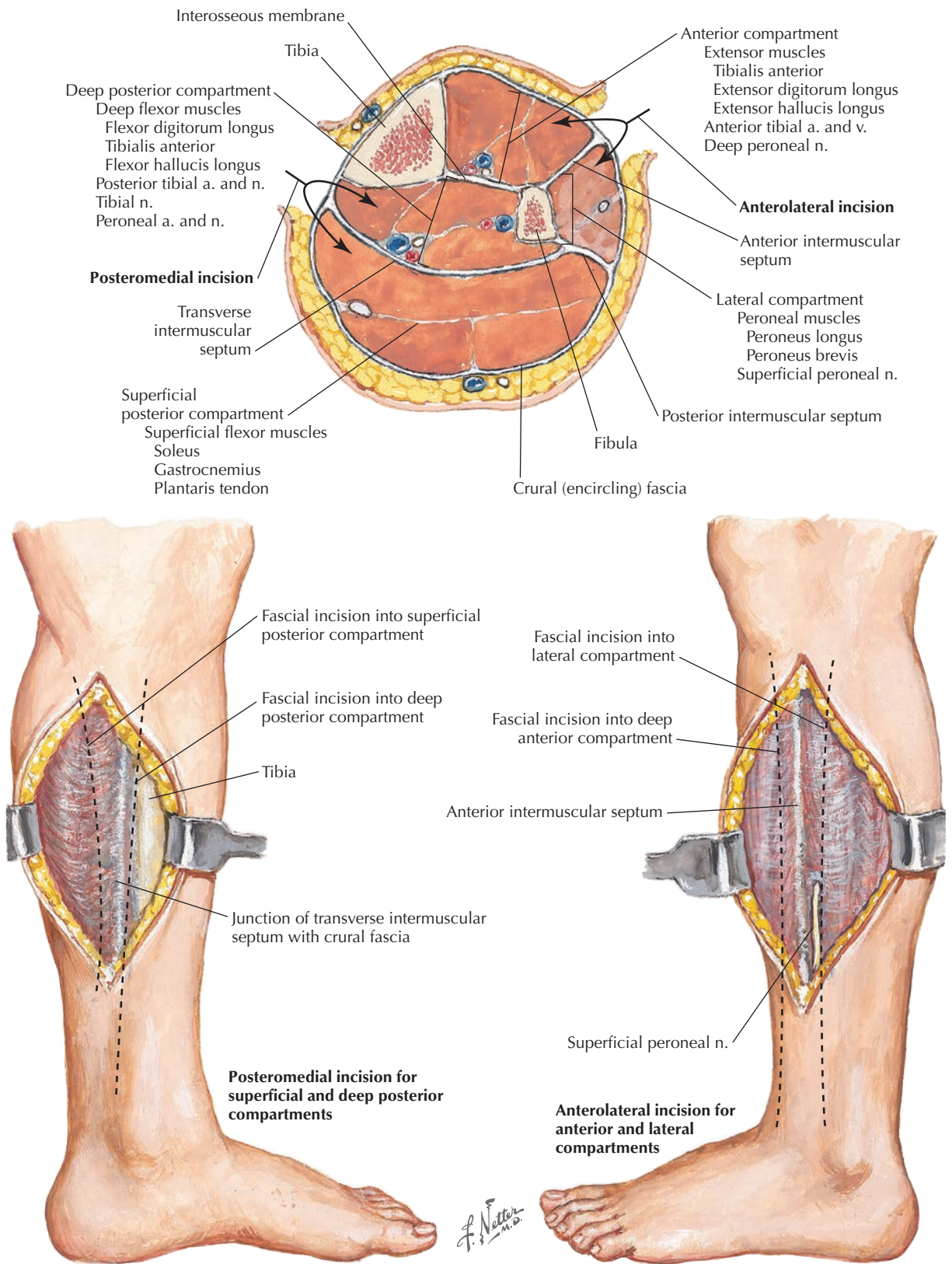


FIGURE 42-8 Incisions for compartment syndrome of leg.

Surgical Anatomy and Technique—Cont'd

The saphenous nerve is parallel and immediately adjacent to the long saphenous vein in the lower leg, and inadvertent injury to this sensory nerve should also be avoided. The proximal third of the soleus muscle is attached to the tibia and fibula. In addition to entering the posterior deep compartment in the middle and distal leg, the soleus must be detached from the tibia for adequate lysis of the proximal portion of the posterior deep compartment (Fig. 42-9).

The lateral incision is placed approximately 1 cm anterior to the border of the fibula. The crural fascial envelope in the lateral compartment is identified and lysed. Care should be taken to avoid injury to the superficial fibular nerve as it emanates from beneath the fibularis (peroneus) longus muscle. Proximally, the common fibular (peroneal) nerve can also be inadvertently injured.

The anterior intermuscular septum is then identified and the anterior compartment crural fascia incised in a longitudinal direction.

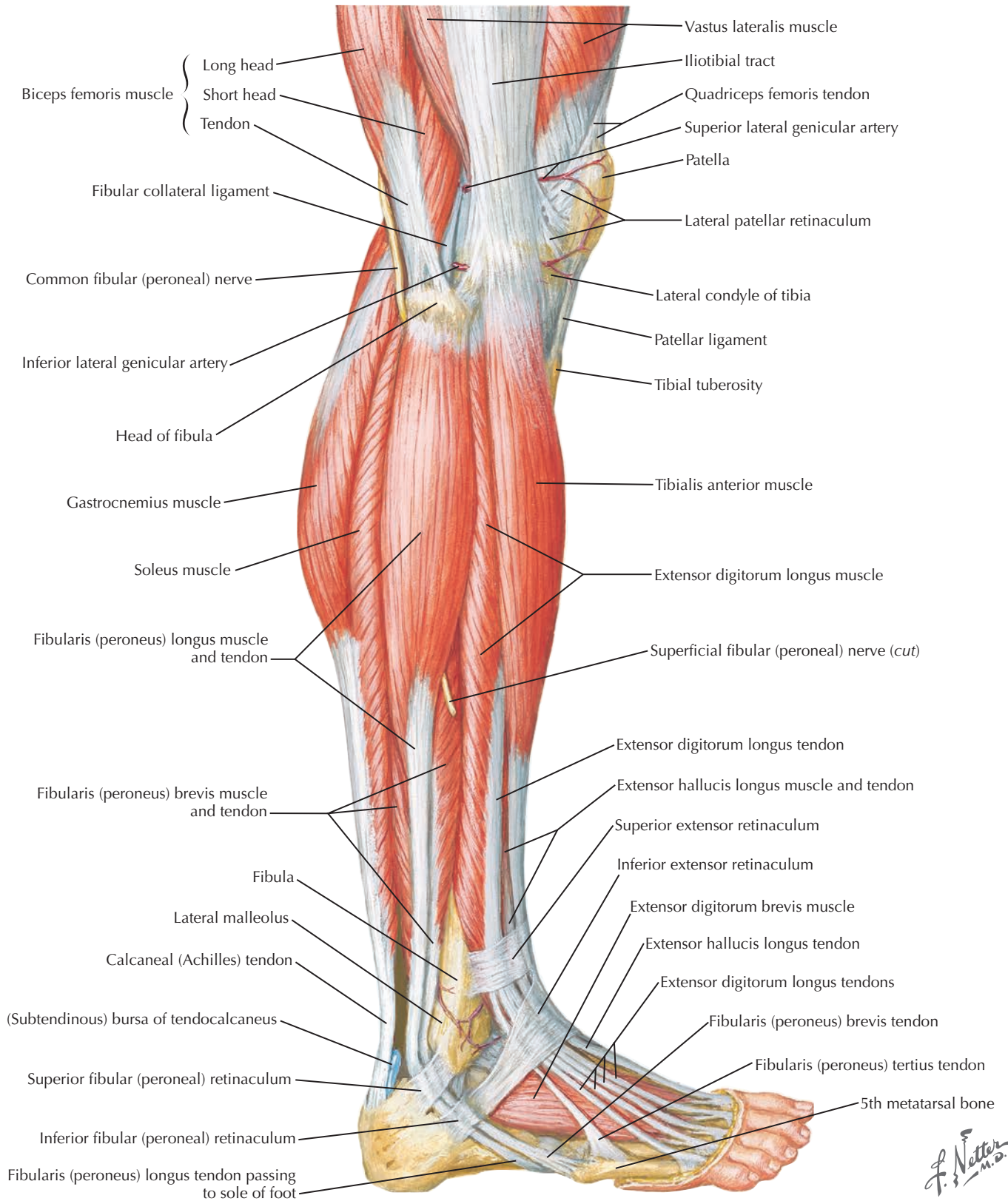


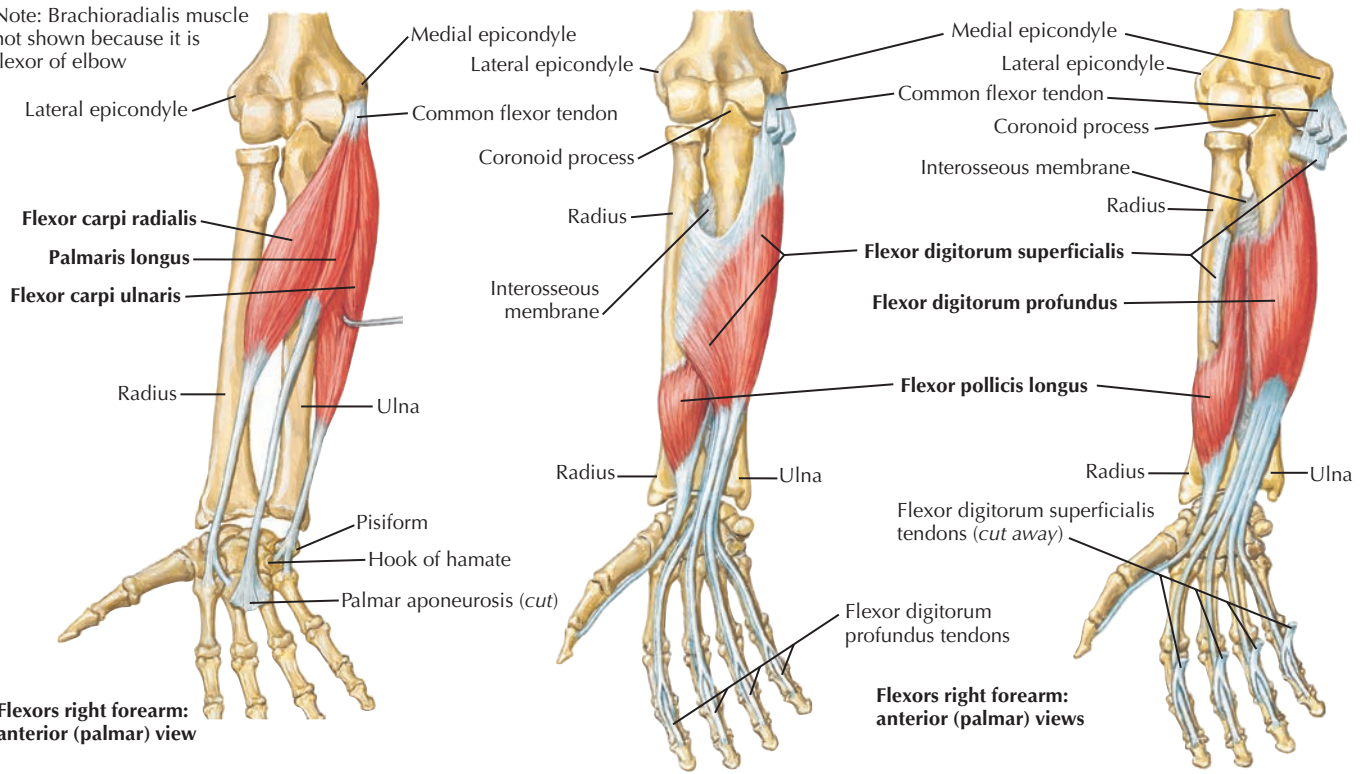
FIGURE 42-9 Muscles of leg with superficial peroneal nerve: lateral view.

F. Netter M.D.

FOREARM FASCOTOMY

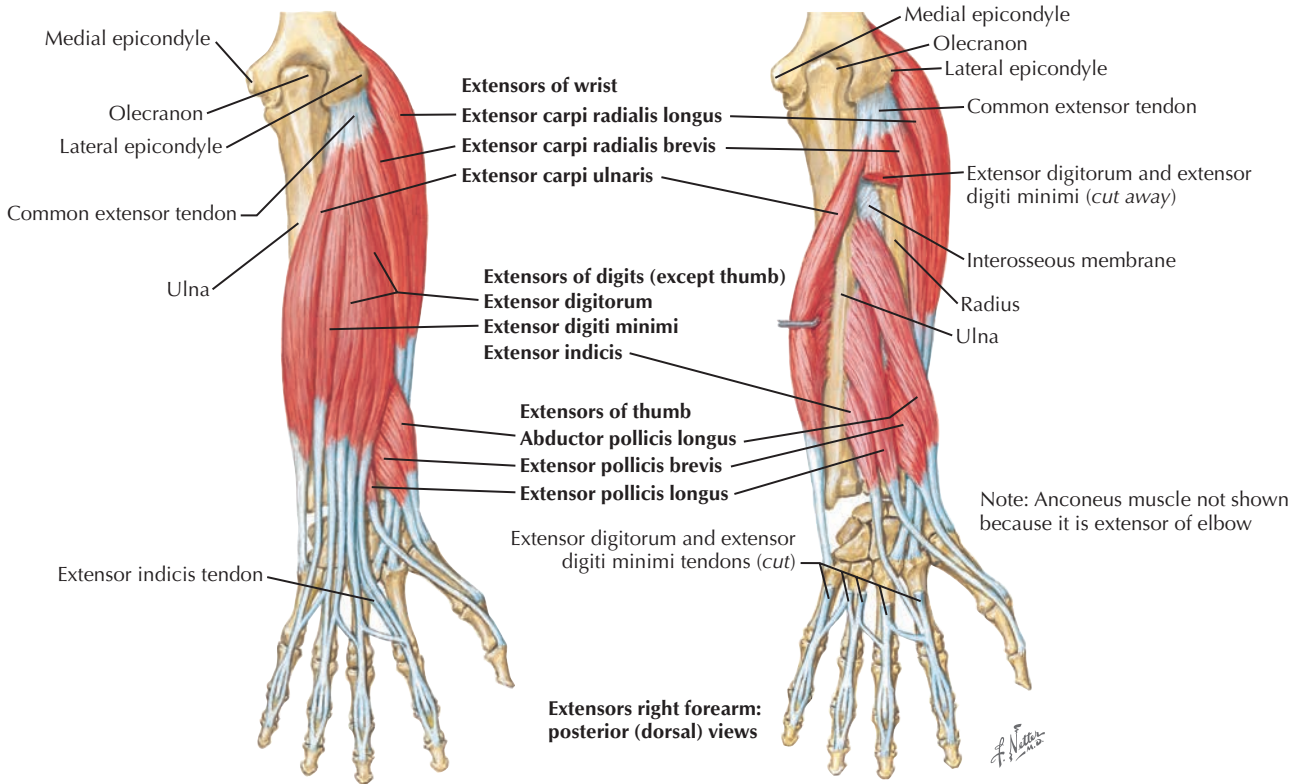
The forearm compartments consist of a single volar compartment and two dorsal compartments. The volar compartment has distinct septae within its muscle groups. There are typically two to three subcompartments arranged in a volar-to-dorsal direction. The most superficial of these contains the flexor carpi radialis, palmaris longus, flexor carpi ulnaris, and superficial portion of the pronator teres (Fig. 42-10). The next division contains the flexor digitorum superficialis, and the flexor digitorum profundus and flexor pollicis longus make up the final section. The main dorsal compartments are divided into the extrinsic finger extensors, thumb extensors with the index proprius, and the wrist extensors with the brachioradialis muscle. These anatomic divisions are important to consider during fasciotomy of the forearm.

Note: Brachioradialis muscle not shown because it is flexor of elbow



Flexors right forearm: anterior (palmar) view

Flexors right forearm: anterior (palmar) views



Extensors right forearm: posterior (dorsal) views

FIGURE 42-10 Individual muscles of forearm: flexors and extensors.

Clinical Diagnosis and Decision Making

The diagnosis of forearm compartment syndrome is based on examination findings. The resting position of the hand and wrist is slight wrist flexion, with metacarpophalangeal and proximal interphalangeal joint flexion and forearm pronation. The presence of a compartment syndrome is usually associated with swelling in the flexor compartment, because this is the most frequently involved compartment. Typically, the hand is also edematous. In more severe cases the dorsal forearm is also involved.

The classic findings of forearm compartment syndrome are disproportionate pain in view of the physical exam, pain with passive stretch of the finger extensors, restricted finger and wrist motion, and paresthesias in the hand along the distribution of the median, the ulnar, and less often the radial nerve (Fig. 42-11). There may be pallor in the terminal digits with prolonged capillary refill and decreased skin temperature. As this condition progresses, complete anesthesia occurs, and the radial and ulnar pulses can be diminished in severe cases.

Ancillary studies should include radiographs because the fracture location can help pinpoint the site of severely injured muscle. In the obtunded or sedated patient, direct compartment pressure measurements should be obtained. A compartment pressure 30 mm Hg above the mean diastolic pressure, or an absolute pressure between 30 and 45 mm Hg, is abnormal.

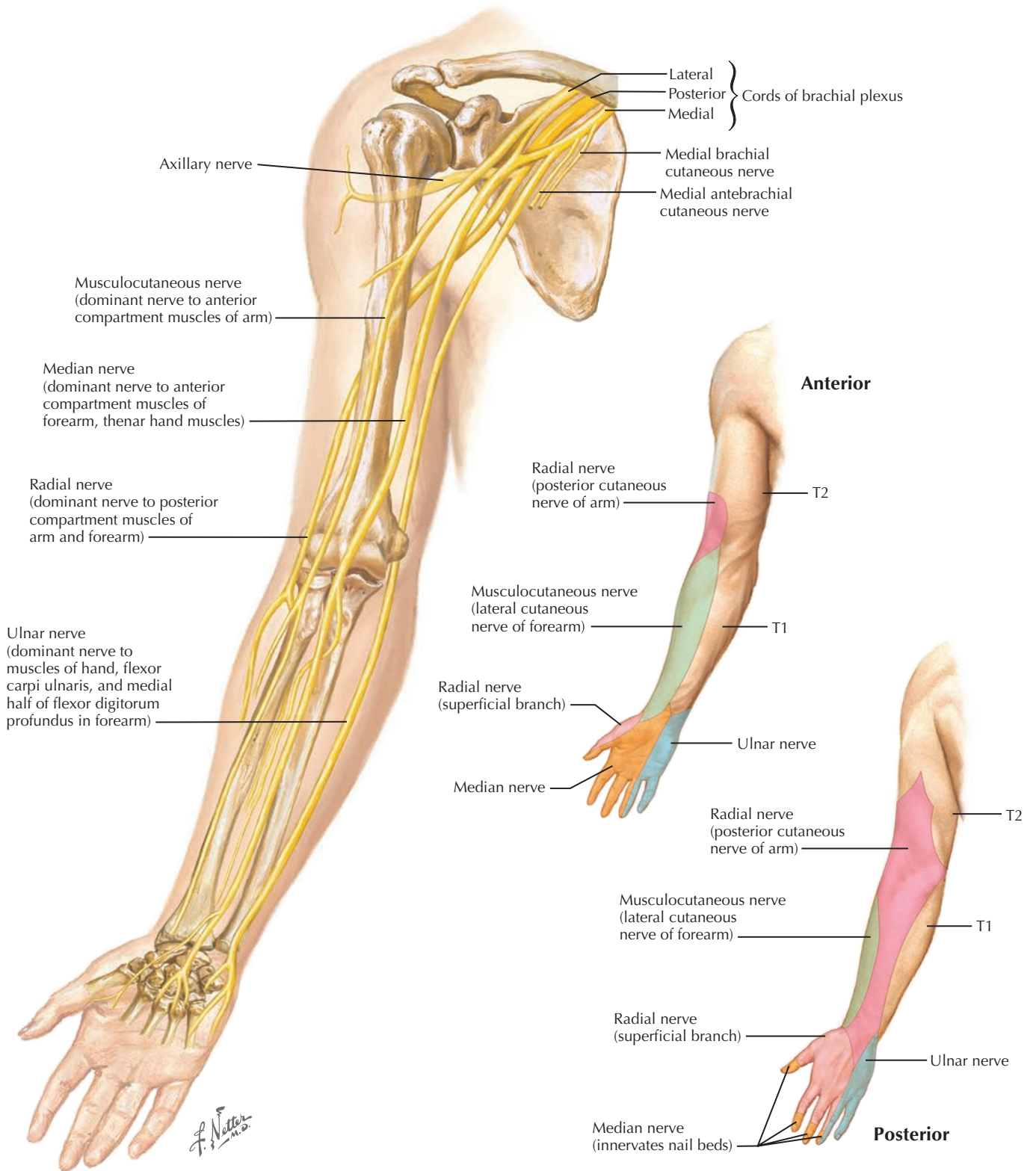


FIGURE 42-11 Nerves of upper limb.

Surgical Principles

Nonoperative treatment should be implemented in patients with potential or equivocal situations. This treatment includes elevation of the limb to the heart level, application of an elbow-to-finger splint, and avoidance of excess intravenous fluids. Any intravenous lines in the affected extremity should be removed.

Surgical Anatomy and Technique

The mainstay of treatment for confirmed compartment syndrome is decompressive fasciotomy. The volar compartment is most often involved and is approached initially through an extensile anterior or Henry-type approach. A carpal tunnel release is included if the swelling is significant in the distal forearm or palmar aspect of the wrist. Decompression should be extended proximal to the elbow flexion crease if there is swelling in that area. In more severe cases the dorsal compartments should also be decompressed.

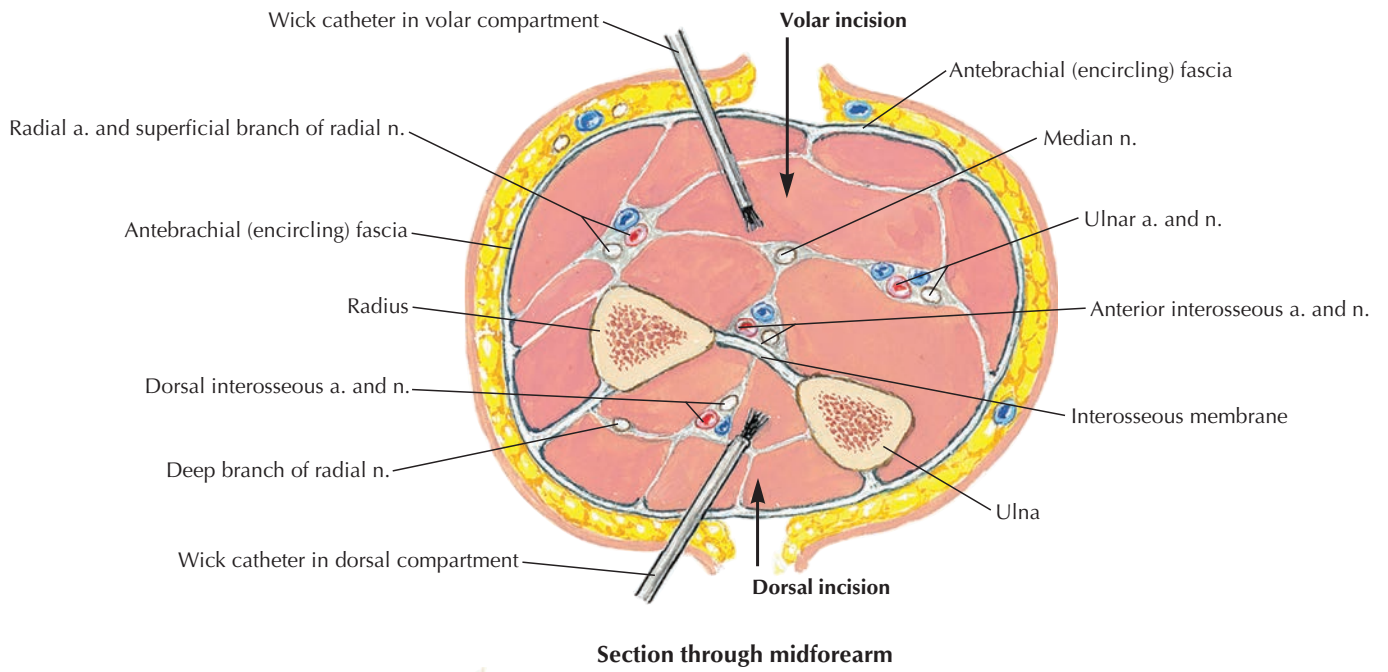
The fascia overlying the respective compartments should be completely incised. The septae between the muscle groups is also incised to ensure full decompression (Figs. 42-12 and 42-13). Often the deepest or most dorsal volar subcompartment is involved in early cases. This compartment is not well visualized without a deeper dissection. In more severe cases this compartment often has the most muscle destruction. The relationship of the median and ulnar nerves within the compartments is such that the ulnar nerve lies adjacent to the flexor digitorum profundus muscle, and the median nerve is generally between the flexor digitorum superficialis and flexor digitorum profundus muscles in the midforearm. The anatomy can be quite distorted as a result of the excessive swelling. The necessity for further surgical intervention is determined by the extent of muscle necrosis.

Closure

A clean and healthy muscle bed is necessary before closure can be considered. In the forearm, several techniques can be used for staged skin closure. Skin staples with intervening vessel loops can be used to approximate the skin sequentially. A vacuum-assisted closure method may be helpful. The distal and proximal extents are primarily approximated, and the central defect is covered with a split-thickness skin graft. The entire wound rarely can be primarily closed.

SUGGESTED READINGS

- Sheridan GW, Matsen FA. Fasciotomy in the treatment of the acute compartment syndrome. *J Bone Joint Surg Am* 1976;58:112.
- Velmahos GC, Theodorou D, Demetriades D, et al. Complications and nonclosure rates of fasciotomy for trauma and related risk factors. *World J Surg* 1997;21:247.
- Williams AB, Luchette FA, Papaconstantinou HT, et al. The effect of early versus late fasciotomy in the management of extremity trauma. *Surgery* 1997;122:861.
- http://www.operationgivingback.facs.org/stuff/contentmgr/files/a384bb3c7b77e154ad25c6136d7be344/miscdocs/lab_manual_extremity_chapter_4__2_.pdf



Section through midforearm

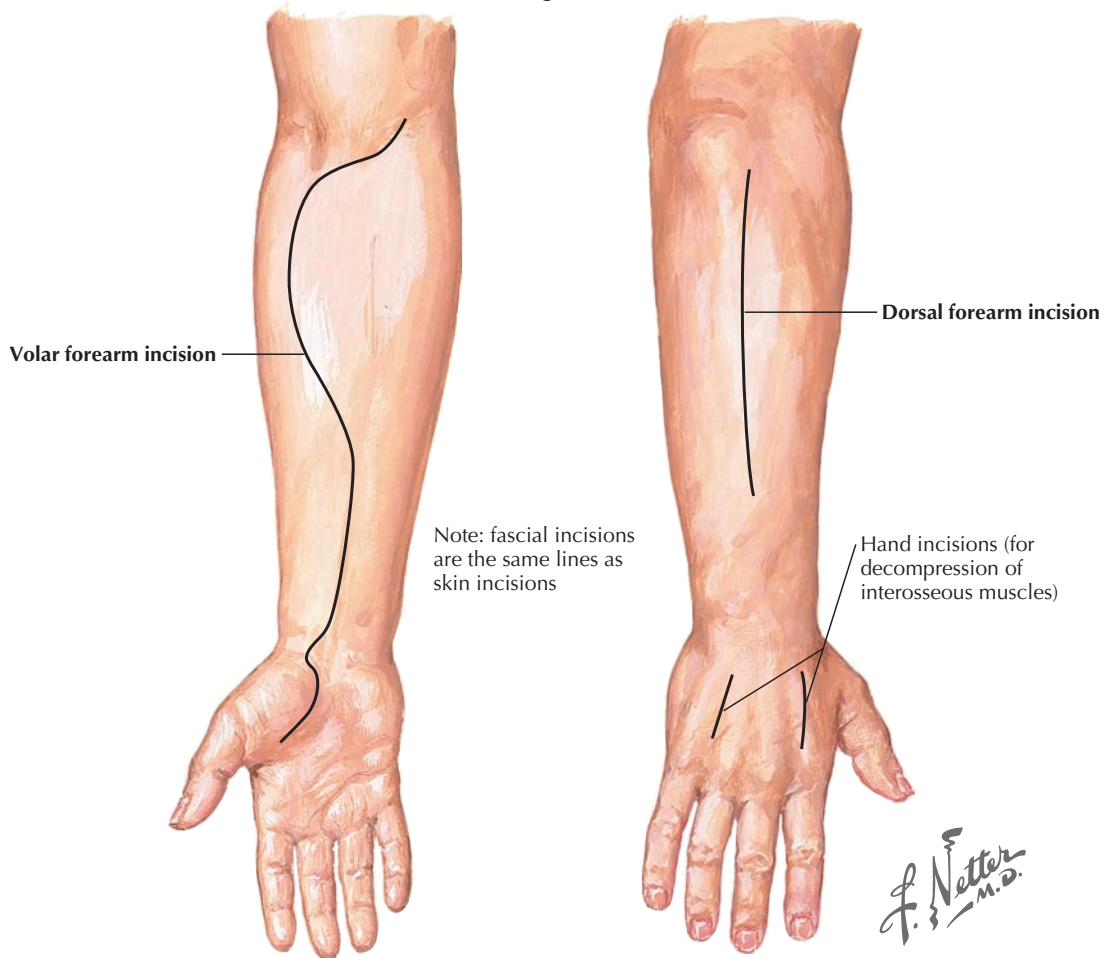


FIGURE 42-12 Cross-sectional anatomy and incisions for compartment syndrome of forearm and hand.

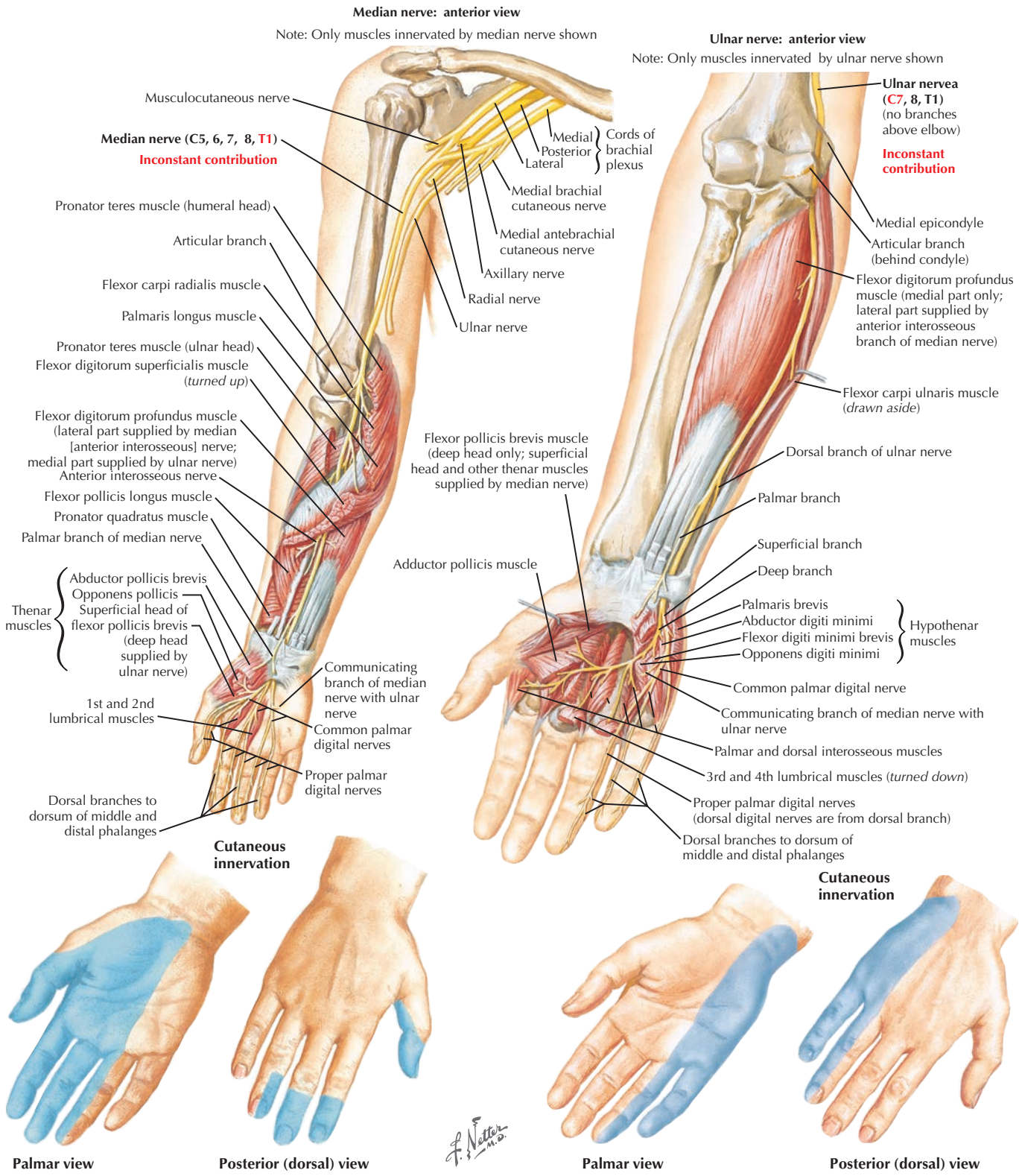


FIGURE 42-13 Median and ulnar nerve in forearm.

Chest Tube Placement

Jeffrey A. Claridge

INTRODUCTION

The most common indications for placement of a chest tube are pneumothorax (simple or tension), hemothorax, hemopneumothorax, empyema, and pleural effusion (acute or chronic). A chest tube needs to be placed in three defined situations. In the *urgent* situation the patient has unstable physiologic parameters and requires immediate chest tube placement. In the *semiurgent* situation the mandatory chest tube is needed “sooner rather than later,” and has an acute problem or indication but appears hemodynamically stable. However, delay in placing the chest tube could result in the patient becoming unstable and the need for an urgent procedure because of clinical deterioration. The *nonurgent* situation is typically elective and occurs in patients with stable hemodynamics and a chronic or recurrent physiologic problem. In other elective situations a chest tube is needed as part of a scheduled procedure, such as diaphragm repair or thoracotomy.

SUPERFICIAL ANATOMY AND TOPOGRAPHIC LANDMARKS

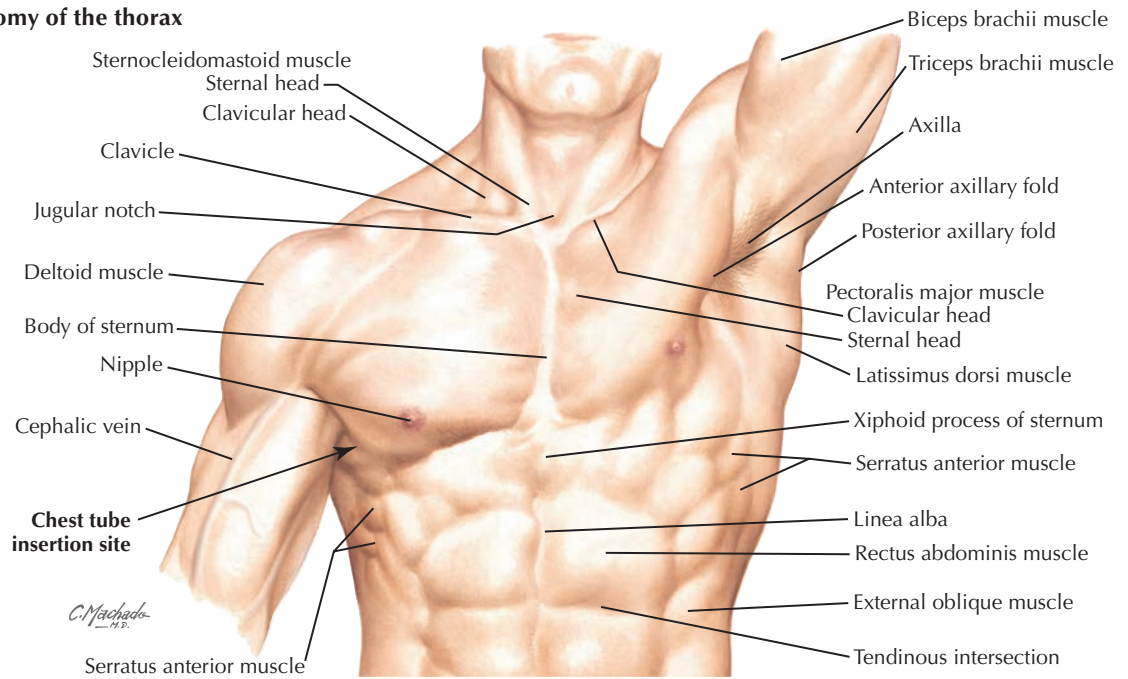
Regardless of the indication or urgency, five key anatomic concepts must be understood to maximize the effectiveness and safety of accessing the pleural space when placing a chest tube, as follows:

1. Identification of superficial landmarks
2. Relationship of the ribs and neurovascular bundle
3. Recognition of the boundaries of the chest and pleural space
4. Differences between right and left chest
5. Cross-sectional anatomy to visualize layers of the chest wall

The first important concept of placing a chest tube or accessing the pleural space involves the ability to identify superficial anatomic landmarks (Fig. 43-1, A). The key landmarks for accessing the pleural space are identification of the clavicular head; midclavicular line; the anterior, middle, and posterior axillary lines; and intercostal spaces with corresponding ribs. The ability to count ribs accurately will facilitate the placement of chest tubes. In a female patient the nipple should *not* be used as a landmark. Instead, the inframammary fold should be used to identify the 5th rib at the anterior axillary line. In a male patient the lower border of the pectoralis major muscle is a good approximation for the site of tube insertion.

The second key concept when accessing the pleural space is to recognize that the intercostal neurovascular bundles lie just below the inferior portion of the ribs (Fig. 43-1, B). Thus it is important to place the chest tube over the most superior portion of the rib to avoid injuring the intercostal neurovascular bundle.

A. Surface anatomy of the thorax



B. Anterior thoracic wall – internal view

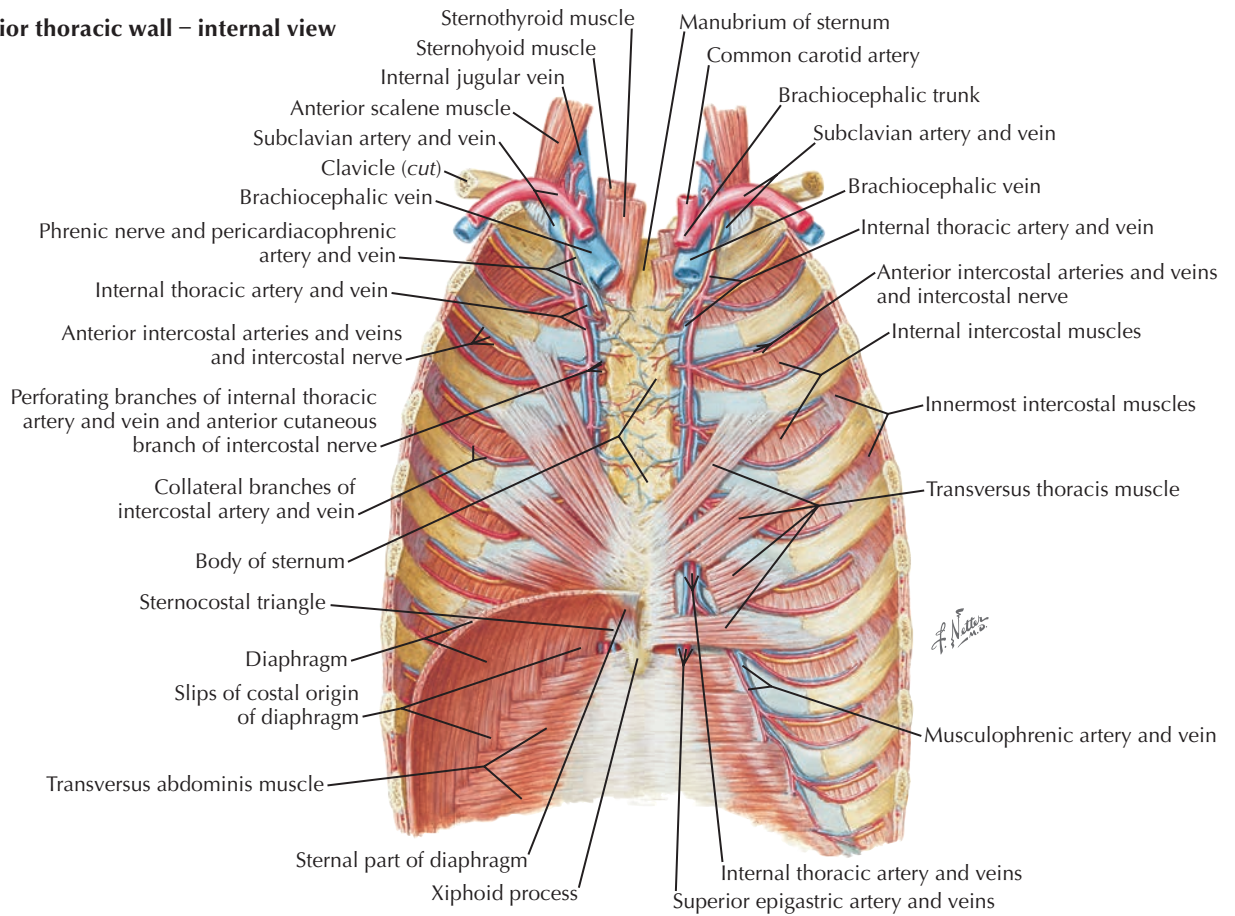


FIGURE 43-1 Anatomy of thorax.

SUPERFICIAL ANATOMY AND TOPOGRAPHIC LANDMARKS—Cont'd

The third anatomic principle is to recognize the boundaries of the chest and pleural space. Failure to recognize these boundaries can result in misadventures in chest tube placement such as placing a tube into or below the diaphragm, which can cause bleeding or injury to intraabdominal or major vascular structures (Fig. 43-2, A).

The fourth critical anatomic concept is to understand the difference between the left and right chest (Fig. 43-2, B). The key differences between the left and right chest must be appreciated when accessing the pleural space. The right lung has three lobes and the left has two lobes. The location of the horizontal fissure on the right and oblique fissure on the left is at approximately the 4th rib at the anterior axillary line. Staying below this rib can help avoid placement of the tube within a fissure.

The fifth and final important anatomic detail is to understand the cross-sectional anatomy of the chest wall and the layers that must be traversed to access the chest. These layers include the skin, subcutaneous tissue, intercostal muscles, and parietal pleura (Fig. 43-2, C).

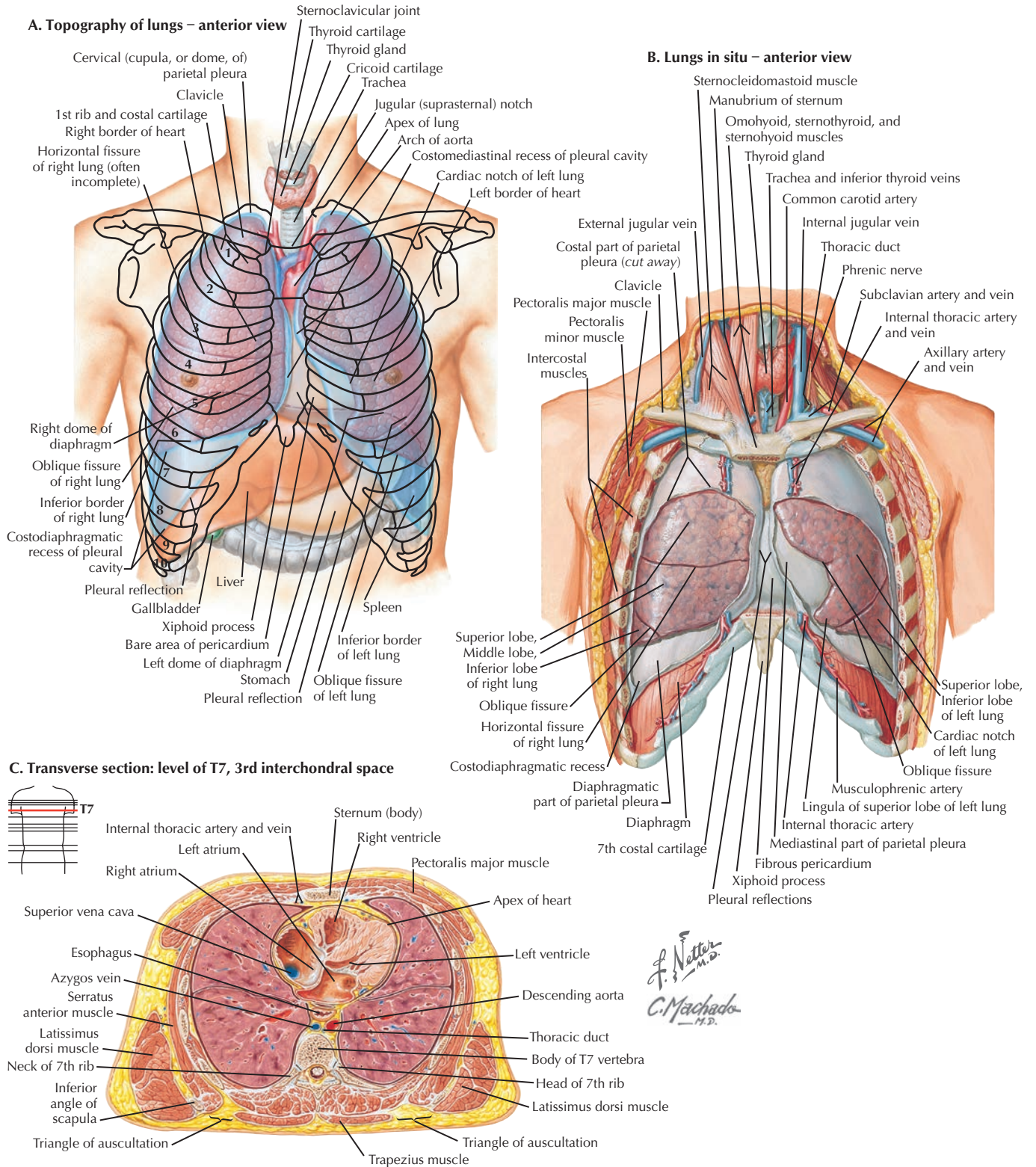


FIGURE 43-2 Lung topography, lungs in situ, and chest wall cross section.

SPECIFIC INDICATIONS AND CONDITIONS

Urgent Placement

A chest tube placed under urgent conditions needs to be done quickly and efficiently. Local anesthetic is often not indicated in this situation. It is still recommended to prepare the area with an antiseptic solution, usually chlorhexidine or povidone-iodine. Towels are placed to outline the aseptic field. The nipple should be visible to help identify the appropriate landmarks, and the ipsilateral arm should be abducted over the patient's head if possible.

Identify the anterior axillary line and the inframammary or subpectoral fold, and identify the rib at this location. Make a 2- to 3-cm skin incision directly over the center of the rib with a No. 10 blade, and take the incision down to the periosteum of the rib. In a thin patient, retracting the skin cranially before making the incision will create more soft tissue for tunneling.

After the incision is made, tunnel through the intercostal muscles and the parietal pleura, and enter the pleural space. The classic description is to use a medium or large Kelly clamp with combined pushing and spreading, but in an urgent situation, this procedure should be done quickly with one or two passes. Once the chest cavity is entered, be sure to spread enough to allow a finger to be placed into the chest. The chest tube can be inserted through this tunnel with the assistance of the large Kelly clamp. Either close the Kelly clamp over the tube, or place the clamp tip through one of the side holes and slide it out the end of the tube (Fig. 43-3). The Kelly clamp can assist in directing the tube posteriorly to evacuate fluid or anteriorly to evacuate a pneumothorax. All the holes in the chest tube must be within the pleural space for the tube to work properly.

Semiurgent Placement

The semiurgent technique is similar to the placement of an urgent chest tube. However, the practitioner will have time to infuse local anesthetic and more completely towel and drape the patient. Local anesthetic can be infused in two steps: infiltration of anesthetic in the skin and soft tissue over the incision site, followed by infiltration over the rib into the intercostal muscles and pleura. A useful strategy is to infiltrate this deeper layer after the skin incision.

The needle should follow the direction of the planned tunnel, aspirating the entire way until the pleura space is entered. If the procedure is performed for pneumothorax or effusion, air or fluid will be aspirated in the syringe; at this point, stop advancing and start withdrawing the needle tip slowly. Infiltrate a large bolus of local anesthetic while slowly withdrawing the needle through the parietal pleura and intercostal muscles.

The tunnel is then dissected as previously described. However, this procedure can be done more slowly in the semiurgent situation than with an urgently placed chest tube.

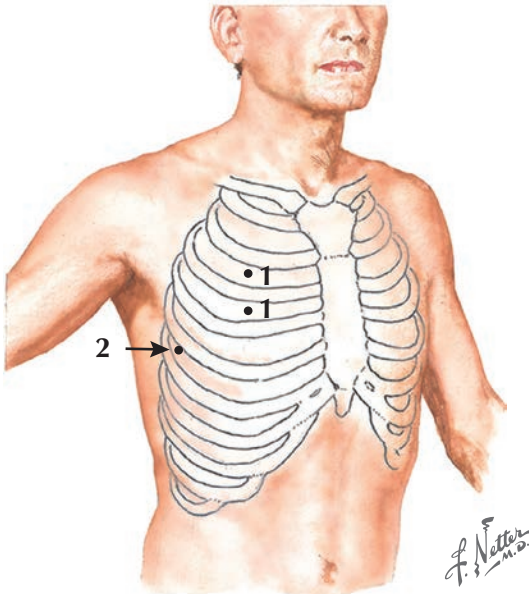
Nonurgent (Elective) Placement

There are no major changes in technique with nonurgent compared with semiurgent tube placement. With an elective situation, however, there is time to review all imaging and select a more precise location for chest tube placement.

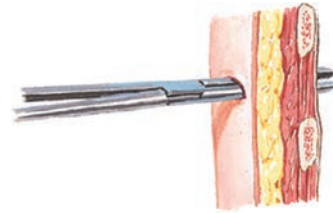
Hemostat technique

Preferred sites

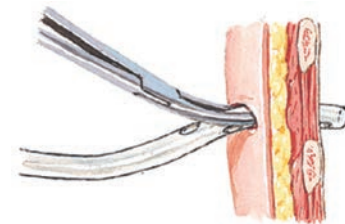
1. For pneumothorax (2nd or 3rd interspace at midclavicular line)
2. For hemothorax (5th interspace at midaxillary line)



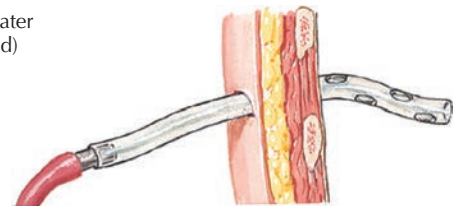
A. Skin incised and pleura entered by blunt dissection



B. Tube inserted into pleural cavity



C. Tube attached to underwater seal (with suction if indicated)



Note: For all techniques, local anesthesia is used; penetrate close to upper border of lower rib to avoid intercostal vessels. Aspirate first for free blood or free air (adherent lung)

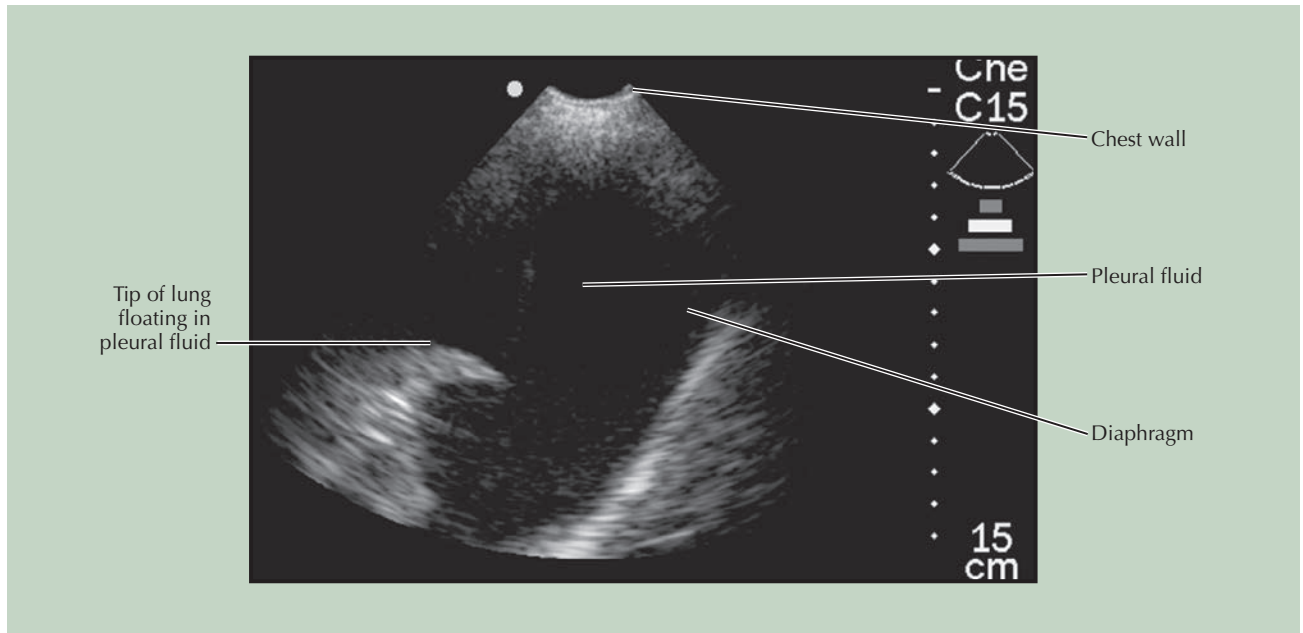


FIGURE 43-3 Landmarks for chest tube placement.

SUGGESTED READINGS

- Dev SP, Nascimiento B, Simone C, Chien V. Chest-tube insertion. *N Engl J Med* 2007;357:e15.
- Hoth JJ, Kincaid EH, Meredith JW. Injuries to the chest. In Ashley SW, editor. *ACS surgery: principles and practice*. Hamilton, Ontario: Decker; 2012. www.acssurgery.com.
- Varghese TK Jr. Chest trauma. In Mulholland MH et al, editors. *Greenfield's surgery: scientific principles and practice*, 5th ed. Philadelphia: Wolters Kluwer/Lippincott, Williams & Wilkins; 2011, pp 370-84.

Emergency Thoracotomy for Trauma

Amy McDonald

INTRODUCTION

Injury to the thoracic cavity is second only to brain injury as a leading cause of trauma deaths. Most thoracic injuries are managed with nonsurgical therapies. Emergency thoracotomy is a lifesaving procedure only used in select circumstances. Knowledge of the appropriate indications for thoracotomy and thoracic anatomy are paramount. The American College of Surgeons (ACS) Committee on Trauma has summarized indications for use of thoracotomy in the ED as follows (Fig. 44-1, A):

Emergency Department Thoracotomy is best applied to patients sustaining penetrating cardiac injuries who arrive at trauma centers after a short scene and transport time with witnessed or objectively measured physiologic parameters (signs of life): pupillary response, spontaneous ventilation, presence of carotid pulse, measurable or palpable blood pressure, extremity movement, and cardiac electrical activity.

SURGICAL PRINCIPLES

The most expeditious entry into the thoracic cavity is through a left anterolateral thoracotomy incision performed in the 4th or 5th intercostal space (Fig. 44-1, B). This incision can be performed easily with a scalpel and then Mayo scissors, if available. A right anterolateral thoracotomy incision does not provide adequate exposure for control of most cardiac injuries but is useful for penetrating injuries to the right chest cavity.

The patient should be placed in the supine position with the arms stretched out. If time allows, a wedge should be placed under the left side of the chest, creating an approximately 15-degree tilt for better exposure. The 4th or 5th intercostal space is located just below the nipple in men and, with the breast retracted, at the inframammary fold in women. The incision should extend from the left sternal edge to the midaxillary line. The inferior portion of the pectoralis major and minor, serratus anterior, and intercostal muscles are divided (Fig. 44-1, C).

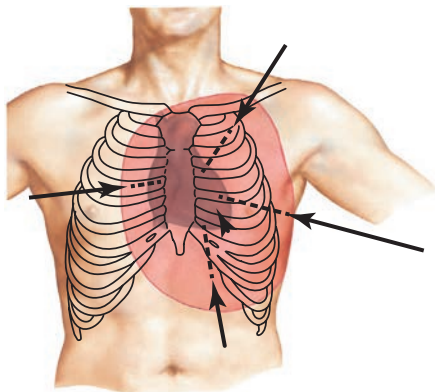
If necessary, the incision can be extended across the sternum to the right midaxillary line as a “clamshell” thoracotomy. Dividing the sternum transversely also will divide the internal mammary arteries, which can lead to troublesome bleeding if they are not ligated (Fig. 44-1, D).

Placement of a rib retractor with the handle toward the left axilla allows for easier extension of the incision into the right side of the chest. Assisted ventilation should be stopped during incision of the pleura to minimize iatrogenic injury to the lung. The emergent nature of the thoracotomy does not allow time for placement of a double-lumen endotracheal tube (ETT) before pleural incision.

THORACOTOMY TECHNIQUE

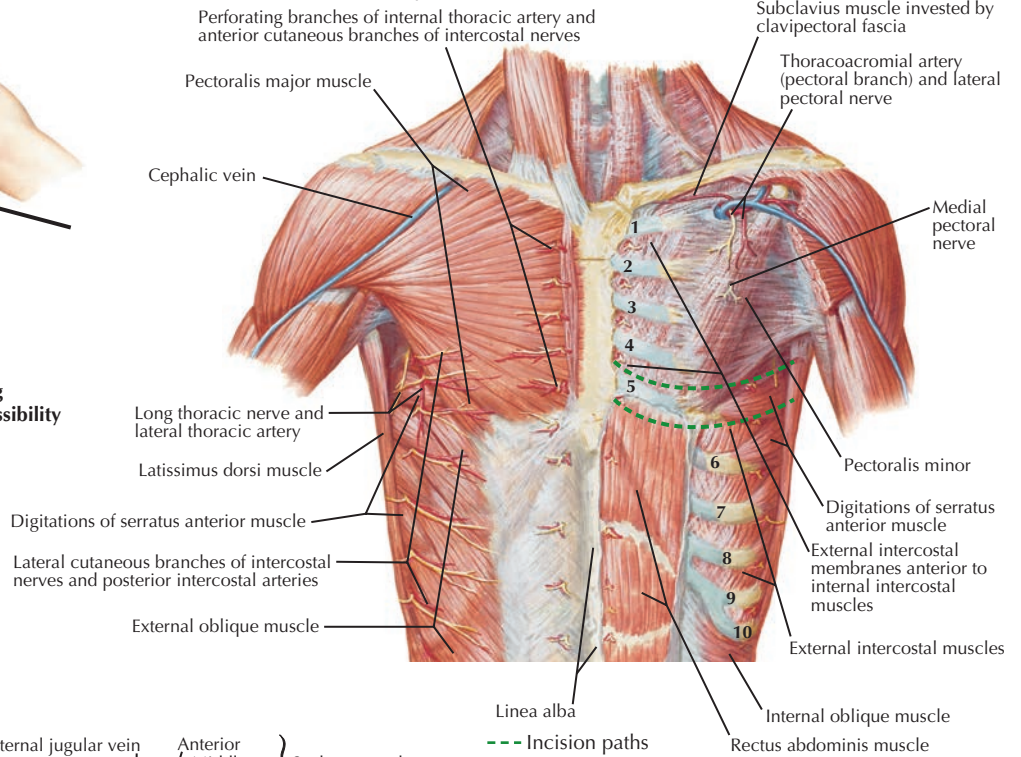
After ventilation is resumed, the inflated left lung can inhibit further progress. Deflation of the left lung can be facilitated by advancing the ETT into the right main bronchus, which can help improve exposure to the underlying structures. Five major maneuvers can be performed, depending on the findings, as follows:

1. Mobilization of the left lung
2. Relief of cardiac tamponade and control of the cardiac defect
3. Performance of open cardiac massage
4. Control of the pulmonary hilum
5. Clamping of the descending thoracic aorta

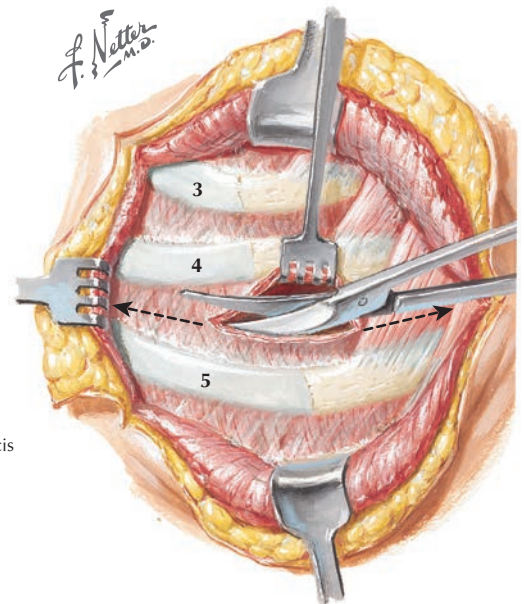
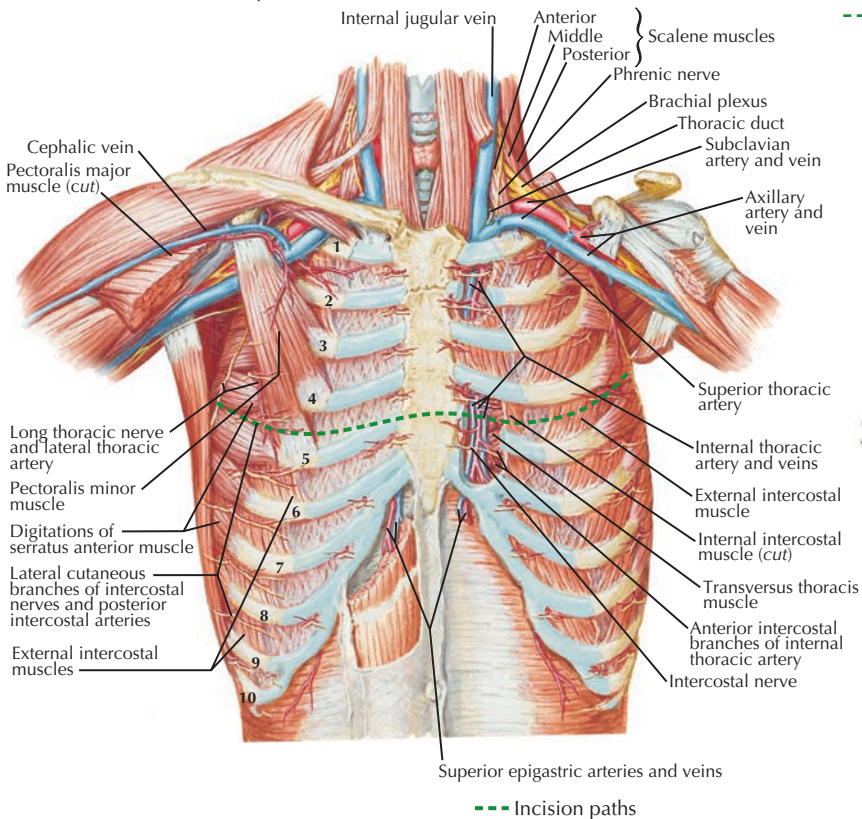


A. Area of chest wall where penetrating wounds should alert physician to possibility of cardiac injury

B. Left anterolateral thoracotomy



D. "Clamshell" thoracotomy



C. Skin and pectoralis major muscle have been divided and reflected; intercostal and pectoralis minor muscles are divided in 4th interspace

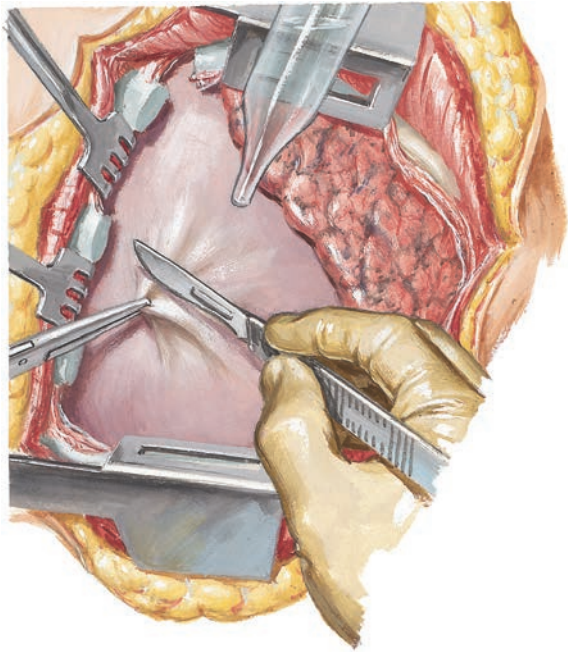
FIGURE 44-1 Entry into thoracic cavity: "clamshell" and left anterolateral thoracotomy.

Lung Mobilization

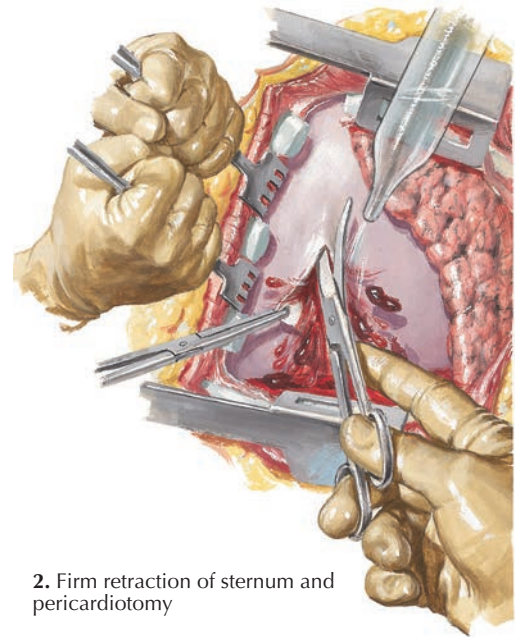
The surgeon can visualize the heart by pushing the patient's left lung posteriorly. Bulging or visualization of pericardial blood requires immediate pericardiotomy. The incision in the pericardium is performed anterior and parallel to the phrenic nerve, which courses along the posterior third of the pericardium. The incision should be long enough to allow delivery of the heart into the left side of the chest for inspection and temporary control of cardiac wounds.

Control of Cardiac Injury

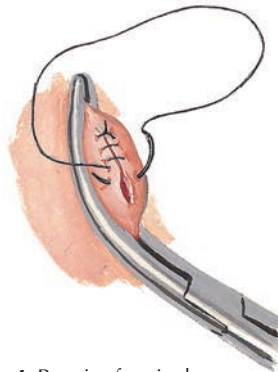
Definitive control of cardiac injury is best managed in the operating room. The thin walls of the atria should be reapproximated with atraumatic vascular clamps (i.e., Satinsky clamps), followed by closure with a running suture (Fig. 44-2). The muscular left ventricle is usually repaired with pledgeted sutures.



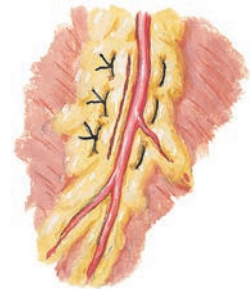
1. Pericardium grasped with Kocher clamp before incision: irrigating syringe in readiness



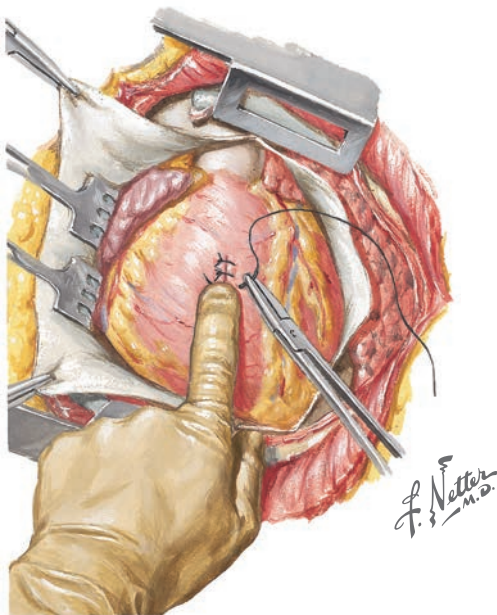
2. Firm retraction of sternum and pericardiotomy



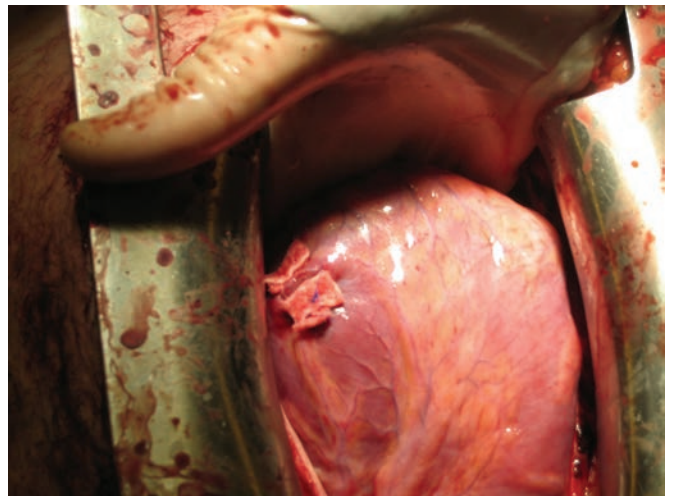
4. Repair of auricular or great-vessel wound



5. Repair close to coronary artery



3. Digital control of bleeding and cardiorrhaphy



Pledget repair of left ventricle

FIGURE 44-2 Pericardiotomy and cardiorrhaphy.

Cardiac Massage

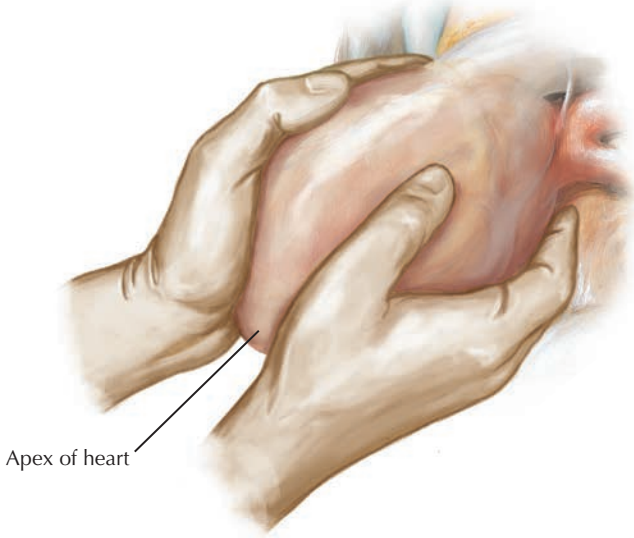
Delivery of the heart upward through the pericardial incision is helpful in performing massage. Open cardiac massage is best performed with two hands by using a hinged clasp motion with the proximal palms as the fulcrum. The heart is compressed from the apex to the base (Fig. 44-3, *A*).

Control of a major pulmonary or pulmonary hilar injury is facilitated by incising the inferior pulmonary ligament. Care must be taken not to lacerate the inferior pulmonary vein during this maneuver (Fig. 44-3, *B*).

Control at Hilum and Injury Repair

The pulmonary hilum can be controlled manually or with an atraumatic clamp. Another useful maneuver to control hemorrhage involves twisting the lung 180 degrees. Hilar occlusion is not well tolerated, particularly in the hypotensive patient, and carries a high mortality; it should be used only if absolutely necessary.

A. Open cardiac massage



B. Left anterolateral thoracotomy

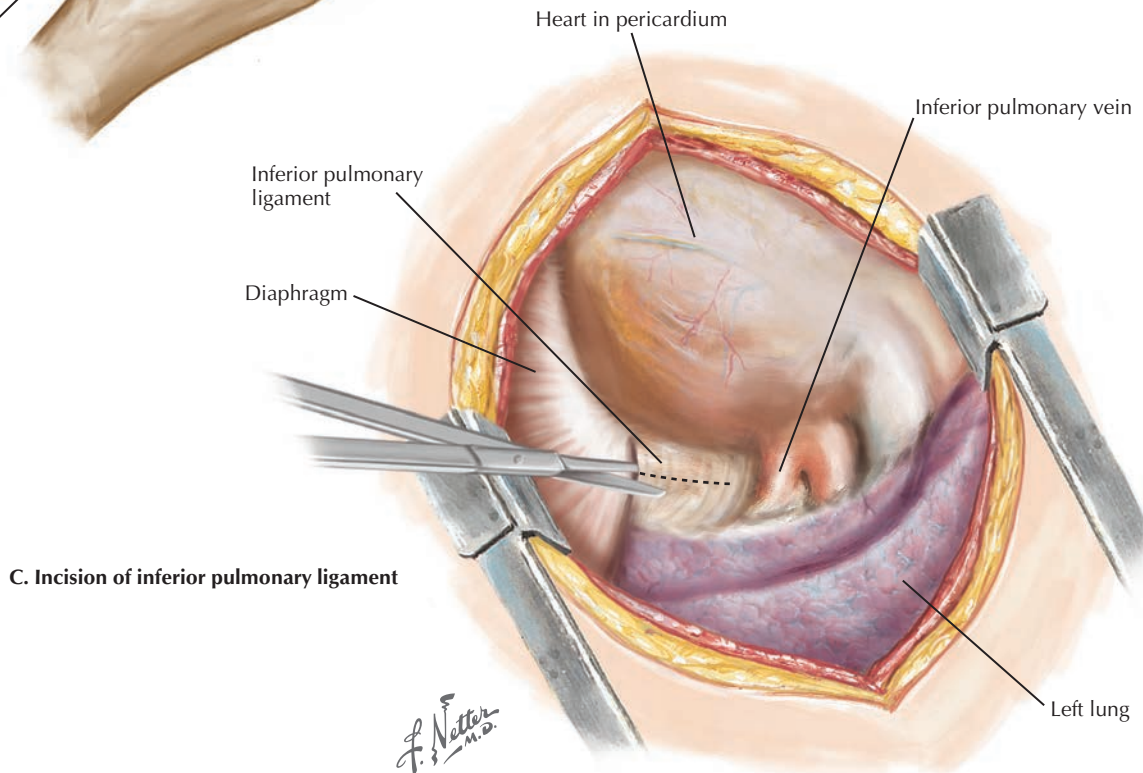
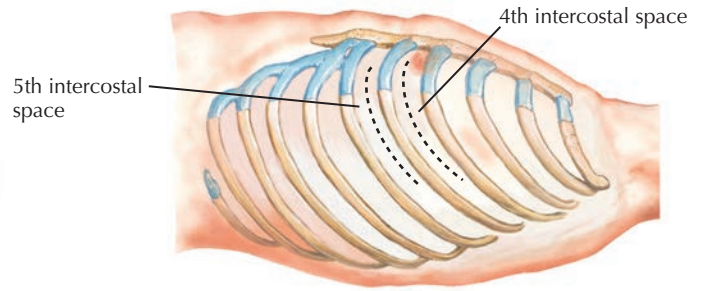


FIGURE 44-3 Cardiac massage, left thoracotomy, and ligament incision.

Control at Hilum and Injury Repair—Cont'd

Pulmonary injuries are best treated by nonanatomic resection, direct suture repair, or pulmonary tractotomy. Pulmonary tractotomy is especially suitable for through-and-through injuries. The injury tract is opened with a linear stapling device or between clamps (Fig. 44-4, A). Bleeding vessels are then oversewn within the tract (Fig. 44-4, B).

Aortic Clamping

Occlusion of the descending thoracic aorta is done to preserve cerebral and coronary blood flow and to stop major vascular hemorrhage from below the diaphragm before laparotomy. The benefit of this maneuver is controversial. Thoracic aortic cross-clamping results in cardiac strain secondary to a sudden increase in arterial afterload. This maneuver also increases visceral ischemia below the cross-clamp and bleeding from injuries proximal to the site of occlusion.

Cross-clamping of the descending thoracic aorta is accomplished by retracting the left lung anteriorly. The aorta is identified as the first longitudinal tubular structure encountered anterior to the thoracic vertebral bodies. It should not be confused with the esophagus, which is in a more anterior position.

Placement of a nasogastric or orogastric tube can facilitate identification of the aorta (Fig. 44-4, C). The mediastinal pleura is opened anteriorly and the parietal pleura posteriorly by using either blunt or sharp dissection. A cross-clamp is then placed. The aorta is not completely encircled because injury to the intercostal vessels may occur. The aortic cross-clamp should be removed as soon as practical to prevent ongoing cardiac strain and visceral ischemia.

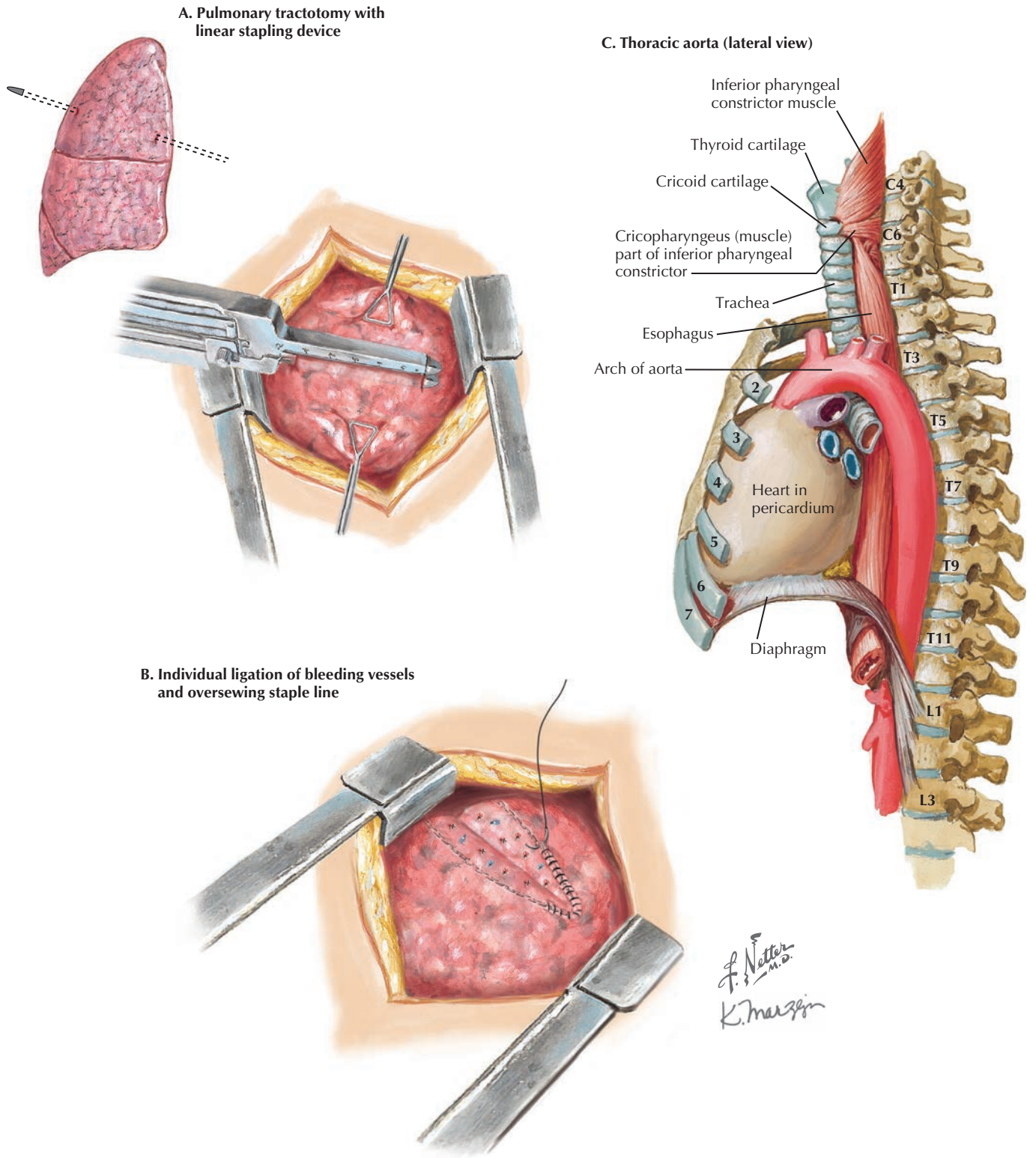


FIGURE 44-4 Pulmonary tractotomy.

CONCLUSION

Emergency thoracotomy is a lifesaving maneuver in select trauma patients, especially those with isolated penetrating cardiac injury. Knowledge of thoracic anatomy allows for the safe and effective performance of this procedure.

SUGGESTED READINGS

- American College of Surgeons. Practice management guidelines for emergency department thoracotomy. Committee on Trauma Working Group, Ad Hoc Subcommittee on Outcomes. *J Am Coll Surg* 2001;193:303-9.
- Cothren CC, Moore EE. Emergency department thoracotomy for the critically injured patient: objectives, indications, and outcomes. *World J Emerg Surg* 2006;24:1-4.
- Hunt PA, Greaves I, Owens WA. Emergency thoracotomy in thoracic trauma: a review. *Injury* 2006;37:1-19.
- Morgan BS, Jordan JP. Emergency thoracotomy: the indications, contraindications and evidence. *J Army Med Corps* 2009;155:87-93.

Tracheal Intubation and Endoscopic Anatomy

Samuel DeJoy and Charles E. Smith

INTRODUCTION

Proficiency in airway management and tracheal intubation requires a firm foundation of knowledge in airway anatomy. This chapter provides an overview of airway anatomy for tracheal intubation with conventional laryngoscopy, videolaryngoscopy (GlideScope), and flexible fiberoptic bronchoscopy. Airway assessment and recognition of a difficult airway are also reviewed. Although the numerous airway management devices include video laryngoscopes, optical stylets, rigid fiberoptic laryngoscopes, and supraglottic ventilatory devices (beyond the scope of this chapter), all require similar anatomic considerations.

AIRWAY ANATOMY

The pulmonary system consists of lungs and a series of airways that are subdivided into upper and lower segments.

Upper Airway

The upper airway consists of the nose, mouth, pharynx, and larynx. There are three pharyngeal segments: (1) nasopharynx, posterior to the soft palate; (2) oropharynx, posterior to the tongue from the tip of the uvula to the tip of the epiglottis; and (3) laryngopharynx, posterior to the epiglottis (Fig. 45-1). The pharyngeal segments are collapsible because the anterior and lateral walls lack bony support.

Inspiratory patency of the pharynx is maintained primarily by contraction of the tensor palatine, genioglossus, and hyoid bone muscles. Loss of muscle tone leads to pharyngeal collapse. During general anesthesia or intravenous sedation, the upper airway becomes obstructed because of a decrease in the anteroposterior diameter of the pharynx at the level of the soft palate and epiglottis. Many anesthetic agents and sedative drugs diminish the action of pharyngeal dilator muscles, which promotes pharyngeal collapse and airway obstruction.

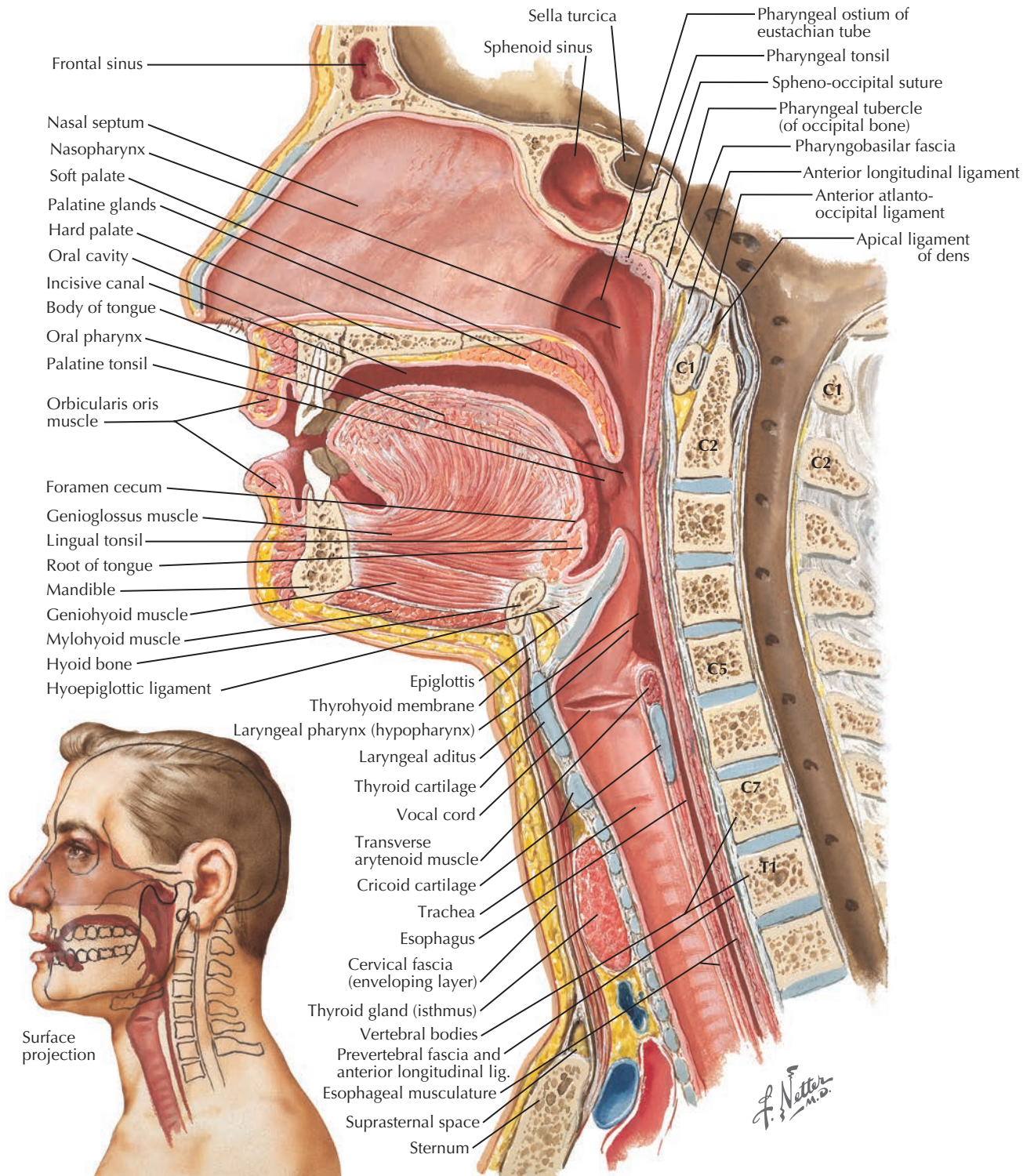


FIGURE 45-1 Sagittal section of pharynx.

Larynx

The larynx serves as the connecting structure between the upper and lower airways (Fig. 45-2). The adult larynx extends from the 4th to the 6th cervical vertebra, and it is composed of nine cartilages, with six paired and three single. The three single cartilages include the thyroid, cricoid, and epiglottis. The paired arytenoid cartilages secure the vocal cords to the larynx. The endolarynx is constructed of two pairs of folds that form the supraglottis and glottis.

The internal and external laryngeal muscles control vocal cord length and tension and movement of the larynx as a whole. These muscles aid in swallowing, respiration, and vocalization and are integral in preventing aspiration into the trachea and lower airway. The hyoid bone suspends and anchors the larynx.

Note the location of the superior laryngeal nerve (important for nerve block anesthesia) adjacent to the hyoid bone (Fig. 45-2). Motor innervation of the laryngeal muscles is through the superior laryngeal nerve (cricothyroid muscle) and recurrent laryngeal nerve (remainder of laryngeal muscles). Stimulation of the supraglottic region, especially where the piriform recesses blend with the hypopharynx, can result in laryngospasm with complete glottic closure.

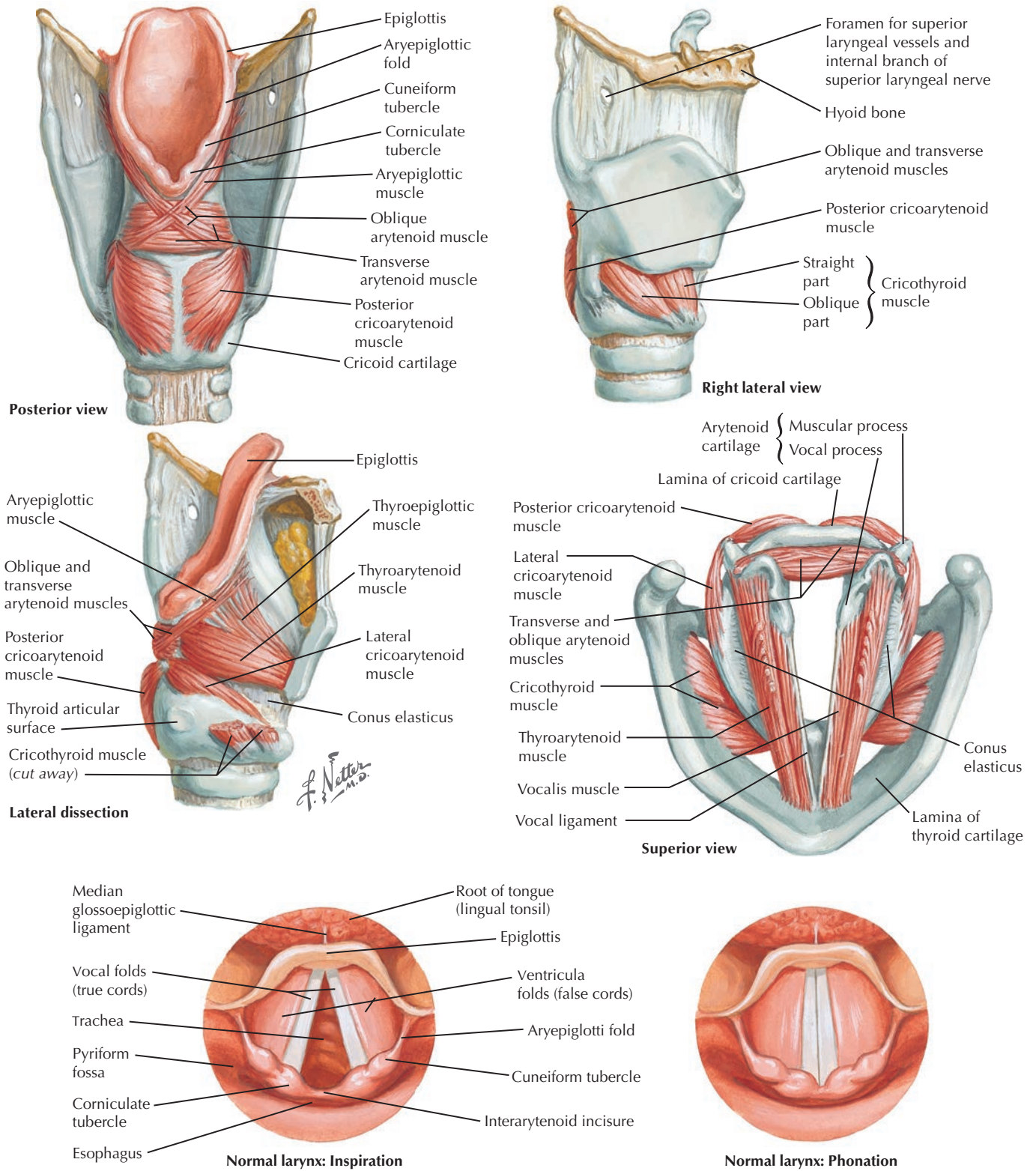


FIGURE 45-2 Views of larynx.

Nose and Nasopharynx

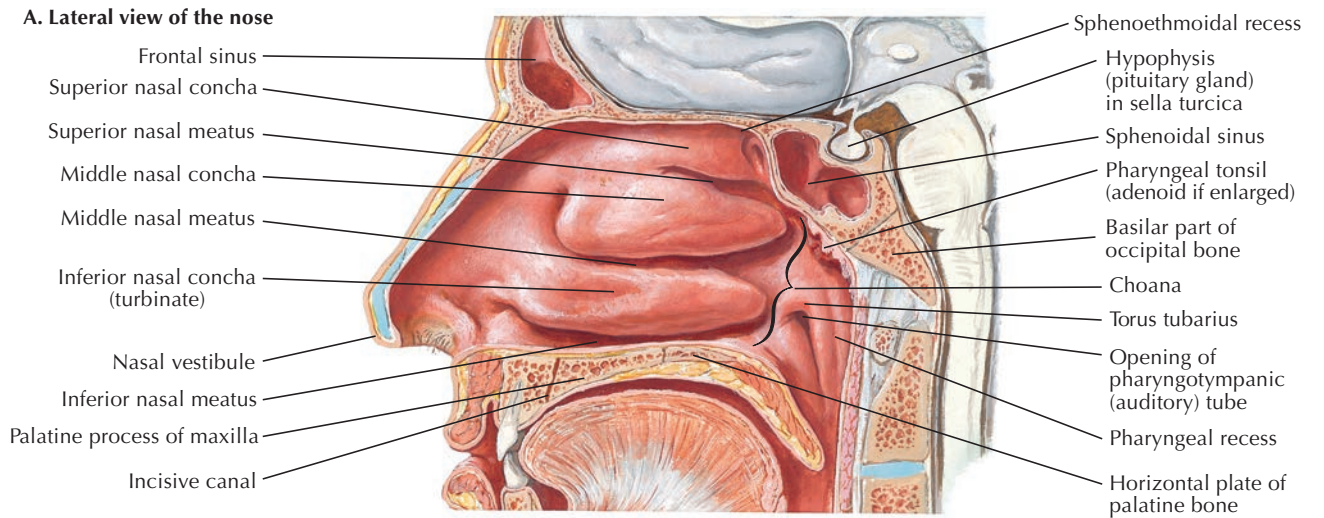
Nasotracheal intubation is an alternative approach to orotracheal intubation. The two nasal fossae extend from the nostrils to the nasopharynx. The nasal fossae are divided by the midline cartilaginous septum and medial portions of the lateral cartilages (Fig. 45-3, A). The nasal fossa is bounded laterally by inferior, middle, and superior turbinate bones. The mucosa covering the middle turbinate is highly vascular, receiving its blood supply from the anterior ethmoid artery, and also contains a large plexus of veins. The middle turbinate is susceptible to avulsion by trauma and is associated with massive epistaxis. The paranasal sinuses (sphenoid, ethmoid, maxillary, and frontal) open into the lateral wall of the nose. The inferior turbinate usually limits the size of the nasotracheal tube.

Lower Airway

The lower airway consists of the trachea, bronchus, bronchioles, respiratory bronchioles, and alveoli. The adult trachea, which begins at the cricoid cartilage opposite the 6th cervical vertebra, contains 16 to 20 cartilaginous rings. The posterior part of the trachea is devoid of cartilage (Fig. 45-3, B). Pressure over the cricoid cartilage (Sellick maneuver) is often applied during rapid-sequence induction and intubation (RSI) to minimize the risk of aspiration in unfasted (full stomach), anesthetized, and paralyzed patients before intubation. However, cricoid pressure may distort airway anatomy, making intubation more difficult.

The trachea divides into two bronchi at the carina. The right and left bronchi are positioned differently; the right extends vertically from the trachea, which allows for an easier pathway for aspirate and foreign particles to enter. This accounts for the higher incidence of unintentional right main bronchus intubations.

Bronchial divisions continue down the pulmonary pathway into increasingly smaller airways. The alveoli complete the final phase of the pulmonary system and constitute the area of primary gas exchange, where oxygen enters the bloodstream and carbon dioxide is removed.



B. Trachea and major bronchi

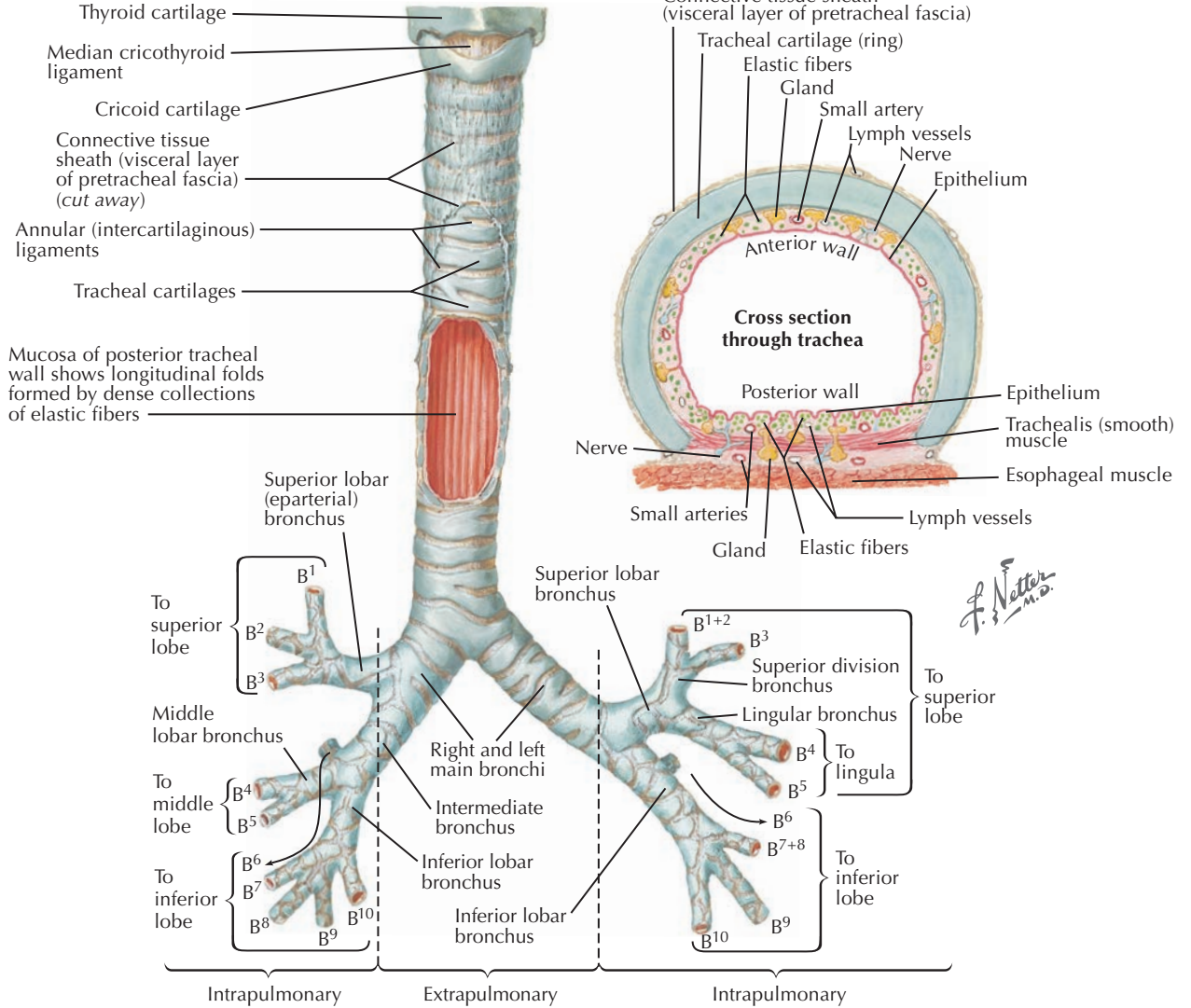


FIGURE 45-3 Nose and lower airway/trachea.

INDICATIONS FOR INTUBATION

Inadequate oxygenation and ventilation can rapidly lead to brain injury or death. Initial ventilatory support is usually accomplished by relieving airway obstruction (suction, chin lift, jaw thrust, oral airway, nasal airway) and bag-mask ventilation (BMV) with 100% oxygen. The oral airway is designed to hold the tongue away from the posterior pharyngeal wall and prevent the tongue from obstructing the glottis.

The nasopharyngeal airway is an uncuffed, trumpetlike tube that is inserted through the nasopharynx, bypassing the oropharynx and mouth. The distal end is just superior to the epiglottis and inferior to the base of the tongue. The proximal end has a flange to prevent the airway from migrating into the nose (Fig. 45-4, A).

Indications for intubation include respiratory failure, severe pulmonary, or multisystem injury, depressed level of consciousness, cardiac arrest, shock, and inadequate BMV. Advantages of intubation include maintenance of a definitive airway; ability to deliver positive pressure ventilation, high inspired oxygen concentration, and positive end-expiratory pressure (PEEP); and decreased risk of aspiration.

PREINTUBATION AIRWAY EXAMINATION

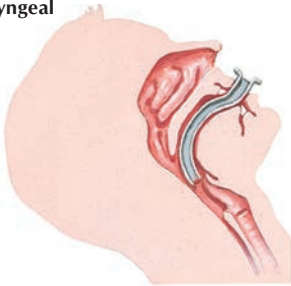
Airway examination should include anatomic and pathologic factors that can predict likelihood of a difficult airway (Fig. 45-4, B). Anatomic factors that increase tracheal intubation difficulty include Mallampati class III (only soft palate visible when patient opens mouth wide and protrudes tongue), limited mouth opening, protruding maxillary incisors, narrow mouth width, cleft lip/palate, small oral cavity, large tongue, tumors, trauma, and infection.

The American Society of Anesthesiologists (ASA) defines the difficult airway as that clinical situation in which a conventionally trained anesthesiologist experiences difficulty with BMV, intubation, or both. Difficult direct laryngoscopy occurs when it is not possible to visualize any portion of the vocal cords after multiple attempts at conventional laryngoscopy. Difficult intubation occurs when intubation requires multiple attempts. Failed intubation occurs when placement of the endotracheal tube (ETT) fails after multiple attempts.

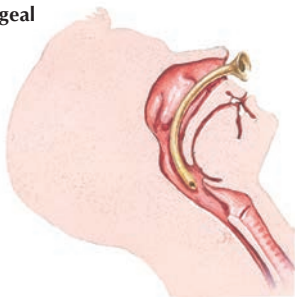
Pathologic factors that further challenge practitioners include tumors, deep fascial plane infections of the face or neck, burns, congenital anomalies, airway trauma, thermal and inhalation injury, and cervical spine trauma (Fig. 45-4, C-E).

A. Oral and nasopharyngeal airway

Oropharyngeal airway

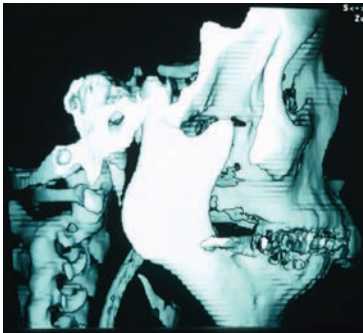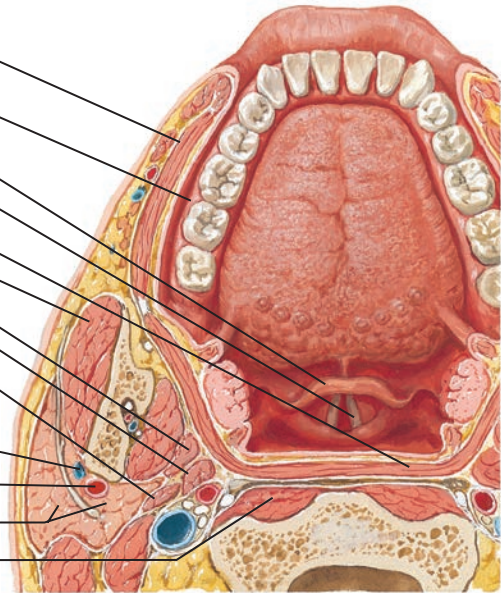


Nasopharyngeal airway



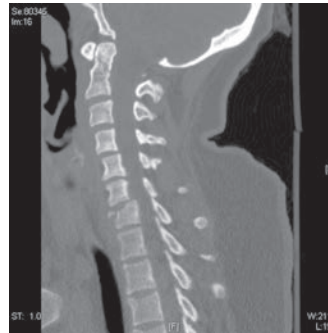B. Axial view of the floor of the mouth showing the oropharynx and glottic opening

- Buccinator muscle
- Vestibule
- Epiglottis
- Glottis
- Superior pharyngeal constrictor muscle
- Masseter muscle
- Styloglossus muscle
- Stylopharyngeus muscle
- Stylohyoid muscle
- Retromandibular vein
- External carotid artery
- Parotid gland
- Longus capitis muscle



C. 3D reconstruction.

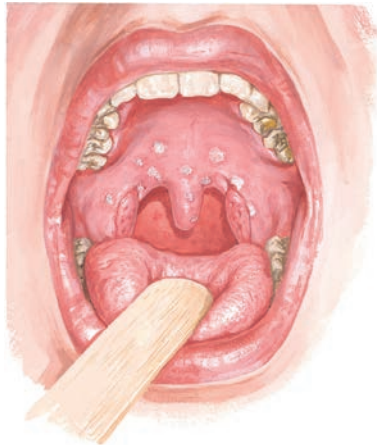Patient sustained multiple traumas after a car accident, including facial fractures and brain injury. The right mandibular condyle has been displaced intracranially, preventing mouth opening. A surgical airway was necessary.



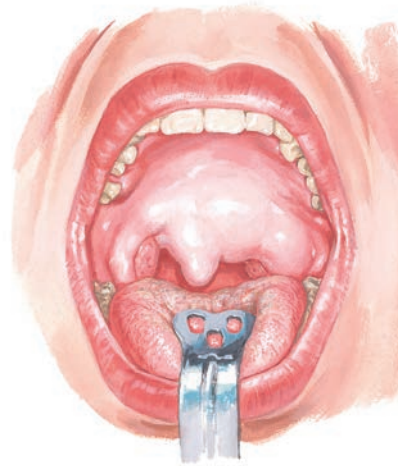D. Sagittal CT of the cervical spine after blunt trauma.

Airway management and tracheal intubation is complicated by the requirement for neck immobilization, making conventional laryngoscopy more difficult. The patient sustained a type II odontoid fracture, flexion tear-drop fracture of C7, and fractures involving the articular pillars of C4 and C7 on the right. She required fiberoptic nasotracheal intubation with in-line immobilization for surgical repair of her fractures.

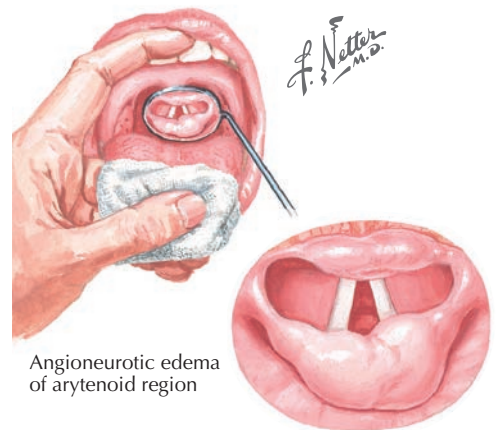
E. Allergic conditions of pharynx



Allergic pharyngitis (as often seen after use of antibiotic or other throat lozenges)



Angioneurotic edema of soft palate and uvula (Quincke edema)



Angioneurotic edema of arytenoid region

FIGURE 45-4 Indications and examination for intubation. 3D, Three-dimensional; C7, 7th cervical vertebra; CT, computed tomography scan. (D courtesy of Timothy Moore, MD, Department of Orthopedic Surgery, MetroHealth Medical Center, Cleveland, Ohio.)

Anesthesia

Unless the patient has experienced cardiac arrest, anesthesia is required to insert the ETT. Anesthesia choice ranges from general anesthesia with or without neuromuscular blocking drugs (paralytics) to nerve block anesthesia or topical anesthesia. When general anesthesia is not used, sedative agents are routinely administered. With fiberoptic bronchoscopy an anti-sialagogue is given; nasal intubation requires mucosal vasoconstriction.

LARYNGOSCOPY

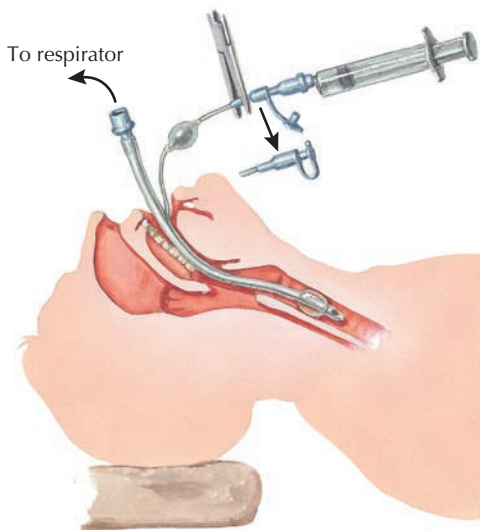
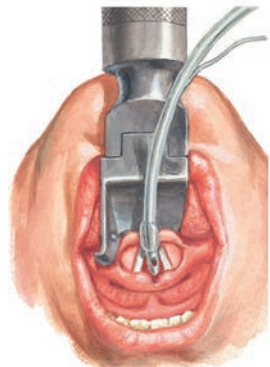
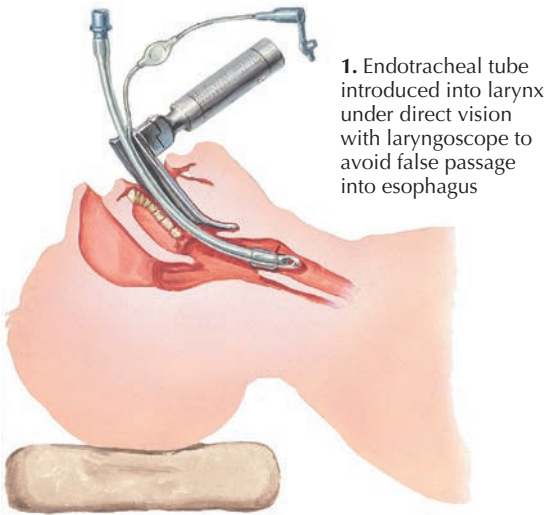
After suitable anesthesia is given, an appropriate-sized laryngoscope blade is inserted to the right of the patient's tongue, which must be displaced and compressed (Fig. 45-5, A). Head extension and the sniffing position facilitate line of sight for the practitioner to insert the tube through the vocal cords. With infants and neonates, use of a straight blade is preferred. Because of the proximity of the upper airway to the cervical spine (see Fig. 45-1), some movement of the atlanto-occipital and atlanto-axial segments generally occurs during laryngoscopy.

With the GlideScope, the blade is introduced into the mouth in the midline and rotated around the tongue. The camera, embedded in the blade, points upward to provide a view of the glottis. An appropriately shaped stylet is necessary to deliver the ETT to the larynx.

During intubation, different views of the glottic opening are achieved, depending on patient anatomy and practitioner skills (Fig. 45-5, B). Pressure over the thyroid cartilage often improves the view at laryngoscopy. The ETT is introduced through the vocal cords until the cuff disappears. Ventilation is confirmed by sustained presence of end-tidal carbon dioxide, auscultation of bilateral breath sounds with absence of air over the epigastrium, and chest rise. The tube is securely taped or tied at the appropriate depth. In adults, an average distance of 20 to 24 cm is required to place the distal end of the tube in the midtracheal position.

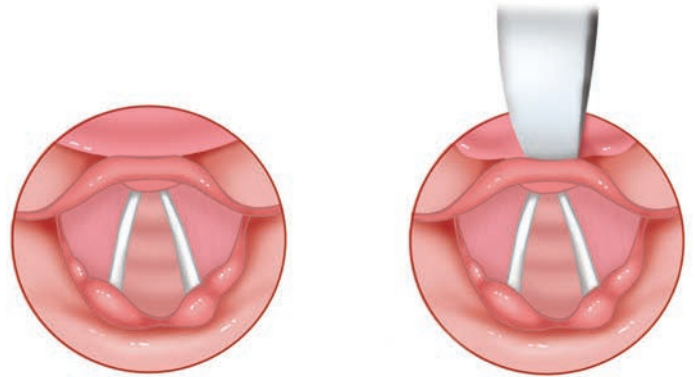
Malpositioning may occur by inserting the ETT into the esophagus or by advancing the tube too distal into the trachea past the carina (endobronchial intubation).

A. Endotracheal intubation

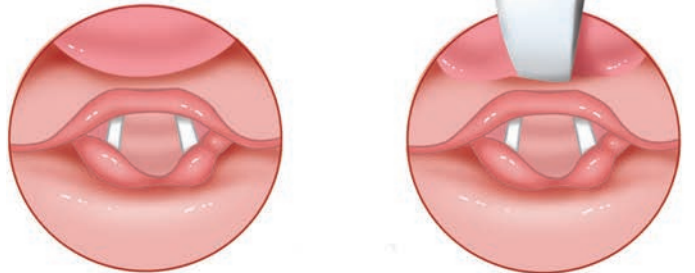


F. Netter M.D.

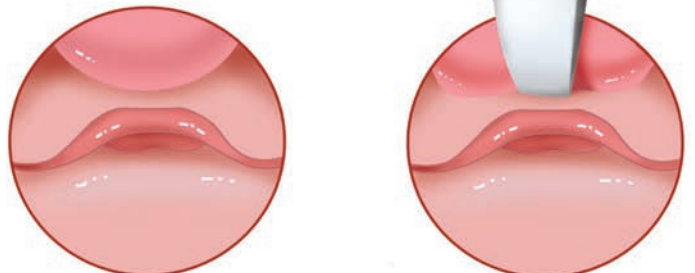
B. Cormack and Lehane laryngeal grades



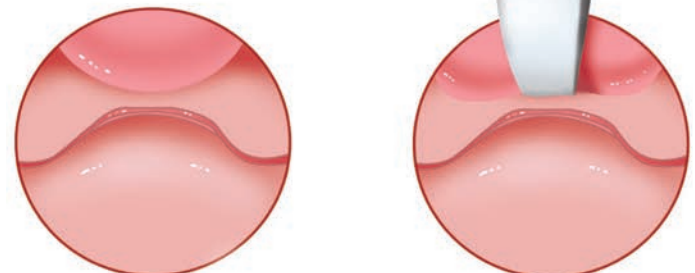
Grade 1. Full glottic opening is visible



Grade 2. Only the posterior portion of the glottic opening is visible



Grade 3. Only the tip of the epiglottis visible



Grade 4. Only the soft palate is visible

FIGURE 45-5 Laryngoscopy. (B illustrations courtesy of Mike Mustar, medical illustrator, MetroHealth Medical Center, Cleveland, Ohio.)

FLEXIBLE FIBEROPTIC BRONCHOSCOPY

Flexible fiberoptic bronchoscopy (FOB) intubation is often done in conscious, spontaneously breathing patients with a known or suspected difficult airway (e.g., unstable cervical spine, cooperative patient). A silicone spray or other lubricant is helpful to ensure easy advancement of the ETT over the FOB. Jaw thrust may improve visualization of anatomic structures. The Ovassapian airway cannula is useful as a guide for traversing the oral cavity with the oral approach. FOB may also be done via a laryngeal mask. Thermosoftening of the ETT (35°C saline) improves navigability through the nasal passageways and reduces epistaxis and nasal damage with the nasal approach.

Oral Approach

The FOB is advanced past the base of the tongue and into the posterior oropharynx, with the epiglottis and glottic opening just distal. In a spontaneously ventilating patient the vocal cords will move with respiration. Successful FOB is achieved by traversing the glottic opening through the vocal cords to view the tracheobronchial tree. Tracheal rings and viewing a distal bronchus after ETT advancement confirm tracheal placement.

Nasotracheal Approach

As the nose is entered with the FOB, it is imperative to visualize the inferior and middle turbinates (Fig. 45-6). As the FOB is advanced from the anterior nasal cavity to the posterior nasal cavity, the following anatomic structures should be visualized:

1. Upper nasal pathway. The practitioner will visualize the orifice of the ethmoid air cells and the maxillary sinus.
2. Lower nasal pathway (preferred pathway). The orifice of the nasal lacrimal duct is encountered.

With continued advancement of the scope, the adenoids and opening of the eustachian tubes can be visualized. Once the FOB is at this level, the posterior pharynx and base of the tongue should come into view, with the epiglottis and glottic opening again just distal. The glottic opening, vocal cords, and tracheal rings are visualized as with the oral approach. Maneuvers to optimize the view are similar as with oral FOB.

Careful attention must be given to the location of the middle and inferior turbinates. These landmarks determine the borders of the two paths usually taken by a tracheal tube passing through the nasal passage. Standard practice is to use the lower pathway to avoid structures of the ethmoid bone and cribriform plate.

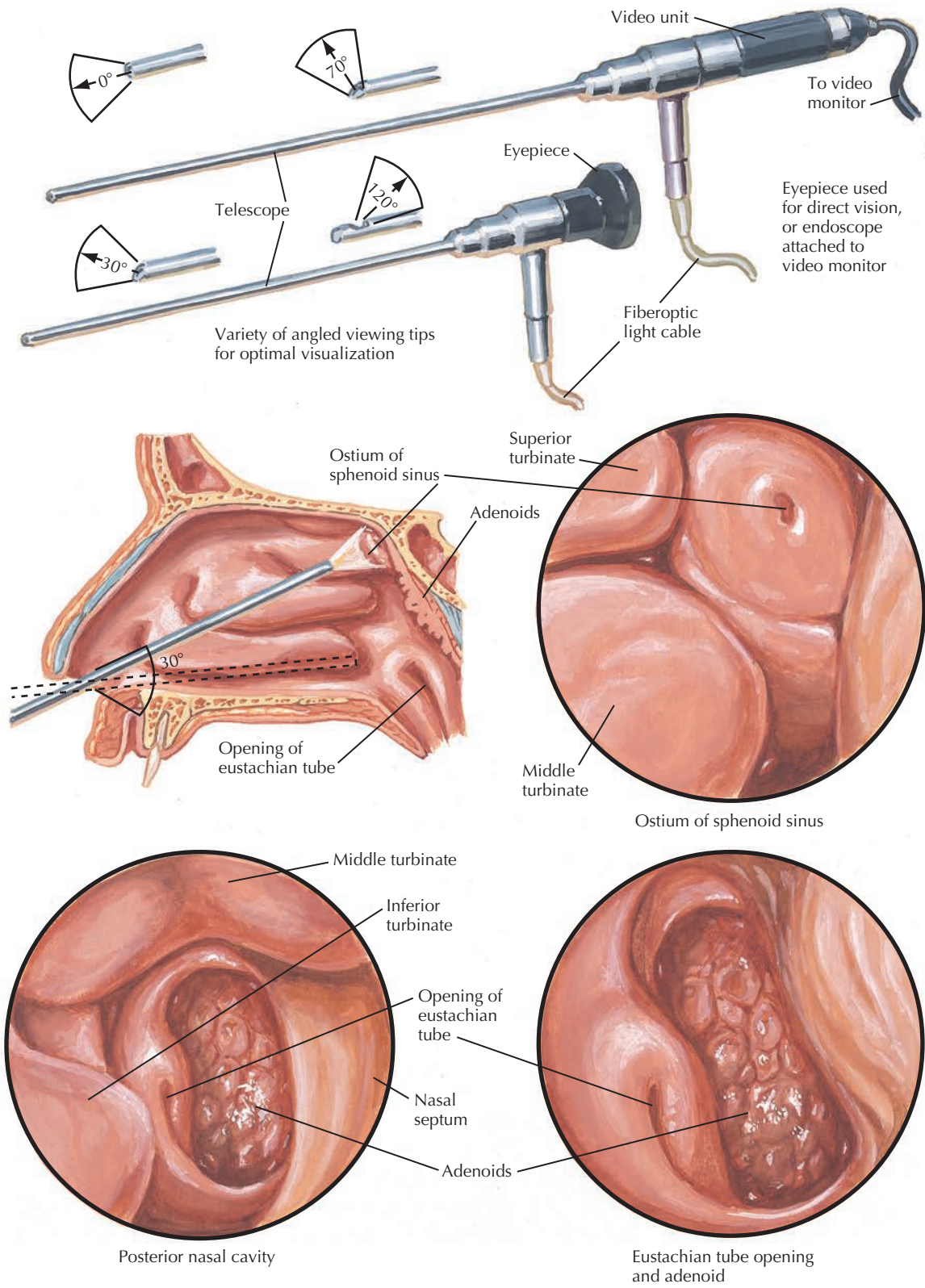


FIGURE 45-6 Sinus endoscopy.

FAILED INTUBATION

It is essential to have contingency plans in the event that intubation is not successful. Such plans usually consist of BMV with oral and nasopharyngeal airways, a supraglottic device (e.g., laryngeal mask airway), or a surgical airway (see Chapter 2).

SUMMARY

The airway is a complex structure. Knowledge of airway anatomy together with clinical skills, judgment, and familiarization with equipment and techniques for ventilation, oxygenation, and intubation are essential to ensure good outcomes, especially during emergency situations.

SUGGESTED READINGS

- American Society of Anesthesiologists. Practice guidelines for management of the difficult airway: an updated report by the American Society of Anesthesiologists task force on management of the difficult airway. *Anesthesiology* 2013;118:251-70.
- Cooper RM, Pacey JA, Bishop MJ, McCluskey SA. Early clinical experience with a new videolaryngoscope (GlideScope) in 728 patients. *Can J Anaesth* 2005;52:191-8.
- Crosby E. Airway management after upper cervical spine injury: what have we learned? *Can J Anesth* 2002;49:733-44.
- Crosby ET, Cooper RM, Douglas MJ, et al. The unanticipated difficult airway with recommendations for management. *Can J Anaesth* 1998;45:757-76.
- Kheterpal S, Han R, Tremper KK, et al. Incidence and predictors of difficult and impossible mask ventilation. *Anesthesiology* 2006;105:885-91.
- Smith CE, DeJoy S. New equipment and techniques for airway management in trauma. *Curr Opin Anaesthesiol* 2001;14:197-209.

Mastectomy

Anthony Visioni and Julian A. Kim

INTRODUCTION

Breast cancer is the most common cancer diagnosed and the second leading cause of cancer mortality in women. Major advances in recent years, including hormonal and monoclonal antibody therapy, have greatly improved outcomes in breast cancer patients. Historically, breast cancer has primarily been a surgically treated disease. In 1894, Halsted (per Dorland's) and Myers described the landmark radical mastectomy. This operation removes the breast tissue, nipple-areola complex, overlying skin, and pectoralis major and minor muscles, in addition to a complete axillary lymphadenectomy. While the radical mastectomy is effective at improving survival, the procedure carries a high morbidity.

Since then, surgeons have developed techniques to minimize morbidity and maximize survival rates. These procedures include partial mastectomy, simple or total mastectomy, modified radical mastectomy, and nipple-sparing mastectomy. Together these procedures have maintained survival rates in properly selected patients while greatly reducing the morbidity of the Halsted radical mastectomy. The approach to surgical intervention is made on the basis of tumor size in relation to breast size, multifocal disease, bilateral disease, specific pathologic considerations of the tumor, the patient's genetic status, and patient preference. This chapter addresses the most common surgical interventions, the partial mastectomy and total mastectomy.

PARTIAL MASTECTOMY

Breast-conserving surgery (i.e. partial mastectomy, lumpectomy, tylectomy, wide local excision, segmental mastectomy) can be considered for early-stage disease (e.g., stages 0, I, and II). When combined with radiation therapy for properly selected patients, breast-conserving surgery has the same survival rate as modified radical mastectomy. Partial mastectomy is increasingly used because the oncologic outcomes are also the same, while improving aesthetics, quality of life, and psychological impact on the patient.

Partial mastectomy is often performed with axillary sentinel lymph node biopsy (SLNB) when the diagnosis of invasive cancer is made. Partial mastectomy can also be performed as excisional biopsy (lumpectomy) without SLNB for a palpable mass or suspicious radiographic finding.

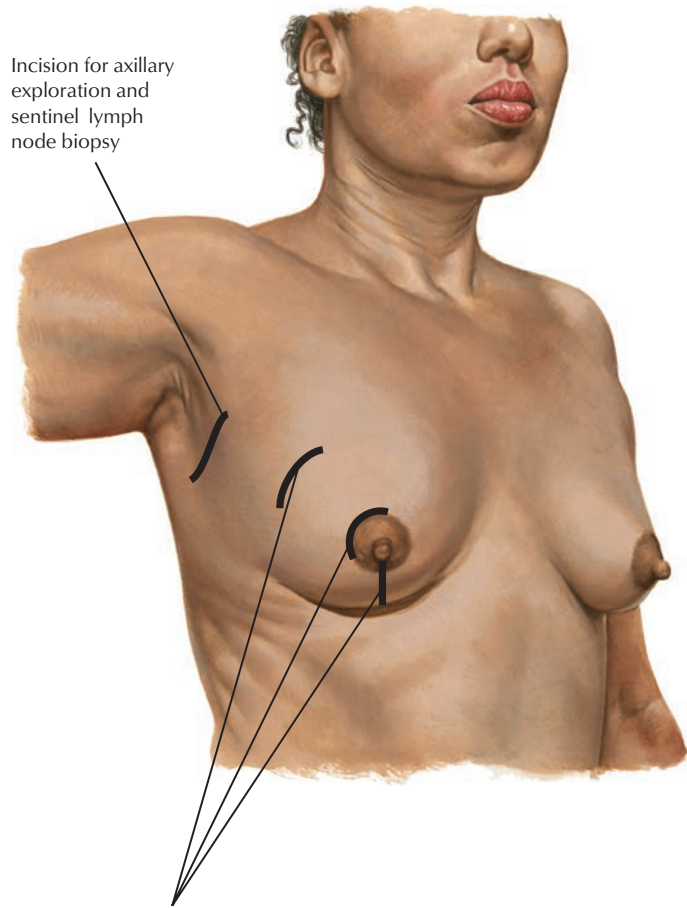
With breast conservation and aesthetics the focus of partial mastectomy, the choice of incision is of great importance (Fig. 46-1, A). Circumareolar incisions provide good cosmesis. Curvilinear incisions that parallel Langer's lines of tension in the upper half of the breast also work well. In the inferior half of the breast, radial incisions provide good cosmesis. For palpable lesions, the incision should be made directly over the tumor. For nonpalpable tumors localized with a wire, care should be made to make the incision over the expected location of the tumor and not necessarily at the insertion of the wire.

Small skin flaps are raised, and then dissection can be performed sharply or with electrocautery. Breast tissue can be grasped with an Allis forceps to facilitate dissection, but care should be used to avoid tearing the tissues (Fig. 46-1, B).

Although currently no consensus exists on margins to obtain for breast-conserving surgery, it is important that the entire lesion is removed with negative margins. Once removed, the specimen must be oriented so that if a margin is positive, another more localized excision can be done (Fig. 46-1, C).

Depending on the size of the breast and the size of the specimen being resected, oncoplastic techniques may be used. For large specimens that may cause dimpling of the skin or obvious deformity, rotation of a portion of breast tissue into the cavity may improve aesthetics. Also, for large breasts and a large specimen, breast reduction techniques may be used to preserve symmetry.

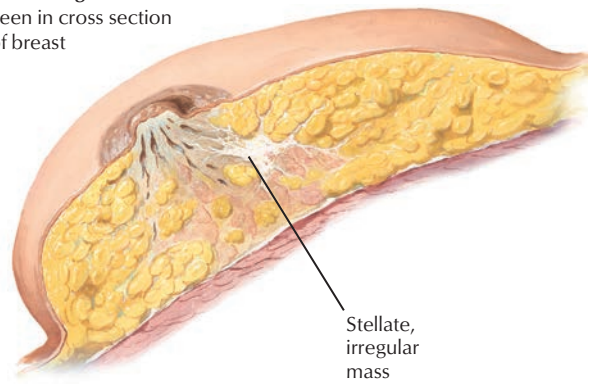
A. Incision for partial mastectomy



Incision for axillary exploration and sentinel lymph node biopsy

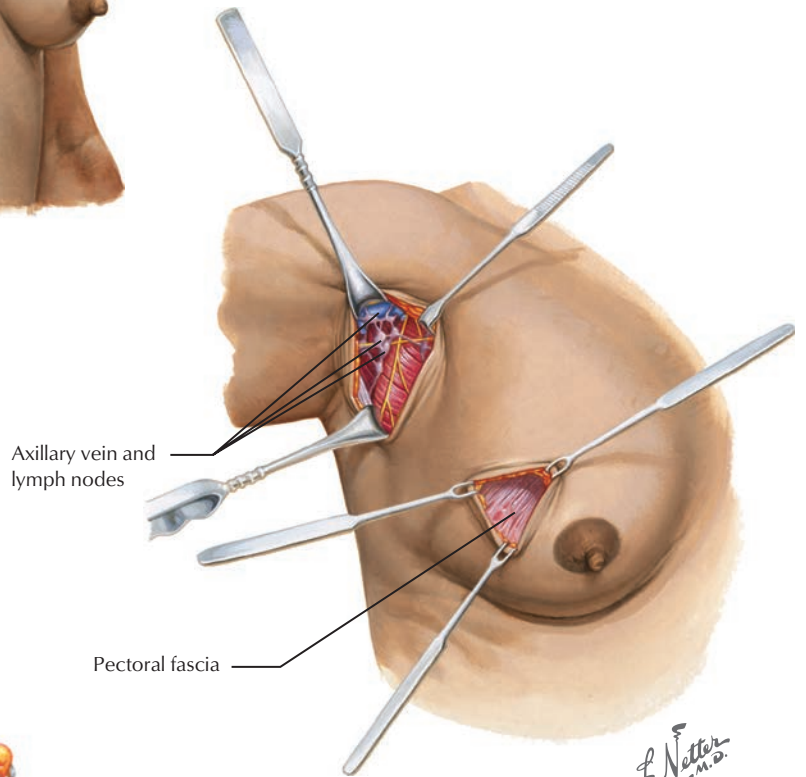
With aesthetic in mind, the incisions of choice are circumareolar, curvilinear that parallel Langer's lines (upper half of the breast), and radial (inferior half of the breast).

Infiltrating carcinoma
Seen in cross section of breast



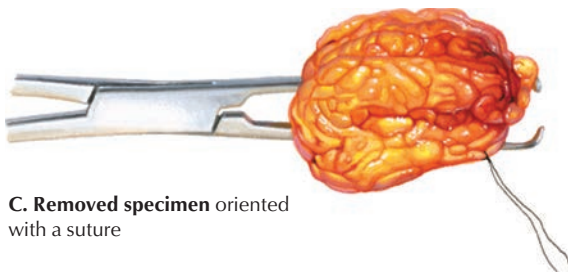
Stellate, irregular mass

B. Dissection of breast



Axillary vein and lymph nodes

Pectoral fascia



C. Removed specimen oriented with a suture

F. Netter M.D.
C. Machado M.D.

FIGURE 46-1 Partial mastectomy.

TOTAL MASTECTOMY

When patients have large tumors in relation to breast size, multifocal disease, or advanced-stage disease, total mastectomy may be the treatment of choice. Other factors, such as patient preference and genetic mutation status, also play an important role in determining surgical treatment options. There is increasing use of genetic testing to screen women at exceptionally high risk for developing breast cancer. Many of these genetically high-risk women are choosing prophylactic mastectomy over close surveillance.

Modified Radical Mastectomy

For most breast cancer patients in whom mastectomy is indicated, the procedure of choice is the modified radical mastectomy. This approach combines total mastectomy (discussed below) with axillary lymph node dissection (see Chapter 49). In the case of prophylactic mastectomy, the typical procedure is the total mastectomy.

The incision for the procedure is typically an ellipse centered on the areola (Fig. 46-2, A). This incision should encompass previous biopsy and excision scars. Methylene blue dye is injected along the superior border of the nipple for SLNB (see Chapter 48).

Skin flaps are then raised, typically with the use of skin hooks or rakes to provide tension (Fig. 46-2, B). The skin flaps should be approximately 7 to 10 mm and thick enough to avoid necrosis and buttonholes, but thin enough to resect all breast tissue. These flaps are carried superiorly to the level of the clavicle and inferiorly to the inframammary fold. The flaps should reach the lateral border of the sternum medially and the latissimus dorsi muscle laterally.

Figure 46-2, C, shows a lateral view of the breast with the correct plane of dissection for mastectomy being deep to the pectoral fascia.

The breast is then dissected off the chest wall, starting superiorly at the clavicle (Fig. 46-2, D and E). This dissection continues inferiorly deep to the retromammary fascia and investing fascia of the pectoralis major muscle. The breast tissue is retracted inferiorly as electrocautery is used to dissect the tissue and investing fascia of the pectoralis from the underlying muscle.

Care should be taken to identify perforating vessels from the pectoralis muscle to the breast tissue and divide them accordingly. These vessels can bleed briskly and if divided too close to the pectoralis, they may retract into the muscle.

Breast Removal and Reconstruction

For a total mastectomy, once the dissection has reached the inframammary fold, the breast can be removed and the overlying skin closed with drains in place (Fig. 46-2, F). If a modified radical mastectomy is performed, the lateral border of the breast that is attached to the axilla should be left in place, and the axillary lymph node dissection is completed. This approach will remove a single specimen containing the breast and contents of the axilla.

An important consideration of breast surgery is reconstruction options. It is important to have a candid discussion with patients before any surgical intervention. Also, it is advisable to consult with a reconstructive plastic surgeon to devise an optimal treatment plan for each patient. Some patients may be candidates for mastectomy and reconstruction at the same surgery, whereas others require delayed reconstruction.

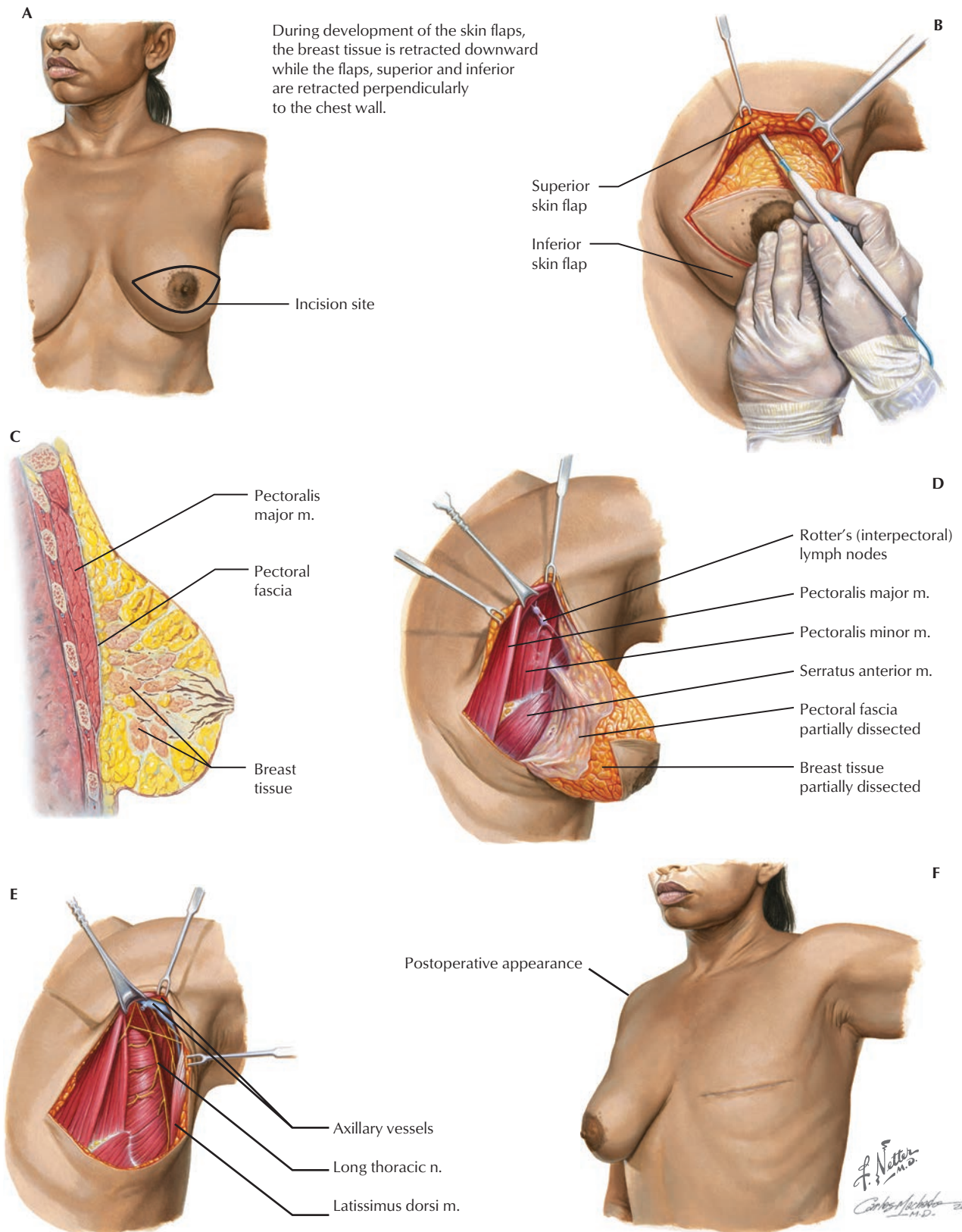


FIGURE 46-2 Total mastectomy with modified radical technique.

SUMMARY

Discussion with the breast cancer patient and multidisciplinary team is essential to determine the most appropriate surgical approach. Skin flap thickness is important; if too thin, there is risk of necrosis, and if too thick, risk of recurrence. When the surgeon is dissecting the investing fascia off the pectoralis major, the perforating vessels can be a source of postoperative bleeding, and care should be taken to ligate or cauterize them appropriately. Breast reconstruction options can affect aspects of the resection and should be planned in advance.

SUGGESTED READINGS

- Clarke M, Collins R, Darby S, et al. Effects of radiotherapy and of differences in the extent of surgery for early breast cancer on local recurrence and 15-year survival: an overview of the randomised trials. *Lancet* 2005;366(9503):2087-106.
- Kuerer HM. *Kuerer's breast surgical oncology*. New York: McGraw-Hill Medical; 2010.
- National Institutes of Health (NIH) consensus conference. Treatment of early-stage breast cancer. *JAMA* 1991;265(3):391-5.
- Salhab M, Bismohun S, Mokbel K. Risk-reducing strategies for women carrying BRCA1/2 mutations with a focus on prophylactic surgery. *BMC Womens Health* 2010;10:28.
- Soltanian H, Okada H. Understanding genetic analysis for breast cancer and its implications for plastic surgery. *Aesthet Surg J* 2008;28(1):85-91.
- Van Dongen JA, Voogd AC, Fentiman IS, et al. Long-term results of a randomized trial comparing breast-conserving therapy with mastectomy. European Organization for Research and Treatment of Cancer 10801 trial. *J Natl Cancer Inst* 2000;92(14):1143-50.

Duct Excision

Anthony Visioni and Julian A. Kim

INTRODUCTION

Nipple discharge is a common complaint for women, with the possibility of intraductal cancer the greatest concern. However, benign disease is more often the cause of nipple discharge. It is therefore important to identify patients who might be at risk for malignancy and would be candidates for surgical resection. Nipple discharge can be defined as physiologic versus pathologic. Pathologic nipple discharge (PND) usually requires surgery to rule out malignancy. PND is typically unilateral, spontaneous, bloody or serous, and from a single duct. Green, creamy, bilateral, nonspontaneous drainage or drainage from multiple ducts usually indicates a nonmalignant process that does not require surgery.

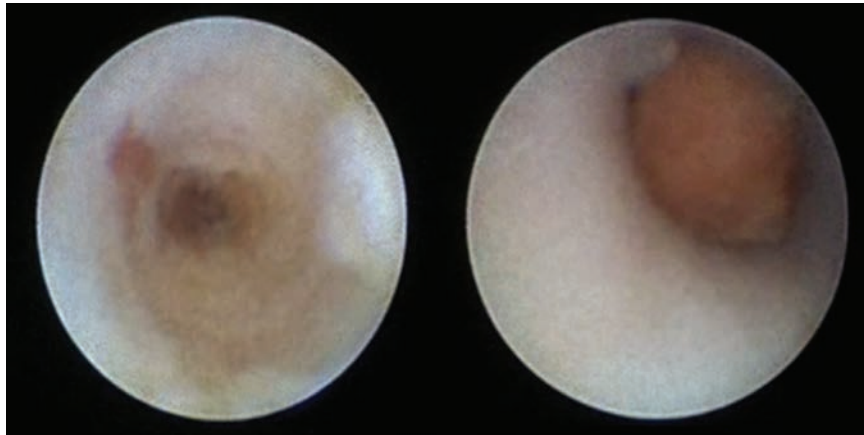
PREOPERATIVE WORKUP

Diagnostic mammography is currently the test of choice in the workup of PND and is generally indicated in all patients. Ultrasound, magnetic resonance imaging (MRI), and ductography are being studied for prediction of malignant disease in PND, although no consensus exists on their use. Also under investigation is *ductoscopy*, real-time endoscopic imaging of the ductal system. Ductoscopy can differentiate normal ducts from intraductal papilloma and provide therapeutic options (Fig. 47-1, A). Although great advances have been made in the equipment and success of ductoscopy, its use is still limited to specialized centers.

Cytology is of limited use for the diagnosis of PND. Even in properly selected patients, cytology is not extremely sensitive or specific.

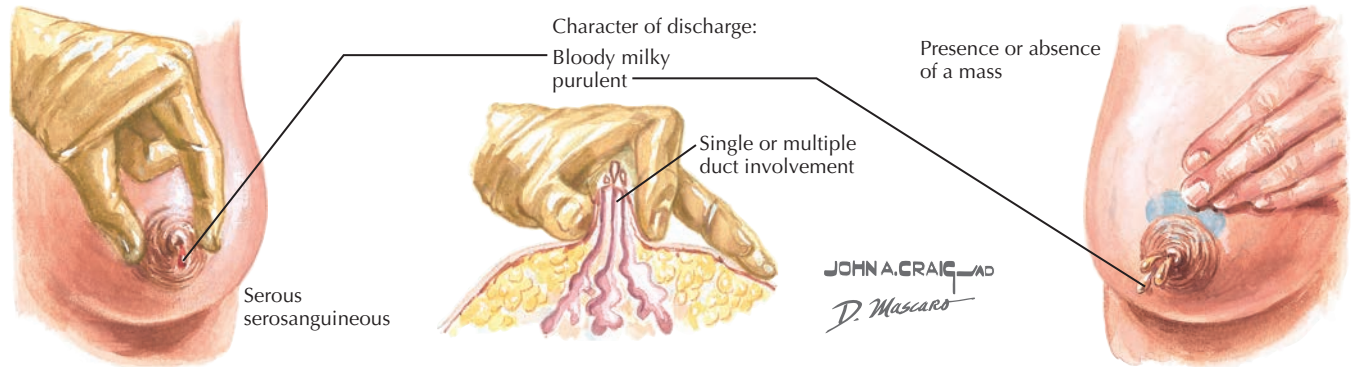
There are several algorithms for the workup of PND, but the most important aspect of the evaluation is to prove that the discharge is not caused by a malignancy (Fig. 47-1, B and C). This often requires surgical resection and pathologic examination of the duct.

A. Ductoscopy



Ductoscopy can differentiate normal ducts (left) from intraductal papilloma (right) and provide therapeutic options.

B. Clinical considerations with nipple discharge



C. Management algorithm for nipple discharge

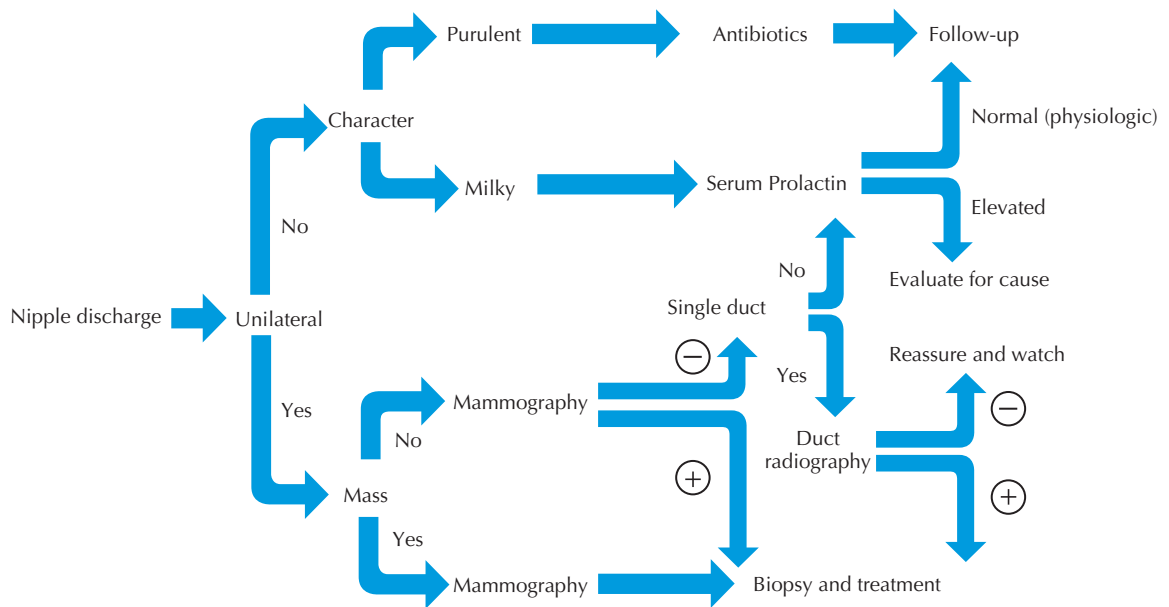


FIGURE 47-1 Management algorithm for nipple discharge.

SURGICAL PRINCIPLES

Duct anatomy is complex, and therefore an attempt should be made to identify the duct from which there is pathologic discharge. Several methods are used to achieve this. First, the nipple can be expressed in the operating room and the draining duct cannulated with a lacrimal probe (Fig. 47-2). Another method is to inject methylene blue preoperatively to guide the dissection of the correct duct. Some authors suggest preoperative ductography to distend the duct of interest and determine the distance needed to dissect from the ductal orifice to the lesion. Some centers equipped with ductoscopy can attempt to visualize and remove the lesion endoscopically; if this is not successful, a standard duct excision is done.

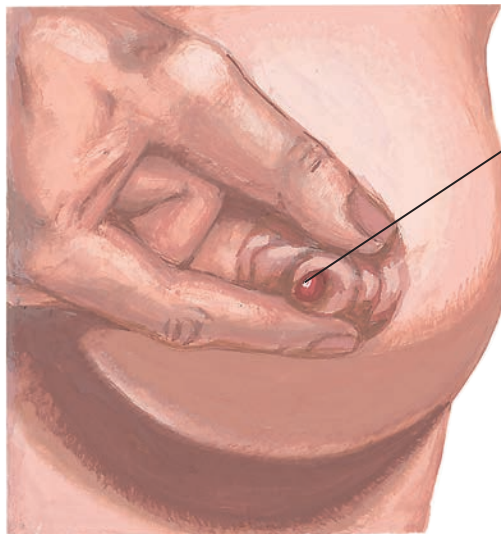
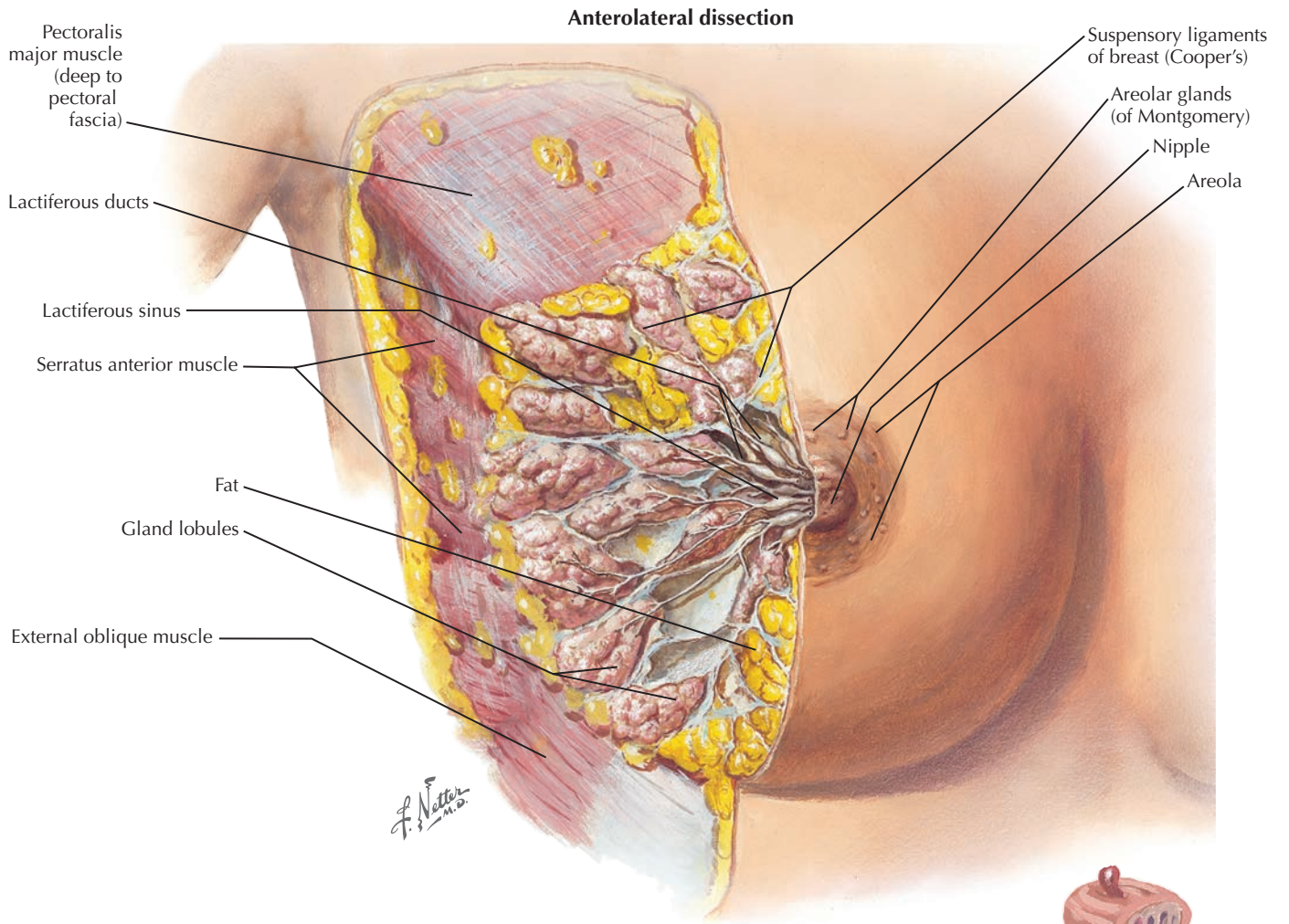
EXCISION TECHNIQUE

If the affected duct cannot be identified on the day of surgery, a *central* duct excision can be performed. This procedure removes all the duct tissue, as opposed to a major duct excision that removes only the affected duct. Some authors argue that this method is overaggressive and recommend breast MRI and close follow-up if no abnormality is noted.

Once the duct is identified, the standard incision for a major duct excision is curvilinear around the nipple-areolar complex. If there is a palpable mass, a curvilinear or radial incision over the mass may be used.

After incision, the nipple-areolar complex is sharply dissected and raised as a flap. Major ducts should be divided close to the nipple. Care must be taken to ensure proper thickness of the flap; a buttonhole or necrosis can occur if the flap is too thin, and segments of duct containing pathology can be left behind if it is too thick.

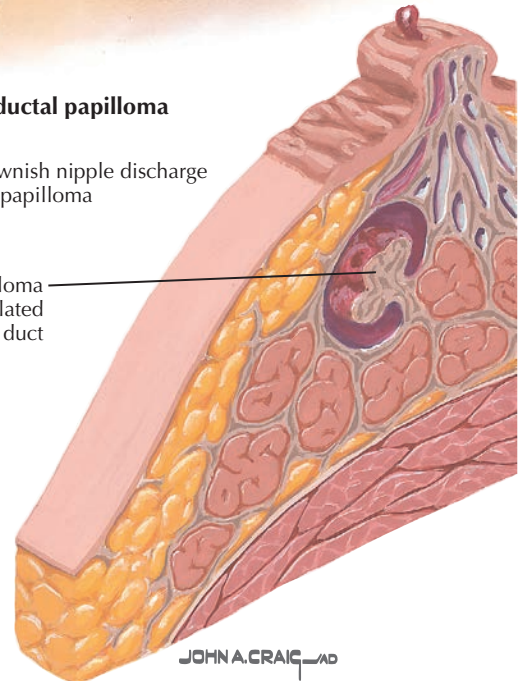
A cone of tissue surrounding the duct of interest is dissected down to the gland lobule (Fig. 47-2). After the duct and surrounding tissue are removed, the remaining defect can be closed with absorbable suture. Before closing the skin, the nipple should be checked to ensure it is everted. If not, a subcutaneous stitch can be placed to evert the nipple.



Solitary intraductal papilloma

Blood-tinged or brownish nipple discharge suggests intraductal papilloma

Single large papilloma located within a dilated mammary duct



JOHN A. CRAIG MD

Palpation will often reveal a mass near the nipple. Duct opening can be cannulated with a fine probe, and only involved duct need be excised

FIGURE 47-2 Duct excision and intraductal papilloma.

SUMMARY

Surgeons must differentiate pathologic from physiologic nipple discharge and therefore surgical from nonsurgical candidates. The duct should be transected close to the nipple and dissected to the gland lobule to ensure that the lesion is removed. Women should be counseled preoperatively about the impact on breastfeeding and cosmesis.

SUGGESTED READINGS

- Dietz JR, Crowe JP, Grundfest S, Arrigain S, Kim JA. Directed duct excision by using mammary ductoscopy in patients with pathologic nipple discharge. *Surgery* 2002;132(4):582-7; discussion 587-8.
- Hussain AN, Policarpio C, Vincent MT. Evaluating nipple discharge. *Obstet Gynecol Surv* 2006;61(4):278-83.
- Kuerer HM. *Kuerer's breast surgical oncology*. New York: McGraw-Hill Medical; 2010.
- Louie LD, Crowe JP, Dawson AE, et al. Identification of breast cancer in patients with pathologic nipple discharge: does ductoscopy predict malignancy? *Am J Surg* 2006;192(4):530-3.
- Mokbel K, Escobar PF, Matsunaga T. Mammary ductoscopy: current status and future prospects. *Eur J Surg Oncol* 2005;31(1):3-8.

Sentinel Lymph Node Biopsy

Anthony Visioni and Julian A. Kim

INTRODUCTION

Several cancers, including breast cancer and melanoma, are similar in that regional lymph node metastasis greatly impacts treatment, chance of recurrence, and survival rate. Therefore, management of regional lymph node metastasis is of great interest in patients with these diseases. Previously, the standard of care for a patient diagnosed with invasive cancer was to perform a lymphadenectomy—removal of all regional lymph tissue. Although associated with high morbidity, the procedure was performed to diagnose and treat regional lymph node disease and to correctly stage a patient for further systemic therapy.

Sentinel lymph node biopsy (SLNB) has dramatically changed the management of breast cancer and melanoma patients. The procedure was first described in 1977 by Cabanas for penile cancer; diagnostic and therapeutic applications have since grown. Instead of routine lymphadenectomy, patients who are clinically node negative can now be accurately staged with minimal morbidity.

DYE/RADIOTRACER AND INJECTION SITES

The injection site for the blue dye or the radiotracer can be either over the tumor or the areola (Fig. 48-1). In the operating room the surgeon then looks for a blue lymph node (if dye is used), a radioactive lymph node (if radiotracer is used), or both. With a radiotracer, multiple nodes may be radioactive. It is important to search for the node with the highest level of radioactivity. This node, as well as all nodes with more than 10% of the highest count, should be removed for pathologic evaluation.

In breast cancer, the choice of blue dye or radiolabeled colloid to perform SLNB has been the subject of multiple studies. Some studies report that the combination of blue dye and radiolabeled colloid is optimal for identification of sentinel nodes, whereas other studies show equivalence. In general, the choice of blue dye or radiolabeled colloid should be dictated by surgeon preference as well as contraindications in patients (e.g., pregnancy, allergy).

LYMPHATIC DRAINAGE

Another important consideration is the choice of injection site. The lymphatic drainage of the breast and overlying skin are the same: both drain to the axillary lymph nodes. Therefore, intradermal injection (vs. peritumoral injection) of radiotracer is an acceptable practice. Peri-areolar and subareolar injections work equally well for SLNB. However, intradermal injection of blue dye may lead to skin discoloration and should be avoided in breast cancer. This approach contrasts with melanoma, in which intradermal injections are required; the discoloration of the skin is irrelevant because a wide local excision will be performed at the time of SLNB (Fig. 48-1).

In the case of melanoma, injection of radiolabeled colloid allows for preoperative *lymphoscintigraphy*. The lymphatic drainage is more variable in melanoma; therefore, lymphoscintigraphy with use of intraoperative gamma probe increases the likelihood of identifying the sentinel lymph node in melanoma involving various anatomic locations.

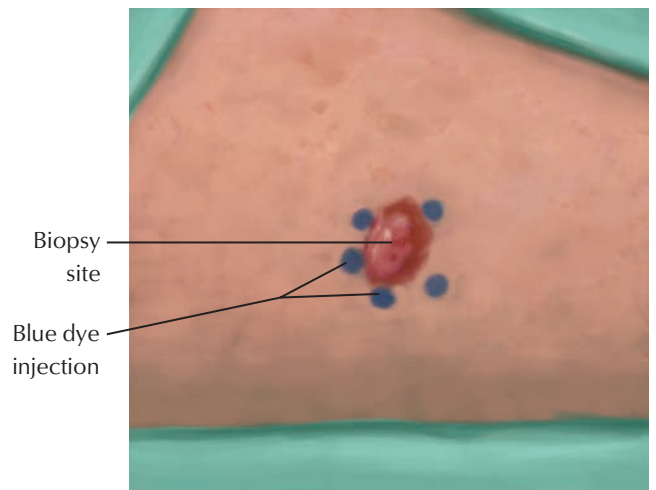
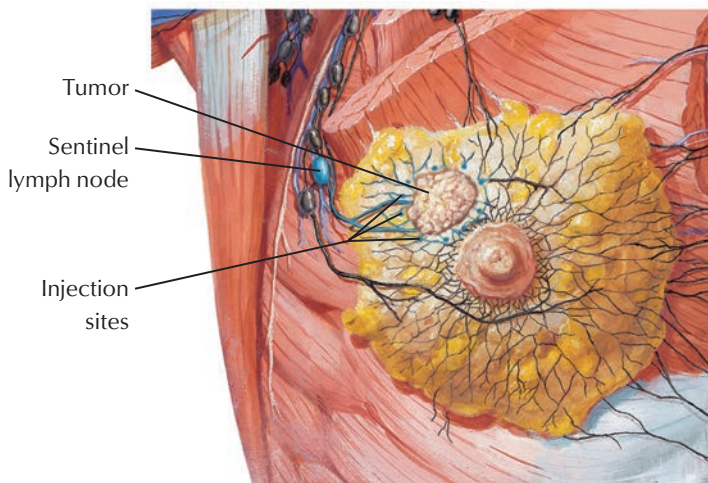
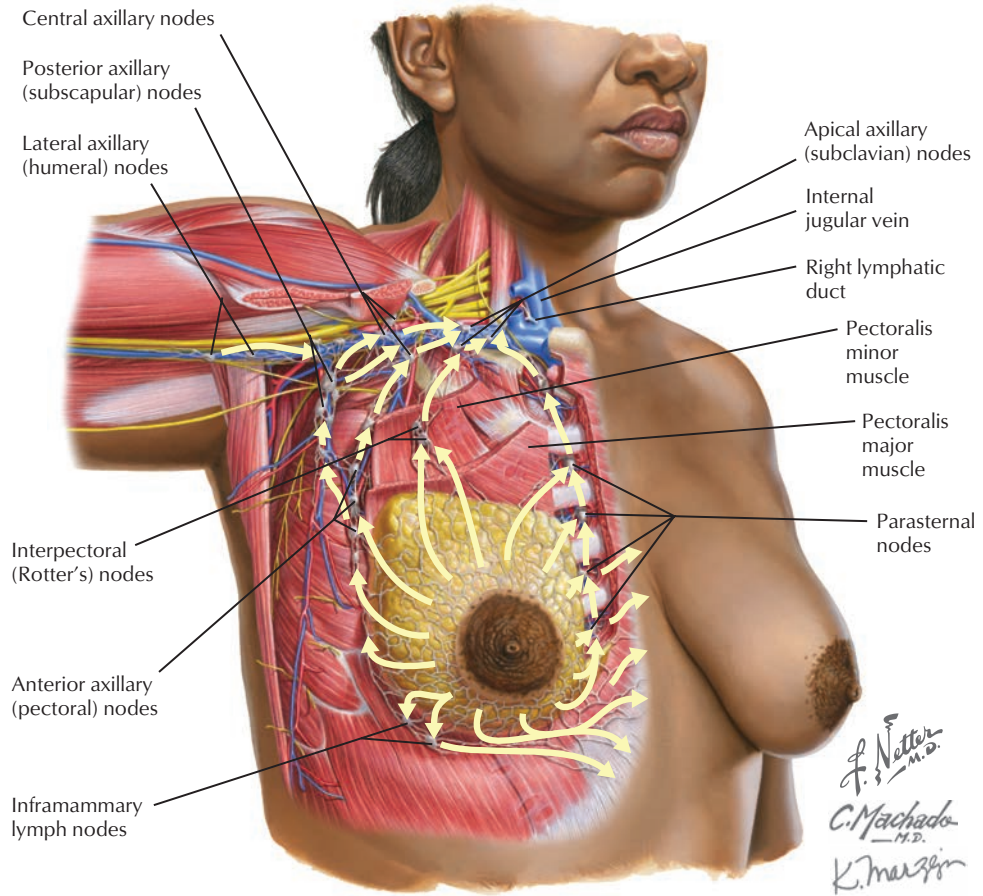


FIGURE 48-1 Sentinel lymph node biopsy.

LESION DRAINAGE TO LYMPH NODES

Unlike breast cancer, the variable locations of cutaneous melanoma lead to SNLB being performed in multiple locations. Typically, upper-extremity melanoma will drain to the axillary lymph nodes, although epitrochlear lymph nodes may also contain the sentinel node in distal tumors (Fig. 48-2, *A*). Lesions of the scalp typically drain to the posterior cervical lymph nodes, whereas lesions of the face and oral cavity usually drain to the anterior cervical lymph nodes (Fig. 48-2, *B*). Lower-extremity tumors can drain into the popliteal or inguinal node basins (Fig. 48-2, *C* and *D*).

Incisions for the sentinel lymph node biopsies are guided by the expected location of sentinel nodes. For breast cancer, a curvilinear incision at the inferior margin of the axillary hairline is almost uniformly used. This approach allows excellent access to the axilla, as well as excision of the scar if subsequent lymphadenectomy is required. This incision is also used for melanoma in the axilla. Preoperative lymphoscintigraphy for patients with melanoma will indicate if there is an epitrochlear or popliteal sentinel node in tumors of the distal extremity. If a node is found in these beds, a small axial incision over the bed will suffice. If the sentinel node is located in the inguinal region, a 3-cm axial incision below the inguinal ligament should provide the necessary exposure. However, these incisions can be tailored to the location of the sentinel nodes seen on lymphoscintigraphy.

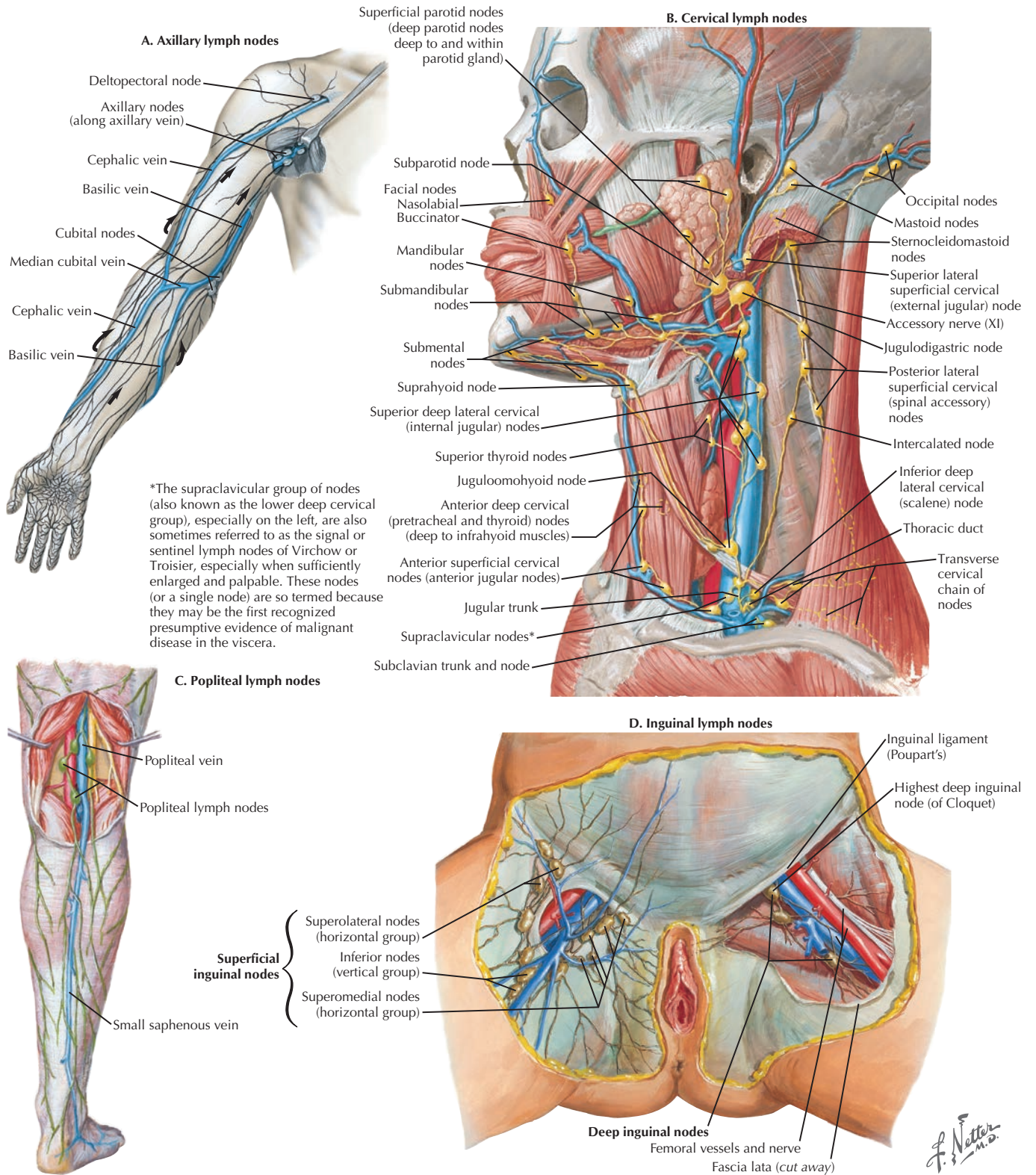


FIGURE 48-2 Axillary, cervical, popliteal, and inguinal lymph nodes.

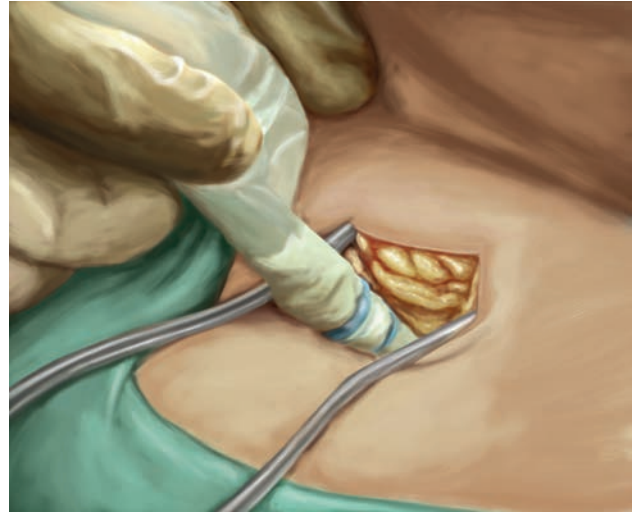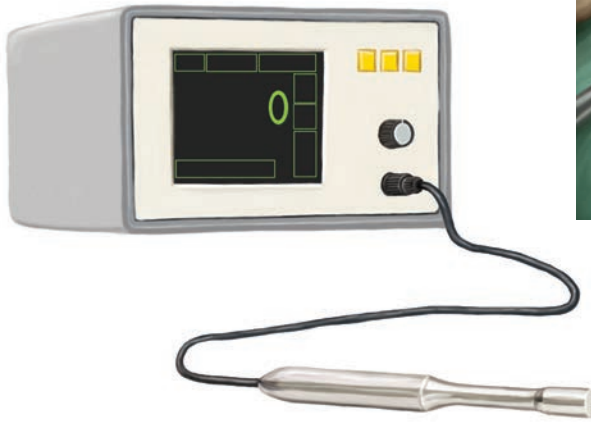
IDENTIFICATION OF THE SENTINEL LYMPH NODE

After entering the approximate area of the sentinel node, the surgeon begins localized dissection. If blue dye is used, careful dissection is performed until a blue node is discovered. If radiolabeled colloid is used, a gamma probe will guide the dissection (Fig. 48-3, *A*).

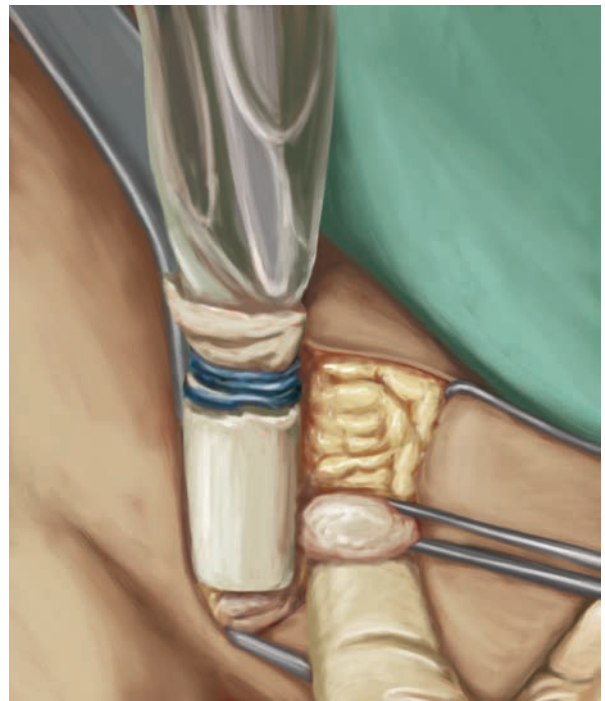
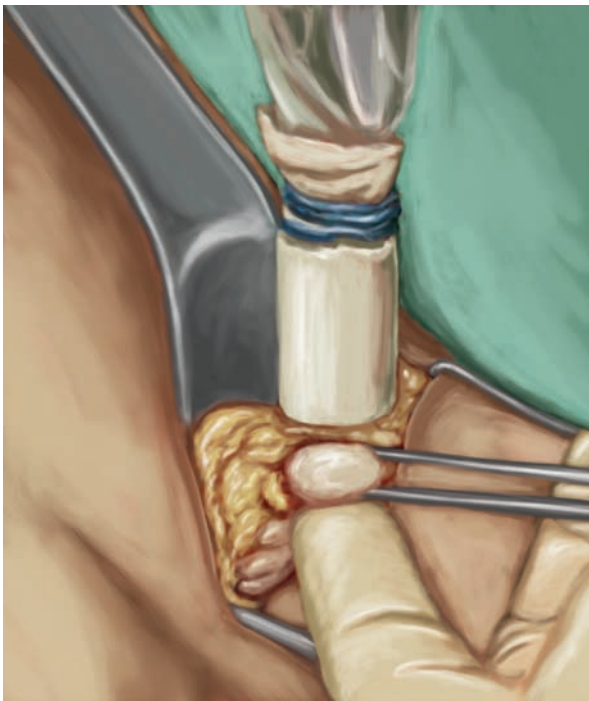
It is important to understand the relationship between the injection site and the direction the probe is pointing. In a phenomenon referred to as “shine through,” pointing the gamma probe in the direction of the injection site could cause falsely elevated counts and mislead the approach of the dissection. It is also important to understand this principle, as it applies to the lymph nodes themselves.

After identifying a “hot” lymph node (Fig. 48-3, *B*), the surgeon should examine the tissue directly behind it to ensure that the node is truly hot and not just registering background from another node (Fig. 48-3, *C*).

A. Gamma counter unit



B. Identifying "hot" lymph node



C. After identifying a "hot" lymph node (*left*), the tissue directly behind it should be examined to insure that the node is truly "hot" and not just registering background from another node (*right*).

K. Marzani

FIGURE 48-3 Identification of "hot" lymph node.

SUMMARY

Both radiolabeled colloid and blue dye can be used with equivalent identification of sentinel nodes. In breast cancer, subdermal, intradermal, periareolar, and subareolar injections lead to equivalent identification of sentinel nodes, although prior axillary surgery, multicentric tumors, and other factors may affect the choice. Intradermal blue dye should be avoided in breast cancer. Sentinel lymph node biopsy usually does not require extensive deep dissection, but care is taken in the axillary, inguinal, and popliteal dissection to avoid vascular structures. When using radioactive colloid, the surgeon should remove the node with any highest count and any nodes within 10% of the highest count should be removed.

SUGGESTED READINGS

- Ashikaga T, Krag DN, Land SR, et al. Morbidity results from the NSABP B-32 trial comparing sentinel lymph node dissection versus axillary dissection. *J Surg Oncol* 2010;102(2):111-18.
- Bagaria SP, Faries MB, Morton DL. Sentinel node biopsy in melanoma: technical considerations of the procedure as performed at the John Wayne Cancer Institute. *J Surg Oncol* 2010;101(8):669-76.
- Kelly TA, Kim JA, Patrick R, Grundfest S, Crowe JP. Axillary lymph node metastases in patients with a final diagnosis of ductal carcinoma in situ. *Am J Surg* 2003;186(4):368-70.
- Krag DN, Anderson SJ, Julian TB, et al. Sentinel-lymph-node resection compared with conventional axillary-lymph-node dissection in clinically node-negative patients with breast cancer: overall survival findings from the NSABP B-32 randomised Phase 3 trial. *Lancet Oncol* 2010;11(10):927-33.
- Lynch MA, Jackson J, Kim JA, Leeming RA. Optimal number of radioactive sentinel lymph nodes to remove for accurate axillary staging of breast cancer. *Surgery* 2008;144(4):525-31; discussion 531-2.
- Menes TS, Schachter J, Steinmetz AP, Hardoff R, Gutman H. Lymphatic drainage to the popliteal basin in distal lower extremity malignant melanoma. *Arch Surg* 2004;139(9):1002-6.
- Sloan P. Head and neck sentinel lymph node biopsy: current state of the art. *Head Neck Pathol* 2009;3(3):231-7.

Axillary and Inguinal Lymphadenectomy

Anthony Visioni and Julian A. Kim

INTRODUCTION

British surgeon Sir Berkeley Moynihan stated, “Surgery of cancer is not the surgery of the organs; it is the surgery of the lymphatic system.” This statement is especially true of breast cancer and melanoma, in which specific operations are carried out to remove regional lymph node metastases. Lymph node dissection (LND) was the standard of care for staging as well as treating these patients. However, sentinel lymph node biopsy (SLNB) changed the way surgeons stage and treat both breast cancer and melanoma (see Chapter 48).

Currently, LND is rarely used as a staging procedure. Furthermore, emerging evidence indicates LND may not impact survival rate in select patients with breast cancer. However, it continues to have a role in regional treatment of cancer for melanoma and breast cancer. Typically, most patients seen for LND have had their primary tumor excised and SLNB performed, which has shown metastatic disease in lymph nodes. These patients then undergo a workup to determine whether they are free of distant metastatic disease. Patients with distant metastatic disease are usually not candidates for LND and would benefit more from systemic therapies.

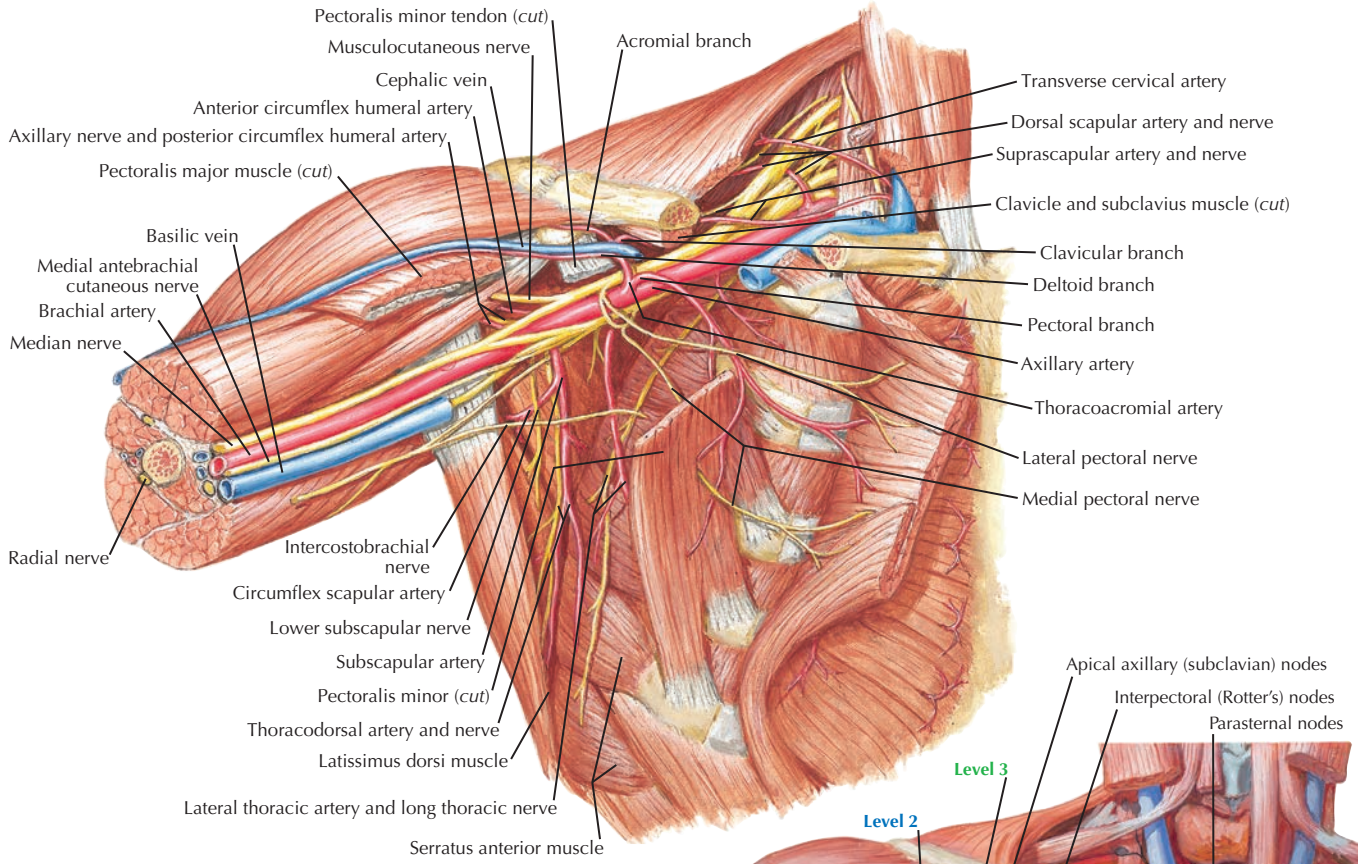
AXILLARY LYMPH NODE DISSECTION

A thorough understanding of the anatomy of the axilla is extremely important when performing an axillary lymph node dissection (ALND). The procedure involves an extensive dissection around important neurovascular structures.

The boundaries of the axilla are the axillary vein superiorly, serratus anterior muscle and chest wall medially, subscapularis and teres minor posteriorly, latissimus dorsi laterally, and pectoralis minor and major muscles anteriorly (Fig. 49-1, A). These structures create a pyramid, with the apex positioned superiorly.

The lymph nodes of the axilla are divided into levels I, II, and III, on the basis of their anatomic location in relation to the pectoralis minor (Fig. 49-1, B). Level I nodes are lateral to the lateral edge of the pectoralis minor muscle, level II nodes are posterior to the pectoralis minor, and level III nodes are medial to the medial edge. Lymph nodes are also located between the pectoralis minor and major muscles (Rotter's interpectoral nodes).

A. Axillary vessels and muscles



B. Axillary lymph nodes

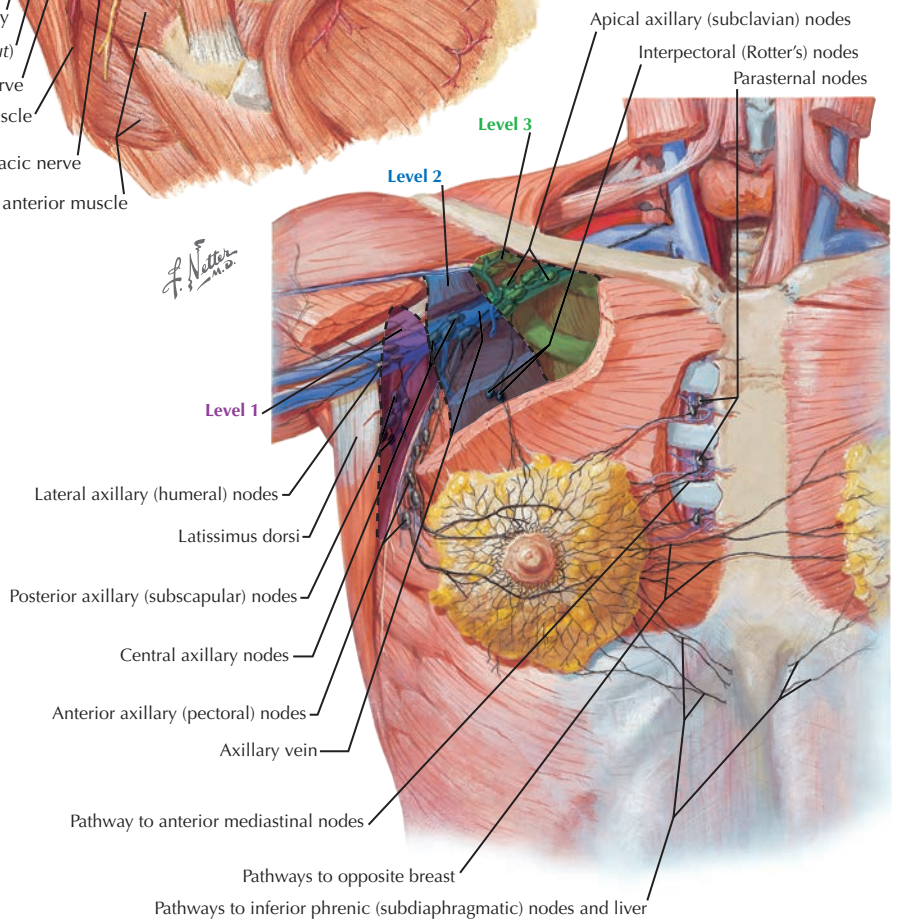


FIGURE 49-1 Axilla (dissection) and lymph vessels/nodes of mammary gland.

AXILLARY LYMPH NODE DISSECTION—Cont'd

The patient should be positioned with the arm abducted 90 degrees. If the patient is undergoing a modified radical mastectomy, access to the axilla is gained through the mastectomy incision (see Chapter 46). Otherwise, a curvilinear incision at the inferior margin of the axillary hairline is typically used (Fig. 49-2, A). If present, a scar from previous SLNB should be used for the incision instead.

The initial step in ALND is creating skin flaps. The flaps should be raised superiorly to the level of the axillary vein and inferiorly to the 4th or 5th rib. Laterally, the flaps should extend to the latissimus dorsi and medially to the pectoralis major. If the ALND is part of a modified radical mastectomy, these flaps may be already raised as part of the mastectomy.

After raising the skin flaps, the surgeon should identify the axillary vein (Fig. 49-2, B). This is typically performed by following the latissimus dorsi muscle to its insertion. Its tendon will course posterior to the lateral aspect of the axillary vein. Once identified, the axillary vein should be skeletonized inferiorly, with its inferior branches ligated. It is important to recognize the thoracodorsal vessels and nerve; these course inferiorly, but will actually enter the axillary vein posteriorly, and should not be ligated.

The axillary vein can be followed medially, leading to the dissection of level II nodes. Currently, there is little indication to remove level III nodes, which therefore are typically not dissected.

After the superior dissection is completed, the specimen can be retracted inferiorly and the remainder of the lymphatic tissue (level I nodes) removed. When the surgeon is beginning to dissect inferiorly, special care should be taken to identify and preserve the long thoracic nerve. This nerve will follow a course along the chest wall and insert into the serratus anterior muscle. Excessive traction on the specimen can raise or tent the long thoracic nerve, which may make the nerve appear to insert into the specimen, subjecting it to ligation.

The thoracodorsal nerve is also important to identify, coursing laterally along the medial surface of the latissimus dorsi muscle (Fig. 49-2, B).

While the surgeon is dissecting inferiorly, an intercostobrachial nerve is seen coursing from the chest wall through the axilla to the upper arm. The intercostobrachial nerve is a sensory nerve to the medial upper arm. Although it can be sacrificed if involved with prominent adenopathy, an attempt should be made to preserve the intercostobrachial nerve.

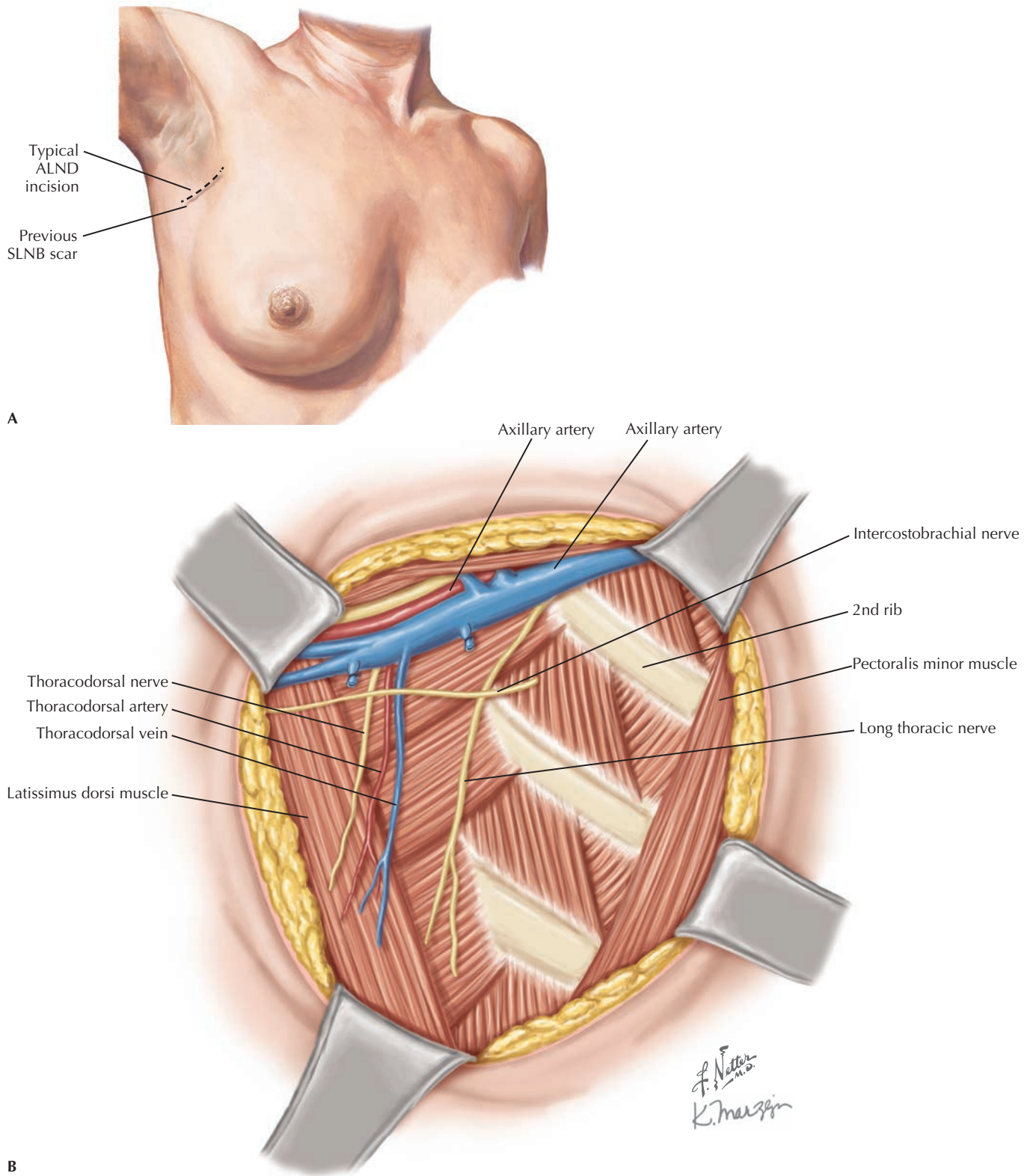


FIGURE 49-2 Axillary lymph node dissection. ALND, Axillary lymph node dissection; SLNB, sentinel lymph node biopsy.

INGUINAL LYMPH NODE DISSECTION

Similar to an ALND, dissection of the inguinal lymphatic tissue requires an understanding of the relevant anatomy to avoid neurovascular injury. For an inguinal lymph node dissection (ILND), the borders of the operation are defined by the sartorius muscle laterally, the adductor longus muscle medially, and the inguinal ligament superiorly. The sartorius courses medially across the thigh, creating a triangle containing lymphatic tissue.

The lymphatic tissue of the inguinal region is divided into superficial and deep (Fig. 49-3). The superficial lymph nodes are those in the previously mentioned triangle, superficial to the fascia lata. The lymph tissue surrounds the greater saphenous vein medially and extends laterally and superiorly toward the anterior superior iliac spine (ASIS). These are the primary nodes removed during an ILND.

The deep inguinal nodes are deep to the fascia lata and within the femoral sheath. The nodes course superiorly with the artery and vein beneath the inguinal ligament. Although not routinely excised during ILND, the deep inguinal nodes should be removed as well if there is obvious adenopathy or bulky disease.

Access to this region is obtained through an elongated curvilinear incision (Fig. 49-3, A). Skin flaps are then raised laterally to the sartorius muscle and medially to the adductor longus muscle.

Typically, the surgeon starts the dissection by clearing the lymphatic tissue superior to the inguinal ligament and just medial to the ASIS. The dissection can then be carried inferiorly and laterally along the sartorius muscle (Fig. 49-3, B).

Once the lateral border of the specimen has been dissected, attention is turned to the medial border. While the medial border of the specimen is cleared, the aponeurosis of the external oblique muscle will be identified with the superficial inguinal ring. Also identified is the femoral sheath, containing the femoral artery, vein, and nerve. Care is taken to identify the great saphenous vein, which will uniformly be superficial to the fascia of the medial thigh (Fig. 49-3, C). The great saphenous vein will then drain into the femoral vein through the saphenous opening or fossa ovalis.

This procedure removes the superficial inguinal nodes. If access to the deep nodes is required, an incision can be made through the aponeurosis of the external oblique muscle and inguinal ligament.

If exposed femoral vessels are a concern after the specimen has been removed, a sartorius muscle flap may be used for coverage (Fig. 49-3, D). This maneuver involves dissecting the sartorius from its insertion on the ASIS and rotating it medially over the femoral vessels. This flap is then sutured into place along the inguinal ligament. Care should be taken to ensure that its medial blood supply remains intact.

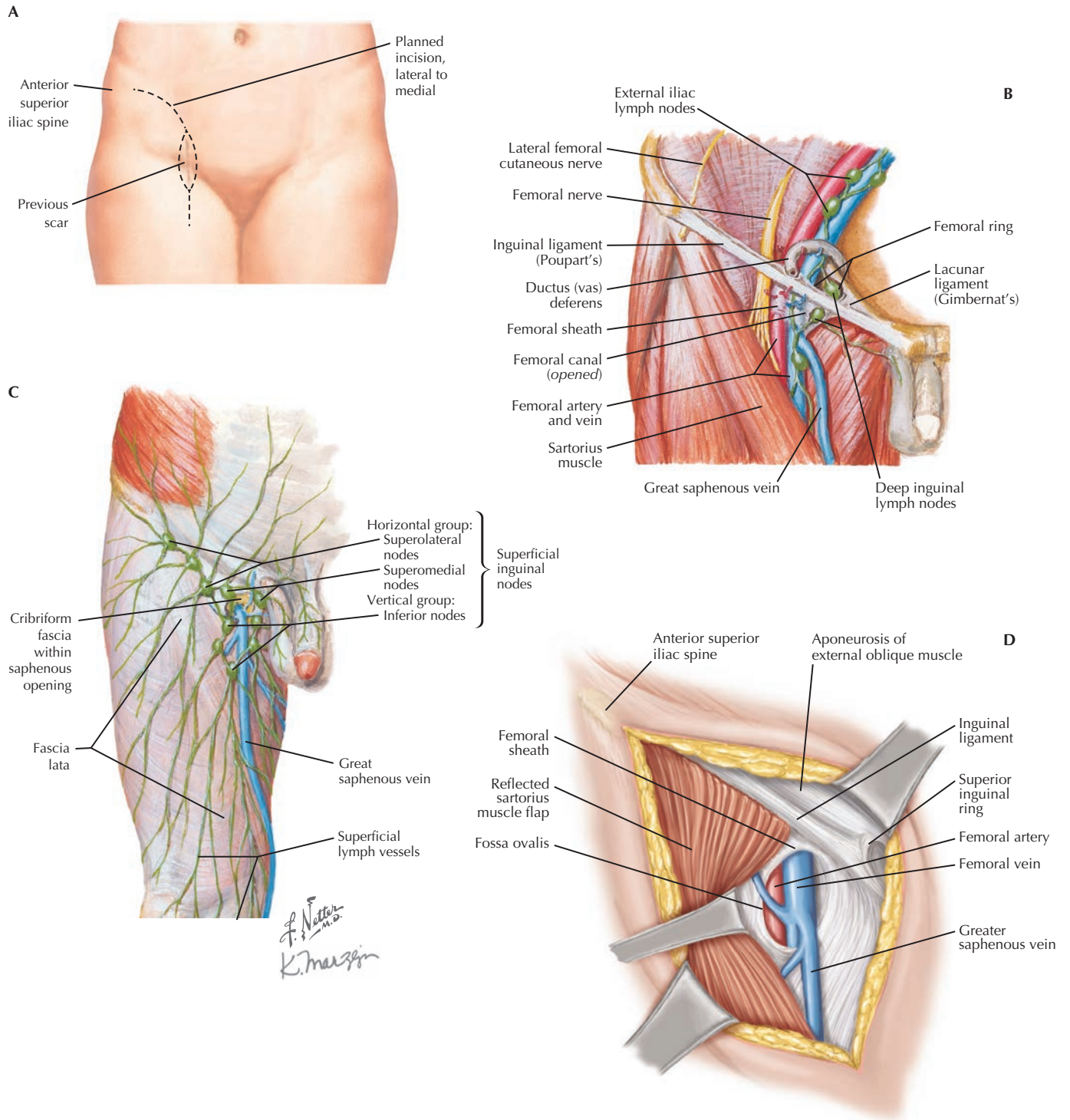


FIGURE 49-3 Inguinal lymph node dissection.

SUMMARY

Careful attention to neurovascular structures coursing through lymphatic beds will prevent injury during axillary and inguinal lymphadenectomy. For axillary procedures, only tissue inferior to the axillary vein is removed. For inguinal surgery, deep nodes are not routinely resected, and a sartorius flap may be used for exposed vessels.

SUGGESTED READINGS

Dzwierzynski WW. Complete lymph node dissection for regional nodal metastasis. *Clin Plast Surg* 2010;37(1):113-25.

Faries MB, Thompson JF, Cochran A, et al. The impact on morbidity and length of stay of early versus delayed complete lymphadenectomy in melanoma: results of the Multicenter Selective Lymphadenectomy Trial (I). *Ann Surg Oncol* 2010;17(12):3324-9.

Giuliano AE, Hunt KK, Ballman KV, et al. Axillary dissection vs no axillary dissection in women with invasive breast cancer and sentinel node metastasis: a randomized clinical trial. *JAMA* 2011;305(6):569-75.

Schmidt C. How to handle positive sentinel nodes. *J Natl Cancer Inst* 2010;102(24):1820-3.

Retroperitoneal Sarcoma



Anthony Visioni and Julian A. Kim

INTRODUCTION

Retroperitoneal sarcomas account for 10% to 15% of adult soft tissue sarcomas, or about 1000 new cases each year. Patients have relatively poor survival rates because these tumors often do not produce symptoms until late in the disease. Retroperitoneal sarcomas can become quite large before symptoms begin; about half will exceed 20 cm at diagnosis.

Nonsurgically treated lymphoma should be ruled out in patients with retroperitoneal masses. Computed tomography (CT) scans should be performed to determine the extent of the tumor, show its relationship to surrounding structures, and identify possible distant metastases. CT-guided biopsy of the mass is the technique of choice for definitive diagnosis.

Complete margin-negative resection is the standard of care for retroperitoneal sarcoma. These tumors can invade surrounding organs, with kidney, colon, pancreas, and spleen most often involved. Also, these tumors create intense reactions in surrounding tissues; these reactions make it difficult to assess whether the tumors are invading, rather than just pushing on, surrounding structures.

PREOPERATIVE IMAGING AND INCISION

The retroperitoneum has many vital structures, including the kidneys, pancreas, inferior vena cava (IVC), and the aorta (Fig. 50-1). These structures are close to each other and can become greatly distorted by a large retroperitoneal tumor. Preoperative imaging is particularly useful; the CT scan in Figure 50-1 shows a large, right retroperitoneal tumor. This tumor encroaches on the IVC and clearly involves the right kidney. Availability of this information before surgery can allow for preoperative assessment of kidney function in the event of nephrectomy and planning for possible vascular resection (consulting with vascular surgeon).

Incisions for this operation are varied. A standard midline laparotomy incision works well for most cases. In other situations, placement of the patient in the lateral decubitus position and performing a curvilinear flank incision allows the best exposure. Most cases can be performed through a midline incision, and this chapter focuses on the procedure through this incision.

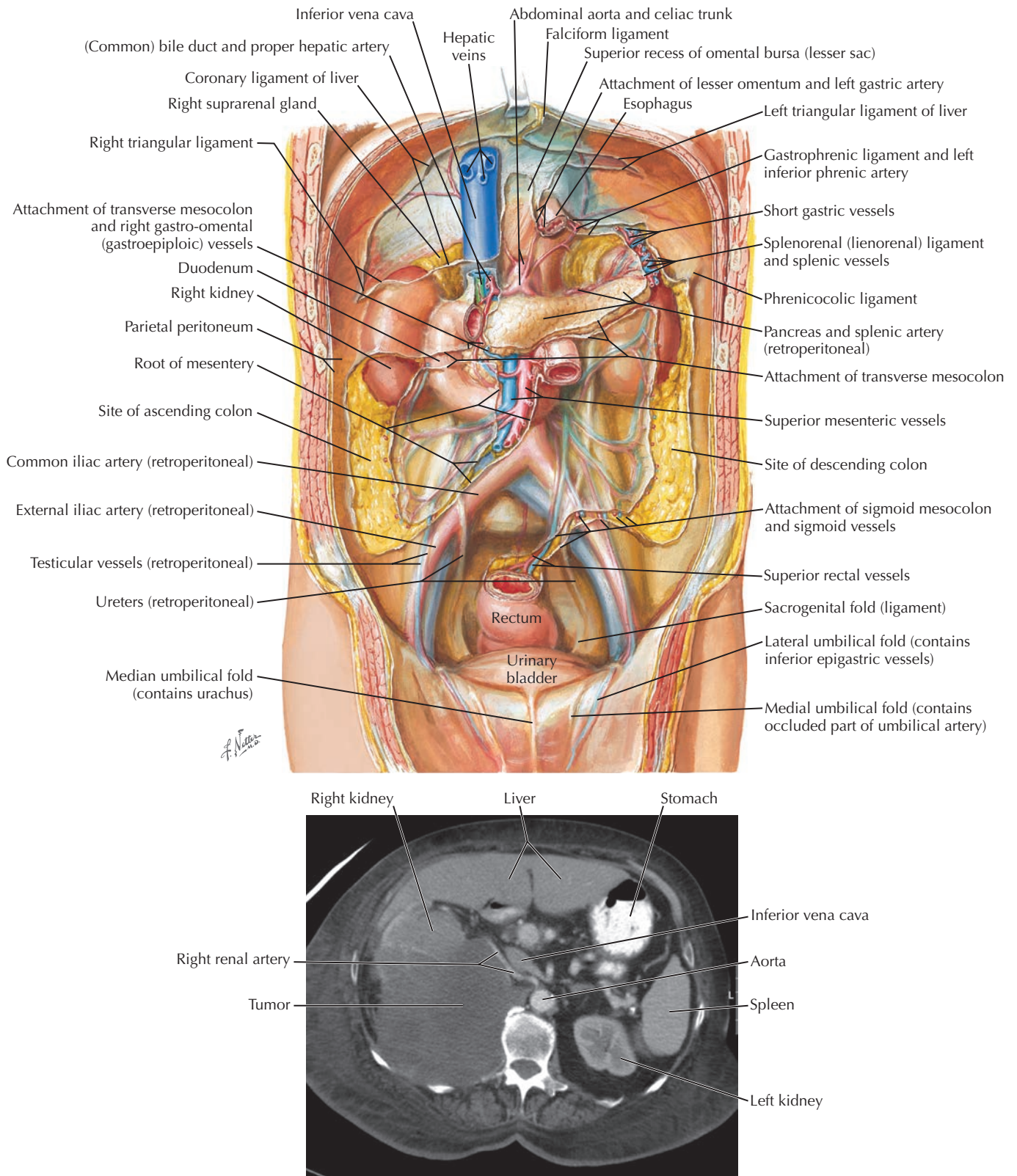


FIGURE 50-1 Retroperitoneal anatomy and CT scan of large tumor.

ABDOMINAL EXPOSURE FOR TUMOR REMOVAL

After the surgeon enters the abdomen, the retroperitoneal tumor is often the first structure to be seen and distorts the normal anatomy; a common site is shown in [Figure 50-2](#). It is in these situations that correctly recognizing structures and being in the correct plane are vital.

Typically, the first step to approaching a retroperitoneal tumor, or gaining access to the retroperitoneum for any procedure, is to retract the colon (either ascending or descending) medially and find the reflection of peritoneum, the white line of Toldt. This line will guide the dissection and provide exposure into the right or left retroperitoneum, where tumors typically develop. (Toldt's fascia, or membrane, is part of the renal fascia anterior to the kidney.)

If more superior exposure is required in the right retroperitoneum, a Kocher maneuver can be performed. This maneuver involves freeing the lateral border of the duodenum from its retroperitoneal attachments and retracting it medially.

Once full exposure of the tumor is obtained, a more detailed assessment can be made of the surrounding structures that are involved. Margin status has a major impact on survival rate, so every attempt should be made for a complete en bloc, margin-negative resection. This often means that the kidney, portions of the colon, vascular structures, or portions of the duodenum are resected.

[Figure 50-2](#) shows the right retroperitoneum after removal of a large retroperitoneal tumor. Notice that the right kidney was resected as well. In this case the right colon and the duodenum have been mobilized and retracted medially.

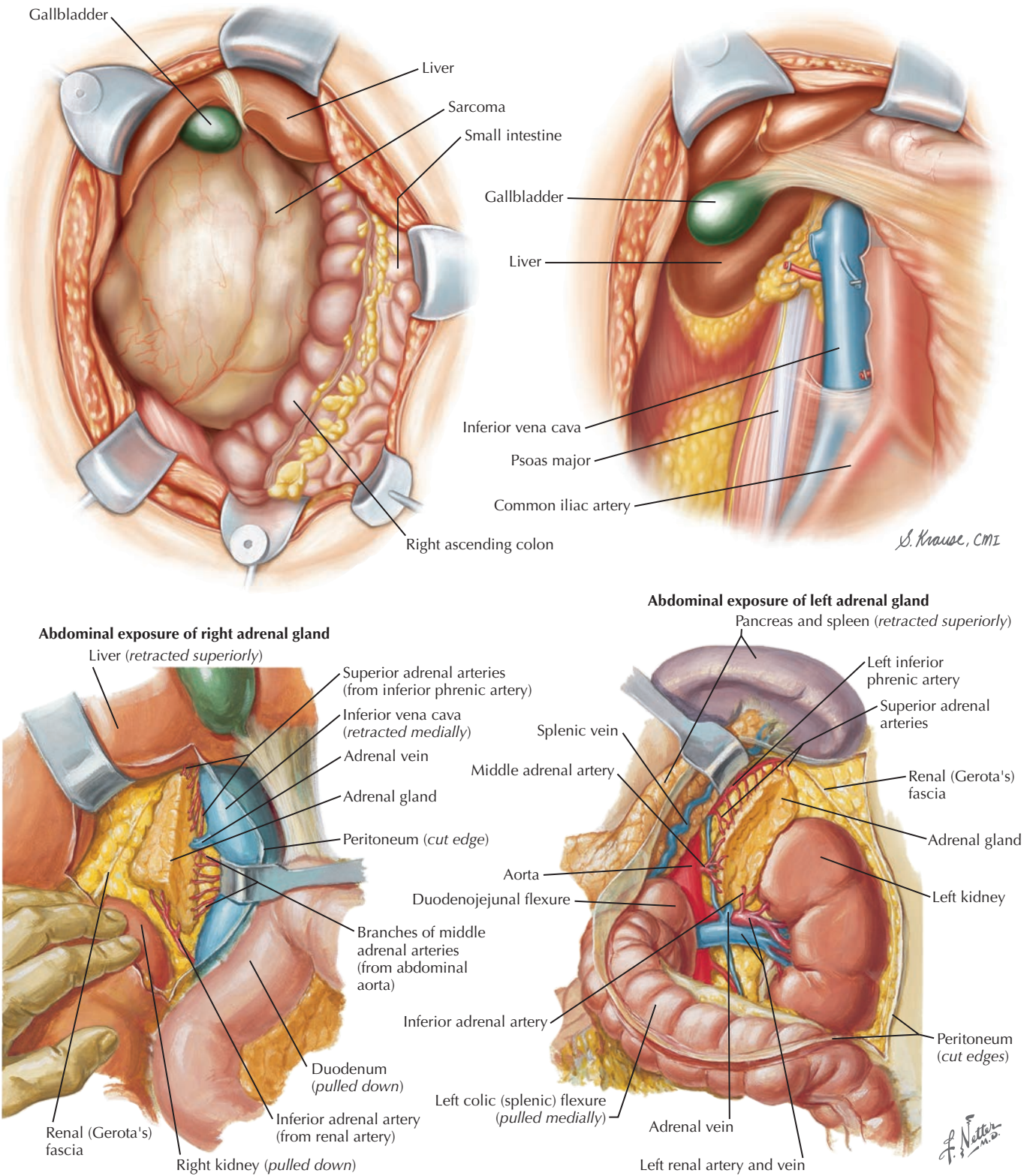


FIGURE 50-2 Abdominal exposure of retroperitoneal tumor.

SUMMARY

Tissue diagnosis is required before excision of retroperitoneal tumors because large tumors may be lymphomas or other nonsurgically treated disease. Preoperative imaging to determine extent of tumor and possible invasion into surrounding structures is useful. Kidney function is assessed preoperatively in case nephrectomy is needed. Margin-negative resection without rupture of the pseudocapsule is the goal, with use of a multidisciplinary approach (e.g., vascular surgeon, radiation oncologist).

SUGGESTED READINGS

- Anaya DA, Lev DC, Pollock RE. The role of surgical margin status in retroperitoneal sarcoma. *J Surg Oncol* 2008;98(8):607-10.
- Hueman MT, Herman JM, Ahuja N. Management of retroperitoneal sarcomas. *Surg Clin North Am* 2008;88(3):583-97, vii.
- Raut CP, Pisters PW. Retroperitoneal sarcomas: combined-modality treatment approaches. *J Surg Oncol* 2006;94(1):81-7.
- Thomas DM, O'Sullivan B, Gronchi A. Current concepts and future perspectives in retroperitoneal soft-tissue sarcoma management. *Expert Rev Anticancer Ther* 2009;9(8):1145-57.

Hysterectomy for Benign and Malignant Conditions

Kimberly Resnick

INTRODUCTION

Hysterectomy may be performed for both benign and malignant conditions of the uterus. The surgical approach to hysterectomy is determined by the pathology at hand as well as operator experience. Surgical approaches may include total abdominal hysterectomy, total laparoscopic hysterectomy, laparoscopic assisted vaginal hysterectomy, robotic hysterectomy or total vaginal hysterectomy. This chapter focuses on the basic description of the total abdominal extrafascial hysterectomy. Oophorectomy is described in Chapter 52.

SURGICAL ANATOMY

Cardinal and Uterosacral Ligaments

Excellent knowledge of both intraperitoneal and extraperitoneal anatomy is critical to perform a hysterectomy. Uterine support is provided by the cardinal and uterosacral ligaments (Fig. 51-1). The cardinal ligaments extend laterally from the level of the cervical-uterine junction and divide the pelvic cavity in potential spaces: the paravesical spaces divide the cavity anteriorly and the pararectal spaces divide it posteriorly. The uterosacral ligaments extend from the cardinal ligaments posteriorly toward the ischial spines and sacrum. Between the uterosacral ligaments lies the uppermost portion of the rectovaginal septum covered by peritoneum. This area can serve as the entry point into the retrouterine space.

Round and Broad Ligaments

The round ligaments arise from the fundus of the uterus and extend laterally along the ventral aspect of the abdominal wall toward the inguinal canal. The round ligaments comprise smooth muscle and small vessels and terminate in the fat pad of the labium majora.

The broad ligament consists of an anteroposterior layer of peritoneum draped over the uterus and extends from the round ligament to the infundibulopelvic ligaments posteriorly (Fig. 51-2). The retroperitoneal space and structures can be accessed through the broad ligament, which contains areolar fat.

Vascular Landmarks and Ureteral Injury

Uterine blood supply is derived from the uterine artery, which originates in the anterior branch of the hypogastric (internal iliac) artery (Fig. 51-3, A). Additional branches and collateral vessels include the vaginal and cervical branches of the uterine artery. The uterine artery crosses the lower third of the ureter before the uterine entry point at the cervicouterine junction. The majority of pelvic surgery–related ureteral injuries occur at this location, and detailed knowledge of ureteral anatomy and the relationship to the uterus and uterine blood supply is necessary to avoid iatrogenic injury to the ureter (Fig. 51-3, B).

Additional uterine blood supply is obtained from the ovarian blood vessels (direct branch from aorta). Venous drainage enters into the hypogastric veins, inferior vena cava (right ovarian vein), and left renal vein (left ovarian vein).

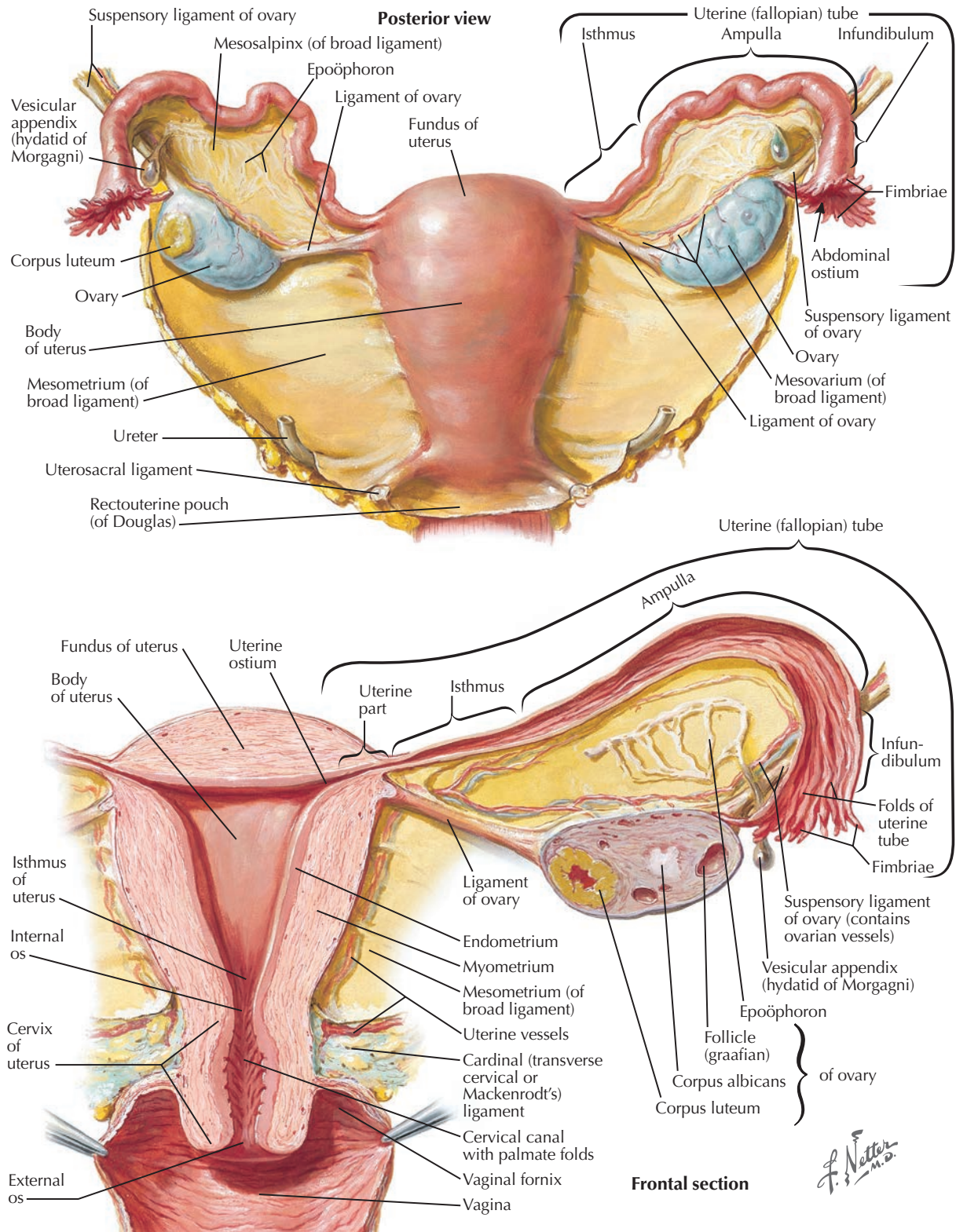


FIGURE 51-1 Uterus, ovaries, and uterine tubes.

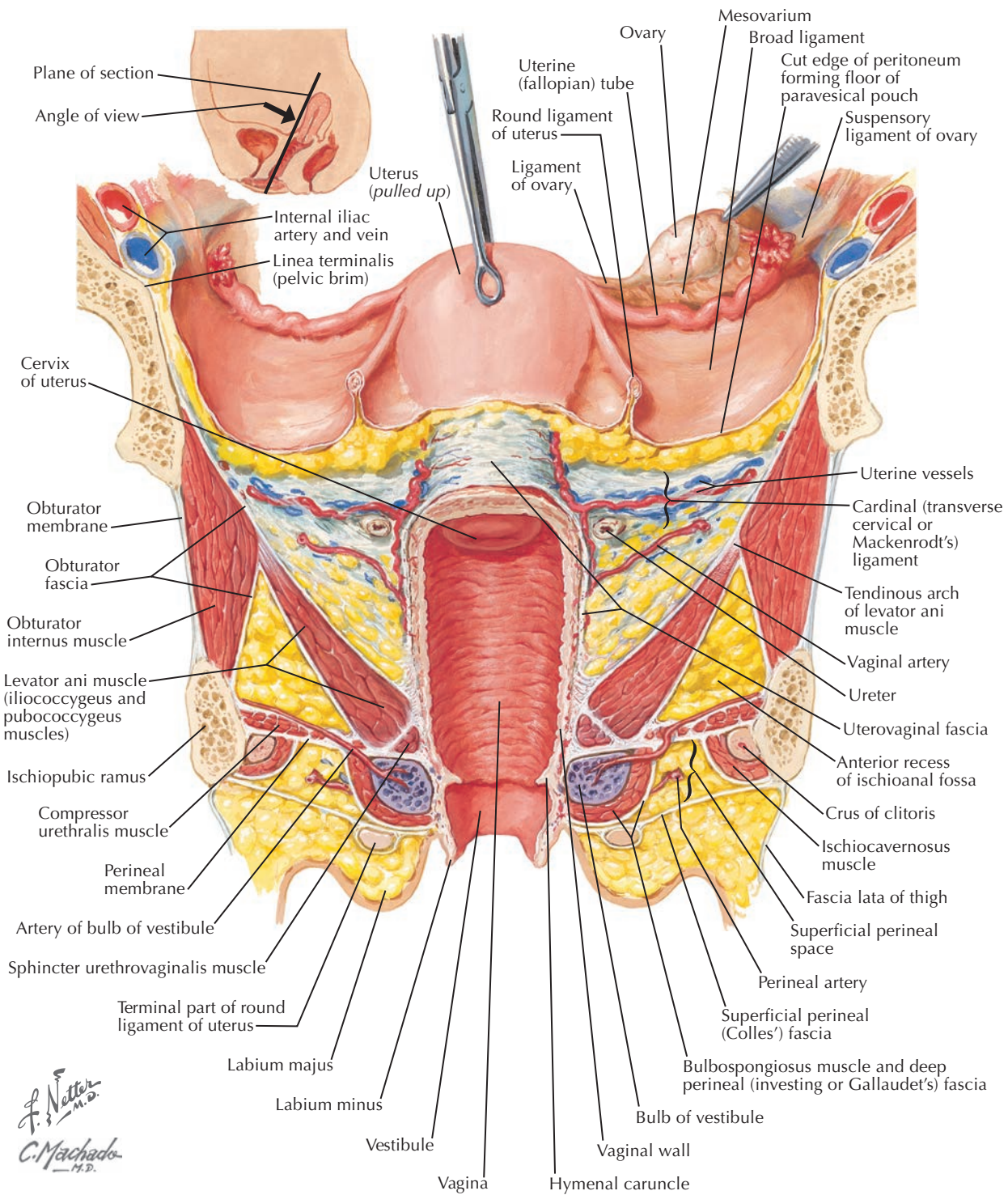
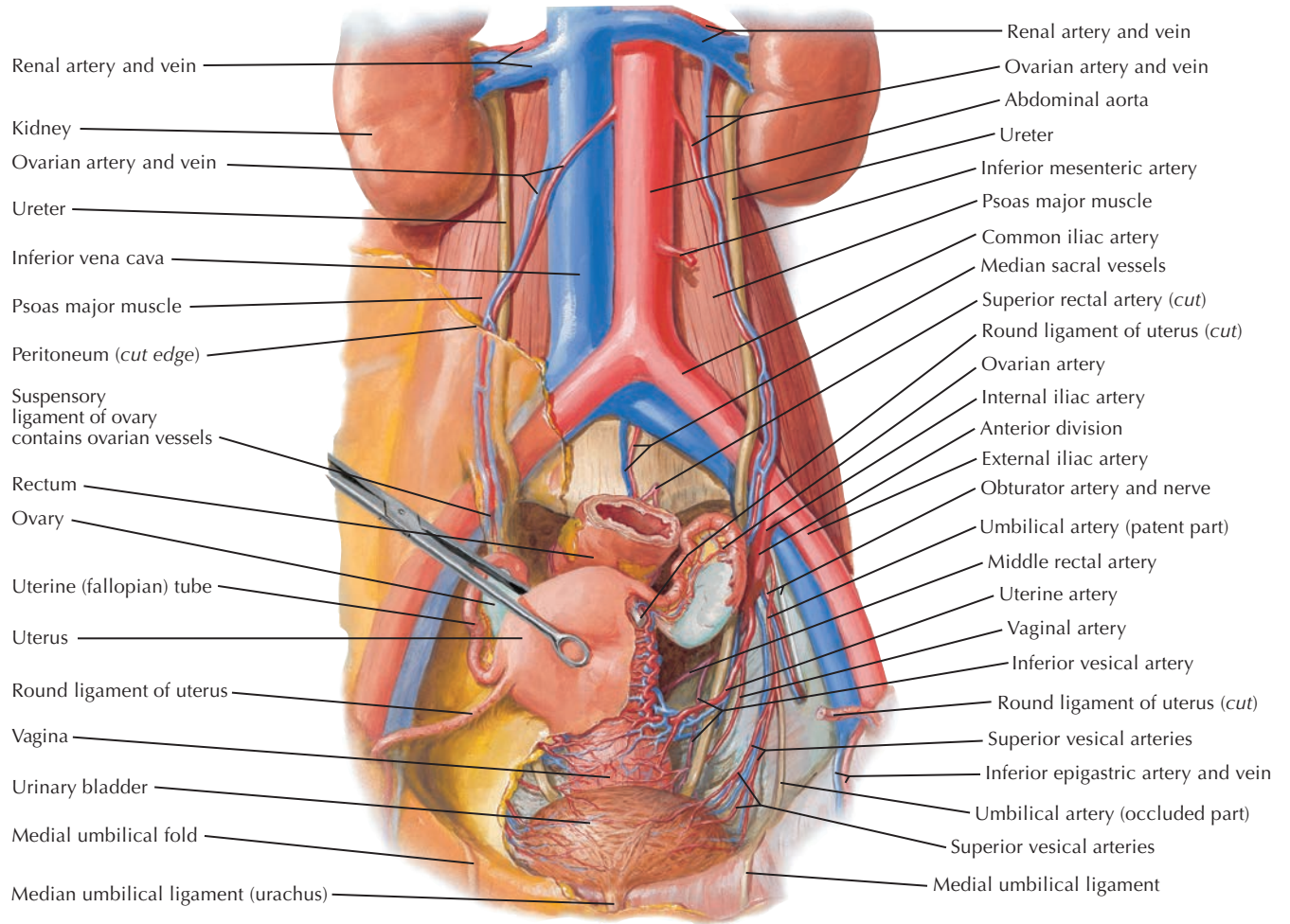
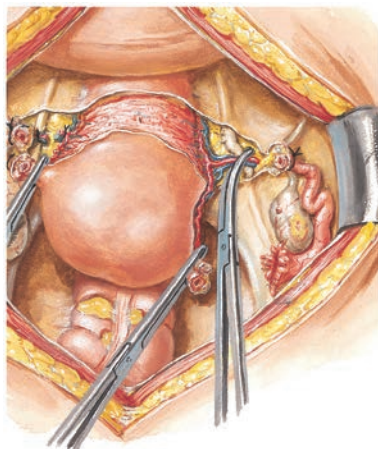


FIGURE 51-2 Ligamentous and fascial support of pelvic viscera.

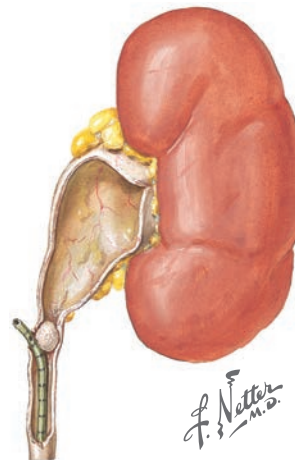
A. Arteries and veins of pelvic organs: anterior view



B. Injuries to the ureter



Ureter caught in clamp applied to overlying uterine vessels in course of hysterectomy



Perforation of weakened ureteral wall by catheter during attempt to bypass a calculus

FIGURE 51-3 Arteries and veins of pelvic organs and ureteral injury.

HYSTERECTOMY

Total abdominal hysterectomy with ovarian preservation may be indicated for a variety of both benign and malignant conditions. Dysfunctional uterine bleeding, uterine leiomyomas, and endometriosis may all be benign indications for hysterectomy. Persistent cervical dysplasia, endometrial hyperplasia or malignancy, ovarian malignancy, and microinvasive cervical cancer are neoplastic indications for hysterectomy.

Surgical Approach

The abdominal incision may be chosen on the basis of operator experience, patient body habitus, and uterine size or pathology. With a diagnosis of malignancy or large uterine size, the author recommends a traditional vertical midline incision. Once this incision is made and the peritoneal cavity entered, careful abdominal and pelvic exploration is undertaken. Pelvic washings are taken if necessary as part of a surgical staging procedure. The patient's intestines are packed into the upper abdomen, and a self-retaining retractor (e.g., Balfour, Bookwalter) is used.

Kelley clamps are placed on the uterine cornua bilaterally, and gentle upward traction is used. The round ligaments are identified bilaterally and suture-ligated with 0 Vicryl (Fig. 51-4, A). These sutures are left long and tagged. The round ligaments are transected, and the retroperitoneal space is entered.

Abdominal Dissection

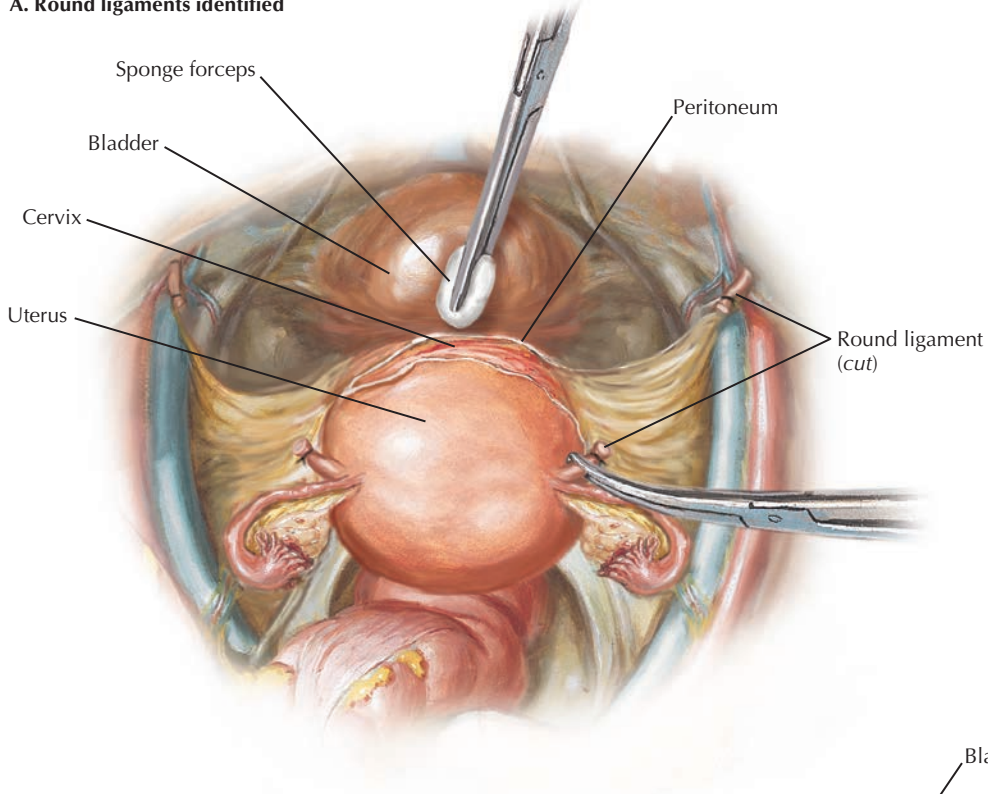
The vesicouterine peritoneum is grasped and cut just below the reflection onto the lower uterus. In this way the bladder is moved inferiorly away from the patient's cervix. Gentle blunt dissection, dissection with a sponge forceps, or sharp dissection may be used. If the patient has a history of previous pelvic surgery, including cesarean section, the author would recommend sharp dissection. This maneuver may be facilitated by grasping the lower uterine segment and cervix between the thumb and forefinger and pushing the uterine cervix anteriorly.

The posterior broad ligament is dissected parallel to the course of the infundibulopelvic ligaments bilaterally (Fig. 51-4, B). If significant dissection into the retroperitoneum is planned, this dissection may be continued along the white line of Toldt, with mobilization of the cecum and the sigmoid colon. Once this dissection is performed, the retroperitoneal space is now clearly visible through the layer of areolar fat. This tissue may be dissected with gentle blunt dissection, monopolar cautery, or gentle dissection with a suction tip.

The ureter will be identified coursing along the medial leaf of the broad ligament, below the infundibulopelvic ligaments. The pararectal space may be developed by gentle dissection between the hypogastric artery and ureter (Fig. 51-5). The author recommends awaiting ureteral peristalsis so as not to confuse the ureter with anterior division of the hypogastric artery.

Once these structures are clearly identified and the ureters identified and out of harm's way, bilateral salpingo-oophorectomy may be performed (see Chapter 52).

A. Round ligaments identified



B. Infundibulopelvic ligaments

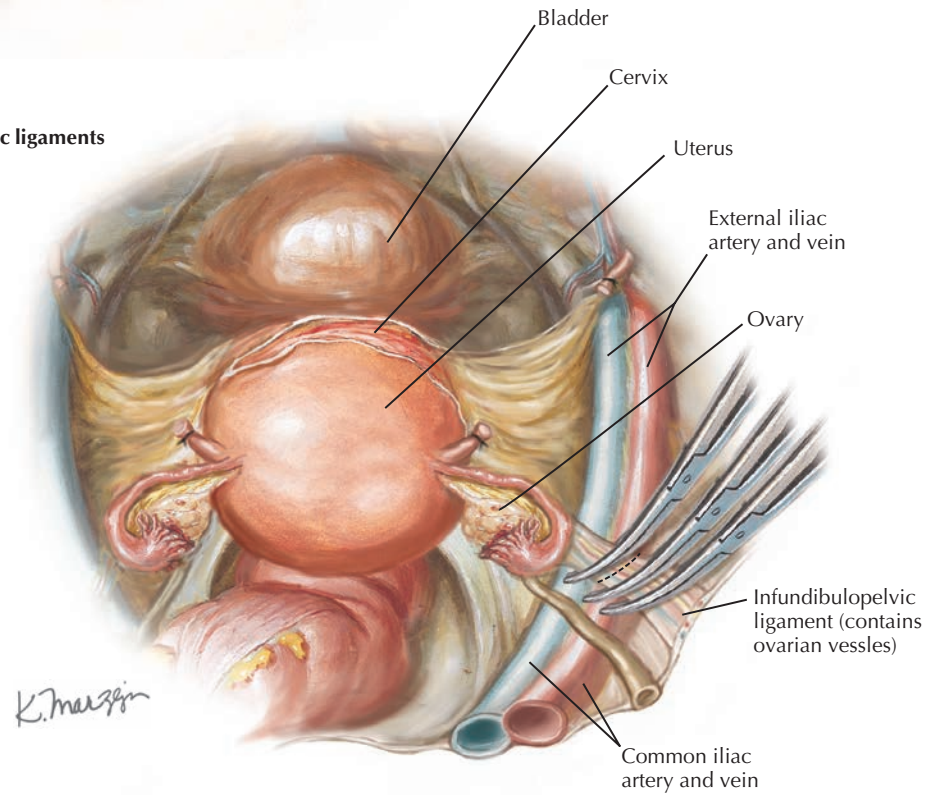


FIGURE 51-4 Abdominal hysterectomy: isolation of round and infundibulopelvic ligaments.

Ovarian Preservation

In the hysterectomy with ovarian preservation, a window is created beneath the infundibulo-pelvic ligament and parallel to it. This window may be extended to the level of the uterine artery. The utero-ovarian pedicles may be double-clamped with either slightly curved Heaney or Zeppelin clamps and the pedicle cut between the two clamps. The ovarian pedicle is double-ligated with 0 Vicryl suture. The clamps may remain on the uterine side to be used for gentle upward traction, and the previously placed Kelley clamps may be removed. The remaining tubes and ovaries may be gently packed into the upper abdomen.

Clamping and Mobilization

The uterine vessels are skeletonized bilaterally. The vessels are subsequently clamped with a slightly curved heavy clamp (e.g., Heaney, Zeppelin). A secondary clamp is placed above this clamp to prevent back-bleeding from the uterus. The vessels are cut with scissors and suture-ligated with a single 0 Vicryl suture. Care should be taken to pass the needle directly through the tip of the clamp to avoid passing it through the vascular portion of this pedicle. The heavy clamp is then removed.

The remaining cardinal ligaments and uterosacral ligaments are subsequently clamped with straight heavy clamps, cut with a scalpel, and suture-ligated with 0 Vicryl sutures. Care must be taken to remain close to the cervicouterine junction to avoid lateral migration and injury to the ureter.

Specimen Removal and Closure

The pubocervical fascia is incised and careful blunt traction used to ensure that the bladder is well below the cervix. Heavy right-angle clamps are then placed bilaterally below the patient's cervix, thus clamping the top portion of the vagina.

Heavy scissors (Jorgensen) are used to amputate the specimen from the vagina. The specimen is inspected to make certain the cervix is intact and no portion remains. The vaginal angles are suture-ligated below the heavy clamps, which are removed. The angle sutures are left long and tagged. The remaining vaginal cuff is closed with interrupted figure-of-eight sutures with 0 Vicryl.

By placing gentle traction on the vaginal-angle sutures, the surgeon should inspect the cuff for hemostasis. The pelvis should be copiously irrigated and hemostasis achieved. The sutures remaining on the vaginal angles and round ligaments may then be cut. The fascia may be closed in standard fashion.

Female: superior view (peritoneum and loose areolar tissue removed)

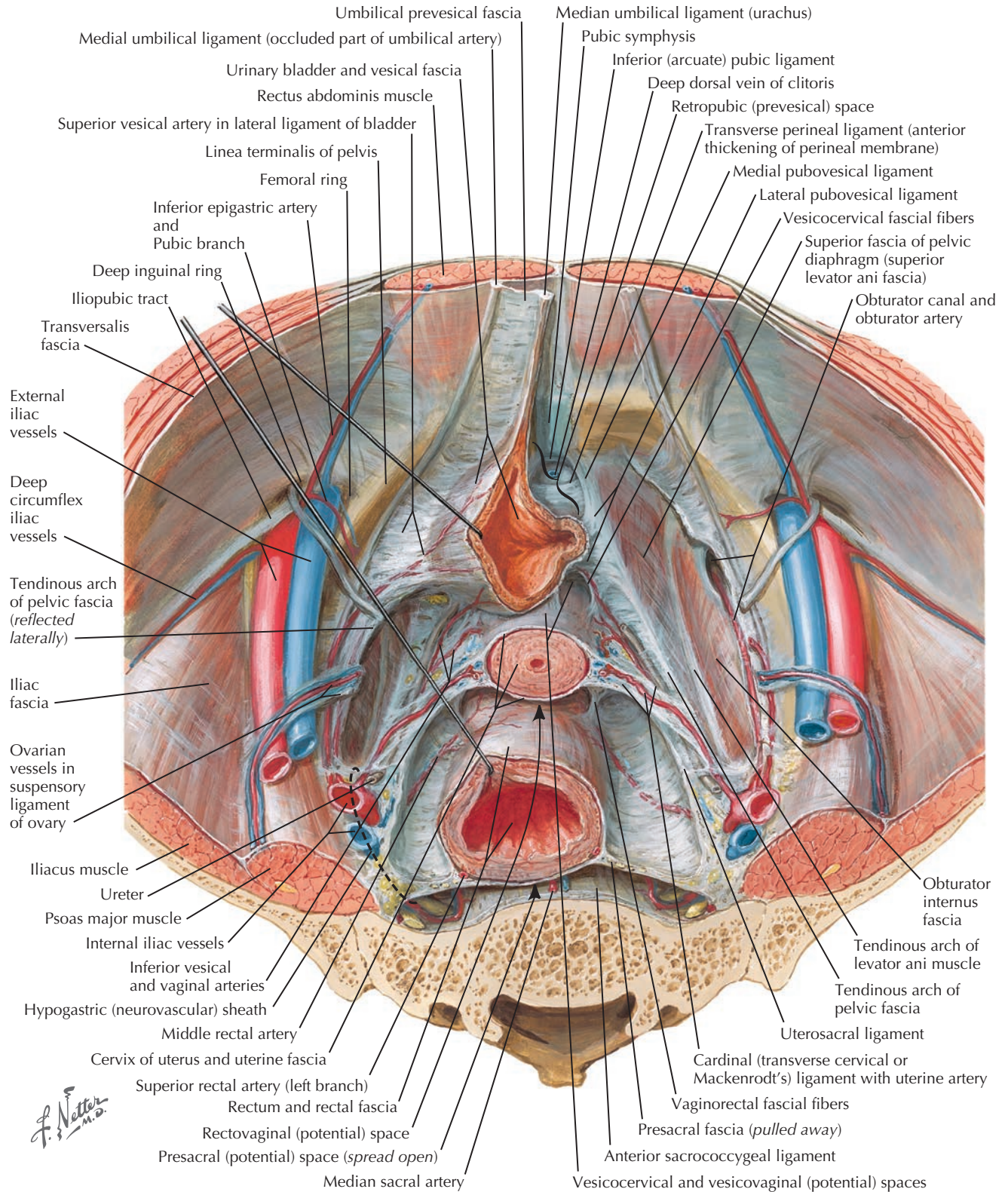


FIGURE 51-5 Pelvic cross section with peritoneum removed.

SUGGESTED READINGS

- Baggish MS, Karram MM. Atlas of pelvic anatomy and gynecologic surgery, 3rd ed. Philadelphia: Saunders; 2010.
- Rock JA, Jones HW. TeLinde's operative gynecology, 9th ed. Philadelphia; Lippincott, Williams & Wilkins, 2003.
- Wheeless CR, Parker J. Atlas of pelvic surgery, 3rd ed. Philadelphia: Lippincott, Williams & Wilkins; 1997.

Oophorectomy for Benign and Malignant Conditions

Robert L. DeBernardo

INTRODUCTION

The ovary is a complex organ from both a histologic and a functional standpoint. As a result, numerous tumors, both benign and malignant, can arise in the adnexa. The surgical approach is often determined by the pathology as well as the desire to preserve gonadal function and fertility.

Although the vast majority of tumors arising in the ovary will be benign, especially in younger women, proper surgical management of ovarian or tubal malignancy is much more complex. Epithelial ovarian and tubal malignancies tend to metastasize early and spread along peritoneal surfaces throughout the abdomen. These surgeries are designed to render the patient with minimal residual disease and often require pelvic peritonectomy with en bloc rectosigmoid resection to clear the pelvis. Proper surgery often includes equally radical upper abdominal resection. Multiple studies have shown that complete cytoreduction of metastatic disease impacts both overall survival rates and progression-free survival rates in women with epithelial ovarian malignancy. Overall survival rates of 66 to 120 months is achievable even in women with advanced disease.

PREOPERATIVE IMAGING

Preoperative imaging of an adnexal mass helps not only to characterize the tumor, but also to assess for ascites, hydronephrosis, lymphadenopathy, and omental implants that may impact the preoperative counseling and surgical approach. Ultrasonography is the most frequently used modality to assess a pelvic mass. It is readily accessible, noninvasive, and provides excellent characteristics of the lesion itself. The ultrasonographer should comment on lesion size, cystic/solid components, complexity, and Doppler flow along with evidence of hydronephrosis and ascites. Magnetic resonance imaging (MRI) can provide significantly more information about an ovarian tumor, but in reality MRI is rarely helpful in triaging an adnexal mass. Most lesions believed to be complex should be removed in all age groups. Computed tomography (CT) scans are essential to evaluate the retroperitoneum and upper abdomen in women with an ovarian mass that may be malignant.

SURGICAL APPROACH

The most prudent approach to a patient with an adnexal mass is made on the basis of the patient's age, desire for future fertility/hormonal preservation, and imaging characteristics. Almost all pelvic masses in children, premenopausal girls, and postmenopausal women should be evaluated. Triage is made on the basis of imaging characteristics, symptoms, and concern for malignancy. Low-risk lesions, especially in premenopausal girls, can often be followed for spontaneous resolution, especially if these are primarily cystic in nature. Solid masses or complex masses in any age group are more likely to be malignant and usually require surgical evaluation. Tumor markers (e.g., CA125) should be obtained preoperatively, although these may be informative in only 90% of cases. The surgical approach, whether laparoscopic, robotic, or conventional laparotomy, depends on the nature of the lesion and the likelihood of identifying a malignancy.

ANATOMY AND DISSECTION OF THE ADNEXA

The adnexa refers to both the ovary and fallopian tube. An intimate understanding of the vascular supply to the adnexa and the relationship to the underlying ureter and uterus is required before commencing surgery (Fig. 52-1). The general principles are similar regardless of surgical approach (open, laparoscopic, or robotic).

Anterior view

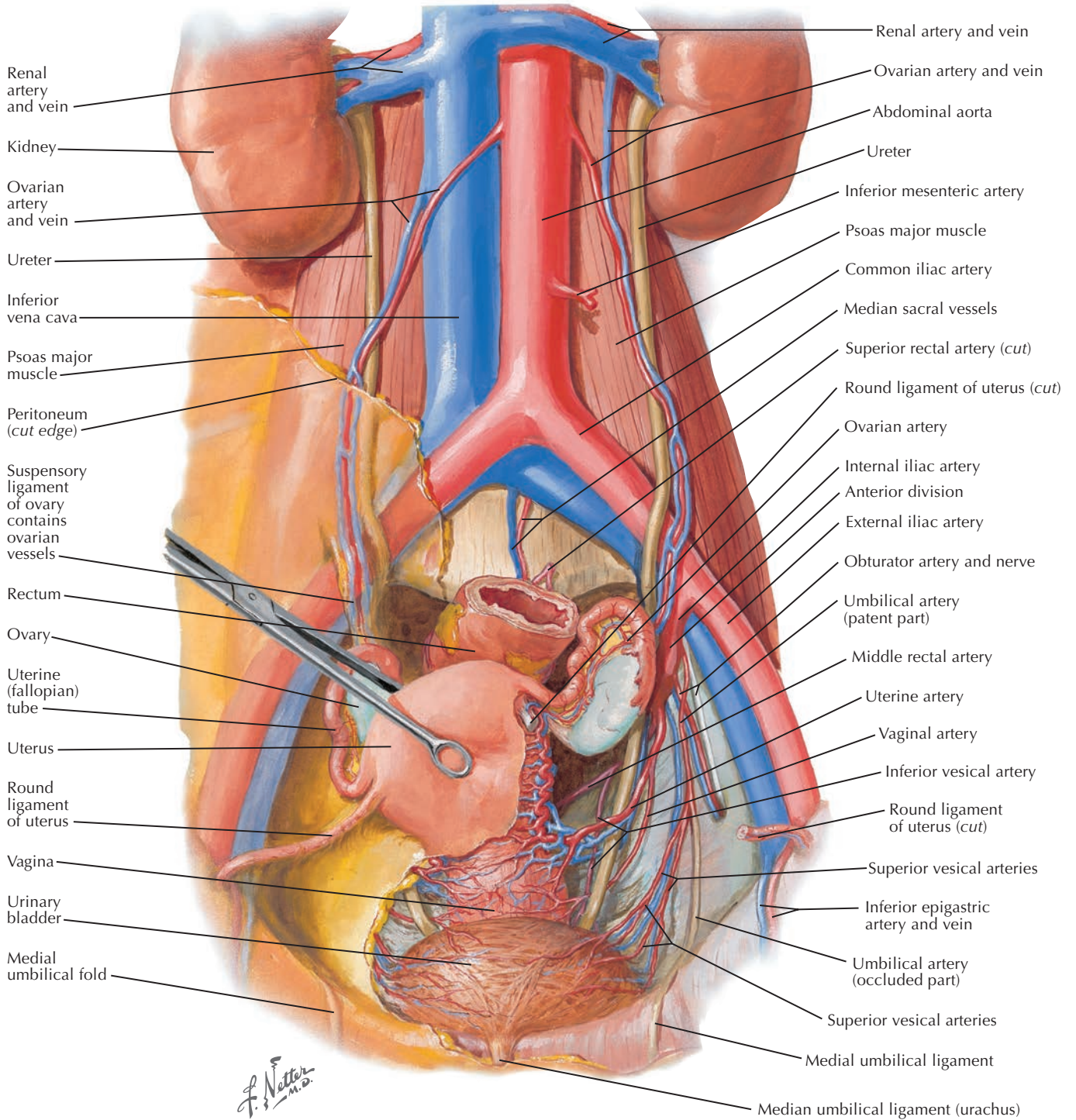


FIGURE 52-1 Arteries and veins of female pelvic organs.

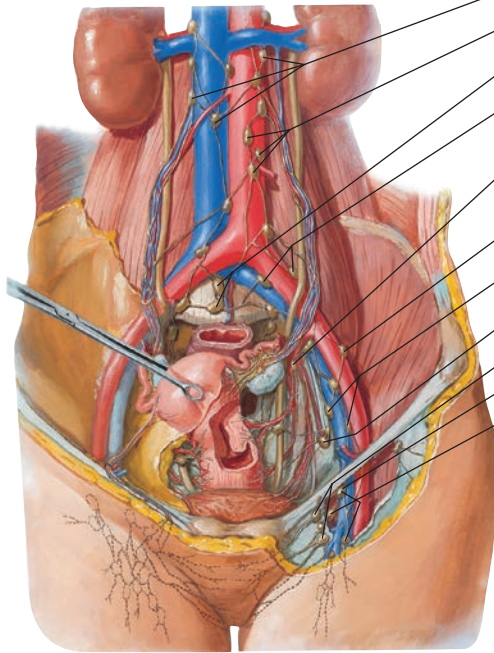
Gonadal Vessels and Infundibulopelvic Ligament

The best approach to removing a pelvic mass is first to open the retroperitoneum and identify the gonadal vessels and ureter. The gonadal blood supply, or infundibulopelvic ligament (IP), originates from the aorta and runs parallel to the ureter, crossing into the pelvis over the bifurcation of the common iliac vessels (Fig. 52-2, A).

These vessels run through the adnexa, providing blood supply to the ovary and fallopian tube, then anastomose to the uterus and become the utero-ovarian vessels. The peritoneum is incised lateral to the IP along the psoas muscle and external iliac artery and can be extended to the white line of Toldt. Gentle dissection with a large Kelly clamp along the sacrum will develop this space, with the gonadal vessels superiorly, the ureter on the medial leaf of the peritoneum, and the iliac vessels laterally.

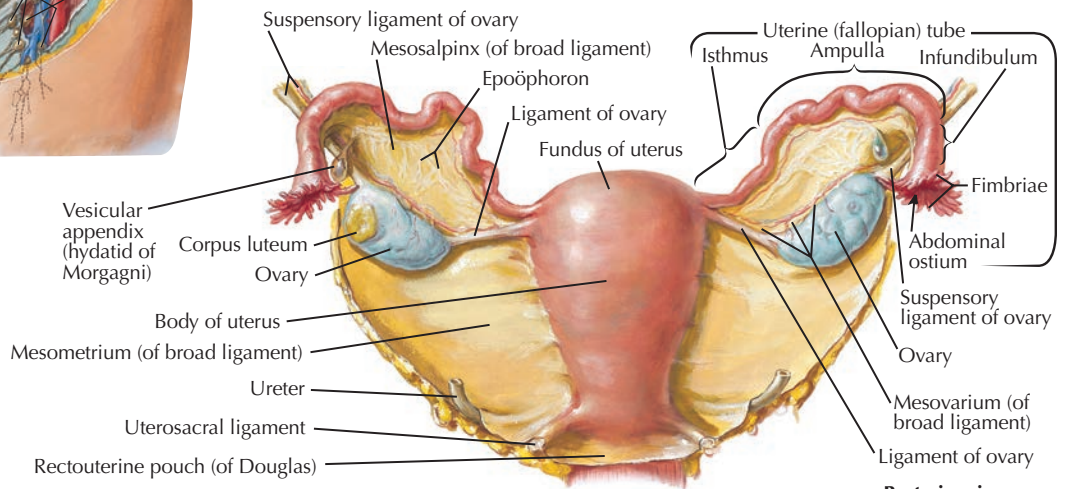
The IP can then be isolated, clamped, and cut, with the ureter under direct visualization. The adnexa can be elevated out of the pelvis and its peritoneal attachments mobilized until reaching its attachment to the uterus, the utero-ovarian pedicle (Fig. 52-2, B).

A. Pelvic cavity: lymphatics (female pelvis)

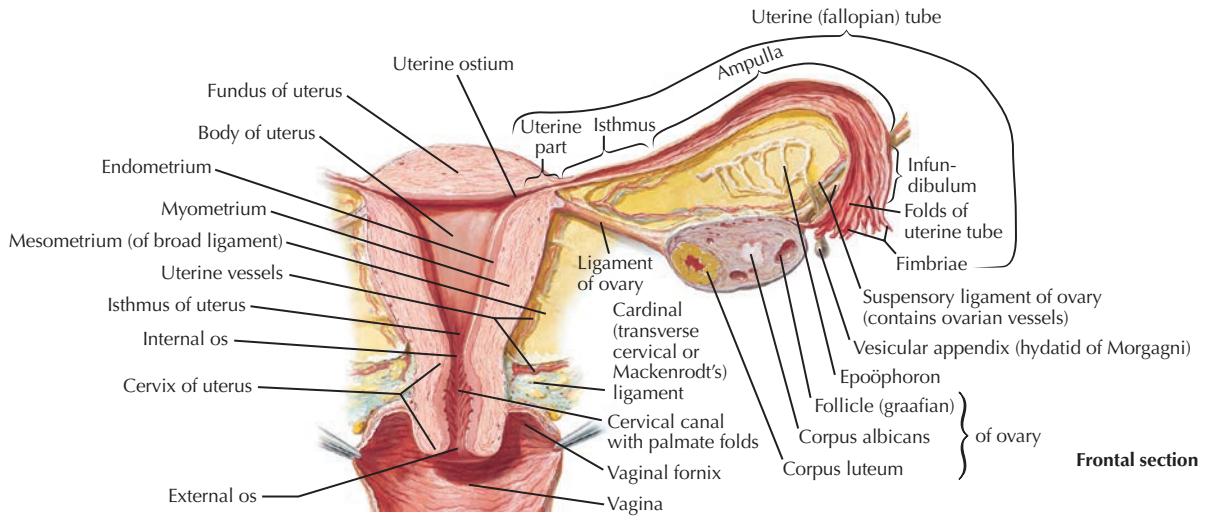


- Lateral aortic (lumbar) nodes
- Preaortic lymph nodes
- Promontorial (middle sacral) nodes
- Common iliac nodes
- Internal iliac node
- Lateral (superior) external iliac node
- Medial (inferior) external iliac nodes
- Obturator node
- Superficial inguinal nodes
- Highest deep inguinal node (of Cloquet)
- Deep inguinal nodes

B. Adult uterus, ovaries, and uterine tubes



Posterior view



Frontal section

FIGURE 52-2 Pelvic cavity lymphatics and adult uterus, ovaries, and tubes.

Utero-ovarian Vessels

The utero-ovarian vessels are supplied by both the gonadal vessels cephalad and the uterine vessels caudad. This pedicle needs to be secured when removing the ovary, unless the uterus is being removed concurrently. Unlike the gonadal vessels, the utero-ovarian pedicle is poorly defined in many patients, and securing it can be challenging; a large clamp (e.g., Heaney) with a suture ligature works best. A vascular stapling device or Ligasure is frequently used in laparoscopic cases.

It is important to recognize that the ureter is deep and lateral to the utero-ovarian pedicle, except when the tumor is encasing the pelvic side wall, as can be seen in endometriosis or, more often, ovarian malignancy.

LARGE MASSES AND MODIFIED APPROACHES

Unfortunately, some ovarian tumors can routinely grow to be greater than 20 or 30 cm before they are identified. In these cases, it may not be possible to isolate the blood supply and identify the ureter before removing the mass itself (Fig. 52-3, A).

It is preferable to remove an ovarian mass intact, without rupture, to avoid seeding the peritoneum should malignancy exist. In cases of malignancy, the surgical approach should be modified in one of two ways. If the utero-ovarian pedicle can be identified, the safest approach is to sacrifice this pedicle first and proceed with the operation described earlier, but in reverse. This approach allows for the mobilization of the adnexa cephalad by incising the peritoneum along the pelvic side wall, thus allowing for the ureter to drop away from the gonadal blood supply. Once the dissection is carried to the pelvic brim, the IP generally is easily isolated and secured.

In some cases, neither the IP nor the utero-ovarian pedicle can be identified, and the mass itself can often be delivered through the incision and the adnexa itself clamped. In the author's experience, there is little chance of inadvertently injuring the ureter because it runs deep to the IP pedicle (Fig. 52-3, B).

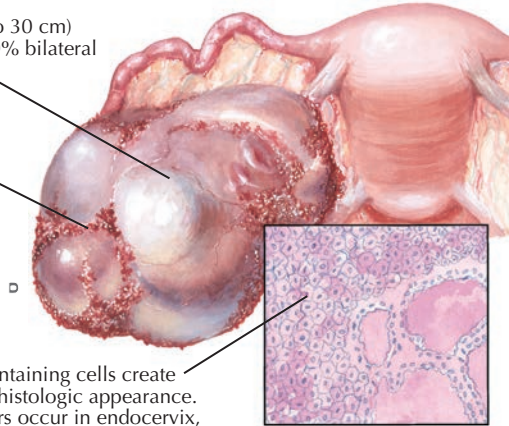
Nonetheless, it is prudent to develop the retroperitoneum once the mass has been removed, and identify the ureter to ensure it has been uninjured.

A. Clear cell carcinoma of ovary

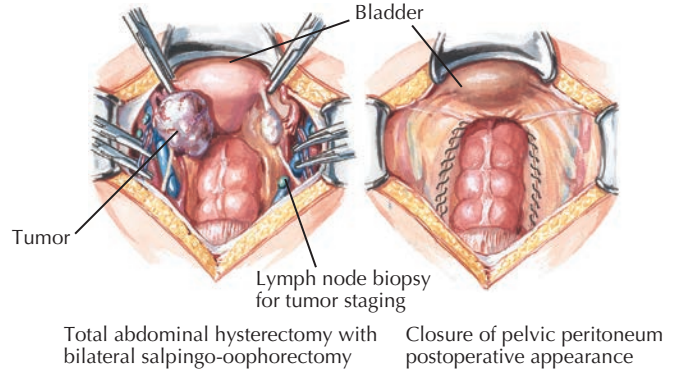
Pelvic mass (up to 30 cm)
Partially cystic 40% bilateral
predominantly

Papillary
projections

Glycogen-containing cells create
"hobnailed" histologic appearance.
Similar tumors occur in endocervix,
vagina, and endometrium.



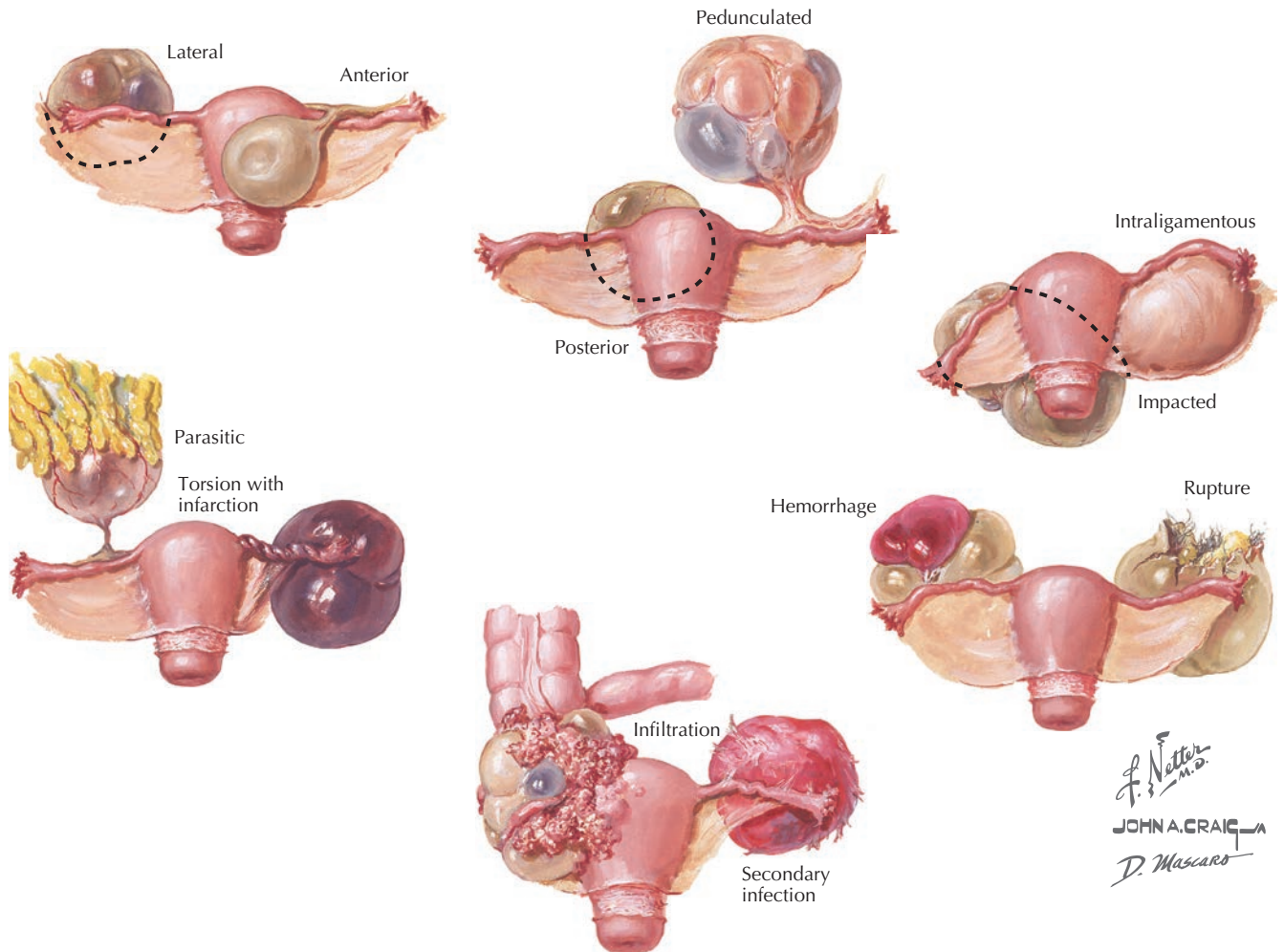
Surgical Management



Total abdominal hysterectomy with
bilateral salpingo-oophorectomy

Closure of pelvic peritoneum
postoperative appearance

B. Diagnosis of ovarian neoplasms



F. Netter M.D.
JOHN A. CRAIG
D. Mascaro

FIGURE 52-3 Ovarian carcinomas: diagnosis and management.

RADICAL OOPHORECTOMY

In rare cases in which the previous techniques fail, or more often in the setting of an advanced pelvic malignancy, a more radical surgical approach becomes necessary. This is often the case when there is extensive pelvic pathology, such as stage IV endometriosis or advanced ovarian malignancy. Not only are the normal anatomic landmarks obscured, but the pelvic peritoneum is extensively involved in the disease process.

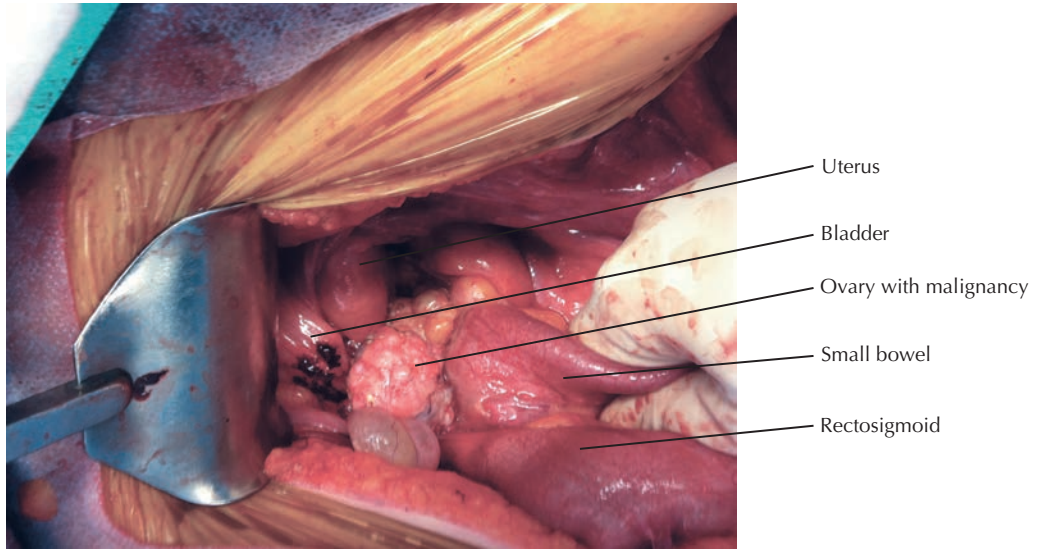
The resection of the adnexa in these patients starts in the upper abdomen at or near the origin of the gonadal blood supply. Generally, the white line of Toldt is developed bilaterally and the abdominal ureter and gonadal blood supply identified. It may be helpful to isolate the ureters at this point on vessel loops to keep them under continuous surveillance. Gentle tension facilitates the dissection. The gonadal vessels can be sacrificed at their origin or anywhere along their abdominal path. In the setting of an ovarian malignancy, the peritoneum overlying the gutters is incorporated along with this pedicle and taken en bloc into the pelvis, incorporating any extrapelvic disease (Fig. 52-4, A).

The dissection is then carried into the pelvis proper. Staying in the retroperitoneum, any involved peritoneal surfaces are included circumferentially to encompass the tumor. Anteriorly, the lateral pelvic side wall peritoneum is mobilized off the external iliac vessels and psoas muscle with gentle traction and monopolar cautery. The round ligaments are sacrificed at this point, and the bladder peritoneum can be resected when necessary, often without need for partial cystectomy.

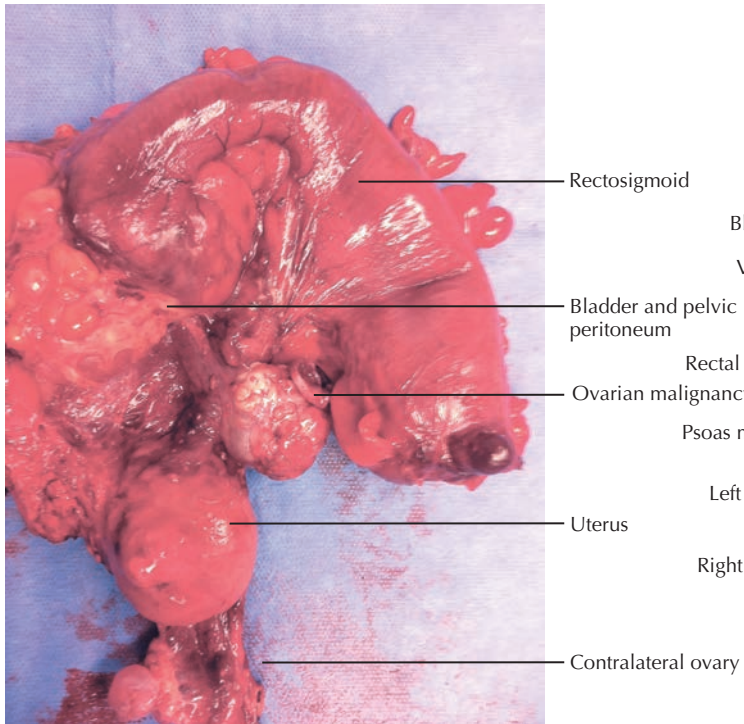
This peritoneum is contiguous with the peritoneum overlying the uterus. Advanced ovarian malignancy disease almost always involves the posterior pelvic peritoneum and sigmoid mesentery, requiring rectosigmoid resection to eradicate the disease completely. Once the sigmoid is transected, the retroperitoneal dissection is carried laterally to encompass the anterior dissection and posteriorly along the sacrum. Similar to a colorectal malignancy, the dissection continues behind the rectum in the plane between the peritoneum and mesorectum (Fig. 52-4, B).

Unlike a situation involving colorectal cancer, the objective here is not to obtain gross margins, but to debulk gross tumor to microscopic, residual disease. In the vast majority of cases, the tumor respects the peritoneum, and the dissection down to the level of the levator muscles is unnecessary. Once beyond the rectal reflection, the rectum can be skeletonized.

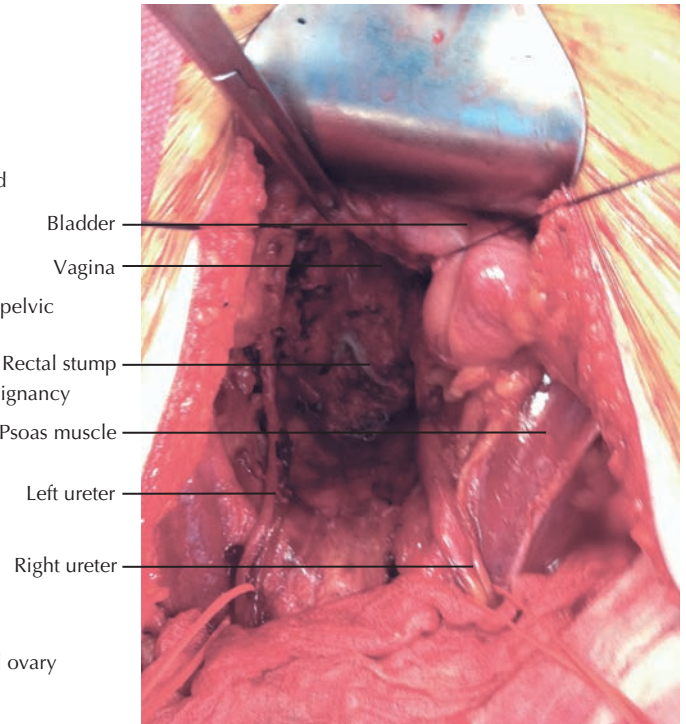
At this point, the adnexal structures are completely incorporated in the surgical specimen. The procedure is completed by isolating the uterine arteries, either at their origins or just medial to where they cross the ureters. Dissection is carried down along the cervix until the cervicovaginal refection is identified. A colpotomy is performed and the rectovaginal septum developed. The rectum can then be transected with a stapling device and the specimen removed (Fig. 52-4, C).



A. Ovarian malignancy invading rectosigmoid, uterus, and pelvic peritoneum



B. Radical oophorectomy specimen: ovaries, tubes, uterus with en bloc rectosigmoid resection, and pelvic peritoneum



C. Pelvis after radical resection

FIGURE 52-4 Ovarian malignancy and radical oophorectomy.

SUGGESTED READINGS

- Alcázar JL, Royo P, Jurado M, et al. Triage for surgical management of ovarian tumors in asymptomatic women: assessment of an ultrasound-based scoring system. *Ultrasound Obstet Gynecol* 2008;32(2):220-5.
- Chang SJ, Bristow RE. Evolution of surgical treatment paradigms for advanced-stage ovarian cancer: redefining “optimal” residual disease. *Gynecol Oncol* 2012;125(2):483-92.
- Esselen KM, Rodriguez N, Growdon W, et al. Patterns of recurrence in advanced epithelial ovarian, fallopian tube and peritoneal cancers treated with intraperitoneal chemotherapy. *Gynecol Oncol* 2012;127(1):51-4.
- Giuntoli RL 2nd, Vang RS, Bristow RE. Evaluation and management of adnexal masses during pregnancy. *Clin Obstet Gynecol* 2006;49(3):492-505.
- Moore RG, Miller MC, Disilvestro P, et al. Evaluation of the diagnostic accuracy of the risk of ovarian malignancy algorithm in women with a pelvic mass. *Obstet Gynecol* 2011;118 (2 Pt 1):280-8.

Laparoscopic Transperitoneal Radical Nephrectomy

Lee E. Ponsky

INTRODUCTION

Increased use of three-dimensional (3D) imaging has led to better detection of renal tumors in recent years. Since the introduction of laparoscopic nephrectomy by Clayman and colleagues in 1990, this minimally invasive approach to kidney removal has become the “gold standard.” Laparoscopic radical nephrectomy has demonstrated oncologic outcomes comparable to those seen with open radical nephrectomy, but with less morbidity, shorter hospital stay, less pain, quicker recovery, and improved cosmesis.

PREOPERATIVE IMAGING

Typically, a contrast-enhanced computed tomography (CT) scan or a magnetic resonance (MR) image is obtained before surgery. Although not necessarily required, CT and MRI offer precise mapping of the kidney, its vasculature, and relation to adjacent organs. Also, imaging of the renal vein and vena cava helps ensure no evidence of tumor thrombus and provides preoperative clinical staging. It is also prudent to visualize the contralateral kidney to confirm adequate function. Cross-sectional images are usually sufficient, but coronal images can be extremely helpful as well (Fig. 53-1, A).

SURGICAL APPROACH

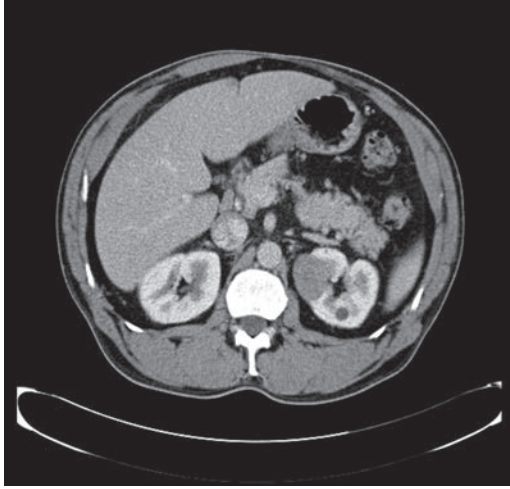
The kidney can be removed by using either a transperitoneal or a retroperitoneal approach. Both techniques have been demonstrated to be safe and effective. The transperitoneal approach is more common, but it is helpful for surgeons to be able to perform the retroperitoneal approach, particularly for patients with multiple previous intraabdominal surgeries or a hostile abdomen. The retroperitoneal approach also offers the ability to control the renal hilum almost immediately. However, with limited recognizable landmarks for orientation using the retroperitoneal approach, the majority of laparoscopic radical nephrectomies are performed transperitoneally.

PATIENT POSITIONING AND TROCAR PLACEMENT

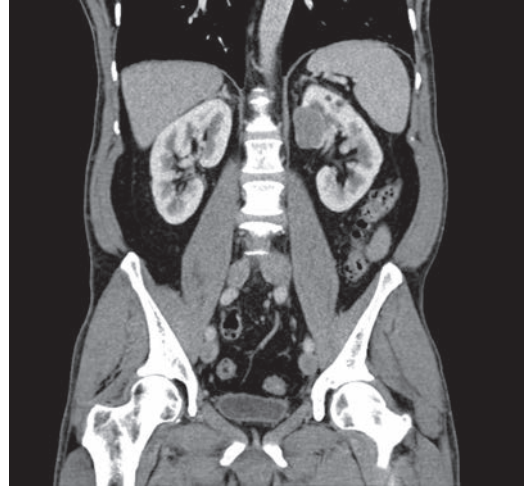For a left radical nephrectomy, the patient is placed in the right lateral decubitus position with the left flank up (Fig. 53-1, B). The patient is centered over the break in the bed. The lower leg is bent and the top leg straight, and the dependent hip, knee, and ankle padded appropriately. Pillows can be placed between the legs. An axillary roll should be placed under the axilla, to protect from nerve damage. The patient's lower arm is placed straight out on an arm board, and the upper arm should be secured to an upper arm board. The upper arm must be safely positioned away from the working field to ensure full access to laparoscopic instrumentation.

It is important to secure the patient to the table with heavy tape wrapped around the patient (preferably directly to skin) and table several times, to prevent the patient from moving or sliding during surgery. For the transperitoneal approach, the patient can be rotated posteriorly just before being secured to the table. It is also helpful to plan for the extraction site, marking it before positioning and including it in the prepped and draped area.

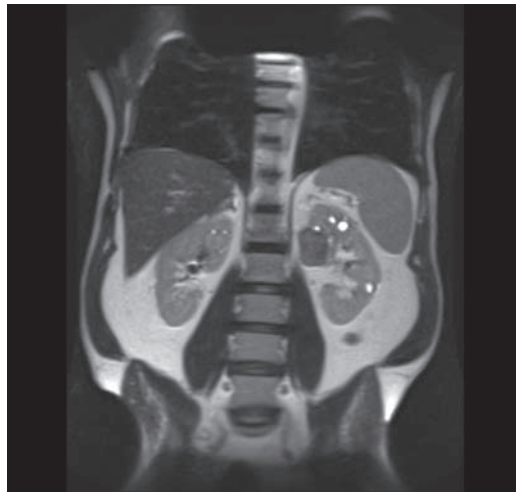
Port sites have been described in several ways, depending on surgeon preference. The author's group typically uses the Verres needle for access, although the Hasson cutdown technique is also appropriate. Correct placement of the right-handed port is typically marked half the distance between the anterior superior iliac spine and the umbilicus, then moved superiorly up to the level of the umbilicus. This would typically be a 10-mm port. The middle camera port is typically placed just lateral to the rectus abdominis muscle, approximately in line with the tip of the 12th rib. The left-handed, typically 5-mm port is approximately at the junction of the lateral aspect of the rectus muscle and the subcostal border.

A. Preoperative imaging of renal mass

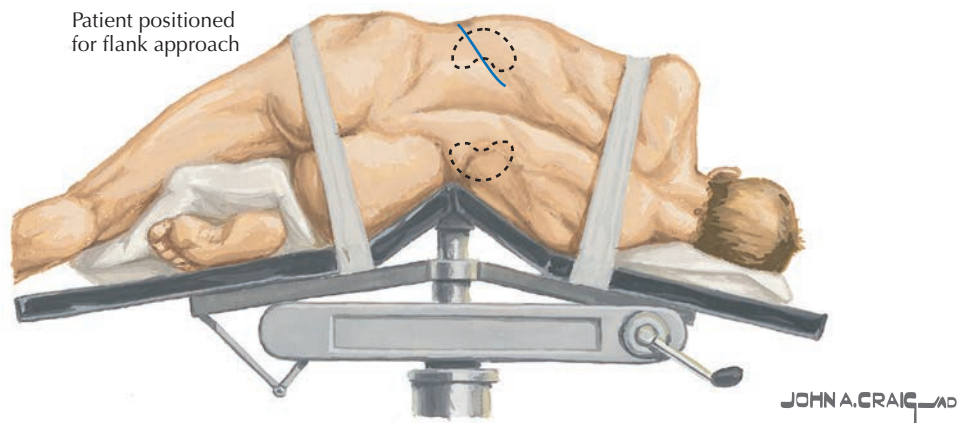
Cross-sectional CT of left renal mass



Coronal CT of left renal mass



Coronal MRI of left renal mass

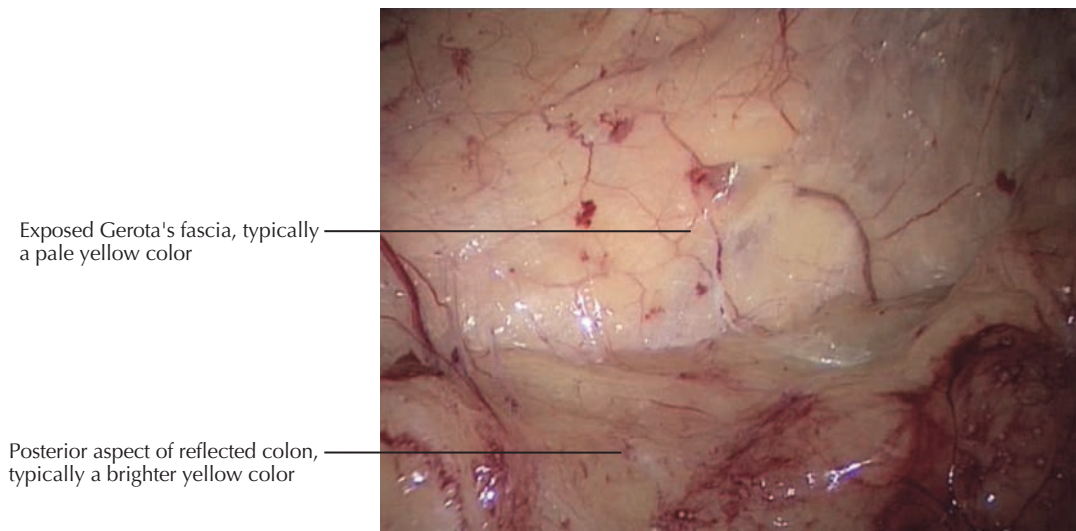
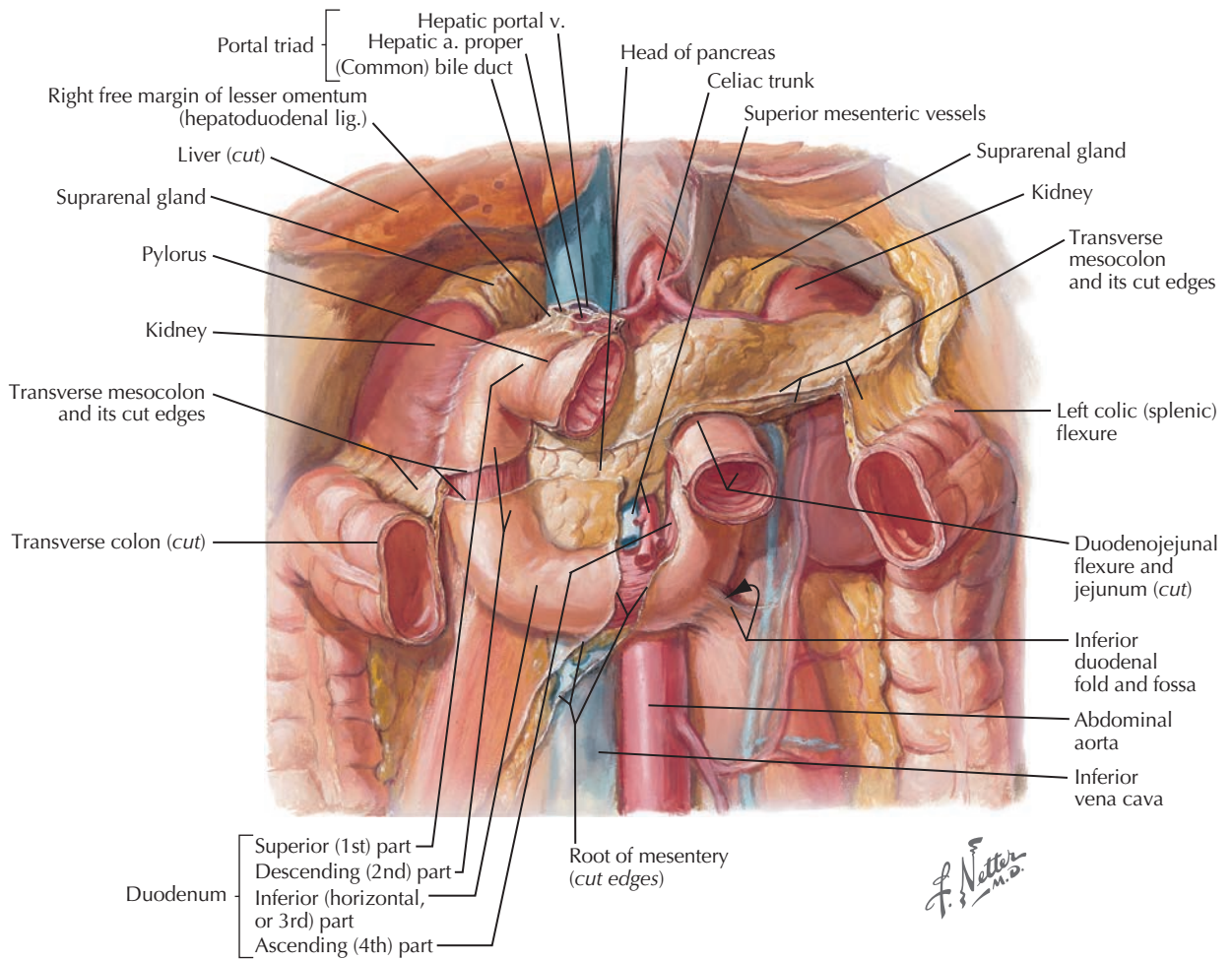
B. Surgical approach to the kidney**FIGURE 53-1** Preoperative imaging of renal mass and surgical approach.

MOBILIZATION OF LEFT COLON

Once the abdomen is entered, a brief survey completed, and any adhesions dissected free, the first step is to reflect the left colon. Although the standard description of mobilizing the colon describes incising along the white line of Toldt, it is not necessary to incise that laterally; in fact, it could be more challenging to incise that laterally because the peritoneum needs to be dissected off Gerota's fascia posteriorly and reflected medially to expose the retroperitoneum and kidney (Fig. 53-2).

It is important to incise the peritoneum lateral to the colon. If the white line of Toldt is incised, the surgeon must be certain not to continue to follow that plane posteriorly, to prevent dissecting the kidney's lateral attachments, complicating the dissection. It is useful to leave the kidney's lateral attachments until after the hilum is controlled; the lateral attachments help "retract" the kidney up without using one of the instruments to retract the kidney. This peritoneal layer is very thin; the surgeon must stay outside Gerota's fascia, but avoid entering the posterior mesentery. There is a clear difference in the appearance of the fat layers of Gerota's fascia (paler yellow) and posterior mesentery (brighter yellow).

It is often helpful to free up the upper-pole attachments between the spleen and kidney to avoid an inadvertent capsular tear of the spleen from a retraction injury. It is important to reflect the colon far enough superiorly to ensure sufficient access to the upper pole of the kidney, and low enough to ensure access to the ureter below the lower pole.



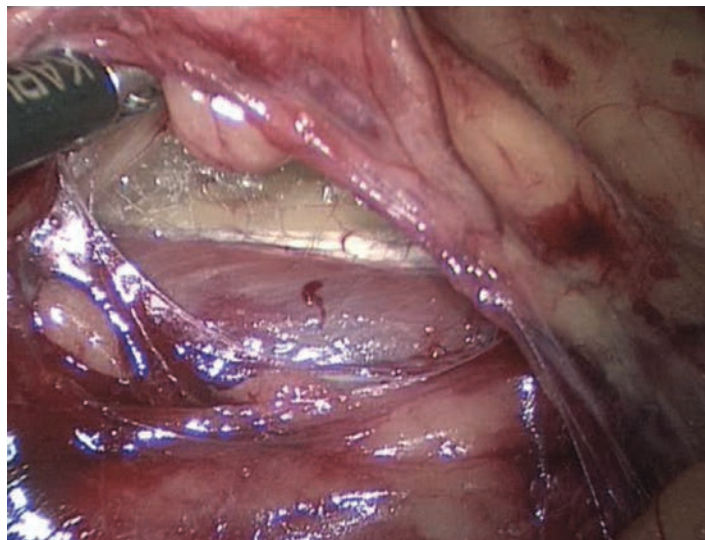
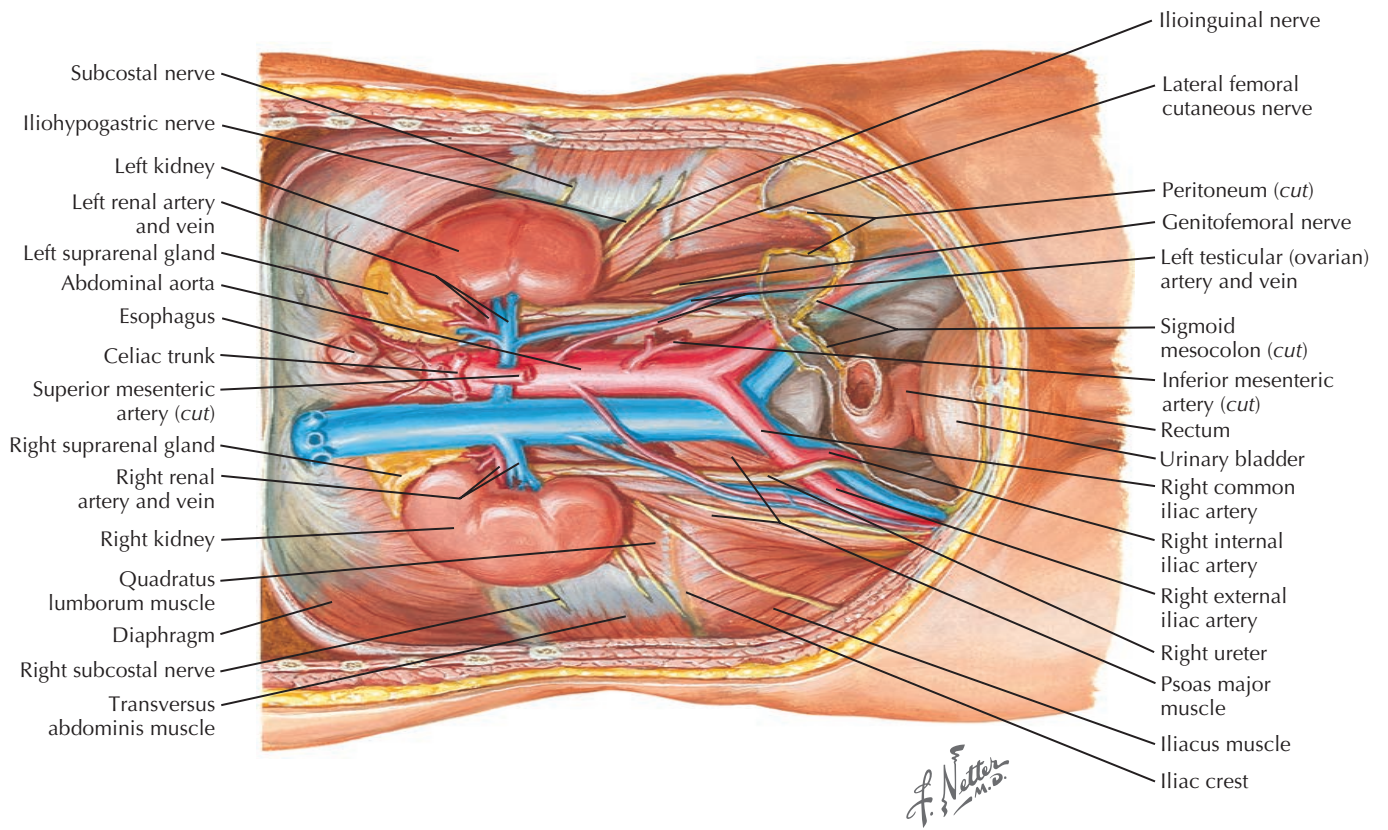
Posterior aspect of the mesentery reflected medially off the Gerota's fascia. The Gerota's fascia is more pale than the posterior mesenteric fat.

FIGURE 53-2 Reflected colon and mesentery medially; kidney and Gerota's fascia laterally.

DISSECTION

Ureter

Once the colon is reflected, it is helpful to dissect the ureter free. Starting below the lower pole of the kidney, the surgeon should dissect lateral to the aorta, identifying the ureter and gonadal vein (Fig. 53-3). Once identified, the ureter should be retracted laterally, exposing the psoas muscle posteriorly. At that point, the ureter can be clipped and divided with the lateral attachments to the ureter all the way to the abdominal side wall. The proximal end of the divided ureter can then be used for gentle retraction to help follow the psoas muscle, ureter, and gonadal vein (on the left) as landmarks up to the renal hilum.



The left ureter and gonadal vein are retracted up, exposing the psoas muscle posteriorly.

FIGURE 53-3 Anatomic relations of kidney and psoas exposure.

Renal Hilum

Typically the renal vein will be anterior to the renal artery. Once the attachments overlying the hilum are divided, the renal artery should be identified posterior to the renal vein. Some variation may be seen, because the renal artery can be directly posterior, inferior, or slightly superior to the renal vein, but typically is directly posterior (Fig. 53-4, A).

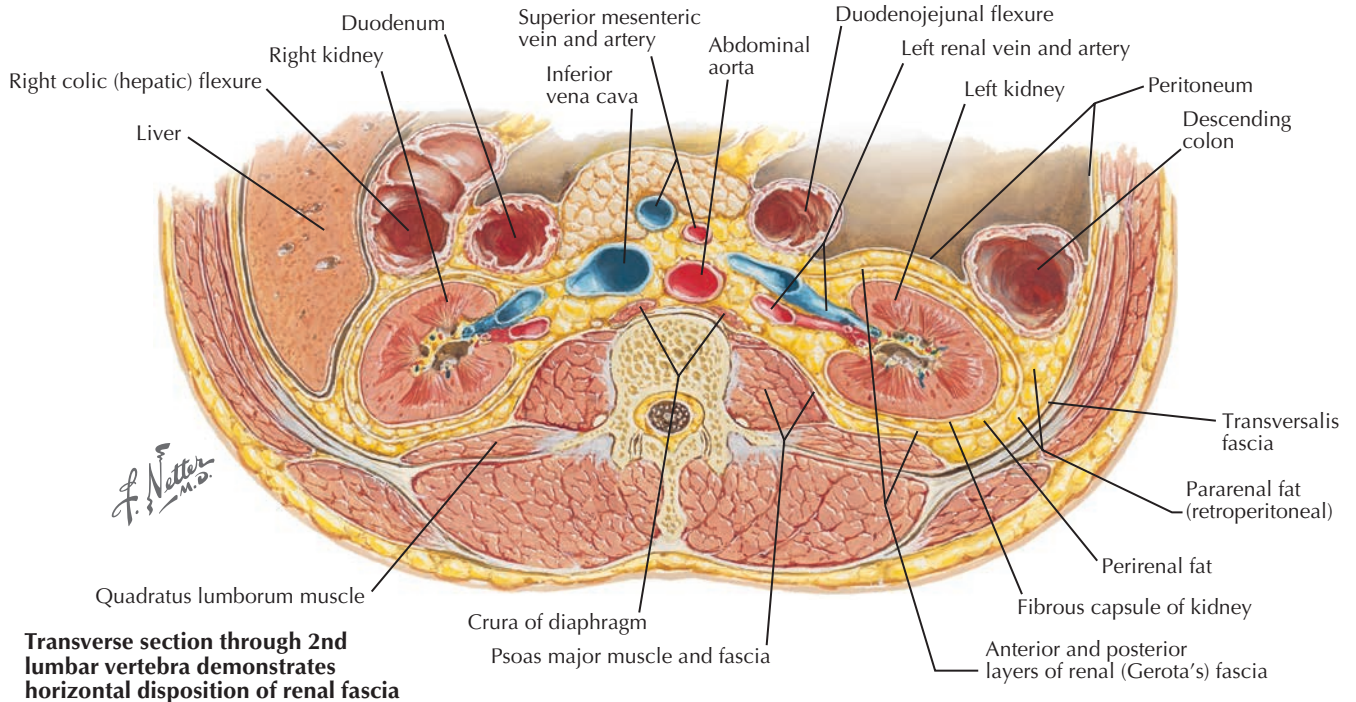
The renal artery should be controlled and divided before dividing the renal vein. The surgeon should be cautious because accessory arteries or veins and lumbar vessels may require control. Preoperative imaging is typically helpful, but these accessory vessels are not always identified, and intraoperative caution should be taken while dissecting the renal hilum.

Adrenal Gland

The original description of the radical nephrectomy involved removal of the adrenal gland, but more recent evidence shows that removal of the adrenal gland may not be necessary for all radical nephrectomies. The adrenal gland is often preserved in many contemporary series of radical nephrectomies.

If the surgeon desires to preserve the adrenal gland, the dissection should start immediately superior to the renal vein (Fig. 53-4, B). On the left, the renal vein should be divided distal to the adrenal vein insertion into the renal vein. The adrenal gland should be dissected from the upper pole of the kidney. On the right side, special caution is taken because the right adrenal vein is short, with its insertion directly into the vena cava.

A. Demonstrates the renal vein typically anterior to the renal artery



B. Demonstrates the relationship between the adrenal and upper pole of the kidney

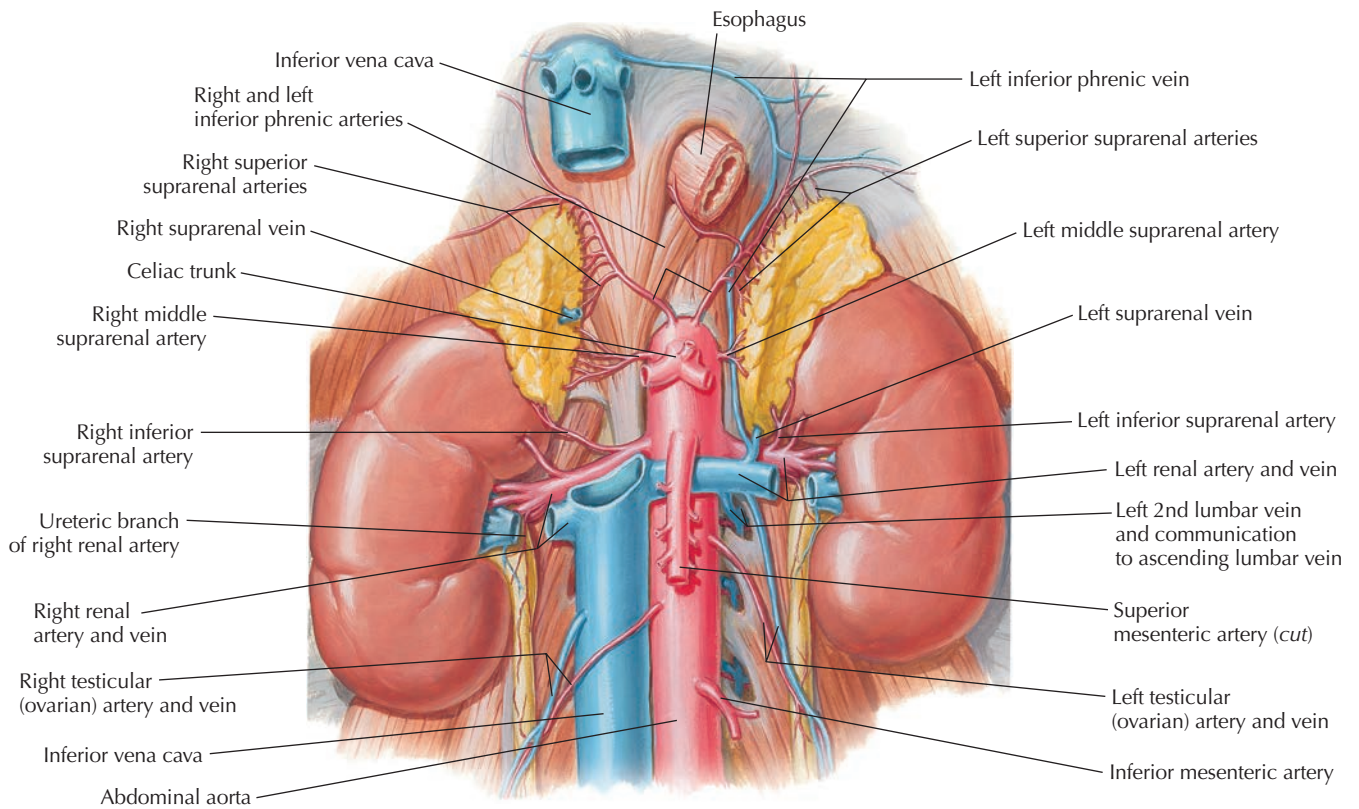


FIGURE 53-4 Relationships of renal vessels and adrenal gland.

Lateral Attachments Divided

Once the ureter, hilum, and upper pole attachments are all divided, the kidney's lateral attachments can be divided, freeing up the kidney completely. Care should be taken to stay outside Gerota's fascia, but not intrude into the abdominal side wall.

EXTRACTION

Once free from all attachments, the kidney should be placed into a nonpermeable sac for removal. An extraction site should be determined before surgery; a Pfannenstiel or a Gibson extraction incision is often used. Once the kidney is removed, the extraction incision is closed. With any trocar incisions greater than 5 mm, the fascia should be closed and the skin reapproximated.

SUGGESTED READINGS

- Colombo JR Jr, Haber GP, Jelovsek JE, et al. Seven years after laparoscopic radical nephrectomy: oncologic and renal functional outcomes. *Urology* 2008;71(6):1149-54.
- Maurice MJ, Ponsky L. Laparoscopic radical nephrectomy (adrenal gland sparing). *Urologybook.com*. <http://www.urologybook.com/laparoscopic-radical-nephrectomy-adrenal-gland-sparing/>
- Pareek G, Hedican SP, Gee JR, Bruskewitz RC, Nakada SY. Meta-analysis of the complications of laparoscopic renal surgery: comparison of procedures and techniques. *J Urol* 2006; 175(4):1208-13.
- Ponsky L, Cherullo E, Moinzadeh A, et al. The Hem-o-lok clip is safe for laparoscopic nephrectomy: a multi-institutional review. *Urology* 2008;71(4):593-6.

Radical Prostatectomy



William Tabayoyong and Robert Abouassaly

INTRODUCTION

Radical prostatectomy for the treatment of prostate cancer has been performed for more than 100 years. The location of the prostate deep in the pelvis challenged surgical extirpation and caused significant morbidity. Radical prostatectomy is a “gold standard” in the treatment of localized prostate cancer, and level 1 evidence confirms that it offers a survival advantage over the absence of treatment in men with this disease. With increased understanding of the anatomy of the prostate and surrounding structures, along with improvements in instrumentation, the morbidity associated with radical prostatectomy has decreased substantially. Currently, urinary continence is achieved in approximately 90% of patients, and erectile function is preserved in most men with good preoperative function.

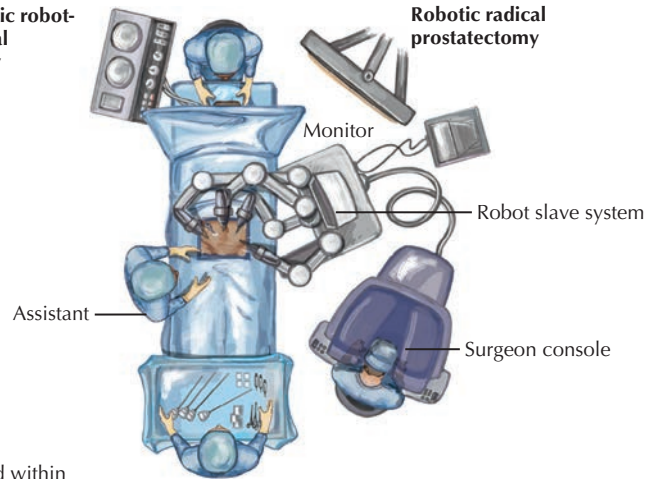
Traditionally, radical prostatectomy has been performed in the open retropubic or perineal approach. In the last decade, however, use of minimally invasive approaches has dramatically increased, particularly laparoscopic robot-assisted radical prostatectomy (Fig. 54-1, A). This approach has gained popularity because of its greater technical ease for the surgeon, especially with laparoscopic suturing, which allows for more precise suture placement during the vesicourethral anastomosis.

PROSTATE CANCER: THERAPEUTIC PRINCIPLES

Once the diagnosis of prostate cancer is made on biopsy, staging is obtained depending on the patient's Gleason score, prostate-specific antigen (PSA), clinical stage, and life expectancy. Staging can include a bone scan and pelvic CT or MRI scan. If the malignancy has a high probability of being localized to the prostate, treatment options are discussed with the patient, including active surveillance, radiation therapy, or surgery, depending on disease factors, life expectancy, and patient preference. Radical prostatectomy is considered in men with life expectancy greater than 10 years who have prostate cancer at significant risk of progression.

The variation in prostate size and shape, as well as its location deep in the pelvis between the bladder and urethra and adjacent to the rectum, make surgical extirpation challenging (Fig. 54-1, B). Additionally, the prostate is surrounded by a venous plexus, and the neurovascular bundles responsible for erection run alongside the prostate. Therefore the surgical dissection required during radical prostatectomy should be performed meticulously by a surgeon with detailed knowledge of the anatomic relationships of the prostate.

A. Laparoscopic robot-assisted radical prostatectomy



Robotic radical prostatectomy

B. Anatomical position of the prostate. The prostate is located within the pelvis between the bladder and urethra, adjacent to the rectum, surrounded by a venous plexus and neurovascular bundles.

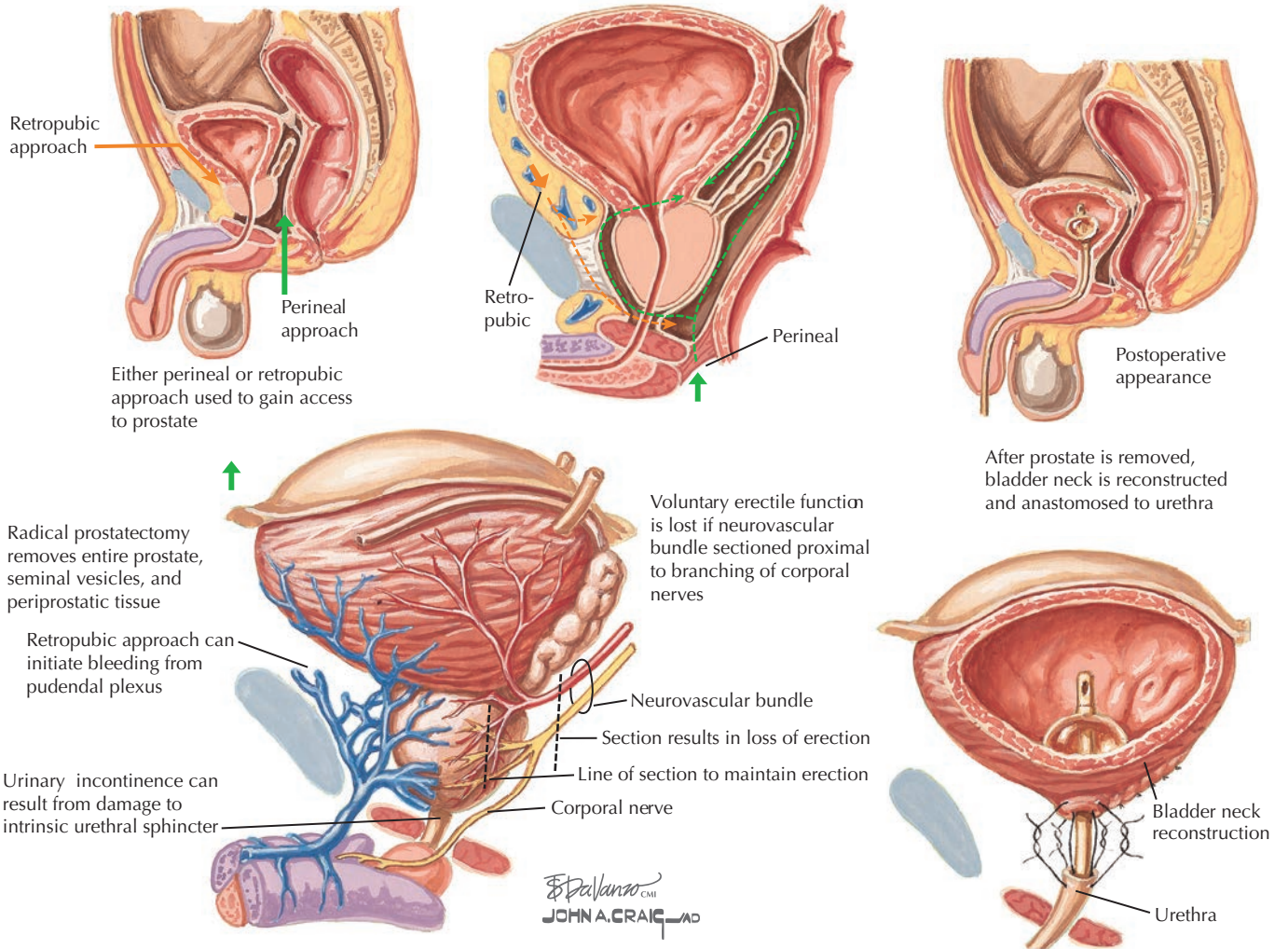


FIGURE 54-1 Robot-assisted prostatectomy and surgical approaches to prostate.

SURGICAL APPROACH

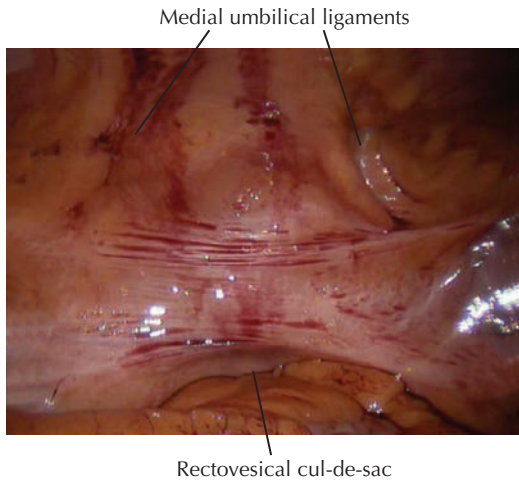
Posterior Prostatic Dissection

Initial inspection of the pelvis is performed to identify the relevant landmarks: the medial umbilical ligaments and the vasa deferentia. The rectovesical cul-de-sac (pouch of Douglas) is approached, and the courses of the vasa are identified through the peritoneal layer (Fig. 54-2, A-D).

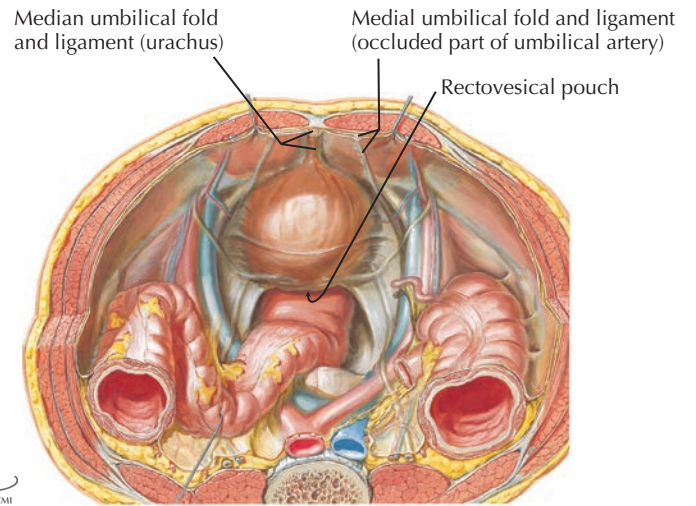
The overlying peritoneum is incised, and the ampulla of the vas deferens is isolated and transected. Retraction on the vas deferens ventromedially allows for identification and dissection of the ipsilateral seminal vesicle. The artery to the seminal vesicle is either clipped or controlled with bipolar electrocautery. The contralateral vas deferens and seminal vesicle are then dissected in a similar manner.

The seminal vesicles and vasa are retracted ventrally, exposing Denonvilliers' fascia (Fig. 54-2, E and F). This fascia is incised sharply just dorsal to the base of the prostate. This approach allows entry into a plane containing perirectal fat, and the surgeon can then carefully dissect the prostate off of the rectum in an antegrade direction to the prostatic apex.

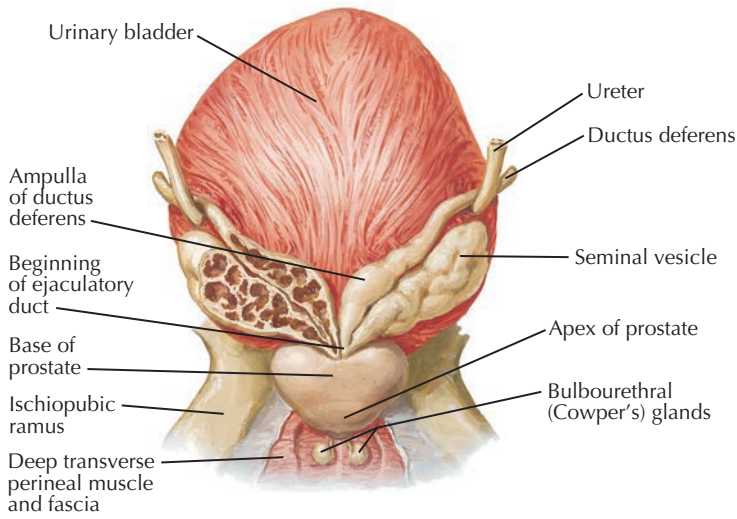
A. Pelvis before incision of overlying peritoneum



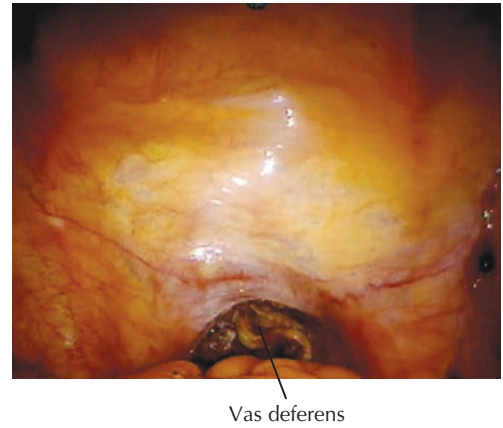B. Medial umbilical ligaments



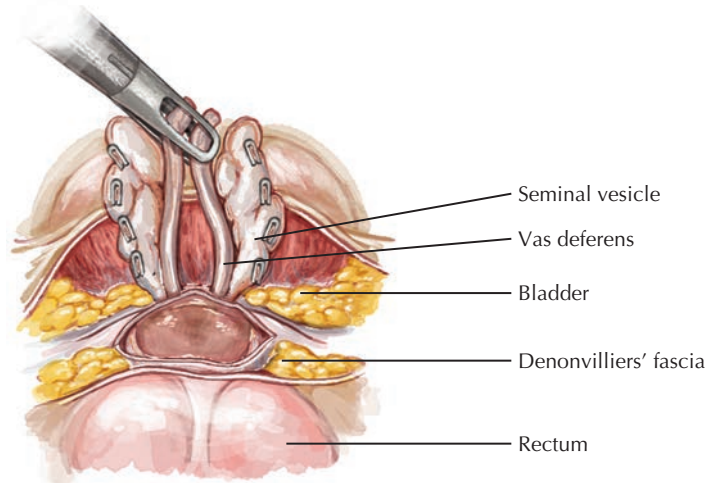
C. Posterior view of prostate



D. Vasa deferentia identified



E. Posterior antegrade dissection between bladder and rectum



F. Seminal vesicles and vasa are retracted ventrally, exposing Denonvilliers' fascia

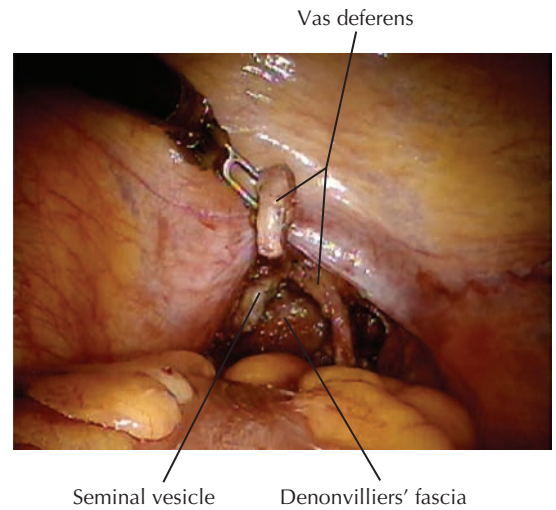


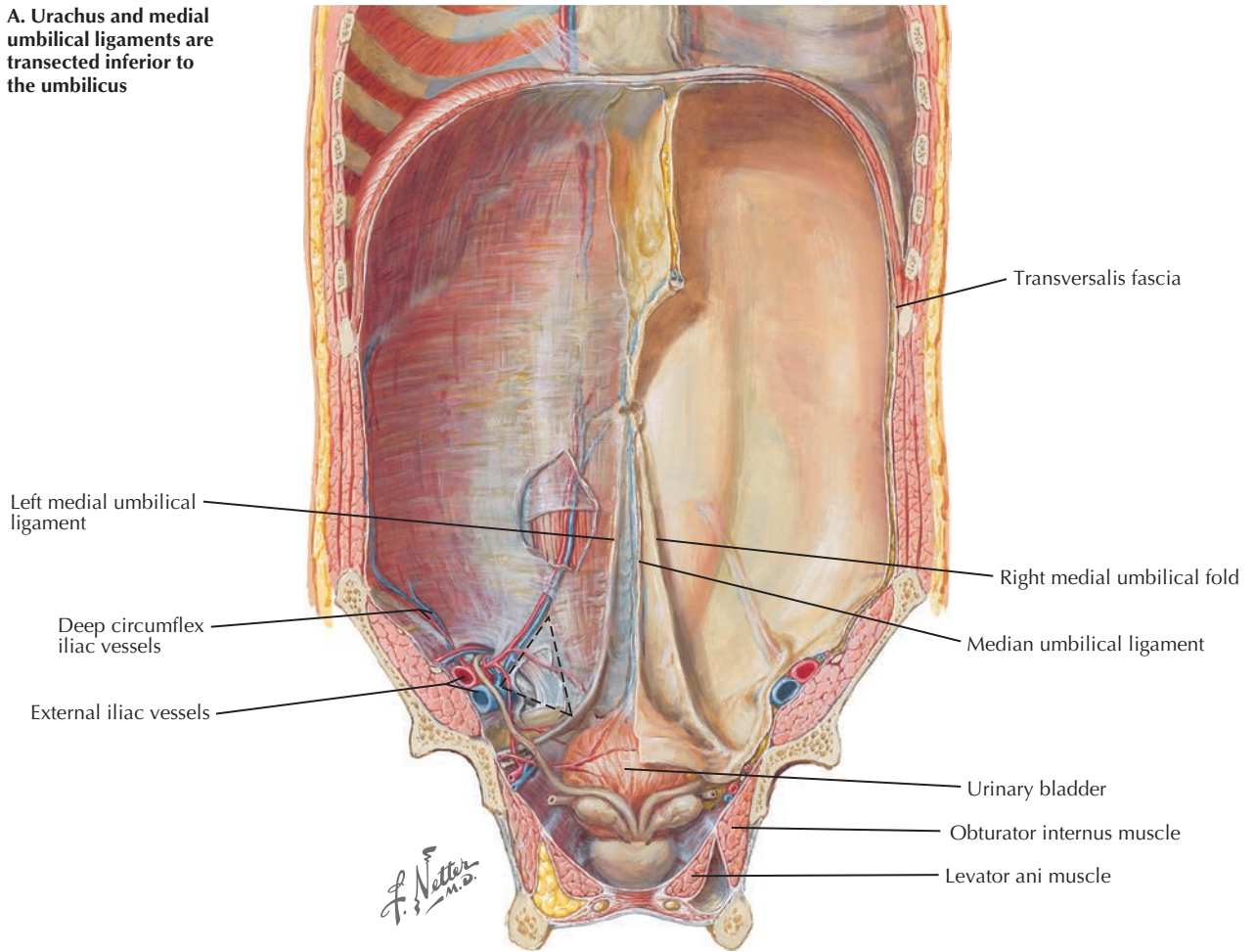
FIGURE 54-2 Posterior prostatic dissection.

Development of Space of Retzius

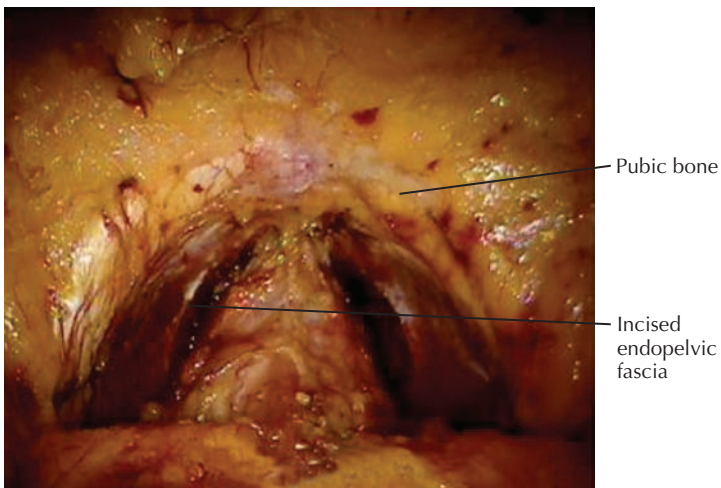
The urachus and medial umbilical ligaments are transected with electrocautery just inferior to the umbilicus (Fig. 54-3). The bladder is carefully dissected off of the anterior abdominal wall just deep to the posterior rectus sheath and transversalis fascia. The lateral limits of the dissection are the lateral borders of the medial umbilical ligaments.

The bladder is then swept off of the iliac vessels and obturator muscles. The endopelvic fascia is exposed and sharply incised from the base of the prostate to the puboprostatic ligaments bilaterally. The superficial dorsal vein is coagulated with bipolar electrocautery and transected. Levator muscle fibers are then swept off of the lateral aspects of the prostate, exposing the prostate-urethral junction. The puboprostatic ligaments are sharply transected, allowing greater access to the prostatic apex. The deep dorsal venous complex (DVC) is then suture-ligated.

A. Urachus and medial umbilical ligaments are transected inferior to the umbilicus



B. The bladder is dissected off of the anterior abdominal wall and swept off of the iliac vessels and obturator muscles. The endopelvic fascia is then sharply incised.



C. The dorsal venous complex is suture-ligated.

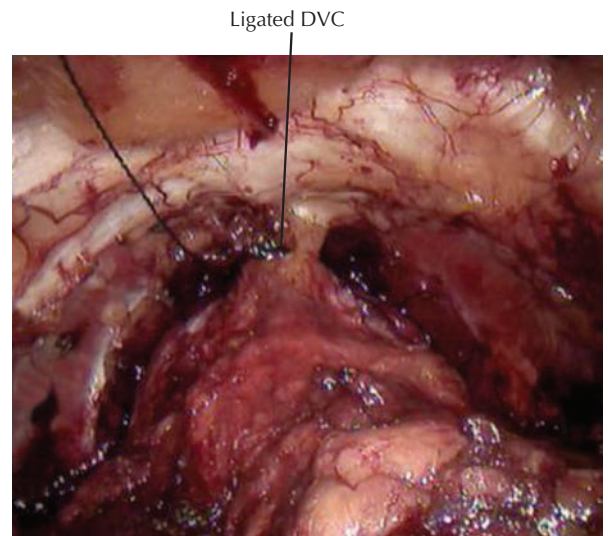


FIGURE 54-3 Development of space of Retzius.

Bladder Neck Dissection

The contour of the prostate, the pliability of the tissues, and the balloon from the urethral catheter are used to identify the bladder neck just proximal to the base of the prostate. Electrocautery is then used to dissect the anterior, lateral, then posterior bladder neck off of the base of the prostate (Fig. 54-4, *A*).

An enlarged median lobe of the prostate, if present, is identified at this point in the procedure. The dissection is modified to ensure complete excision with the prostate specimen.

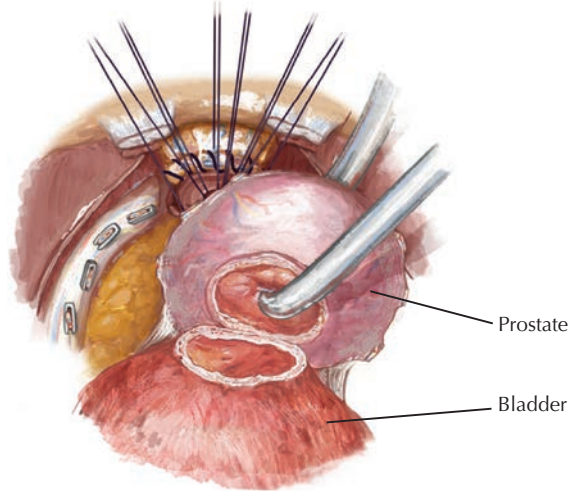
Care is taken by the surgeon during the posterior bladder neck dissection to avoid injuring the ureters by visually identifying and avoiding the ureteral orifices. Once through the posterior bladder neck, the surgeon can enter the posterior plane developed earlier in the procedure, and the transected vasa and seminal vesicles can be visualized and grasped for retraction.

Neurovascular Bundle Preservation

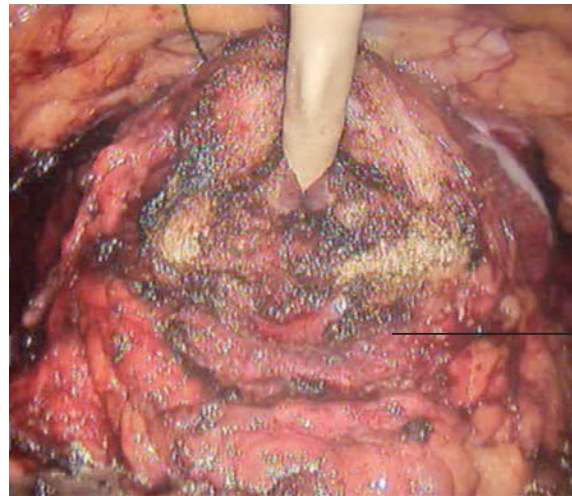
Release of the neurovascular bundles can be performed at this point in the procedure, or after control of the vascular pedicles to the prostate (Fig. 54-4, *B*). The levator fascia is sharply incised over the anterolateral prostate, preserving the underlying prostatic fascia. This incision is carried distal beyond the prostatic apex, and proximal to the vascular pedicles.

The dissection is then carried dorsally along the surface of the prostate until the posterior plane is entered, and the neurovascular bundles are completely released off of the prostatic surface. In many patients, venous or small arterial tributaries coursing between the neurovascular bundles and the prostate are encountered, and these must be ligated and transected.

A. Bladder neck dissection



Division of bladder neck



Bladder neck

B. Neurovascular bundle preservation. The neurovascular bundles are completely released off of the prostatic surface.

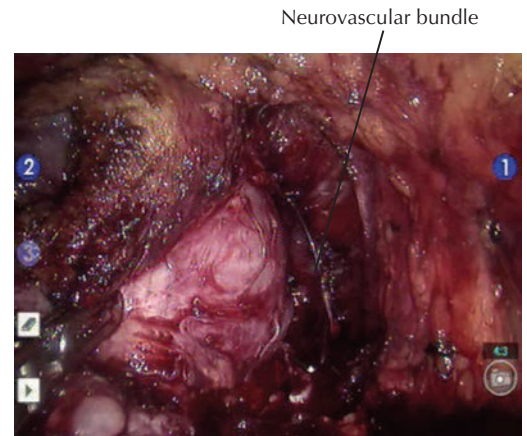
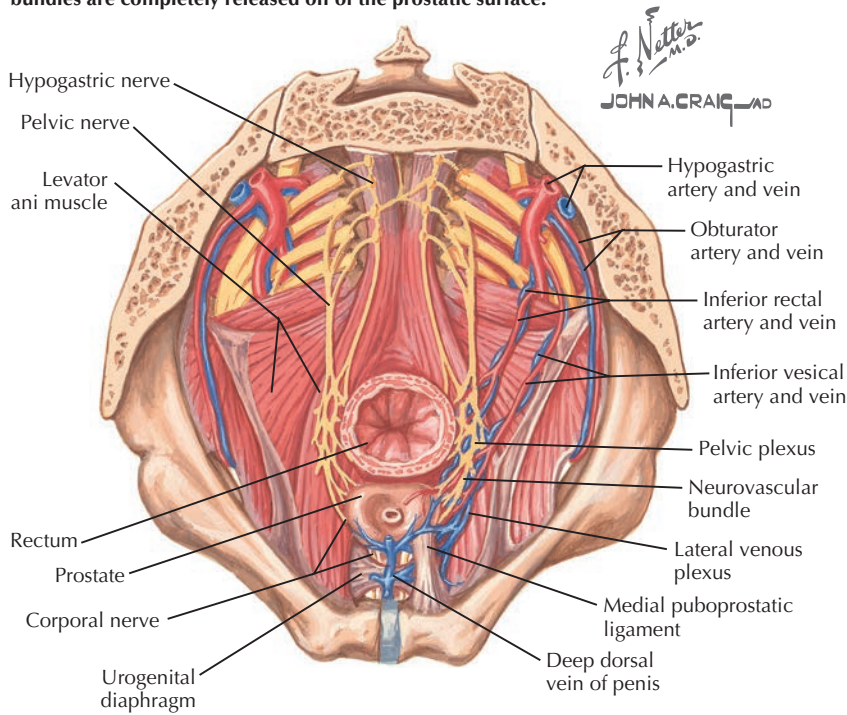
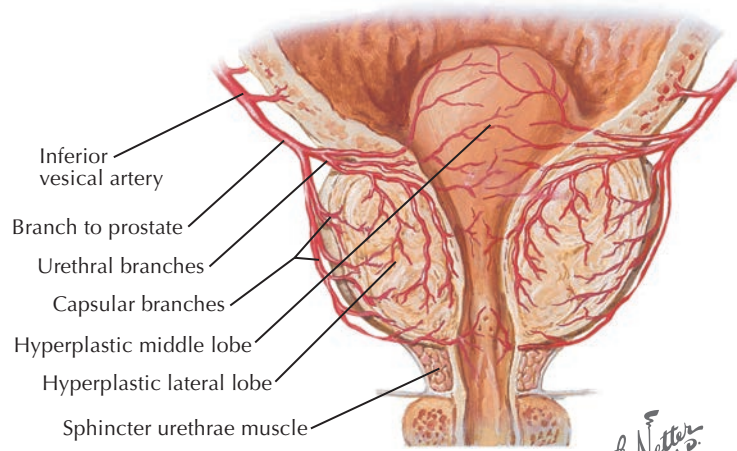


FIGURE 54-4 Bladder neck dissection and neurovascular bundle.

Prostatic Pedicle Ligation and Division of Deep Dorsal Venous Plexus

The base of the prostate is left attached by the vascular pedicles (Fig. 54-5). The seminal vesicles and vasa are retracted anteriorly and contralaterally, defining the prostatic pedicles at the 5 and 7 o'clock positions. The pedicles are then clipped or suture-ligated and transected sharply.

The DVC is transected immediately proximal to the previously placed suture ligature. If bleeding from the DVC occurs, repeated suture ligation invariably results in adequate hemostasis. Once the DVC is completely divided, the prostate can be retracted farther out of the pelvis, and the junction between the prostatic apex and urethra can be seen.



**Arterial supply of prostate
(frontal section, anterior view of
specimen with benign hyperplasia)**

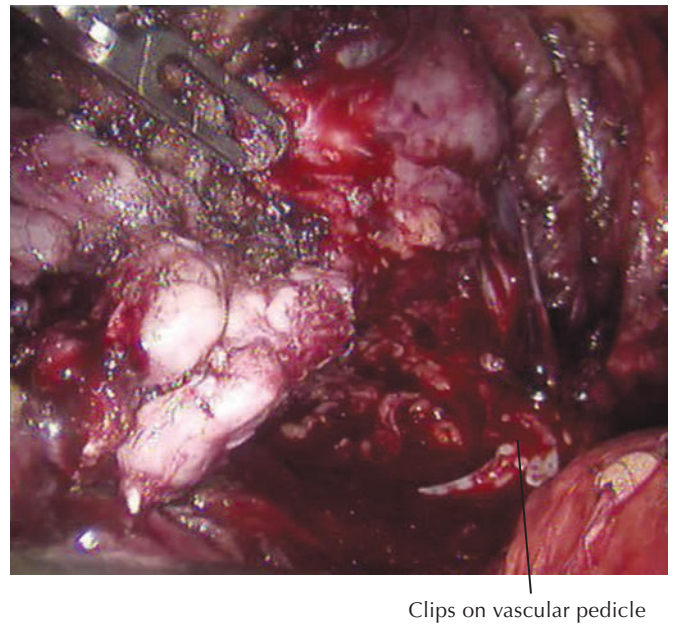
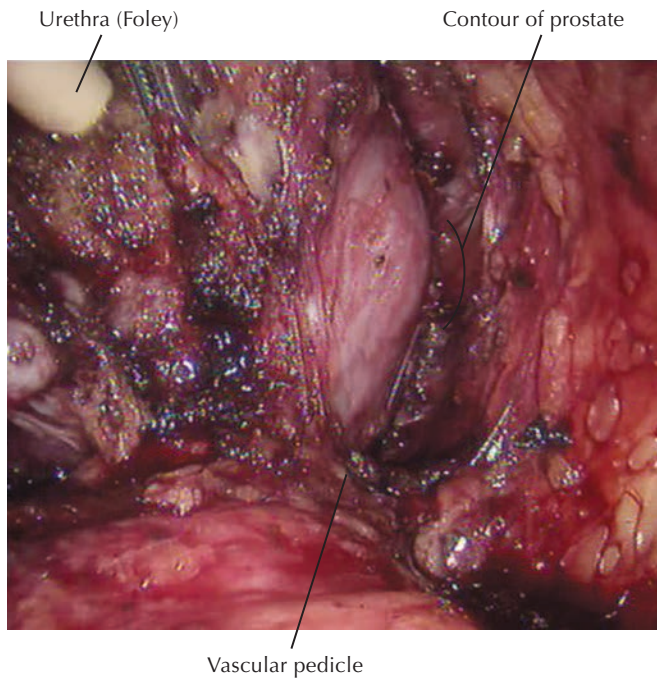


FIGURE 54-5 Prostatic pedicle ligation and division of deep dorsal venous plexus.

Division of Urethra

The apex of the prostate is further defined with careful dissection around the urethra (Fig. 54-6, *A*). Inspection is done to confirm the neurovascular bundles are dissected off of the prostatic apex to ensure that the bundles will not be inadvertently transected during urethral division. The anterior urethra is then divided sharply just distal to the prostate apex.

Care is taken to inspect the contour of the posterior prostatic apex before dividing the posterior urethra. In some cases the posterior prostatic apex can protrude beyond the anterior apex, requiring a more distal dissection in this area. Once the urethra is divided, the prostate is free to be placed in a specimen bag for later extraction.

Vesicourethral Anastomosis

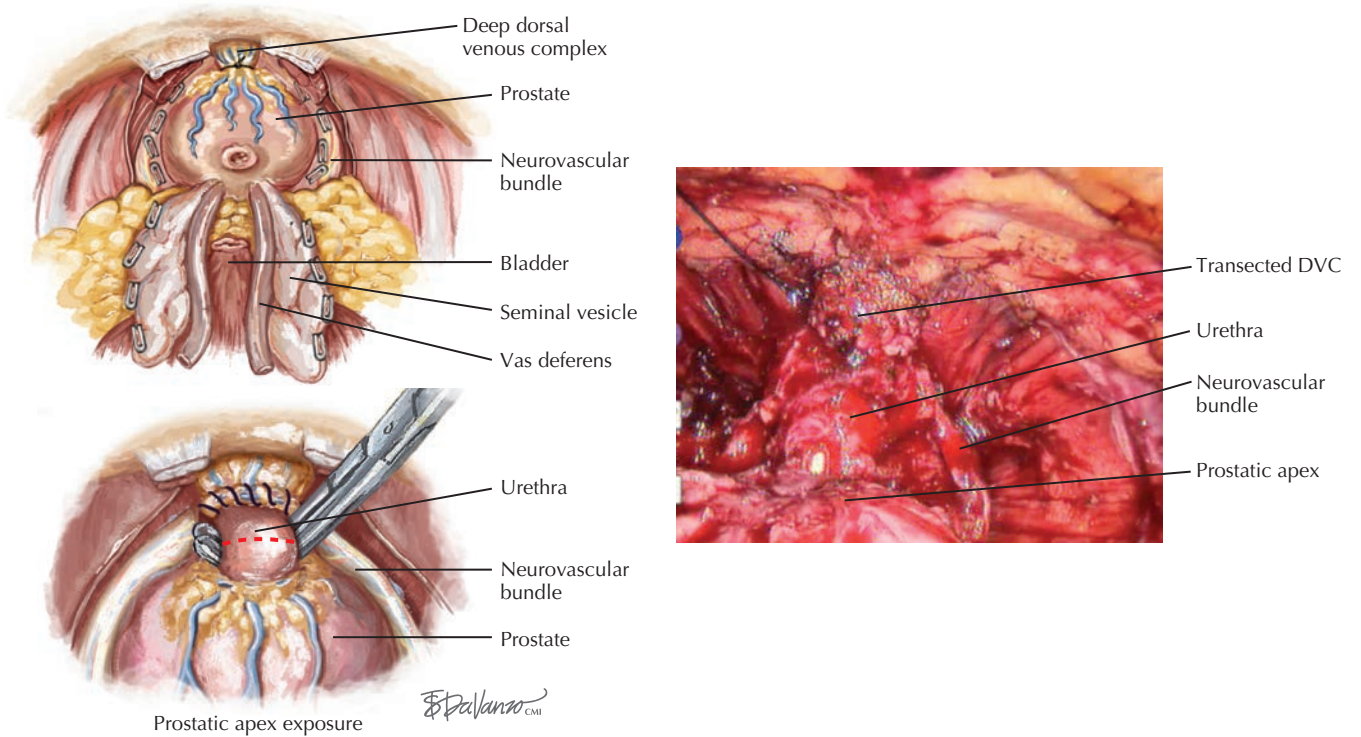
The vesicourethral anastomosis is created by running two sutures in opposite directions from the midposterior to the midanterior bladder neck (Fig. 54-6, *B*). Adequate apposition of the posterior bladder neck is needed to avoid postoperative urine leaks, because this is the area of greatest tension.

A urethral catheter is placed under vision at the completion of the anastomosis. A closed suction drain is then left in the prevesical space, adjacent to but not directly on the anastomosis.

Specimen Extraction

Incisions in the fascia and skin of the umbilical port are extended appropriately to allow safe extraction of the entrapped prostate specimen. Fascial and skin incisions are closed and dressings applied.

A. Division of the urethra



B. Vesicourethral anastomosis. The anastomosis is created by running two sutures in opposite directions from the midposterior neck to the midanterior bladder neck.

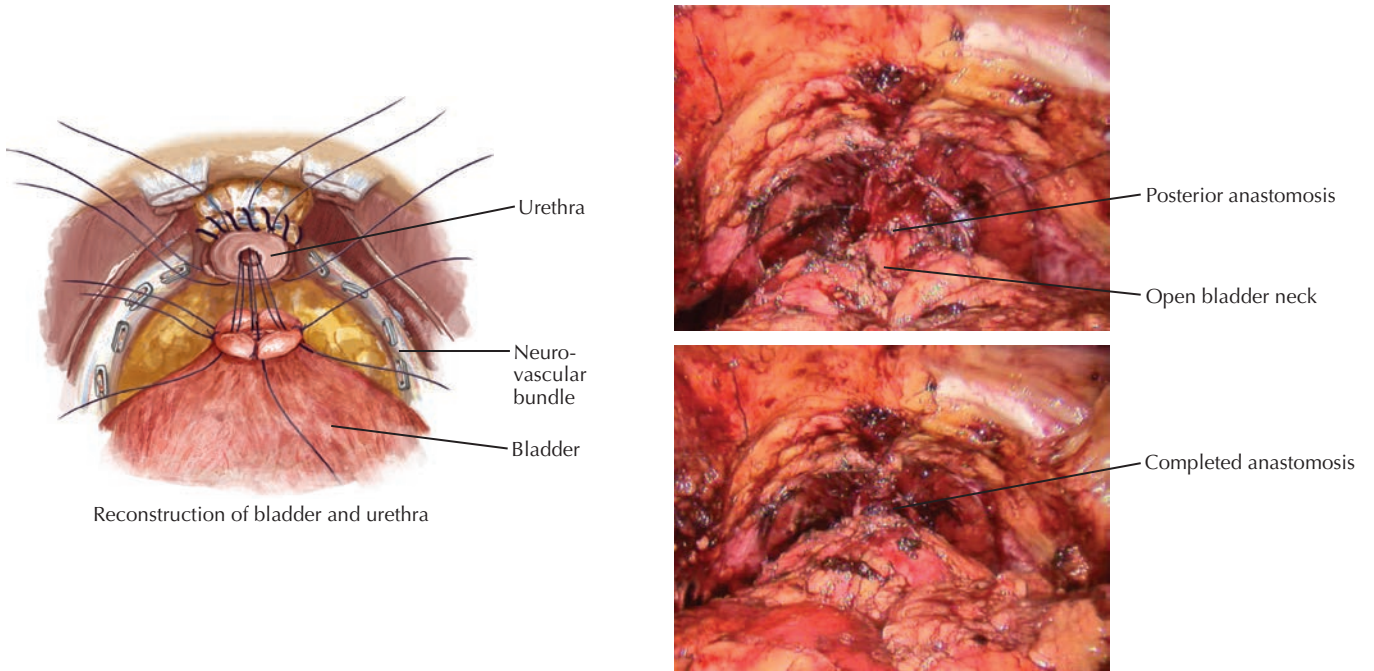


FIGURE 54-6 Division of urethra and vesicourethral anastomosis.

SUGGESTED READINGS

- Bill-Axelson A, Holmberg L, Ruutu M, et al. Radical prostatectomy versus watchful waiting in early prostate cancer. *N Engl J Med* 2011;364:1708.
- Ficarra V, Novara G, Artibani W, et al. Retropubic, laparoscopic, and robot-assisted radical prostatectomy: a systematic review and cumulative analysis of comparative studies. *Eur Urol* 2009;55:1037.
- Hu JC, Gu X, Lipsitz SR, et al: Comparative effectiveness of minimally invasive vs open radical prostatectomy. *JAMA* 2009;302:1557.
- National Comprehensive Cancer Network: Clinical practice guidelines in oncology. 2010;V.3.201. www.nccn.org
- Young HH: The early diagnosis and radical cure of carcinoma of the prostate. *Johns Hopkins Hosp Bull* 1905;16:315.

Radical Cystectomy

Jessica M. Yih, Jonathan E. Kiechle, and Edward E. Cherullo

INTRODUCTION

In the United States, bladder cancer is the fourth most common type in men and the ninth most common type of cancer in women. Non–muscle-invasive bladder cancer can often be treated with transurethral resections of bladder tumors and possible intravesical immunotherapy or chemotherapy with cystoscopic surveillance. Unfortunately, for muscle-invasive bladder cancer or for tumors with high-grade features and invasion into the lamina propria (T1) without metastatic disease, radical cystectomy with urinary diversion remains the cornerstone of treatment. Other indications for cystectomy include bacille Calmette-Guérin (BCG)–refractory carcinoma in situ (CIS), and as a palliative procedure for patients with severely symptomatic, metastatic bladder cancer necessitating acute hospital care and readmissions.

The first reported total cystectomy was in 1887 by Bernhard Bardenheuer. Radical cystectomy in men classically involves the removal of the bladder, distal ureters, prostate, and seminal vesicles. In women who choose not to maintain their fertility and who have extensive disease, *anterior pelvic exenteration* is traditionally performed, including cystectomy, salpingo-oophorectomy, hysterectomy, urethrectomy, and resection of the anterior one third of the vaginal wall. For radical cystoprostatectomy, advances in surgical technique have included nerve-sparing procedures to preserve potency in men and prostate-sparing procedures to accompany orthotopic bladder substitution. Recent data also challenge anterior pelvic exenteration in female patients and support more limited resection in those without extensive disease, preserving the anterior vaginal wall, uterus, ovaries, and pelvic supporting ligaments. Pelvic lymphadenectomy is performed regardless of gender.

SURGICAL APPROACH

Cystectomy has traditionally been performed through a low abdominal midline incision. Advances in laparoscopic technique now offer patients the option of laparoscopic or robotic-assisted cystectomy. However, despite reports of successfully completed intracorporeal laparoscopic construction of urinary diversions, the postcystectomy method of urinary reservoir formation is generally still completed with open techniques.

Bladder Mobilization

The midline incision length is determined on the basis of surgeon preference and experience, individual patient anatomy, extent of disease, and planned urinary diversion. Inferiorly, the incision should extend to the symphysis pubis to obtain adequate exposure. After incision of the skin and anterior and posterior layers of anterior abdominal wall fascia, the extraperitoneal space is entered first, and the space of Retzius is developed to mobilize the bladder away from the symphysis pubis anteriorly and to expose the external iliac artery and vein laterally.

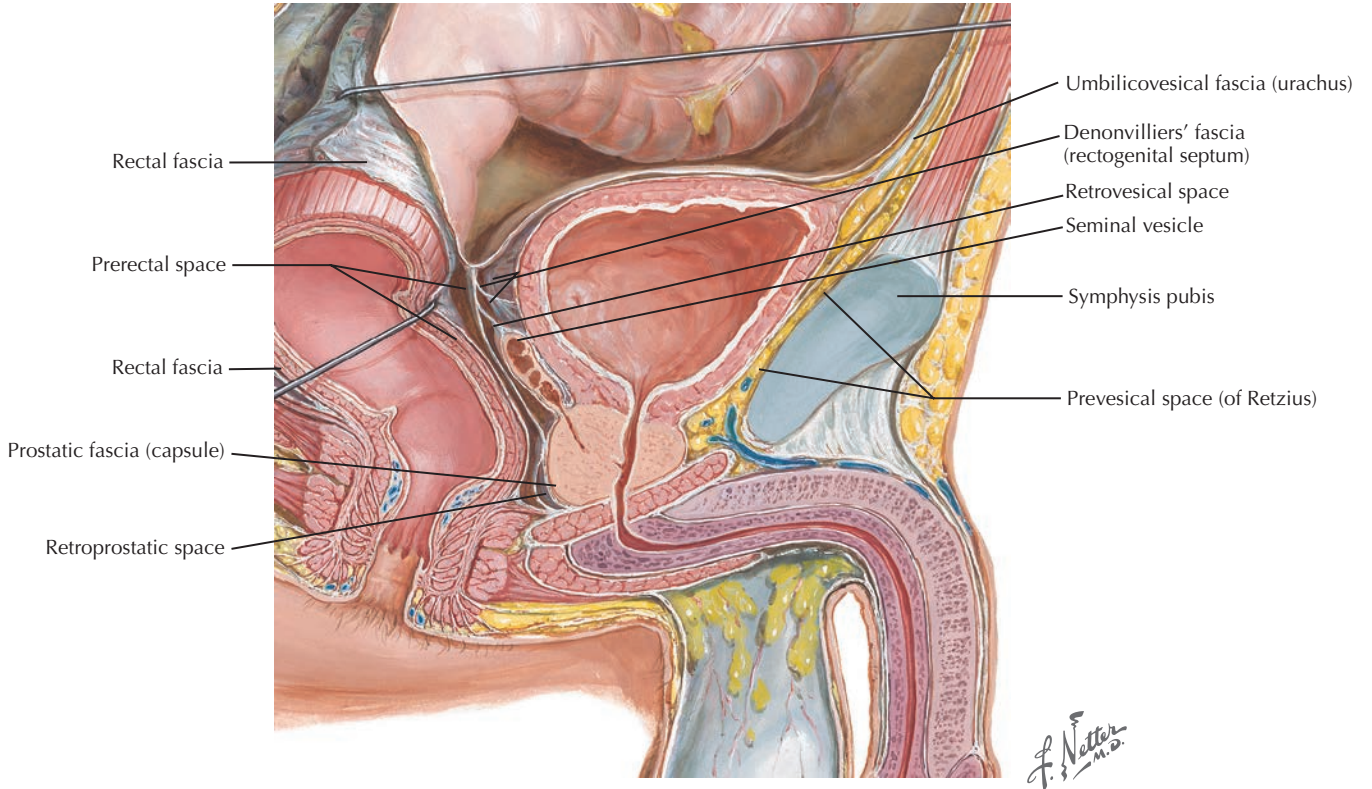
The peritoneum located at the proximal midline incision is opened and extended laterally from the medial umbilical ligament to the internal inguinal rings. The urachus is divided high near the level of the umbilicus and subsequently used for retraction. Anatomically, an avascular plane of fibroareolar connective tissue can be followed, between the posterior rectus sheath and the peritoneum and along the medial umbilical ligaments. Care should be taken to avoid injury to the inferior epigastric arteries, which course in this plane and serve as the primary blood supply to the rectus abdominis muscle.

With the medial umbilical ligaments traced inferiorly and the space of Retzius open, a self-retaining retractor can be placed to facilitate exposure. Extra care is taken when applying traction on the most inferior aspect of the wound; injury to the femoral and genitofemoral nerves can result from prolonged stretch or compression. The symphysis should be visible with the retractor in place (Fig. 55-1, A).

The sigmoid colon is often adherent laterally to the side wall and occasionally to the bladder. The sigmoid colon is mobilized medially at this point by opening the peritoneum at the white line of Toldt. The small bowel can be placed in a damp, countable towel and pushed cephalad, and the sigmoid laid in the midline, with gentle retraction holding this exposure. These maneuvers provide excellent exposure and facilitate dissection.

The peritoneal wings previously left in place by developing the space of Retzius and opening the peritoneum from the umbilicus to the inguinal ring are easily seen and divided with electrocautery to the level of the vas deferens in the male patient. The vas deferens is divided with the understanding that vascular structures are associated with both vasa. The authors prefer to use ties to allow later identification of the seminal vesicles (Fig. 55-1, B).

A. Sagittal section of fascial planes



B. Pelvic contents: male (superior view)

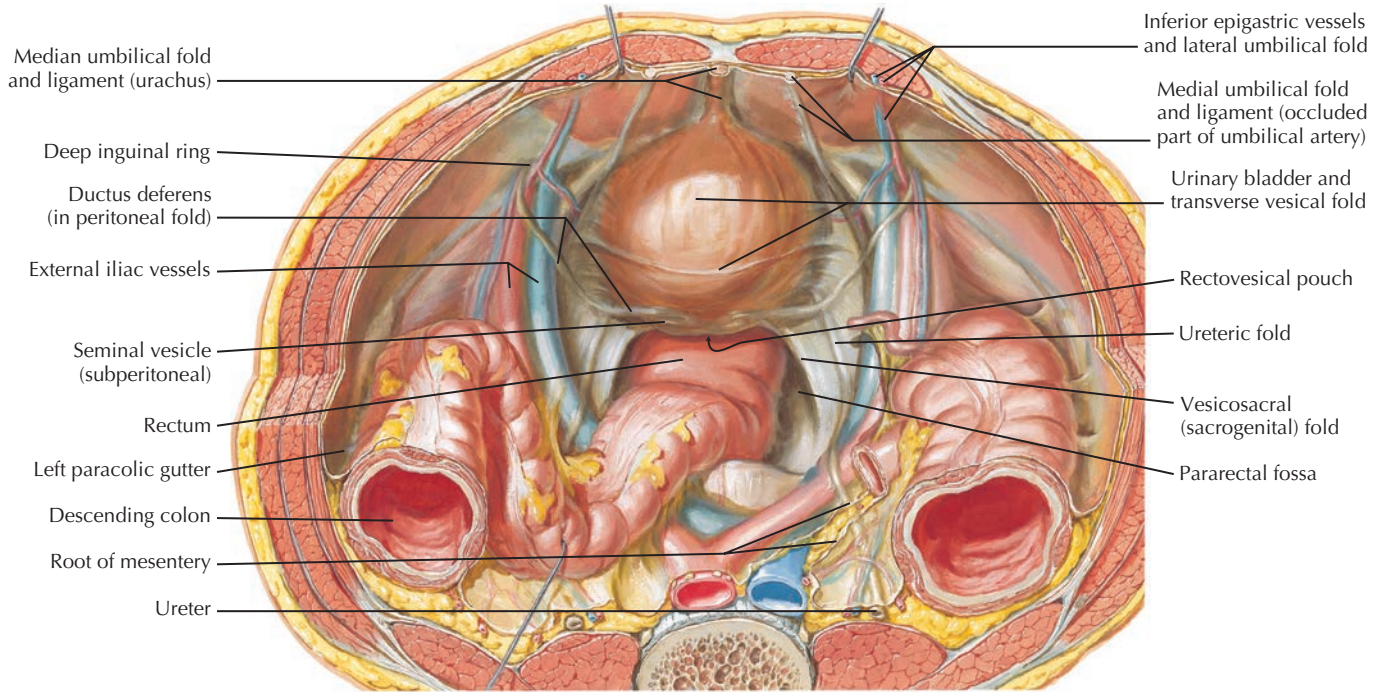


FIGURE 55-1 Male: fascial planes and pelvic contents.

Dissection of Ureters

After bilateral ligation of the vas deferens, the immediate posterior peritoneum along the bladder and above the sigmoid is opened. This approach allows identification of the ureters as they cross the iliac vessels and anterior mobilization of the bladder off the proximal rectum to the level of the prostate and seminal vesicles. This maneuver can be done with a gentle blunt movement; extra care should be taken because this loose plane of connective tissue becomes dense at the level of the prostate and cannot always be easily bluntly dissected. Forceful blunt dissection here risks rectal injury.

The left ureter is identified posterior to the sigmoid colon, in a position often more medial than expected. The retroperitoneal space behind the sigmoid colon at the level of the sacral promontory is opened to allow the ureter to be passed to the other side after its division. The right ureter is found by dividing the visible peritoneal fold overlying it (Fig. 55-2).

The ureters are mobilized cephalad approximately 5 cm and caudad to the ureterovesical junction. Care must be taken to preserve soft tissue around the ureter. The periureteral blood supply is enveloped in this layer, and excellent vascularity will aid in a successful, patent anastomosis for the urinary diversion. The distal 5 mm of each ureter can then be divided and sent as a frozen section to ensure adequacy of the margin. In some cases of CIS, numerous frozen sections may need to be sent before an adequate margin is achieved. However, this practice has come under debate in recent years, with contradictory conclusions regarding the value of a negative margin in reducing risk of upper tract cancer recurrence.

This dissection allows for clear visualization of the common, external, and internal iliac arteries and prepares the surgeon to commence with pelvic lymphadenectomy.

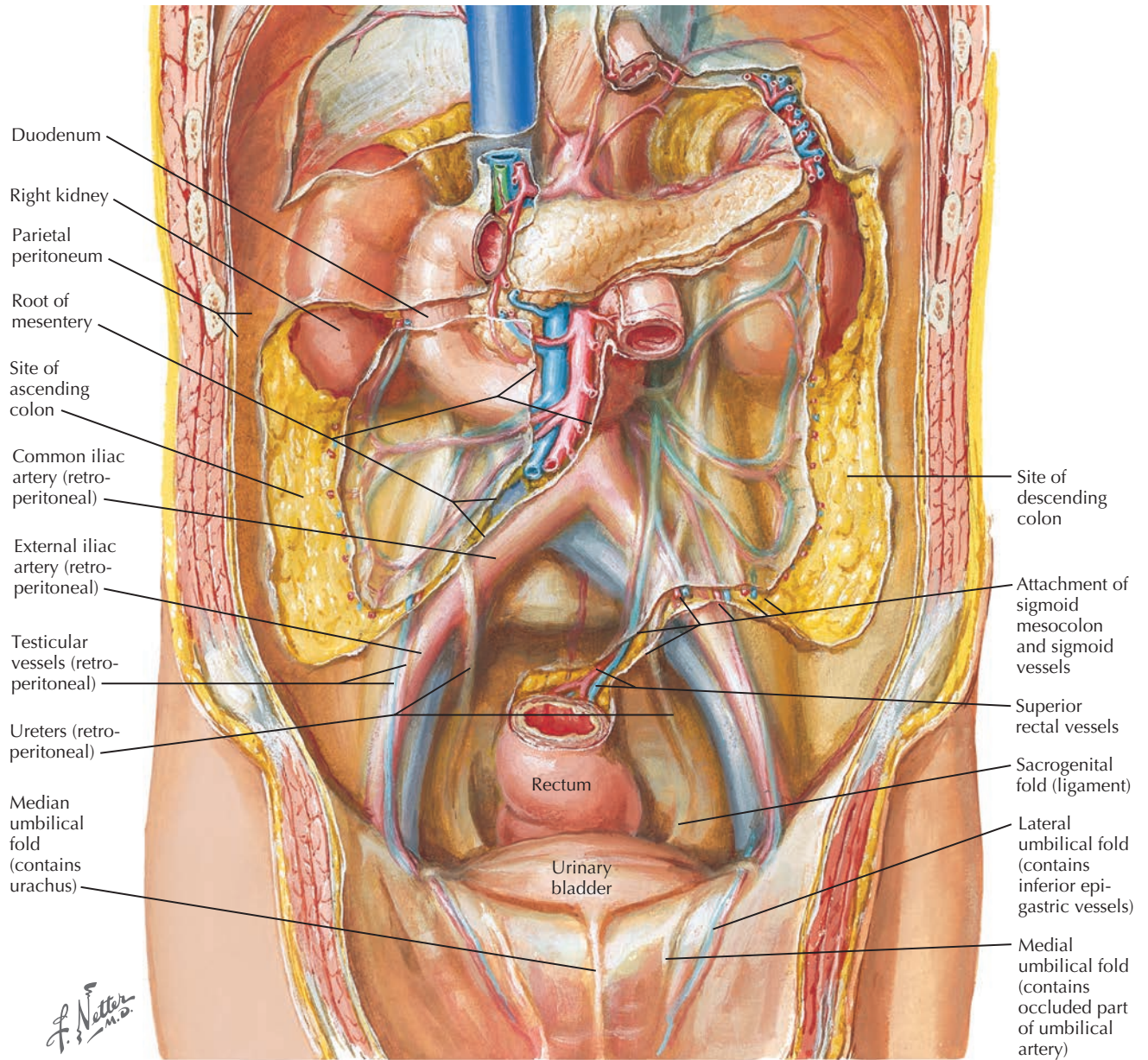


FIGURE 55-2 Peritoneum of posterior abdominal wall.

PELVIC LYMPHADENECTOMY

Limits of the lymphadenectomy are often variable depending on extent of disease. It has been demonstrated that 25 to 30 nodes should be resected to determine nodal status, and that this can be curative in some cases of micrometastatic nodal disease. The most limited dissection should at least include all fibroadipose and lymphatic tissue between the external iliac artery laterally, the internal iliac artery medially, the crossing of the ureter at the common iliac artery cranially, the circumflex iliac vein or inguinal ligament of Cooper caudally, and the obturator nerve inferiorly. More extensive dissection can extend to the genitofemoral nerve laterally and the bifurcation of the aorta cranially or even to the inferior mesenteric artery (Fig. 55-3).

Two important anatomic notes during the lymphadenectomy are the frequent presence of an accessory obturator vein draining into the external iliac vein and the proximity of the obturator nerve during dissection. Injury to the obturator nerve will result in difficulty adducting the ipsilateral lower extremity. The obturator artery and vein can be sacrificed with no adverse sequelae.

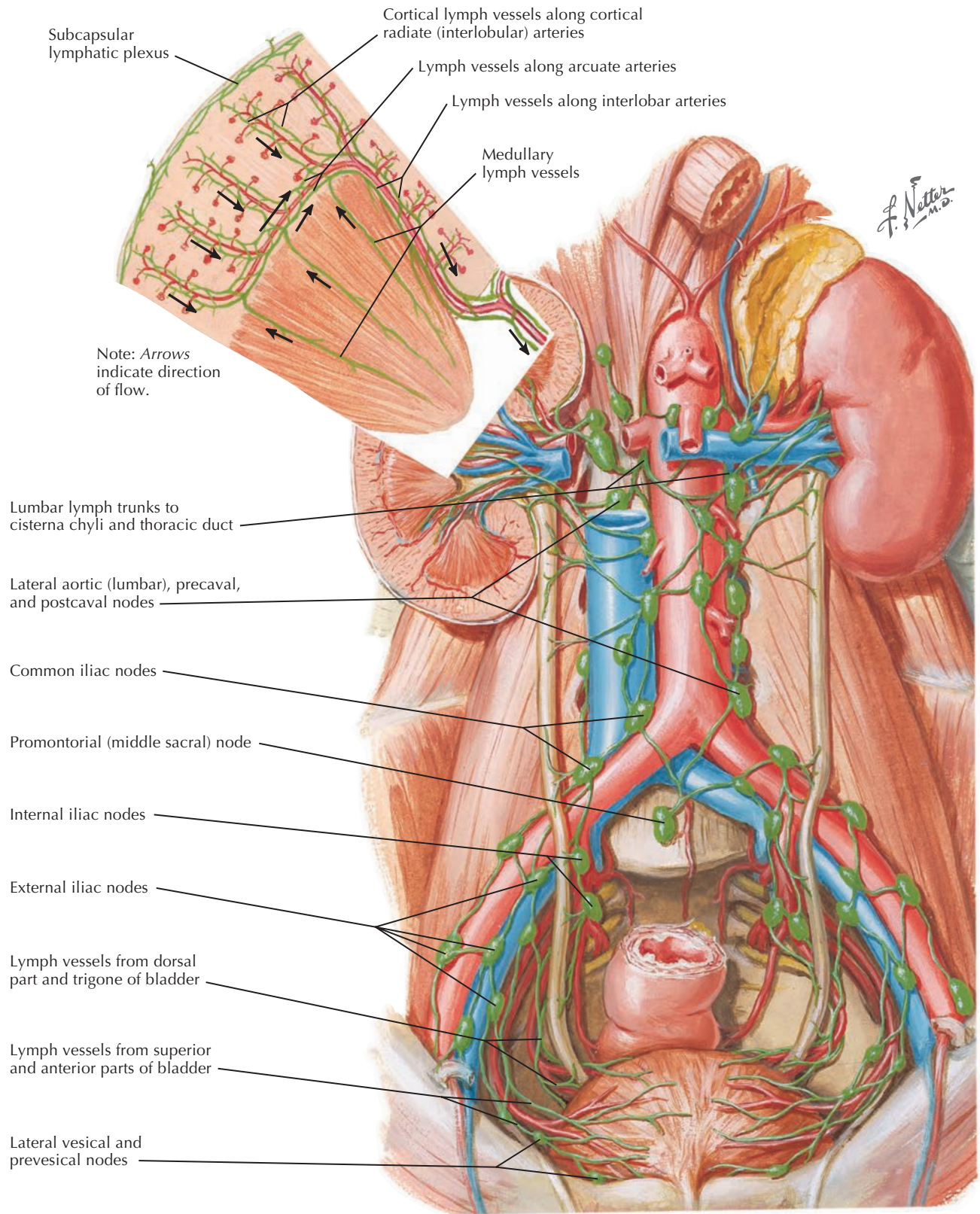


FIGURE 55-3 Lymph vessels and nodes of kidneys and bladder.

PEDICLE DISSECTION

Knowledge of vascular anatomy is the key to successful dissection of the lateral and posterior pedicles of the bladder. With the internal iliac artery already exposed and the vas deferens divided, the superior vesical artery, the first anterior branch of the internal iliac artery, can be safely ligated near its branching from the internal iliac artery (Fig. 55-4, A).

The remainder of the vascular supply to the bladder and prostate, although termed vessels, is carried in arteries of small enough caliber that collective division between stapling devices, clips, thermal dissectors, or ligation can be accomplished without individual identification. It is extremely important to remember that the use of stapling devices or thermal dissectors will divide tissues irrespective of tissue planes, and precise knowledge of the patient's anatomy is critical to avoid injury to adjacent structures.

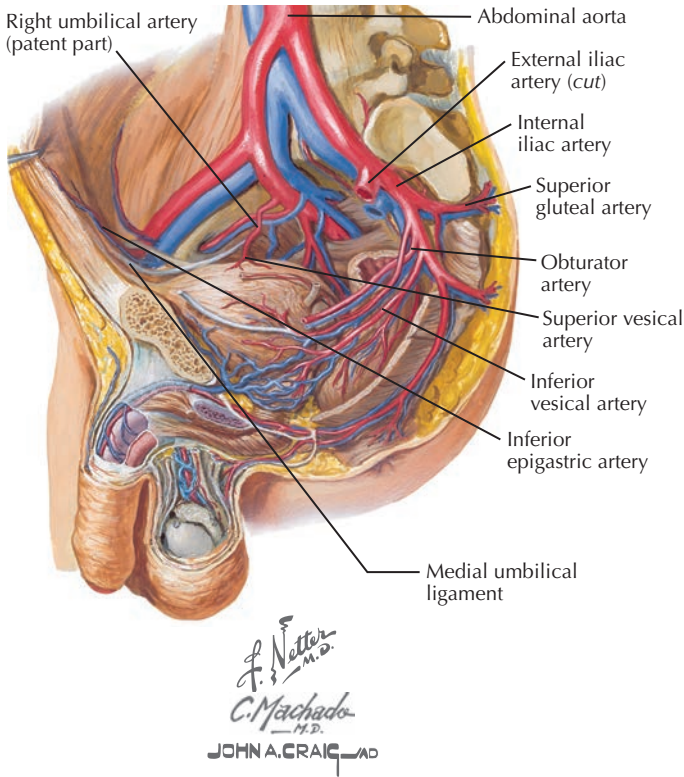
After ligating the superior vesicle artery, the surgeon can divide the remaining lateral and posterior pedicles of the bladder as previously described, to the level of the endopelvic fascia. Anterior retraction of the bladder exposes the pedicles, facilitating their division.

Using a combination of sharp and blunt dissection, the surgeon brings bladder with the seminal vesicles forward off the rectum. The posterior pedicles can now be visualized, postero-medial to the divided ureteral stump. This pedicle is divided to the level of the seminal vesicles with a thermal dissector or surgical stapler. Continuing distally, a plane may be developed between the rectum posteriorly and the posterior lamina of Denonvilliers' fascia anteriorly, taking care to stay anterior to the prerectal fat.

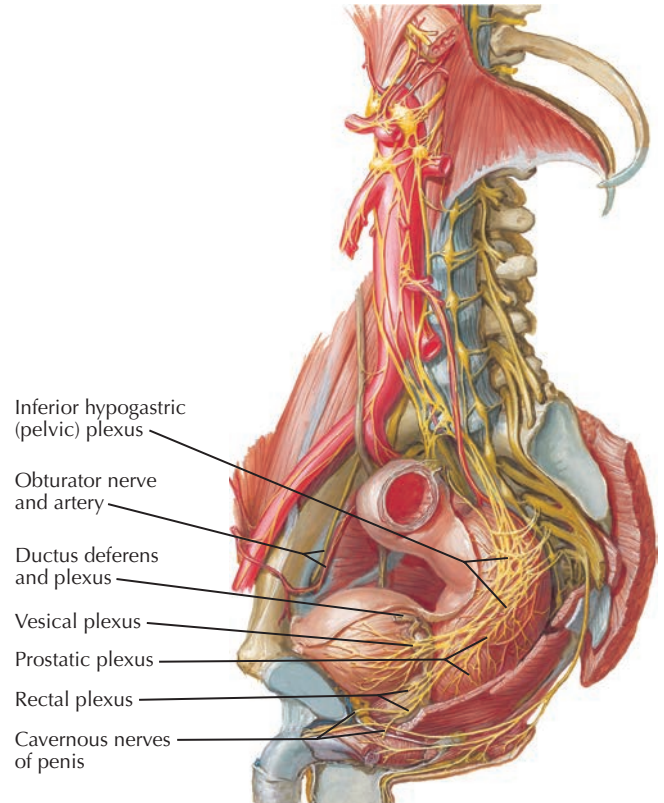
The space posterior to the prostate is developed caudally as close to the prostatic apex as possible. Here the surgeon may choose to continue with either nerve-sparing or non-nerve-sparing technique. Care should be taken to avoid damaging any of the autonomic nerves from the pelvic plexuses, because these nerves innervate the urinary sphincters and will play an important role in postoperative continence if an orthotopic urinary diversion is constructed (Fig. 55-4, B).

To preserve the autonomic plexus, an incision should be made between the lateral pelvic fascia and Denonvilliers' fascia to find the neurovascular bundles that lie posterolaterally along the prostate (Fig. 55-4, C and D).

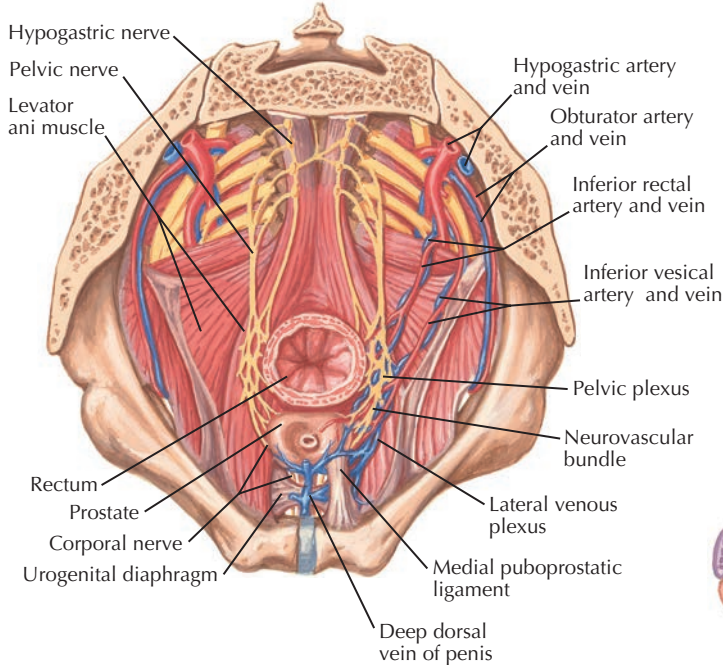
A. Arteries of male pelvis



B. Innervation of small and large intestine



C. Neural and vascular supply of prostate and penis



D. Voluntary erectile function is lost if neurovascular bundle sectioned proximal to branching of corporal nerves

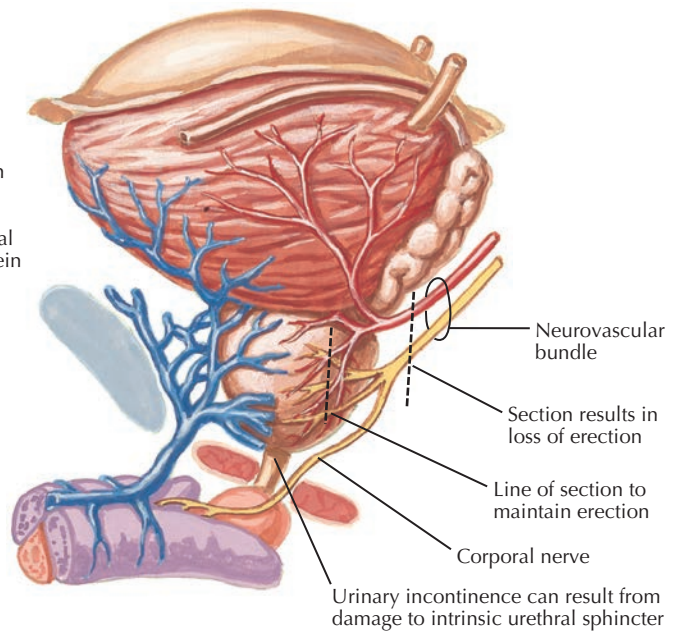


FIGURE 55-4 Male: vascular supply of pelvic organs and loss of erection.

URETHRAL LIGATION

After dissection of the pedicles, urethral ligation is completed in a manner similar to a prostatectomy.

Continuing caudally from the previously developed space of Retzius, the space anterior to the prostate is first opened, and the prostate is separated from its anterior attachments to the pubis. The endopelvic fascia and puboprostatic ligaments are exposed anteriorly, and the endopelvic fascia is opened, revealing the muscular attachments of the levator muscles to the prostate. With the endopelvic fascia open bilaterally, the anterior prostatic fascia, the extension of the endopelvic fascia over the prostate, can be suture-ligated. The dorsal venous complex (Santorini's plexus) is located within this fascia (Fig. 55-5).

The lateral edges of the prostate are dissected from the remaining muscular attachments of the levator ani muscle. The urethra is then freed with blunt dissection, isolated, and divided. This approach exposes the triangular extension of Denonvilliers' fascia; when incised, this exposes the rectum. Any remaining pedicle attachments of the bladder or prostate are then divided. The specimen, comprising the bladder, terminal ureters, seminal vesicles, and prostate, can then be removed en bloc. Anastomotic sutures can be placed in the remaining proximal urethra if orthotopic urinary diversion is planned.

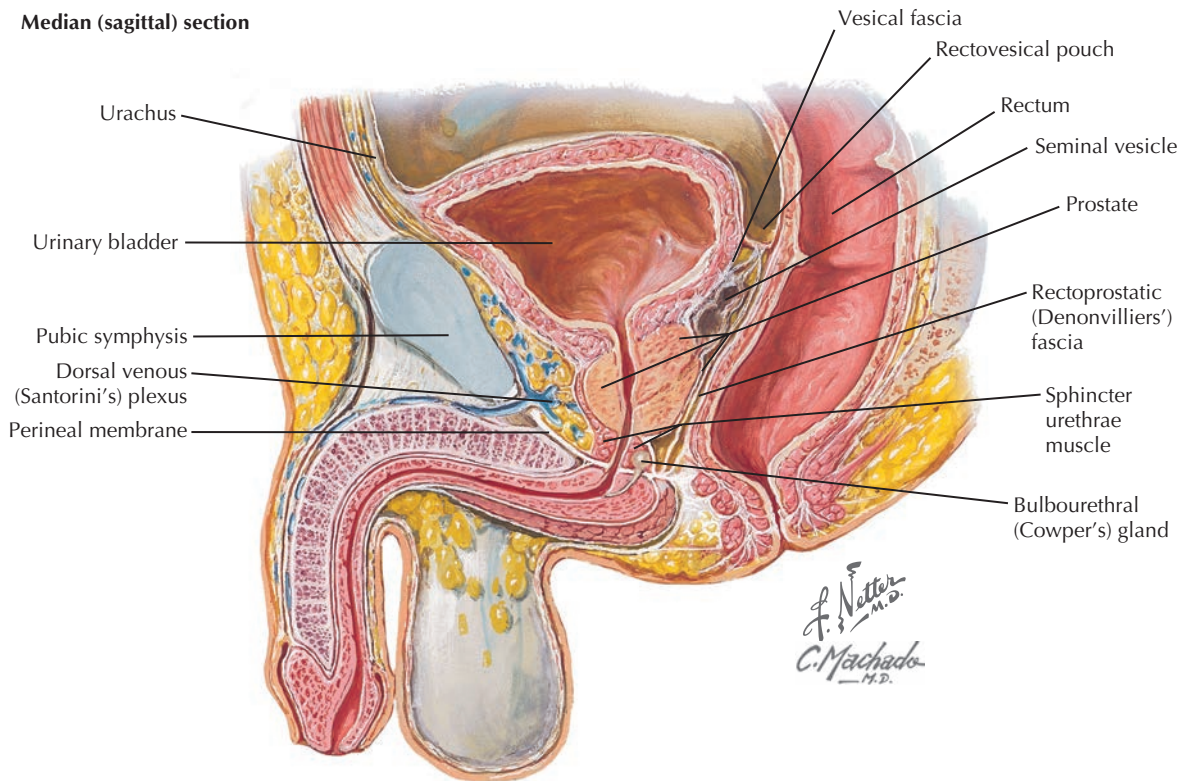


FIGURE 55-5 Pelvic viscera and perineum: male

ANTERIOR PELVIC EXENTERATION

In female patients who have extensive disease, anterior pelvic exenteration is traditionally performed, including cystectomy, salpingo-oophorectomy, hysterectomy, urethrectomy, and resection of the anterior one third of the vaginal wall. After a lower abdominal midline incision, the peritoneum is incised laterally toward the round ligaments, which are then ligated. An anterior retraction stitch on the fundus of the uterus facilitates exposure of the uterine vessels.

First, the ovarian vessels and infundibulopelvic ligaments are ligated, which allows for better exposure because the intestines can be packed upward into the abdomen away from the pelvis. The ureters are traced to the vascular supply of the uterus. The uterine vessels are suture-ligated at their origin from the internal iliac vessels to mobilize and expose the ureters to the ureterovesical junction, where they are ligated (Fig. 55-6, A).

The uterus is now mobilized laterally from its attachments at the cervix and inferior ligaments. The uterus can be left attached anteriorly to the posterior aspect of the bladder to be removed en bloc with the specimen.

Bladder Mobilization

Technique for division of the lateral pedicles varies depending on whether a vagina-sparing procedure is being performed. The lateral blood supply is isolated as it branches from the internal iliac artery, and the inferior uterine arteries must be ligated. The bladder is mobilized medially away from the lateral walls of the pelvis to expose the endopelvic fascia, the perirectal fat pad, and the lateral pedicles.

A povidone-iodine (Betadine) swab stick in the vagina is elevated cranially and ventrally to aid exposure of the apex of the vagina, which is opened immediately distal to the cervix into the posterior vagina by cautery. The incision at the apex of the vagina can be continued down bilaterally on the anterolateral sides of the vagina to the bladder neck.

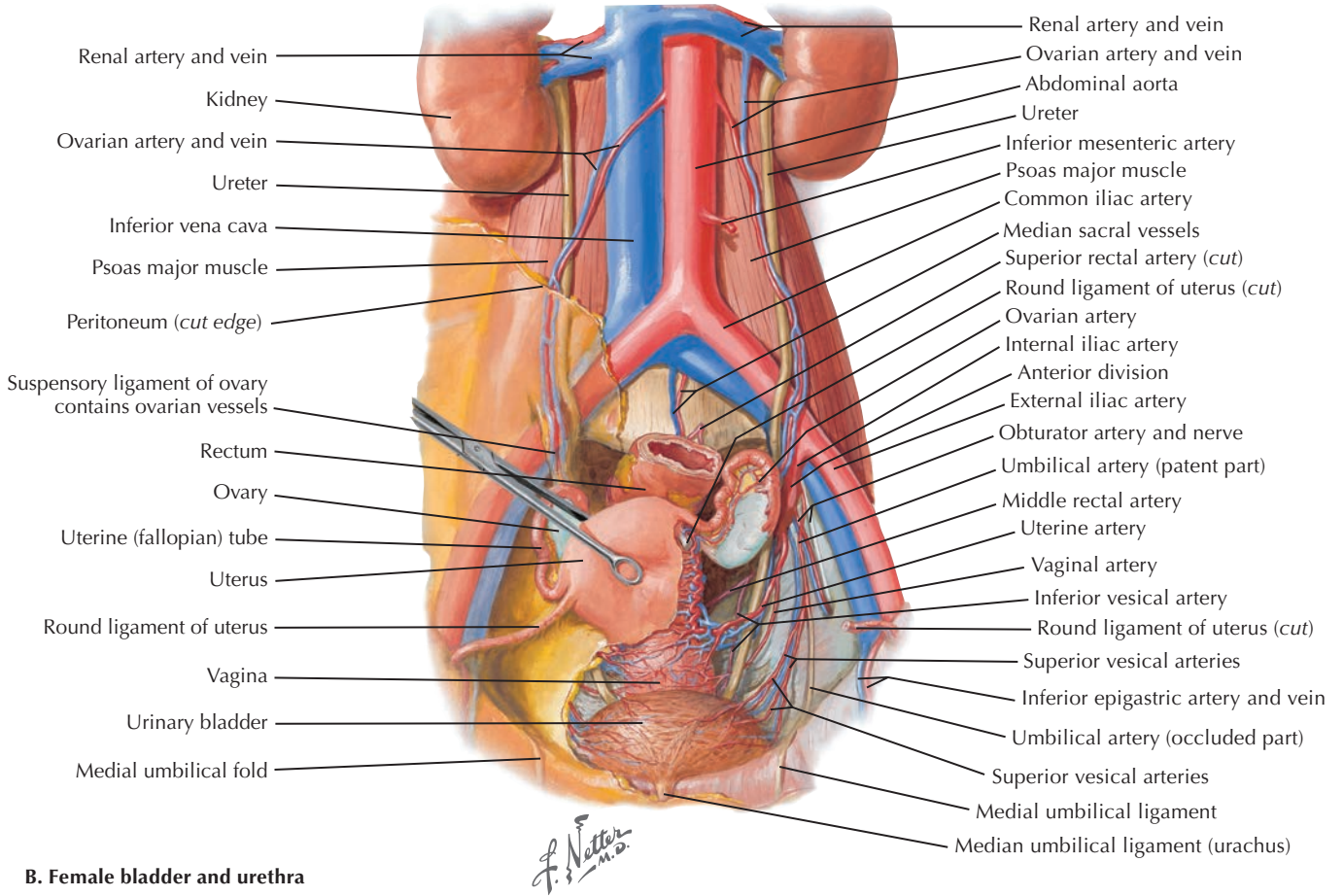
The authors' preference is to spare the anterior vaginal wall when the disease appears confined to the bladder or when cystectomy is being performed for benign disease. If vaginal sparing is not possible, on entering the vagina anteriorly, the surgeon can divide the lateral bladder pedicles en bloc with the anterior wall of the vagina, using thermal dissectors or suture ligation (Fig. 55-6, B). Staples and clips should be avoided in this situation because these objects may migrate into the vagina postoperatively.

The lateral pedicles with the remaining small, unnamed vessels can be ligated to the level of the endopelvic fascia.

Vagina-Sparing Technique

Alternatively, if the vagina is to be spared fully, or in cases of limited disease and previous hysterectomy, the space between the anterior vagina and the posterior bladder wall is developed, taking care to dissect closely to the anterior vaginal wall. If hysterectomy is required, a circumferential incision of the vagina close to the vaginal apex allows for removal of the cervix and uterus. Closure of the vagina depends on the method of urethrectomy described below (Fig. 55-6, B).

A. Arteries and veins of pelvic organs: female (anterior view)



B. Female bladder and urethra

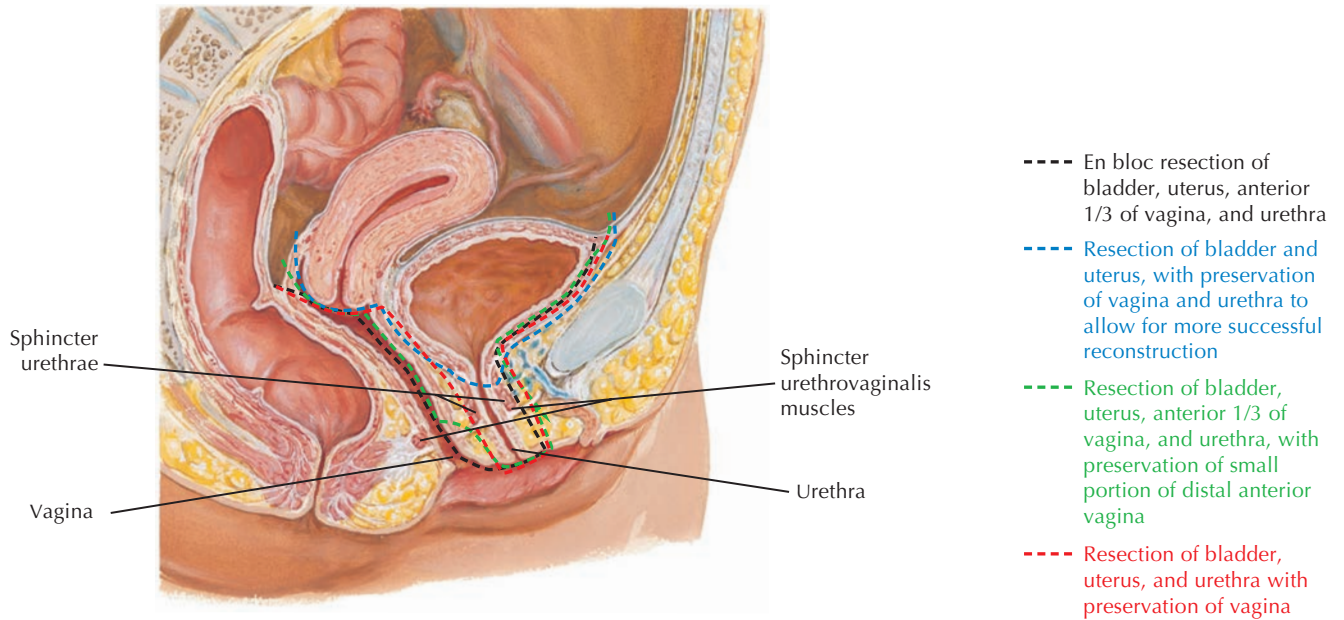


FIGURE 55-6 Female: vascular supply of pelvic organs and anterior exenteration resections.

URETHRECTOMY

Classically, a urethrectomy is performed in radical cystectomy. In the event that an orthotopic neobladder is planned, a frozen section of the urethra can be sent to confirm a negative margin, in which case the urethra can be left intact to aid in maintenance of continence with the neobladder. Otherwise, to perform a complete urethrectomy, the patient must be positioned to allow for access to the introitus.

The labia are retracted laterally to expose the urethra. If vagina-sparing techniques are not used, a U-shaped incision can be made from the top of the introitus surrounding the anterior vaginal wall and carried around the urethra (Fig. 55-7, A). Within the pelvis, the pubourethral suspensory ligaments, corresponding to the puboprostatic ligaments in men, are ligated to release the bladder and urethra. The dorsal vein complex superior to the urethra is isolated and ligated. Any other periurethral attachments are released circumferentially and passed in continuity through the vaginal incision in to the pelvis.

Alternatively, a circular incision can be made around the urethra. The portion of the anterior vagina below the bladder neck is left in the pelvis to support the reconstruction of the vagina. The urethra is sharply dissected off the anterior vaginal wall and, after ligation of all other periurethral attachments, passed in to the pelvis (see Fig. 55-6, B).

Vaginal Reconstruction

When the anterior wall of the vagina is removed, vaginal reconstruction is necessary. Classically, and the authors' preference, is to fold the posterior wall of the vagina toward the apex as a flap for coverage of the introital defect (Fig. 55-7, B). The reconstruction is completed with an absorbable suture, typically 2-0 Vicryl or its equivalent. This maneuver obligatorily shortens the vagina.

Alternatively, the lateral edges of the vagina can be approximated. Often this leads to a very narrow, nonfunctional vagina, and the suture line may be under tension. Preservation of the anterior vagina is recommended when considering construction of an orthotopic neobladder; overlapping suture lines between the vagina and neobladder may predispose to fistula formation.

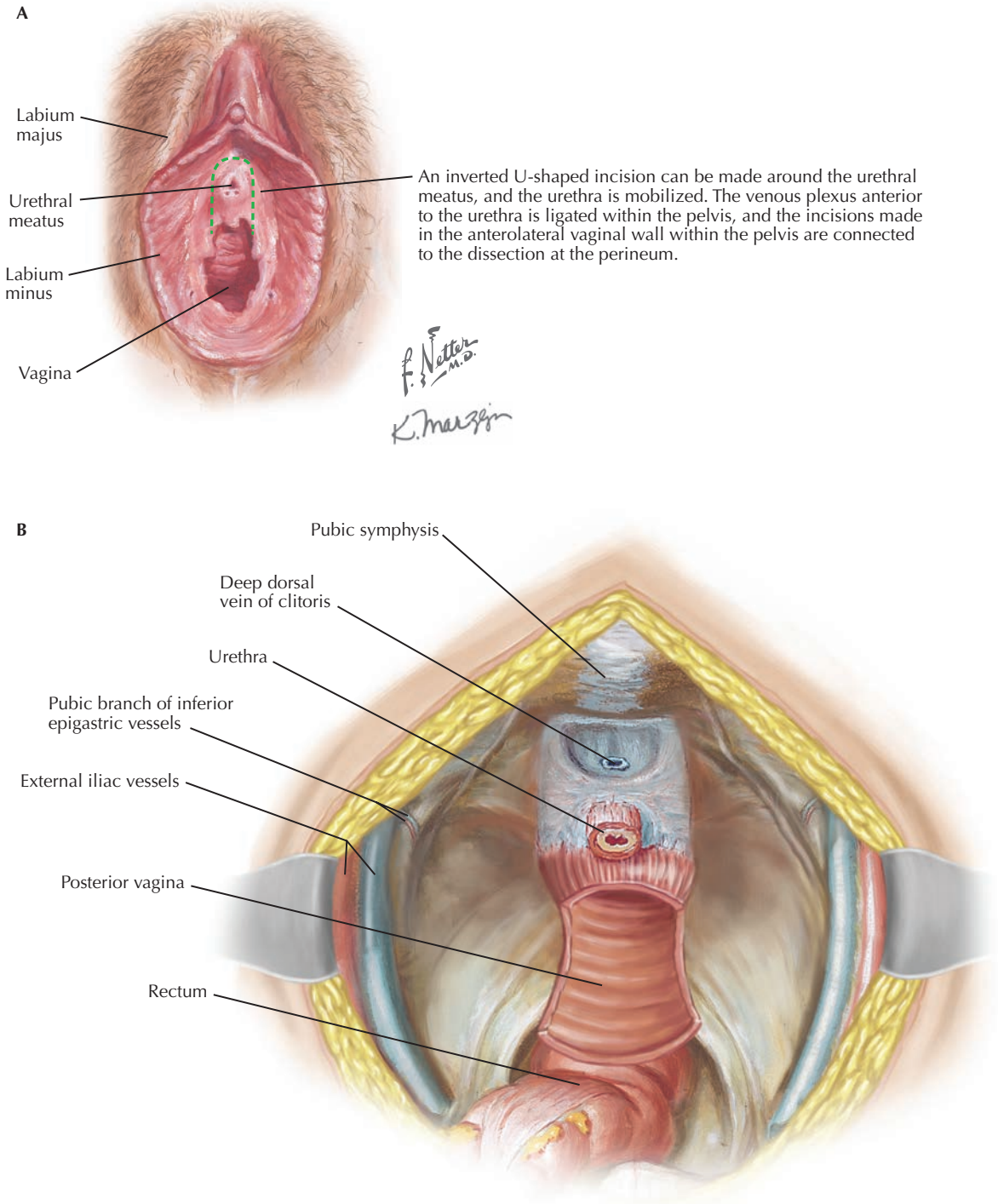


FIGURE 55-7 Urethra incision and resection.

SUGGESTED READINGS

- Chang SS. Radical cystectomy. In Smith J, Howards SS, Preminger GM, Hinman F, editors. *Hinman's atlas of urologic surgery*. Philadelphia: Saunders-Elsevier; 2012.
- Gakis G, Efstathiou J, Lerner SP, et al. Radical cystectomy and bladder preservation for muscle-invasive urothelial carcinoma of the bladder. ICUD-EAU International Consultation on Bladder Cancer. *Eur Urol* 2012.
- Ghonheim MA. Radical cystectomy in men. In Graham SD, Keane TE, editors. *Glenn's urologic surgery*. Philadelphia: Lippincott, Williams & Wilkins; 2009.
- Weizer AZ, Lee CT. Radical cystectomy in women. In Graham SD, Keane TE, editors. *Glenn's urologic surgery*. Philadelphia: Lippincott, Williams & Wilkins; 2009.

Index

A

Abdomen

- autonomic nerves and ganglia, 292f
 - innervation of, 377f
 - organ procurement exposures, 205f
 - posterior layer reconstruction, 382
 - right lower quadrant anatomy, 243f
 - upper, sagittal view, 173f
 - vasculature, 124f
- Abdominal aorta, 38f, 43f, 52f, 55f, 73f, 84f, 96f, 106f, 129f, 173f
- Abdominal aortic aneurysm
- aortic and iliac arterial relationships, 403f
 - aortic dissection, 404-406
 - exposure of midline retroperitoneum, 401f
 - iliac exposure, 402
 - incisional anatomy, 400
 - lateral approach to left iliac bifurcation, 402
 - left renal vein, 405f, 407f
 - lumbar spine and visceral vessels, 409f
 - midline abdominal approach, 399
 - renal vasculature, 406
 - ruptured, 410
 - special concerns, 408
 - surgical planning, 400
 - tube graft repair, 411f
- Abdominal cavity, free air in, 83f
- Abdominal dissection, in hysterectomy, 582
- Abdominal exposure, for retroperitoneal tumor removal, 572, 573f
- Abdominal organ donation
- dissection of portal triad structures, 206
 - incision for donor surgery, 204
 - kidney and pancreas procurement, 209f
 - organ procurement exposures, 205f
 - pancreaticoduodenal allograft, 208
 - suprahepatic aortic exposure, 207f
- Abdominal ostium, 579f
- Abdominal wall
- and anatomic landmarks in hernia repair, 347f
 - anatomy
 - for ostomy placement, 246-248
 - for ventral hernia open repair, 376
- anterior, and creation of retrorectus space, 381f

- Abdominal wall (*Continued*)
- aperture preparation, 249f
 - posterior, peritoneum of, 43f, 625f
 - and viscera, 281f
- Abdominoperineal resection
- indications for, 307
 - left colon mobilization, anatomic approach to, 310
 - perineal dissection, 317f
 - preoperative evaluation, 308
 - rectal dissection approach, 312-316, 313f
- Above-knee amputation, 464, 465f
- arteries and veins of leg, 461f
 - cross-sectional anatomy of thigh, 460f
 - fascial compartments of leg, 459f
 - indications for, 457
 - preoperative evaluation, 457
- Abscess
- Crohn-related, 338
 - intersphincteric, 327
 - perirectal
 - anatomic description, 328
 - deep postanal space, 333f
 - with fistula, 330
 - perineal innervation and patient positioning, 331f
 - sites of, 329f
 - surgical management, 330-332
- Accessory hemiazygos vein, 68f
- Accessory hepatic arteries, 131f, 156f, 167f, 190f
- Accessory hepatic ducts, 130f, 159f
- Accessory nerve (XI), 5f, 393f
- Accessory obturator vessels, 343f, 357f
- Acromion, 27f
- Acute cholecystitis, 132, 133f, 140
- Acute mesenteric ischemia, 413
- Adductor brevis muscle, 453f, 460f
- Adductor (Hunter's) canal, 447f
- Adductor longus muscle, 433f, 440, 452f
- Adductor magnus muscle, 447f, 453f, 455f, 460f
- Adductor magnus tendon, 453f
- Adductor pollicis muscle, 506f
- Adenocarcinoma
- gastric, 94
 - infiltrating esophagus, 53f
 - polypoid, 99f
- Adenoids, 537f
- Adenoma
- inferior parathyroid, 33f
 - intrathyroid parathyroid, 35f
- Adnexa, anatomy and dissection of, 588-592
- Adrenal artery, 39f

- Adrenal glands, 47f, 573f
- dissection, in radical nephrectomy, 604
 - histology of, 39f
 - and renal vessels, relationships, 605f
- Adrenal tumors, surgical interventions, 37
- Adrenal vein, 44f-45f
- Adrenalectomy
- left laparoscopic, 46
 - port site placement for, 41f
 - right laparoscopic, 42
 - transabdominal laparoscopic, 40
- Advancement flap, 336
- Airway anatomy for tracheal intubation
- flexible fiberoptic bronchoscopy, 536
 - laryngoscopy, 534, 535f
 - larynx, 528, 529f
 - lower airway, 530
 - nose and nasopharynx, 530
 - pharynx: sagittal section, 527f
 - preintubation airway examination, 532-534, 533f
 - sinus endoscopy, 537f
 - trachea, 531f
 - upper airway, 526-530
- Ala of sacrum, 235f
- Allen test, 478
- Allergic pharyngitis, 533f
- Allograft
- kidney, 209f
 - anatomic variations of, 211f
 - ureteral anastomosis of, 215f
 - vascular anastomoses of, 213f
- pancreas, 209f
- arterial reconstruction for, 217f
 - portal drainage of, 219f
 - pancreaticoduodenal, 208
- Ampulla of ductus deferens, 315f
- Ampullary stone, 133f, 145f
- Amputation
- above- and below-knee
 - arteries and veins of leg, 461f
 - cross-sectional anatomy of thigh, 460f
 - fascial compartments of leg, 459f
 - indications for, 457
 - postoperative care, 464
 - preoperative evaluation, 457
 - surgical principles, 458
- above-knee, 464, 465f
- below-knee, 462, 463f
- Amyand's hernia, 342, 345f
- Anal glands, 327
- Anastomosis
- AV, 422, 424
 - of celiac and superior mesenteric artery grafts, 417f

- Anastomosis (*Continued*)
 between common bile duct and
 duodenum, 151f
 ileocolic, 259f
 in left colectomy, 274
 in liver transplantation, 225f, 226, 227f
 patellar, 451f, 461f
 in right colectomy, 264
 in transverse colectomy, 284
 ureteral, of kidney allograft, 215f
 vascular
 of kidney allograft, 213f
 of pancreas allograft, 218
 vesicourethral, 618, 619f
- Anesthesia, for tracheal intubation, 534
- Aneurysm
 abdominal aortic. *See* Abdominal aortic
 aneurysm
 dissecting, of carotid artery, 391f
 popliteal artery, 456f
- Angioneurotic edema, of arytenoid region,
 533f
- Angle of His, 120, 121f
- Ankle, muscles, arteries, and nerves of,
 484f
- Anococcygeal ligament, 333f
- Anorectal fistula, 335f
- Anorectal junction, 303f
- Ansa cervicalis, 23f, 393f, 397f
- Ansa of Galen, 29f
- Ansa subclavia, 63f, 69f
- Anserine bursa, 453f
- Anterior cecal artery, 237f, 259f
- Anterior cecal vein, 190f, 291f
- Anterior compartment of leg, 459f
- Anterior deep cervical nodes, 5f
- Anterior facial vein, 5f
- Anterior inferior iliac spine, 435f, 453f
- Anterior intercostal arteries, 379f
- Anterior intermuscular septum, 459f
- Anterior jugular nodes, 5f
- Anterior jugular vein, 5f, 23f
- Anterior longitudinal ligament, 173f, 435f
- Anterior mediastinum, 63f
- Anterior pelvic exenteration
 bladder mobilization, 632
 vagina-sparing technique, 632
- Anterior sacral foramina, 435f
- Anterior sacrococcygeal ligament, 290f,
 303f
- Anterior sacroiliac ligament, 435f
- Anterior scalene muscle, 23f, 393f
- Anterior superficial cervical nodes, 5f
- Anterior superior iliac spine, 343f, 347f,
 357f, 433f, 435f, 437f, 452f-453f
- Anterior tibial artery, 451f, 461f
- Anterior tibial recurrent artery, 451f
- Anterior transperitoneal exposure, to
 visceral vessels, 416-418
- Anterior vagal trunk, 52f, 69f
- Anteromedial intermuscular septum, 433f,
 452f
- Anus, 289f
- Aorta, 45f, 73f
 clamping of, 522
 dissection of, 404-406
 relationships with
 colon, duodenum, and left renal vein,
 405f
 lumbar spine and visceral vessels, 409f
 retroperitoneal structures, 403f
 retroperitoneum and left renal vein,
 407f
 thoracic, 378f, 523f
- Aortic arch, 23f, 52f, 67f
 1st, 33f
- Aortic exposure from midline abdomen
 for aneurysm, 399
 ruptured, 410
 aortic and iliac arterial relationships,
 403f
 aortic dissection, 404-406
 aortobifemoral bypass, 410
 esophagus and thoracic aorta, 411f
 exposure of midline retroperitoneum,
 401f
 iliac exposure, 402
 incisional anatomy, 400
 lateral approach to left iliac bifurcation,
 402
 left renal vein, 405f, 407f
 lumbar spine and visceral vessels, 409f
 renal vasculature, 406
 special concerns, 408
 surgical planning, 400
- Aortic plexus, 88f
- Aorticorenal ganglia, 87f-88f, 292f
- Aortobifemoral bypass, 410
- Aortopofunda graft, 447f
- Apical axillary (subclavian) nodes, 543f
- Appendectomy
 laparoscopic approach, 238-240
 open approach, 240
 surgical principles
 exposure, 234
 operative anatomy, 236, 237f
- Appendicitis
 diagnosis and evaluation, 232
 retrocecal, 234
- Appendicular artery, 237f, 241f, 243f, 259f,
 281f, 291f
- Appendix
 cecal and appendicular arteries, variations
 in, 241f
 ileocecal region, 237f
 and iliac vessels, 242f
 inflamed, 243f
 in hernial sac, 342, 345f
 operative anatomy, 236, 237f
 right lower quadrant anatomy, 243f
 variations in position of, 239f
 vermiform, 235f, 237f, 239f
- Arc of Riolan, 263f, 268, 271f
- Arcuate artery, 484f
- Arcuate line, 301f, 343f, 357f, 379f, 383f,
 435f
- Areolar glands (of Montgomery), 551f
- Arteriae rectae, 259f, 269f, 281f, 291f, 311f
- Arterial line anatomy
 axillary artery, 480, 481f
 brachial artery, 480, 481f
 dorsalis pedis artery, 482
 femoral artery, 482
 in ICU setting, 477
 radial artery, 478
- Arterial reconstruction, for pancreas
 allograft, 217f
- Arterial supply
 abdominal wall, 376, 379f
 colon, 259f, 268
 duodenum, 103f, 189f, 193f, 207f
 esophagus, 67f
 knee, 451f
 large intestine, 269f, 283f, 311f
 leg, 461f
 liver, 158, 207f
 pancreas, 177f, 189f, 193f, 207f
 pelvis and rectum, 311f
 prostate, 617f
 spleen, 189f, 193f, 207f
 stomach, 55f, 84f, 87f, 96f, 103f, 124f,
 189f
- Arterial variations
 arteries of right colon, 262, 263f
 cecal and appendicular arteries, 241f
 hepatic arteries, 131f, 156f, 190f
 of large intestine, 271f
 renal artery, 211f
- Arteriovenous (AV) access for hemodialysis:
 upper extremity
 AV fistulas, 424, 425f
 cutaneous innervation of upper limb, 428,
 429f
 duplex ultrasound vein mapping, 423f
 factors for success, 421
 preoperative evaluation, 422
 prosthetic AV graft, 426, 427f
- Arteriovenous (AV) fistulas
 brachio basilic, 424
 brachiocephalic, 424
 radiocephalic, 424
- Articular surface of thyroid, 29f
- Aryepiglottic muscle, 29f
- Ascending cervical artery, 23f, 29f
- Ascending colon, 235f
 site of, 43f
- Atheroma, at carotid bifurcation, 391f
- Atherosclerosis of mesenteric vessels, 413,
 416
- Atonic stomach, 121f
- Atrophy, of left hepatic lobe, 160f
- Auricular wound repair, 519f
- Axillary artery, 379f, 511f
 cannulation, 480, 481f
- Axillary lymph node dissection, 562-564,
 565f
 creation of skin flaps, 564
- Axillary lymph nodes, 557f, 563f
- Axillary nerve, 429f
- Axillary vein, 427f, 511f
- Axillary vessels, 545f
- Axilloprofunda bypass graft, 447f
- Azygos vein, 68f, 173f, 221f, 511f
 arch of, 52f
 mediastinal system of veins, 61f
- B**
- Backbench preparation
 of kidney, 210
 of pancreas, 216
- Balloon, laparoscopic, in TEP procedure,
 365f
- Balloon catheters, in transcystic stone
 extraction, 146, 147f
- Base of pyramid, renal, 211f
- Basilic vein, 423f
- Basket retrieval of stones, from common bile
 duct, 147f
- Bassini repair, 352
- Below-knee amputation, 462, 463f
 arteries and veins of leg, 461f
 cross-sectional anatomy of thigh, 460f
 fascial compartments of leg, 459f
 indications for, 457
 preoperative evaluation, 457
- Below-knee anatomy, 488f
- Bicaval anastomosis, 225f
- Biceps brachii tendon, 481f
- Biceps femoris muscle, 455f, 460f
- Bicipital aponeurosis, 481f
- Bile leaks, 158
- Biliary cirrhosis, 161f
- Biliary colic, 132, 133f
- Biliary tree
 transcystic access to, 147f
 variations in, 158

- Billroth II gastrojejunostomy, 98, 99f
 Björk flap, 16
 Bleeding ulcer, duodenal
 principles of treatment, 102
 surgical approach, 104
 Body
 of gallbladder, 129f, 143f
 of mandible, 27f
 of T12 vertebra, 173f
 of uterus, 289f
 Boundaries
 anatomic, in carotid endarterectomy, 389
 of neck dissection levels I through III, 4
 Bowel elevation
 in end ostomy, 250
 in loop ostomy, 254
 Bowel eversion, to create spigot, 253f
 Bowel loop, entering hernial sac, 344f
 Bowel-to-dermis suture, 255f
 Brachial artery, 425f, 427f
 cannulation, 480, 481f
 Brachial plexus, 27f, 52f, 393f
 Brachioaxillary AV graft, 426, 427f
 Brachio basilic AV fistula, 424, 425f
 Brachiocephalic AV fistula, 424, 425f
 Brachiocephalic trunk, 23f, 29f, 52f, 67f, 509f
 Brachiocephalic veins, 23f, 52f, 61f, 68f
 Brachioradialis muscle, 481f
 Branchial cleft, 1st, 33f
 Breast cancer. *See also* Pathologic nipple discharge (PND)
 morbidity and survival, 541
 partial mastectomy, 542, 543f
 total mastectomy
 breast removal and reconstruction, 544
 modified radical, 544, 545f
 Breast cancer: SLNB, 553
 dye/radiotracer and injection sites, 554, 555f
 identification of sentinel lymph node, 558, 559f
 lesion drainage to lymph nodes, 556
 lymphatic drainage, 554
 Bronchi
 right and left, 52f
 superior lobar, 531f
 Bronchial artery, 67f
 Bronchoscopy, flexible fiberoptic, 536
 Brooke ileostomy, 253f
 Buccinator muscle, 533f
 Buccopharyngeal membrane, disintegrating, 33f
 Bulbospongiosus muscle, 580f
 Bulbourethral gland, 301f, 315f, 383f
- C**
- Calcaneal (Achilles) tendon, 455f
 Calcaneal tuberosity, 455f
 Calculus, in Hartmann's pouch, 133f
 Cancers
 breast. *See* Breast cancer
 esophageal, 51
 gastric, principles of treatment, 94
 pancreatic
 clinical features, 187f
 principles of treatment, 186
 prostate, radical prostatectomy for, 608
 urinary bladder, cystectomy for, 621
 Cancers: rectal
 anatomy
 for colonic mobilization and dissection, 288-296
 for preoperative imaging, 288
 Cancers: rectal (*Continued*)
 for rectal mobilization and dissection, 298-304
 endopelvic fascia and potential spaces, 290f
 history of management of, 287
 pelvic visceral and perineum, 289f
 surgical principles, 288
 Cannulation, radial artery, 478
 Capsular plexus, adrenal gland, 39f
 Capsule
 adrenal, 39f, 45f
 fibrous
 of spleen, 199f
 of thyroid gland, 29f
 joint, 453f
 Carcinomas
 clear cell, of ovary, 593f
 esophageal, 53f
 of gastric fundus, 99f
 of pancreatic tail adherent to spleen, 177f
 Cardiac massage, 520, 521f
 Cardiac nerves, 63f, 69f
 Cardiac notch, 73f, 75f, 95f, 115f
 Cardiac plexus, 63f, 69f
 Cardinal ligaments, 290f, 578
 Cardiorrhaphy, 519f
 Carotid arteries, 397f
 Carotid bifurcation
 arterial dissection, 394-396
 atherosclerotic obstruction at, 395f
 exposure, 392
 anatomic landmarks, 394
 mobilization, 396
 Carotid endarterectomy
 anatomic boundaries, 389
 anatomic landmarks, 394
 arterial dissection, 394-396
 arteriotomy and closure, 396
 carotid arteries, 395f
 carotid bifurcation, 396
 incision lines, 391f
 nerves and fascial layers of neck, 393f
 platysma muscle division, 390
 right external carotid artery branches, 397f
 surgical principles, 392
 Carotid sheath, 25f
 Carotid sinus nerve (of Hering), 397f
 Catheterization
 femoral vein, 474, 475f
 internal jugular vein, 470, 471f
 subclavian vein, 472, 473f
 venous, common details for, 470
 Catheters
 for drainage of perirectal abscess, 333f
 transarterial, 102
 Caudal pancreatic artery, 55f, 96f, 189f
 Cavocavostomy, side-to-side, 227f
 Cecal arteries, 241f
 Cecum, 235f
 variations in posterior peritoneal attachment of, 237f
 Celiac artery, 124f
 Celiac axis, 73f, 414, 415f
 Celiac ganglia, 87f, 173f, 233f, 292f
 Celiac nodes, 57f, 97f, 179f
 Celiac plexus, 87f, 233f
 branch of posterior vagal trunk to, 69f
 Celiac trunk, 38f, 52f, 77f, 88f, 96f, 106f, 129f, 175f, 207f, 263f, 407f
 Central line anatomy
 common details for venous catheterization, 470
 complications, 474
 femoral vein catheterization, 474
 internal jugular vein catheterization, 470
 Central line anatomy (*Continued*)
 subclavian vein catheterization, 472
 target vessel identification with ultrasound, 469
 Central tendon of diaphragm, 73f
 Central vein, 39f
 Cephalic vein, 425f, 427f, 517f
 thrombosis, 423f
 Cervical fascia
 investing layer of, 25f, 391f
 pretracheal layer of, 25f
 Cervical lymph nodes, 557f
 Cervical rootlets, 12f
 Cervical sympathetic trunk, 69f
 Cervicothoracic (stellate) ganglion, 63f, 69f
 Cervix of uterus, 289f-290f, 580f, 583f
 Chemoradiation, preoperative, 308
 Chest tube placement
 chest wall cross section, 511f
 indications for, 507
 landmarks for, 508-510, 513f
 left and right chest, 510
 lung topography, 511f
 nonurgent (elective) placement, 512
 semiurgent placement, 512
 superficial anatomy, 508-510
 thoracic anatomy, 509f
 urgent placement, 512
 Chest wall, cross section of, 511f
 Cholangiocatheter, 135f
 Cholangiogram, 136, 137f
 T-tube, 145f
 Cholecystectomy
 laparoscopic, 134-136
 open, 138
 Cholecystitis
 acute, 132, 133f, 140
 chronic, 145f
 Cholecystography, 137f
 Choledochoduodenostomy, 150, 151f
 Choledochojejunostomy, Roux-en-Y, 225f
 Choledocholithiasis, 145f
 Choledochotomy, 146, 149f
 Cholelithiasis, 133f, 134-136
 Chronic mesenteric ischemia, 413
 Circle of death, 360, 361f
 Circular esophageal muscle, 75f
 Circular muscle, vermiform appendix, 239f
 Circumflex scapular artery, 481f
 Cirrhosis
 Laennec's, 221f
 pathways of formation, 161f
 Cisterna chyli, 292f
 Clamping
 of aorta, 522
 of uterine vessels, in hysterectomy, 584
 Clamshell thoracotomy, 517f
 Clavicle, 17f, 25f, 27f, 391f, 473f
 Clear cell carcinoma of ovary, 593f
 Clear cells, 39f
 Clinical presentation
 of femoral hernia, 368
 of mesenteric ischemia, 413
 of pyloric stenosis, 110
 Closure of defects, during Roux-en-Y gastric bypass, 122
 Coccygeus muscle, 303f, 331f
 Coccyx, 303f, 435f
 Colectomy
 left
 anatomy for preoperative imaging, 266
 indications for, 265
 sigmoid and descending colon, 274
 splenic flexure, 272
 surface anatomy, incision, and port placement, 266

- Colectomy (*Continued*)
 surgical principles, 266
 upper mesorectal mobilization, 274
 vascular anatomy, 268
 right
 anastomosis, 264
 identification of ileocolic vessels, 260
 indications for, 257
 inferior dissection, 264
 medial to lateral approach, 260
 middle colic vessels, 262
 omentum and lesser sac, 262-264
 retroperitoneal structures, 261f
 superficial anatomy and topographic landmarks, 258
 transection of ileocolic vessels, 262
 variation in arteries of right colon, 262, 263f
- Colic impression
 hepatic, 223f
 splenic, 199f
- Colles' fascia, 331f
- Colloid, radiolabeled, 554, 560
- Colon
 anatomy for mobilization and dissection in TME, 288-296
 area for, 38f
 arterial supply, 259f
 left
 anatomic approach to mobilization, 310
 mobilization in radical nephrectomy, 600
 right, variations in vascular anatomy, 263f
 vascular supply, 269f, 291f
- Common bile duct, 43f, 55f, 84f, 96f, 106f, 137f, 157f, 167f
 end-to-end anastomosis, 225f
 gallstones in, 141
 hepatic duct joining, 130f
 laparoscopic exploration, 144-146
 obstructed by pancreatic cancer, 187f
 open exploration, 148, 149f
 in pancreaticoduodenectomy, 192, 193f
 stricture of, 139f
 transcystic approach, 146
- Common carotid artery, 15f, 27f, 29f, 52f, 67f, 397f
- Common facial vein, 5f, 393f, 394
- Common femoral artery, 433f
 accessing, 443f
 anatomy, 440
 avoidance of, 446, 447f
 exposure, 439
 major arterial branches, 444, 445f
 surgical principles
 incisions and closure, 442
 nerve and venous injury, 442
- Common femoral vein, 443f
- Common fibular (peroneal) nerve, 460f, 494f
- Common hepatic artery, 77f, 84f, 88f, 96f, 103f, 124f, 177f, 415f
- Common hepatic duct, 129f, 137f, 155f, 173f
 cystic duct adherent to, 130f
- Common iliac artery, 38f, 43f, 213f, 242f, 261f, 403f
- Common iliac vein, 205f, 235f
- Common iliac vessels, 445f
- Compact cells, 39f
- Compartment syndrome, 485
 forearm, 485
 clinical diagnosis and decision making, 502
 incisions for, 505f
- Compartment syndrome (*Continued*)
 leg
 circulatory pathophysiology, 493f
 clinical diagnosis and decision making, 492
 etiology, 490, 491f
 incisions for, 497f
- Complex fistula, 334, 336
- Complications
 catheter-related, 474
 of duodenal ulcers, 83f
 of splenectomy, sepsis, 198
- Computed tomography (CT)
 angiogram
 of abdominal aortic aneurysm, 409f
 of celiac axis and superior mesenteric artery, 415f
 of femoral hernia, 369f
 multiphase, in pancreatic cancer, 187f
 of periappendicular anatomy, 235f
 preoperative, for retroperitoneal sarcoma, 570, 571f
- Continuous longitudinal muscle, 239f
- Contrast studies, of pyloric stenosis, 112, 113f
- Cooper's ligament repair, 352
- Cormack and Lehane laryngeal grades, 535f
- Corona mortis, 360, 361f
- Coronary artery repair, 519f
- Coronary ligament of liver, 43f, 223f, 571f
- Coronary vein, 221f
- Corrugator cutis ani muscle, 321f
- Corset, 247f
- Corset constriction, hepatic, 160f
- Cortex, adrenal, 45f
- Cortical capillaries, 39f
- Costal cartilage, 7th, 173f
- Costal pleura, 52f
- Costodiaphragmatic recess of pleural cavity, 173f, 511f
- Cowper's gland, 301f, 315f, 383f
- Cremaster muscle, 343f-344f, 349f, 369f, 437f
- Cremasteric artery, 359f, 379f, 433f
- Cremasteric branch of inferior epigastric artery, 301f
- Cremasteric vessels, 347f
- Cribriform fascia, 567f
- over saphenous opening, 437f
- Cricoid cartilage, 15f, 17f, 23f, 25f, 35f
- Cricopharyngeus muscle, 29f
- Cricothyroid artery, 23f
- Cricothyroid ligament, 23f
- Cricothyroid membrane, 15f
- Cricothyroid muscle, 15f, 17f, 23f, 29f, 471f
- Critical view
 in laparoscopic cholecystectomy, 134
 in open cholecystectomy, 135f
- Crohn-related abscess and fistula, 338
- Crohn ulcer, 337f
- Crossmatching, immunologic, 205f
- Cruciate incision, in trachea, 15f
- Crura of diaphragm, 123f, 173f
 closure, and 360-degree fundoplication, 78, 79f
 in esophageal mobilization, 72
 in gastric mobilization, 76
 pillars of right crus, 73f
 in relation to truncal vagotomy, 91f
 right and left, 52f
- Crus of clitoris, 289f, 580f
- Crypts of Lieberkühn, 239f
- Cupula of pleura, 15f, 23f
- Curve tunnel, 447f
- Cutaneous innervation, of upper limb, 428, 429f
- Cystectomy, radical
 anterior pelvic exenteration
 bladder mobilization, 632
 vagina-sparing technique, 632
 indications for, 621
 pedicle dissection, 628
 pelvic lymphadenectomy, 626
 surgical approach
 bladder mobilization, 622
 dissection of ureters, 624
 urethral ligation, 630
 urethrectomy, vaginal reconstruction, 634
- Cystic artery, 55f, 84f, 96f, 129f, 135f
- Cystic duct, 55f, 84f, 129f, 173f, 193f
 variations in, 130f, 142, 143f, 159f
- Cystic node (of Calot), 57f, 179f
- Cystohepatic triangle (of Calot), 129f, 134
- D**
- Deep artery and vein of thigh, 460f
- Deep circumflex iliac vessels, 290f, 301f
- Deep dorsal vein
 of clitoris, 289f-290f, 303f, 635f
 of penis, 615f
- Deep dorsal venous plexus, division of, 616, 617f
- Deep external pudendal artery, 379f
- Deep external pudendal vessels, 440
- Deep fascia of leg, 459f
- Deep fibular (peroneal) nerve, 494f
- Deep inguinal lymph nodes, 440, 566
- Deep inguinal ring, 290f, 301f, 343f, 357f, 369f, 383f, 437f, 623f
- Deep postanal space, 332, 333f
- Deep posterior compartment of leg, 459f
- Deep transverse perineal muscle, 289f, 315f
- Dehydration, in hypertrophic pyloric stenosis, 111f
- Deltoid muscle, 25f, 27f, 473f
- Denonvilliers fascia, 301f, 303f, 315f, 610, 611f, 623f, 631f
- Dentate line, 305f, 321f
- Descending colon, 235f
 area for, 38f
 distal, brought through stoma, 251f
 in left colonic resection, 274
 site of, 43f
- Descending genicular artery, 445f, 451f
- Diagnosis
 of compartment syndrome
 forearm, 502
 leg, 492, 493f
 of pyloric stenosis, 110
- Diaphragm, 38f, 47f, 68f, 95f, 173f, 379f, 383f
 right and left crura, 52f, 72, 73f
 sternal part, 509f
 stomach distal to, 71f
 urogenital, 615f
- Diaphragmatic grooves, hepatic, 160f
- Diaphragmatic surface, of spleen, 199f
- Digastric muscle (anterior belly), 9f, 17f, 25f, 27f, 397f
- Digastric muscle (posterior belly), 11f, 17f, 25f, 27f
- Direct hernia space, 363f
- Direct inguinal hernia, 342
- Dissecting aneurysm, of carotid artery, 391f
- Distal pancreatectomy
 indications for, 171
 laparoscopic
 mobilization and dissection, 182
 trocar placement, 182

- Distal pancreatectomy (*Continued*)
 open retrograde, with splenectomy, 174-176, 175f
 preoperative evaluation, 172
 radical antegrade modular pancreatectomy, 178
 with splenic preservation, 180
- Distal rectum, 289f
- Donor surgery
 abdominal incision for, 204
 dissection of portal triad structures, 206
 goals of, 204
 kidney and pancreas procurement, 209f
 organ procurement exposures, 205f
 pancreaticoduodenal allograft, 208
 suprahepatic aortic exposure during, 207f
- Dorsal digital nerves and veins, 437f, 461f
- Dorsal nerve of penis, 331f
- Dorsal pancreatic artery, 55f, 77f, 84f, 96f, 103f, 177f, 189f, 263f
- Dorsal root ganglion, 88f, 235f, 377f
- Dorsal scapular artery, 393f
- Dorsal venous complex, 612, 613f
- Dorsalis pedis artery, 482, 484f
- Drainage
 of ischioanal abscess, 332
 of perirectal abscess, 333f
 setons, through fistula in ano, 334
- Duct anastomosis, in liver transplant, 226
- Duct excision for PND
 and intraductal papilloma, 551f
 management algorithm, 549f
 preoperative workup, 548
 surgical principles, 550
 technique, 550
- Ductoscopy, 549f
- Ductus deferens, 242f, 293f, 301f, 315f, 343f-344f, 347f, 357f, 359f, 383f, 433f, 623f
- Duodenal bulb, 103f
 deformed, 85f
- Duodenal fossae, 123f, 271f
- Duodenal/gastric anastomosis, 194
- Duodenal impression, hepatic, 223f
- Duodenal ulcers, 81, 85f
 bleeding
 principles of treatment, 102
 surgical approach, 104
 complications of, 83f
 in second portion of duodenum, 105f
- Duodenitis, 105f
- Duodenoenterostomy, 218
- Duodenojejunal flexure, 45f, 106f, 175f
- Duodenotomy, for bleeding ulcer, 104
- Duodenum, 43f, 45f, 73f, 121f, 175f, 242f, 261f, 405f
 anatomy, 271f
 anatomy of structures adjacent to, 106f
 descending part, 123f, 281f
 innervation, 88f
 pancreatic cancer invading, 187f
 superior part, 129f
- Duplex ultrasound, preoperative vessel mapping, 422, 423f
- Dye, for SLNB, 554, 560
- E**
- Ectopic parathyroid glands, 35f
- Edema, angioneurotic, 533f
- Ejaculatory duct, 315f
- Elastic ligation of internal hemorrhoids, 323f
- Emergency thoracotomy for trauma
 aortic clamping, 522
 cardiac massage, 520, 521f
- Emergency thoracotomy for trauma (*Continued*)
 clamshell and left anterolateral approaches, 517f
 control at hilum and injury repair, 520-522
 control of cardiac injury, 518
 deflation of left lung, 516
 indications for, 515
 lung mobilization, 518
 pericardiectomy and cardiorrhaphy, 519f
 pulmonary tractotomy, 523f
 surgical principles, 516
- End colostomy, 251f
- End ostomy
 elevation of bowel, 250
 maturing of, 252
- End-stage liver disease, 221f
- Endopelvic fascia, 613f
- Endorectal ultrasonography, 309f
- Endoscopic retrograde cholangiopancreatography (ERCP), 137f
- Endoscopy
 of bleeding duodenal ulcer, 102, 103f, 105f
 gastrointestinal, 85f
 of Nissen fundoplication, 80f
 sinus, 537f
- Endotracheal tube, 16, 18, 532, 534, 535f
- Enteric plexus, 89f
- Epiglottitis, 29f, 533f
- Epiploic veins, 68f
- Erector spinae muscle, 173f, 377f
- Esophageal hiatus, 73f, 75f
- Esophageal impression, hepatic, 223f
- Esophageal mobilization, anatomy for, 72-74
- Esophageal plexus, 52f, 68f-69f, 88f
- Esophageal sphincter, lower, 66
- Esophageal stricture, 53f
- Esophageal varices, 221f
- Esophageal veins, 190f
- Esophagectomy
 indications, 51
 Ivor Lewis approach, 58-59
 three-hole (modified McKeown), 60-62
 transhiatal, 54-56
- Esophagogastric junction, 79f
- Esophagus, 27f, 29f, 38f, 43f, 393f, 407f
 abdominal part, 52f, 73f, 95f, 121f
 arteries of, 67f
 cervical part, 52f
 congenital short, with herniation, 71f
 embryonic, 33f
 fundoplication created around, 78
 innervation of, 69f
 in relation to truncal vagotomy, 91f
 thoracic part, 52f, 411f
 veins of, 68f
- Eustachian tube, 537f
- Extensor digitorum longus muscle, 459f
- Extensor hallucis longus muscle, 459f
- Extensor hallucis longus tendon, 484f
- Extensor muscles, 501f
- External anal sphincter muscle, 289f, 305f, 321f, 333f
- External branch of superior laryngeal nerve, 28
- External carotid artery, 17f, 23f, 25f, 27f, 29f, 397f
- External hemorrhoidal plexus, 321f
- External hemorrhoids, 320
- External iliac artery, 43f, 215f, 235f, 261f, 359f, 442
 branches of, 445f
- External iliac lymph nodes, 567f
- External iliac vein, 205f, 359f
- External iliac vessels, 289f-290f, 301f, 347f, 357f, 359f, 433f, 435f, 635f
- External inguinal ring, 349f
- External intercostal muscle, 377f
- External jugular node, 5f
- External jugular vein, 5f, 9f, 11f, 23f, 61f, 68f, 391f, 393f
- External oblique muscle, 173f, 235f, 247f, 347f, 359f, 369f, 378f, 381f, 437f, 551f
 aponeurosis, 343f, 353f, 381f, 437f, 567f
- External pudendal vein, 445f
- External spermatic fascia, 344f, 347f
- External urethral orifice, 289f
- Extra-levator dissection, 314
- Extraction of kidney, 606
- Extrahepatic bile ducts, 129f
- Extramucosal pyloromyotomy (Ramstedt), 109, 112
- Extraperitoneal fascia, 344f, 381f
- Extraperitoneal plane, for mesh deployment, 385f
- Extrasphincteric fistula, 334, 335f
- F**
- Facial artery, 9f
 external maxillary, 5f
- Facial nerve (VII), 397f
 marginal mandibular branch, 8, 9f
- Facial vein, 9f
 ligated, 393f
- Failed tracheal intubation, 538
- Falciform ligament, 43f, 73f, 173f, 383f
- Falciform round ligaments, 190f
- Fallopian tube, 289f, 579f, 591f, 633f
- Fascia lata, 437f, 460f
- Fascia of deep perineal muscles, 303f
- Fascia over strap muscles, 5f
- Fascial compartments of leg, 459f, 487f
- Fascial layers of neck, 393f
- Fascial support of pelvic viscera, 580f
- Fasciotomy: forearm, 500-504
 compartment syndrome
 clinical diagnosis and decision making, 502
 incisions for, 505f
 surgical anatomy and technique, 504
 surgical principles, 504
 flexor and extensor muscles, 501f
 median and ulnar nerves, 506f
 nerves of upper limb, 503f
- Fasciotomy: leg, 486-498
 circulatory pathophysiology, 493f
 common fibular (peroneal) nerve, 494f
 compartment syndrome
 clinical diagnosis of, 492
 etiology of, 490, 491f
 incisions for, 497f
- cross-sectional anatomy, 488f-489f
 fascial compartments, 487f
 measurement of intracompartmental pressure, 495f
 muscles of leg with superficial peroneal nerve, 499f
 surgical anatomy and technique, 496-498
 surgical principles, 496
- Fatty septal cirrhosis, 161f
- Femoral artery, 357f, 379f, 447f, 461f
 cannulation, 482
 exposure, 434
- Femoral branch of genitofemoral nerve, 359f, 361f
- Femoral canal, 369f

- Femoral exposure
 anatomic landmarks for femoral incisions, 435f
 femoral anatomy, 432
 of femoral artery, 434
 saphenofemoral anatomy, 436
 of saphenofemoral junction, 436, 437f
 thigh muscles, 433f
- Femoral hernia repair
 anatomy, 368, 369f
 clinical presentation, 368
 diagnostic imaging, 368
- Femoral nerve, 235f, 351f, 357f, 361f, 383f, 440
- Femoral ring, 290f, 343f, 357f, 359f, 433f, 567f
- Femoral sheath, 301f, 359f, 432, 433f
- Femoral space, 363f
- Femoral triangle, 441f
- Femoral vein, 225f, 357f, 369f, 437f, 483f
 catheterization, 474, 475f
 injury to, 442
- Femoral vessels, 347f, 351f
- Femur, 460f
- Ferguson hemorrhoidectomy, 324
- Fibrin glue, on cut edge of liver, 169f
- Fibrous appendix of liver, 223f
- Fibrous capsule, splenic, 199f
- Fibrous loop for intermediate digastric tendon, 17f
- Fibula, 459f
 head of, 433f, 452f
- Fibular (peroneal) artery, 451f, 455f, 461f
- Fibularis brevis tendon, 455f, 484f
- Fibularis (peroneus) longus muscle, 459f
- Fibularis longus tendon, 455f
- First rib, 23f, 52f, 63f
- Fish-mouth incision, 465f
- Fistula
 in ano
 anatomic description, 334
 preoperative imaging and patient positioning, 334
 surgical management, 334-336
 arteriovenous, for hemodialysis, 422, 424
 Crohn-related, 338
 perianal abscess with, 330
- Fistula plug, 336
- Flap elevation, subplatysmal, 6, 7f
- Flexible fiberoptic bronchoscopy
 nasotracheal approach, 536
 oral approach, 536
- Flexor carpi radialis tendon, 479f
- Flexor carpi ulnaris tendon, 479f
- Flexor digitorum longus muscle, 459f
- Flexor digitorum longus tendon, 455f
- Flexor hallucis longus muscle, 459f
- Flexor hallucis longus tendon, 455f
- Flexor muscles, 247f, 501f
- Flexor retinaculum, 425f, 455f
- Flushing of donor organs, 204, 206
- Fold of Treves, 237f
- Foot, 484f
- Foramen cecum, 33f
- Forearm
 compartment syndrome, 485
 clinical diagnosis and decision making, 502
 incisions for, 505f
 cutaneous innervation of, 429f
 fasciotomy, 500-504
 surgical anatomy and technique, 504
 surgical principles, 504
 individual muscles of, 501f
 median and ulnar nerve in, 506f
 nerves of upper limb, 503f
- Forearm looped AV graft, 426, 427f
- Frenulum, 242f
- Fundoplication, 360-degree. *See* Nissen fundoplication
- Fundus
 of gallbladder, 129f, 143f
 of stomach, 47f, 73f, 95f, 120, 121f
 carcinoma of, 99f
 of uterus, 289f, 579f
- Fungating carcinoma, esophageal, 53f
- G**
- Gallbladder, 73f, 95f, 157f, 173f, 193f
 anatomy, 128
 hepatic ducts joining, 130f
 parts of, 129f, 143f
 removal and extraction of, 136
- Gallstone ileus, 132
- Gallstones
 in common bile duct, 141
 symptomatic, 132
- Gamma counter unit, 559f
- Gamma probe, 558
- Gastrectomy
 surgical approach, 94-98
 surgical trends, 93
- Gastric antrum, 115f, 117f
- Gastric artery, 55f, 77f, 84f, 88f, 124f, 129f, 411f, 415f
 attachment of, 43f
 esophageal branch of, 69f
- Gastric bypass, laparoscopic Roux-en-Y, 120-122, 123f
- Gastric cancer, principles of treatment, 94
- Gastric folds (rugae), 75f
- Gastric impression
 hepatic, 223f
 splenic, 199f
- Gastric mobilization, anatomy
 and retroesophageal space mobilization, 76
 short gastric vessels, 76
- Gastric nodes, 57f, 179f
- Gastric outlet syndrome, 132
- Gastric secretion, vagal control of, 89f
- Gastric ulcers, 81
 complications of, 83f
- Gastric veins, 61f, 68f, 190f, 201f, 221f
- Gastritis, with erosions, 85f, 103f
- Gastro-omental arteries, 55f, 77f, 84f, 87f, 96f, 103f, 177f, 207f
- Gastro-omental nodes, 97f
- Gastro-omental vein, 61f, 68f, 97f, 190f, 195f, 201f, 405f
- Gastro-omental vessels, 43f, 199f
- Gastrocnemius muscle, 453f, 455f, 459f
- Gastroduodenal artery, 55f, 77f, 84f, 88f, 96f, 102, 124f, 129f, 177f, 192
- Gastroepiploic artery, 55f, 77f, 88f, 96f, 103f, 177f, 189f, 207f
- Gastroesophageal junction, 71f
- Gastroesophageal reflux disease (GERD)
 anatomy for
 crural closure and 360-degree fundoplication, 78
 esophageal mobilization, 72-74
 gastric mobilization, 76
 preoperative studies, 70
 surgical principles, 66
- Gastropexy, 79f
- Gastrophrenic ligament, 38f, 43f, 281f
- Gastrosplenic ligament, 173f, 199f
- Geniohyoid muscle, 17f
- Genitofemoral nerve, 38f, 242f, 261f, 293f, 359f
 femoral branch, 349f, 433f
 genital branch, 343f, 357f, 361f, 377f
- Gerota's fascia, 45f, 46, 601f
- Gibson's incision, 212, 213f
- Glossopharyngeal nerve (IX), 397f
- Glottis, 533f
- Gluteus maximus muscle, 235f, 331f, 460f
- Gluteus medius muscle, 235f, 433f, 452f
- Gluteus minimus muscle, 235f
- Gonadal vein, 407f
- Gonadal vessels, 590
- Goodsall's rule, 335f
- Gracilis muscle, 433f, 440, 447f, 452f, 455f, 460f
- Gracilis tendon, 433f, 452f
- Grafts
 axilloprofunda bypass, 447f
 popliteal artery bypass, 456f
 prosthetic AV
 brachioaxillary graft, 426
 forearm looped graft, 426
 repair of abdominal aortic aneurysm, 411f
 superior mesenteric artery, 417f
- Gray rami communicantes, 292f, 378f
- Gray ramus, 233f, 292f
- Great auricular nerve, 5f, 9f, 11f, 393f
- Great saphenous vein, 369f, 437f, 440, 445f, 459f, 461f, 475f
- Great splanchnic nerve, 233f
- Greater omentum, 73f, 95f, 121f, 193f, 297f
 relationship to transverse colon and stomach, 280
- Greater pancreatic artery, 77f, 103f, 177f
- Greater sciatic foramen, 435f
- Greater splanchnic nerve, 69f
- Greater thoracic splanchnic nerve, 87f-88f, 292f
- Greater trochanter, 433f, 452f-453f
- Groin
 crease, inguinal ligament in relation to, 443f
 femoral anatomy, 432
 incision, in abdominal aortic aneurysm surgery, 400
 saphenofemoral anatomy, 436
 vascular anatomy, 351f
 wound closure, 442
- H**
- Hand
 compartment syndrome, 485
 incisions for, 505f
 cutaneous innervation of, 429f
- Hand-assisted approach, splenectomy, 200
- Hartmann's pouch, 129f, 133f, 143f
- Heart
 apex of, 511f, 521f
 injury, control of, 518
- Heineke-Mikulicz pyloroplasty, 104
- Hemiazygos vein, 61f, 68f
- Hemodialysis: upper extremity AV access
 AV fistulas, 424, 425f
 cutaneous innervation of upper limb, 428, 429f
 duplex ultrasound vein mapping, 423f
 factors for success, 421
 preoperative evaluation, 422
 prosthetic AV graft, 426, 427f
- Hemorrhoidectomy, operative, 324, 325f
- Hemorrhoidopexy, stapled, 324

- Hemorrhoids
 anatomy of, 319, 321f
 external, 321f
 internal, 321f
 office procedures for, 323f
 rubber band ligation, 322
 strangulated, 324, 325f
- Hemostat technique, 513f
- Hemothorax, chest tube placement, 513f
- Hepatectomy
 bile leaks and, 158
 cirrhosis, pathways of formation, 161f
 improved surgical outcomes, 153
 left hepatic lobectomy, 166-168, 167f, 169f
 MRI and surgical view, 157f
 parenchymal dissection, 164, 168
 right hepatic lobectomy, 162-164, 163f, 165f
 surgical principles, 154-158
 variations in
 cystic and hepatic ducts, 159f
 form of liver, 160f
- Hepatic arteries, 55f, 67f, 84f, 96f, 415f
 anastomosis, 225f, 227f
 variations in, 131f, 156f, 190f
- Hepatic ducts, 129f, 143f
 variations in, 130f
- Hepatic flexure, 73f, 106f, 121f, 175f, 279f
 mobilization, in transverse colectomy, 278
- Hepatic nodes, 57f, 179f
- Hepatic plexus, 87f
 vagal branch to, 69f
- Hepatic portal vein, 55f, 68f, 84f, 96f, 106f, 157f, 179f, 195f, 201f
 division of, 224
 tributaries, 191f
- Hepatic veins, 52f, 61f, 68f, 97f, 169f, 205f
- Hepatoduodenal ligament, 73f, 95f, 115f
 arterial anatomy, 193f
- Hepatogastric ligament, 73f, 95f, 115f
- Hepatopancreatic ampulla (of Vater), 129f
- Hepatorenal recess (Morison's pouch), 173f
- Hernial sac, 344f
 dissected from femoral defect, 371f
 identification of, 348
 inflamed appendix in, 345f
 isolation and ligation of, 349f
 reduction of, 360
 through femoral ring, 369f
- Hernias
 femoral
 anatomy of, 369f
 clinical presentation, 368
 laparoscopic surgical repair, 372, 373f
 open surgical repair, 370-372, 371f
 inguinal. *See* Inguinal hernia
 ventral. *See* Ventral hernia open repair
- Herniation, potential sites of, 124f
- Hesselbach's triangle, 301f, 342, 343f, 360
- Hiatal hernia, sliding, 70, 71f
- High ligation of inferior mesenteric artery, 266
- Highly selective vagotomy
 decision making regarding, 86
 surgical approach, 90
- Hilum
 pulmonary, control of, 520-522
 renal, 211f
 dissection of, 604
 splenic, 199f
- Hip joint ligaments, 433f, 452f-453f
- Horseshoe abscess, 332
- Hot lymph node, 558, 559f
- Hydrochloric acid, 89f
- Hypoglossus muscle, 17f, 27f
- Hyoid bone, 5f, 11f, 17f, 25f, 29f, 397f, 471f
- Hyperplasia, parathyroid, 34
- Hypertonic stomach, 121f
- Hypertrophic pyloric stenosis, 111f
- Hypogastric nerves, 292f, 313f, 615f
- Hypogastric plexus, 233f
- Hypogastric sheath, 290f
- Hypoglossal nerve (XII), 9f, 394, 397f
- Hypothenar muscles, 506f
- Hypotonic stomach, 121f
- Hysterectomy
 abdominal dissection, 582
 arteries and veins of pelvic organs, 581f
 clamping and mobilization, 584
 isolation of round and infundibulopelvic ligaments, 583f
 ligamentous and fascial support of pelvic viscera, 580f
 ovarian preservation, 584
 pelvic cross section with peritoneum removed, 585f
 specimen removal and closure, 584
 surgical anatomy
 cardinal and uterosacral ligaments, 578
 round and broad ligaments, 578
 vascular landmarks and ureteral injury, 578
 surgical approach, 582
 uterus, ovaries, and uterine tubes, 579f
- I
- Ileal artery, 281f
- Ileocecal region, 237f
 and iliac vessels, 242f
- Ileocolic artery, 237f, 259f, 261f
- Ileocolic vein, 190f
- Ileocolic vessels
 identification of, 260
 transection of, 262
- Ileopubic tract, 358
- Ileostomy
 anatomic landmarks and surgical technique, 249f
 Brooke technique, 253f
- Ileum, 235f
 division of, 253f
 terminal part, 237f, 242f-243f
- Ileus, gallstone, 132
- Iliac crest, 38f, 435f, 475f
- Iliac fascia, 290f, 359f, 433f
- Iliac fossa, 435f
- Iliac vessels, 242f-243f
- Iliacus muscle, 38f, 235f, 290f, 343f, 357f, 361f, 433f, 452f
- Iliococcygeus muscle, 303f
- Iliohypogastric nerve, 38f, 348, 349f, 377f
- Ilioinguinal nerve, 38f, 347f, 348, 349f, 377f, 461f
- Iliolumbar artery, 213f, 403f
- Iliolumbar ligament, 435f
- Iliopectineal line, 435f
- Iliopsoas muscle, 359f, 383f, 433f, 447f, 452f-453f, 460f, 475f
- Iliopubic eminence, 435f
- Iliopubic tract, 290f, 343f, 357f, 361f
- Iliotibial tract, 433f, 452f, 455f, 460f
- Incarcerated hemorrhoids, 324, 325f
- Incarcerated inguinal hernia, 342, 345f
- Incision planning
 for carotid endarterectomy, 391f
 for choledochoduodenostomy, 151f
 for compartment syndrome of forearm and hand, 505f
 of leg, 497f
- Incision planning (*Continued*)
 for neck dissection, 6
 for partial mastectomy, 542, 543f
 for retroperitoneal sarcoma, 570
 for SLNB, 556
- Indirect hernia space, 363f
- Indirect inguinal hernia, 342
- Inferior anal nerve, 331f
- Inferior approach, to right colectomy, 264
- Inferior deep lateral cervical node, 5f
- Inferior duodenal fossa, 401f
- Inferior epigastric artery, 213f, 290f, 361f, 379f, 403f, 445f
- Inferior epigastric vein, 205f
- Inferior epigastric vessels, 301f, 343f, 347f, 359f, 383f, 435f
- Inferior ganglion of vagus nerve, 69f
- Inferior gluteal vein, 445f
- Inferior laryngeal nerve, 29f
- Inferior lateral genicular artery, 451f
- Inferior mediastinum, 63f
- Inferior mesenteric artery, 38f, 123f, 233f, 266, 268, 295f, 403f, 405f
 anterior view in TME, 294
 medial oblique view in TME, 294
- Inferior mesenteric ganglion, 233f
- Inferior mesenteric plexus, 233f
- Inferior mesenteric vein, 57f, 68f, 97f, 123f, 175f, 201f, 205f, 268, 273f, 311f, 407f
 anterior view in TME, 294
 medial oblique view in TME, 296
- Inferior pancreatic artery, 77f, 103f, 177f
- Inferior parathyroid gland, 29f, 32
 adenoma of, 33f
- Inferior pharyngeal constrictor muscle, 27f, 29f
- Inferior phrenic artery, 43f, 46, 55f, 67f, 77f, 84f, 96f, 189f, 281f, 411f
- Inferior phrenic plexus, 87f
- Inferior phrenic vein, 46, 68f, 205f
- Inferior polar artery, 55f, 96f
- Inferior (arcuate) pubic ligament, 290f, 303f
- Inferior pulmonary ligament, incision of, 521f
- Inferior pulmonary vein, 521f
- Inferior rectal artery, 269f, 311f
- Inferior rectal veins, 190f
- Inferior suprarenal artery, 45f
- Inferior thyroid artery, 23f, 27f, 67f
 anatomy for ligation of, 30
- Inferior thyroid veins, 23f, 27f, 68f
- Inferior vena cava, 38f, 61f, 68f, 97f, 106f, 115f, 155f, 173f, 195f, 208, 407f
- Inferior vesical artery, 242f, 261f, 290f, 293f, 403f, 617f, 633f
- Infradiaphragmatic fascia, 75f
- Infrahepatic vena cava anastomosis, 225f
- Infrayoid artery, 23f
- Infrayoid muscles, fascia of, 25f
- Inframammary lymph nodes, 543f
- Infrarenal aorta, 405f
- Infundibulopelvic ligaments, 583f, 590
- Infundibulum, 129f, 143f
- Inguinal canal, 433f
- Inguinal falx (conjunct tendon), 301f, 343f, 353f, 369f, 383f, 437f
- Inguinal hernia
 Amyand's, 345f
 incarcerated, 345f
 indirect, 344f
 strangulated, 345f
- Inguinal hernia laparoscopic repair
 benefits of, 355
 inguinal region, 359f
 key anatomic concepts
 inguinal geometry, 360
 inguinal ligament vs. ileopubic tract, 358

- Inguinal hernia laparoscopic repair
(*Continued*)
myopectineal orifice, 356, 357f
pectineal ligament, 358
landmarks: warning triangles and corona mortis, 361f
principles of, 360
totally extraperitoneal approach, 356, 364, 365f
transabdominal preperitoneal approach, 356, 362-364, 363f
- Inguinal hernia open repair
anatomic landmarks, 346, 347f
Bassini repair, 353f
exposed anatomy for, 349f
ilioinguinal and iliohypogastric nerves, 348
McVay repair, 353f
primary tissue repair, 352
surgical approach, 346-348
tension-free repair, 350, 351f
terminology, 342
- Inguinal ligament, 357f, 359f, 433f, 443f, 447f, 452f
- Inguinal (Poupart's) ligament, 303f, 343f, 353f, 358, 359f, 369f, 437f, 440, 441f
- Inguinal lymph nodes, 557f
dissection, 566, 567f
- Inguinal region, 343f, 359f, 435f, 437f, 475f
- Inguinal triangle (Hesselbach's), 301f, 342, 343f, 357f, 360, 383f
- Injection
of incarcerated hemorrhoids, 325f
of internal hemorrhoids, 323f
sites
intra-arterial, 481f, 483f
for SLNB, 554
- Innervation
of abdomen, 292f, 377f
of abdominal wall, 376
of ankle and foot, 484f
cutaneous, of upper limb, 428, 429f
of duodenum, 88f
of esophagus, 69f
of intestine, 233f
of leg, 461f
of oral and pharyngeal regions, 397f
of pelvis and rectum, 311f
perianal, 331f
of small and large intestine, 270f, 629f
of stomach, 86, 87f-88f
of upper limb, 503f
of wrist, 479f
- Insertion site for chest tube, 509f, 513f
- Inspiration, normal larynx, 529f
- Intercalated node, 5f
- Interchondral space, third, 511f
- Intercostal muscles, 173f, 379f, 473f
- Intercostal nerves, 173f
and arteries, course and relations of, 378f
third, 69f
- Intercostal space, 4th and 5th, 521f
- Intercostal vessels, 173f
- Intercostobrachial nerve, 565f
- Intercrural fibers, 347f, 437f
- Interfoveolar ligament, 301f, 383f
- Intermediate antebrachial vein, 425f
- Intermediate digastric tendon, fibrous loop for, 25f
- Intermediate hepatic artery, 129f
- Intermesenteric defect, 124f
- Intermesenteric plexus, 292f
- Internal anal sphincter, 305f, 333f
- Internal branch of superior laryngeal nerve, 29f
- Internal carotid artery, 23f, 29f, 33f, 394, 397f
- Internal hemorrhoidal plexus, 321f
- Internal hemorrhoids, 320
office procedures for, 323f
surgical management, 325f
- Internal iliac artery, 38f, 213f, 215f, 235f, 242f, 259f, 281f, 403f
- Internal iliac vein, 205f
- Internal iliac vessels, 290f
- Internal inguinal ring, 359f
- Internal intercostal muscle, 377f
- Internal jugular nodes, 5f, 61f
- Internal jugular vein, 12f, 17f, 23f, 27f, 52f, 61f, 68f, 393f
catheterization, 470, 471f
- Internal oblique muscle, 235f, 343f, 353f, 359f, 369f, 381f, 437f
aponeurosis of, 247f
- Internal pudendal artery, 403f
- Internal pudendal vein, 269f
- Internal spermatic fascia, 344f
- Internal thoracic artery, 52f, 67f, 378f-379f
- Interosseous membrane, 451f, 459f
- Interpectoral (Rotter's) nodes, 543f, 545f
- Intersigmoid recess, 293f, 403f
- Intersphincteric abscess, 327, 329f, 330
- Intersphincteric fistula, 334, 335f
- Intersphincteric transanal transection of rectum, 305f
- Intervertebral foramen, 235f
- Intestine
autonomic innervation, 233f, 270f
large
arteries of, 269f, 283f, 311f
innervation of, 270f, 629f
vascular variations of, 271f
veins of, 269f
small, 235f, 409f
area for, 38f
innervation of, 270f, 629f
- Intra-arterial injection sites, 481f, 483f
- Intracompartmental pressure measurement, leg, 495f
- Intraductal papilloma, 551f
- Intrahepatic stones, 145f
- Intramural reflex, 89f
- Intraoperative parathyroid hormone (IOPH), 30, 34
- Intraoperative ultrasound
in cholecystectomy, 137f
of gallbladder, 136
- Intubation: tracheal
airway anatomy
larynx, 528, 529f
lower airway, 530
nose and nasopharynx, 530
pharynx: sagittal section, 527f
trachea, 531f
upper airway, 526-528
anesthesia, 534
failed, 538
flexible fiberoptic bronchoscopy
nasotracheal approach, 536
oral approach, 536
indications for, 532, 533f
laryngoscopy, 534, 535f
preintubation airway examination, 532-534
sinus endoscopy, 537f
- Ischial spine, 303f, 331f, 435f
- Ischioanal fossa, anterior recess of, 301f, 383f
- Ischiococcygeus muscle, 331f
- Ischiopubic ramus, 315f
- Ischiorectal abscess, 328, 329f, 330, 332
- Isthmus of thyroid gland, 15f, 16
- Ivor Lewis esophagectomy, 58-59
- J**
- Jejunal arteries, 55f, 96f, 189f, 269f, 281f, 291f
- Jejunum, 121f, 123f, 175f
- Joint capsule, 453f
- Jugular notch, 25f, 391f, 509f
- Jugular trunk, 5f
- Jugulo-omohyoid node, 5f
- Jugulodigastric node, 5f
- Juxtaesophageal nodes, 61f
- K**
- Kidney transplantation
allograft
anatomic variations of, 211f
ureteral anastomosis of, 215f
vascular anastomoses of, 213f
backbenching, 210
entering peritoneum, 212
ureteroneocystostomy, 214
- Kidneys, 38f, 45f, 95f, 106f, 175f, 242f, 261f
allograft, 209f
anatomic relations of, 603f
gross structure of, 211f
lateral attachments, division of, 606
lymph vessels and nodes of, 627f
retroperitoneal, 73f
- Knee
above- and below-knee amputation
above-knee, 464, 465f
arteries and veins of leg, 461f
below-knee, 462, 463f
cross-sectional anatomy of thigh, 460f
fascial compartments of leg, 459f
postoperative care, 464
preoperative evaluation, 457
surgical principles, 458
arteries of, 451f
muscles of, 453f
- Kocher maneuver, 104, 149f, 150, 188, 206
- L**
- Labial form of ileal orifice, 242f
- Labium majus, 289f, 635f
- Labium minus, 289f, 635f
- Lactiferous ducts, 551f
- Lacunar ligament (Gimbernat's), 301f, 343f, 351f, 357f, 359f, 383f, 433f, 440
- Laennec's cirrhosis, 161f, 221f
- Landmarks
anatomic
for femoral incisions, 435f
in inguinal hernia repair, 347f
for carotid bifurcation exposure, 394
external, for ostomy location, 248, 249f
identifying inguinal ligament, 346
for thyroidectomy, 24, 25f
topographic
for chest tube placement, 508-510, 513f
for right colectomy, 258
vascular, for hysterectomy, 578
- Laparoscopic approach
appendectomy, 238-240
principles of exposure, 234
cholecystectomy
critical view, 134
positioning and trocar placement, 134

- Laparoscopic approach (*Continued*)
 common bile duct exploration, 144-146
 transcystic approach, 146
 transductal/choledochotomy approach, 146
 distal pancreatectomy, 182
 femoral hernia repair, 372, 373f
 left colectomy, 266
 pyloromyotomy for pyloric stenosis, 116, 117f
 Roux-en-Y
 and ligament of Treitz, 123f
 surgical anatomy, 120-122
 surgical criteria, 120
 splenectomy, 200
 TME, oblique view of retroperitoneum, 295f
 transperitoneal radical nephrectomy
 dissection procedures, 602-606
 extraction, 606
 mobilization of left colon, 600
 surgical approach, 598
- Laparoscopic inguinal hernia repair
 benefits of, 355
 inguinal region, 359f
 key anatomic concepts
 inguinal geometry, 360
 inguinal ligament vs. ileopubic tract, 358
 myopectineal orifice, 356, 357f
 pectineal ligament, 358
 landmarks: warning triangles and corona mortis, 361f
 principles of, 360
 totally extraperitoneal approach, 356, 364, 365f
 transabdominal preperitoneal approach, 356, 362-364, 363f
- Laparoscopic ports
 in adrenalectomy, 40, 41f
 five-port placement, in Ivor Lewis esophagectomy, 59f
 placement
 in bile duct exploration, 145f
 for distal pancreatectomy, 183f
 for left colectomy, 266, 267f
- Laparoscopic stapler, 303f
 Laparotomy pad, 249f
 Large intestine
 arteries of, 269f, 283f, 311f
 innervation of, 270f, 629f
 vascular variations of, 271f
- Laryngeal grades, Cormack and Lehane, 535f
 Laryngoscopy, 534, 535f
 Larynx, 528, 529f
 epithelium of, 33f
 nerves of, 29f
- Lateral antebrachial cutaneous nerve, 425f, 429f
 Lateral arcuate ligament, 73f
 Lateral compartment of leg, 459f
 Lateral cricoarytenoid muscle, 29f
 Lateral cutaneous nerve of thigh, 460f
 Lateral femoral cutaneous nerve, 38f, 359f, 361f, 433f, 437f
 Lateral malleolus, 455f, 484f
 Lateral patellar retinaculum, 433f
 Lateral pubovesical ligament, 290f
 Lateral sacral artery, 213f, 403f
 Lateral sural cutaneous nerve, 455f, 459f
 Lateral thyroid lobe, 33f
 Lateral umbilical fold, 43f
 Lateral umbilical ligament, 235f
 Latissimus dorsi muscle, 377f, 509f, 545f
 Least splanchnic nerve, 233f
- Left anterolateral thoracotomy, 517f
 Left colectomy
 anatomy for preoperative imaging, 266
 indications for, 265
 sigmoid and descending colon, 274
 splenic flexure, 272
 surface anatomy, incision, and port placement, 266
 surgical principles, 266
 upper mesorectal mobilization, 274
 vascular anatomy, 268
- Left colic artery, 259f, 295f
 Left colic flexure, 45f, 73f, 95f, 175f, 193f, 271f, 297f, 401f
 Left colic vein, 190f, 269f, 405f
 Left colon mobilization, 310
 in radical nephrectomy, 600
- Left common iliac bifurcation, 402
 Left hepatic lobectomy, 166-168
 Left inferior epigastric artery and vein, 235f
 Left laparoscopic adrenalectomy
 port site placement, 41f
 surgical technique, 46
- Left ventricle, 511f
 pledged repair of, 519f
- Leg
 arteries and veins, 461f
 common fibular (peroneal) nerve, 494f
 compartment syndrome, 485
 clinical diagnosis and decision making, 492, 493f
 etiology, 490, 491f
 incisions for, 497f
 cross-sectional anatomy
 below knee, 488f
 middle and lower tibia, 489f
 fascial compartments of, 459f, 487f
 fasciotomy, 486-498
 surgical anatomy and technique, 496-498
 surgical principles, 496
 measurement of intracompartmental pressure, 495f
 muscles of, 455f
 with superficial peroneal nerve, 499f
- Lesser occipital nerve, 393f
 Lesser omentum, 43f, 73f, 87f, 95f, 115f, 121f, 129f, 173f, 175f, 409f
- Lesser sac
 laparoscopic view, 273f
 in right colectomy, 262-264
- Lesser sciatic foramen, 435f
 Lesser splanchnic nerve, 233f
 Lesser thoracic splanchnic nerve, 88f, 292f
 Levator ani muscle, 190f, 281f, 289f, 305f, 331f, 383f
 Levator scapulae muscle, 27f, 393f
 Levators, divided, 317f
 Level Ia-Ib neck dissection, 8
 Level II-III neck dissection, 10
 Lichtenstein repair, 346
 Lienorenal ligament, 199f, 281f
 Ligament of Treitz, 73f, 122, 123f, 271f
 Ligamentous support of pelvic viscera, 580f
 Ligamentum teres of liver, 223f
 Ligamentum venosum, fissure for, 223f
 Ligation of intersphincteric fistula tract (LIFT), 336
 Linea alba, 173f, 235f, 247f, 343f, 381f, 437f
 reconstruction of, 384
 in ventral hernia repair, 376
 Linea semilunaris, 385f
 Linea terminalis of pelvis, 290f, 435f
 Lingual artery, 397f
 Lingual nerve, 9f
- Littre's hernia, 342
 Liver, 68f
 anatomy, 223f
 variations in, 154, 160f
 area for bare area of, 38f
 coronary ligament of, 43f
 distribution of vessels and ducts, 155f
 inferior border, 95f
 resection. *See* Hepatectomy
- Liver transplantation
 anastomoses in, 226, 227f
 for end-stage liver disease, 221f
 incision, exposure goals for, 222
 indications for, 220
 postoperative surveillance, 220
 retrohepatic dissection, 224
 Roux-en-Y choledochojejunostomy, 225f
- Lobectomy
 left hepatic, 166-168, 167f, 169f
 right hepatic, 162-164, 163f, 165f
- Lobes of liver, 73f, 95f, 115f, 121f, 155f, 193f, 223f
 caudate, 281f
 variations in, 158, 160f
- Lobes of thyroid gland, 23f, 26, 27f, 29f
 Long thoracic nerve, 565f
 Longitudinal esophageal muscle, 75f, 121f
 Longus capitis muscle, 27f, 533f
 Longus colli muscle, 52f
 Loop-end ileostomy, 255f
 Loop ostomy, 254
- Lower airway anatomy for tracheal intubation
 bronchial divisions, 530
 preintubation airway examination, 532-534, 533f
 trachea, 530, 531f
- Lower anterior mesorectal dissection, 301f
 Lower deep cervical group of nodes, 5f
 Lower esophageal sphincter, 66
 Lower limb, veins and nerves of, 437f
 Lower mesorectum, anterior mesorectal anatomy, 300
- Lumbar spine, aortic relationship with, 409f
 Lumbar sympathetic ganglion, 1st, 233f
 Lumbar veins, 205f, 407f
 Lumbar vertebrae, 3rd and 4th, 73f
 Lumbosacral trunk, 235f
 Lumbrical muscles, 479f
 Lung bud, 33f
- Lungs
 left
 deflation in thoracotomy, 516
 mobilization of, 518
 topography of, 511f
- Lymph nodes. *See also* Sentinel lymph node biopsy (SLNB)
 of breast, 543f
 esophageal, 61f
 femoral, 440
 in femoral canal (Cloquet's), 359f, 433f
 of inguinal region, 441f
 of kidneys and bladder, 627f
 lesion drainage to, 556
 mammary gland, 563f
 in neck, 5f
 pancreatic, 57f
 pancreatic carcinoma metastatic to, 177f
 perirectal, tumor involvement of, 309f
 regional, metastasis, 553
- Lymphadenectomy
 axillary, 562-564, 565f
 in gastrectomy, 98
 inguinal, 566, 567f
 levels I-III, 12f
 pelvic, 626

Lymphatic drainage
 and choosing dye/radiotracer injection site, 554
 of pancreas, 179f
 of stomach, 97f
 Lymphoid nodules, aggregate, 239f

M

Mackenrodt's ligament, 290f
 Magnetic resonance imaging (MRI)
 hepatic artery, 157f
 pelvic, 308
 Maloney dilator, 79f
 Mammary gland lymph nodes, 563f
 Mandible, 5f, 27f
 Mandibular nodes, 5f
 Manometric tracing, showing tachyoddia, 139f
 Marginal artery, 259f, 269f, 281f
 Marginal mandibular branch of facial nerve, 8, 9f
 Masseter muscle, 27f
 Mastectomy
 partial, 542, 543f
 radical, 541
 total
 breast removal and reconstruction, 544
 modified radical, 544, 545f
 Mastoid process, 17f, 25f, 27f
 Maturing
 end colostomy, 251f
 end ostomy, 252
 loop ostomy, 254
 McBurney's point, 239f
 McKeown esophagectomy (modified),
 three-hole approach, 60-62
 McVay repair, 352
 Medial antebrachial cutaneous nerve, 425f, 429f
 Medial arcuate ligament, 73f
 Medial circumflex femoral artery, 440, 483f
 Medial epicondyle of femur, 453f
 Medial infrageniculate approach, exposure
 of popliteal artery and vein, 454
 Medial malleolus, 455f
 Medial patellar retinaculum, 433f, 453f
 Medial pubovesical ligament, 290f
 Medial suprageniculate approach, exposure
 of popliteal artery and vein, 450
 Medial sural cutaneous nerve, 455f, 459f
 Medial to lateral approach, to right
 colectomy, 260
 Medial umbilical ligament, 213f, 235f, 247f,
 290f, 301f, 347f, 357f, 403f, 612, 613f
 Median cricothyroid ligament, 17f, 23f
 Median cubital vein, 425f, 427f
 Median nerve, 429f, 479f, 506f
 Median sacral artery, 213f, 259f, 269f, 290f,
 403f
 Median sacral vein, 205f, 269f, 445f
 Median umbilical fold, 43f, 571f
 Median umbilical ligament, 343f, 357f, 383f
 Mediastinum
 azygos system of veins, 61f
 subdivisions of, 63f
 Medulla
 adrenal, 39f, 45f
 renal, 211f
 Medullary arteriole, 39f
 Melanoma: SLNB, 553
 dye/radiotracer and injection sites, 554,
 555f
 identification of sentinel lymph node, 558,
 559f

Melanoma: SLNB (*Continued*)
 lesion drainage to lymph nodes, 556
 lymphatic drainage, 554
 Mercedes incision, in right hepatic
 lobectomy, 163f
 Mesenteric ischemia
 anterior transperitoneal exposure,
 416-418
 and configuration of graft, 417f
 celiac axis and superior mesenteric artery,
 415f
 clinical presentation, 413
 retroperitoneal exposure, 418
 through abdomen or flank, 419f
 surgical anatomy, 414
 surgical planning, 416
 Mesentericoparietal recess, 123f, 271f, 297f,
 401f
 Mesentery, root of, 43f, 175f, 293f, 623f
 Mesh reinforcement
 in repair of femoral hernia, 370, 373f
 in tension-free inguinal hernia repair, 350,
 351f
 in ventral hernia open repair, 375, 384,
 385f
 Mesoappendix, 237f, 239f
 Mesocolon, 295f
 Mesorectal fascia, and potential spaces, 290f
 Mesorectal peritoneum, 313f
 Mesorectum, 289f, 299f
 lower, anterior mesorectal anatomy, 300
 upper, posterior mesorectal anatomy, 298
 Metatarsal bones, 484f
 Metatarsal veins, 437f
 Middle cervical sympathetic ganglion, 63f,
 69f
 Middle colic artery, 55f, 96f, 175f, 189f,
 193f, 259f, 282, 409f
 Middle colic vein, 175f, 190f, 282
 Middle colic vessels, 262
 Middle mediastinum, 63f
 Middle pharyngeal constrictor muscle, 27f
 Middle rectal artery, 242f, 259f, 261f, 290f
 Middle rectal vein, 190f
 Middle scalene muscle, 393f
 Middle suprarenal artery, 45f
 Middle thyroid vein, 23f, 27f
 Midjugular nodal chain boundary, of neck
 level III, 4, 11f
 Midline raphe, in tracheotomy procedure,
 14
 Midline retroperitoneum, exposure of, 401f
 Milligan-Morgan hemorrhoidectomy, 324
 Minimally invasive surgeries
 esophagectomy, 54
 radical prostatectomy, 607
 Minor calyces, 211f
 Mobilization
 esophageal, 72-74
 gastric, 76
 of hepatic flexure, in transverse
 colectomy, 278
 of left colon, 310
 in radical nephrectomy, 600
 of pancreas, 181f
 of right hemicolon, 204
 of right hepatic lobe, 162
 of splenic flexure, 272, 278
 of thyroid gland, 26
 upper mesorectal, 274
 of urinary bladder
 in anterior pelvic exenteration, 632
 in radical cystectomy, 622
 Modified Hanley procedure, 332
 Modified radical mastectomy, 544, 545f
 Mouth cavity, 33f

Mucosa
 esophageal, 75f
 exposing, for kidney allograft, 215f
 urinary bladder, 293f
 Multiphase CT, in pancreatic cancer, 187f
 Muscle fibers, adrenal, 39f
 Muscle flap, in below-knee amputation, 463f
 Muscles
 of ankle and foot, 484f
 of axilla, 563f
 of knee, 453f
 of leg, 455f
 with superficial peroneal nerve, 499f
 of neck, 27f
 of thigh, femoral exposure, 433f
 Muscular thickening, esophageal, 75f
 Musculature
 abdominal, 377f
 infrahyoid and suprahyoid, for
 tracheotomy, 17f
 pyloric, before and after pyloroplasty, 107f
 of stomach, 121f
 Musculophrenic arteries, 379f, 509f
 Mushroom catheter, 333f
 Mylohyoid muscle, 9f, 17f, 25f, 27f
 Myofascial flaps, in above-knee amputation,
 465f
 Myopectineal orifice, 356, 357f

N

Nasal septum, 537f
 Nasopharyngeal airway, 533f
 Nasopharynx, 530
 Nasotracheal intubation, 530
 NAVEL structures, 440
 Neck
 anterior triangle of, 391f
 muscles, 27f
 nerves and fascial layers, 393f
 scintigram and sonogram of, 31f
 Neck dissection (supraomohyoid)
 incision planning and patient positioning,
 6
 level Ia-Ib, 8
 level II-III, 10
 neck anatomy for surgical planning, 4
 Necrosis, liver, 221f
 Neoplasms, ovarian, 593f
 Nephrectomy, radical
 dissection
 adrenal gland, 604
 lateral attachments divided, 606
 renal hilum, 604
 ureter, 602
 extraction, 606
 Gerota's fascia exposed, 601f
 mobilization of left colon, 600
 patient positioning and trocar placement,
 598
 preoperative imaging, 598, 599f
 surgical approach, 598
 Nerve to soleus muscle, 455f
 Nerves of Latarjet, 120
 Nervi erigentes, 233f, 312, 313f
 Neurovascular bundle, 609f
 preservation of, 614, 615f
 sectioning, and loss of erection, 629f
 Newborn, adrenal gland, 39f
 Ninth rib, 199f
 Nipple discharge, pathologic, 547
 duct excision
 and intraductal papilloma, 551f
 surgical principles, 550
 technique, 550

- Nipple discharge, pathologic (*Continued*)
 management algorithm, 549f
 preoperative workup, 548
- Nissen fundoplication
 anatomy for
 crural closure and, 78
 esophageal mobilization, 72-74
 gastric mobilization, 76
 preoperative studies, 70
 surgical principles for GERD, 66
- Nonfatty septal cirrhosis, 161f
- Nonurgent (elective) placement of chest tube, 512
- Nose
 lateral view, 531f
 nasotracheal intubation, 530
- O**
- Oblique line of thyroid cartilage, 17f
- Obturator anastomotic vessels, 445f
- Obturator artery, 213f, 361f, 403f
 aberrant, 445f
- Obturator bypass, 446, 447f
- Obturator canal, 303f, 440, 483f
- Obturator externus muscle, 440
- Obturator fascia, 331f
- Obturator foramen, 435f
- Obturator internus fascia, 290f
- Obturator internus muscle, 331f, 580f
- Obturator nerve, 235f, 301f, 383f, 460f
- Obturator vein, 291f
 cutaneous branches, 437f
- Obturator vessels, 301f, 343f, 357f
- Omental bursa, 173f, 273f, 281f, 409f
 superior recess of, 43f, 223f
- Omental foramen (Winslow), 73f, 95f, 103f, 173f, 193f, 409f
- Omental taenia, 237f
- Omental veins, 68f
- Omentum, in right colectomy, 262-264
- Omohyoid muscle, 11f, 17f, 25f, 27f, 393f, 471f
- Oophorectomy
 anatomy and dissection of adnexa, 588-592
 arteries and veins of pelvic organs, 589f
 for benign and malignant conditions, 587
 gonadal vessels and infundibulopelvic ligament, 590
 large masses and modified approaches, 592
 pelvic cavity lymphatics, 591f
 preoperative imaging, 588
 radical, 594, 595f
 surgical approach, 588
 utero-ovarian vessels, 592
- Open inguinal hernia repair
 abdominal wall, 347f
 anatomic landmarks, 346, 347f
 Bassini and McVay repairs, 353f
 exposed anatomy for, 349f
 ilioinguinal and iliohypogastric nerves, 348
 inguinal region: dissections, 343f
 patent processus vaginalis and indirect inguinal hernia, 344f
 primary tissue repair, 352
 surgical approach, 346-348
 tension-free repair, 350, 351f
 terminology, 342
 types of hernias, 345f
- Open retrograde distal pancreatectomy with splenectomy, 174-176, 175f
 division of pancreas, 176
 division of splenic artery and vein, 176
- Open surgical approach
 appendectomy, 240
 principles of exposure, 234
 cholecystectomy, 138
 critical view, 135f
 common bile duct exploration, 148, 149f
 femoral hernia repair, 370-372, 371f
 left colectomy incisions, 267f
 pyloromyotomy for pyloric stenosis, 114, 115f
- Open ventral hernia repair
 abdominal wall
 anatomy of, 376
 anterior, 379f
 posterior, 383f
 creation of retrorectus space, 380, 381f
 exposure of Cooper's ligament and pelvis, 382
 innervation of abdomen and perineum, 377f
 intercostal nerves and arteries, 378f
 lateral dissection in preperitoneal plane, 382
 mesh deployment, 384, 385f
 posterior layer reconstruction, 382
 preoperative imaging, 376
 reconstruction of linea alba, 384
 surgical principles, 376
- Opponens digiti minimi muscle, 479f
- Opponens pollicis muscle, 479f
- Oral region nerves, 397f
- Orbicularis oris muscle, 391f
- Organ transplantation
 abdominal organ donation, 204-208
 crossmatching, 203
 kidney, 210-214
 liver, 220-226
 pancreas, 216-218
- Oropharyngeal airway, 533f
- Orthotonic stomach, 121f
- Orthotopic liver transplant, 222
- Ostium
 abdominal, 579f
 of sphenoid sinus, 537f
- Ostomy
 abdominal wall anatomy
 external landmarks, 248
 preoperative imaging, 246
 creation of trephine, 248
 end colostomy, 251f
 end ostomy
 elevating bowel, 250
 maturing of, 252
 ileostomy, 249f
 Brooke technique, 253f
 loop ostomy, 254
 planned site of, 246
- Ovarian artery, 213f, 403f
- Ovarian veins, 205f
- Ovarian vessels, 293f
- Ovaries, 289f, 579f, 591f, 633f
 clear cell carcinoma of, 593f
 preservation, in hysterectomy, 584
- P**
- Pain
 in acute cholecystitis, 133f
 in biliary colic, 133f
 right lower quadrant, 232
- Palmaris longus tendon, 479f
- Pancreas, 43f, 47f, 106f
 allograft, 209f
 anatomy for preoperative evaluation, 173f
- Pancreas (*Continued*)
 division of, 176, 177f
 head of, 129f
 cancer treatment, 186
 lymph vessels and nodes, 57f
 lymphatic drainage, 179f
 mobilization of, 181f
 neck of, 195f
 division of, 178
 tail of, 38f, 199f
 artery to, 77f
- Pancreas transplantation
 allograft
 arterial reconstruction for, 217f
 portal drainage of, 219f
 backbench preparation, 216
 side-to-side duodenoenterostomy, 218
- Pancreatectomy, distal
 indications for, 171
 laparoscopic
 mobilization and dissection, 182
 trocar placement, 182
 open retrograde, with splenectomy, 174-176, 175f
 preoperative evaluation, 172
 radical antegrade modular
 pancreaticosplenectomy, 178
 with splenic preservation, 180
- Pancreatic duct, 129f, 143f
- Pancreatic vein, 201f, 209f
- Pancreatica magna, 55f, 189f
- Pancreaticoduodenal allograft, 208
- Pancreaticoduodenal arteries, 55f, 77f, 88f, 96f, 103f, 129f, 177f, 193f, 207f, 259f, 269f, 281f, 311f
- Pancreaticoduodenal nodes, 57f, 179f
- Pancreaticoduodenal vein, 97f, 115f, 195f, 201f, 291f, 405f
- Pancreaticoduodenectomy
 indications for, 185
 principles of pancreatic cancer treatment, 186
 surgical approach, 188-194
- Pancreaticosplenectomy, radical antegrade modular, 178
- Pantaloon hernia, 342
- Papilla
 major duodenal, stenosis of, 139f
 renal, 211f
 of Vater, 217f
- Papilloma, intraductal, 551f
- Para-aortic autonomic nerves, 295f
- Paraduodenal fossa, 271f, 297f, 401f
- Parasitic neoplasm of ovary, 593f
- Parathyroid glands, 27f, 29f
 anatomy and embryology of, 32-34
 ectopic, 35f
 preservation of, 30
- Parathyroidectomy
 anatomic landmarks for incision, 25f
 localizing photographs, 30
 surgical anatomy for, 27f
- Paratracheal nodes, 61f
- Paraumbilical veins, 190f, 383f
- Parenchymal dissection in hepatectomy, 164, 165f, 168, 169f
- Parietal peritoneum, 43f, 173f, 351f, 403f
- Parietal pleura, mediastinal part of, 52f
- Parietal surface of liver, 155f
- Parotid gland, 5f, 9f, 25f, 27f, 533f
- Partial mastectomy, 542, 543f
- Patella, 433f, 452f-453f, 475f
- Patellar anastomosis, 451f, 461f
- Patellar ligament, 433f, 453f, 483f
- Patellar nerve plexus, 437f
- Patent processus vaginalis, 344f

- Pathologic nipple discharge (PND), 547
 duct excision
 and intraductal papilloma, 551f
 surgical principles, 550
 technique, 550
 management algorithm, 549f
 preoperative workup, 548
- Patient positioning
 for examination of fistula in ano, 334
 for neck dissection, 5f, 6
 for retroperitoneal exposure to abdominal aorta, 418, 419f
 for transperitoneal radical nephrectomy, 598, 599f
 for visualization of perianal area, 331f
- Pecten pubis, 435f
- Pectineal fascia, 359f, 433f
- Pectineal ligament (Cooper's), 301f, 351f, 357f, 358, 383f, 433f
 exposure, in ventral hernia repair, 382
 sewn to inguinal ligament, 371f
- Pectineus muscle, 433f, 447f, 452f-453f, 460f
- Pectoralis major muscle, 25f, 27f, 378f, 509f, 517f, 545f, 551f
- Pectoralis minor muscle, 543f, 565f
- Pedicle dissection, bladder, in radical cystectomy, 628
- Pedicle ligation, prostatic, 616, 617f
- Pedunculated neoplasm of ovary, 593f
- Pelvic lymphadenectomy, 626
- Pelvic nerve, 233f
- Pelvic organs: arteries and veins, 311f, 581f, 589f
 in female pelvis, 633f
 in male pelvis, 629f
- Pelvic side wall, lateral, 301f
- Pelvic splanchnic nerves, 270f
- Pelvic viscera
 ligamentous and fascial support, 580f
 male, 631f
 and rectal cancer, 289f
- Pelvis
 bones and ligaments of, 435f
 cross section, with peritoneum removed, 585f
 exposure, in ventral hernia repair, 382, 385f
 fascial planes and pelvic contents (male), 623f
 following radical oophorectomy, 595f
 nerves of, 311f
 posterior, and lower abdominal wall, 383f
- Penis
 deep dorsal vein of, 615f
 dorsal nerve of, 331f
 fundiform ligament of, 343f
 neural and vascular supply of, 629f
 suspensory ligament of, 437f
- Peptic stenosis, 53f
- Perianal abscess, 329f
- Perianal block, 330
- Periappendicular anatomy, 235f
- Pericardiacophrenic artery, 379f
- Pericardiotomy, 519f
- Pericardium, 52f, 519f
- Perimuscular rectal venous plexus, 269f
- Perineal membrane, 289f, 383f, 631f
- Perineal nerves, 331f
- Perineum
 innervation of, 377f
 male, 631f
 MRI showing midrectal cancer, 289f
- Perirectal abscess
 anatomic description, 328
 deep postanal space abscess, 332, 333f
- Perirectal abscess (*Continued*)
 with fistula, 330
 perineal innervation and patient positioning, 331f
 sites of, 329f
 surgical management, 330-332
- Perirectal fat, rectal tumor invading, 309f
- Peristalsis, visible, in hypertrophic pyloric stenosis, 111f
- Peritoneal flap, 363f
- Peritoneal sac, 71f
- Peritoneum, 38f, 75f, 381f, 435f
 incised, and gallbladder retraction, 135f
 mesorectal, scored bilaterally, 313f
 of posterior abdominal wall, 43f, 625f
 reflected with contents, 215f
- Persistent left inferior vena cava, 211f
- Pes anserinus, 433f, 452f-453f
- Peterson's defect, 124f
- Pharyngeal branch of vagus nerve, 69f
- Pharyngeal region nerves, 397f
- Pharynx
 allergic conditions of, 533f
 developmental anatomy, 33f
 sagittal section, 527f
- Phonation, normal larynx, 529f
- Phrenic nerve, 23f, 52f, 63f, 73f, 292f, 393f, 511f
- Phrenicocolic ligament, 43f, 279f, 281f, 571f
- Phrenoesophageal ligament, 74, 75f
- Physiologic nipple discharge, 547
- Piggyback anastomosis, of donor vena cava, 227f
- Pillars, crural, 72, 73f, 76, 79f
- Piriformis muscle, 303f, 331f
- Plantaris tendon, 455f, 459f
- Platysma muscle, 5f, 25f, 57f, 391f
 elevated, 7f
- Pleura, cupula of, 15f, 23f
- Pleural cavity, costodiaphragmatic recess of, 173f
- Pleural fluid, 513f
- Pneumothorax, chest tube placement, 513f
- Polypoid adenocarcinoma, 99f
- Popliteal artery, 460f
- Popliteal artery exposure, 449
 aneurysm repair, 456f
 arteries of knee and thigh incisions, 451f
 medial infrageniculate approach, 454
 medial suprageniculate approach, 450
 muscles of knee and thigh, 453f
 muscles of leg, superficial dissection, 455f
 muscles of thigh
 anterior, 452f
 superficial/deeper dissections, 455f
 posterior approach, 454
 surgical principles, 450
- Popliteal lymph nodes, 557f
- Popliteal vein, 460f
- Popliteal vein exposure, 449
 medial infrageniculate approach, 454
 medial suprageniculate approach, 450
 muscles of knee and thigh, 450
 muscles of leg, superficial dissection, 455f
 muscles of thigh
 anterior, 450
 superficial/deeper dissections, 455f
 posterior approach, 454
 surgical principles, 450
- Porta hepatis, 223f
- Portahepatic shunts, 221f
- Portal drainage, of pancreas allograft, 219f
- Portal triad, 106f, 175f, 206
- Portal venogram, 137f
- Portocaval anastomoses, 191f
- Postcholecystectomy syndromes, 139f
- Posterior approach
 exposure of popliteal artery and vein, 454
 prostatic dissection, 610, 611f
- Posterior cecal artery, 237f, 259f, 281f, 311f
- Posterior cecal vein, 190f, 405f
- Posterior cricoarytenoid muscle, 29f
- Posterior cutaneous nerve of thigh, 460f
- Posterior facial vein, 5f
- Posterior gastric fundus, 78, 79f-80f
- Posterior intercostal artery, 3rd right, 67f
- Posterior intercostal vein, 6th right, 68f
- Posterior lateral superficial cervical nodes, 5f
- Posterior mediastinum, 63f
- Posterior parietal nodes, 61f
- Posterior scrotal nerves, 331f
- Posterior tibial artery, 459f
- Posterior tibial recurrent artery, 451f
- Posterior tibial vein, 459f
- Posterior vagal trunk, 88f
 branch to celiac plexus, 69f
- Postnecrotic cirrhosis, 161f
- Postoperative surveillance, for liver transplantation, 220
- Potential spaces, mesorectal fascia and, 290f
- Pouches, pharyngeal, 33f
- Pregnancy, symptomatic gallstone disease in, 140
- Preoperative evaluation
 for abdominoperineal resection, 308
 for above- and below-knee amputation, 457
 for distal pancreatectomy, 172
 for upper extremity AV access for hemodialysis, 422
- Preoperative imaging
 for abdominoperineal resection, 308
 for distal pancreatectomy, 172, 173f
 for fistula in ano, 334
 for left colectomy, 266
 for oophorectomy, 588
 for ostomy creation, 246
 of pyloric stenosis, 112
 for retroperitoneal sarcoma, 570, 571f
 for total mesorectal excision, 288
 for transperitoneal radical nephrectomy, 598, 599f
 for ventral hernia open repair, 376
- Preoperative localization, for parathyroidectomy, 34
- Preoperative studies, for GERD, 70
- Preperitoneal plane, lateral dissection of, 382
- Prepyloric vein, 97f, 117f, 195f
- Prerectal space, 623f
- Presacral fascia, 290f
- Presacral space, 290f
- Preservation
 of neurovascular bundle, in radical prostatectomy, 614
 of ovaries, in hysterectomy, 584
 of parathyroid glands, 30
 of spleen, in distal pancreatectomy, 180, 181f
- Prestenotic pseudodiverticula, 105f
- Pretracheal nodes, 5f, 23f
- Pretracheal venous plexus, 15f
- Prevesical space (of Retzius), 623f
- Primary tissue repair, of inguinal hernia, 352
- Proctoscopy, 309f
- Profunda femoris artery, 433f, 442, 443f, 444, 446, 461f, 475f, 483f
- Prolapsed hemorrhoids, 321f
- Proper hepatic artery, 43f, 55f, 77f, 88f, 96f, 106f, 124f, 129f, 167f, 173f, 193f, 223f
- Prostate cancer, therapeutic principles, 608

- Prostate gland, 281f, 301f, 315f
 anatomical position of, 609f
 neural and vascular supply of, 629f
- Prostatectomy
 bladder neck dissection, 614, 615f
 development of space of Retzius, 612, 613f
 division of deep dorsal venous plexus, 616
 division of urethra, 618, 619f
 neurovascular bundle preservation, 614
 posterior prostatic dissection, 610, 611f
 prostatic pedicle ligation, 616, 617f
 radical, 607
 robot-assisted, 609f
 specimen extraction, 618
 vesicourethral anastomosis, 618, 619f
- Prostatic fascia, 623f
- Prostatic pedicle ligation, 616, 617f
- Prostatic utricle, 315f
- Prosthesis, immediate postoperative, 458
- Prosthetic AV graft
 brachioaxillary, 426
 forearm looped, 426
- Pseudodiverticula, prestenotic, 105f
- Psoas major muscle, 38f, 215f, 235f, 247f, 290f, 343f, 357f, 363f, 433f, 452f
- Psoas muscle exposure, in radical nephrectomy, 603f
- PTFE bypass graft, popliteal artery, 456f
- Pubic crest, 343f
- Pubic ramus, 369f
- Pubic symphysis, 289f, 303f, 343f, 357f, 435f, 623f, 635f
- Pubic tubercle, 347f, 433f, 435f, 437f, 447f, 452f
- Pubococcygeus muscle, 303f
- Pudendal canal (Alcock's), 331f
- Pudendal nerve, 233f, 331f
- Pulmonary plexuses, 69f
- Pulmonary tractotomy, 522, 523f
- Pyloric musculature, before and after pyloroplasty, 107f
- Pyloric nodes, 57f, 179f
- Pyloric spreader, 117f
- Pyloric stenosis
 clinical presentation and diagnosis of, 110
 hypertrophic, 111f
 preoperative imaging, 112
 pyloromyotomy, 109
 laparoscopic approach, 116
 open surgical approach, 114
 principles of, 112
- Pyloromyotomy, 104
 for bleeding duodenal ulcer, 105f
 for pyloric stenosis, 112, 114, 116
- Pyloroplasty, Heineke-Mikulicz, 104, 107f
- Pylorus, 73f, 95f
 cross section of, 115f
- Pyramidalis muscle, 347f
- Q**
- Quadrangle lobe of liver, 73f
- Quadratus lumborum muscle, 38f
- Quadriceps femoris tendon, 433f, 452f-453f, 483f
- Quincke edema, 533f
- R**
- Radial artery, 423f, 425f, 427f
 cannulation, 478
- Radial nerve, superficial branch, 425f, 429f
- Radial recurrent artery, 481f
- Radical antegrade modular pancreaticosplenectomy, 178
- Radical cystectomy
 anterior pelvic exenteration
 bladder mobilization, 632
 vagina-sparing technique, 632
 indications for, 621
 pedicle dissection, 628
 pelvic lymphadenectomy, 626
 surgical approach
 bladder mobilization, 622
 dissection of ureters, 624
 urethral ligation, 630
 urethrectomy, vaginal reconstruction, 634
- Radical mastectomy, 541
 modified, 544
- Radical nephrectomy
 dissection
 adrenal gland, 604
 lateral attachments divided, 606
 renal hilum, 604
 ureter, 602
 extraction, 606
 Gerota's fascia exposed, 601f
 mobilization of left colon, 600
 patient positioning and trocar placement, 598
 preoperative imaging, 598, 599f
 surgical approach, 598
- Radical oophorectomy, 594, 595f
- Radical prostatectomy
 bladder neck dissection, 614, 615f
 development of space of Retzius, 612, 613f
 division of deep dorsal venous plexus, 616
 division of urethra, 618, 619f
 minimally invasive approaches, 607
 neurovascular bundle preservation, 614
 posterior prostatic dissection, 610, 611f
 prostatic pedicle ligation, 616
 robot-assisted, 609f
 specimen extraction, 618
 vesicourethral anastomosis, 618, 619f
- Radiocephalic AV fistula, 424, 425f
- Radiography, upper GI, 85f
- Radiotracer, for SLNB, 554
- Rami communicantes, gray and white, 69f, 88f
- Ramus marginalis mandibularis, of facial nerve, 5f
- Ramus of mandible, 27f
- Reconstruction
 after gastrectomy, 98, 99f
 after pancreaticoduodenectomy, 194
 arterial, for pancreas allograft, 217f
 in modified radical mastectomy, 544
 vaginal, in urethrectomy, 634
- Rectal cancer
 anatomy for
 colonic mobilization and dissection, 288-296
 preoperative imaging, 288
 rectal mobilization and dissection, 298-304
 endopelvic fascia and potential spaces, 290f
 historical management of, 287
 pelvic visceral and perineum, 289f
 surgical principles, 288
- Rectal fascia, 290f, 623f
- Rectal plexus, 270f
- Rectal venous plexus, 445f
- Rectosigmoid, ovarian malignancy invading, 595f
- Rectosigmoid arteries, 263f
- Rectosigmoid junction, 299f, 321f
- Rectosigmoid vein, 190f
- Rectouterine pouch (of Douglas), 289f, 579f
- Rectovaginal space, 290f
- Rectovesical pouch, 281f, 631f
- Rectum, 38f, 43f, 281f, 289f-290f, 611f, 635f
 anatomy for mobilization and dissection in TME, 298-304
 arteries and nerves of, 311f
 dissection, 312-316, 313f
 echoic pattern on ultrasound, 309f
 transection from above, 302, 303f
 transection from below, 304, 305f
- Rectus abdominis muscle, 173f, 212, 235f, 247f, 290f, 301f, 343f, 347f, 357f, 361f, 383f
- Rectus femoris muscle, 433f, 452f, 460f
- Rectus femoris tendon, 433f, 460f
- Rectus sheath, 247f, 343f, 357f, 369f, 379f, 437f
 relaxing incision in, 353f
- Recurrent laryngeal nerve, 52f, 63f, 69f, 393f
 anatomy of, 28
 intraoperative photo of, 29f
- Reducible inguinal hernia, 342
- Regenerative nodules, in cirrhosis, 161f, 221f
- Renal artery, 38f, 88f, 403f
 donor, 215f
 in relation to renal vein, 605f
 variations in, 211f
- Renal column (of Bertin), 211f
- Renal (Gerota's) fascia, 45f, 175f
- Renal impression, splenic, 199f
- Renal pelvis, 211f
- Renal vasculature, 406
- Renal veins, 38f, 61f, 68f, 205f, 403f
 donor, 215f
 left, 405f, 407f, 408
 in relation to renal artery, 605f
 variations in, 211f
- Reperfusion
 injury, 490
 portal, 226
- Resection bed
 in pancreaticoduodenectomy, 195f
 in splenectomy, 201f
- Retrocecal appendix, 239f
- Retrocecal recess, 237f
- Retroesophageal space, mobilization of, 76
- Retrograde bypass, aorto-superior mesenteric artery, 416, 418
- Retromandibular vein, 533f
- Retroperitoneal exposure
 to abdominal aorta, 418
 of iliac arteries for obturator bypass, 447f
- Retroperitoneal sarcomas
 abdominal exposure for tumor removal, 572, 573f
 preoperative imaging and incision, 570
 retroperitoneal anatomy, 571f
- Retroperitoneal structures, 261f
 aortic and iliac arterial relationships with, 403f
- Retroperitoneum, 297f, 447f
 anatomy, 571f
 aortic relationships with, 407f
 midline, exposure of, 401f
 open, 163f
- Retroprostatic space, 623f
- Retropubic space, 290f
- Retrorectus space, creation of, 380
- Retrovesical space, 623f
- Ribs
 first, 23f, 52f, 63f
 ninth, 199f
 tenth, 279f

- Right and left chest, differences between, 510
- Right atrium, 511f
- Right colectomy
- anastomosis, 264
 - identification of ileocolic vessels, 260
 - indications for, 257
 - inferior dissection, 264
 - medial to lateral approach, 260
 - middle colic vessels, 262
 - omentum and lesser sac, 262-264
 - retroperitoneal structures, 261f
 - superficial anatomy and topographic landmarks, 258
 - transection of ileocolic vessels, 262
 - variation in arteries of right colon, 262, 263f
- Right colic artery, 261f
- Right colic flexure, 73f, 106f, 121f, 175f
- Right colic vein, 190f
- Right hemicolon mobilization, 204
- Right hepatic lobectomy, 162-164, 163f, 165f
- Right laparoscopic adrenalectomy
- port site placement, 41f
 - surgical technique, 42
- Right lower quadrant anatomy, 243f
- Rigid proctoscopy, 309f
- Robot-assisted prostatectomy, 609f
- Root of mesentery, 43f, 175f, 293f, 623f
- Round ligaments
- of liver, 73f, 95f, 223f, 383f
 - of uterus, 289f, 293f, 445f, 578, 583f, 633f
- Roux-en-Y choledochojejunostomy, 225f
- Roux-en-Y gastric bypass, laparoscopic, 120-122, 123f
- Rubber band ligation, of hemorrhoids, 322
- Rupture
- of abdominal aortic aneurysm, 410
 - of ovary, 593f
- S**
- Sacral nerve, 233f
- Sacral plexus, 233f, 270f
- Sacral promontory, 235f, 289f, 295f, 299f, 303f, 435f
- Sacral sympathetic ganglion, 1st, 233f
- Sacral sympathetic trunk, 270f
- Sacrogenital fold, 43f
- Sacroiliac joint, synovial portion, 235f
- Sacrospinous ligament, 435f
- Sacrotuberous ligament, 331f, 435f
- Sacrum, 289f
- Saddlelike liver, 160f
- Saphenofemoral venous junction, 431
- exposure of, 436, 437f
- Saphenous nerve, 459f
- Saphenous opening, 369f
- Sarcomas, retroperitoneal
- abdominal exposure for tumor removal, 572, 573f
 - margin-negative resection for, 569
 - preoperative imaging and incision, 570
- Sartorius muscle, 433f, 440, 452f-453f, 460f
- Sartorius tendon, 433f
- Scalene muscles, 17f, 25f, 27f, 52f, 517f
- Scalene node, 5f
- Scapula, 17f
- Scarpa's fascia, 281f
- Sciatic nerve, 460f
- Segments of liver, 155f
- Selective neck dissection
- incision planning and patient positioning, 6
 - level Ia-Ib, 8
 - level II-III, 10
 - neck anatomy for surgical planning, 4
- Semimembranosus bursa, 453f
- Semimembranosus muscle, 455f, 460f
- Semimembranosus tendon, 453f
- Seminal colliculus, 315f
- Seminal vesicle, 301f, 315f, 610, 611f, 623f, 631f
- Semitendinosus muscle, 455f, 460f
- Semitendinosus tendon, 433f
- Semiurgent placement of chest tube, 512
- Sensory branches to larynx, 29f
- Sentinel lymph node biopsy (SLNB)
- in cancer management, 553
 - dye/radiotracer and injection sites, 554, 555f
 - identification of sentinel lymph node, 558, 559f
 - lesion drainage to lymph nodes, 556
 - lymphatic drainage, 554
- Sentinel lymph nodes of Virchow (or Troisier), 5f
- Sepsis
- complication of splenectomy, 198
 - of fistula tract, 337f
- Serosa
- splenic, 199f
 - visceral peritoneum, 239f
- Serratus anterior muscle, 377f, 473f, 481f, 551f
- digitations of, 517f
- Setons, for fistula drainage, 334, 337f
- Shoe-shine maneuver, 80f
- Short gastric arteries, 77f, 84f, 88f, 96f, 193f, 199f
- Short gastric veins, 68f, 97f, 115f, 190f, 195f, 201f, 209f
- Short gastric vessels, 43f, 55f, 76, 174
- Short hepatic vein, 163f
- Shouldice repair, 352
- Sigmoid arteries, 242f, 259f, 269f, 281f, 293f
- Sigmoid colon, 235f, 295f, 403f
- in left colonic resection, 274
- Sigmoid mesocolon, 38f, 43f, 259f, 281f, 293f, 403f
- Sigmoid vein, 190f
- Signs, of appendicitis, 232
- Simple perirectal abscess, 328
- Sinus endoscopy, 537f
- Sinusoids, 320
- Skeletonization, left hemicolectomy, 275f
- Skin flaps
- in axillary lymph node dissection, 564
 - in modified radical mastectomy, 544, 545f
- Sliding hiatal hernia, 70, 71f
- Slit catheter technique, 495f
- SLNB. *See* Sentinel lymph node biopsy (SLNB)
- Small intestine, 235f, 409f
- area for, 38f
 - innervation, 270f, 629f
- Small saphenous vein, 437f, 455f, 459f
- Soft palate, angioneurotic edema, 533f
- Soleus muscle, 453f, 455f, 459f
- Space of Retzius, development of, 612, 613f
- Specimen removal
- in hysterectomy, 584
 - in radical prostatectomy, 618
- Spermatic cord, 301f, 347f, 349f, 357f, 359f, 383f, 437f
- Sphincter urethrae, 289f, 301f, 633f
- Spinal accessory nerve, 12f
- Spinal accessory nodes, 5f
- Spinal nerve
- C2 and C3, 393f
 - ventral root, 88f
- Spinal nerve trunk, 377f
- Spinal sensory ganglion, 88f, 235f
- Spleen, 73f, 95f, 297f
- area for, 38f
 - mobilization of, 182
 - omental adhesions, 273f
 - preservation, in distal pancreatectomy, 180, 181f
 - and surrounding structures, 199f
 - veins of, 115f
- Splenectomy
- indications for, 197
 - laparoscopic technique, hand-assisted or open approach, 200
 - open retrograde distal pancreatectomy with, 174-176, 175f
 - surgical principles, 198
- Splenic artery, 43f, 55f, 67f, 77f, 84f, 87f, 96f, 103f, 124f, 129f, 177f, 199f
- division of, 176, 177f
- Splenic flexure, 45f, 73f, 95f, 175f, 193f, 279f, 401f
- in left colonic resection, 272
 - mobilization, in transverse colectomy, 278
 - in TME, 296, 297f
- Splenic nodes, 57f, 179f
- Splenic plexus, 87f
- Splenic pulp, 199f
- Splenic trabeculae, 199f
- Splenic vein, 45f, 47f, 57f, 68f, 97f, 195f, 199f, 221f
- division of, 177f
- Splenius capitis muscle, 27f
- Splenorenal ligament, 38f, 43f, 173f, 199f, 281f
- Stapled hemorrhoidopexy, 324
- Stapling
- large venous structures, 169f
 - in pulmonary tractotomy, 523f
- Stellate ganglion, branch to esophagus and recurrent nerve, 69f
- Stenosis
- of carotid artery, 391f
 - of major duodenal papilla, 139f
 - pyloric. *See* Pyloric stenosis
- Sternocleidomastoid muscle, 5f, 12f, 25f, 27f, 57f, 391f, 473f
- edge of, 15f
 - medial margin of, 23f
 - retracted, 11f
 - sternal and clavicular heads, 27f
 - unwrapping from investing fascia, 10
- Sternohyoid muscle, 11f, 17f, 25f, 26, 27f
- Sternothyroid muscle, 25f, 26, 27f
- Sternum, 17f, 378f
- manubrium of, 25f, 27f
- Stoma site
- in end colostomy, 251f
 - in ileostomy, 249f
 - location of, 246
 - in loop-end ileostomy, 255f
- Stomach, 52f, 129f, 173f, 409f, 411f
- area for, 38f
 - arterial supply, 55f, 84f, 87f, 96f, 103f
 - bleeding lesions of, 105f
 - cardiac part, 73f, 75f
 - fundus, 47f
 - posterior, 78, 80f
 - greater curvature, 95f
 - mobilization of, 77f
 - herniated portion of, 71f
 - innervation, 86, 87f-88f

- Stomach (*Continued*)
 lesser curvature
 anterior vagal branch to, 69f
 perforated ulcer of, 83f
 posterior wall, 273f
 relationship to greater omentum, 280
 venous and lymphatic drainage, 97f
 Stomach pouch, 120, 121f
 Strangulated hemorrhoids, 324
 Strangulated inguinal hernia, 342, 345f
 Strap muscles
 fascia over, 5f
 in tracheotomy procedure, 14
 Stricture, of bile duct, 139f
 Styloglossus muscle, 533f
 Stylohyoid muscle, 11f, 17f, 25f, 27f, 533f
 Styloid process, 17f, 27f
 Subclavian artery, 29f, 52f, 67f, 379f, 397f, 509f
 Subclavian trunk and node, 5f
 Subclavian vein, 23f, 52f, 61f, 68f
 catheterization, 472, 473f
 Subclavicular nerves, 393f
 Subcostal muscles, 377f
 Subcostal nerve, 38f, 437f
 Subcutaneous tissue
 abdominal, 381f
 rectus sheath, 247f
 Subhiatal fat ring, 75f
 Sublay mesh, in ventral hernia open repair, 375, 384
 Submandibular boundary of neck level I, 4
 Submandibular ganglion, 9f
 Submandibular gland, 9f, 25f, 27f
 Submandibular nodes, 5f
 Submental boundary of neck level I, 4, 9f
 Submental nodes, 5f
 Submucosa
 esophageal, 75f
 vermiform appendix, 239f
 Submucous abscess, 329f
 Submucous venous plexus, 68f
 Subphrenic recess, 175f
 Subplatysmal flap, raising, 6
 Subpyloric nodes, 97f
 Subsartorial (Hunter's) canal, 432
 Superficial anorectal abscess, 330
 Superficial cervical artery, 23f
 Superficial circumflex iliac artery, 379f, 461f
 Superficial circumflex iliac vessels, 437f
 Superficial epigastric vessels, 437f
 Superficial femoral artery, 433f
 Superficial fibular (peroneal) nerve, 437f, 459f, 494f
 Superficial fistula, 335f
 Superficial inguinal ring, 344f, 347f, 437f
 Superficial peroneal nerve, 499f
 Superficial posterior compartment of leg, 459f
 Superior cervical sympathetic ganglion, 63f, 69f
 Superior deep lateral cervical nodes, 5f
 Superior duodenal fold, 123f, 297f, 401f
 Superior duodenal fossa, 297f, 401f
 Superior epigastric artery, 378f
 Superior epigastric vessels, 173f
 Superior fibular retinaculum, 455f
 Superior flap dissection, along deep surface of anterior facial vein, 5f
 Superior ganglion of vagus nerve, 69f
 Superior gluteal artery, 213f, 403f
 Superior gluteal vein, 291f, 445f
 Superior hemorrhoidal artery, 233f
 Superior hemorrhoidal plexus, 233f
 Superior hypogastric plexus, 270f
 Superior ileocecal recess, 237f
 Superior intercostal veins, 61f, 68f
 Superior laryngeal artery, 23f, 27f
 Superior laryngeal nerve, 23f, 29f, 69f, 397f
 anatomy of, 28
 external branch of, 27f, 28
 Superior lateral genicular artery, 451f
 Superior lateral superficial cervical node, 5f
 Superior mediastinum, 63f
 Superior mesenteric artery, 38f, 55f, 57f, 77f, 87f, 103f, 129f, 175f, 177f, 188, 194, 205f, 233f, 237f, 261f, 291f, 403f, 408
 accessible portions, 416
 below pancreas, 415f
 exposure, in mesenteric ischemia, 414
 Superior mesenteric ganglion, 88f
 Superior mesenteric nodes, 57f, 179f
 Superior mesenteric plexus, 87f, 233f
 Superior mesenteric vein, 57f, 68f, 97f, 115f, 175f, 188, 189f, 194, 201f, 219f
 Superior mesenteric vessels, 43f
 Superior pancreatic nodes, 57f, 97f, 179f
 Superior parathyroid gland, 27f, 29f, 32, 33f
 Superior pharyngeal constrictor muscle, 533f
 Superior phrenic nodes, 61f
 Superior polar artery, 55f, 96f
 Superior ramus of pubis, 435f, 453f
 Superior rectal artery, 259f, 269f, 281f, 290f, 311f
 Superior rectal veins, 190f, 405f
 Superior rectal vessels, 43f
 Superior suprarenal arteries, 45f
 Superior thyroid artery, 23f, 27f, 29f, 397f
 Superior thyroid nodes, 5f
 Superior thyroid vein, 23f, 27f
 Superior vena cava, 23f, 61f, 68f
 Superior vesical arteries, 213f, 301f, 383f, 403f
 Supraclavicular nerves, 5f, 429f
 Supraclavicular nodes, 5f
 Supradiaphragmatic fascia, 75f
 Supraduodenal artery, 55f, 77f, 84f, 96f, 103f, 177f, 189f
 Suprahepatic aorta, 207f
 Suprahepatic vena cava anastomosis, 225f
 Suprahypoid node, 5f
 Supraleator abscess, 328, 330
 Supraomohyoid neck dissection
 incision planning and patient positioning, 6
 level Ia-Ib, 8
 level II-III, 10
 neck anatomy for surgical planning, 4
 Suprapancreatic dissection, 193f
 Suprapyloric nodes, 97f
 Suprarenal glands, 38f, 43f, 106f, 175f, 199f, 211f
 arteries and veins of, 45f
 Suprarenal plexus, 292f
 Suprarenal vein, 68f, 205f, 407f
 Suprascapular artery, 23f, 29f, 393f
 Suprasphincteric fistula, 334, 336
 Suprasternal notch, 15f, 35f
 Suprasternal space (of Burns), 25f
 Supravesical fossa, 383f
 Surgical anatomy
 fasciotomy
 forearm, 504
 leg, 496-498
 hysterectomy, 578
 laparoscopic Roux-en-Y, 120-122
 mesenteric ischemia, 414
 parathyroidectomy, 27f
 thyroidectomy, 22-24
 Suspensory ligament
 of breast, 551f
 of ovary, 289f-290f, 579f-580f
 of penis, 437f
 Sympathetic cardiac branches, 63f
 Sympathetic ganglion, 12th thoracic, 233f
 Symptomatic gallstones, 132
 Symptomatic hemorrhoids, 320, 322
 Syndesmotic portion of sacroiliac joint, 235f
- T**
- T-tube, closure of laparoscopic cholecystectomy over, 147f, 149f
 Tachyoidia, 139f
 Taenia libera, 237f, 242f, 321f
 Technetium 99m sestamibi scan
 of cricoid cartilage, 35f
 of neck, 31f
 Tendinous arch
 of levator ani muscle, 303f
 of pelvic fascia, 290f
 Tendon of semitendinosus muscle, 453f
 Tendons of wrist, 479f
 Tension-free inguinal hernia repair, 346, 350, 351f
 Tensor fasciae latae muscle, 433f, 452f, 460f
 Tenth rib, 279f
 Terminal ileum, 237f, 242f-243f
 Testicular artery, 379f
 Testicular (ovarian) artery and plexus, 292f
 Testicular (ovarian) artery and vein, 38f, 269f, 405f
 Testicular vessels, 43f, 242f, 261f, 293f, 301f, 347f, 351f, 359f, 433f
 Thenar muscles, 506f
 Thigh
 arteries and nerves, 483f
 cross-sectional anatomy, 460f
 muscles, 433f
 anterior view, 452f
 deep dissection, 453f
 posterior view, 455f
 Thoracic anatomy, for chest tube placement, 509f
 Thoracic aorta, 52f, 67f
 Thoracic cardiac branch of vagus nerve, 63f
 Thoracic duct, 5f, 52f, 61f, 68f, 173f, 292f
 Thoracic ganglion of sympathetic trunk, 88f
 Thoracic sympathetic ganglion, 3rd, 69f
 Thoracic sympathetic trunk, 69f
 Thoracoacromial artery, 517f
 Thoracodorsal artery, 481f, 565f
 Thoracodorsal nerve, 481f, 565f
 Thoracotomy for trauma, emergency
 aortic clamping, 522
 cardiac massage, 520, 521f
 clamshell and left anterolateral approaches, 517f
 control at hilum and injury repair, 520-522
 control of cardiac injury, 518
 deflation of left lung, 516
 indications for, 515
 lung mobilization, 518
 pericardiectomy and cardiorrhaphy, 519f
 pulmonary tractotomy, 523f
 surgical principles, 516
 Thorax, 509f
 Three-hole esophagectomy (modified McKeown), 60-62
 Thrombosis, cephalic vein, 423f
 Thyroarytenoid muscle, 29f
 Thyrocervical trunk, 23f, 29f, 52f, 67f, 393f, 397f

- Thyroepiglottic muscle, 29f
 Thyrohyoid membrane, 17f, 23f, 29f
 Thyrohyoid muscle, 17f, 25f, 27f
 Thyroid cartilage, 15f, 17f, 23f, 25f
 lamina removed, 29f
 Thyroid gland, 15f, 17f, 23f, 473f
 anatomy for exposing, 26
 embryonic, 33f
 fibrous capsule, 29f
 right lobe, 27f
 Thyroid isthmus, 33f
 Thyroidectomy
 indications, 21
 surgical anatomy for, 22-24, 27f
 Tibia, 459f, 489f
 Tibial collateral ligament, 453f
 Tibial nerve, 455f
 Tibial tuberosity, 433f, 453f
 Tibialis anterior muscle, 459f
 Tibialis posterior muscle, 459f
 Tibialis posterior tendon, 455f
 Tissue sampling, endoscopic, 85f
 TME. *See* Total mesorectal excision (TME)
 Toldt's fascia, 272, 299f
 Tongue, embryonic, 33f
 Total mastectomy
 breast removal and reconstruction, 544
 modified radical, 544, 545f
 Total mesorectal excision (TME)
 anatomy for
 colonic mobilization and dissection,
 288-296
 preoperative imaging, 288
 rectal mobilization and dissection,
 298-304
 arteries and veins of colon and rectum,
 291f
 autonomic nerves and ganglia of
 abdomen, 292f
 endopelvic fascia and potential spaces,
 290f
 inferior mesenteric artery and vein
 anterior view, 294, 295f
 medial oblique view, 296, 297f
 lower mesorectum: anterior mesorectal
 anatomy, 298, 300
 pelvic viscera and perineum, 289f
 rectal transection
 from above, 302
 from below, 304
 intersphincteric transanal, 305f
 splenic flexure, 296
 stapled rectal transection, 303f
 surgical principles, 288
 upper mesorectum: posterior mesorectal
 anatomy, 298, 299f
 Totally extraperitoneal (TEP) hernia repair
 femoral, 372
 inguinal, 356, 364, 365f
 Trachea, 15f, 23f, 29f, 52f, 57f, 67f, 393f,
 531f
 embryonic, 33f
 Tracheal intubation
 airway anatomy
 larynx, 528, 529f
 lower airway, 530
 nose and nasopharynx, 530
 pharynx: sagittal section, 527f
 trachea, 531f
 upper airway, 526-528
 anesthesia, 534
 failed, 538
 flexible fiberoptic bronchoscopy
 nasotracheal approach, 536
 oral approach, 536
 indications for, 532, 533f
 Tracheal intubation (*Continued*)
 laryngoscopy, 534, 535f
 preintubation airway examination,
 532-534
 sinus endoscopy, 537f
 Tracheobronchial nodes, 61f
 Tracheostomy tube, in place, 15f
 Tracheotomy
 anatomy with trachea visualized, 16
 anatomy with tracheotomy tube in place,
 18
 external anatomy, 14
 indications and principles, 13-14
 preoperative considerations, 14
 strap muscles and midline raphe, 14
 thyroid isthmus, 16
 Tractotomy, pulmonary, 522, 523f
 Transabdominal laparoscopic adrenalectomy,
 40
 Transabdominal preperitoneal (TAPP) hernia
 repair
 femoral, 372, 373f
 inguinal, 356, 362-364, 363f
 Transampullary septum, 139f
 Transcystic approach, to common bile duct
 exploration, 146, 147f
 Transductal/choledochotomy approach, to
 common bile duct exploration, 146,
 147f
 Transhiatal esophagectomy, 54-56
 Transperitoneal medial visceral rotation,
 419f
 Transperitoneal radical nephrectomy,
 laparoscopic
 dissection
 adrenal gland, 604
 lateral attachments divided, 606
 renal hilum, 604
 ureter, 602
 extraction, 606
 Gerota's fascia exposed, 601f
 mobilization of left colon, 600
 patient positioning and trocar placement,
 598
 preoperative imaging, 598, 599f
 surgical approach, 598
 Transplantation, organ
 abdominal organ donation, 204-208
 crossmatching, 203
 kidney, 210-214
 liver, 220-226
 pancreas, 216-218
 Transsphincteric fistula, 334, 335f, 336
 Transversalis fascia, 173f, 247f, 290f, 301f,
 344f, 351f, 357f, 381f, 433f
 Transverse cervical artery, 29f, 393f
 Transverse cervical chain of nodes, 5f
 Transverse cervical nerves, 5f, 393f
 Transverse colectomy
 creation of anastomosis, 284
 hepatic flexure, 278
 indications for, 277
 middle colic artery and vein, 282
 relationships of greater omentum to
 transverse colon and stomach, 280
 splenic flexure, 278
 surgical principles, 277
 Transverse colon, 106f, 115f, 123f, 129f,
 175f, 199f, 297f, 401f
 relationship to greater omentum, 280
 Transverse intermuscular septum, 459f
 Transverse mesocolon, 38f, 43f, 123f, 175f,
 189f, 199f, 259f, 271f, 297f, 401f
 Transverse pancreatic artery, 55f, 96f,
 189f
 Transverse perineal ligament, 290f, 303f
 Transversus abdominis muscle, 38f, 235f,
 247f, 343f, 347f, 359f, 381f, 385f, 509f
 Transversus thoracis muscle, 378f
 Trapdoor flap, 16
 Trapezius muscle, 5f, 17f, 25f, 27f, 377f-
 378f, 471f
 Trepine creation, for ostomy, 248
 Triangle of auscultation, 511f
 Triangle of doom, 360, 361f
 Triangle of pain, 360, 361f
 Triangular ligament of liver, 43f, 223f, 417f,
 571f
 mobilization of, 167f
 Triceps brachii muscle, 481f
 Trocar placement in laparoscopic procedures
 cholecystectomy, 134
 distal pancreatectomy, 182
 transperitoneal radical nephrectomy, 598
 Truncal vagotomy
 decision making regarding, 86
 surgical approach, 90
 Tube graft, in aortic aneurysm repair, 411f
 Tubercle of Zuckerkandl, 28, 29f
 Tumors
 adrenal, 37
 esophageal, 53f
 ovarian, large masses, 592
 rectal, invasion of perirectal fat, 309f
 retroperitoneal, 571f
 in tail of pancreas, 173f
 Turbinates, 537f
- ## U
- Ulcers
 anterior and posterior erosion, 82
 Crohn, 337f
 duodenal, 81, 85f
 gastric, 81, 85f
 multiple (kissing ulcers), 105f
 surgical decision making, 86
 Ulnar nerve, 429f, 481f, 506f
 Ultrasonography
 duplex, preoperative vessel mapping, 422,
 423f
 endorectal, 309f
 in identification of target vessels, 469
 intraoperative, of gallbladder, 136
 of neck, 31f
 of pyloric stenosis, 112, 113f
 Umbilical artery, 213f, 301f, 403f
 Umbilical prevesical fascia, 301f, 347f, 383f
 Umbilicovesical fascia, 623f
 Umbilicus, 190f, 383f
 Uncinate process of pancreas, 106f, 175f, 194
 Upper abdomen, sagittal view, 173f
 Upper airway anatomy for tracheal
 intubation, 526-528
 larynx, 528, 529f
 nose and nasopharynx, 530
 pharynx, 527f
 preintubation airway examination,
 532-534, 533f
 Upper extremity AV access for hemodialysis
 AV fistulas, 424, 425f
 cutaneous innervation of upper limb, 428,
 429f
 duplex ultrasound vein mapping, 423f
 factors for success, 421
 preoperative evaluation, 422
 prosthetic AV graft, 426, 427f
 Upper GI bleeding, 102
 Upper GI contrast studies, of pyloric
 stenosis, 113f
 Upper GI series, 70

- Upper jugular nodal chain boundary, of
neck level II, 4, 11f
- Upper limb
cutaneous innervation of, 429f
nerves of, 503f
- Upper mesorectum
mobilization, 274
posterior mesorectal anatomy for TME,
298
- Upper posterior mesorectal dissection, 299f
- Urachus, 381f, 612, 613f, 623f, 631f
- Ureteroneocystostomy, 214, 215f
- Ureters, 38f, 43f, 209f, 235f, 242f, 261f,
269f, 289f, 315f, 359f, 383f
anatomic relations of, 293f
arteries of, 213f, 403f
dissection
in radical cystectomy, 624
in radical nephrectomy, 602-606
injury to, 578, 581f
- Urethra, 289f, 303f, 617f
division of, 618, 619f
female, 633f
ligation of, in cystectomy, 630
- Urethral meatus, 635f
- Urethrectomy, in radical cystectomy, 634,
635f
- Urgent placement of chest tube, 512
- Urinary bladder, 38f, 43f, 215f, 242f, 270f,
289f, 315f, 347f, 435f
arteries of, 213f
cancer, cystectomy for, 621
lymph vessels and nodes of, 627f
mobilization
in anterior pelvic exenteration, 632
in radical cystectomy, 622
neck of, dissection of, 614, 615f
trigone of, 315f
- Urogenital diaphragm, 615f
- Uterine artery, 213f, 403f
- Uterine tubes, 579f
- Utero-ovarian vessels, 592
- Uterosacral ligaments, 289f-290f, 578
- Uterovaginal venous plexus, 445f
- Uterus, 579f, 591f
anterior retraction, 313f
body of, 289f
hysterectomy
abdominal, 583f
surgical anatomy, 578
surgical approach, 582-584
total abdominal extrafascial, 577
- V**
- Vagal control of gastric secretion, 89f
- Vagal trunk, 87f
- Vagina, 289f, 303f
in abdominoperineal resection, 314
closed, in perineal dissection, 317f
reconstruction, in urethrectomy, 634
sparing technique, in anterior pelvic
exenteration, 632
- Vaginal artery, 580f
- Vaginal fornix, 289f
- Vagotomy
cuts, 91f
decision making regarding, 86
- Vagovagal reflex, 89f
- Vagus nerve (X), 23f, 29f, 52f, 63f, 69f, 91f,
233f, 393f
- Vas deferens, 610, 611f
- Vascular fold of cecum, 237f
- Vasculature
abdominal, 124f
axillary, 563f
pelvic organs, 581f, 589f
renal, 211f, 406
- Vastus intermedius muscle, 433f, 452f-453f,
460f
- Vastus lateralis muscle, 433f, 447f, 452f,
460f, 475f
- Vastus medialis muscle, 433f, 452f-453f,
460f
- Venae comitantes of vagus nerve, 68f
- Venous blood, deoxygenated, 225f
- Venous catheterization, 470
- Venous drainage
left colon, 268
spleen, 201f
stomach, 97f
- Venous supply
abdominal organs, 209f
colon and rectum, 291f
duodenum, 195f
esophagus, 68f
large intestine, 269f
leg, 461f
mediastinal system of, 61f
pancreas, 195f
spleen, 195f
stomach, 115f, 195f
- Ventral hernia open repair
abdominal wall
anatomy of, 376
anterior, 379f
posterior, 383f
creation of retrorectus space, 380, 381f
exposure of Cooper's ligament and pelvis,
382
innervation of abdomen and perineum,
377f
intercostal nerves and arteries, 378f
lateral dissection in preperitoneal plane,
382
- Ventral hernia open repair (*Continued*)
mesh deployment, 384, 385f
posterior layer reconstruction, 382
preoperative imaging, 376
reconstruction of linea alba, 384
surgical principles, 376
- Vermiform appendix, 235f, 237f
- Vertebral artery, 29f, 67f, 393f, 397f
- Vertebral column, 73f
- Vertebral ganglion, 63f
of cervical sympathetic trunk, 69f
- Vertebral vein, 61f, 68f
- Vesical plexus, 270f
- Vesical venous plexus, 445f
- Vesicocervical space, 290f
- Vesicosacral (sacrogenital) fold, 623f
- Vesicourethral anastomosis, 618, 619f
- Vesicouterine pouch, 289f
- Visceral surface
of liver, 155f, 173f
of spleen, 199f
- Visceral vessels
anterior transperitoneal exposure,
416-418
aortic relationship with, 409f
- Vocalis muscle, 29f
- Volar forearm incision, 505f
- W**
- Warning triangles, inguinal region, 360,
361f
- White rami communicantes, 378f
- White ramus, 233f, 292f
- Wick catheter technique, 495f
- Wrist, tendons and nerves of, 479f
- X**
- Xiphoid process of sternum, 509f
- Y**
- Y graft, in pancreas transplantation, 216,
217f
- Z**
- Z line, juncture of esophageal and gastric
mucosa, 75f
- Zona fasciculata, 39f
- Zona glomerulosa, 39f
- Zona reticularis, 39f